



New molecular classification of large cell neuroendocrine carcinoma and small cell lung carcinoma with potential therapeutic impacts

Sylvie Lantuejoul^{1,2}, Lynnette Fernandez-Cuesta³, Francesca Damiola¹, Nicolas Girard⁴, Anne McLeer^{2,5}

¹Department of Biopathology, Pathology Research Platform- Synergie Lyon Cancer- CRCL, Centre Léon Bérard Unicancer, Lyon, France;

²Université Grenoble Alpes, Grenoble, France; ³Section of Genetics, International Agency for Research on Cancer (IARC-WHO), Lyon, France;

⁴Institut Curie, Institut du Thorax Curie Montsouris, Paris, France; ⁵Department of Pathology and Cancer Molecular Genetics Platform, CHU Grenoble Alpes, Grenoble, France

Contributions: (I) Conception and design: All authors; (II) Administrative support: All authors; (III) Provision of study materials or patients: All authors; (IV) Collection and assembly of data: All authors; (V) Data analysis and interpretation: All authors; (VI) Manuscript writing: All authors; (VII) Final approval of manuscript: All authors.

Correspondence to: Sylvie Lantuejoul, MD, PhD. Département de Biopathologie, Plateforme Anapath Recherche Synergie Lyon Cancer-Est CRCL, Centre de Lutte Contre le Cancer UNICANCER Léon Bérard, 28 rue Laënnec, 69008 Lyon, France. Email: sylvie.lantuejoul@lyon.unicancer.fr.

Abstract: Large cell neuroendocrine carcinoma (LCNECs) and small cell lung carcinomas (SCLCs) are high-grade neuroendocrine carcinomas of the lung with very aggressive behavior and poor prognosis. Their histological classification as well as their therapeutic management has not changed much in recent years, but genomic and transcriptomic analyses have revealed different molecular subtypes raising hopes for more personalized treatment. Indeed, four subtypes of SCLCs have been recently described, SCLC-A driven by the master gene ASCL1, SCLC-N driven by NEUROD1, SCLC-Y by YAP1 and SCLC-P by POU2F3. Whereas SCLC standard of care is based on concurrent chemoradiation for limited stages and on chemotherapy alone or chemotherapy combined with anti-PD-L1 checkpoint inhibitors for extensive stage SCLC, SCLC-A variants could benefit from DLL3 or BCL2 inhibitors, and SCLC-N variants from Aurora kinase inhibitors combined with chemotherapy, or PI3K/mTOR or HSP90 inhibitors. In addition, a new SCLC variant (SCLC-IM) with high-expression of immune checkpoints has been also reported, which could benefit from immunotherapies. PARP inhibitors also gave promising results in combination with chemotherapy in a subset of SCLCs. Regarding LCNECs, they represent a heterogeneous group of tumors, some of them exhibiting mutations also found in SCLC but with a pattern of expression of NSCLC, while others harbor mutations also found in NSCLC but with a pattern of expression of SCLC, questioning their clinical management as NSCLCs or SCLCs. Overall, we are probably entering a new area, which, if personalized treatments are effective, will also lead to the implementation in practice of molecular testing or biomarkers detection for the selection of patients who can benefit from them.

Keywords: Lung cancer; neuroendocrine; high-grade; molecular; classification

Submitted Feb 16, 2020. Accepted for publication May 12, 2020.

doi: 10.21037/tlcr-20-269

View this article at: <http://dx.doi.org/10.21037/tlcr-20-269>

Introduction

Lung neuroendocrine (NE) neoplasms account for approximately 20% of all lung cancers. They can be subdivided into low- and intermediate-grade NE tumors

represented by typical and atypical carcinoids, and high-grade NE carcinomas represented by large cell neuroendocrine carcinoma (LCNEC) and small cell lung carcinoma (SCLC). LCNEC and SCLC account for 3%

and 13–15% of all lung cancers, respectively. In recent years, the incidence of SCLC has slightly decreased, whereas that of LCNEC has discreetly raised (1,2). The vast majority of LCNEC and SCLC patients are heavy smokers around 65 years of age, with metastatic disease at diagnosis. Both carcinoma types are very aggressive, with 5-year overall survival rates below 15–25% (LCNEC) and 5% (SCLC) for extensive stages (2,3). However, the therapeutic management of NSCLCs and SCLCs has not changed much in recent years, favoring for SCLCs platinum and etoposide-based chemotherapy and for LCNECs therapies close enough to that of NSCLCs.

However, whereas the histological classifications were unchanged until recently, several publications have dismembered LCNECs and SCLCs at the genomic and transcriptomic levels, leading to the identification of new molecular subtypes. The LCNEC group is heterogeneous, constituted both by tumors that harbor mutations that can be found in SCLC but with an expression pattern typical of NSCLC, and by tumors carrying typical NSCLC mutations but with a pattern of expression of SCLC, questioning their clinical management as NSCLCs or SCLCs. Regarding SCLCs, different “variants” have been successively described besides the predominant “classic” subtype, based on morphology, immunophenotype and expression profiles, and this distinction could allow for more personalized treatments.

SCLC

Morphological classification

According to the 2015 classification of lung tumors (3,4), SCLCs are defined as malignant carcinomas with NE characteristics. They belong to the group of neuroendocrine neoplasms (NENs) of the lung and are the most aggressive NENs with the worst prognosis. Since the 2004 WHO classification (5), only pure SCLC and combined SCLC have been recognized. On histopathological examination, pure SCLC is composed of a dense proliferation of small tumor cells, arranged in sheets or ribbons, with extensive areas of necrosis. Less frequently, NE (organoid) features such as rosettes, palisades and nests may be found. At high power fields, tumor cells are round to spindle-shaped; they usually measure less than the size of 3 resting lymphocytes and have a sparse cytoplasm. The chromatin is finely granular, with a typical salt and pepper appearance and with inconspicuous nucleoli. Nuclear molding is common

as well as apoptotic bodies and nuclear debris known as the Azzopardi effect. Mitoses are also numerous, with an average number of 80 per 2 mm² area. These features are most evident in surgical specimens where tumor cells appear larger with a distinct cytoplasm and a focal vesicular chromatin (6). Combined SCLCs account for 10% to 25% of all SCLC and are defined by a mixture of pure SCLC and of adenocarcinoma, squamous cell, large cell or sarcomatoid (spindle or giant cells) carcinoma (4,5), whatever the amount of NSCLC component. In contrast, for combined LCNEC and SCLC, a minimum of 10% of LCNEC is required. Combined SCLCs are more frequently diagnosed on widely sampled surgical specimens in comparison to biopsies (7,8). Combined SCLC and pure SCLC share the same epidemiology and clinical presentation, even if combined SCLC tends to be more peripheral and could harbor a worse prognosis, possibly due to relative resistance of non-SCLC components to SCLC standard chemotherapy (9). Interestingly, an intermediate variant of SCLC was present in the 1981 WHO classification (10) and was defined by larger cells with distinct cell borders, a moderate amount of eosinophilic cytoplasm, and a single nucleus with a prominent central nucleolus and paranucleolar chromatin clearing (11). This intermediate subtype of SCLC was then removed from the subsequent classifications, the presence of larger cells being attributed to the larger size of the samples, with no significance per se.

Immunophenotype

Immunohistochemistry can be of great help to assert the diagnosis of SCLC, particularly on small biopsies when tumor cells are crushed. The vast majority of SCLCs diffusely express Achaete-Scute Family BHLH Transcription Factor 1 (ASCL1, also called hASH1) (12,13) as well as CD56 (NCAM1) with a membrane staining (14,15). In contrast, synaptic vesicle protein Synaptophysin and dense-core associated protein Chromogranin A cytoplasmic stainings are observed in 54% and in 37% of the cases, respectively, and can be focal (3,4,16-19). In addition, thyroid transcription factor 1 (TTF1) is expressed in 90% of SCLCs (20). However, 10% to 25% of SCLCs could lose neuroendocrine markers (4,21) and this absence seems to be a characteristic of the intermediate variant described by Gazdar *et al.* in 1985 (11). In addition, some of the SCLCs with negative neuroendocrine markers have also been shown to lose cytokeratin and express vimentin. P16 nuclear staining is observed in almost all SCLCs, unlike

RB1, which is assumed to be absent (22,23). Regarding pathogenesis, SCLCs were initially supposed to arise from normal bronchial NE Kulchintsky-type cells, involved in lung growth and differentiation through the activation of airway chemoreceptors (24). It is now believed, based on genomic profiling studies, that SCLC could derive from multipotent precursor cells common to NE and non-NE pulmonary neoplasms. Indeed, Sutherland *et al.* (25) showed in transgenic mice that, while NE cells serve as the prevalent cell of origin of SCLC, SCLC can also arise, albeit with a lesser penetrance, from alveolar type II cells in which *Trp53* and *Rb1* have been inactivated. The authors proposed that the loss of *Rb1*, a critical controller of NE differentiation, could be a mechanism by which, under specific conditions, a subset of progenitor-like alveolar type II cells could differentiate toward a more NE cell-like state. These findings are in accordance with studies of treatment-resistant *EGFR*-mutated adenocarcinomas which have undergone a histological transformation to SCLC (26,27). In these cases, small-cell tumours were identified by morphology and positive immunohistochemical staining for synaptophysin, chromogranin, or NCAM, together with a loss of RB1, and genomic sequencing showed that these transformed SCLC tumours retained the original *EGFR*-activating mutation (26). Furthermore, in transgenic mice, Lin C *et al* showed that expression of the *EGFR* exon 21 L858R mutation under the control of the SPC promoter leads to tumorigenesis (28). Alveolar type II cells could thus serve as the cell of origin of SCLC as well as *EGFR*-mutant adenocarcinoma, depending on the molecular alterations in presence, as *EGFR* TKI-resistant SCLCs have been shown to branch out early from the adenocarcinoma clones that harbor completely inactivated *RB1* and *TP53* (27).

Of note, to date, no preneoplastic lesions have been identified for LCNEC or SCLC in humans, but preneoplastic neuroendocrine cells have been isolated in a mouse model of SCLC (29). Especially, no transitions from well-differentiated neuroendocrine tumors to SCLC have been described.

Molecular classification: identification of SCLC subtypes

Genome and transcriptome analyses on nearly 200 resected SCLCs (30-32) unveiled a high load of somatic mutations (8.62 nonsynonymous mutations per megabase). These molecular studies identified bi-allelic inactivation of *TP53* and *RB1* in nearly all the tumors analyzed, mostly through mutations, loss of heterozygosity (LOH), or inactivating

rearrangements. Inactivating mutations in *NOTCH* genes, which lead to the inactivation of HES1, an antagonist of ASCL1, were found in 25% of SCLC tumors. The transcription factors SOX2 and the MYC family of proteins were also frequently altered in SCLC: *SRY-box 2* (*SOX2*) was amplified in 27% of SCLC cases and *MYC* genes were altered through copy number amplification (9% *MYCL1*, 4% *MYCN*, and 6% *MYC*) and fusion transcripts (*RLF-MYCL1*). In addition, recurrent mutations in chromatin remodeling genes such as *CREBBP*, *EP300*, as well as *PTEN*, *SLIT2* or *EPHA7* mutations or *FGFR1* amplifications have also been described.

Two main key lineage-specific factors, ASCL1 and NEUROD1, responsible for neuroendocrine differentiation are reactivated in SCLC (33). ASCL1 activates NE differentiation, and regulates stemness, cell cycle progression, and mitosis. ASCL1 expression is limited to dormant progenitor pulmonary NE cells in mature lung but its reactivation in NE carcinomas maintains tumor development and survival. Its targets are *MYCL1*, *RET*, *SOX2*, *BCL2* and nuclear factor I B (*NFIB*) oncogenes, as well as NOTCH ligand *DLL3*. Of note, *NKX2-1* (also called *TTF1*) gene expression is also positively regulated by ASCL1 (34) as well as *BRN2* (brain-2; also known as *POU3F2*) (35). In contrast, NEUROD1 promotes neurogenic differentiation of cells during development and malignant behavior in SCLC cell lines. It targets *MYC* (36) and oncogenic Myc^{T58A} promotes the development of slow growing NE tumors (37). Of note, both ASCL1-high and NEUROD1-high SCLCs express insulinoma associated protein 1 (INSM1), which is a driver of NE differentiation in many organs and tissues. Extensive transcriptional analyses performed in human tumors, genetically engineered mouse models (GEMMs) and patient-derived xenografts (PDXs) (32,37,38) have revealed differential activation of these regulatory pathways. They led to the identification beside the classical SCLCs expressing high levels of ASCL1, of SCLC variants either expressing more NEUROD1 than ASCL1 or neither one (11,36,37,39-41). A certain plasticity has been reported between the different subtypes of SCLCs, with variants more frequently observed in tumors recurring after initial response to therapy (42). The dual ASCL1- and NEUROD1-negative variants have no NE phenotype and express RE1 silencing transcription factor (REST). They harbor an epithelial to mesenchymal transition (EMT) profile and activate the NOTCH, HIPPO and TGFβ pathways (40). These non-NE NOTCH-active SCLCs are probably slow growing tumors, but could be relatively chemoresistant in *in vitro*

studies (43,44). They are driven either by *YAP1* or *POU2F3* master genes (32,45,46) with the current distinction of four subtypes of SCLCs, each of them mainly driven by a specific gene: SCLC-A, driven by *ASCL1*, SCLC-N by *NEUROD1*, SCLC-Y by *YAP1* and SCLC-P by *POU2F3* (47). *YAP1* is a regulator of transcription activated by the HIPPO growth signaling pathway, and SCLC-Y tumors are RB1-positive by immunohistochemistry, which is rarely observed in SCLC (45), but they are enriched for *CCND1* amplification and *CDKN2A* inactivation, which result in RB1 inactivation and cell-cycle control defects (48). *POU2F3* is a master regulator of the NE low SCLC subtype, involving *IFGR1* pathway to increase cell proliferation. Interestingly, it has been proposed that SCLC-P tumors could arise from chemosensory tuft cells (46). Recently, Gay *et al.* identified by non-negative matrix factorization (NMF) analysis of RNAseq in a series of 81 resected SCLC tumor samples and 62 SCLC cell lines, a cluster called SCLC-IM, composed of “mesenchymal” tumors which lose cytokeratin and express vimentin, are NE markers negative and highly express immune checkpoints, *STING*-related genes, and inflammatory markers (49). This SCLC variant could be more sensitive to immune checkpoint inhibitors, which is of particular interest given the fact that the vast majority of SCLCs are considered as cold tumors. Indeed, they exhibit low levels of CD3, CD8 and CD20 tumor-infiltrating lymphocytes (TILs), low ratios of total/effector T-cells (50) and only 5% to 15% of tumors are PD-L1 positive with a 1% cut-off (51,52), contrasting with high TILs and stromal macrophages PD-L1 expression. In addition, class I and II major histocompatibility complex (MHC) molecules and regulatory chemokines, such as IL-2 and Macrophage Activating Factor, are down-regulated in most SCLCs, contrasting with a high production of IL-15, all these findings favoring intrinsic resistance to immunotherapies (53).

Regarding epigenetic abnormalities, DNA methylation patterns can also define different SCLC subtypes. A global DNA hypomethylation is observed in most SCLCs, but a subgroup of SCLCs present hypermethylated promoter CPG islands leading to specific gene silencing. This subgroup is characterized by a poor prognosis and a high expression of the *EZH2* (E2F target and histone methyltransferase) gene (41,54). *EZH2* is a target of E2F, which is normally repressed by RB1, and overexpressed in SCLC due to the universal loss of *RB1*. *EZH2* is a histone methyltransferase that forms the polycomb repressive complex 2 (PRC2) and plays a role in homeostasis of SCLC cells. *EZH2* mediates tri-methylation of histone

H3 at lysine 27 (H3K27me3) in discrete promoter CpG islands, leading to transcriptional repression. Schlafen family member 11 (*SLFN11*) is one of the genes repressed by *EZH2* and its loss of expression results in increased DNA damage repair after cytotoxic chemotherapy through Homologous Recombination system activation and this loss has been implicated in chemotherapy resistance in SCLC PDX (55). Other epigenetic abnormalities have been reported in SCLC, such as Caspase 8 (*CASP8*), *FAS* and *TRAIL-R1* gene promoter silencing methylation (56).

Therapeutic implications

To date, SCLC standard of care consists in non-targeted approaches. They are based for limited stage SCLC on concurrent chemoradiation, and for extensive stage SCLC, on chemotherapy alone or chemotherapy combined with anti-PD-L1 checkpoint inhibitors, such as atezolizumab and durvalumab (54,55). The most commonly recommended chemotherapy regimen is platinum-etoposide (PE), which has been proven to increase survival with less toxicity than other regimens that combine anthracyclines, vinca-alkaloids, methotrexate and/or cyclophosphamide (57). SCLCs are chemosensitive in first-line setting, with response rates ranging from 70% to 80%, with up to 50% of complete responses. However, the majority of patients die from recurrences, which are refractory to chemotherapy. With the addition of atezolizumab to chemotherapy (58), median PFS has been shown to be 5.2 *vs.* 4.3 months (HR =0.77, 95% CI: 0.62–0.96, P=0.02), and median OS reached 12.3 *vs.* 10.3 months (HR =0.70, 95% CI: 0.54–0.91, P=0.007). Interestingly, benefits were consistent across all patients' subgroups and no biomarker, including PD-L1 expression or tumor mutation load, predicted the magnitude of benefit in this trial, despite preliminary data suggesting some predictive role (59). Recurrent SCLC is divided into two categories: refractory (disease progression occurring less than 3 months from completion of initial therapy) or sensitive (progression after 3 months) (60). Rates of response to second-line therapy are substantially lower in patients with refractory/resistant disease. Reinitiation of the front-line chemotherapy regimen is proposed if the initial response duration is 6 months or more based on reported response rates of 50–60%. The benefit of second-line chemotherapy in recurrent SCLC was evaluated in a randomized trial comparing oral topotecan with best supportive care (61). Although topotecan induced response in only 7% of patients, it did significantly improve overall

survival.

With the recognition of SCLC variants, emerging therapies guided on biology could be proposed in the future. DLL3 inhibitors, including antibody drug conjugate, bi-specific T cell engager and chimeric antigen receptor (CAR)-T cell constructs, could be specifically recommended in SCLC-A (62). Rovalpituzumab teserine (Rova-T) is an antibody drug conjugate consisting of a monoclonal antibody targeting DLL3, a cathepsin-cleavable linker, and a pyrrolobenzodiazepine (PBD) warhead (62). The first-in-human clinical trial of Rova-T in recurrent SCLC demonstrated encouraging activity despite frequent severe side-effects attributable to the PBD warhead. However, subsequent studies including the phase 2 TRINITY study and the phase 3 TAHOE trial in the second line setting showed disappointing efficacy data leading to the discontinuation of the development of Rova-T (63,64). Besides antibody-drug conjugates, other DLL3-targeting therapies are under investigation in SCLC and include the bispecific T cell engager (BiTE) AMG 757 (NCT03319940), and a chimeric antigen receptor CAR-T AMG119 (NCT03392064). Other strategies for SCLC-A could include BCL2-inhibitors, as BCL2 is a target of ASCL1, but limited clinical evidence is available in SCLC patients treated with BCL2 inhibitors such as venetoclax (65). Inhibitors of LSD1 (Lysine-specific histone demethylase A1), a flavin adenine dinucleotide FAD-dependent demethylase highly expressed in SCLC-A (66), are also in early stage development. The SCLC-N variant expressing high levels of MYC and NEUROD1 could be sensitive to Aurora kinase inhibitors when combined with chemotherapy as shown in mouse models (37). Single-agent alisertib (MLN8237) was evaluated in a phase 1 study which included 48 patients with SCLC, 36 presenting with chemotherapy-sensitive disease and the remaining with chemotherapy-refractory disease. The ORR in this group was 21% (67). Aurora amplification has also been associated with resistance to taxanes, justifying proposing a combination of paclitaxel as second line therapy. In a randomized phase II trial, the combination of alisertib plus paclitaxel showed a modest improvement in survival, with no statistical significance. Ultimately, as Aurora kinase also phosphorylates and impairs LKB1/STK11, whose loss is one of the resistance factors to immunotherapies, immune checkpoint inhibitors could benefit from the association with Aurora kinase inhibitors. Trials are ongoing with other agents such as LY3295668 that preclinically demonstrated synthetic lethal activity in RB1-deficient tumors (68).

Another strategy in SCLC-N could involve PI3K/mTOR pathway and HSP90 inhibitors (65). SCLC-P cell lines were reported to be sensitive to IGFR1-inhibitors (46), however, such inhibitors are currently not available in the clinic. SCLC-IM may actually represent the molecular subtype that would be biologically the most prone to be sensitive to immunotherapy, but this has not been formally tested so far. Ultimately, as PARP1 is highly expressed in SCLC, PARP inhibitors (PARPIs) were evaluated in combination with chemotherapy. A phase II trial with veliparib plus temozolomide in previously treated SCLC patients failed to meet its primary end-point of improved PFS but did show an improved ORR of 39%. SLFN11 was a clear predictive marker of benefit with improved PFS (5.7 vs. 3.6 months) and OS (12.1 vs. 7.5 months) in the subset of patients with tissue for analysis (69). Veliparib was tested in combination with cisplatin and etoposide doublet in 128 patients with ES SCLC in a randomized control trial. The median PFS was 6.1 vs. 5.5 months [unstratified hazard ratio (HR) =0.75, one-sided P=0.06] (70). PARPIs are also being studied in combination with various other novel agents, including the vascular endothelial growth factor inhibitor cediranib, or the WEE1 G2 checkpoint kinase inhibitor AZD1775 (71,72). *Figure 1* summarizes the main molecular subtypes of SCLC and LCNEC and the potential therapeutic impacts of such classification. However, despite all these encouraging perspectives for a class of tumors that until now has not benefited from targeted therapies, a major pitfall is the absence of selection of patients based on molecularly-defined SCLC subsets. Retrospective biomarker analyses are planned in some of the trials, but they are limited by the reduced availability of material from patients with advanced disease.

LCNEC

Histopathological classification

LCNEC is a high-grade neuroendocrine carcinoma with strong similarities to SCLC, regarding epidemiology, prognosis and genetics. LCNEC was classified in the 1999 and 2004 WHO classifications of lung tumors as a large-cell carcinoma variant (5,73), but in the 2015 classification, LCNEC was in a separate chapter, close to SCLC (4). Its definition is based on the recognition of NE morphology and expression of NE markers by immunohistochemistry, or presence of NE granules with electron microscopy, which is rarely performed nowadays. However, large-cell carcinomas

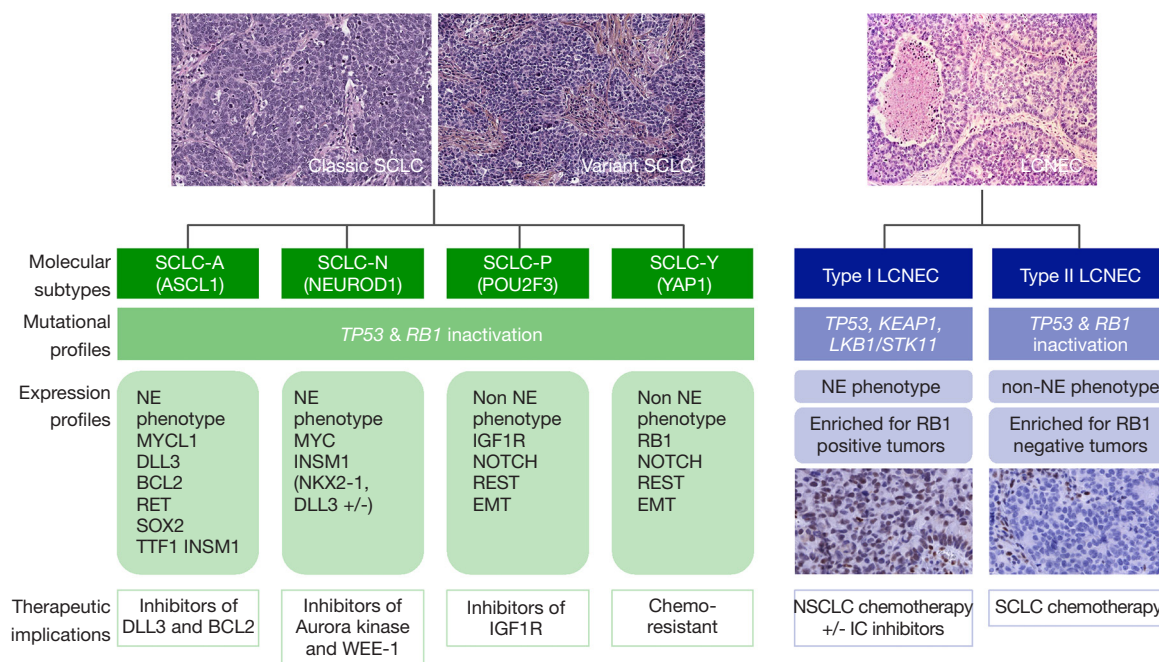


Figure 1 Main molecular subtypes of small cell lung carcinoma (SCLC) and large cell neuroendocrine carcinoma (LCNEC) with their potential therapeutic impacts. This figure includes cases of SCLC and LCNEC stained with Hematoxylin Eosin Saffron ($\times 200$ for SCLC and $\times 100$ for LCNEC), and LCNECs stained with RB1 antibody (immunohistochemistry using 13A10 clone from Leica Biosystems, Buffalo Grove, IL USA; immunoperoxidase, $\times 200$).

with NE morphology but non-NE immunophenotype have been reported, as well as large-cell carcinoma with non-NE morphology but with NE immunophenotype or ultrastructural features (17). To date, no preneoplastic lesions have been identified for high-grade NENs, but genomic abnormalities characteristic of these carcinomas has been detected in normal epithelial cells in smokers (74).

Histologically, LCNECs are characterized by a NE morphology with organoid nesting, trabecular growth, palisading or rosette-like structures; they typically exhibit a high mitotic rate, higher than 10 mitoses per 2 mm^2 , often between 80 and 100 per 2 mm^2 , and a non-small cell cytology with a cell size larger than three times the diameter of resting lymphocytes. However, some LCNECs presenting a predominant number of smaller cells have been reported, suggesting a significant size variability (75). Cytoplasm are classically ample and eosinophilic to basophilic, and there is a low nuclear-to-cytoplasm ratio. Chromatin is frequently vesicular with prominent nucleoli. Necrosis is often widespread but can be focal. All these diagnostic criteria have been described from surgical specimens, but they can be difficult to demonstrate on small biopsy specimens, as NE morphology is required

for the diagnosis. Most of the time, these tumors are classified as non-small lung carcinomas on biopsies and cytology, and recognized as LCNEC only on subsequent surgical specimens. Even in these cases, recognition of NE morphology with palisading and rosettes can be subtle. Demonstration of NE markers, which is mandatory for the diagnosis of LCNEC, is of great help on small specimens. Among them, CD56 is probably the most sensitive for LCNEC diagnosis (expressed in 92% to 98% of LCNECs) but lacks specificity as nearly 10% of adenocarcinomas, squamous cell carcinomas, and large-cell carcinomas express it with up to 30% of positive cells. Conversely, chromogranin A, expressed in nearly 70% of LCNECs, is likely the most specific but lacks sensitivity. Synaptophysin is expressed in 87% LCNECs but lacks specificity as it can be found in up to 10% of adenocarcinomas and 5% of squamous cell carcinomas (76) but CD56, synaptophysin and chromogranin A are co-expressed in less than 4% of non-NE NSCLC (77,78). The expression of these markers is widely dependent on the level of differentiation and at least 50% of malignant cells positive for one of the above-mentioned antibodies is required for the diagnosis (4,5). ASCL1 can also be detected in most LCNECs (22,79),

as well as TTF1 which is expressed by 41% to 75% of LCNECs (80-82).

Molecular classification

George *et al.* have provided a very comprehensive multi-omics analysis of LCNECs based on whole exome/genome sequencing (WES/WGS) of 60 matched tumor-normal cases, RNA sequencing of 69 tumors, and Affymetrix 6.0 SNP arrays for copy number variations on 60 tumors (83). This study revealed amplifications of the 8p12 region containing the *FGFR1* gene (7%) and of the 14q13 region containing the *NKX2-1 (TTF-1)* gene (10%), as in adenocarcinomas and squamous cell carcinomas of the lung, respectively, but also amplifications of the 1p34 region containing the *MYCL1* gene (12%) and of the 8q24.21 region containing the *MYC* gene (5%), as in SCLC (see above). *TP53* and *RB1* mutations were found in 92% and 42% of the cases, respectively, as well as *LKB1 (STK11)* (30%) and *KEAP1* (22%) mutations. In addition, loss-of-heterozygosity (LOH), biallelic alterations and larger genomic rearrangements leading to somatic alterations of *RB1* and *STK11/KEAP1* were found in up to 82% of the cases and were mutually exclusive. *RAS*-pathway (*KRAS/NRAS/HRAS*) mutations (10%) and *BRAF* mutations, which occur preferentially in lung adenocarcinomas, were also reported, as well as other genomic alterations affecting *CREBBP*, *EP300*, *NOTCH*, *MEN1*, and *ARID1A*. Subsequently, other studies using targeted sequencing (54,84-88) confirmed these observations, and found additional amplifications of *MYCN* (2%), *SRY-box 2 (SOX2)* (11%), and *cyclin E1 (CCNE1)* (9%) (85), as well as *SMARCA2* mutations (11%), *PI3KCA-AKT-mTOR* mutations (88), and neurotrophic receptor tyrosine kinase 2 (*NTRK2*) and 3 (*NTRK3*) gene mutations (19%) (85).

Regarding expression profiles, LCNECs constitute their own class, differing from other NSCLCs and carcinoids, but close to SCLCs (83). They can be divided molecularly into two separate subtypes, the type I being characterized by *STK11/KEAP1* alterations, but with an NE phenotype, high expression of *ASCL1* and *DLL3* and downregulation of *NOTCH* pathway, as in the SCLC classical subtype (see above). Conversely, the type II is characterized by *RB1* alterations, but a predominant non-NE phenotype (with low expression of chromogranin A and synaptophysin), high levels of *REST* and *NOTCH*, and immune cell response activation. Rekhtman *et al.* (85) also deciphered different molecular subtypes: one with *TP53/RB1* inactivation and

MYCL amplification, and another one with retained *TP53/RB1* functions, *NOTCH* mutations and either *STK11/KRAS/TTF1* mutations, similar to that of adenocarcinoma, or *KEAP1* mutations or *SOX2/FGFR1* amplifications, as with squamous cell carcinoma. Ultimately, they reported a “carcinoid-like” subtype with *MEN1* mutations and low mutational burden. Gene expression profiling showed that SCLCs and LCNECs belong to the same clusters, and as LCNECs can be combined with SCLCs, suggesting that LCNECs probably originate from the same precursors than SCLCs. However, given their low *ASCL1* expression and their higher expression of the non-NE specific marker hairy/enhancer of split 1 (*HES1*), a basic helix-loop-helix transcription factor acting as a key effector of notch signaling pathway (89), LCNECs are also close to non-NE NSCLCs in some ways. Regarding targetable mutations, they are rarely detected in LCNECs, with to 2% and 1% of *EGFR* and *BRAF* mutations respectively, which are more frequently observed in wild-type *RB1* LCNECs (85). By contrast, *KRAS* mutations are observed in 22–24% of LCNECs and are considered to be responsible for poor response to chemotherapy (85,90).

Therapeutic implications

Surgical removal has to be considered each time it is possible and a perioperative chemotherapy has been suggested to be beneficial to patients with resected LCNEC (91,92). For advanced stages, there is no standard of treatment for LCNEC, which can be either treated by SCLC-type chemotherapy (platinum-etoposide based) (93-99) or by NSCLC-type chemotherapy regimens (gemcitabine/taxane/pemetrexed combined with platinum). However, LCNEC seemed to respond poorly to PE-based chemotherapy (100), with a far better benefit obtained with gemcitabine- or taxane-based chemotherapy (87,90,99,101,102). Subsequently Derks JL and al showed in a retrospective series of LCNECs classified according to their molecular profile that patients with LCNECs *RB1* wild-type and/or expressing *RB1* by immunohistochemistry have superior overall survival when treated with NSCLC-like chemotherapy compared to SCLC-like chemotherapy (9.6 vs. 5.6 months) (87), with no difference in outcome for patients with inactivated *RB1*. The effectiveness of second-line chemotherapy could be different between LCNECs and SCLCs (103). While *PD1/PDL1* inhibitors showed no efficacy in SCLCs as a second-line treatment, responses are reported in LCNECs in late-line setting with overall

similar efficacy as in NSCLCs (104,105). Trials are ongoing to further confirm this finding (NCT03591731) (*Figure 1*). Ultimately, LCNECs which may harbor targetable abnormalities should be systematically screened to drive potential access to precision medicine approaches using kinase inhibitors.

Conclusions

The above summarized genomic studies on SCLCs and LCNECs have provided new potential avenues for a more adapted treatment of these aggressive cancers. Although promising, the effectiveness of these therapeutic options needs extensive and rigorous testing in thoroughly designed clinical trials before reaching the clinical setting.

Acknowledgments

We want to thank Drs Bregtje Hermans and Jules Derks from the Maastricht University, Netherlands, for providing us with the RB1 immunohistochemistry pictures.

Funding: None.

Footnote

Provenance and Peer Review: This article was commissioned by the Guest Editor (Helmut H. Popper) for the series “New Developments in Lung Cancer Diagnosis and Pathological Patient Management Strategies” published in *Translational Lung Cancer Research*. The article was sent for external peer review organized by the Guest Editor and the editorial office.

Conflicts of Interest: All authors have completed the ICMJE uniform disclosure form (available at <http://dx.doi.org/10.21037/tlcr-20-269>). The series “New Developments in Lung Cancer Diagnosis and Pathological Patient Management Strategies” was commissioned by the editorial office without any funding or sponsorship. The authors have no other conflicts of interest to declare.

Ethical Statement: The authors are accountable for all aspects of the work in ensuring that questions related to the accuracy or integrity of any part of the work are appropriately investigated and resolved.

Disclaimer: Where authors are identified as personnel of the International Agency for Research on Cancer/World

Health Organization, the authors alone are responsible for the views expressed in this article and they do not necessarily represent the decisions, policy or views of the International Agency for Research on Cancer/World Health Organization.

Open Access Statement: This is an Open Access article distributed in accordance with the Creative Commons Attribution-NonCommercial-NoDerivs 4.0 International License (CC BY-NC-ND 4.0), which permits the non-commercial replication and distribution of the article with the strict proviso that no changes or edits are made and the original work is properly cited (including links to both the formal publication through the relevant DOI and the license). See: <https://creativecommons.org/licenses/by-nc-nd/4.0/>.

References

1. Derks JL, Hendriks LE, Buikhuisen WA, et al. Clinical features of large cell neuroendocrine carcinoma: a population-based overview. *Eur Respir J* 2016;47:615-24.
2. Govindan R, Page N, Morgensztern D, et al. Changing epidemiology of small-cell lung cancer in the United States over the last 30 years: analysis of the surveillance, epidemiologic, and end results database. *J Clin Oncol* 2006;24:4539-44.
3. Travis WD, Brambilla E, Nicholson AG, et al. The 2015 World Health Organization Classification of Lung Tumors: Impact of Genetic, Clinical and Radiologic Advances Since the 2004 Classification. *J Thorac Oncol* 2015;10:1243-60.
4. Travis WD, Brambilla E, Burke AP, et al. WHO Classification of Tumours of the Lung, Pleura, Thymus and Heart. 4th Ed. Geneva: WHO, 2015.
5. Travis WD, Brambilla E, Müller-Hermelink HK, et al. eds. Pathology and Genetics of Tumours of the Lung, Pleura, Thymus and Heart. Lyon: IARC Press, 2004.
6. Vollmer RT. The effect of cell size on the pathologic diagnosis of small and large cell carcinomas of the lung. *Cancer* 1982;50:1380-3.
7. Nicholson SA, Beasley MB, Brambilla E, et al. Small cell lung carcinoma (SCLC): a clinicopathologic study of 100 cases with surgical specimens. *Am J Surg Pathol* 2002;26:1184-97.
8. Ruffini E, Rena O, Oliaro A, et al. Lung tumors with mixed histologic pattern. Clinico-pathologic characteristics and prognostic significance. *Eur J Cardiothorac Surg* 2002;22:701-7.

9. Travis WD. Pathology of lung cancer. *Clin Chest Med* 2002;23:65-81, viii.
10. World Health Organization. *Histological Typing of Lung Tumours*. 2nd Ed. Geneva: World Health Organization, 1981.
11. Gazdar AF, Carney DN, Nau MM, et al. Characterization of variant subclasses of cell lines derived from small cell lung cancer having distinctive biochemical, morphological, and growth properties. *Cancer Res* 1985;45:2924-30.
12. Miki M, Ball DW, Linnoila RI. Insights into the achaete-scute homolog-1 gene (hASH1) in normal and neoplastic human lung. *Lung Cancer* 2012;75:58-65.
13. Ye B, Cappel J, Findeis-Hosey J, et al. hASH1 is a specific immunohistochemical marker for lung neuroendocrine tumors. *Hum Pathol* 2016;48:142-7.
14. Thunnissen E, Borczuk AC, Flieder DB, et al. The Use of Immunohistochemistry Improves the Diagnosis of Small Cell Lung Cancer and Its Differential Diagnosis. An International Reproducibility Study in a Demanding Set of Cases. *J Thorac Oncol* 2017;12:334-46.
15. Lantuejoul S, Moro D, Michalides RJ, et al. Neural cell adhesion molecules (NCAM) and NCAM-PSA expression in neuroendocrine lung tumors. *Am J Surg Pathol* 1998;22:1267-76.
16. Hasleton PS, Flieder DB, editors. *Spencer's Pathology of the Lung*. 6th ed. Cambridge: Cambridge University Press, 2013.
17. Travis WD. Advances in neuroendocrine lung tumors. *Ann Oncol* 2010;21 Suppl 7:vii65-71.
18. Caplin ME, Baudin E, Ferolla P, et al. Pulmonary neuroendocrine (carcinoid) tumors: European Neuroendocrine Tumor Society expert consensus and recommendations for best practice for typical and atypical pulmonary carcinoids. *Ann Oncol* 2015;26:1604-20.
19. Wick MR, Marchevsky AM. Neuroendocrine neoplasms of the lung: Concepts and terminology. *Semin Diagn Pathol* 2015;32:445-55.
20. Kontogianni K, Nicholson AG, Butcher D, et al. CD56: a useful tool for the diagnosis of small cell lung carcinomas on biopsies with extensive crush artefact. *J Clin Pathol* 2005;58:978-80.
21. Guinee DG, Fishback NF, Koss MN, et al. The spectrum of immunohistochemical staining of small-cell lung carcinoma in specimens from transbronchial and open-lung biopsies. *Am J Clin Pathol* 1994;102:406-14.
22. Hiroshima K, Iyoda A, Shida T, et al. Distinction of pulmonary large cell neuroendocrine carcinoma from small cell lung carcinoma: a morphological, immunohistochemical, and molecular analysis. *Mod Pathol* 2006;19:1358-68.
23. Leversha MA, Fielding P, Watson S, et al. Expression of p53, pRB, and p16 in lung tumours: a validation study on tissue microarrays. *J Pathol* 2003;200:610-9.
24. Boers JE, den Brok JL, Koudstaal J, et al. Number and proliferation of neuroendocrine cells in normal human airway epithelium. *Am J Respir Crit Care Med* 1996;154:758-63.
25. Sutherland KD, Proost N, Brouns I, et al. Cell of origin of small cell lung cancer: inactivation of Trp53 and Rb1 in distinct cell types of adult mouse lung. *Cancer Cell* 2011;19:754-64.
26. Oser MG, Niederst MJ, Sequist LV, et al. Transformation from non-small-cell lung cancer to small-cell lung cancer: molecular drivers and cells of origin. *Lancet Oncol* 2015;16:e165-72.
27. Lee JK, Lee J, Kim S, et al. Clonal History and Genetic Predictors of Transformation Into Small-Cell Carcinomas From Lung Adenocarcinomas. *J Clin Oncol* 2017;35:3065-74.
28. Lin C, Song H, Huang C, et al. Alveolar type II cells possess the capability of initiating lung tumor development. *PLoS One* 2012;7:e53817.
29. Kim DW, Wu N, Kim YC, et al. Genetic requirement for Mycl and efficacy of RNA Pol I inhibition in mouse models of small cell lung cancer. *Genes Dev* 2016;30:1289-99.
30. Peifer M, Fernández-Cuesta L, Sos ML, et al. Integrative genome analyses identify key somatic driver mutations of small-cell lung cancer. *Nat Genet* 2012;44:1104-10.
31. Rudin CM, Durinck S, Stawiski EW, et al. Comprehensive genomic analysis identifies SOX2 as a frequently amplified gene in small-cell lung cancer. *Nat Genet* 2012;44:1111-6.
32. George J, Lim JS, Jang SJ, et al. Comprehensive genomic profiles of small cell lung cancer. *Nature* 2015;524:47-53.
33. Ito T, Udaka N, Yazawa T, et al. Basic helix-loop-helix transcription factors regulate the neuroendocrine differentiation of fetal mouse pulmonary epithelium. *Development* 2000;127:3913-21.
34. Horie M, Miyashita N, Mattsson JSM, et al. An integrative transcriptome analysis reveals a functional role for thyroid transcription factor-1 in small cell lung cancer. *J Pathol* 2018;246:154-65.
35. Sakaeda M, Sato H, Ishii J, et al. Neural lineage-specific homeoprotein BRN2 is directly involved in TTF1 expression in small-cell lung cancer. *Lab Invest* 2013;93:408-21.
36. Borromeo MD, Savage TK, Kollipara RK, et al. ASCL1

- and NEUROD1 Reveal Heterogeneity in Pulmonary Neuroendocrine Tumors and Regulate Distinct Genetic Programs. *Cell Rep* 2016;16:1259-72.
37. Mollaoglu G, Guthrie MR, Böhm S, et al. MYC Drives Progression of Small Cell Lung Cancer to a Variant Neuroendocrine Subtype with Vulnerability to Aurora Kinase Inhibition. *Cancer Cell* 2017;31:270-85.
 38. Poirier JT, Dobromilskaya I, Moriarty WF, et al. Selective tropism of Seneca Valley virus for variant subtype small cell lung cancer. *J Natl Cancer Inst* 2013;105:1059-65.
 39. Carney DN, Gazdar AF, Bepler G, et al. Establishment and identification of small cell lung cancer cell lines having classic and variant features. *Cancer Res* 1985;45:2913-23.
 40. Zhang W, Girard L, Zhang YA, et al. Small cell lung cancer tumors and preclinical models display heterogeneity of neuroendocrine phenotypes. *Transl Lung Cancer Res* 2018;7:32-49.
 41. Poirier JT, Gardner EE, Connis N, et al. DNA methylation in small cell lung cancer defines distinct disease subtypes and correlates with high expression of EZH2. *Oncogene* 2015;34:5869-78.
 42. Carney DN, Mitchell JB, Kinsella TJ. In vitro radiation and chemotherapy sensitivity of established cell lines of human small cell lung cancer and its large cell morphological variants. *Cancer Res* 1983;43:2806-11.
 43. Lim JS, Ibaseta A, Fischer MM, et al. Intratumoural heterogeneity generated by Notch signalling promotes small-cell lung cancer. *Nature* 2017;545:360-4.
 44. Hassan WA, Yoshida R, Kudoh S, et al. Notch1 controls cell chemoresistance in small cell lung carcinoma cells. *Thorac Cancer* 2016;7:123-8.
 45. McColl K, Wildey G, Sakre N, et al. Reciprocal expression of INSM1 and YAP1 defines subgroups in small cell lung cancer. *Oncotarget* 2017;8:73745-56.
 46. Huang YH, Klingbeil O, He XY, et al. POU2F3 is a master regulator of a tuft cell-like variant of small cell lung cancer. *Genes Dev* 2018;32:915-28.
 47. Rudin CM, Poirier JT, Byers LA, et al. Molecular subtypes of small cell lung cancer: a synthesis of human and mouse model data. *Nat Rev Cancer* 2019;19:289-97.
 48. Sonkin D, Thomas A, Teicher BA. Are neuroendocrine negative small cell lung cancer and large cell neuroendocrine carcinoma with WT RB1 two faces of the same entity? *Lung Cancer Manag* 2019;8:LMT13.
 49. Gay CM, Diao L, Stewart CA, et al. ASCL1, NEUROD1, and POU2F3 Drive Distinct Subtypes of Small Cell Lung Cancer with Unique Therapeutic Vulnerabilities. *J Thorac Oncol* 2019;14:S213.
 50. Carvajal-Hausdorf D, Altan M, Velcheti V, et al. Expression and clinical significance of PD-L1, B7-H3, B7-H4 and TILs in human small cell lung Cancer (SCLC). *J Immunother Cancer* 2019;7:65.
 51. Yu H, Batenchuk C, Badzio A, et al. PD-L1 Expression by Two Complementary Diagnostic Assays and mRNA In Situ Hybridization in Small Cell Lung Cancer. *J Thorac Oncol* 2017;12:110-20.
 52. Schultheis AM, Scheel AH, Ozretić L, et al. PD-L1 expression in small cell neuroendocrine carcinomas. *Eur J Cancer* 2015;51:421-6.
 53. Tian Y, Zhai X, Han A, et al. Potential immune escape mechanisms underlying the distinct clinical outcome of immune checkpoint blockades in small cell lung cancer. *J Hematol Oncol* 2019;12:67.
 54. Karlsson A, Jönsson M, Lauss M, et al. Genome-wide DNA methylation analysis of lung carcinoma reveals one neuroendocrine and four adenocarcinoma epitypes associated with patient outcome. *Clin Cancer Res* 2014;20:6127-40.
 55. Gardner EE, Lok BH, Schneeberger VE, et al. Chemosensitive Relapse in Small Cell Lung Cancer Proceeds through an EZH2-SLFN11 Axis. *Cancer Cell* 2017;31:286-99.
 56. Hopkins-Donaldson S, Cathomas R, Simões-Wüst AP, et al. Induction of apoptosis and chemosensitization of mesothelioma cells by Bcl-2 and Bcl-xL antisense treatment. *Int J Cancer* 2003;106:160-6.
 57. Available online: https://www.nccn.org/professionals/physician_gls/pdf/sclc.pdf
 58. Horn L, Mansfield AS, Szczesna A, et al. First-Line Atezolizumab plus Chemotherapy in Extensive-Stage Small-Cell Lung Cancer. *N Engl J Med* 2018;379:2220-9.
 59. Antonia SJ, López-Martin JA, Bendell J, et al. Nivolumab alone and nivolumab plus ipilimumab in recurrent small-cell lung cancer (CheckMate 032): a multicentre, open-label, phase 1/2 trial. *Lancet Oncol* 2016;17:883-95.
 60. Gazdar AF, Bunn PA, Minna JD. Small-cell lung cancer: what we know, what we need to know and the path forward. *Nat Rev Cancer* 2017;17:765.
 61. Pelayo Alvarez M, Westeel V, et al. Chemotherapy versus best supportive care for extensive small cell lung cancer. *Cochrane Database Syst Rev* 2013;(11):CD001990.
 62. Saunders LR, Bankovich AJ, Anderson WC, et al. A DLL3-targeted antibody-drug conjugate eradicates high-grade pulmonary neuroendocrine tumor-initiating cells in vivo. *Sci Transl Med* 2015;7:302ra136.
 63. Morgensztern D, Besse B, Greillier L, et al. Efficacy

- and Safety of Rovalpituzumab Tesirine in Third-Line and Beyond Patients with DLL3-Expressing, Relapsed/Refractory Small-Cell Lung Cancer: Results From the Phase II TRINITY Study. *Clin Cancer Res* 2019;25:6958-66.
64. Available online: <https://news.abbvie.com/news/phase-3-trial-rova-t-as-second-line-therapy-for-advanced-small-cell-lung-cancer-tahoe-study-halted.htm>
 65. Cardnell RJ, Li L, Sen T, et al. Protein expression of TTF1 and cMYC define distinct molecular subgroups of small cell lung cancer with unique vulnerabilities to aurora kinase inhibition, DLL3 targeting, and other targeted therapies. *Oncotarget* 2017;8:73419-32.
 66. Augert A, Eastwood E, Ibrahim AH, et al. Targeting NOTCH activation in small cell lung cancer through LSD1 inhibition. *Sci Signal* 2019;12:eaau2922.
 67. Melichar B, Adenis A, Lockhart AC, et al. Safety and activity of alisertib, an investigational aurora kinase A inhibitor, in patients with breast cancer, small-cell lung cancer, non-small-cell lung cancer, head and neck squamous-cell carcinoma, and gastro-oesophageal adenocarcinoma: a five-arm phase 2 study. *Lancet Oncol* 2015;16:395-405.
 68. Gong X, Du J, Parsons SH, et al. Aurora A Kinase Inhibition Is Synthetic Lethal with Loss of the RB1 Tumor Suppressor Gene. *Cancer Discov* 2019;9:248-63.
 69. Byers LA, Krug L, Waqar S, et al. MA11.07. Improved small cell lung cancer (SCLC) response rates with veliparib and temozolomide: results from a phase II trial. *J Thorac Oncol* 2017;12:S406-7.
 70. Owonikoko TK, Dahlberg SE, Sica GL, et al. Randomized Phase II Trial of Cisplatin and Etoposide in Combination With Veliparib or Placebo for Extensive-Stage Small-Cell Lung Cancer: ECOG-ACRIN 2511 Study. *J Clin Oncol* 2019;37:222-9.
 71. Liu JF, Barry WT, Birrer M, et al. Combination cediranib and olaparib versus olaparib alone for women with recurrent platinum-sensitive ovarian cancer: a randomised phase 2 study. *Lancet Oncol* 2014;15:1207-14.
 72. Lallo A, Frese KK, Morrow CJ, et al. The Combination of the PARP Inhibitor Olaparib and the WEE1 Inhibitor AZD1775 as a New Therapeutic Option for Small Cell Lung Cancer. *Clin Cancer Res* 2018;24:5153-64.
 73. Travis WD, Colby TV, Corrin B, et al. Sobin and pathologists from 14 countries. *Histological Typing of Lung and Pleural Tumors*. 3rd ed. Berlin: Springer, 1999.
 74. Swarts DR, Ramaekers FC, Speel EJ. Molecular and cellular biology of neuroendocrine lung tumors: evidence for separate biological entities. *Biochim Biophys Acta* 2012;1826:255-71.
 75. Marchevsky AM, Gal AA, Shah S, et al. Morphometry confirms the presence of considerable nuclear size overlap between "small cells" and "large cells" in high-grade pulmonary neuroendocrine neoplasms. *Am J Clin Pathol* 2001;116:466-72.
 76. Ionescu DN, Treaba D, Gilks CB, et al. Nonsmall cell lung carcinoma with neuroendocrine differentiation--an entity of no clinical or prognostic significance. *Am J Surg Pathol* 2007;31:26-32.
 77. Sterlacci W, Fiegl M, Hilbe W, et al. Clinical relevance of neuroendocrine differentiation in non-small cell lung cancer assessed by immunohistochemistry: a retrospective study on 405 surgically resected cases. *Virchows Arch* 2009;455:125-32.
 78. Derks JL, Dingemans AC, van Suylen RJ, et al. Is the sum of positive neuroendocrine immunohistochemical stains useful for diagnosis of large cell neuroendocrine carcinoma (LCNEC) on biopsy specimens? *Histopathology* 2019;74:555-66.
 79. Borges M, Linnoila RI, van de Velde HJ, et al. An achaete-scute homologue essential for neuroendocrine differentiation in the lung. *Nature* 1997;386:852-5.
 80. Sturm N, Lantuéjoul S, Laverrière MH, et al. Thyroid transcription factor 1 and cytokeratins 1, 5, 10, 14 (34betaE12) expression in basaloid and large-cell neuroendocrine carcinomas of the lung. *Hum Pathol* 2001;32:918-25.
 81. Du EZ, Goldstraw P, Zacharias J, et al. TTF-1 expression is specific for lung primary in typical and atypical carcinoids: TTF-1-positive carcinoids are predominantly in peripheral location. *Hum Pathol* 2004;35:825-31.
 82. Carlson JW, Nucci MR, Brodsky J, et al. Biomarker-assisted diagnosis of ovarian, cervical and pulmonary small cell carcinomas: the role of TTF-1, WT-1 and HPV analysis. *Histopathology* 2007;51:305-12.
 83. George J, Walter V, Peifer M, et al. Integrative genomic profiling of large-cell neuroendocrine carcinomas reveals distinct subtypes of high-grade neuroendocrine lung tumors. *Nat Commun* 2018;9:1048.
 84. Vollbrecht C, Werner R, Walter RFH, et al. Mutational analysis of pulmonary tumours with neuroendocrine features using targeted massive parallel sequencing: a comparison of a neglected tumour group. *Br J Cancer* 2015;113:1704-11.
 85. Rekhtman N, Pietanza MC, Hellmann MD, et al. Next-Generation Sequencing of Pulmonary Large

- Cell Neuroendocrine Carcinoma Reveals Small Cell Carcinoma-like and Non-Small Cell Carcinoma-like Subsets. *Clin Cancer Res* 2016;22:3618-29.
86. Miyoshi T, Umemura S, Matsumura Y, et al. Genomic Profiling of Large-Cell Neuroendocrine Carcinoma of the Lung. *Clin Cancer Res* 2017;23:757-65.
 87. Derks JL, Leblay N, Thunnissen E, et al. Molecular Subtypes of Pulmonary Large-cell Neuroendocrine Carcinoma Predict Chemotherapy Treatment Outcome. *Clin Cancer Res* 2018;24:33-42.
 88. Simbolo M, Barbi S, Fassan M, et al. Gene Expression Profiling of Lung Atypical Carcinoids and Large Cell Neuroendocrine Carcinomas Identifies Three Transcriptomic Subtypes with Specific Genomic Alterations. *J Thorac Oncol* 2019;14:1651-61.
 89. Natsugoshi R, Sato Y, Matsumoto T, et al. The balance between the expressions of hASH1 and HES1 differs between large cell neuroendocrine carcinoma and small cell carcinoma of the lung. *Lung Cancer* 2011;74:405-10.
 90. Naidoo J, Santos-Zabala ML, Iyriboz T, et al. Large Cell Neuroendocrine Carcinoma of the Lung: Clinico-Pathologic Features, Treatment, and Outcomes. *Clin Lung Cancer* 2016;17:e121-9.
 91. Abedallaa N, Tremblay L, Baey C, et al. Effect of chemotherapy in patients with resected small-cell or large-cell neuroendocrine carcinoma. *J Thorac Oncol* 2012;7:1179-83.
 92. Sarkaria IS, Iyoda A, Roh MS, et al. Neoadjuvant and adjuvant chemotherapy in resected pulmonary large cell neuroendocrine carcinomas: a single institution experience. *Ann Thorac Surg* 2011;92:1180-6; discussion 1186-7.
 93. Iyoda A, Hiroshima K, Moriya Y, et al. Prospective study of adjuvant chemotherapy for pulmonary large cell neuroendocrine carcinoma. *Ann Thorac Surg* 2006;82:1802-7.
 94. Rossi G, Cavazza A, Marchioni A, et al. Role of chemotherapy and the receptor tyrosine kinases KIT, PDGFRalpha, PDGFRbeta, and Met in large-cell neuroendocrine carcinoma of the lung. *J Clin Oncol* 2005;23:8774-85.
 95. Yamazaki S, Sekine I, Matsuno Y, et al. Clinical responses of large cell neuroendocrine carcinoma of the lung to cisplatin-based chemotherapy. *Lung Cancer* 2005;49:217-23.
 96. Veronesi G, Morandi U, Alloisio M, et al. Large cell neuroendocrine carcinoma of the lung: a retrospective analysis of 144 surgical cases. *Lung Cancer* 2006;53:111-5.
 97. Le Treut J, Sault MC, Lena H, et al. Multicentre phase II study of cisplatin-etoposide chemotherapy for advanced large-cell neuroendocrine lung carcinoma: the GFPC 0302 study. *Ann Oncol* 2013;24:1548-52.
 98. Sun JM, Ahn MJ, Ahn JS, et al. Chemotherapy for pulmonary large cell neuroendocrine carcinoma: similar to that for small cell lung cancer or non-small cell lung cancer? *Lung Cancer* 2012;77:365-70.
 99. Masters GA, Temin S, Azzoli CG, et al. Systemic Therapy for Stage IV Non-Small-Cell Lung Cancer: American Society of Clinical Oncology Clinical Practice Guideline Update. *J Clin Oncol* 2015;33:3488-515.
 100. Dowlati A, Lipka MB, McColl K, et al. Clinical correlation of extensive-stage small-cell lung cancer genomics. *Ann Oncol* 2016;27:642-7.
 101. Christopoulos P, Engel-Riedel W, Grohé C, et al. Everolimus with paclitaxel and carboplatin as first-line treatment for metastatic large-cell neuroendocrine lung carcinoma: a multicenter phase II trial. *Ann Oncol* 2017;28:1898-902.
 102. Niho S, Kenmotsu H, Sekine I, et al. Combination chemotherapy with irinotecan and cisplatin for large-cell neuroendocrine carcinoma of the lung: a multicenter phase II study. *J Thorac Oncol* 2013;8:980-4.
 103. Shimada Y, Niho S, Ishii G, et al. Clinical features of unresectable high-grade lung neuroendocrine carcinoma diagnosed using biopsy specimens. *Lung Cancer* 2012;75:368-73.
 104. Mauclet C, Duplaquet F, Pirard L, et al. Complete tumor response of a locally advanced lung large-cell neuroendocrine carcinoma after palliative thoracic radiotherapy and immunotherapy with nivolumab. *Lung Cancer* 2019;128:53-6.
 105. Chauhan A, Arnold SM, Kolesar J, et al. Immune checkpoint inhibitors in large cell neuroendocrine carcinoma: current status. *Oncotarget* 2018;9:14738-40.

Cite this article as: Lantuejoul S, Fernandez-Cuesta L, Damiola F, Girard N, McLeer A. New molecular classification of large cell neuroendocrine carcinoma and small cell lung carcinoma with potential therapeutic impacts. *Transl Lung Cancer Res* 2020;9(5):2233-2244. doi: 10.21037/tlcr-20-269