

Journal of Hand Surgery (European Volume)

<http://jhs.sagepub.com>

New trends in arthroscopic management of type 1-B TFCC injuries with DRUJ instability

A. ATZEI

Journal of Hand Surgery (European Volume) 2009; 34; 582 originally published online Jul 20, 2009;
DOI: 10.1177/1753193409100120

The online version of this article can be found at:
<http://jhs.sagepub.com/cgi/content/abstract/34/5/582>

Published by:



<http://www.sagepublications.com>

On behalf of:



British Society for Surgery of the Hand



Federation of the European Societies for Surgery of the Hand

Additional services and information for *Journal of Hand Surgery (European Volume)* can be found at:

Email Alerts: <http://jhs.sagepub.com/cgi/alerts>

Subscriptions: <http://jhs.sagepub.com/subscriptions>

Reprints: <http://www.sagepub.com/journalsReprints.nav>

Permissions: <http://www.sagepub.co.uk/journalsPermissions.nav>

NEW TRENDS IN ARTHROSCOPIC MANAGEMENT OF TYPE 1-B TFCC INJURIES WITH DRUJ INSTABILITY

A. ATZEI

From the Hand Surgery Unit, Policlinico 'G. B. Rossi', Verona, Italy

Advances in radiocarpal and distal radioulnar joint (DRUJ) diagnostic arthroscopy permits a treatment-oriented classification of triangular fibrocartilage complex (TFCC) peripheral tears: 1) repairable distal tears; 2) repairable complete tears; 3) repairable proximal tears; 4) non-repairable tears; and 5) tears associated with DRUJ arthritis. Class 1 tears should be sutured; Class 2 and 3 are associated with DRUJ instability and require TFCC reattachment to the fovea; Class 4 tears need reconstruction using a tendon graft and Class 5 tears require an arthroplasty. Arthroscopic assisted TFCC foveal reattachment is possible through the direct foveal portal, a dedicated DRUJ working portal. Arthroscopic TFCC reconstruction using a tendon graft showed promising results.

Keywords: distal radioulnar joint, DRUJ, instability, triangular fibrocartilage complex, TFCC, wrist

INTRODUCTION

Injury to the triangular fibrocartilage complex (TFCC) is a frequent cause of ulnar-sided pain and disability in the wrist. In 1989, Palmer (1989) classified disorders of the TFCC into two basic categories: traumatic (Class 1) and degenerative (Class 2). These were subdivided into different types, depending on the location of the tear and the presence or absence of chondromalacic change. Class 1 traumatic lesions are subdivided into four types according to the tear's location. Type 1-B injuries are peripheral tears located at the ulnar end of the TFCC.

Recent advances in histology and functional anatomy show that the ulnar end of the TFCC is arranged in a complex tri-dimensional manner and has three components: the proximal triangular ligament, the distal hammock structure and the ulnar collateral ligament (UCL) (Nakamura et al., 1996). Some authors question the existence of an UCL (Adams and Holley, 1993; Palmer and Werner, 1981) or consider it to be a part of the floor of the ECU sheath (Benjamin et al., 1990; Kauer, 1992), and this may include some surrounding loose ligamentous tissue (Nakamura et al., 1996).

The distal hammock structure and the UCL are the distal component of the TFCC (dc-TFCC), while the proximal triangular ligament represents the proximal component (pc-TFCC) (Fig 1). The latter is a strong ligamentous structure originating from the fovea ulnaris and attached by its two limbs, palmar and dorsal, to the ulnar corners of the distal radius. It forms the distal ligament which stabilises the distal radioulnar joint (DRUJ) (Nakamura and Makita, 2000). Due to the magnitude and direction of the traumatic force, either the dc-TFCC or pc-TFCC or both may be torn. When there is an isolated laceration of the dc-TFCC, DRUJ

stability is preserved. Conversely, when a type 1-B TFCC tear involves disruption of the pc-TFCC, the DRUJ becomes unstable leading to ulnar-sided pain, reduced grip strength, decreased forearm rotation and clinical signs of an unstable DRUJ.

There is still uncertainty about the best treatment for type 1-B TFCC tears associated with DRUJ instability. Different arthroscopic techniques have been suggested to suture the torn TFCC to the dorsal ulnocarpal joint capsule and the ECU tendon subsheath (Badia and Jiménez, 2006; Bohringer et al., 2002; Conca et al., 2004; Corso et al., 1997; de Araujo et al., 1996; Haugstvedt and Husby, 1999; Pederzini et al., 2006; Trumble et al., 1997; Whipple and Geissler, 1993; Zachee et al., 1993) These techniques restore tautness of the TFCC by direct suture of the lacerated dc-TFCC and thus improve patients' symptoms. However, when TFCC tears involve the pc-TFCC and the DRUJ is clinically unstable, traditional arthroscopic suture may not restore joint stability, as it fails to repair the foveal attachment of the pc-TFCC (Hermansdorfer and Kleinman, 1991; Kleinman, 2007).

In such cases, open repair is recommended, since it restores the anatomy by reattaching the proximal component of the TFCC to its foveal insertion (Garcia-Elias et al., 2003; Kleinman, 2007). Although good results have been documented with open repair, a careful and extensive exposure of the distal radioulnocarpal joint (Bain and Roth, 2007; Garcia-Elias et al. 2003; Nakamura et al., 2004) is required to reattach the TFCC using either transosseous sutures passed through drill holes (Hermansdorfer and Kleinman, 1991; Nakamura et al., 2004) or bone anchors (Chou et al., 2003). New arthroscopic techniques have been introduced for the treatment of either repairable or non-repairable TFCC peripheral tears associated with DRUJ instability, when

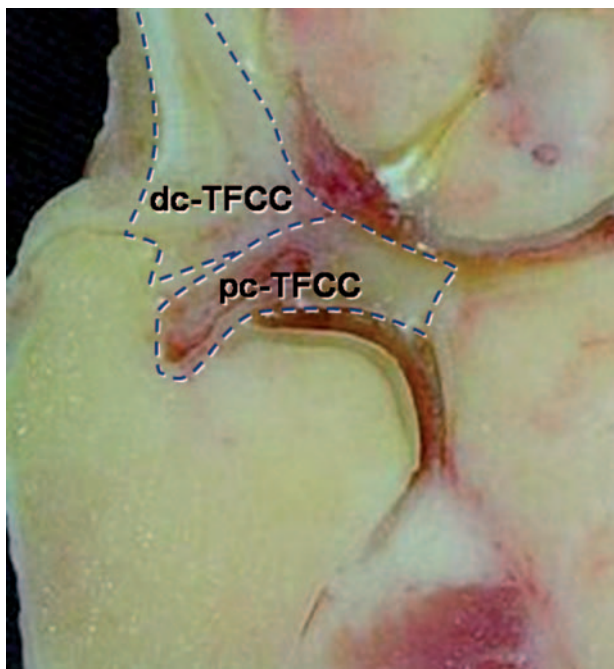


Fig 1 Coronal slice of the ulnar wrist. The TFCC is outlined. It is composed of the distal component of the TFCC (dc-TFCC), formed by the UCL and the distal hammock structure, and of the proximal component (pc-TFCC), the proximal triangular ligament, which originates from the ulnar fovea and basistyloid and stabilises the distal radioulnar joint.

secondary degenerative change has not occurred. This article reports my approach to arthroscopic assisted TFCC foveal repair and reconstruction.

CLINICAL PRESENTATION OF TYPE 1-B TFCC TEAR WITH DRUJ INSTABILITY

Patients with a peripheral TFCC tear and DRUJ instability complain of ulnar-sided wrist pain, usually after a fall on the outstretched hand or a violent traction and twisting injury of the wrist or forearm. The wrist spontaneously 'gives way' when trying to open a bottle, rotate a steering-wheel, turn a door handle or hold an object while rotating the forearm. The ulnar foveal sign (Tay et al., 2007) of point tenderness over the ulnar capsule just palmar to the ECU tendon suggests this diagnosis. Pain is provoked by passive forearm rotation and may be associated with a 'click' or intra-articular grinding. Active and passive motion of the wrist and DRUJ are normal, though resisted forearm rotation is often weak and can reproduce the symptoms. DRUJ laxity is evaluated by passive antero-posterior translation of the ulna on the radius in neutral rotation, in full supination and then in full pronation. Provided the forearm muscle are relaxed, greater laxity is seen in the painful wrist. The amount of radioulnar translation grades the DRUJ laxity as 'slight' when less than 5 mm,

'mild' when 5 to 10 mm or 'severe' when greater than 10 mm. If the translation is abnormal in full supination the dorsal limb of the pc-TFCC is either ruptured or attenuated. When the translation is abnormal in full pronation the palmar limb of the pc-TFCC is incompetent. There is a 'soft' resistance to translation in the clinically unstable DRUJ, compared to the 'firm' resistance felt in the uninjured DRUJ (Atzei et al., 2006b). However, contraction of the muscular stabilisers of the DRUJ can cause false negative findings, and DRUJ stability needs to be confirmed under anaesthesia. Radiographs are of limited help, but may reveal an associated ulnar styloid fracture, non-union or positive ulnar variance. The value of magnetic resonance imaging (MRI), even with intra-articular gadolinium, is uncertain. An MRI arthrogram may diagnose a tear, but may not accurately assess the size and location of the tear (Zanetti et al., 1997). Arthroscopy identifies the TFCC tear and is the gold standard for diagnosis (Fulcher and Poehling, 1998; Pederzini et al., 1992).

ARTHROSCOPIC ASSESSMENT OF TYPE 1-B TFCC TEAR

Thorough assessment of the tear requires evaluation of both components of the TFCC with not only an arthroscopy of the radiocarpal joint to evaluate the dc-TFCC but also of the DRUJ to evaluate the pc-TFCC. The tear is visualised during radiocarpal arthroscopy in the dorsoulnar corner of the TFCC and probed through the 6-R portal. The TFCC tension is evaluated by the trampoline test (Hermansdorfer and Kleinman, 1991) and the hook test. The trampoline test assesses the TFCC tautness by applying a compressive load across it with the probe. The test is positive when the TFCC is soft and compliant and suggests a peripheral TFCC tear. The hook test consists of applying traction to the ulnar-most border of the TFCC with the probe inserted through the 4-5 or 6-R portal. The test is positive when the TFCC can be pulled distally and radially towards the centre of the radiocarpal joint (Fig 2). It detects the foveal disruption of the pc-TFCC. Specific traction on the palmar or dorsal TFCC can help detect which limb of the pc-TFCC is ruptured.

DRU arthroscopy is the only way to identify ligamentous laceration of the pc-TFCC or avulsion of its foveal attachment. It is required when there is a positive hook test and/or when the TFCC tear is associated with DRUJ instability. An 18-gauge hypodermic needle used to probe the foveal insertion provides a simple assessment of the pc-TFCC. DRU arthroscopy also allows the cartilage of the distal ulna to be examined for chondromalacia.

Arthroscopy of the radiocarpal and DRU joints allows assessment of three factors: the laceration, the healing potential and the status of the cartilage of the head of the ulna and sigmoid notch.

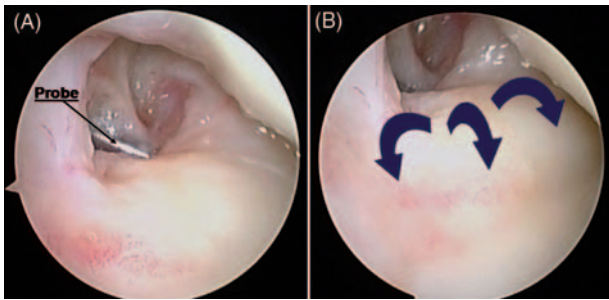


Fig 2 The hook test. (A) The probe is inserted through the 6-R portal through the TFCC tear and traction is applied to the ulnar-most border of the TFCC. (B) The test is positive when the TFCC can be pulled upwards and radially (arrows), when the pc-TFCC is torn or avulsed from the fovea.

Lacerated components of the triangular fibrocartilage complex

The distal (dc-TFCC) and proximal (pc-TFCC) components of the TFCC both need evaluation as they may be involved either separately or together.

Three different types of ligamentous damage are possible:

- (1) The isolated tear of the distal component: the trampoline test is positive, but the hook test is negative. Integrity of the foveal attachments of the pc-TFCC is confirmed by DRU arthroscopy.
- (2) Complete tear of both distal and proximal components: a tear of the dc-TFCC is visible during RC arthroscopy and a pc-TFCC avulsion is demonstrated by DRU arthroscopy. Both trampoline and hook tests are positive.
- (3) The isolated tear of the proximal component: this can be confirmed only by DRU arthroscopy. Standard RC arthroscopy looks normal, but both trampoline and hook tests are positive and suggest this diagnosis.

Healing potential of the triangular fibrocartilage complex tear

Chronic mid-substance ligamentous tears may show necrotic edges that cannot be debrided back to a well vascularised area, and direct repair is unlikely to heal. Poor healing can also be expected when degeneration or retraction of the ligamentous remnants prevent or only permit re-approximation under tension. In the above conditions or after a failed repair with elongation, direct repair is unlikely to be successful. Congenital hypoplasia of the styloid and foveal area with flattening of the ulna head can also be associated with poor healing.

Cartilage status of the distal radioulnar joint

Well-preserved articular cartilage is a 'sine qua non' for ligament repair or reconstruction of the DRUJ. When DRU arthroscopy shows a chondral lesion, either due to acute injury or chronic instability, salvage options are recommended.

Based on these arthroscopic findings, five classes of TFCC peripheral tears can be recognised and specific treatment can be considered (Table 1).

INDICATIONS FOR ARTHROSCOPIC TFCC REPAIR OR RECONSTRUCTION

Class 1 isolated repairable distal tear showing slight to no DRUJ instability should be treated by arthroscopic suturing of the TFCC to the dorsal ulnocarpal joint capsule and the ECU tendon subsheath. Both complete (Class 2) and isolated repairable proximal tears (Class 3) with DRUJ instability require foveal reattachment of the TFCC. Class 4 non-repairable tears, due to retracted or degenerated ligamentous remnants, need ligament reconstruction using a tendon graft, either open (Adams, 2000) or arthroscopic (Atzei et al., 2006c). For Class 5 TFCC tears associated with an arthritic DRUJ neither TFCC repair nor reconstruction are indicated, and salvage procedures are required, such as excision arthroplasty (Bowers, 1985; Darrach, 1913; Sauvé and Kapandji, 1936) or joint replacement (Laurentin-Perez et al., 2008).

Apart from osteoarthritis, repair is also contraindicated in a chronic Essex-Lopresti interosseous membrane injury, previous soft-tissue infection, osteomyelitis or severe osteoporosis of the ulnar head. A positive ulnar variance with secondary ulnar impaction, carpal chondromalacia and hypoplasia of the palmar or dorsal sigmoid notch are relative contraindications.

SURGICAL TECHNIQUE

DRUJ laxity is assessed under anaesthesia. A standard wrist arthroscopy is conducted (Atzei et al., 2006a). I prefer to use a dry technique (del Piñal et al., 2007), which helps arthroscopic repair (Atzei et al., 2005; del Piñal et al., 2006). I use a 2.7 mm arthroscope, reserving the 1.9 mm arthroscope for smaller wrists. Tears of the distal-TFCC are seen on the dorsal-ulnar aspect and are frequently covered by hypertrophic synovitis or fibrovascular granulation tissue, which is removed with a shaver. A probe is inserted in the 6-R portal to assess the tension of the TFCC, using the trampoline test and the hook test. If the TFCC is lax, proximal-TFCC attachment is assessed via DRU arthroscopy through the distal DRUJ portal, with the forearm supinated and traction reduced. In smaller wrists, a volar ulnar (VU) portal is used

(Slutsky, 2007). As the DRUJ is a very narrow and tight joint, DRU arthroscopy may be difficult to perform when the pc-TFCC is still intact. However, when the pc-TFCC is torn, scope insertion is easier as the articular disc is loose and more space is available. Preliminary assessment of pc-TFCC tautness can be done using an 18-gauge needle inserted percutaneously about 1 cm proximal to the 6-U portal with the forearm held in full supination. The needle enters the joint close to the fovea and can be used to lift the articular disc. DRU arthroscopy demonstrates the ligamentous laceration or avulsion of the pc-TFCC from the fovea.






Repair of the foveal insertion of the TFCC is performed by reattachment of the pc-TFCC with a suture anchor or screw. Arthroscopic reattachment of the foveal insertion of the TFCC requires a separate portal to provide access to the fovea ulnaris. This direct foveal (DF) portal has been devised to remove the ligamentous remnants, prepare the bone, and to drill and insert the suture screw or anchor. It is located about 1 cm proximal to the 6-U portal and is made with the forearm in full supination as this produces dorsal displacement of the ulnar styloid and the ECU tendon and presents the palmar aspect of the distal ulna (Fig 3). The fovea and the ulnar-most area of the distal ulna become subcutaneous and can be easily exposed. The DF portal is easier

than the volar ulnar portal (Slutsky, 2007), but is only used to introduce instruments. After confirming the 6-U portal with an 18-gauge needle, a 2 to 2.5 cm longitudinal skin incision is made proximally between the ECU and the FCU. The dorsal sensory branches of the ulnar nerve (DSBUN) are identified by subcutaneous dissection and protected. The risk of damaging this nerve is reduced by forearm supination, as the nerve is displaced palmarwards.

The extensor retinaculum is exposed and split along its fibres. The DRUJ capsule is incised longitudinally to reach the distal articular surface of the ulnar head under the TFCC. The fovea is located palmarly at the base of the ulnar styloid, just lateral to the capsule as an area of soft bone. With the scope in the distal DRUJ portal, the DF portal permits the use of a small shaver or curette to debride the torn or avulsed ligament back to healthy tissue, remove the inflammatory fibrovascular tissue from the fovea and prepare it for suture screw or anchor insertion. Curettage of the fovea can also be performed as a mini-open procedure. Drilling and insertion of the screw or anchor is also done through the DF portal as a mini-open procedure; neither a power drill nor intraoperative fluoroscopy is required.

A screw or anchor with a pair of sutures is preferred, so that a suture can be passed through each limb of the ligament. This will also recreate a broader footprint of

Table 1—Treatment-orientated classification of TFCC peripheral tears

	Class 1 Repairable Distal Tear	Class 2 Repairable Complete Tear	Class 3 Repairable Proximal Tear	Class 4 Non-Repairable Tear	Class 5 Arthritic DRUJ
					
CLINICAL DRUJ INSTABILITY	None / Slight	Mild / Severe	Mild / Severe	Severe	Mild / Severe
STATUS OF TFCC DISTAL COMPONENT	Torn	Torn	Intact	Torn	§
STATUS OF TFCC PROXIMAL COMPONENT	Intact	Torn	Torn	Torn	
HEALING POTENTIAL OF TFCC TEAR	Good	Good	Good	Poor	
STATUS OF DRUJ CARTILAGE	Good	Good	Good	Good	Poor
TREATMENT	REPAIR Suture (ligam-to-capsule)	REPAIR Foveal Refixation		RECONSTRUCTION Tendon Graft	SALVAGE Arthroplasty or Joint Replacement

Peripheral tears of the triangular fibrocartilage complex are categorised according to clinical instability and arthroscopic findings. Repairable distal tear (Class 1) can be treated by the traditional arthroscopic suture. Complete repairable tear (Class 2) and proximal repairable tear (Class 3) are associated with DRUJ instability and require foveal reattachment of the TFCC. Non-repairable lesion (Class 4) needs reconstruction using a tendon graft. When TFCC tear is associated to advanced DRUJ cartilage degeneration (Class 5), it should be treated by either excision arthroplasty or prosthetic joint replacement, regardless the variable arthroscopic findings (§).

the pc-TFCC (Lo and Burkhart, 2003). I prefer to use a 3.7 mm absorbable screw with two preloaded 2-0 Fiberwire sutures (Small Joint Bio-Corkscrew Suture Anchor, ref. AR-1923BNF, Arthrex Inc., Naples, FL, USA) exiting the DF portal from under the TFCC. Then the forearm is placed in neutral rotation, so that the screw's head lies under the TFCC's ulnarmost part.

The suture ends are then inserted into the tip of a 25-G needle, or a Tuohy needle. With the scope in the 3-4 portal, the first suture is inserted in an outside-in fashion from the DF portal, close to the TFCC's palmar edge, to hold the palmar limb of the ligament (Fig 4). A grasper is introduced through the 6-U portal to retrieve the suture from the RC-joint. The same procedure is repeated to suture the dorsal limb.

The wrist traction is released and an assistant maintains the ulnar head in a reduced position with the forearm in neutral rotation. The sutures are tied under arthroscopic vision using a small knot-pusher, assuring adequate pc-TFCC compression against the distal ulna (Fig 5). Knots should be located at the prestyloid recess or just outside the DRUJ capsule.

Complete tear closure is confirmed. Even in larger Class 2 TFCC peripheral tears, further ligament-to-capsule sutures are seldom necessary to repair the dc-TFCC. The DRUJ is assessed for range of forearm rotation and residual laxity. The DRUJ capsule and the opening between retinaculum fibres are approximated and the skin closed.

The patient is placed in a long arm splint in neutral forearm rotation for the first week and a Münster-type splint (a short arm splint that extends to the epicondyle, allowing elbow flexion and extension but restricts forearm rotation) for another 3 weeks. Full wrist flexion/extension is started at 3 weeks. During the first week of rehabilitation, progressive forearm rotation is

allowed, but the splint is still worn between exercises. During the next 6 weeks resisted movements are not permitted. Progressive resisted wrist and hand strengthening exercises are begun after the sixth week until the patient is able to bear weight on the operated wrist. Sport and heavy work tasks are allowed only after 3 months.

ARTHROSCOPIC RECONSTRUCTION OF THE TFCC USING TENDON GRAFTS

The technique of TFCC reconstruction is a modification of the open procedure (Adams, 2000), using the palmaris longus (PL) or similar graft. The TFCC remnant is debrided with a shaver or a radiofrequency device to expose the fovea ulnaris. The skin incision (Fig 6) for the 4-5 portal is extended 2 to 3 cm proximally to allow drilling of the distal radius and later intra-articular introduction of the dorsal limb of the graft. The extensor retinaculum is incised and the dorso-ulnar corner of the distal radius exposed by subperiosteal dissection. The posterior interosseous nerve is not divided and is retracted radially. A palmar longitudinal incision is made between the ulnar neurovascular bundle and the finger flexor tendons and extended 3 cm proximally from the proximal wrist crease. The palmar carpal arch is coagulated, the pronator quadratus is retracted proximally and the ulnarmost part of the distal radius is exposed subperiosteally. The PL tendon is harvested through this incision. Sometimes a 1 cm transverse extension is required to help expose this tendon. When the PL is absent, either the flexor superficialis tendon from the ring finger or a strip of flexor carpi radialis tendon is harvested.

The ulnar corner of the distal radius is drilled under fluoroscopic control to prevent fracture of the

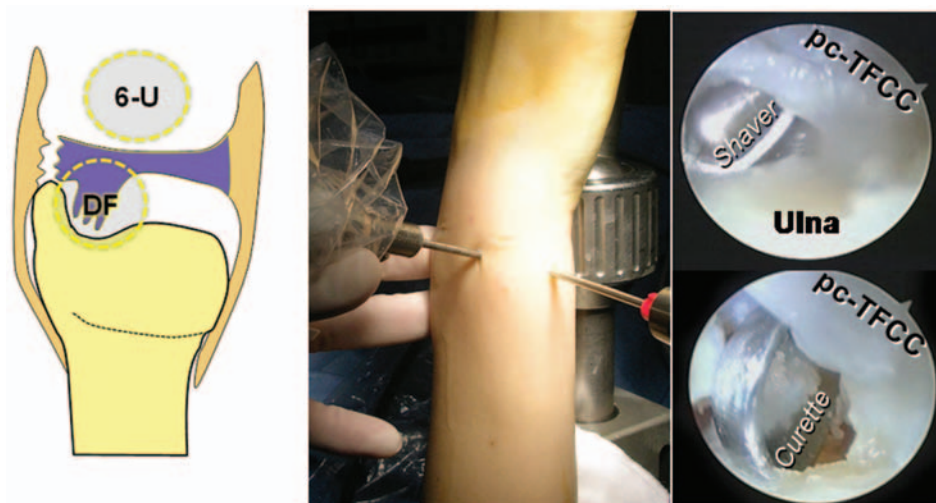


Fig 3 The direct foveal (DF) portal is located about 1 cm proximal to the 6-U portal. It is a working portal to provide access to the ulnar styloid and fovea. With the scope in the distal DRUJ portal, a small shaver or curette is inserted through the DF portal to debride the torn or avulsed ligament and the fovea.

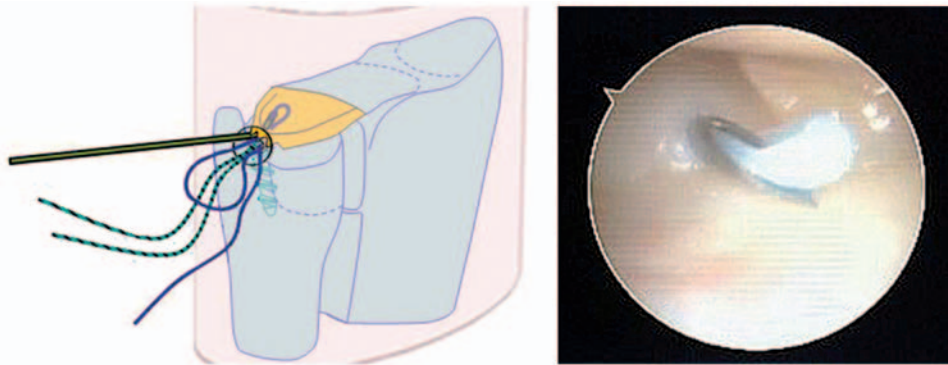


Fig 4 With the scope in the 3-4 portal, the end of the first suture is inserted into the tip of a 25-G Tuohy needle and is passed through the TFCC via the DF portal in an outside-in fashion.

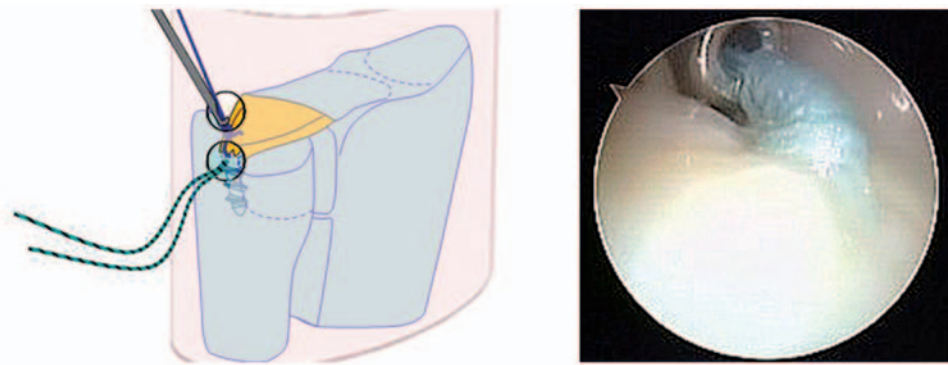


Fig 5 The suture is tied under arthroscopic vision using a small knot-pusher. The pc-TFCC is pushed forcefully against the distal ulna after the wrist traction is released, the forearm is held neutral rotation and the ulnar head reduced by an assistant. The knots of both sutures are located in the pre-styloid recess or just outside the DRUJ capsule at the level of the 6-U portal.

subchondral bone. A guide-wire for a 2.4 mm cannulated drill bit is driven through the radius a few millimetres proximal to the articular surface of the lunate fossa and radial to the sigmoid notch. The tunnel is progressively enlarged to 3.4–4 mm with standard drill bits.

The arthroscope is introduced through the 3-4 portal to visualise the foveal area after TFCC debridement. The centre of forearm rotation is identified on the foveal area of the ulnar head and marked with a radiofrequency device through the 6-U portal. The pointing tip of a small joint compass (Dyonics, Smith & Nephew Inc., Andover, MA, USA) is positioned on the marked area, and the drill guide rests against the distal ulnar shaft exposed through a 4 cm skin incision which begins 3 to 4 cm proximal to the 6-U portal (Fig 7). A guide-wire is driven through the compass and proper positioning is checked by fluoroscopy. The ulnar hole is drilled from outside-in with the cannulated drill bit and enlarged to accommodate both ends of the tendon graft. The arthroscope in the 3-4 portal allows visualisation of the interval between the ulno-lunate and the ulno-triquetral ligament on the palmar ulnar aspect of the wrist (Fig 8).

An opening is created through this interval just distal to the TFCC with a trocar introduced via the 6-R portal. The palmar limb of the graft is mounted on a shuttle wire (Concept shuttle relay suture passing system, Linvatec Corp., Largo, FL, USA), and is grasped inside the ulnocarpal joint through the opening between the ulnocarpal ligaments. Then it is pulled outside through the ulnar tunnel by an arthroscopic grasper. Passage of the tendon graft between the ulnocarpal ligaments, distal to the TFCC, provides improved stabilisation of the ulnar carpus. Due to the limited field of view, this step is difficult to perform in the open technique. The graft's dorsal limb is then mounted on the shuttle wire. This is introduced in the RC joint via the 4-5 portal and withdrawn through the ulnar tunnel. With the ulnar head reduced in the sigmoid notch and the wrist in neutral rotation, both ends of the graft are tensioned and temporarily pinned outside the ulnar tunnel with a hypodermic needle. The tension for reconstruction is assessed to permit full forearm rotation. Overtightening the reconstructed ligaments will cause excessive compression of the DRUJ. A slight dorsopalmar

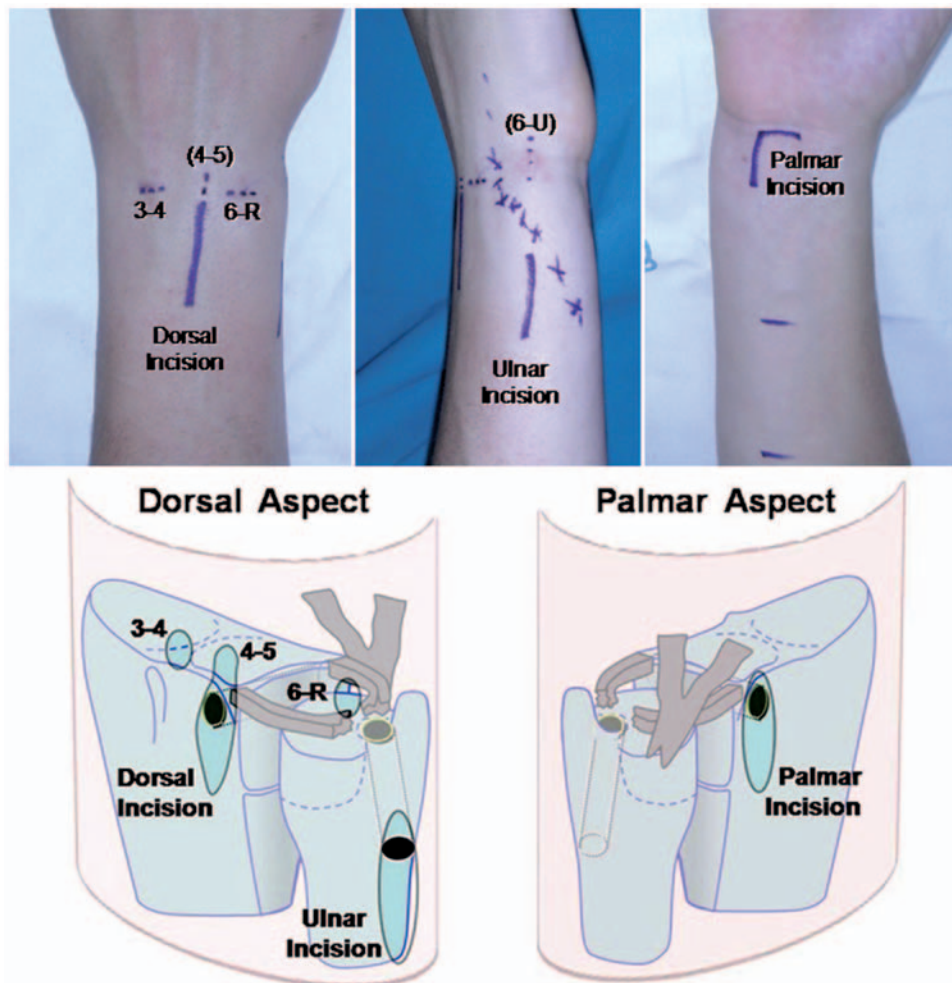


Fig 6 Arthroscopic portals and skin incisions for arthroscopic assisted TFCC reconstruction using tendon grafts. Standard 3-4 and 6-R portals are created. Accessory 4-5 portal is extended 2 to 3 cm proximally in order to expose the distal radius, through which a sagittal tunnel is drilled. The palmar incision helps protect the finger flexor tendons and ulnar neurovascular bundle and exposes the palmar opening of the radial tunnel. The same incision permits harvesting of the PL tendon. The ulnar incision is separated from the 6-U portal (accessory) by a 3 to 4 cm skin bridge through which the DSBUN crosses the ulnar wrist (crossed line).

translation of the ulna is permitted, but a 'firm' end point should be evident during translation of the DRUJ. This is also confirmed by arthroscopic examination and probing.

The graft is fixed with a 4 mm absorbable interference screw (Biotenodesis System Screw[®], Arthrex Inc., Naples, FL, USA) (Fig 9) inside either the ulnar drill hole or a metaphyseal hole (Lee et al., 2005).

The wrist is immobilised in neutral rotation or slight supination in a long cast for 3 weeks, followed by a further 4 weeks in a Münster-type splint, during which time the flexion/extension of the elbow is regained. Rotation is recovered, but the wrist is protected by the splint between the therapy sessions for the following 2 weeks. Progressive resisted wrist and hand strengthening exercises are begun after the eighth week. Complete use

is delayed until after 4 months and heavy loading is avoided for 6 months.

RESULTS AND COMPLICATIONS

I have performed an arthroscopic assisted repair of the foveal insertion of the TFCC in 37 patients since 2001 (Atzei et al., 2005). Twenty-nine patients had Class 2 TFCC peripheral tears and eight had Class 3 tears. A detailed study was conducted on 18 patients (13 males and five females, mean age 34.2 years) with a minimum follow-up of 1 year (mean 18 months, maximum 37 months). All patients had a history of trauma and complained of pain in the ulnar fovea with slight (10 patients) to mild (eight patients) DRUJ instability.

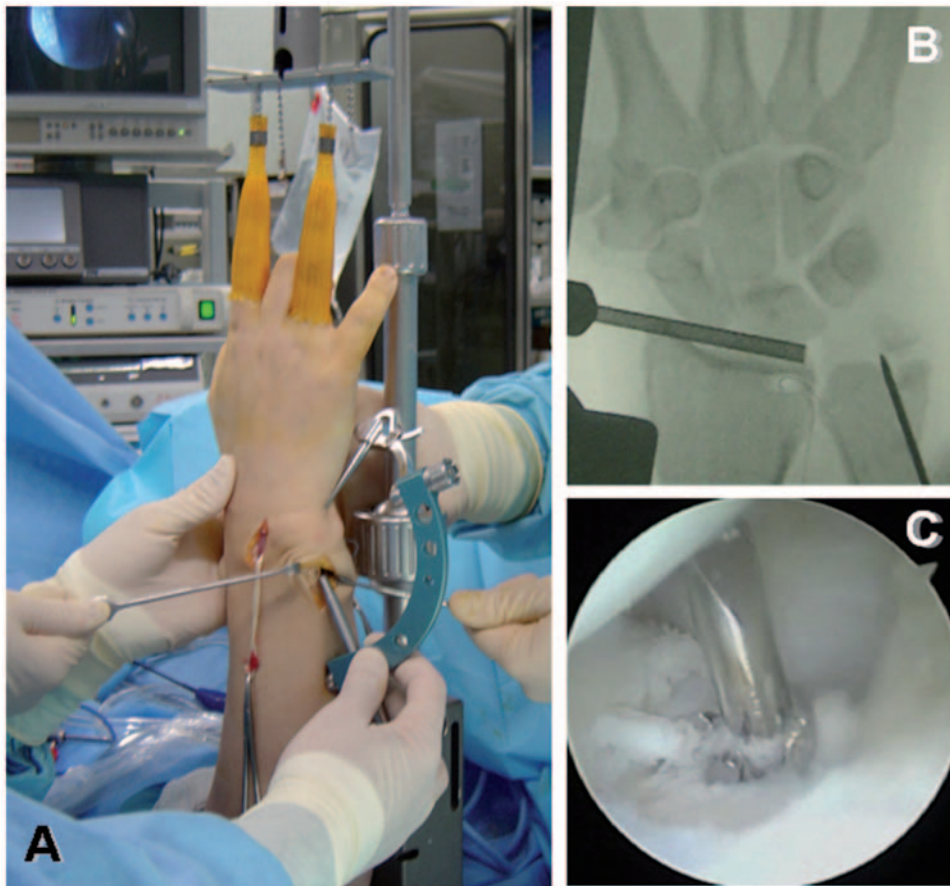


Fig 7 A small-joint arthroscopic compass (Dyonics, Smith & Nephew Inc., Andover, MA, USA) is used to guide the drill to create the ulnar tunnel (A). After the guide-wire is driven through the ulna, intra-operative fluoroscopy is recommended to prevent bone tunnel complications (B), then the tunnel is enlarged by progressive drilling to accommodate both ends of the graft (C).

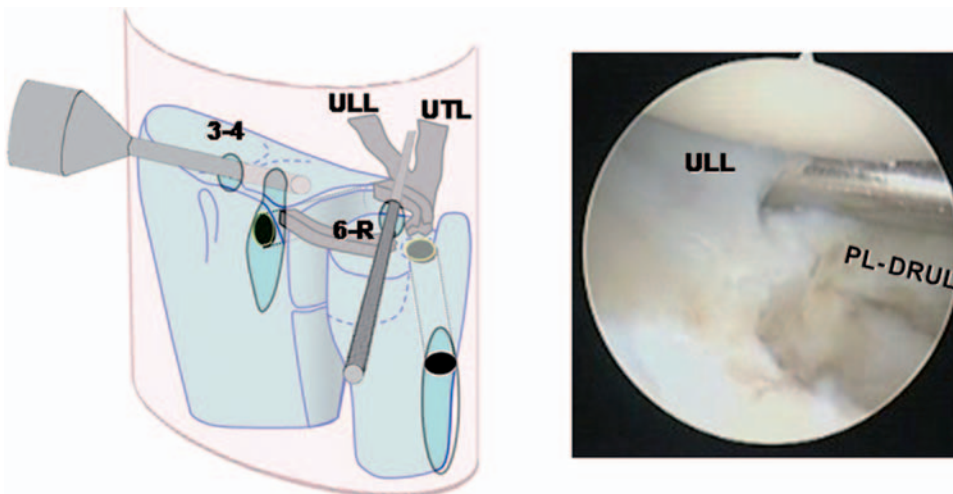


Fig 8 With the scope in the 3-4 portal, a trocar introduced through the 6-R portal is directed into the interval between the ulno-lunate (ULL) and the ulno-triquetral ligament (UTL) just distal to the palmar limb of the DRUJ ligament (PL-DRUL) in order to create an opening for the introduction of the palmar limb of the graft.

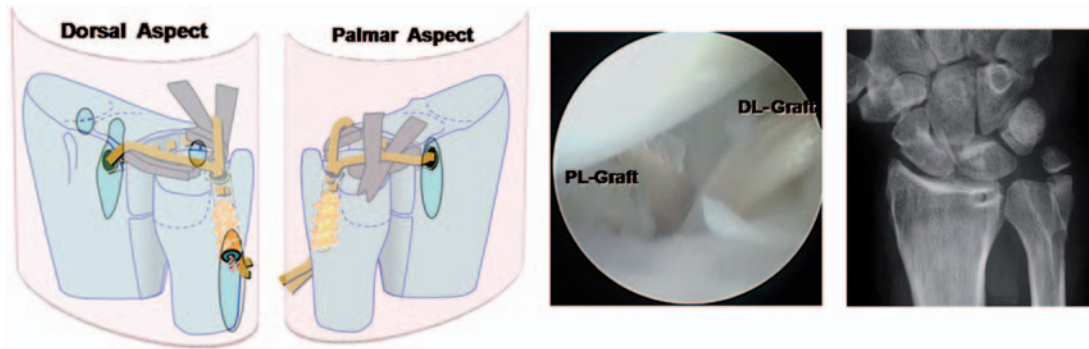


Fig 9 An interference screw is used to fix the tendon graft under proper tension and restore stability of the ulno-carpal and the distal radioulnar joint. At the end of the procedure, arthroscopy shows both palmar (PL-Graft) and dorsal limb of the tendon graft (DL-Graft) converging towards the fovea. Plain X-rays show proper tunnel positioning.

Although radiographs showed an ulnar positive variance in three patients, there were no detectable signs of ulnocarpal impaction or cartilage degeneration. Arthroscopy revealed a Palmer Type 1B ulnar avulsion of the TFCC in all patients. Fourteen were complete TFCC peripheral tears (Class 2) and four were proximal tears (Class 3).

At follow-up the patients had an increased range of motion (from 90.7% to 96% on the contralateral side) and grip strength (from 73% to 90%). Pain decreased from 8.3 to 1.2 on a 10 point visual analogue scale. The Modified Mayo Wrist Score was excellent in 14 patients, good in three and fair in one. DASH score averaged 10.5. Fifteen patients (83.3%) resumed their previous work and recreational activities while three patients (16.7%) had restricted function.

I have arthroscopically reconstructed the TFCC using tendon grafts in eight patients since 2005 (Atzei et al., 2006a). Four patients (all males, mean age 28 years) had a minimum follow-up of one year (average 22 months, maximum 34 months).

Three patients complained of severe chronic DRUJ instability following distal radius fracture and one patient had instability due to chondrocalcinosis. The ulnar styloid was ununited in two. In all, arthroscopy revealed a Palmer Type 1B ulnar avulsion of the TFCC which was not reducible in two cases and had poor TFCC quality and healing potential in the remaining two (Class 4). One patient had associated luno-triquetral instability (Geissler stage 3).

At follow-up, DRUJ stability was restored in all. The range of motion increased from 85% to 95% on the contralateral side and grip strength increased from 65% to 87%. Pain decreased from 8.7 to 1.7 on a 10 point visual analogue scale. Modified Mayo Wrist Score was excellent in three patients and good in one. All patients were satisfied with the results of the procedure, three resumed manual activities and previous work and one changed work for unrelated reasons.

Although arthroscopic assisted repair or reconstruction of the TFCC are procedures requiring specific

training and experience, few complications should be encountered, provided care is taken. Transient neuropraxia of the DSBUN developed in four patients who had arthroscopic foveal repair and this recovered spontaneously in 3 to 4 months. The surgical scar on the ulnar side of wrist may adhere to deeper structures and become painful especially after prolonged immobilisation. Therefore scar conditioning techniques are recommended, starting in the early stages of physiotherapy. During arthroscopic reconstruction, the ulnar tunnel may crack as the interference screw is inserted. In my experience it happened in one patient, in which the tunnel healed spontaneously during the period of planned immobilisation and DRUJ stability was maintained at the 6 month follow-up.

Radiocarpal and DRU arthroscopy allows classification of TFCC tears and helps decide treatment. Arthroscopic assisted repair and reconstruction can overcome the difficulties of open surgery.

Acknowledgements

The author sincerely thanks Riccardo Luchetti, MD, Marc Garcia-Elias, MD, PhD, and Francisco del Piñal, MD, PhD, for their contribution to the development of the classification system and their helpful comments and suggestions in reviewing the manuscript.

References

- Adams BD. Anatomic reconstruction of the distal radioulnar ligaments for DRUJ instability. *Tech Hand Up Extrem Surg.* 2000, 4: 154–60.
- Adams BD, Holley KA. Strains in the articular disk of the triangular fibrocartilage complex: a biomechanical study. *J Hand Surg Am.* 1993, 18: 919–25.
- Atzei A, Luchetti R, Borelli PP, Sgarbossa A, Cugola L. Arthroscopic TFCC reconstruction by tendon graft. *Rivista di Chirurgia della Mano.* 2006a, 43: 370–6.
- Atzei A, Luchetti R, Carita E, Papini-Zorli I, Cugola L. Arthroscopically assisted foveal reinsertion of the peripheral avulsions of the TFCC. *J Hand Surg Br.* 2005, 30(Suppl.): 40.

- Atzei A, Luchetti R, Garcia-Elias M. Lesioni capsulo-legamentose della radio-ulnare distale e fibrocartilagine triangolare. In Landi A, Catalano F, Luchetti R. (Eds.) *Trattato di Chirurgia della Mano. Verduci Editore Roma, 2006b*. 159–87.
- Atzei A, Luchetti R, Sgarbossa A, Carità E, Llusà M. Set-up, portals and normal exploration in wrist arthroscopy. *Chirurgie de la Main*. 2006c, 25 (Suppl.): S131–44.
- Badia A, Jiménez A. Arthroscopic repair of peripheral triangular fibrocartilage complex tears with suture welding: a technical report. *J Hand Surg Am*. 2006, 31: 1303–7.
- Bain GI, Roth JH. Surgical approaches to the distal radioulnar joint. *Tech Hand Up Extrem Surg*. 2007, 11: 51–6.
- Benjamin M, Evans EJ, Pemberton DJ. Histological studies on the triangular fibrocartilage complex of the wrist. *J Anat*. 1990, 172: 59–67.
- Bohringer G, Schadel-Hopfner M, Petermann J, Gotzen L. A method for all-inside arthroscopic repair of Palmer 1B triangular fibrocartilage complex tears. *Arthroscopy*. 2002, 18: 211–3.
- Bowers WH. Distal radioulnar joint arthroplasty: the hemiresection-interposition technique. *J Hand Surg Am*. 1985, 10: 169–78.
- Chou KH, Sarris IK, Sotereanos DG. Suture anchor repair of ulnar-sided triangular fibrocartilage complex tears. *J Hand Surg Br*. 2003, 28: 546–50.
- Conca M, Conca R, Pria AD. Preliminary experience of fully arthroscopic repair of triangular fibrocartilage complex lesions. *Arthroscopy*. 2004, 20: 79–82.
- Corso SJ, Savoie FH, Geissler WB, Whipple TL, Jimenez W, Jenkins N. Arthroscopic repair of peripheral avulsions of the triangular fibrocartilage complex of the wrist: a multicenter study. *Arthroscopy*. 1997, 13: 78–84.
- Darrach W. Partial excision of the lower shaft of the ulna for deformity following Colle's fracture. *Ann Surg*. 1913, 57: 764–5.
- de Araujo W, Poehling GG, Kuzma GR. New Tuohy needle technique for triangular fibrocartilage complex repair: preliminary studies. *Arthroscopy*. 1996, 12: 699–703.
- del Piñal F, García-Bernal FJ, Delgado J, Sanmartín M, Regalado J, Cerezal L. Correction of malunited intra-articular distal radius fractures with an inside-out osteotomy technique. *J Hand Surg Am*. 2006, 31: 1029–34.
- del Piñal F, García-Bernal FJ, Pisani D, Regalado J, Ayala H, Studer A. Dry arthroscopy of the wrist: surgical technique. *J Hand Surg Am*. 2007, 32: 119–23.
- Fulcher S, Poehling G. The role of operative arthroscopy for the diagnosis and treatment of lesions about the distal ulna. *Hand Clin*. 1998, 14: 285–96.
- Garcia-Elias M, Smith DE., Llusà M. Surgical approach to the triangular fibrocartilage complex. *Tech Hand Up Extrem Surg*. 2003, 7: 134–40.
- Haugstvedt JR, Husby T. Results of repair of peripheral tears in the triangular fibrocartilage complex using an arthroscopic suture technique. *Scand J Plast Reconstr Surg Hand Surg*. 1999, 33: 439–47.
- Hermansdorfer JD, Kleinman WB. Management of chronic peripheral tears of the triangular fibrocartilage complex. *J Hand Surg Am*. 1991, 16: 340–6.
- Kauer JMG. The distal radioulnar joint: anatomic and functional considerations. *Clin Orthop Relat R*. 1992, 275: 37–45.
- Kleinman WB. Stability of the distal radioulnar joint: biomechanics, pathophysiology, physical diagnosis and restoration of function. What we have learned in 25 years. *J Hand Surg Am*. 2007, 32: 1087–106.
- Laurentin-Perez LA, Goodwin AN, Babb BA, Scheker LR. A study of functional outcomes following implantation of a total distal radioulnar joint prosthesis. *J Hand Surg Eur*. 2008, 33: 18–28.
- Lee SK, Kubiak EN, Liporace FA, Parisi DM, Iesaka K, Posner MA. Fixation of tendon grafts for collateral ligament reconstructions: a cadaveric biomechanical study. *J Hand Surg Am*. 2005, 30: 1051–5.
- Lo IKY, Burkhart SS. Double-row arthroscopic rotator cuff repair: re-establishing the footprint of the rotator cuff. *Arthroscopy*. 2003, 19: 1035–42.
- Nakamura T, Makita A. The proximal ligamentous component of the triangular fibrocartilage complex: functional anatomy and three-dimensional changes in length of the radioulnar ligament during pronation-supination. *J Hand Surg Br*. 2000, 25: 479–86.
- Nakamura T, Nakao Y, Ikegami H, Sato K, Takayama S. Open repair of the ulnar disruption of the triangular fibrocartilage complex with double three-dimensional mattress suturing technique. *Tech Hand Up Extrem Surg*. 2004, 8: 116–23.
- Nakamura T, Yabe Y, Horiuchi Y. Functional anatomy of the triangular fibrocartilage complex. *Hand Surg*. 1996, 21: 581–6.
- Palmer AK. Triangular fibrocartilage complex lesions: a classification. *J Hand Surg Am*. 1989, 14: 594–606.
- Palmer AK, Werner FW. The triangular fibrocartilage complex of the wrist: anatomy and function. *J Hand Surg Am*. 1981, 6: 153–62.
- Pederzini L, Luchetti R, Soragni O. et al. Evaluation of the triangular fibrocartilage complex tears by arthroscopy, arthrography, and magnetic resonance imaging. *Arthroscopy*. 1992, 8: 191–7.
- Pederzini LA, Tosi M, Prandini M. All-class suture technique for Palmer class 1B triangular fibrocartilage repair. *Rivista di Chirurgia della Mano*. 2006, 43: 1–3.
- Sauvé L, Kapandji M. Nouvelle technique de traitement chirurgical des luxations recidivantes isolées de l'extrémité inférieure du cubitus. *J Chir*. 1936, 47: 589–94.
- Slutsky DJ. Distal radioulnar joint arthroscopy and the volar ulnar portal. *Tech Hand Up Extrem Surg*. 2007, 11: 38–44.
- Tay SC, Tomita K, Berger RA. The 'ulnar fovea sign' for defining ulnar wrist pain: an analysis of sensitivity and specificity. *J Hand Surg Am*. 2007, 32: 438–44.
- Trumble TE, Gilbert M, Vedder N. Isolated tears of the triangular fibrocartilage: management by early arthroscopic repair. *J Hand Surg Am*. 1997, 22: 57–65.
- Whipple TL, Geissler WB. Arthroscopic management of wrist triangular fibrocartilage complex injuries in the athlete. *Orthopedics*. 1993, 16: 1061–7.
- Zachee B, De Smet L, Fabry G. Arthroscopic suturing of TFCC lesions. *Arthroscopy*. 1993, 9: 242–3.
- Zanetti M, Bram J, Hodler J. Triangular fibrocartilage and intercarpal ligaments of the wrist: does MR arthrography improve standard MRI? *J Magn Reson Imag*. 1997, 7: 590–4.

Received: 16 June 2008

Accepted after revision: 19 October 2008

Andrea Atzei, MD, Hand Surgery Unit, Policlinico 'G. B. Rossi', P. le L. A. Scuro, 10, 37100 Verona, Italy. Tel.: +39 3385036401; fax: +39 045914264.

E-mail: andreatzei@libero.it; andreatzei@email.it.

doi: 10.1177/1753193409100120 available online at <http://jhs.sagepub.com>