

Original Article

NF- κ B activation and overexpression of regulated genes in human diabetic nephropathy

Sergio Mezzano¹, Claudio Aros¹, Alejandra Droguett¹, M. Eugenia Burgos¹, Leopoldo Ardiles¹, Claudio Flores¹, Herman Schneider¹, Marta Ruiz-Ortega² and Jesús Egido²

¹Division of Nephrology, School of Medicine, Universidad Austral, Valdivia, Chile and ²Fundación Jiménez Díaz, Universidad Autónoma, Madrid, Spain

Abstract

Background. Nuclear factor- κ B (NF- κ B) regulates genes involved in renal disease progression, such as the chemokines monocyte chemoattractant protein-1 (MCP-1) and RANTES. NF- κ B is activated in experimental models of renal injury, and *in vitro* studies also suggest that proteinuria and angiotensin II could be important NF- κ B activators. It has been proposed that locally produced MCP-1 may be involved in the development of diabetic nephropathy (DN). We examined the hypothesis that NF- κ B could be an indicator of renal damage progression in DN.

Methods. Biopsy specimens from 11 patients with type 2 diabetes and overt nephropathy were studied by southwestern histochemistry for the *in situ* detection of activated NF- κ B. In addition, by immunohistochemistry and/or *in situ* hybridization, we studied the expression of MCP-1 and RANTES, whose genes are regulated by NF- κ B.

Results. NF- κ B was detected mainly in cortical tubular epithelial cells and, to a lesser extent, in some glomerular and interstitial cells. A strong upregulation of MCP-1 and RANTES was observed in all the cases, mainly in tubular cells, and there was a strong correlation between the expression of these chemokines and NF- κ B activation in the same cells, as observed in serial sections ($r=0.7$; $P=0.01$). In addition, the tubular expression of these chemokines was correlated mainly with the magnitude of the proteinuria ($P=0.002$) and with interstitial cell infiltration ($P<0.05$).

Conclusions. The activation of NF- κ B and the transcription of certain pro-inflammatory chemokines in tubular epithelial cells are markers of progressive DN.

Proteinuria might be one of the main factors inducing the observed pro-inflammatory phenotype.

Keywords: diabetic nephropathy; MCP-1; NF- κ B; RANTES; renal disease progression

Introduction

Transcription factors, such as nuclear factor- κ B (NF- κ B) and activated protein-1 (AP-1), regulate the gene expression of several cytokines, chemotactic and matrix proteins involved in inflammation, immunological responses and cell proliferation [1–3]. NF- κ B regulates many genes involved in the progression of renal disease, such as the chemokines monocyte chemoattractant protein-1 (MCP-1) and RANTES (regulated on activation normal T-cell expressed and secreted chemokine) [3–5].

An upregulation of MCP-1 in tubulointerstitial lesions of human diabetic nephropathy (DN) has been observed, suggesting that locally produced MCP-1 may be involved in the development of advanced DN [6]. Recent data have shown that NF- κ B is activated in tubules and glomeruli in various experimental models of renal injury, and *in vitro* studies also suggest that proteinuria and angiotensin II (AngII), both involved in the pathophysiology of DN, could be important NF- κ B activators. Thus, rats with protein overload proteinuria, a model with interstitial inflammation and tubular upregulation of MCP-1 and osteopontin (OPN), present NF- κ B activation in tubules [7]. In human proteinuric non-diabetic renal disease, we have shown that a tubular overactivation of NF- κ B and AP-1 and a simultaneous upregulation of certain pro-inflammatory and profibrogenic genes are markers of progressive renal disease, such as occurs in human membranous nephropathy [8].

Correspondence and offprint requests to: Sergio Mezzano, MD, Department of Nephrology, School of Medicine, Universidad Austral Bueras 1003 2 P, PO Box 8-D, Valdivia, Chile. Email: smezzano@uach.cl

We have also demonstrated recently that AngII activates NF- κ B in the kidney via AT₁ and AT₂ receptors [9], and that this peptide participates in the mononuclear cell recruitment in experimental nephritis through NF- κ B activation and MCP-1 upregulation, expanding data on AngII as a pro-inflammatory mediator [10].

As the tubulointerstitial injury is also a major feature of DN and an important predictor of renal dysfunction, in which the renin-angiotensin system (RAS) and proteinuria have been implicated [11], we addressed the idea that NF- κ B could be an indicator of renal damage progression in human DN. Therefore, we studied the *in situ* expression of the activated transcription factor NF- κ B by using southwestern histochemistry (SWH) and its correlation with the expression of MCP-1 and RANTES (protein and mRNA) in renal biopsy sections of patients with DN.

Materials and methods

Human kidney specimens

Kidney samples were obtained by percutaneous renal biopsy from patients undergoing diagnostic evaluation at the Division of Nephrology, Universidad Austral, Valdivia, Chile. The renal biopsies from 11 patients with type 2 diabetes mellitus and overt nephropathy were studied. None of the patients had a good metabolic control. Five out of 11 patients were nephrotic. None of the patients had been treated with angiotensin-converting enzyme (ACE) inhibitors or AngII receptor blockers at the time of the biopsy. None of them had renal vein thrombosis.

Control human kidney specimens ($n = 5$) were taken from normal portions of renal tissue from patients who underwent surgery because of localized renal tumours.

For light microscopy, kidney tissues were fixed in 4% buffered formalin, dehydrated and embedded in paraffin by conventional techniques. Sections were stained with haematoxylin and eosin, periodic acid-Schiff and silver methenamine.

Southwestern histochemistry

This technique has been described in detail recently [8]. In brief, digoxigenin (DIG)-labelled double strain synthetic sense DNA with the consensus sequence of NF- κ B (5'-AGTTGAGGGGACTTTCCCAGGC-3') (Gibco-BRL, Life Technology, Gaithersburg, MD) (DIG oligonucleotide 3-end labelling kit, Boehringer Mannheim, Mannheim, Germany) was used as probe.

Formalin-fixed paraffin-embedded 4 μ m kidney sections were incubated with 5 mM levamisole (Sigma Chemical Co., St Louis, MO), and fixed with 0.2% paraformaldehyde for 30 min at 28°C. Preparations were then digested with 0.5% pepsin A (433 U/mg; Sigma Chemical Co.) in 1 M HCl for 30 min at 37°C, and washed twice with buffer 1 [10 mM HEPES, 40 mM NaCl, 10 mM MgCl₂, 1 mM dithiothreitol (DTT), 1 mM EDTA and 0.25% bovine serum albumin (BSA), pH 7.4]. Next, sections were incubated with 0.1 mg/ml DNase I in buffer 1 for 30 min at 30°C, and washed once with buffer 2 (buffer 1 with 10 mM EDTA instead of MgCl₂) to end

the reaction. Finally, they were exposed to decreasing alcohol gradients (70, 90 and 100%), and incubated overnight at 37°C with the labelled probe diluted in buffer 1 containing 0.5 mg/ml poly(dI-dC) (Pharmacia LKB, Piscataway, NJ) at a concentration empirically established (100 pM).

Sections were washed twice with buffer 1, once with washing buffer (0.03% Tween-20 in buffer 1 with 0.1 M maleic acid, 0.15 M NaCl, pH 7.5), and then incubated for 1 h in blocking solution [0.1 \times standard saline citrate (SSC: 1 \times 0.15 M NaCl in 0.015 M trisodium citrate pH 7), 0.1% SDS diluted 1:10 in washing buffer]. Then, the sections were incubated with anti-DIG antibody conjugated with alkaline phosphatase (1:250 in blocking solution; Boehringer Mannheim) overnight at 4°C. Next, sections were washed in washing buffer and in buffer 3 (0.1 M Tris-HCl, 0.1 M NaCl, 50 mM MgCl₂, pH 9.5) at room temperature. Alkaline phosphatase was then visualized with nitroblue tetrazolium chloride and 5-bromo-4-chloro-3-indolyl-phosphate (NBT/BCIP) (DAKO, Carpinteria, CA). Colour was allowed to develop in the dark at 37°C for 1 h or until a visible precipitate appeared. The reaction was stopped by incubation in TE buffer (10 mM Tris, 1 mM EDTA, pH 8.0), and sections were dehydrated in an ethanol series and mounted in Canadian balsam (Polysciences Inc., Warrington, PA).

As negative controls, we used the following: (i) absence of probe; (ii) mutant NF- κ B DIG-labelled probe (sense: 5'-AGTTGAGGCTCCTTTCCCAGGC-3'); and (iii) competition assays with a 200-fold excess of unlabelled NF- κ B, followed by incubation with labelled probe.

Immunohistochemistry (IMH)

Paraffin-embedded biopsy specimens were used for detection of MCP-1, RANTES, NF- κ B p50, NF- κ B p65, CD68 (macrophage marker) and α -smooth muscle actin (α -SMA). Specific biotinylated secondary antibodies were used, followed by streptavidin-horseradish peroxidase (HRP) conjugate (Dako), and revealed with diaminobenzidine (DAB).

The following primary antibodies were employed: anti-MCP-1 (goat polyclonal IgG, AB-279-NA; R&D Systems, Minneapolis, MN); anti-RANTES (goat polyclonal, AB-278-NA; R&D Systems); anti-NF- κ B p50 (goat polyclonal IgG, sc-1191; Santa Cruz); anti-NF- κ B p65 (mouse monoclonal, cat 1697838; Boehringer Mannheim); CD68 (mouse monoclonal, PG-M1; Dako); and α -SMA (mouse monoclonal α -SMA, 1A4; Dako). Briefly, 5 μ m thick renal sections were adhered to polylysine-coated glass and fixed overnight at 56°C. After deparaffinizing through xylene, alcohol and distilled water, endogenous peroxidase was blocked by 3% H₂O₂ for 20 min. The sections were then treated in a microwave oven in a solution of 0.1 mM citrate buffer pH 6.0 for 20 min, and transferred to distilled water. After rinsing in Tris-HCl-phosphate-buffered saline (TPS), the sections were incubated with 1:10 normal rabbit serum in TPS/1% BSA. The sections were then incubated overnight at 4°C with unlabelled polyclonal and monoclonal specific primary antibodies. For the α -SMA staining, after three rinses in TPS, the sections were incubated with biotinylated rabbit anti-mouse antibody in a 1:200 dilution in TPS-1% BSA. For detection of MCP-1 and RANTES, the sections were incubated with biotinylated rabbit anti-goat antibody (diluted 1:300) in TPS-1% BSA for 30 min at 22°C. After three rinses in TPS, they were incubated with streptavidin-peroxidase (Dako) 1:500 for 30 min. Colour was developed

with DAB and then counterstained with haematoxylin, dehydrated and mounted with Canadian balsam (Polysciences, Inc.). The specificity was checked by omission of primary antibodies and use of non-immune sera.

Cryostat sections (5 μm thick) from tissue fragments, frozen and kept in liquid nitrogen, were also used for the detection of CD4 T lymphocytes (mouse monoclonal, MT310; Dako) and CD8 T lymphocytes (mouse monoclonal, DK25; Dako).

Assessment of MCP-1 and RANTES expression in human DN by *in situ* hybridization (ISH)

ISH was performed as described previously [12]. Biotin-labelled human MCP-1 and RANTES probes were purchased from R&D Systems. Tissue was fixed in 4% buffered formalin, embedded in paraffin wax and cut into 5 μm sections which were mounted onto 3-aminopropyltriethoxysilane-coated slides treated with diethylpyrocarbonate (DEPC) (Sigma Chemical Co.).

Tissue sections were dewaxed with xylene and rehydrated through a series of decreasing ethanol solutions. Slide-mounted sections were treated with 2 × SSC at 60°C for 10 min and washed with DEPC-treated water.

Then, tissue sections were digested with proteinase K (5 μg/ml in 0.05 M Tris pH 7.6) for 60 min at 37°C. After a wash with DEPC-treated water, the sections were incubated with a pre-hybridization solution (Dako mRNA *in situ* hybridization solution) for 60 min at 37°C. The hybridization reaction was performed overnight at 37°C with 100 μl of biotin-labelled probe cocktails for each cytokine (200 ng/ml) (R&D Systems) in a humidified chamber.

Then, the slides were washed twice with 4 × SSC 30% formamide, 2 × SSC 30% formamide and 0.2 × SSC 30% formamide at 37°C for 5 min and then with 1 × TBS (Tris-buffered saline) containing 2% Triton at room temperature for 15 min.

Detection was performed with avidin-alkaline phosphatase conjugate (Dako) for 30 min at room temperature, washed for 5 min with 1 × TBS and using NBT-BCIP as the enzyme substrate for 120 min at 37°C in the dark (R&D Systems). Tissues were then dehydrated in an ethanol series and mounted in Canadian balsam (Polysciences Inc.).

The specificity of the reaction was confirmed by: (i) demonstrating the disappearance of hybridization signal when RNase (100 μg/ml; Sigma Chemicals Co.) was added in

0.05 M Tris after the digestion with proteinase K; (ii) by the use of a sense probe (R&D Systems); (iii) with a negative control (plasmid DNA) (Dako); and (iv) without a probe.

IMH quantification

The surface area labelled was evaluated by quantitative image analysis using a KZ 300 imaging system 3.0 (Zeiss, München-Hallbergmoos, Germany). Briefly, the percentage of the stained area was calculated as the ratio of suitable binary thresholded image and the total field area. For each sample, the mean staining area was obtained by analysis of 20 different fields (40×) excluding glomeruli and vessels. Quantification was done twice, independently, and inter-assay variations were not significant. The staining score is expressed as density/mm².

Tubulointerstitial cell infiltration and interstitial fibrosis were classified into four groups according to their extent and the presence of tubular atrophy and degeneration: (i) normal; (ii) involvement of up to 25% of the cortex; (iii) involvement of 26–50% of the cortex; and (iv) extensive damage involving >50% of the cortex.

Interstitial fibrosis was defined by the presence of interstitial collagen in sections stained with Masson. Staining for α-SMA was particularly prominent in areas of fibrosis around atrophic tubules, and detects vascular smooth muscle cells, activated mesangial cells and interstitial myofibroblasts.

Statistical analysis

The statistical analysis was performed with the GraphPad Instat (GraphPad Software, San Diego, CA). The results of the clinical data are expressed as the mean ± SD. The score for the intensity and distribution of staining for the SWH, IMH and ISH are expressed as the mean ± SEM. Spearman correlation was used to correlate the NF-κB tubular activation with proteinuria, and MCP-1 and RANTES tubular overexpression. Fisher's test was used when appropriate. A *P*-value of <0.05 was considered significant.

Results

The patients' profile is shown in Table 1. Eight out of 11 patients were female, with a mean age of 53 ± 8 years

Table 1. Clinical data and staining score for NF-κB and MCP-1 of patients with diabetic nephropathy

Case	Gender	Age (years)	Serum creatinine (mg/dl)	Proteinuria (g/day)	MCP-1 (density/mm ²)	NF-κB (density/mm ²)
1	F	45	0.8	0.5	449	3361
2	F	40	1.6	1	1830	4468
3	F	42	0.9	3.5	1623	6080
4	F	51	2.3	7	1890	9851
5	M	54	1.4	6.5	1619	8694
6	F	55	1.4	8.5	2295	12 408
7	M	55	1.5	0.3	532	980
8	F	56	1.7	2.5	2964	14 153
9	F	60	2.1	1.8	1383	4676
10	F	62	2	1.5	1699	4493
11	M	66	2.1	8	–	8304
		53 ± 8	1.6 ± 0.48	3.7 ± 3.1	1628 ± 235	7042 ± 1211

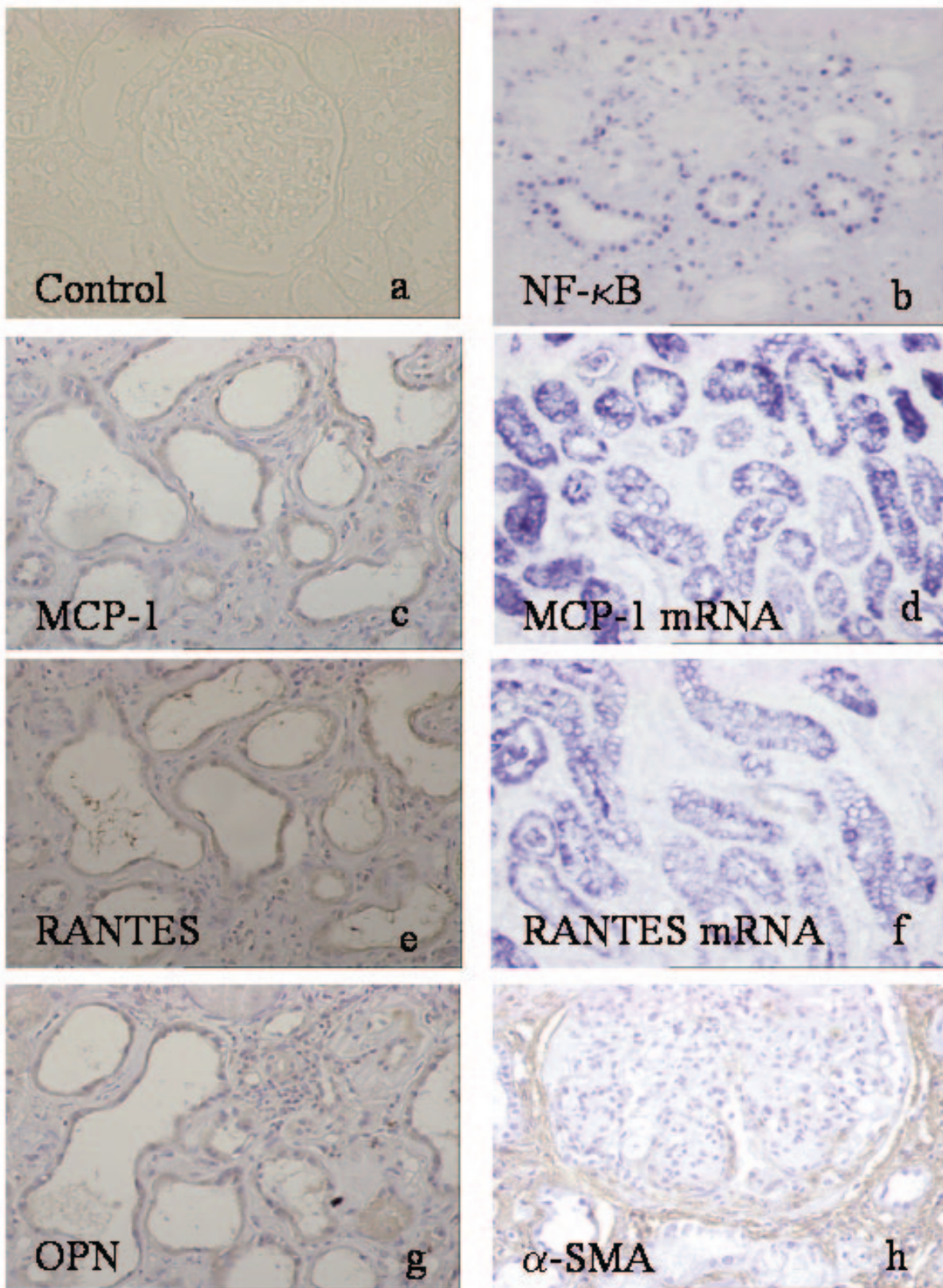


Fig. 1. Activated NF- κ B (by SWH) and overexpression of related chemokines in human diabetic nephropathy. Control normal renal tissue did not present staining for NF- κ B by SWH (a). Activated NF- κ B was mainly detected in tubular epithelial cells (b). In serial sections, positive staining for MCP-1 protein (c), RANTES protein (e) and OPN protein (g) was present mainly in tubular cells, as observed in those dilated and atrophic tubules. MCP-1 mRNA (d) and RANTES mRNA (f) were detected by ISH on the same tubular cells. The interstitial myofibroblasts were detected by α -actin staining (h).

(range 40–66). Mean serum creatinine was 1.6 ± 0.48 mg/dl (range 0.8–2.3). Renal function deterioration was present in six out of 11 patients, with a serum creatinine >1.5 mg/dl, and five patients were nephrotic with a proteinuria >3.5 g/day. A mean arterial pressure over 110 mmHg was present in 10 out of 11 patients.

Detection of activated NF- κ B by SWH in DN

Activated NF- κ B was detected mainly in cortical tubular epithelial cells (Figure 1b) and sparsely in some glomerular cells, mainly podocytes (Figure 2a). The mean staining score for NF- κ B was 7042 ± 1211 , and this activated transcription factor was observed in the renal sections of all the patients studied, in comparison with its absence in the control normal renal specimens (Figure 1a). In addition to podocytes, some nuclei of parietal cells and endothelial cells were positive for activated NF- κ B.

As shown in Figure 2, there was a significant Spearman correlation ($r = 0.8$, $P = 0.002$) between the magnitude of the proteinuria and the staining score for NF- κ B. Patients with nephrotic proteinuria >3.5 g/day had a significantly ($P < 0.05$) higher NF- κ B staining score (9067 ± 1034) than patients with proteinuria <3.5 g/day (5355 ± 1848).

By computer image analysis, we segmented the interstitial area in patients with marked interstitial inflammatory cell infiltration, counting the NF- κ B-positive nuclei, and observing mainly NF- κ B-positive mononuclear cells.

Detection of pro-inflammatory chemokines (MCP-1 and RANTES) by IMH and ISH

As NF- κ B promotes the expression of a number of genes involved in inflammation, such as cytokines and chemotactic proteins, we studied the expression of the pro-inflammatory chemokines (MCP-1 and RANTES) in the renal tissue of these patients. We observed a significant upregulation of these chemokines, mainly in tubular epithelial cells (Figure 1, case 4), with a marked correlation between MCP-1 and RANTES mRNA expression, as previously reported [12], and with stronger expression in those with interstitial cell infiltration and fibrosis (MCP-1 mRNA staining score 19401 ± 4318 ; RANTES mRNA 11914 ± 3063). As noted in Figure 1, there was a marked co-expression of both chemokines in the same tubular cells, as observed in serial sections of these cases. We did not detect

MCP-1 or RANTES mRNA expression in control renal tissue. In the glomeruli, there was no mRNA upregulation of these pro-inflammatory cytokines but, in some biopsies, a mild glomerular immunostaining for MCP-1 and RANTES was observed.

In addition, we also studied by IMH the expression of these proteins using specific polyclonal antibodies. MCP-1 and RANTES protein expression, almost

absent in normal renal tissue, was detected mainly in epithelial tubular cells and with a stronger immunostaining in those with progressive injury, and with a pattern similar to that observed for their respective mRNAs (Figure 1c and e). The staining score for MCP-1 protein was 1628 ± 235 and for RANTES it was 1215 ± 268 . As observed in serial sections (Figure 1, case 4; Figure 2, case 8), there was a strong co-expression of both chemokines in the same tubular epithelial cells. In some cases of DN, we observed a mild glomerular immunostaining for the MCP-1 and RANTES proteins. In addition, we studied the expression of OPN by IMH. Using a monoclonal antibody, this chemokine was detected mainly in tubular epithelial cells of DN patients, with a pattern similar to MCP-1 and RANTES (Figure 1g).

In the whole population of DN patients, the staining score for MCP-1 and RANTES was significantly correlated with the staining score for NF- κ B tubular activation ($r = 0.7$; $P < 0.01$) (Figure 2). As was noted in serial sections, we observed the same tubular cells expressing activated NF- κ B in the nuclei and MCP-1 and RANTES in the cytoplasm (Figure 2a–c, arrows).

Detection of NF- κ B subunits p50 and p65 by IMH in DN

The activated form of NF- κ B is a heterodimer, which usually consists of two proteins, the p65 (also called RelA) subunit and the p50 subunit that bind to a common DNA site.

In order to study the NF- κ B components in DN, immunostaining for the NF- κ B subunits p50 and p65 was performed. The subunits were detected mainly in tubular epithelial cells (cytoplasm and nuclei) of DN patients. In general, a good correlation between p50, p65 and activated NF- κ B, observed by SWH, was noted.

Detection of interstitial inflammatory cell infiltration

The composition of the inflammatory cell infiltration was examined further by IMH with specific anti-monocyte/macrophage CD68, anti-lymphocyte CD4, anti-lymphocyte CD8 and anti- α -SMA (interstitial myofibroblasts) antibodies.

As the interstitial cell infiltration was found in almost all cases, a large number of cells were recognized as macrophages/monocytes, according to the immunostaining for CD68. However, in cryostat sections, increased numbers mainly of CD4⁺ cells and scarce CD8⁺ cells were also found in the interstitium. Furthermore, positive staining for interstitial myofibroblasts (α -SMA-positive cells) was also found (Figure 1h), particularly in areas of fibrosis. In these patients, there was a significant association between the interstitial cell infiltration and the staining score for NF- κ B ($P < 0.05$, Fisher's test).

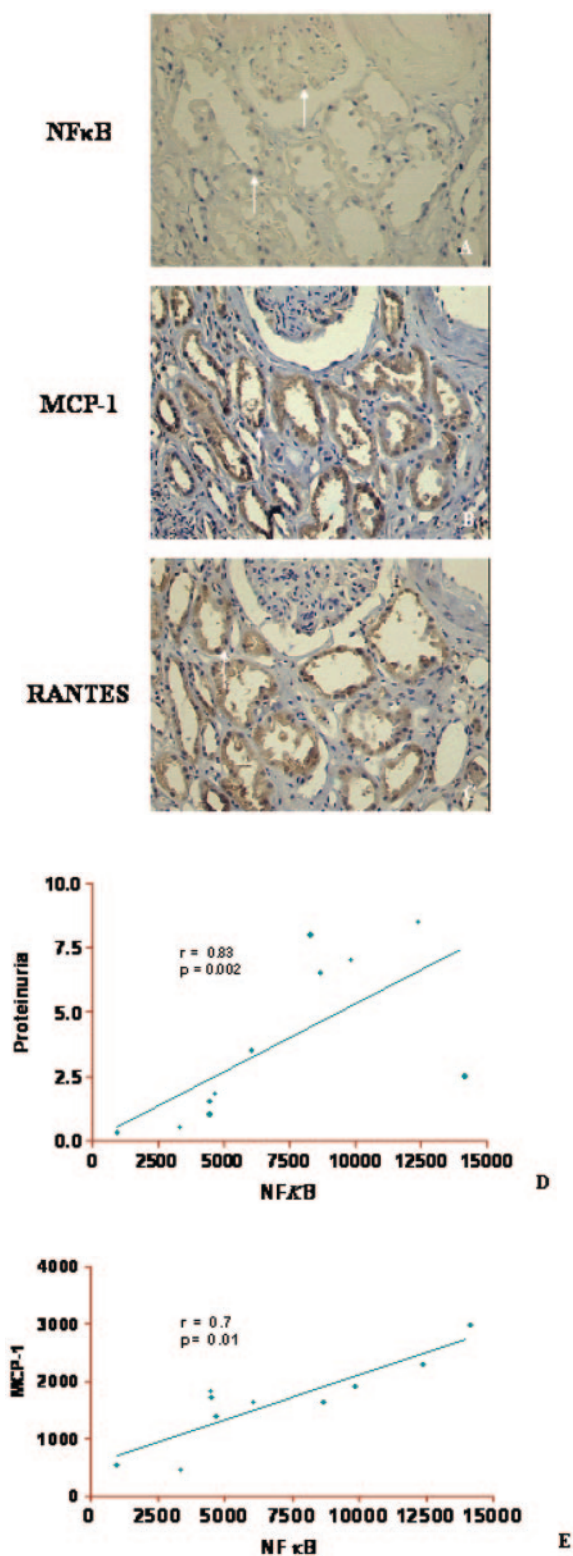


Fig. 2. Serial renal sections by SWH (a) and IMH (b and c) of a patient with diabetic nephropathy (case 8), showing tubular NF- κ B activation, and MCP-1 and RANTES expression in the same tubular cells. In these serial sections, we observe that activated NF- κ B (SWH) was expressed in the nucleus of tubular cells (a), and MCP-1 and RANTES protein (IMH) were expressed in the cytosol of the same cells (b and c). Spearman correlations between proteinuria and NF- κ B ($r = 0.82$, $P = 0.002$), and between MCP-1 and NF- κ B ($r = 0.7$, $P = 0.01$) are shown in (d) and (e).

Discussion

This study shows NF- κ B activation and a simultaneous upregulation of certain dependent pro-inflammatory genes (MCP-1 and RANTES) mainly in tubular epithelial cells of patients with DN, which correlates with the magnitude of proteinuria and the interstitial cell infiltration. Our results suggest that MCP-1 and RANTES may be involved in the pathogenesis of advanced interstitial lesions of DN, possibly through macrophage/monocyte and lymphocyte recruitment and activation.

Studies in diabetic rats have demonstrated increased glomerular expression of MCP-1 in the early stages of diabetic glomerular injury, associated with increased infiltration of monocyte/macrophages, and both findings are suppressed with RAS blockade [13]. In humans, urinary levels of MCP-1 were significantly elevated in patients with diabetic nephrotic syndrome and advanced tubulointerstitial lesions, increasing in accordance with the extent of proteinuria [6]. MCP-1 production by human mesangial cells in culture is facilitated in a diabetic milieu [6], and MCP-1-positive cells were detected in the interstitium of advanced DN. Our results obtained in diabetic patients with advanced glomerular and interstitial lesions support and extend those observations, confirming that tubular epithelial cells are the main source of MCP-1, and suggesting that the mesangial expression observed in the early stage is translated to the tubular cells in the later stage.

In streptozotocin-induced diabetes, NF- κ B activation in renal cortical tissue has been reported [14], and *in vitro* studies have reported that advanced glycation end-products induce oxidative stress and activate NF- κ B in mesangial cells [15]. Other studies in patients with type 1 and type 2 diabetes have reported that insufficient glycaemic control increases NF- κ B binding activity in peripheral blood mononuclear cells [16] and that this activation is oxidative stress sensitive and correlates with the degree of DN, thereby postulating a role for oxidative stress and NF- κ B activation in late diabetic complications [17].

Activated NF- κ B plays an important role in the upregulation of MCP-1 and RANTES expression in many cell types [4,5,18,19]. In our diabetic patients, NF- κ B activity was detected mainly in cortical tubular epithelial cells and, to a lesser extent, in some glomerular cells (mainly podocytes). In addition, some renal interstitial cells, mainly mononuclear cells, also showed NF- κ B activation. In these patients, we have observed in serial sections that the same tubular epithelial cells simultaneously revealed NF- κ B activation (by SWH) and the presence of dependent proinflammatory genes (MCP-1 and RANTES mRNA by ISH), supporting that this transcription factor is involved in the expression of these genes [8].

These data also support the idea that the increased trafficking of proteins in tubular cells could activate NF- κ B and, consequently, augment the tubular

expression of target genes associated with interstitial cell infiltration and tubulointerstitial damage [8,12,20]. The mechanisms by which proteinuria could cause interstitial inflammation and fibrosis are still not fully understood. In several experimental models of renal injury, characterized by heavy and sustained proteinuria, the overexpression of chemokines such as MCP-1, RANTES and OPN, and of vasoactive peptides such as AngII and endothelin-1 [21], was demonstrated in renal tissue. These peptides are potent pro-inflammatory mediators, and therefore could amplify the inflammatory response in the kidney. The incubation of tubular epithelial cells with albumin in concentrations similar to those found in the urine from patients with nephrotic syndrome induced an increment in the NF- κ B activity and an upregulation of pro-inflammatory molecules [4,5]. A recent observation suggests that this activation in human proximal tubular cells requires H₂O₂ through a protein kinase C (PKC)-dependent pathway [22].

In general, NF- κ B can also be induced in a great variety of cells in response to many different stimuli such as the pro-inflammatory cytokines tumour necrosis factor- α (TNF- α) and interleukin-1 β (IL-1 β), activators of PKC, oxidants, viruses, lipopolysaccharide and UV light [1,3]. Recently, AngII has been added to the list of important molecules that activate NF- κ B. AngII participates in mononuclear cell recruitment in experimental nephritis through NF- κ B activation and MCP-1 upregulation, and the systemic infusion of AngII into normal rats activates NF- κ B in glomerular, tubular and infiltrating cells [9].

Moreover, as proteinuria can also elicit the synthesis of AngII in renal cortex and NF- κ B activation, this pathway has been proposed as a mechanism by which persistent proteinuria may participate in the progression of renal disease [21]. In this regard, in some models of renal injury, the administration of an ACE inhibitor prevented proteinuria and the activation of NF- κ B.

On the whole, the results of the present study support the notion that NF- κ B tubular activation, together with the upregulation of related genes, could be markers of renal damage progression in human type 2 DN. Persistent proteinuria, local AngII and hyperglycaemia/glucosuria may be important factors in the activation of NF- κ B and the pro-inflammatory response.

Acknowledgements. This work was supported by research grants from Fondo Nacional de Investigación Científica y Tecnológica, CHILE (FONDECYT 1040163), Dirección de Investigación, Universidad Austral, Valdivia.

Conflict of interest statement. None declared.

References

- Barnes PJ, Karin M. Nuclear factor- κ B. A pivotal transcription factor in chronic inflammatory diseases. *N Engl J Med* 1997; 336: 1066–1071
- Karin M, Liu Z, Zandi E. AP-1 function and regulation. *Curr Opin Cell Biol* 1997; 9: 240–246
- Guijarro C, Egido J. Transcription factor κ B (NF- κ B) in renal disease. *Kidney Int* 2001; 59: 415–424
- Wang Y, Rangan GK, Tay Y-C, Wang Y, Harris DC. Induction of monocyte chemoattractant protein-1 by albumin is mediated by nuclear factor κ B in proximal tubule cells. *J Am Soc Nephrol* 1999; 10: 1204–1213
- Zoja C, Donadelli R, Colleoni S, *et al.* Protein overload stimulates RANTES production by proximal tubular cells depending on NF- κ B activation. *Kidney Int* 1998; 53: 1608–1615
- Banba N, Nakamura T, Matsumura M, Kuroda H, Hattori Y, Kasai K. Possible relationship of monocyte chemoattractant protein-1 with diabetic nephropathy. *Kidney Int* 2000; 58: 684–690
- Gomez-Garre D, Largo R, Tejera N, Fortes J, Manzarbeitia F, Egido J. Activation of nuclear factor κ B in tubular epithelial cells of rats with intense proteinuria. Role of angiotensin II and endothelin-1. *Hypertension* 2001; 37: 1171–1178
- Mezzano S, Barria M, Droguett A *et al.* Tubular NF- κ B and AP-1 activation in human proteinuric renal disease. *Kidney Int* 2001; 60: 1366–1377
- Ruiz-Ortega M, Lorenzo O, Ruperez M, Blanco J, Egido J. Systemic infusion of angiotensin II into normal rats activates nuclear factor κ B and AP-1 in the kidney. Role of AT1 and AT2 receptors. *Am J Pathol* 2001; 158: 1743–1756
- Ruiz-Ortega M, Lorenzo O, Ruperez M, Esteban V, Mezzano S, Egido J. Renin-angiotensin system and renal damage: emerging data on angiotensin II as a proinflammatory mediator. *Contrib Nephrol* 2001; 135: 123–137
- Cao Z, Cooper ME. Role of angiotensin II in tubulointerstitial injury. *Semin Nephrol* 2001; 21: 554–562
- Mezzano S, Droguett MA, Burgos ME *et al.* Overexpression of chemokines, fibrogenic cytokines, and myofibroblasts in human membranous nephropathy. *Kidney Int* 2000; 57: 147–158
- Kato S, Luyckx VA, Ots M *et al.* Renin-angiotensin blockade lowers MCP-1 expression in diabetic rats. *Kidney Int* 1999; 56: 1037–1048
- Iwamoto M, Mizuiri S, Tanimoto H *et al.* Nuclear factor- κ B activation in streptozotocin induced diabetic rats kidneys. *J Am Soc Nephrol* 2001; 12: 838a.
- Lal M, Brismar H, Eklof AC, Aperia A. Advanced glycation endproducts induce oxidative stress and activate NF- κ B, PKC- β 1, and TGF- β 1 in mesangial cells. *J Am Soc Nephrol* 2001; 12: 840a.
- Hofmann MA, Schiekofer S, Kanitz M *et al.* Insufficient glycemic control increases nuclear factor-kappa B binding activity in peripheral blood mononuclear cells isolated from patients with type 1 diabetes. *Diabetes Care* 1998; 21: 1310–1316
- Mohamed AK, Bierhaus A, Schiekofer S, Tritschler H, Ziegler R, Nawroth PP. The role of oxidative stress and NF-kappa B activation in late diabetic complications. *Biofactors* 1999; 10: 157–167
- Duque N, Gomez-Guerrero C, Egido J. Interaction of IgA with Fc α receptors of human mesangial cells activates transcription factor nuclear factor- κ and induces expression and synthesis of monocyte chemoattractant protein-1, IL-8, and IFN-inducible protein-10. *J Immunol* 1997; 159: 3474–3482
- Lynn EG, Siow YL, Frohlich J, Cheung GTY, OK. Lipoprotein-X stimulates monocyte chemoattractant protein-1 expression in mesangial cells via nuclear factor- κ B. *Kidney Int* 2001; 60: 520–532
- Abbate M, Zoja C, Corna D, Capitanio M, Bertani T, Remuzzi G. In progressive nephropathies, overload of tubular cells with filtered proteins translates glomerular permeability dysfunction into cellular signals of interstitial inflammation. *J Am Soc Nephrol* 1998; 9: 1213–1224

21. Largo R, Gomez-Garre D, Soto K *et al.* Angiotensin-converting enzyme is upregulated in the proximal tubules of rats with intense proteinuria. *Hypertension* 1999; 33: 732–739
22. Morigi M, Macconi D, Zoja C *et al.* Protein overload-induced NF- κ B activation in proximal tubular cells requires H₂O₂ through a PKC-dependent pathway. *J Am Soc Nephrol* 2002; 13: 1179–1189

Received for publication: 21.8.03

Accepted in revised form: 11.2.04