

Nodavirus infection causes mortalities in hatchery produced larvae of *Lates calcarifer*: first report from India

I. S. Azad^{1,2,*}, M. S. Shekhar¹, A. R. Thirunavukkarasu¹, M. Poornima¹, M. Kailasam¹,
J. J. S. Rajan¹, S. A. Ali¹, M. Abraham¹, P. Ravichandran¹

¹Central Institute of Brackishwater Aquaculture, 75-Santhome High Road, R. A. Puram, Chennai 600 028, India

²Present address: Aquaculture, Fisheries and Marine Environmental Dept, Kuwait Institute for Science Research, Salmiya 22017, Kuwait

ABSTRACT: Larvae (15 to 21 d post hatch, dph) of the Asian sea bass *Lates calcarifer* (Bloch) suffered heavy mortalities (60 to 90%) during the hatchery-rearing phase. Darkened and moribund larvae showed no evidence of bacterial or parasitic infections. Tissue sections of brain and spinal cord showed clear necrotic vacuolation. Electron microscopy revealed membrane-bound viral particles in the cytoplasm of the nerve cells. The viral particles measured 28 to 30 nm in diameter. Primer sets, designed for the amplification of the RNA2 segment of the piscine nodavirus coat protein gene, were used in the RT-PCR analysis of moribund larvae of 20 and 21 dph which produced the amplified product of 430 bp. The clinical manifestations, pathology and electron microscopy observations supported by the RT-PCR analysis suggest that the nerve necrosis was due to nodavirus infection in the larvae. This is the first report of piscine nodavirus infection from the Indian sub-continent.

KEY WORDS: Nodavirus · *Lates calcarifer* · Larvae · RT-PCR · Histopathology · Nervous necrosis virus

Resale or republication not permitted without written consent of the publisher

INTRODUCTION

In 1997 the Central Institute of Brackishwater Aquaculture succeeded in spawning and larval rearing of captive brood stock of Asian sea bass popularly known in India as Bhetki (Thirunavukkarasu & Kailasam 1999). Lately the demand for the seed of this fish is on the rise and as a result managing fish health is becoming more important.

Asian sea bass, like most marine fish, are susceptible to disease during the larval rearing and nursery phases. Susceptibility of the fish to various diseases during these phases has been well documented, particularly for bacterial diseases caused by *Vibrio* species (Wong & Leong 1989, Anderson & Norton 1991, Azad et al. 2004). Subhasinghe & Shariff (1992) reported on bacteria-associated heavy mortalities in cage-cultured Asian sea bass in Malaysian waters and *Flexibacter columnaris* disease was described by Soltani et al. (1996). Lymphocystis disease has also been found in Asian sea bass (Chao 1984).

The first report of viral infection in Asian sea bass was made by Glazebrook et al. (1990), who described a picorna-like virus associated with mortalities of 15 to 20 d old larvae. This disease was also investigated by Munday et al. (1992) in Asian sea bass and is now recognised as being caused by a piscine nodavirus.

Piscine nodavirus belongs to the genus *Betanodavirus* of the family *Nodaviridae* (Mori et al. 1992, Nishizawa et al. 1997, van Regenmortel et al. 2000). It contains 2 single-stranded, positive-sense, non-polyadenylated RNAs, RNA1 and RNA2, the latter of which encodes a structural protein of the virus. The viral particle is 25 to 32 nm in diameter (Mori et al. 1992, Comps et al. 1996).

Due to its affinity to nerve cells and its ability to cause marked histopathological alterations in nervous tissue, the disease condition caused by piscine nodavirus is now variously referred to as viral encephalopathy and retinopathy (VER), viral nervous necrosis (VNN) or fish encephalitis (Mori et al. 1992, Comps et al. 1994). More than 30 species of fish, from different

*Email: azadis@rediffmail.com

geographical locations have been reported to be susceptible to the virus (Glazebrook et al. 1990, Yoshikoshi & Inoue 1990, Mori et al. 1992, Muroga 1995, Comps et al. 1996, Munday & Nakai 1997, Castric et al. 2001). The disease has also been reported in freshwater aquarium fish from Singapore (Hegde et al. 2003).

Histology and RT-PCR are the common methods used for diagnosis of the virus in fish (Mori et al. 1991, Munday et al. 1992, Nishizawa et al. 1994, Grotmol et al. 1995, Lai et al. 2001, Johansen et al. 2002, Hegde et al. 2003). Diagnosis of piscine nodavirus using RT-PCR for the T4 region (427 bp) of SJNNV coat protein gene (RNA2) has been widely used and many workers have reported positive amplification for the presence of the nodavirus in fish species from different geographical locations (Nishizawa et al. 1994, 1997, Castric et al. 2001, Curtis et al. 2001, Iwamoto et al. 2001, Lai et al. 2001). Primer sequences of Nishizawa et al. (1994) have been recommended for the diagnosis of the piscine nodaviruses (OIE 1997).

A batch of Asian sea bass larvae produced in the fish hatchery facilities of the Central Institute of Brackishwater Aquaculture were observed to experience sudden and unexplained mortality after 15 d of larval rearing. Subsequent investigations revealed that the cause of the disease was piscine nodavirus. The present investigation represents the first report of VNN from the Indian sub-continent and extends the known range of this disease.

MATERIALS AND METHODS

Fish. Broodstock procured from the coastal waters of Chennai (Madras), acclimatized and maintained in cement tanks are being used for the purposes of seed production. Since 1997 more than 15 batches of Asian sea bass larvae have been produced in the institute facility. Though the hatchlings were sampled from 0 d post hatch (dph) for routine histology, the larvae from 15 to 21 dph, corresponding to the appearance of clinical signs, were used in the present investigation.

Tissue preparation for light microscopy. Moribund sea bass larvae of 15 to 21 dph in the size range of 5 to 8 mm with the clinical signs were fixed in neutral buffered formalin (NBF). The tissue was processed following standard procedures. Small larvae were processed whole and the larger ones were cut into head and body portions and processed separately. Thin sections (5 to 6 μm) of the tissue were stained with haematoxylin and eosin (H&E) and observed.

Tissue preparation for transmission electron microscopy. Moribund sea bass larvae (18 to 21 dph) were fixed (as done in the case of light microscopy) in 2.5% glutaraldehyde for 3 to 6 h, depending on the size of

the tissue, rinsed in 0.2 M sodium cacodylate buffer (pH 7.4) and post-fixed in 1% osmium tetroxide. The tissues were dehydrated in ethanol and embedded in an epoxy resin (Araldite EM embedding resin). Semi-thin sections (0.5 to 1.0 μm) were cut using a Diatome diamond knife and stained with toluidine blue for observation under a light microscope to mark the areas of interest for later observation by electron microscopy. Ultra-thin sections (80 to 100 nm) were cut, contrasted in uranyl acetate/lead citrate and observed under an electron microscope (Philips, 200C).

Sampling and processing of tissue for RT-PCR. Head portions of the moribund larvae were pooled and half of the pooled sample was fixed in absolute ethanol. Total RNA was extracted from the tissue using the methodology recommended for VNN diagnosis by the Office Internationale des Epizooties (OIE 1997). Briefly, 150 mg of fish tissue was homogenised in a 0.1% diethyl pyrocarbonate (DEPC) treated and autoclaved plastic tissue homogeniser with 0.5 ml distilled water (DEPC treated) and centrifuged at $10\,000 \times g$ for 10 min. The resultant supernatant was mixed with 40 μl of Proteinase K (1 mg ml^{-1}) and 40 μl of 1% sodium dodecyl sulfate (SDS) and incubated at room temperature for 30 min. The suspension was centrifuged as above and the supernatant was used for total nucleic acid extraction using the phenol-chloroform extraction procedures.

RT-PCR. Two μl of total RNA was subjected to reverse transcription using murine leukemia virus (MuLV) reverse transcriptase. The cDNA was prepared using the RT-PCR kit (Bangalore, Genei). Briefly, The total nucleic acids were preheated at 90°C for 5 min and incubated at 42°C for 30 min in 20 μl PCR buffer (10 mM Tris/HCl, pH 8.3, 50 mM KCl) containing 2.5 U MuLV reverse transcriptase (USB), 1.0 U ribonuclease inhibitor, 0.5 μM reverse primer, 1 mM each of 4 deoxynucleotide triphosphates (dNTP), and 5 mM MgCl_2 . The 2 primers, a reverse primer (5'-CGA-GTC-AAC-ACG-GGT-GAA-GA-3') and a forward primer (5'-CGT-GTC-AGT-CAT-GTG-TCG-CT-3'), were used for amplification of a target sequence (430 bases) of the RNA2 (Nishizawa et al. 1994). The amplified product was visualised using 2% agarose gel electrophoresis.

RESULTS

History of pathogenesis and symptoms

The sea bass larvae, reared in fibre reinforced plastic tanks at a density of 30 l^{-1} , were active and normal in their colouration and swimming behavior until 15 dph. Gradually a few of the larvae became slightly darker than normal and showed lethargy.

The larvae congregated as clusters on the surface near the tank wall. Heavy mortalities in the range of 60 to 90% were recorded at this stage. Smaller larvae were severely affected compared to the larger of their siblings. Anorexia, darkened body colouration and loss of reflexes were the major clinical symptoms noticed in the affected fish. Corkscrew or whirling swimming was not noticed. No bacteria or parasites were recorded from the affected fish in the study.

Histopathology by light and electron microscopy

Light microscopy using H&E staining revealed vacuolation and necrosis in the brain, spinal cord and the eye. The toluidine blue stained sections also confirmed these observations. Vacuolation was severe and widespread in the grey and white matter of the brain compared to the nerve cells of the spinal cord (Fig. 1). Initially (15 dph) the spinal cord (Fig. 1a,b), the brain and retina of the eye showed mild necrotic vacuolation (Fig. 1c,d) followed by

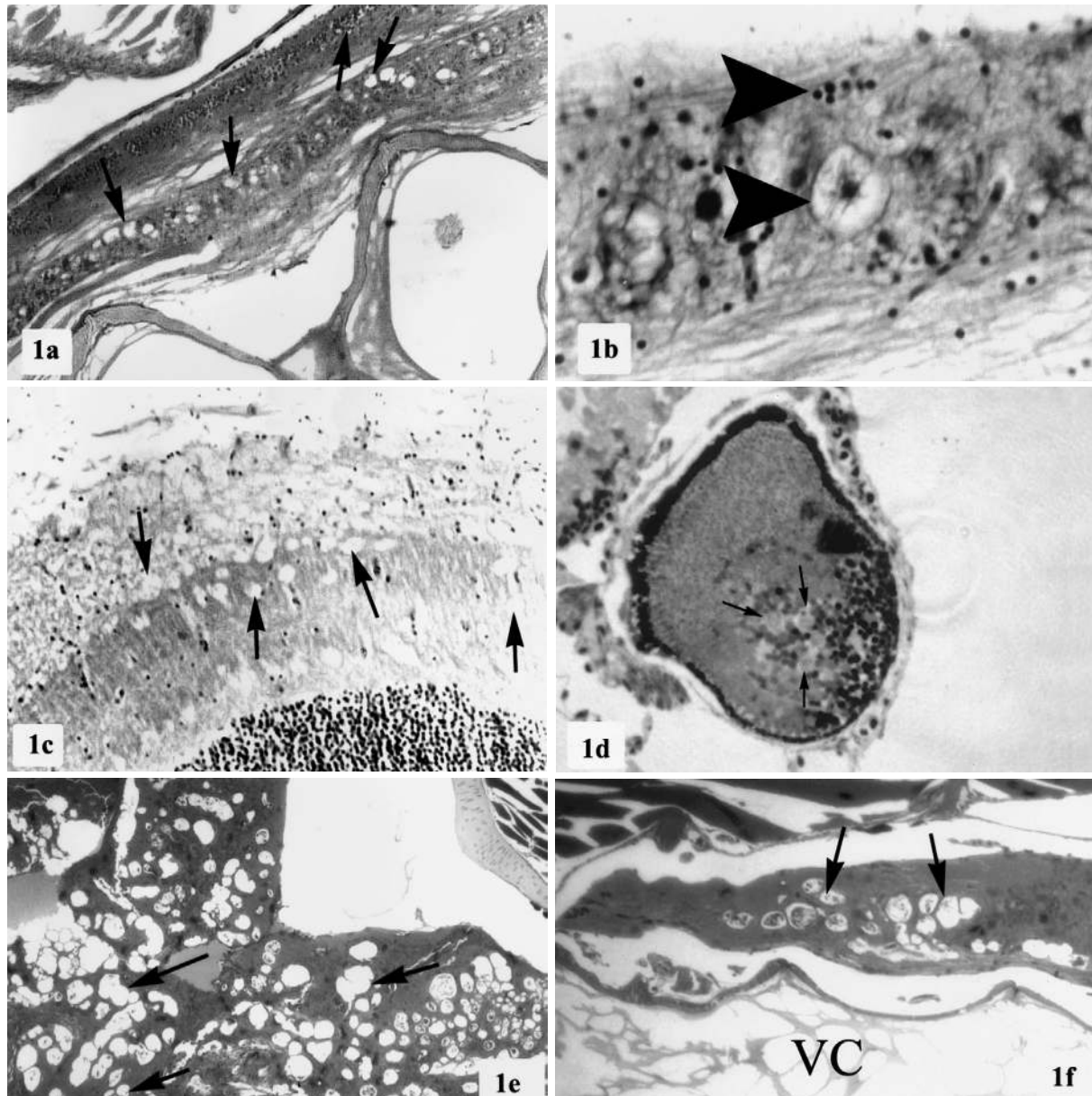


Fig. 1. Haematoxylin and eosin stained sections of (a,b) spinal cord, (c) brain and (d) eye of the sea bass larvae at 15 dph. (a) Vacuolation (arrows) of the spinal cord. (b) Pyknotic nerve cells (arrowheads). (c) Vacuolative degeneration (arrows) of the white matter in the brain tissue. (d) Retina with pyknotic (small arrows) and vacuolative necrosis. Toluidine blue stained semi-thin sections of (e) brain and (f) spinal cord of moribund larvae sampled at 20 d post hatch showing extensive vacuolation (arrows) of both white and grey matter of the brain (e) and spinal cord (f). VC: vertebral column. Magnification: (a) 20 \times , (b) 100 \times , (c-f) 40 \times

heavy and complete necrotic vacuolation of the brain and spinal cord (Fig. 1e,f) by 20 dph.

Electron microscopy of the brain and spinal cord indicated typical membrane bound cytoplasmic inclusions (Fig. 2a,b) with densely packed pockets of virions. Virions released into the surroundings of the cell measured 28 to 30 nm in diameter (Fig. 2c). Several of the nerve cells in the spinal cord showed marginated nucleus and emptied cytoplasm after the viral inclusions were shed into the extracellular spaces (Fig. 2d).

RT-PCR

Amplification with specific primers for RNA2 encoding the T4 region of coat protein gene of nodavirus

resulted in the expected PCR product size of 430 bp as shown in Fig. 3.

DISCUSSION

Observations made in the present investigation on abnormalities in body colouration, feeding and swimming behaviour were similar to those reported by many workers investigating nodavirus-associated infections in Asian sea bass and other fish species (Glazebrook et al. 1990, Yoshikoshi & Inoue 1990, Munday & Nakai 1997, Breuil et al. 2001, Barker et al. 2002). In the present investigation more than 60% of the larvae died within 48 h of onset of observed clinical symptoms, indicating the severity of the nodavirus

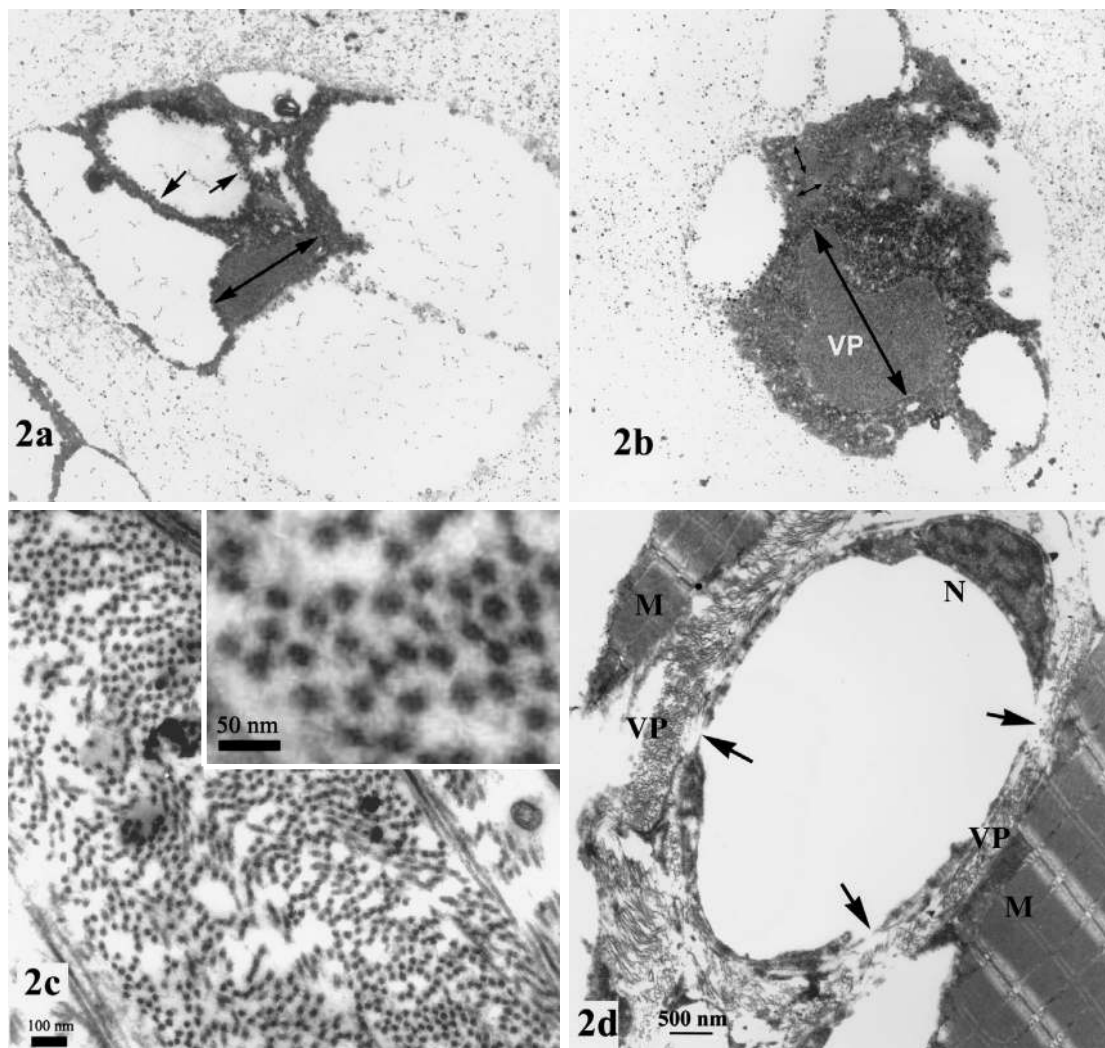


Fig. 2. Electron micrographs of the central nervous system. (a) Membrane bound viral particles in the cell organelle (arrows) and (b) viral inclusions (double-ended arrows) depicting intracytoplasmic localisation of the virus. (c) Viral particles measuring 28 to 30 nm in the intracellular spaces; (inset) very high magnification of the viral particles. (d) Nerve cell of the spinal cord with emptied cytoplasm and cornered nucleus. Arrows indicate probable exit points of viral particles. VP: viral particles, M: muscle, N: nucleus. Magnification: (a,b) 70 000×

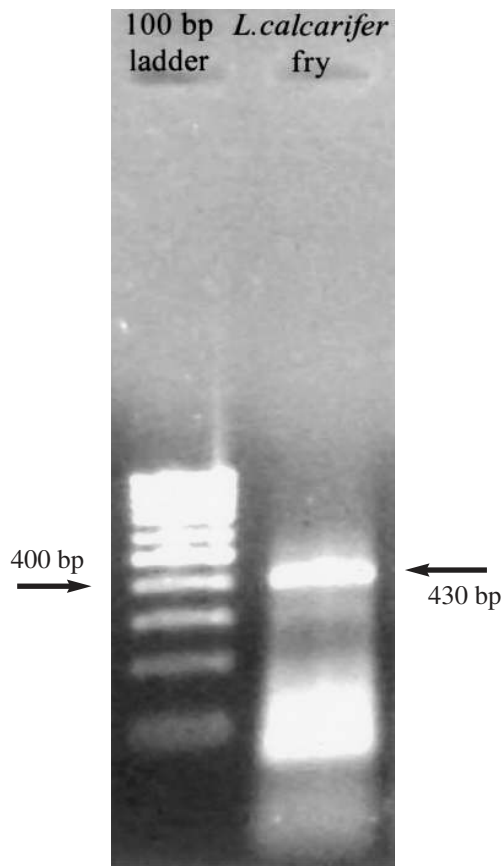


Fig. 3. Agarose gel electrophoresis visualisation of amplified (430 bp) RT-PCR product of the T4 region of the nodavirus

infection. Munday et al. (1992) demonstrated a correlation between the mass mortality of hatchery-reared larvae of Asian sea bass and the vacuolated lesions in the brain and the retina of the larvae. It was observed that the larvae were susceptible at 15 dph onwards, with high mortalities by 19 to 21 dph. Nerve necrosis and vacuolation in fish have been mainly attributed to the viral proliferation and cytopathogenicity itself rather than to any other terminal events (Grotmol et al. 1997). Higher susceptibility of younger larvae to nodavirus compared to the older ones (Johansen et al. 2002) has been reported in many fish species. Asian sea bass larval mortalities have been reported from Indonesia, where abnormal swimming, anorexia and sinking to the bottom were recorded as the major clinical manifestations (Zafran et al. 1998). However, we observed that the larger larvae of Asian sea bass remained less affected compared to their smaller siblings. This could be due to the stress the smaller larvae experience in a co-existing population. Stress factors such as competition for food, sub-optimal water quality, crowding and poor nutrition have been known to aggravate nodavirus infections in sea bass (OIE 1997).

Though histopathology has been the most consistent indicator of nodavirus infection, it is time consuming. PCR-based diagnostics have been widely used to confirm the presence of nodavirus in fish. The T4 region of the viral protein coat gene (RNA2) has been used for diagnostic purposes (Nishizawa et al. 1994). The OIE has recommended the use of this primer set as it could amplify the RNA2 sequence of piscine nodavirus in 9 out of 10 samples from different geographical locations (Nishizawa et al. 1997, Thiery et al. 1999). Results of the present study, clearly showing the vacuolative nervous necrosis of brain, spinal cord and eye and the positive amplification of 430 bp belonging to the T4 region of the piscine nodavirus, are in conformity with the diagnostic features for the presence of piscine nodavirus listed by the OIE.

All the investigations carried out thus far related to the piscine nodavirus in fish have been consistent in reporting necrotic vacuolation of the nerve tissue of the central nervous system. This investigation supports previous studies that found that the nodaviruses are neurotrophic. The results are significant in that they provide an extended distribution range of the piscine nodavirus and contribute to strengthen the diagnostic value of the primer set aimed at amplifying the RNA2 of the T4 region of piscine nodavirus.

Acknowledgements. The authors express their gratitude to Dr. C. V. Mohan, Aquatic Animal Health Expert, Network of Aquaculture Centres in Asia-Pacific, Bangkok, and Dr. K. M. Shankar, Professor, College of Fisheries, Mangalore, India, for critically going through the manuscript. We are indebted to the Christian Medical College and Hospital for extending the electron microscope facilities and we specially thank the Professor in charge of the electron microscope laboratory. Our thanks are due to Mr. Jagannathan and Miss. Rita, technical staff of the Lab for their co-operation and help. We also thank Mr. Subburaj and Mr. Thiagaraj, Fish Culture Division, Central Institute of Brackishwater Aquaculture, for their help.

LITERATURE CITED

- Anderson IG, Norton JH (1991) Diseases of barramundi in aquaculture. *Aust Aquacult* 5(8):21–24
- Azad IS, Thirunavukkarasu AR, Kailasam M, Rajan JJS (2004) Virulence and histopathology of *Vibrio anguillarum*-like (VAL) bacterium isolated from hatchery produced juveniles of *Lates calcarifer* (Bloch). *Asian Fish Sci* 17:101–110
- Barker DE, Mackinnon AM, Boston L, Burt MDB and 6 others (2002) First report of piscine nodavirus infecting wild winter flounder *Pleuronectes americanus* in Passamaquoddy Bay, New Brunswick, Canada. *Dis Aquat Org* 49:99–105
- Breuil G, Mouchel O, Fauvel C, Pepin JF (2001) Sea bass *Dicentrarchus labrax* nervous necrosis virus isolates with distinct pathogenicity to sea bass larvae. *Dis Aquat Org* 45:25–31
- Castric J, Thiéry R, Jeffroy J, de Kinkelin P, Raymond JC (2001) Sea bream *Sparus aurata*, an asymptomatic con-

- tagious fish host for nodavirus. *Dis Aquat Org* 47:33–38
- Chao TM (1984) Studies on the transmissibility of lymphocystis disease occurring in sea bass (*Lates calcarifer*, Bloch). *Singap J Pri Ind* 12:11–16
- Comps M, Pepisn JF, Bonami K (1994) Purification and characterisation of 2 fish encephalitis viruses (FEV) infecting *lates calacrifer* and *Dicentrarchus labrax*. *Aquaculture* 123:1–10
- Comps M, Trindade M, Delsert C (1996) Investigations of fish encephalitis virus (FEV) expression in marine fishes using DIG-labelled probes. *Aquaculture* 143:113–121
- Curtis PA, Drawbridge M, Iwamoto T, Nakai T, Hedrick RP, Gendron AP (2001) Nodavirus infection of juvenile white sea bass, *Atractoscion nobilis*, cultured in southern California: first record of viral nervous necrosis (VNN) in North America. *J Fish Dis* 24:263–271
- Glazebrook JS, Heasman MP, de Beer SW (1990) Picorna-like viral particles associated with mass mortalities in larval barramundi, *Lates calcarifer* Bloch. *J Fish Dis* 13:245–249
- Grotmol S, Totland GK, Kvellestad A, Fjell K, Olsen AB (1995) Mass mortality of larval and juvenile hatchery-reared halibut (*Hippoglossus hippoglossus* L.) associated with the presence of virus-like particles in vacuolated lesions in the central nervous system and retina. *Bull Eur Assoc Fish Pathol* 15:176–180
- Grotmol S, Totland GK, Thorud K, Hjeltne BK (1997) Vacuolating encephalopathy and retinopathy associated with a nodavirus-like agent: a probable cause of mass mortality of cultured larval and juvenile Atlantic halibut *Hippoglossus hippoglossus*. *Dis Aquat Org* 29:85–97
- Hegde A, The HC, Lam TJ, Sin YM (2003) Nodavirus infection in freshwater ornamental fish, guppy, *Poecilia reticulata*—comparative characterization and pathogenicity studies. *Arch Virol* 148:576–586
- Iwamoto T, Mori K, Arimoto M, Nakai T (2001) A combined cell-culture nad RT-PCR method for rapid detection of piscine nodaviruses. *Dis Aquat Org* 24:231–236
- Johansen R, Ranheim T, Hansen MK, Taksdal T, Totland GK (2002) Pathological changes in the juvenile Atlantic halibut *Hippoglossus hippoglossus* persistently infected with nodavirus. *Dis Aquat Org* 50:161–169
- Lai YS, Murali S, Chiu HC, Ju HY and 5 others (2001) Propagation of yellow grouper nervous necrosis virus in a new nodavirus susceptible cell line from yellow grouper, *Epinephelus awoara* (Temmink & Schlegel), brain tissue. *J Fish Dis* 24:299–309
- Mori K, Nakai T, Nagahara M, Muroga K, Mekuchi T, Kunno T (1991) A viral disease in hatchery-reared larvae juveniles of redspotted grouper. *Gyobyo Kenkyu* 26:209–210
- Mori K, Nakai T, Muroga K, Arimoto M, Mushiaki K, Furusawa I (1992) Properties of a new virus belonging to Nodaviridae found in larval striped jack (*Pseudocaranx dentex*) with nervous necrosis. *Virology* 187:368–371
- Munday BL, Nakai T (1997) Special topic review: nodaviruses as pathogens in larval and juvenile marine finfish. *World J Microbiol Biotechnol* 13:375–381
- Munday BL, Langdon JS, Kyatt A, Humphrey JD (1992) Mass mortality associated with a viral-induced vacuolating encephalopathy and retinopathy of larvae and juvenile barramundi, *Lates calcarifer* Bloch. *Aquaculture* 103:197–211
- Muroga K (1995) Viral and bacterial diseases in larval juvenile marine fish and shellfish: a review. *Fish Pathol* 30:71–85
- Nishizawa T, Mori K, Nakai T, Furusawa I, Muroga K (1994) Polymerase chain reaction (PCR) amplification of RNA of striped jack nervous necrosis virus (SJNNV). *Dis Aquat Org* 18:103–107
- Nishizawa T, Furuhashi M, Nagai T, Nakai T, Muroga K (1997) Genomic classification of fish nodaviruses by molecular phylogenetic analysis of the coat protein gene. *Appl Environ Microbiol* 63:1633–1636
- OIE (1997) Viral encephalopathy and retinopathy or viral nerve necrosis. In: Corne DK, Speare DJ, Griffiths S, Cok M, Ritchie R, Olivier G (eds) *OIE Diagnostic Manual for Aquatic Animal Diseases*. Office Internationale des Epizooties, Paris, p 99–107
- Soltani M, Munday BL, Burke CM (1996) The relative susceptibility of fish to infections by *Flexibacter columnaris maritimus*. *Aquaculture* 140:259–264
- Subhasinghe RP, Shariff M (1992) Multiple bacteriosis, with special reference to spoilage bacterium *Shewanella putrefaciens*, in cage culture barramundi in Malaysia. *J Aquat Anim Health* 4:309–311
- Thierry R, Arnauld C, Delsert C (1999) Two isolates of sea bass, *Dicentrarchus labrax* L., nervous necrosis virus with distinct genomes. *J Fish Dis* 22:201–207
- Thirunavukkarasu AR, Kailasam M (1999) Seed production technology for marine fishes. In: Lazarus S, Prakash SG, Vincent SG (eds) *Proceedings of the First National Seminar on Trends in Marine Biotechnology*. ICAS Publication No. 2, p 111–114
- van Regenmortel MHV, Fauquet CM, Bishop DHL, Carstense EB and 7 others (eds) (2000) *Virus taxonomy, classification and nomenclature of viruses*, 7th edn. Academic Press, San Diego, CA
- Wong SY, Leong TS (1989) A comparative study of *Vibrio* infections in healthy and diseased marine finfishes cultured in floating cages near Penang, Malaysia. *Special Issue, Asian Fish Sci* 3:353–359
- Yoshikoshi K, Inoue K (1990) Viral nerve necrosis in hatchery-reared larvae and juveniles of Japanese parrotfish, *Oplegnathus fasciatus* (Temmink & Schlegel). *J Fish Dis* 13:69–77
- Zafran, Harada T, Koesharyani I, Yuasa K, Hatai K (1998) Indonesian hatchery reared seabass larvae (*Lates calcarifer*), associated with viral nervous necrosis (VNN). *Indonesian Fish Res J* 4:19–22

Editorial responsibility: Jo-Ann Leong,
Kaneohe, Hawaii, USA

Submitted: April 2, 2004; Accepted: June 3, 2004
Proofs received from author(s): December 17, 2004