

Non-Transgenic Mouse Models of Kidney Disease

Michael Rabe Franz Schaefer

Division of Pediatric Nephrology, Center for Pediatrics and Adolescent Medicine, University of Heidelberg, Heidelberg, Germany

Key Words

Kidney disease · Mouse models · Fibrosis · Mouse

Abstract

Animal models are essential tools to understand the mechanisms underlying the development and progression of renal disease and to study potential therapeutic approaches. Recently, interventional models suitable to induce acute and chronic kidney disease in the mouse have become a focus of interest due to the wide availability of genetically engineered mouse lines. These models differ by their damaging mechanism (cell toxicity, immune mechanisms, surgical renal mass reduction, ischemia, hypertension, ureter obstruction etc.), functional and histomorphological phenotype and disease evolution. The susceptibility to a damaging mechanism often depends on strain and gender. The C57BL/6 strain, the most commonly used genetic background of transgenic mice, appears to be relatively resistant against developing glomerulosclerosis, proteinuria and hypertension. This review serves to provide a comprehensive overview of interventional mouse models of acute and chronic kidney disease.

© 2016 S. Karger AG, Basel

the preferred animal in kidney research, the use of mice has overtaken that of rats with the advent of murine knockout and transgenic technologies around the turn of the century [1]. Genetically modified mouse lines provide unique opportunities to evaluate the impact of individual proteins on the susceptibility to develop a kidney disease, the phenotype and natural evolution of the disease and the responsiveness to therapeutic interventions.

When designing an experimental protocol, it is critical to evaluate which model of kidney disease, animal strain, gender and study end points are most suitable to address the scientific question of interest. A wide range of rodent models is available to induce various renal phenotypes (e.g., nephrotic syndrome, tubulointerstitial damage, glomerulosclerosis, thrombotic microangiopathy, autoimmune diseases, acute vs. chronic kidney disease [CKD]) (for overview, see fig. 1, 2 and table 1). Most interventional models of kidney disease were initially developed and used in rats and many, but not all, were later transferred to the murine setting. The purpose of this review is to provide a comprehensive overview of kidney disease models established in the mouse.

Genetic Susceptibility to Kidney Damage

Rodent models of kidney disease are essential to understand the impact of genetic factors on the manifestation and progression of renal failure as well as in pharmacological research. While historically the rat used to be

The choice of the right mouse strain is essential since some strains are not susceptible to certain interventions aimed at inducing kidney disease. For example, C57BL/6 mice, the strain which provides the genetic background for

many knockout mice, seem to be relatively resistant to the development of proteinuria, glomerulosclerosis [2–4] and hypertension [5]. Some mouse strains (including C57BL/6) have only one renin gene and a decreased activity of the renin-angiotensin-aldosterone system (RAAS) compared to mice with 2 renin genes (e.g., 129 strain) [6]. In the subtotal nephrectomy model, RAAS activation plays an important role in developing fibrosis of the remnant kidney.

Moreover, the vulnerability of kidneys differs between genders. Female mice seem to be less sensitive to ischemic kidney damage [7] and streptozotocin (STZ)-induced diabetic nephropathy [8] and are less prone to proteinuria [4].

Choice and Assessment of End Points

Some of the murine models of kidney disease result in proteinuria, some in decreased glomerular filtration rate (GFR) with elevated serum creatinine and blood urea nitrogen (BUN) and some in both. The classical histological sign of CKD is progressive fibrosis and loss of nephrons, the functional units of the kidney [9]. Fibrosis of the kidney can be measured histologically by staining with Masson's trichrome or Sirius red and immunofluorescent staining of fibroblasts (with anti-FSP-1), myofibroblasts (with anti-alpha SMA) and different types of collagen. Also, measurement of other (early) fibrosis markers (e.g., TGF-beta 1) on protein or mRNA level can be useful to assess progression of fibrosis.

Non-Surgical Models

Cisplatin

Cisplatin is a platinum-based anticancer drug and nephrotoxicity is the most important and dose-limiting clinical side effect of cisplatin. The compound is cleared by glomerular filtration and tubular secretion and accumulates in the renal tubules, where it exerts direct toxicity to the tubular epithelial cells, leading to local inflammation and interstitial fibrosis. In addition, cisplatin alters renal blood flow [10].

Intraperitoneal (i.p.) injection of an appropriate dose of cisplatin (often 20 mg/kg) in C57BL/6J mice leads to acute kidney failure with marked increases of BUN and serum creatinine within 3 days [11].

Torres et al. [12] developed a murine model of CKD based on repetitive cisplatin administrations. Two doses of i.p. cisplatin (15 mg/kg) were injected at a 2-week in-

terval. GFR was significantly reduced 2 weeks after the second injection and remained decreased during 7 weeks of observation. Plasma creatinine was also elevated compared to controls at 7 and up to 23 weeks after the second cisplatin injection. Kidneys decreased in volume and showed myofibroblast proliferation, increased apoptosis and loss of interglomerular mass by light microscopy and immunohistochemistry. Three-dimensional microscopy revealed a reduction of cuboidal cells of the glomerular capsule and glomerulotubular disconnection [12].

Aristolochic Acid

Aristolochic acid (AA) nephropathy is a progressive tubulointerstitial nephritis caused by a toxin of Aristolochia plants, which damages predominantly the proximal tubule of the nephron. AA has been identified as the underlying cause of Chinese Herb and Balkan nephropathy [13].

Huang et al. [14] tested different regimes to induce an AA nephropathy in C57BL/6 mice. A single i.p. dose of 10 mg/kg aristolochic acid I (AAI) resulted in acute kidney failure leading to death within 14 days. To induce CKD with tubulointerstitial fibrosis, 3 mg/kg AAI were administered every 3 days for 6 weeks followed by 6 weeks remodeling time. The mice exhibited increased levels of serum creatinine and BUN, reduced kidney weight, tubulointerstitial fibrosis (more severe in male mice), elevated systolic blood pressure and an elevated urine albumin/creatinine ratio. However, experiments observing a longer time period after AAI treatment showed functional recovery of the kidney [14].

Although it has been proposed that AA leads to tubulointerstitial damage, administration of AAI in CD1 mice also caused albuminuria, effacement of podocyte foot processes and depletion of podocytes [15].

Adriamycin

Adriamycin is an antineoplastic agent from the group of anthracyclines. Adriamycin induced nephropathy is an experimental model of focal glomerular sclerosis and nephrotic syndrome. A single intravenous injection of adriamycin (dose 10–11 mg/kg) in BALB/c mice leads to proteinuria (present about 5 days post-injection lasting for at least 6 weeks), reduced serum albumin and reduced creatinine clearance (about 50% of control after 4 weeks) [16].

Adriamycin acts as a podocyte toxin and leads to foot process fusion. Histopathologic findings include glomerulosclerosis, infiltration of macrophages and T-lymphocytes, and progressive tubulointerstitial fibrosis [1, 16].

Adriamycin-induced nephropathy cannot be induced in all strains of mice. For example, C57BL/6 mice do not

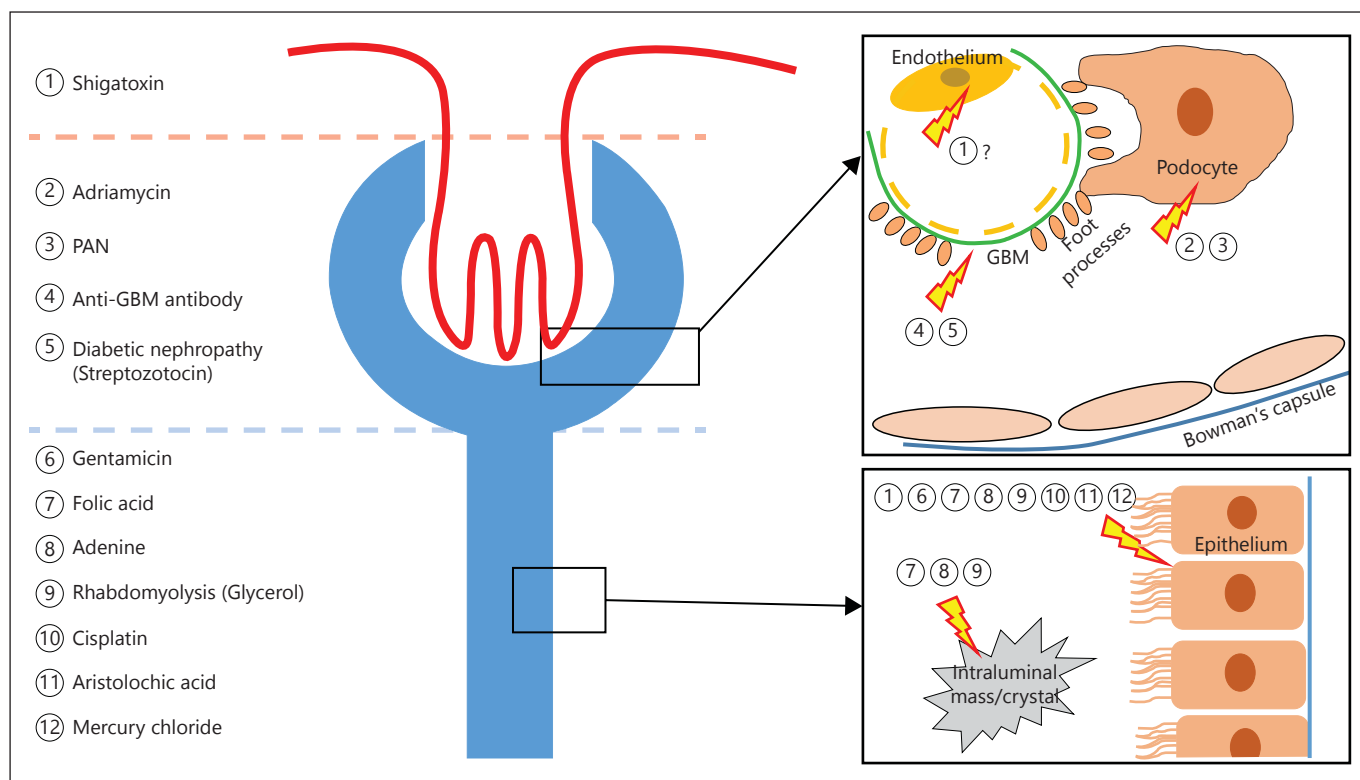


Fig. 1. Non-surgical mouse models of kidney disease.

develop focal glomerular sclerosis or proteinuria after the injection of adriamycin [16]. Papeta et al. [17] showed that the interstrain variability of sensitivity to adriamycin nephropathy depends on a mutation in *PRKDC*, which is involved in the maintenance of the mitochondrial genome.

Folic Acid

I.p. injection of folic acid (FA) at a dose of 250 mg/kg in mice causes acute kidney injury with a maximum increase of serum creatinine, BUN and urine glucose after 2 days [18]. Whereas these parameters return to control levels within 10–15 days, persistent polyuria and decreased urine osmolality suggest a permanent tubular damage even after recovery of global kidney function [18].

After FA administration, crystals occur in the tubular lumen. However, mechanical blockage of the tubules is not the sole mechanism of acute FA nephrotoxicity. Alkalinization of urine decreases intraluminal deposition of FA crystals but tubular lesions are still apparent, indicating that FA has direct nephrotoxic potential [19]. Histopathological findings are typical of acute tubular necrosis

with tubular dilatation, brush border loss, cast formation and accumulation of intraluminal debris 2 days after FA administration and partial regeneration after 6 and 14 days [18].

Acute kidney injury is followed by fibrosis with elevated fibrosis markers (TGF- β 1 and α -SMA) after 6 days and relevant tubulointerstitial fibrosis after 14 days [18]. The area of fibrosis and loss of kidney weight after 3 weeks are in linear correlation with the degree of early kidney damage as indicated by the 2-day BUN level [20].

Adenine

Adenine feeding of rats leads to CKD, and it is assumed that byproducts formed during adenine metabolism crystallize in proximal tubules and lead to degeneration [1]. Jia et al. [21] generated a protocol for adenine-induced kidney disease in mice. To circumvent the problem that mice avoid eating adenine, the compound was mixed with a casein-containing diet that blunted the smell and taste [21]. Supplementation of 0.2% adenine with food for 6 weeks resulted in CKD in C57BL/6 mice with increased levels of urea, creatinine, phosphate and parathormone in serum [22]. Histology shows tubuloin-

terstitial damage with inflammatory cell infiltration, interstitial fibrosis and loss of tubular epithelial cells. No alterations of glomerular architecture are observed with this model [22]. In some, but not all published studies, proteinuria was also seen in C57BL/6 mice after adenine treatment [21, 23]. Ali et al. [23] tested different dosages of adenine for their potential to induce CKD in mice. Supplementation of 0.3% adenine was lethal to all animals within 3–4 days, whereas 0.2% adenine in food led to stable chronic renal insufficiency without mortality in the first 4 weeks [23]. Mori-Kawabe et al. [24] recently reported no alterations of serum creatinine or BUN after supplementation of food with 0.125% adenine for 4 weeks. Hence, the ideal concentration of adenine in food to induce CKD should be between 0.2 and 0.25%.

Anti-GBM-Nephritis

Goodpasture syndrome is an autoimmune disease characterized by rapidly progressive glomerulonephritis and pulmonary hemorrhage. It is caused by antibodies against a protein in the glomerular basement membrane (GBM) – the NC1 domain of the alpha 3 chain of type IV collagen (alpha3(IV)NC1) and linear deposits of IgG along the GBM are seen in immunohistology [25].

Autoimmune anti-GBM-glomerulonephritis in mice can be induced by immunization with heterologous or homologous alpha3(IV)NC1 or preparations of GBM, as well as by injection of heterologous anti-GBM serum.

Hopfer et al. [26] injected recombinant human alpha3(IV)NC1 in DBA/1, C57BL/6, AKR and NOD mice; DBA/1 mice developed severe glomerulonephritis and end-stage renal disease within 3 months with glomerulosclerosis, crescent formation and tubulointerstitial damage. C57BL/6 and AKR mice showed a slower progression of anti-GBM glomerulonephritis with evident histological abnormalities after 6 months; NOD mice developed only minimal glomerular changes [26].

An anti-GBM-nephritis can also be generated in mice by intravenous application of antisera against GBM raised in a different species. This is often combined with pre-immunization by injection of IgG from the donor animal (e.g. sheep IgG if sheep anti-mouse GBM is used) days before injection of anti-GBM [27]. Xie et al. [28] compared different mouse strains (not including C57BL/6) for their susceptibility to develop an immune nephritis after injection of anti-mouse GBM reactive sera. BUB/BnJ, DBA/1J and 129/svJ mice developed severe proteinuria and increased BUN, indicating rapidly progressive glomerulonephritis [28]. The variable susceptibility to immune-mediated nephritis can be explained by the sub-

stantial differences in the interleukin expression profiles between mice strains, which modulate the progression of this disease [29].

Glycerol

Intramuscular injection of glycerol leads to rhabdomyolysis and released myoglobin accumulates in the tubules of the kidney. It is assumed that myoglobin damages tubular cells via oxidative stress and inflammation and leads to renal vasoconstriction [30, 31]. To induce acute kidney failure an appropriate dose of glycerol (5–10 ml/kg 50% glycerol) has to be injected intramuscularly into the hind limbs of mice. Before administration of glycerol, mice must be deprived of water for about 24 h. After intramuscular administration of glycerol in mice, BUN levels are significantly elevated within a few hours [30]. In SCID mice, intramuscular injection of 7.5 ml/kg glycerol results in maximum elevation of BUN and serum creatinine after 24 h and remains elevated for 5 days to normalize thereafter [32]. Histopathological analysis shows tubular damage, which is most severe in the renal corticomedullary boundary zone [30].

Elevated serum creatinine and BUN in this model may not only be related to decreased renal function but also reflect rhabdomyolysis itself. Hence, in this animal model, measurement of the GFR or creatinine clearance should be preferred. Nishida et al. [30] reported a significant reduction of endogenous creatinine clearance 24 h after glycerol injection.

Shiga Toxin – Hemolytic Uremic Syndrome

Shiga toxin (Stx) produced by certain *Escherichia coli* strains causes thrombotic microangiopathy in humans, leading to acute kidney injury. Hemolytic uremic syndrome (HUS) is defined as the combination of acute renal failure, hemolytic anemia and thrombocytopenia. Most cases of HUS (about 90%) in children are caused by Stx, while other cases can be caused by genetic abnormalities in regulators of the complement cascade [33].

In contrast to humans, mice express the Stx-receptor Gb3 in tubular epithelial cells but not in the endothelium of the glomerular capillaries. Consistent with this finding, Porubsky et al. [34] found acute tubular dysfunction without thrombotic microangiopathy after i.p. injection of Shiga toxin-2 (Stx2). By contrast, Keepers et al. [35] reported hemolysis, thrombocytopenia, increased retention parameters and typical histological changes with formation of microthrombi and glomerular fibrin deposition after combined administration of 300 µg/kg LPS and 225 ng/kg Stx2 in C57BL/6 mice. Whereas mice exposed

Table 1. Summary of mouse models of CKD

Model	Protocol/dosage	Target	Proteinuria/ albuminuria	Histological changes	Comment
AA	3 mg/kg i.p. every 3 days for 6 weeks [14]	Tubuloepithelial cells	+	Tubulointerstitial fibrosis	Acute kidney injury after injection of high dose (≥ 10 mg/kg)
Adriamycin	10–11 mg/kg i.v. once (in BALB/c) [16]	Podocytes	+	Glomerulosclerosis, global sclerosis	Interstrain variability (not inducible in B6)
Adenine	0.2% in food [22]	Proximal tubule	+/-	Tubulointerstitial damage and fibrosis, crystals in tubules and tubular dilatation	Supplementation of 0.3% adenine is lethal
Anti-GBM nephritis	Injection of $\alpha 3$ (IV)NC1 [26] or antisera against GBM [27]	GBM, glomerulus	+	Glomerulosclerosis, crescent formation, tubulointerstitial damage	Interstrain variability DBA/1J >B6
PAN	450 mg/kg i.p. (in B6 mice) [41]	Podocytes	+	Minimal change nephrotic syndrome, effacement of podocyte foot process	Nephrotic syndrome in B6, ~50% of BALB/c or C3H die
Cisplatin	2 \times 15 mg/kg i.p. at a 2-week interval [12]	Tubuloepithelial cells	-*	Loss of interglomerular mass, glomerulotubular disconnection	*No proteinuria in B6 (not tested in other mice)
Diabetic nephropathy	Injection of 40–50 mg/kg/STZ i.p. per day for 5 days [3]	Glomerulus (damage by hyperglycemia)	+	Mesangial expansion, nodular glomerulosclerosis	Interstrain variability (mild histologic changes and no relevant proteinuria in B6)
UUO	Ligation of one ureter	Obstruction, hydronephrosis	-	Hydronephrosis, tubular injury, interstitial fibrosis, macrophage infiltration	Fibrosis is more severe in neonatal mice; no relevant changes in creatinine and BUN
5/6 nephrectomy	Uninephrectomy + 2/3 nephrectomy	Reduction of renal mass	+	Glomerulosclerosis and tubulointerstitial fibrosis (in remnant kidney)	Interstrain variability; C57BL/6 are more resistant; resistance of B6 can be overcome by s.c. administration of angiotensin 2
DOCA-salt hypertension	Uninephrectomy + DOCA s.c. + saline p.o.		+	Higher content of collagen in kidney and heart (LV)	

to these toxin doses die within 3–4 days, administration of 100 μ g/kg LPS and 50 ng/kg Stx2 induced milder, non-lethal HUS [36].

Diabetic Nephropathy

Diabetic nephropathy is the leading cause of end-stage renal disease in adults worldwide. STZ induces type I-like diabetes mellitus in mice. It is transported into the cells via the GLUT2 transporter and destroys beta-pancreatic cells through DNA damage. Due to the fact that renal and hepatic cells also express GLUT2, STZ has additional direct nephrotoxic and hepatotoxic effects apart from renal lesions induced by diabetes [1]. Mice strains differ in their susceptibility to develop hyperglycemia, proteinuria and histological changes of kidney following the injection of STZ [8]. C57BL/6 mice are high responders to STZ and

develop hyperglycemia, but are relatively resistant to renal injury. DBA/2 mice are more susceptible to develop proteinuria and histopathological kidney damage. Male mice develop higher glucose levels and more marked proteinuria after treatment with STZ than female animals [8].

Approximately 25–35 weeks after repetitive i.p. injections of 40 mg/kg STZ, DBA/2J mice develop substantial proteinuria, mesangial expansion and nodular glomerular sclerosis, whereas repetitive administration of 50 mg/kg STZ in C57BL/6 causes only a mild increase in mesangial expansion and no significant proteinuria [3]. ApoE-deficient C57BL/6 mice are more affected than wild-type C57BL/6 mice and develop a more severe diabetic nephropathy [37]. Also, hypertension and endothelial dysfunction seem to play a key role in the development of diabetic nephropathy. STZ-treated C57BL/6 mice with an

endothelial nitric oxide synthase deficiency develop hypertension, albuminuria, mesangial matrix expansion, nodular glomerulosclerosis and uremia [38].

Other Non-Surgical Models

Apart from the non-surgical mouse models of kidney disease described above, many other methods have been tested, the most important of which will be briefly mentioned here.

Albumin overload in proximal tubules by i.p. injections of bovine serum albumin (administered at a dose of 10 g/kg) causes proteinuria and tubulointerstitial fibrosis in mice from the 129 strain [39]. This effect is strain dependent and C57BL/6 mice are considered to be more resistant compared to the 129 strain and other mouse strains [4].

Inorganic mercury accumulates in the kidneys and causes damage to proximal tubular epithelial cells and acute kidney failure. Treatment of mice with mercury chloride leads to uremia within 48 h in susceptible strains (e.g., C3H/He mice) whereas C57BL/6 mice appear to be relatively resistant against exposure to this heavy metal [40].

I.p. injection of a high dose of puromycin aminonucleoside (PAN) (450 mg/kg) induces nephrotic syndrome in C57BL/6 mice with albuminuria, hypoalbuminemia and hypercholesterolemia and effacement of podocyte foot processes in electron microscopy analysis [41]. Hence, this intervention seems to provide a suitable model of minimal change glomerulopathy.

Gentamicin, an aminoglycoside antibiotic, causes acute kidney injury in mice. Mice treated with gentamicin i.p. have increased levels of BUN and serum creatinine and histological analysis reveals severe vacuolization of renal proximal tubule cells [42].

Surgical Models

Sub-Total (5/6) Nephrectomy

Sub-total nephrectomy combines unilateral nephrectomy with pole resection, ligation of polar branches of the renal artery or electrocoagulation of the remaining kidney. The procedure was originally developed for use in rats; the intervention is fraught with higher rates of complications and animal losses in mice.

Remnant kidneys develop glomerulosclerosis and tubulointerstitial fibrosis, but histological and functional changes vary between different mouse strains. After 5/6 nephrectomy, C57BL/6, CD1, and 129S3 mice develop persistently elevated levels of serum creatinine and BUN within a week [43].

C57BL/6 mice appear to be much less prone to glomerulosclerosis, hypertension and proteinuria compared to CD1 and 129/sv mice [2, 43]. C57BL/6 mice have only one renin gene and baseline renin activity is 10-fold lower compared to mouse strains possessing 2 renin genes (f.e. 129 strains) [6]. The resistance of C57BL/6 mice to develop hypertension, proteinuria and glomerulosclerosis can be overcome by chronic angiotensin-II administration [43], suggesting that the degree of activation of the RAAS plays a pivotal role in the progression of CKD after sub-total nephrectomy in mice.

DOCA-Salt Hypertension

The deoxycorticosterone acetate (DOCA)-salt hypertension model combines uninephrectomy with subcutaneous (s.c.) administration of DOCA-salt (via s.c. implantation of a DOCA pellet) and supplementation of drinking water with 0.9–1% NaCl (e.g. [44]). After 4 weeks, C57BL/6 mice were found to have significantly increased systolic blood pressure, proteinuria and higher content of collagen in the left ventricle of the heart and in the kidney, indicating a fibrotic alteration of both organs [44]. C57BL/6 mice seem to be relatively resistant to hypertension-induced renal injury compared to other mouse strains (e.g., 129/sv) [5]. However, combining DOCA-salt hypertension with chronic s.c. angiotensin II administration (via osmotic mini pump) aggravated renal damage in C57BL/6 [45].

Unilateral Ureteral Obstruction

Unilateral ureteral obstruction (UUO) is a classic mouse model to investigate the process of tubulointerstitial kidney fibrosis and is suitable for all mouse strains, including C57BL/6 [9].

UUO must be performed under general anesthesia. After abdominal incision, usually one ureter is ligated twice (with or without additional severance of the ureter).

Ureteral obstruction leads to hydronephrosis, tubular injury and cell death, interstitial macrophage infiltration and interstitial fibrosis with proliferation of fibroblasts and myofibroblasts. Complete ureteral obstruction results in marked loss of renal parenchyma and fibrosis within 1–2 weeks. Fibrosis is more severe in neonatal than in adult mice [46]. A disadvantage of this mouse model is the lack of possibility to estimate kidney function from serum creatinine or BUN, because of the compensatory changes of the non-obstructed kidney.

Cochrane et al. [47] showed that the obstructed kidney is able to regenerate after reversal of UUO. In C57BL/6 mice, one ureter was obstructed for 10 days and then ob-

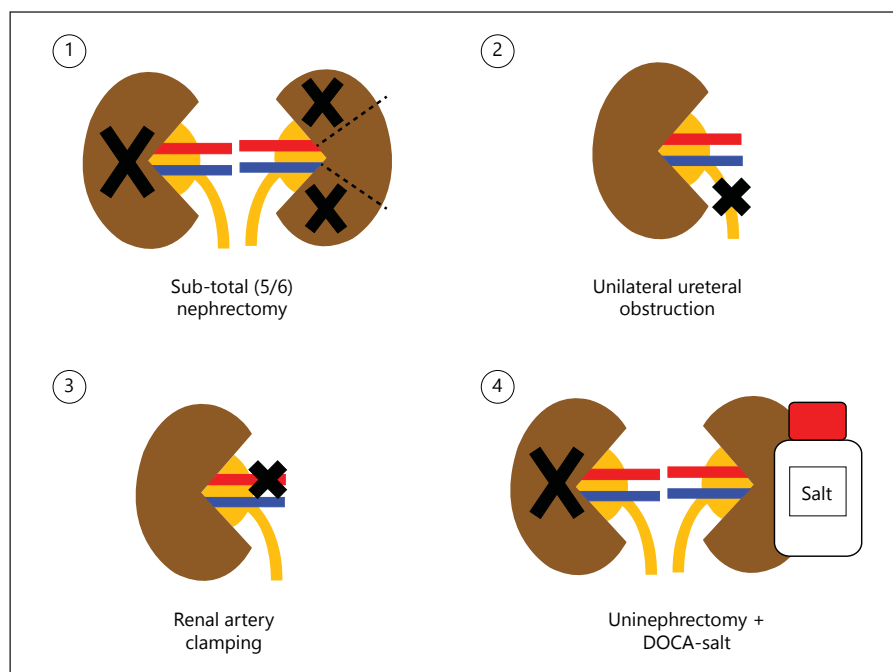


Fig. 2. Surgical mouse models of kidney disease.

struction was removed. Fibrosis was regredient after de-obstruction and areas of repaired tubules increased [47]. In contrast, Tapmeier et al. [48] found no differences in fibrosis and interstitial expansion between kidneys 10 days after UUU and kidneys harvested 10 weeks after re-implantation of the initial obstructed ureter.

Puri et al. [49] developed a murine model of CKD based on transient obstruction of the right kidney and obstruction of the left kidney after partial recovery of the de-obstructed right kidney. They found out that BALB/c mice are more resistant to obstruction-mediated injury than C57BL/6. BALB/c mice showed milder fibrosis and inflammation and higher degree of (histological) recovery of the unobstructed kidney compared to the C57BL/6 strain [49].

Ischemia-Reperfusion

Ischemia is the most common cause of acute kidney injury in humans. Three different models of ischemic acute kidney failure in mice exist: bilateral clamping of renal arteries, unilateral clamping and unilateral clamping combined with contralateral nephrectomy [1].

Wei and Dong [50] tested different durations of ischemia for bilateral clamping of renal arteries in C57BL/6 mice. An ischemia time of 22–25 min resulted in a mild to moderate kidney failure with recovery within about 1 week whereas 30 min ischemia induced severe uremia and death in a significant proportion of mice within 72 h [50].

Gender and strain differences in susceptibility to renal ischemic injury also exist. NIH Swiss and 129/Sv mice are more resistant to develop ischemic kidney injury compared to C57BL/6 [50] and female mice seem to be less sensitive to AKI caused by ischemia than male animals [7].

Conclusion

The animal models of kidney disease reviewed here provide powerful tools to study mechanisms of kidney damage and potential therapeutic approaches in wild-type and transgenic mouse lines. We emphasize the crucial importance to choose the kidney disease model, species, strain, gender and age, as well as appropriate study end points, according to the research question of interest.

Acknowledgments

This work was made possible by grants of the Physician Scientist Program at the University of Heidelberg, Faculty of Medicine (to M.R.) and the EU 7th Framework Programme (EURenOmics, grant No. 2012-305608).

Disclosure Statement

The authors declare that they have no conflicts of interest.

References

- Hewitson TD, Ono T, Becker GJ: Small animal models of kidney disease: a review; in Hewitson TD, Becker GJ (eds): *Kidney Research. Methods in Molecular Biology*. Totowa NJ, Humana Press, 2009, vol 466.
- Ma LJ, Fogo AB: Model of robust induction of glomerulosclerosis in mice: importance of genetic background. *Kidney Int* 2003;64:350–355.
- Qi Z, Fujita H, Jin J, Davis LS, Wang Y, Fogo AB, Breyer MD: Characterization of susceptibility of inbred mouse strains to diabetic nephropathy. *Diabetes* 2005;54:2628–2637.
- Ishola DA Jr, van der Giezen DM, Hahnel B, Goldschmeding R, Kriz W, Koomans HA, Joles JA: In mice, proteinuria and renal inflammatory responses to albumin overload are strain-dependent. *Nephrol Dial Transplant* 2006;21:591–597.
- Hartner A, Cordasic N, Klanke B, Veelken R, Hilgers KF: Strain differences in the development of hypertension and glomerular lesions induced by deoxycorticosterone acetate salt in mice. *Nephrol Dial Transplant* 2003;18:1999–2004.
- Wang Q, Hummler E, Nussberger J, Clément S, Gabbiani G, Brunner HR, Burnier M: Blood pressure, cardiac, and renal responses to salt and deoxycorticosterone acetate in mice: role of renin genes. *J Am Soc Nephrol* 2002;13:1509–1516.
- Hu H, Wang G, Batteux F, Nicco C: Gender differences in the susceptibility to renal ischemia-reperfusion injury in BALB/c mice. *Tohoku J Exp Med* 2009;218:325–329.
- Gurley SB, Clare SE, Snow KP, Hu A, Meyer TW, Coffman TM: Impact of genetic background on nephropathy in diabetic mice. *Am J Physiol Renal Physiol* 2006;290:F214–F222.
- Eddy AA, Lopez-Guisa JM, Okamura DM, Yamaguchi I: Investigating mechanisms of chronic kidney disease in mouse models. *Pediatr Nephrol* 2012;27:1233–1247.
- Sánchez-González PD, López-Hernández FJ, López-Novoa JM, Morales AI: An integrative view of the pathophysiological events leading to cisplatin nephrotoxicity. *Crit Rev Toxicol* 2011;41:803–821.
- Chen CL, Liao JW, Hu OY, Pao LH: Blockade of KCa3.1 potassium channels protects against cisplatin-induced acute kidney injury. *Arch Toxicol* 2015, Epub ahead of print.
- Torres R, Velazquez H, Chang JJ, Levene MJ, Moeckel G, Desir GV, Safirstein R: Three-dimensional morphology by multiphoton microscopy with clearing in a model of cisplatin-induced CKD. *J Am Soc Nephrol* 2016;27:1102–1112.
- Dickman KG, Sweet DH, Bonala R, Ray T, Wu A: Physiological and molecular characterization of aristolochic acid transport by the kidney. *J Pharmacol Exp Ther* 2011;338:588–597.
- Huang L, Scarpellini A, Funck M, Verderio EA, Johnson TS: Development of a chronic kidney disease model in C57BL/6 mice with relevance to human pathology. *Nephron Extra* 2013;3:12–29.
- Zhou Y, Bian X, Fang L, He W, Dai C, Yang J: Aristolochic acid causes albuminuria by promoting mitochondrial DNA damage and dysfunction in podocyte. *PLoS One* 2013;8:e83408.
- Wang Y, Wang YP, Tay YC, Harris DC: Progressive adriamycin nephropathy in mice: sequence of histologic and immunohistochemical events. *Kidney Int* 2000;58:1797–1804.
- Papeta N, Zheng Z, Schon EA, Brosel S, Altintas MM, Nasr SH, Reiser J, D'Agati VD, Gharavi AG: PRKDC participates in mitochondrial genome maintenance and prevents adriamycin-induced nephropathy in mice. *J Clin Invest* 2010;120:4055–4064.
- Stallons LJ, Whitaker RM, Schnellmann RG: Suppressed mitochondrial biogenesis in folic acid-induced acute kidney injury and early fibrosis. *Toxicol Lett* 2014;224:326–332.
- Fink M, Henry M, Tange JD: Experimental folic acid nephropathy. *Pathology* 1987;19:143–149.
- Edwards JC, Bruno J, Key P, Cheng YW: Absence of chloride intracellular channel 4 (CLIC4) predisposes to acute kidney injury but has minimal impact on recovery. *BMC Nephrol* 2014;15:54.
- Jia T, Olauson H, Lindberg K, Amin R, Edvardsson K, Lindholm B, Andersson G, Wernerson A, Sabbagh Y, Schiavi S, Larsson TE: A novel model of adenine-induced tubulointerstitial nephropathy in mice. *BMC Nephrol* 2013;14:116.
- Santana AC, Degaspari S, Catanzi S, Dellè H, de Sá Lima L, Silva C, Blanco P, Solez K, Scavone C, Noronha IL: Thalidomide suppresses inflammation in adenine-induced CKD with uraemia in mice. *Nephrol Dial Transplant* 2013;28:1140–1149.
- Ali BH, Al-Salam S, Al Za'abi M, Waly MI, Ramkumar A, Beegam S, Al-Lawati I, Adham SA, Nemmar A: New model for adenine-induced chronic renal failure in mice, and the effect of gum acacia treatment thereon: comparison with rats. *J Pharmacol Toxicol Methods* 2013;68:384–393.
- Mori-Kawabe M, Yasuda Y, Ito M, Matsuo S: Reduction of NO-mediated relaxing effects in the thoracic aorta in an experimental chronic kidney disease mouse model. *J Atheroscler Thromb* 2015;22:845–853.
- Saus J, Wieslander J, Langeveld JP, Quinones S, Hudson BG: Identification of the Goodpasture antigen as the alpha 3(IV) chain of collagen IV. *J Biol Chem* 1988;263:13374–13380.
- Hopfer H, Maron R, Butzmann U, Helmchen U, Weiner HL, Kalluri R: The importance of cell-mediated immunity in the course and severity of autoimmune anti-glomerular basement membrane disease in mice. *FASEB J* 2003;17:860–868.
- Masaki T, Chow F, Nikolic-Paterson DJ, Atkins RC, Tesch GH: Heterogeneity of antigen expression explains controversy over glomerular macrophage accumulation in mouse glomerulonephritis. *Nephrol Dial Transplant* 2003;18:178–181.
- Xie C, Sharma R, Wang H, Zhou XJ, Mohan C: Strain distribution pattern of susceptibility to immune-mediated nephritis. *J Immunol* 2004;172:5047–5055.
- Xie C, Qin X, Jonnalagadda G, Gong Y, Yan M, Zong P, Zhou XJ, Mohan C: Enhanced susceptibility to immune nephritis in DBA/1 mice is contingent upon IL-1 expression. *Clin Immunol* 2007;124:49–56.
- Nishida K, Watanabe H, Ogaki S, Kodama A, Tanaka R, Imafuku T, Ishima Y, Chuang VT, Toyoda M, Kondoh M, Wu Q, Fukagawa M, Otagiri M, Maruyama T: Renoprotective effect of long acting thioredoxin by modulating oxidative stress and macrophage migration inhibitory factor against rhabdomyolysis-associated acute kidney injury. *Sci Rep* 2015;5:14471.
- Petejova N, Martinek A: Acute kidney injury due to rhabdomyolysis and renal replacement therapy: a critical review. *Crit Care* 2014;18:224.
- Grange C, Moggio A, Tapparo M, Porta S, Camussi G, Bussolati B: Protective effect and localization by optical imaging of human renal CD133+ progenitor cells in an acute kidney injury model. *Physiol Rep* 2014;2:e12009.
- Loirat C, Frémeaux-Bacchi V: Atypical hemolytic uremic syndrome. *Orphanet J Rare Dis* 2011;6:60.
- Porubsky S, Federico G, Müthing J, Jenemann R, Gretz N, Büttner S, Obermüller N, Jung O, Hauser IA, Gröne E, Geiger H, Gröne HJ, Betz C: Direct acute tubular damage contributes to Shiga toxin-mediated kidney failure. *J Pathol* 2014;234:120–133.
- Keepers TR, Psotka MA, Gross LK, Obrigg TG: A murine model of HUS: Shiga toxin with lipopolysaccharide mimics the renal damage and physiologic response of human disease. *J Am Soc Nephrol* 2006;17:3404–3414.
- Suyama K, Kawasaki Y, Miyazaki K, Kanno S, Ono A, Ohara S, Sato M, Hosoya M: The efficacy of recombinant human soluble thrombomodulin for the treatment of shiga toxin-associated hemolytic uremic syndrome model mice. *Nephrol Dial Transplant* 2015;30:969–977.
- Tesch GH, Nikolic-Paterson DJ: Recent insights into experimental mouse models of diabetic nephropathy. *Nephron Exp Nephrol* 2006;104:e57–e62.
- Nakagawa T, Sato W, Glushakova O, Heinig M, Clarke T, Campbell-Thompson M, Yuza-wa Y, Atkinson MA, Johnson RJ, Croker B: Diabetic endothelial nitric oxide synthase knockout mice develop advanced diabetic nephropathy. *J Am Soc Nephrol* 2007;18:539–550.

- 39 Landgraf SS, Silva LS, Peruchetti DB, Sirtoli GM, Moraes-Santos F, Portella VG, Silva-Filho JL, Pinheiro CS, Abreu TP, Takiya CM, Benjamin CF, Pinheiro AA, Canetti C, Caruso-Neves C: 5-Lipoxygenase products are involved in renal tubulointerstitial injury induced by albumin overload in proximal tubules in mice. *PLoS One* 2014;9:e107549.
- 40 Tanaka-Kagawa T, Suzuki M, Naganuma A, Yamanaka N, Imura N: Strain difference in sensitivity of mice to renal toxicity of inorganic mercury. *J Pharmacol Exp Ther* 1998; 285:335–341.
- 41 Shimo T, Adachi Y, Yamanouchi S, Tsuji S, Kimata T, Umezawa K, Okigaki M, Takaya J, Ikehara S, Kaneko K: A novel nuclear factor κ B inhibitor, dehydroxymethylepoxyquinomicin, ameliorates puromycin aminonucleoside-induced nephrosis in mice. *Am J Nephrol* 2013;37:302–309.
- 42 Jamshidzadeh A, Heidari R, Mohammadi-Samani S, Azarpira N, Najbi A, Jahani P, Abdoli N: A comparison between the nephrotoxic profile of gentamicin and gentamicin nanoparticles in mice. *J Biochem Mol Toxicol* 2015;29:57–62.
- 43 Leelahavanichkul A, Yan Q, Hu X, Eisner C, Huang Y, Chen R, Mizel D, Zhou H, Wright EC, Kopp JB, Schnermann J, Yuen PS, Star RA: Angiotensin II overcomes strain-dependent resistance of rapid CKD progression in a new remnant kidney mouse model. *Kidney Int* 2010;78:1136–1153.
- 44 Peng H, Carretero OA, Alfie ME, Masura JA, Rhaleb NE: Effects of angiotensin-converting enzyme inhibitor and angiotensin type 1 receptor antagonist in deoxycorticosterone acetate-salt hypertensive mice lacking Ren-2 gene. *Hypertension* 2001;37:974–980.
- 45 Kirchhoff F, Krebs C, Abdulhag UN, Meyer-Schwesinger C, Maas R, Helmchen U, Hilgers KF, Wolf G, Stahl RA, Wenzel U: Rapid development of severe end-organ damage in C57BL/6 mice by combining DOCA salt and angiotensin II. *Kidney Int* 2008;73:643–650.
- 46 Chevalier RL, Forbes MS, Thornhill BA: Ureteral obstruction as a model of renal interstitial fibrosis and obstructive nephropathy. *Kidney Int* 2009;75:1145–1152.
- 47 Cochrane AL, Kett MM, Samuel CS, Campanale NV, Anderson WP, Hume DA, Little MH, Bertram JF, Ricardo SD: Renal structural and functional repair in a mouse model of reversal of ureteral obstruction. *J Am Soc Nephrol* 2005;16:3623–3630.
- 48 Tapmeier TT, Brown KL, Tang Z, Sacks SH, Sheerin NS, Wong W: Reimplantation of the ureter after unilateral ureteral obstruction provides a model that allows functional evaluation. *Kidney Int* 2008;73:885–889.
- 49 Puri TS, Shakaib MI, Chang A, Mathew L, Olayinka O, Minto AW, Sarav M, Hack BK, Quigg RJ: Chronic kidney disease induced in mice by reversible unilateral ureteral obstruction is dependent on genetic background. *Am J Physiol Renal Physiol* 2010;298:F1024–F1032.
- 50 Wei Q, Dong Z: Mouse model of ischemic acute kidney injury: technical notes and tricks. *Am J Physiol Renal Physiol* 2012; 303:F1487–F1494.