

# Nonoperative and Operative Management of Snapping Scapula

Robert C. Manske,<sup>\*†‡</sup> MEd, MPT, SCS, ATC, CSCS,  
 Michael P. Reiman,<sup>‡</sup> MEd, PT, ATC, CSCS, and Mark L. Stovak,<sup>‡</sup> MD  
 From <sup>†</sup>Wichita State University, Wichita, Kansas,  
 and <sup>‡</sup>Via Christi Regional Medical Center, Wichita, Kansas

Snapping scapula is a painful crepitus of the scapulothoracic articulation. This crepitus is a grinding or snapping noise with scapulothoracic motion that may or may not accompany pain. This condition is commonly seen in overhead-throwing athletes. Treatment of patients with this syndrome begins with nonoperative methods; when nonoperative treatment fails, several surgical options exist. This article will discuss both nonoperative and operative management of this common shoulder condition.

**Keywords:** scapulothoracic crepitus; scapulothoracic bursitis; scapular disorders; shoulder rehabilitation

Scapular function is crucial to not only the shoulder but also the entire upper extremity. As knowledge of the shoulder and its surrounding structures has increased over the past decade, so has interest in the scapula. The scapula's role is 2-fold: it is required to maintain a stable base of support for the humerus; it is also required to be mobile, allowing dynamic positioning of the glenoid fossa during glenohumeral elevation. These 2 functions require active positioning and active motion by the periscapular muscles.<sup>8</sup> Having no true synovial characteristics such as attachment by fibrous, synovial, or cartilaginous tissue, the scapula maintains its function purely through dynamic muscular control.<sup>73</sup> The scapula's attachment to the axial skeleton is provided through the acromioclavicular joint and the sternoclavicular joints.<sup>39</sup> The clavicle acts as a strut for the scapula, opposing medially directed forces of the axioscapular muscles, and allowing scapular rotation and translation along the thoracic cage.<sup>33</sup> This anatomical configuration allows for smooth gliding motions along the thoracic wall.<sup>16,33</sup> Alteration of the normal position or motion of the scapulothoracic joint has been termed *dyskinesia* and can be caused by pain, muscle weakness, muscle inflexibility, or muscle imbalances. Although not extremely common, scapulothoracic crepitus can occasionally be a contributor to shoulder pain and dysfunction in the active athlete.

Scapulothoracic crepitus, also known as "snapping scapula" or "washboard syndrome,"<sup>11,12,14</sup> is a disorder that

ranges from simple annoyance to a truly disabling condition for the symptomatic patient. This crepitus is usually described as production of a snapping, grinding, thumping, or popping sound with scapulothoracic motion. This sound is amplified by the thoracic cavity, which acts as a resonance chamber as in the body of a stringed instrument.<sup>61</sup> Historically identified initially by Boinet,<sup>5</sup> scapular crepitus has been attributed to numerous causes. Bateman<sup>3,4</sup> reported that the lesion might develop because of a chronic, forceful, and repetitive action of the shoulder mechanism. After this action, repetitive microtrauma will then induce microtears along the periosteum at the medial border of the scapula. The end result of this insult will be a traction osteophyte or bone spur at the muscular attachment of the scapula. Codman<sup>14</sup> felt that scapular crepitus was caused by irritation of several bursae around the scapula that may be the result of decreased musculature function or scapular tilting. Milch<sup>50</sup> and Milch and Burman<sup>51</sup> are in agreement with Codman that scapulothoracic crepitus may originate from bursitis, but they identified that an osseous lesion, such as an osteochondroma in the scapulothoracic space, may become pathologic.

Regardless of the cause, symptomatic scapulothoracic crepitus requires either nonsurgical or surgical treatment. This article will cover nonsurgical treatment techniques as well as possible surgical treatments of the snapping scapula syndrome. Because an alteration of scapulothoracic mechanics can be a common condition associated with snapping scapula, a review of anatomy of this region is paramount.

## ANATOMY

The scapula is a large triangular-shaped bone that is situated on the posterior thorax. The pseudointerjoint between the scapula and the thorax is one of the least congruent of the

\*Address correspondence to Robert C. Manske, MEd, MPT, SCS, ATC, CSCS, 1845 North Fairmount, Wichita, KS 67260-0043 (e-mail: robert.manske@wichita.edu).

No potential conflict of interest declared.

human body. Because there is no true bony attachment from the scapula to the axial skeleton, its stability is afforded mainly by the surrounding musculature. The scapula provides a large area for the attachment of 10 muscles. The only attachment of the scapula to the rest of the proximal skeleton is at the acromioclavicular joint. Interposed between the scapula and the thoracic wall lie the subscapularis and the serratus anterior muscles, which help to stabilize the scapula against the chest wall and thus prevent scapular winging.<sup>16</sup> The scapular costal surface is slightly concave, which allows it to come intimately close to the convex posterior surface of the thorax. In its normal resting position, the scapula sits approximately 2 inches laterally from the spine on the posterior thorax. Most will find the scapula located between the second through seventh ribs or transverse processes.<sup>31</sup> Although a large variability exists between people, the scapula generally lies 30° to 40° in the frontal plane and is tipped anteriorly approximately 10° to 20° from the vertical.<sup>40</sup> This static position is commonly referred to as the "plane of the scapula."<sup>14,29,68</sup>

## CAUSES

Soft tissues such as muscle tendons and bursae are located between the bony thorax and the scapula. Several bursae that lie in or around the scapulothoracic joint can potentially cause scapular dysfunction and crepitus<sup>38</sup> (see Table 1). It is in and around these structures that painful scapulothoracic crepitus and/or bursitis can occur.

Several key bursae have been thought to cause lesions in the scapulothoracic joint. One of the anatomical scapulothoracic bursae lies between the ribs and the serratus anterior muscle, whereas the other lies between the subscapularis and the serratus anterior muscles.<sup>11,12</sup> These bursae have recently been termed the *supraserratus bursae*, meaning located above the serratus anterior muscle, and the *infraserratus bursae*, meaning located below the serratus anterior muscle (Figure 1).<sup>37</sup>

In addition to the anatomical bursae, there are several adventitial or outer-lying bursae around the scapulothoracic joint that may become irritated and/or develop in response to abnormal pathomechanics of the scapulothoracic articulation.<sup>13,37,61</sup> The adventitial bursae include 2 infraserratus bursae located at the superomedial angle and at the inferomedial angle of the scapula. The other 2 are the supraserratus bursa located at the superomedial angle and the bursa known as the *trapezoid bursa* located at the base of the spine of the scapula (Figure 2).<sup>37</sup>

Numerous problems can lead to snapping scapula. Muscle atrophy from disuse or nerve injury can lead to a diminished soft tissue interposition between the scapula and the rib cage. In addition, muscle fibrosis from a previous traumatic event can cause symptoms. Other possibilities are soft tissue in origin, such as bursal inflammation in the locations discussed earlier. Tuberculosis or syphilitic lesions are also a possibility, although far more unlikely.<sup>50</sup> Anatomical variances can lead to scapulothoracic incongruence.<sup>19,49,50,60</sup> Structural spinal deformities including

TABLE 1  
Bursae Around the Scapula<sup>a</sup>

Major/anatomical bursae	
Infraserratus bursae:	between the serratus anterior muscle and the chest wall
Supraserratus bursae:	between subscapularis and serratus anterior muscles
Scapulotrapezial bursae:	between the superomedial scapula and the trapezius
Minor/adventitial bursae	
Superomedial angle of the scapula	
Infraserratus bursae:	between the serratus anterior muscle and the chest wall
Supraserratus bursae:	between subscapularis and serratus anterior muscles
Inferior angle of the scapula	
Infraserratus bursae:	between the serratus anterior muscle and the chest wall
Spine of the scapula	
Trapezoid bursae:	between the medial spine of scapula and the trapezius

<sup>a</sup>From Kuhn JE, Hawkins RJ. Evaluation and treatment of scapular disorders. In: Warner JP, Iannotti JP, Gerber C, eds. *Complex and Revision Problems in Shoulder Surgery*. Philadelphia, Pa: Lippincott-Raven Publishers; 1997:357-375.

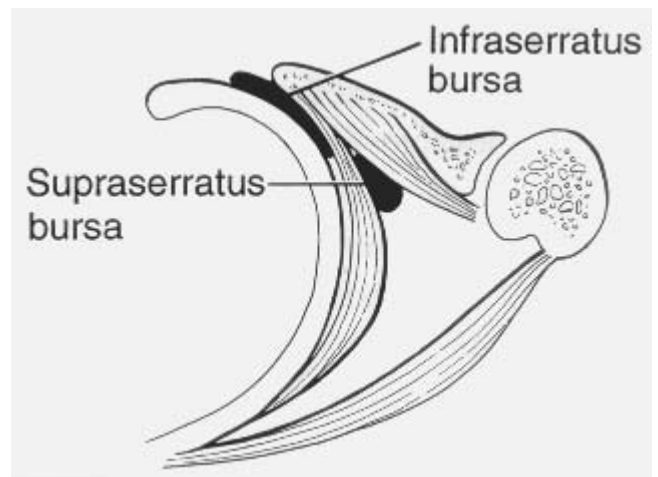
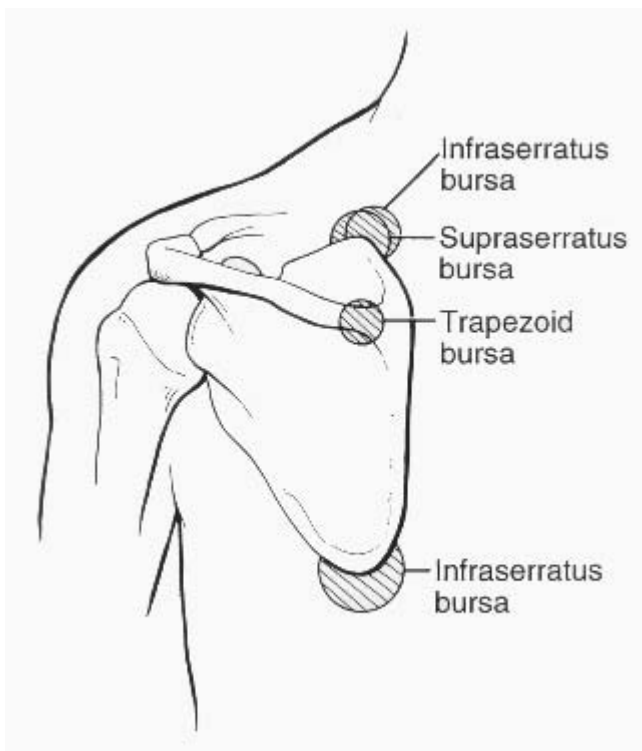


Figure 1. Anatomical bursae. (From Kuhn JE, Hawkins RJ. Evaluation and treatment of scapular disorders. In: Warner JP, Iannotti JP, Gerber C, eds. *Complex and Revision Problems in Shoulder Surgery*. Philadelphia, Pa: Lippincott-Raven Publishers; 1997.)

scoliosis and thoracic kyphosis have also been implicated in snapping scapula.<sup>14</sup> The superomedial and inferomedial angles of the scapula can have a hooked shape. The superomedial angle can also have a bony prominence known as the Luschka tubercle. Bony abnormalities such as osteochondromas of the rib and scapula have been described. Osteochondromas are the most common scapular tumors.<sup>64</sup> Healing fractures of the rib or scapula with bony angulation or increased callus can cause symptoms.<sup>50,71</sup> Bone spurs can form as a result of muscle avulsions or simply from muscle traction on the scapula.<sup>37</sup>



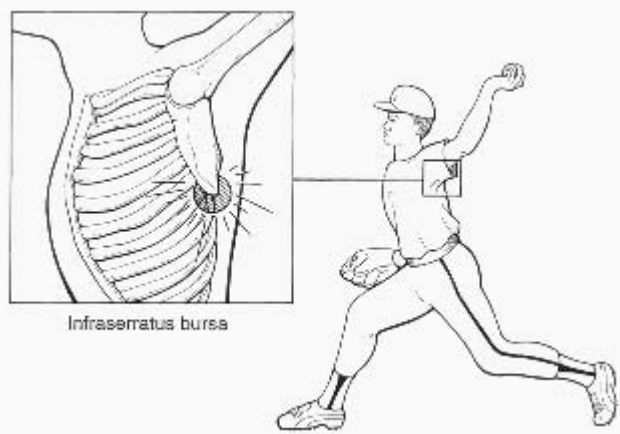
**Figure 2.** Adventitial bursae. (From Kuhn JE, Hawkins RJ. Evaluation and treatment of scapular disorders. In: Warner JP, Iannotti JP, Gerber C, eds. *Complex and Revision Problems in Shoulder Surgery*. Philadelphia, Pa: Lippincott-Raven Publishers; 1997.)

Several cases of subscapular elastofibroma have been implicated in causing scapular snapping<sup>24</sup> in younger pitchers. An elastofibroma is a non-neoplastic soft tissue growth that appears to form in response to repetitive microtrauma.<sup>24</sup> In the presence of an elastofibroma reported by Haney, the typical patient was more concerned with the palpable mass that developed rather than pain.<sup>24</sup>

It is also important to recognize that scapulothoracic crepitus may not always be pathologic. Grunfeld reported finding scapular crepitus in 31% of 100 asymptomatic persons.<sup>23</sup> The potential for the crepitus to be asymptomatic may increase if the finding is bilateral. However, repetitive snapping scapula may lead to painful symptoms over time. This is important to remember if the symptoms seem out of proportion to those that might be expected or if there is the potential for secondary gain, as in the cases of litigation or workers' compensation.<sup>64</sup> In addition, those with psychiatric conditions may not respond to treatment as well as do other patients.<sup>37</sup>

## DIAGNOSIS

Patients generally complain of pain with increasing activity of the shoulder. One of the most consistent findings is that of scapular noise or crepitus with motion of the scapula.<sup>49-51,63,74</sup> This noise can be variable as a single snap or a series of snaps or may be so slight that it can only be detect-

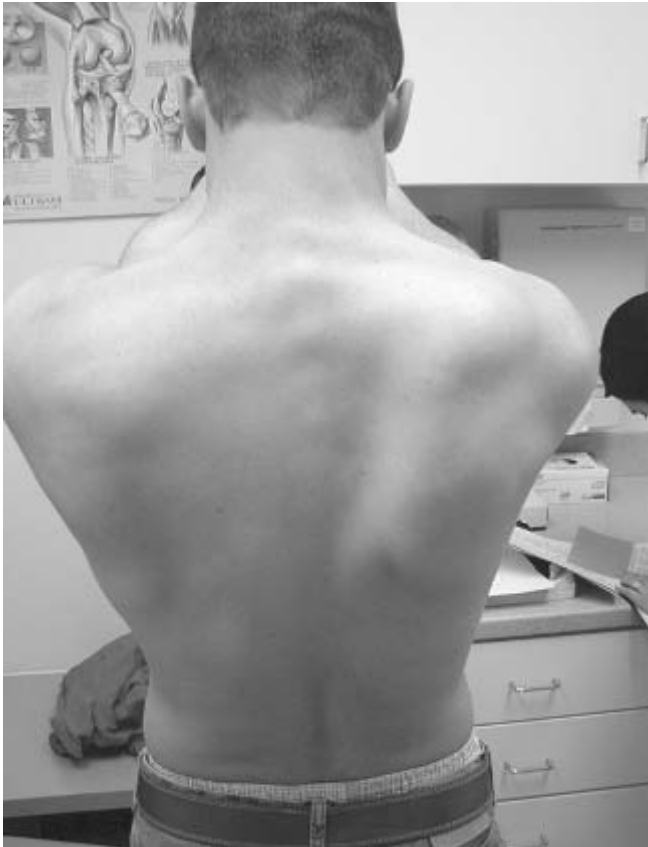

**Figure 3.** Bursae at the inferior angle of the scapula in baseball pitchers. (From Kuhn JE, Hawkins RJ. Evaluation and treatment of scapular disorders. In: Warner JP, Iannotti JP, Gerber C, eds. *Complex and Revision Problems in Shoulder Surgery*. Philadelphia, Pa: Lippincott-Raven Publishers; 1997.)

ed through crepitus with palpation.<sup>49-51</sup> Some patients will have no pain,<sup>51</sup> whereas others may have an extreme tenderness at the superior angle and medial border of the scapula.<sup>48-51,63,65,67,74</sup> This pain will commonly be associated with a palpable or audible crepitus in the scapulothoracic region. The patient may or may not complain of a feeling of fatigue before the onset of symptoms. A history of overuse during sports<sup>36,45,46,61,70</sup> such as swimming, pitching a ball (Figure 3), weight training, gymnastics, and football has been implicated in the onset of symptoms, as has work<sup>36,37</sup> and local trauma.<sup>25,63</sup> A nonspecific complaint of pain under the scapula is also a common occurrence.

Visual inspection may reveal bilateral asymmetry in the scapula. The dominant extremity should be determined because handedness may result in a slight depression of the dominant extremity.<sup>32</sup> Scapular winging is also a commonly noted finding in patients with scapulothoracic crepitus (Figure 4).<sup>37,52</sup> Poor posture in patients who have a moderate to severe forward head position and anterior rounded shoulders may contribute to scapular symptoms.<sup>48,56,74</sup> One must thoroughly assess muscle flexibility and soft tissue tightness in the muscles surrounding and contributing to the shoulder girdle. A tight pectoralis minor can contribute to faulty scapular mechanics and can be seen by evaluating the resting shoulder position while the patient is supine on the examining table. Tightness of the pectoralis minor will result in the affected shoulder maintaining a resting position anterior or higher while supine, as compared to the unaffected side (Figure 5). Close attention should also be paid to evaluation of the trapezius and levator scapula muscles. Chronic overuse or postures that hold these muscles in shortened positions can potentially be problematic for normal scapular function. Trapezius tightness can be determined by use of muscle length testing (Figure 6).

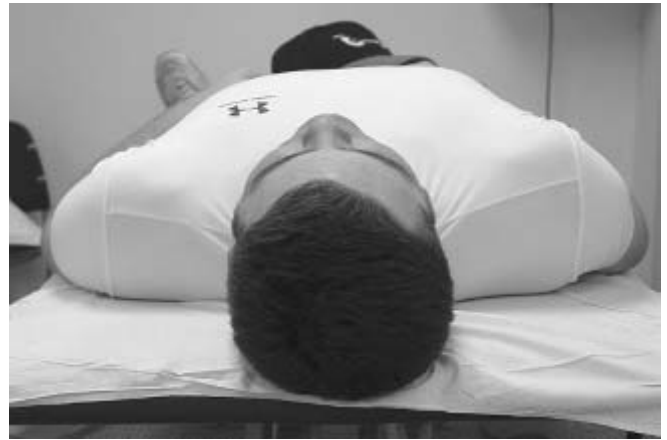Assessment of muscle strength is also critical during the evaluation of the patient with snapping scapula syndrome.



**Figure 4.** Scapular winging in an overhead-throwing athlete.

Of particular interest will be the strength of the scapular muscles including the upper, middle, and lower trapezius; rhomboids; serratus anterior; latissimus dorsi; levator scapula; rotator cuff muscles; and deltoids. Proper technique of basic manual muscle testing procedures is detailed in Kendall et al.<sup>32</sup> In addition, testing to rule out cervical spine radicular pain as a possible differential diagnosis is always warranted. A Spurling test can be used to reproduce radicular symptoms emanating from the cervical spine.<sup>20</sup>

After assessment of muscle strength has been performed, an assessment of scapulohumeral rhythm must be performed. During both shoulder abduction and shoulder flexion, the scapulothoracic joint contributes to elevation of the humerus by upwardly rotating the scapula and glenoid fossa.<sup>16,27,33,62</sup> The overall ratio of glenohumeral to scapulothoracic rotation is 2:1 throughout the full range of elevation. However, most movement occurs at the glenohumeral joint during the first 30° of abduction and the first 60° of flexion at a ratio of 4:1, then continues at a ratio of 2:1.<sup>62</sup> Elevation of the shoulder also induces a posterior scapular tilting that has been defined as the superior scapula and acromion moving away from the greater tuberosity of the humerus while the inferior scapular angle moves toward the rib cage.<sup>16,26,41,42,44</sup> Faulty patterns commonly seen include decreased glenohumeral motion with increased scapular motion during elevation of the

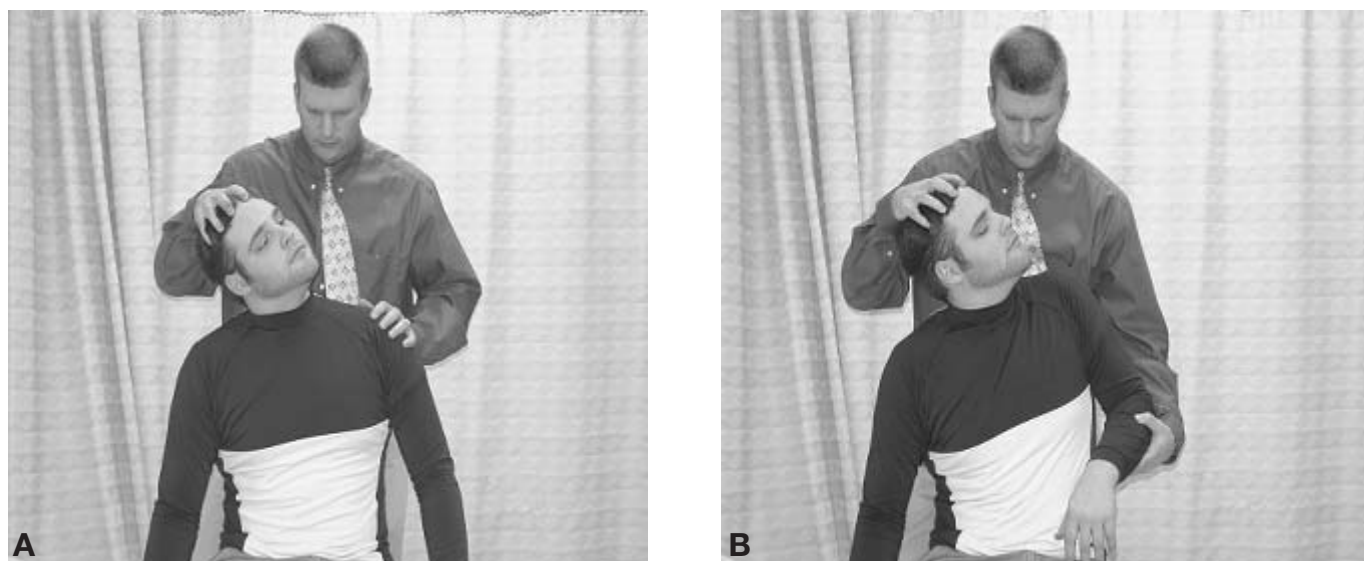


**Figure 5.** Pectoralis minor tightness of the right shoulder.

shoulder. Tightness of the latissimus dorsi, pectoralis major, and rotator cuff muscles may not allow normal motion to occur between the humerus and the scapula. With decreased glenohumeral motion, a protrusion at the lateral border of the axilla may be noticed. A protrusion in this location may be the inferior angle of the scapula, which has been protracted excessively because of the restricted tissue extensibility. A loss of muscle tone or alteration of scapulothoracic rhythm may lead to increased friction between the vertebral border of the scapula and the rib cage, resulting in crepitus or snapping.<sup>61</sup>

Palpation of the medial scapular border may elicit pain in the area of the superomedial and inferomedial bursae. The medial border of the scapula is often easily palpated if the patient is asked to adduct and internally rotate the shoulder while touching the opposite scapula.

Two of the most common causes of referral pain in and around the scapular, which may at times be confused with or could occur concomitantly with snapping scapula, come from either the cervical spine or the glenohumeral joint. Cervical spine abnormality at levels C5 to C8 can cause symptoms of scapular pain.<sup>7,9,43</sup> A quick manual muscle test of the cervical myotomes can help to rule out cervical spine abnormality as a source of scapular pain from nerve root origin. Table 2 lists upper extremity muscles, innervations, and nerve root levels, allowing a quick screening of relevant myotomes. The glenohumeral joint is another area that can refer or cause pain in the scapular region. Neer<sup>55</sup> thought that the glenohumeral joint is one of the most common locations that can cause scapular pain. The glenohumeral joint can cause scapular pain from any condition that may alter the normal scapulohumeral rhythm. Several abnormalities can cause this alteration to occur, including shoulder impingement in which the patient has pain during elevation. When this occurs, the common compensatory shoulder pattern is to elevate and/or protract the scapula in an attempt to elevate the arm further during functional activities. This movement can cause an overuse of the scapular muscles that direct these motions. Second, the patient with glenohumeral instability may excessively recruit the scapular muscles in an attempt to



**Figure 6.** A, part 1 of assessing trapezius tightness; B, part 2 of assessing trapezius tightness. Lifting the upper extremity will place the upper trapezius on slack, allowing further motion if the trapezius is the cause of limited motion.

**TABLE 2**  
Shoulder Muscles With Innervation<sup>a</sup>

Muscle	Peripheral Nerve	Nerve Root	Quick Manual Muscle Test
Pectoralis major	Pectoral	C5-C8	
Latissimus dorsi	Thoracodorsal	C7 (C6, C8)	
Teres major	Subscapular	C5-C8	
Teres minor	Axillary	C5(6)	
<b>Deltoid</b>	Axillary	<b>C5(6)</b>	Shoulder abduction
Supraspinatus	Suprascapular	C5(6)	
Subscapularis	Subscapular	C5-C8	
Infraspinatus	Suprascapular	C5(C6)	
<b>Biceps</b>	Musculocutaneous	<b>C5-C6</b>	Elbow flexion
Brachialis	Musculocutaneous	C5-C6	
<b>Triceps</b>	Radial	<b>C7</b>	Elbow extension
<b>Extensor carpi radialis longus</b>	Radial	<b>C6</b>	Wrist extension
Extensor carpi ulnaris	Radial	C7	
<b>Flexor carpi radialis</b>	Median	<b>C7</b>	Wrist flexion
Flexor carpi ulnaris	Ulnar	C8	
Extensor digitorum communis	Radial	C7	
<b>Flexor digitorum profundus radial ½</b>	Median	<b>C8</b>	Finger flexion
<b>Flexor digitorum profundus ulnar ½</b>	Ulnar	<b>C8</b>	
<b>Lumbricalis</b>	Median and ulnar	<b>C8-T1</b>	Finger abduction

<sup>a</sup>Bolded muscles and nerve root levels used for quick myotome screening.

better stabilize the shoulder during functional activities.<sup>21</sup> Again, because of excessive compensation, these muscles may quickly fatigue and become a cause of discomfort on the posterior aspect of the shoulder and scapula.

After the history and physical examination are used to narrow the differential, then radiological studies may also be useful. An AP view and a tangential (Y) view should always be obtained to evaluate the scapula and ribs. If these tests do not show any clear abnormalities, then a CT scan may be needed for more bony definition. Mozes et al<sup>54</sup> recommended 3-dimensional CT scans for evaluation of bony incongruity between the anterior scapula and the

chest wall. They found bony incongruity in 26 of 26 patients with snapping scapula. Fluoroscopy may also be used to visualize the grating or snapping during simulated shoulder motion. Finally, if there do not appear to be any bony abnormalities present to explain the crepitus, an MRI may better define a soft tissue lesion such as an inflamed bursa or an infection.

Electromyogram and nerve conduction time studies are also useful to determine if the cause of scapular winging is a neurological injury. An injury to the long thoracic nerve could lead to decreased serratus anterior function and subsequent scapular winging and snapping.

## NONOPERATIVE MANAGEMENT

As with most physical ailments, an attempt at nonsurgical rehabilitation is recommended with scapular dysfunction.<sup>64</sup> Although pain-relieving modalities may help reduce pain, correction of postural faults, strengthening of weak muscles, and stretching of tight muscles may be more effective in eliminating the abnormality.<sup>8</sup> The direction of rehabilitation will obviously depend on the factors causing the snapping scapula. It is generally believed that if the offending cause of scapulothoracic crepitus is soft tissue abnormalities, altered posture, scapular winging, or scapulothoracic dyskinesia, surgical intervention will not be required.<sup>12,45,46</sup>

Rehabilitation for the snapping scapula syndrome patient should address not only all the functional roles of the scapula<sup>43,53,58</sup> but also postural considerations. The most common postural dysfunction involving the shoulder has been described in the literature to include such characteristics as increased thoracic kyphosis, forward head, rounded shoulders, abducted and forward-tipped scapula,<sup>34</sup> and suboccipital extension.<sup>18,28</sup> Functionally tightened muscles include the pectoralis major and minor, levator scapulae, upper trapezius, latissimus dorsi, subscapularis, sternocleidomastoid, rectus capitis, and scalene muscles. Muscles that could be inhibited or weakened functionally would include the rhomboids, mid and lower trapezius, serratus anterior, teres minor, infraspinatus, posterior deltoid, and longus colli or longus capitis. The most common of these are the lower stabilizers of the scapula (serratus anterior, middle trapezius, and lower trapezius).<sup>21,28</sup>

Scapular weakness and abnormal rhythm have often been associated with instability and rotator cuff abnormality.<sup>21,58,69</sup> Additional abnormalities, including biceps tendinitis, thoracic outlet syndrome, and headaches, are also distinct possibilities.<sup>28,40</sup> The rehabilitation program for the patient with snapping scapula must address all of these functional issues.

Restoring scapular strength establishes static proximal stability to provide a stable base.<sup>35</sup> Because the scapular muscles' primary function is static posturing of the shoulder girdle (an activity of prolonged duration), endurance training should be emphasized. These muscles are not typically required to produce large amounts of force,<sup>30</sup> yet they are required to produce this force over an extended period of time. Scapular muscle fatigue can lead to compensatory motion.<sup>6,47</sup> Strengthening of these muscles should also take into account the natural force couples and the fact that many roles of the scapula are eccentric actions. Emphasis should be on strengthening the inhibited or functionally weakened muscles in both open and closed chain functional patterns. Gradual progression into functional patterns of movement that include, or closely resemble, the patient's required activities would improve the chances of a successful rehabilitation outcome.

The ultimate goal of rehabilitation is for the patient to have full, functional recovery. Weak muscles cannot be optimally strengthened if their antagonistic counterparts are not stretched.<sup>28</sup> It is important to stretch the tightened muscles that may be inhibiting functional strength; it is also important to maintain proper posture during the functional rehabilitation program. Proper postural alignment will allow for maximal neuromuscular efficiency because the normal length-tension relationship, force couple relationship, and arthrokinematics will be maintained during functional movement patterns.<sup>18,28,40</sup> Biomechanical faults will be minimized, and static proximal stability of the shoulder girdle will be improved.


Closed kinetic chain strengthening can be advantageous in the early stages of rehabilitation because of the stabilization effects. Proximal joint stability can be promoted in gradually increased ranges of motion. Improved shoulder girdle stability will be promoted with less risk of overloading static and dynamic restraints (Figure 7).

Other means of nonsurgical treatment have included local injections, nonsteroidal anti-inflammatory medications, and thermal modalities.<sup>11,12,48,50,61</sup> Ciullo<sup>11</sup> and Ciullo and Jones<sup>12</sup> implemented the use of diathermy, ultrasound, and iontophoresis to the undersurface at the medial border of the scapula, along with periscapular and rotator cuff muscle strengthening.<sup>11,12</sup> Thoracic spinal mobilization to promote correct posture and spinal movement should also be a point of emphasis in the treatment plan.

Avoiding prolonged, excessive scapular protraction and elevation will limit functional scapular weakness and improve the biomechanical advantage of the shoulder girdle to perform its typical endurance activities. Abduction and elevation of the scapula cause increased pressure on the underlying soft tissues and strain on the attached muscles and tendons.<sup>61</sup> Alteration of scapulothoracic rhythm and loss of muscle tone may lead to increased friction between the vertebral border of the scapula and rib cage, resulting in crepitus or snapping.<sup>3,61</sup>

Progression along the rehabilitation continuum from isometric and isotonic scapular and rotator cuff strengthening to endurance eccentric strengthening of the scapular muscles is recommended. Scapular core exercises as identified by Moseley et al<sup>53</sup> should be emphasized early on. These include scaption (Figure 8), press-up (Figure 9), rowing (Figure 10), and push-up plus (Figure 11) exercises. Advanced scapular exercises can then be progressed to functional patterns emphasizing eccentric scapular control. Exercises of this nature include plyometric exercises such as Plyoback (AliMed Inc, Dedham, Mass), proprioceptive neuromuscular facilitation (PNF) D2 patterns mimicking triplanar upper extremity movements, and Swiss ball isometric-hold scapular stabilization exercises (Figure 12). Endurance strengthening, by definition, consists of low intensity (power output) with high volume (amount of training time from high repetitions of activity).<sup>2</sup> Because these muscles are more postural in nature, higher repetitions with lighter loads may be more appropriate for a more functional training stimulus.<sup>30</sup> Performing repetitions in the range of 12 to 20 with lighter loads will simu-

<sup>8</sup>References 11, 12, 25, 37, 45, 46, 61, 70, 74.



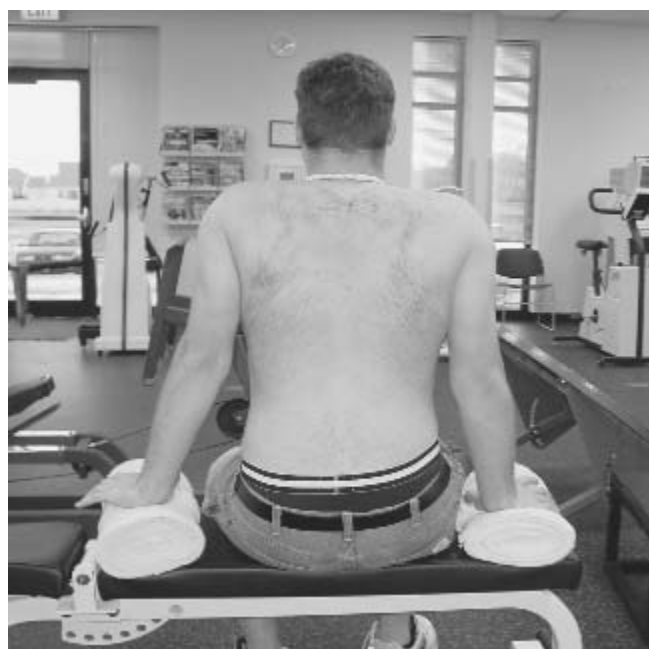**Figure 7.** A, scapular closed kinetic chain clock exercise on wall; B, scapular clock closed kinetic chain exercise with manual resistance added.

late longer-duration activities that will more closely resemble the true function of the scapular stabilizers during sporting activities. A gradual progression into these activities, as well as activities involving eccentric strengthening of the lower stabilizers of the scapula, must be closely monitored. Care must be taken when implementing eccentric strengthening because eccentric contractions can transmit increased tension to the musculotendinous unit, although a likely benefit is the maturation of strong tissue.<sup>15</sup>

Implementation of the rehabilitation program should be comprehensive. Thought must be given to strengthening of the core or trunk of the body (the *core* is defined as the lumbo-pelvic-hip complex).<sup>18</sup> The trunk serves as the crossroads for energy transfer in all human movement. Forces can move from the lower to the upper extremities or vice versa,<sup>17</sup> which will help ensure that functional patterns of movement are strengthened. The core stabilizers are primarily type I slow-twitch muscle fibers.<sup>22,59</sup> Therefore, these muscles, like the scapular stabilizers, should function in prolonged contraction states. Performing endurance strengthening with a gradual pro-



**Figure 8.** Scaption (scapular plane elevation) exercise.



**Figure 9.** Press-up plus exercise.

gression in the load required to control will increase the strength endurance of the muscle or pattern of movement that is being addressed. Core strength endurance must be trained appropriately to allow a person to maintain dynamic postural control for prolonged periods of time.<sup>1</sup> Once again, emphasizing proper posture is important. Lower scapular stabilization can be facilitated with contraction of the contralateral gluteus maximus via the thoracolumbar fascia. This fascia is a connecting point between contralateral gluteus maximus and latissimus dorsi. Strengthening these structures in unison will allow for increased force potential and “functional” stability. A comprehensive plan must also include progression into strengthening in isolation as well. Isolated scapular weaknesses and tightened muscles must be addressed in isolation, as previously discussed. Isolated strength deficits



**Figure 10.** Machine rowing exercise.



**Figure 12.** Swiss ball closed kinetic chain isometric scapular stabilization exercise.



**Figure 11.** Wall push-up plus exercise.

should be addressed after the larger functional strengthening patterns when planning each treatment session to help avoid isolated muscular fatigue.

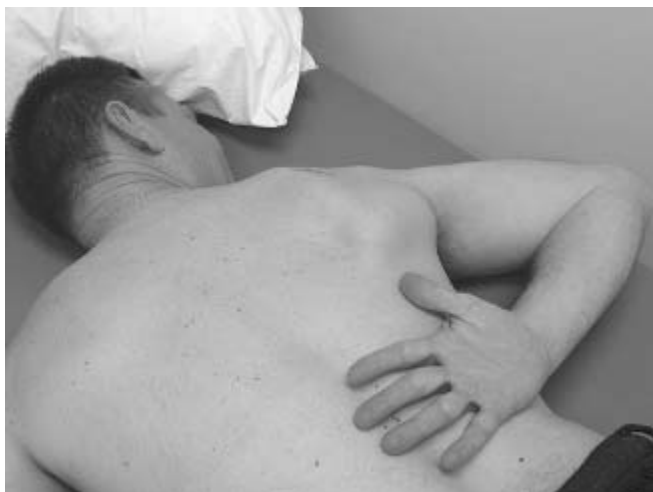Planning a treatment program for snapping scapula should account for all potential deficits and contributing factors. Posture, strength, and endurance should be the main theme of a comprehensive, multifaceted approach.

Pain and inflammation should be the guide throughout the progression of the program. Planning the progression to include reproduction of specific requirements that the patient will return to is also imperative. Failure to adequately train the patient in functional activities can be a common reason for poor results with therapeutic exercise programs.

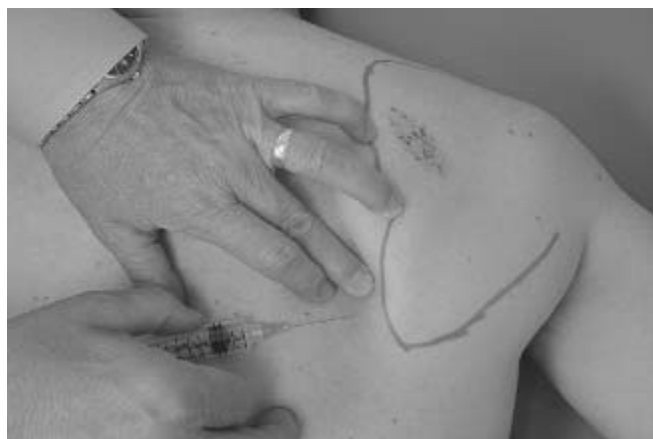If these initial treatment options do not control the discomfort, then oral steroidal medications are another option. If anti-inflammatory drug side effects limit the ability to use oral agents effectively or their usage is ineffective, then injections are a viable option. These are best given with a 1.5-inch needle with a 22- to 25-gauge caliber. Injecting any of the bursae can be easily done with the patient's arm in a position of extension, internal rotation, and adduction, trying to reach high up the spine while lying prone. This is similar to the surgical "chicken wing" position (Figure 13). Kuhn et al have described putting the arm in a position of 60° of abduction and 30° of forward flexion to make palpation of the inferomedial bursa easier.<sup>38</sup> A sterile environment should always be obtained, and any steroid agent can be used. Combining the injection with an anesthetic agent can make the injection not only therapeutic but also diagnostic. Care must be taken to stay in the proper plane parallel to the undersurface of the scapula when performing the injection because a pneumothorax would be a possibility if the needle were inserted too deeply (Figure 14). For the superomedial bursa injections, the needle should be placed at a 45° angle just off the superior medial tip of the scapula (Figure 15). It should be inserted approximately 2 cm laterally in a cephalad to caudad direction.<sup>64</sup>

If all nonsurgical measures fail to relieve the symptoms after 3 to 6 months and the diagnosis is certain, then surgical options are also available. The decision and timing for surgery is patient-dependent and should be considered only after failure of nonsurgical measures. Patients more likely to fail nonsurgical treatment may be those with a nerve deficit that cannot recruit the muscle innervated by the damaged nerve leading to scapular dyskinesis, those





**Figure 13.** “Chicken wing” position for scapulothoracic injection.

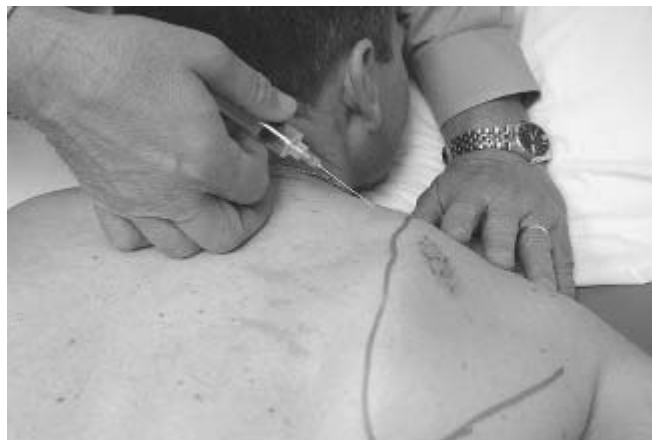

**Figure 14.** Scapulothoracic injection at the inferomedial angle of the scapula.

with bony incongruities, and those who can voluntarily snap their scapulas and do so frequently out of habit or for secondary gain. One should beware of patients who can grind, pop, or snap the scapula, particularly in cases of litigation, after minor trauma, or in workers' compensation cases.<sup>64</sup> Many surgical approaches to the snapping scapula exist, but all focus on removing the involved bursa or removing any bony incongruities that may exist.

## OPERATIVE MANAGEMENT

Several authors have described the resection of the superomedial angle of the scapula, and this has been by far the most common surgical approach.<sup>36,49,63,72,74</sup> This procedure would be an option if bony incongruity is thought to be the main cause of the snapping. An incision is made over the medial spine of the scapula, and the soft tissue is dissected down to the spine. The periosteum over the spine is incised and the supraspinatus, rhomboid, and levator scapula

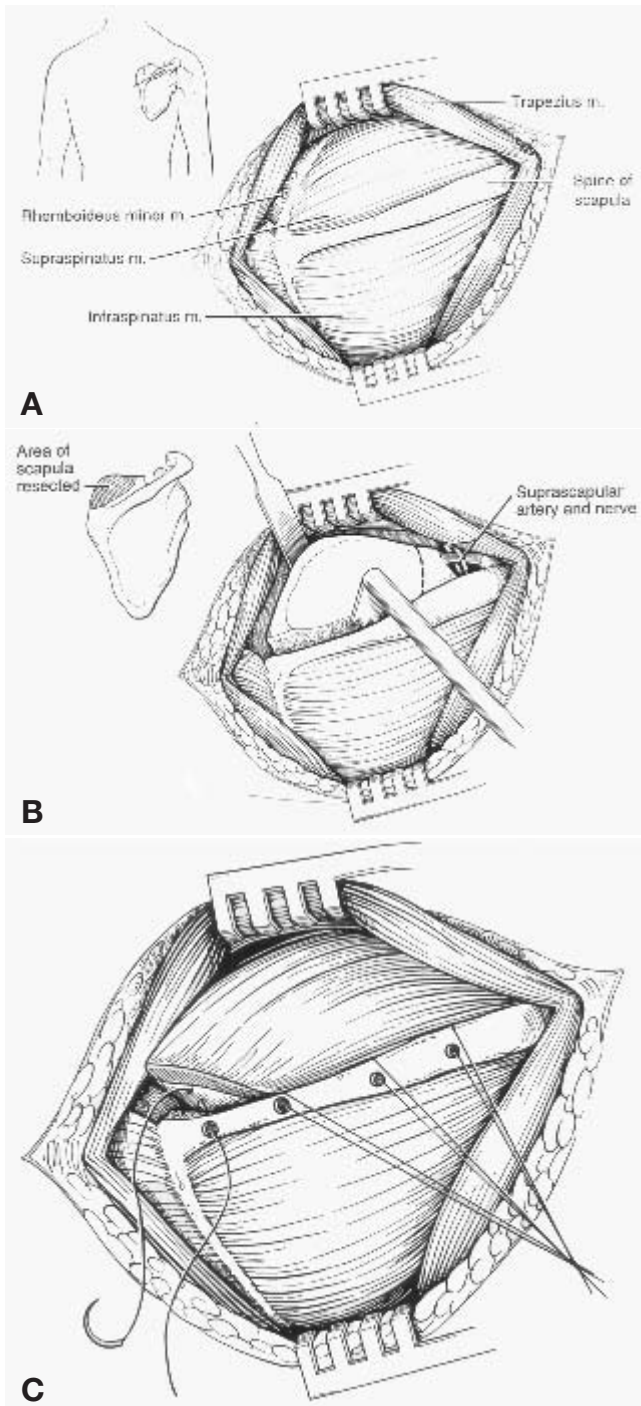


**Figure 15.** Scapulothoracic injection at the superomedial angle of the scapula.

muscles are dissected free in the subperiosteal plane. The superomedial angle of the scapula is resected with an oscillating saw and the area smoothed with rongeurs. After the resection, the reflected muscles fall back into place, and the periosteum is reapproximated to the spine by suturing through drill holes (Figure 16). After surgery, the patients use a sling, and passive motion begins immediately. Active motion is added at 8 weeks, and resistive exercises are added at 12 weeks after surgery. Outcomes of this procedure are reportedly very good even though the bone removed appears to be normal on both gross and histologic examinations.<sup>38</sup> This has led several authors<sup>45,46,57,70</sup> to pursue bursectomy rather than superomedial angle resection because just removing normal bone may not be treating all of the abnormality that is causing the symptoms. Bursectomy alone would be an option if no evidence existed radiographically to account for the snapping and no incongruity between the scapula and chest wall was found during surgery.

Sisto and Jobe described an open procedure to resect the bursa at the inferior angle of the scapula.<sup>70</sup> An oblique excision was made just distal to the inferior angle of the scapula. The trapezius and then the latissimus dorsi muscles were split in line with their fibers, exposing the bursa. The bursa was sharply excised, and any osteophytes were removed. The incision was closed using a drain and compression dressing, and physical therapy began after 1 week. Gentle throwing was allowed in these 4 athletes, who were all pitchers, at 6 weeks after surgery, and all of them returned to their previous level of competition.

McClusky and Bigliani described an open procedure to resect the superomedial bursa.<sup>45</sup> A vertical incision was made medial to the vertebral border of the scapula, and the trapezius was dissected free. A subperiosteal dissection was used to free the levator scapula and the rhomboid muscles. A plane was developed between the serratus anterior and the chest wall. The bursa was resected and any bony abnormalities removed. The muscles were all reapproximated to the scapula and the wound closed. A sling was used for comfort and passive motion, and pen-



**Figure 16.** Technique of resection of the superomedial border of the scapula for symptomatic scapulothoracic crepitus. A, the trapezius has been elevated from the spine of the scapula; B, the supraspinatus is reflected, as are the rhomboids and serratus medially, and the superomedial angle of the scapula is resected with care taken to preserve the suprascapular notch and neurovascular structures; C, the supraspinatus is secured to the spine of the scapula. (From Kuhn JE, Hawkins RJ. Evaluation and treatment of scapular disorders. In: Warner JP, Iannotti JP, Gerber C, eds. *Complex and Revision Problems in Shoulder Surgery*. Philadelphia, Pa: Lippincott-Raven Publishers; 1997.)

dulum exercises began immediately. Active motion was allowed at 3 weeks and strengthening at 6 weeks after surgery. Gentle throwing was allowed at 12 weeks. Eight of the 9 patients described good or excellent results.

Ciullo and Jones described a technique for the arthroscopic treatment of snapping scapula.<sup>12</sup> This procedure allowed resection of both the supraserratus and infraserratus bursae at the superomedial angle of the scapula in addition to the bursa at the inferior angle of the scapula. They were also able to resect any abnormal bony prominences through the arthroscope. All 13 patients in this study returned to their previous level of activity. This procedure offers all of the typical advantages of arthroscopy over the open procedures described, including better cosmesis and an easier rehabilitation. However, this is a technically challenging procedure because of visualization and portal placement concerns and should be considered only by arthroscopists who are comfortable with the technical challenges of the procedure.

Harper et al described a method of arthroscopic bony resection of the superior medial corner of the scapula.<sup>25</sup> They described symptom relief in 6 of 7 patients. One surgery had to be abandoned secondary to intraoperative swelling. The surgical position used was prone with the arm draped free to allow full range of motion to evaluate that a smooth surface between the scapula and chest wall was created.

One problem with arthroscopic surgery as compared to open exploration is that a painful trapezoid bursa may be missed with the arthroscope.<sup>57</sup> Another difficulty with arthroscopy is access and visualization of the superior angle of the scapula with the standard portals.<sup>10</sup> Standard portals have been inferior to the scapular spine 3 to 4 fingerbreadths from the medial scapular border.<sup>66</sup> This position was recommended to avoid the dorsal scapular nerve and artery, the accessory nerve, and the neurovascular structures at the superomedial angle of the scapula.<sup>66</sup>

The close proximity of these portals along with the required depth of penetration through the rhomboid muscles make these portals difficult to use to access the superomedial border.<sup>10</sup> Chan et al have described an inside-out technique to create a superior portal that enables easier access to the superomedial border of the scapula.<sup>10</sup> A line is marked between the superior angle of the scapula medially and the outer aspect of the acromion laterally and divided into thirds. These 2 points were chosen because they are easily palpable, fixed bony landmarks. The point of trocar entry was the traditionally accepted position (2 cm medial to the medial border of the scapula just below the level of the spine of the scapula). The point of exit for the trocar is the junction of the medial and middle thirds of the marked imaginary line. After trocar insertion, Chan et al dissected 5 fresh-frozen cadaveric specimens in the lateral position with the arm in traction to mimic the surgical position.<sup>10</sup> They found the mean distance between the arthroscopic superior portal and the accessory, dorsal scapular, and suprascapular nerves to be 18.2 mm, 20.2 mm, and 24.6 mm, respectively.<sup>10,60</sup> After portal positioning, the arm was brought into the chicken wing position to proceed with scapulothoracic arthroscopy.

Despite the lack of agreement among orthopaedic surgeons regarding which procedure is best for snapping scapula, most studies have resulted in good outcomes for very high percentages of patients. A combination of bursectomy and bony resection may be the best option for many patients, and this must be a decision made intraoperatively based on the patient's given findings. Most patients returned to work and/or sports (including overhead sports) within about 3 to 4 months regardless of the procedure chosen. Few studies in the literature discuss the postoperative rehabilitation protocol in much detail, but it is clear that return to sports is not allowed until proper thoracic posture, scapular control, and strength are obtained with the physical therapy techniques previously described.

## CONCLUSIONS

Scapulothoracic crepitus and bursitis are common conditions seen by sports medicine clinicians. For most patients, the initial treatment plan for this condition is nonoperative and requires scapular strengthening exercises and postural reeducation. Local modalities, oral anti-inflammatory medications, and localized injections can also be recommended. Surgical correction should be saved for those who do not demonstrate satisfactory clinical outcomes with nonoperative intervention.

## REFERENCES

- Ashmen KJ, Swanik CB, Lephart SM. Strength and flexibility characteristics of athletes with chronic low back pain. *J Sport Rehabil*. 1996;5:275-286.
- Baechele TR. *Essentials of Strength Training and Conditioning*. Champaign, Ill: Human Kinetics; 1994.
- Bateman JE. *The Shoulder and Neck*. Philadelphia, Pa: WB Saunders Company; 1972.
- Bateman JE. Shoulder injury in the throwing sports. In: *The American Academy of Orthopedic Surgeons: Symposium on Sports Medicine*. St. Louis, Mo: CV Mosby; 1969:94.
- Boinet W. *Bulletin de la Societe Imperiale de Chirurgie de Paris, 2nd Series*. 1867;8:458.
- Bradley J, Tibone J. Electromyographic analysis of muscle action about the shoulder. *Clin Sports Med*. 1991;10:789-795.
- Brown C. Compressive, invasive referred pain to the shoulder. *Clin Orthop*. 1983;173:55-62.
- Burkhart SS, Morgan CD, Kibler WB. The disabled throwing shoulder: spectrum of pathology part III: the SICK scapula dyskinesis, the kinetic chain, and rehabilitation. *Arthroscopy*. 2003;19:641-661.
- Cailliet R. *Neck and Arm Pain*. 3rd ed. Philadelphia, Pa: FA Davis; 1991.
- Chan BK, Chakraborti AJ, Bell SN. An alternative portal for scapulothoracic arthroscopy. *J Shoulder Elbow Surg*. 2002;11:253-258.
- Ciullo JV. Subscapular bursitis: treatment of "snapping scapula" or "washboard syndrome." *Arthroscopy*. 1992;8:412.
- Ciullo JV, Jones E. Subscapular bursitis: conservative and endoscopic treatment of "snapping scapula" or "washboard syndrome." *Orthop Trans*. 1993;16:740.
- Cobey MC. The rolling scapula. *Clin Orthop*. 1968;60:193-194.
- Codman EA. *The Shoulder: Rupture of the Supraspinatus Tendon and Other Lesions in or About the Subdeltoid Bursa*. Malabar, Fla: Krieger Publishing; 1984:123-177.
- Curwin S, Stanish WD. *Tendinitis: Its Etiology and Treatment*. Lexington, Mass: Heath; 1984.
- Della Valle CJ, Rokito AS, Birdzell MG, Zuckerman JD. Biomechanics of the shoulder. In: Norkin M, Frankel VH, eds. *Basic Biomechanics of the Musculoskeletal System*. Philadelphia, Pa: Lippincott Williams & Wilkins; 2001:318-339.
- Dintman G, Ward B, Tellez, T. *Sports Speed*. Champaign, Ill: Human Kinetics; 1997.
- Dominguez RH, Gajda R. *Total Body Training*. East Dundee, Ill: Moving Force Systems; 1982.
- Edelson JG. Variations in the anatomy of the scapula with reference to snapping scapula. *Clin Orthop*. 1996;11:111-115.
- Evans RC. *Illustrated Orthopedic Physical Assessment*. 2nd ed. St. Louis, Mo: Mosby; 2001.
- Glousman R, Jobe FW, Tibone JE, Moynes D, Antonelli D, Perry J. Dynamic electromyographic analysis of the throwing shoulder with glenohumeral instability. *J Bone Joint Surg Am*. 1988;70:220-226.
- Gracovetsky S, Farfan H. The optimum spine. *Spine*. 1986;11:543-573.
- Grunfeld G. Beitrag zur Genese des Skapularkrachens und der Skapuloargeraushe. *Arch Orthop J Unfall Chir*. 1927;24:610-615.
- Haney TC. Subscapular elastofibroma in a young pitcher: a case report. *Am J Sports Med*. 1990;18:642-644.
- Harper GD, McIlroy S, Bayley JIL, Calvert PT. Arthroscopic partial resection of the scapula for snapping scapula: a new technique. *J Shoulder Elbow Surg*. 1999;8:55-57.
- Herbert LJ, Moffet H, MacFadyen BJ, et al. Scapular behavior in shoulder impingement syndrome. *Arch Phys Med Rehabil*. 2002;83:60-69.
- Inman VT, Saunders JB, Abbott LC. Observations of the function of the shoulder joint. *Clin Orthop*. 1996;330:3-12.
- Janda V. Muscles and cervicogenic pain syndromes. In: Grant R, ed. *Physical Therapy of the Cervical and Thoracic Spine*. New York, NY: Churchill Livingstone; 1988:153-166.
- Johnston TB. The movements of the shoulder joint: a plea for the use of the "plane of the scapula" as the plane of reference in movements occurring at the humero-scapular joint. *Br J Surg*. 1937;25:252.
- Kamkar A, Irrgang JJ, Whitney SL. Nonoperative management of secondary shoulder impingement syndrome. *J Orthop Sports Phys Ther*. 1993;17:212-224.
- Kapandji I. *The Physiology of Joints*. Vol 1. 5th ed. London, England: Churchill Livingstone; 1982.
- Kendall FP, McCreary EK, Provance PG. *Muscles Testing and Function*. 4th ed. Baltimore, Md: Williams & Wilkins; 1993:81.
- Kibler WB. The role of the scapula in athletic shoulder function. *Am J Sports Med*. 1998;26:325-337.
- Kisner C, Colby LA. *Therapeutic Exercise: Foundation and Techniques*. 4th ed. Philadelphia, Pa: FA Davis; 2002.
- Knott M, Voss D. *Proprioceptive Neuromuscular Facilitation*. New York, NY: Harper and Row; 1968.
- Kouvalchouk JF, Merat J, Durey A. *Subscapular Crepitus*. Clichy, France: Societe Francaise de Chirurgie Orthopedique et Traumatologique; 1985:587-588.
- Kuhn JE. Scapulothoracic crepitus and bursitis. In: DeLee JC, Drez D, Miller MD, eds. *Orthopedic Sports Medicine Principles and Practice*. Vol 1. 2nd ed. Philadelphia, Pa: Elsevier Science; 2003.
- Kuhn JE, Plancher KD, Hawkins RJ. Symptomatic scapulothoracic crepitus and bursitis. *J Am Acad Orthop Surg*. 1998;6:267-273.
- Levangie PK, Norkin CC. *Joint Structure and Function: A Comprehensive Analysis*. 3rd ed. Philadelphia, Pa: FA Davis; 2001.
- Lewitt K. *Manipulative Therapy in Rehabilitation of the Locomotor System*. London, England: Butterworth-Heinemann; 1985.
- Ludewig PM, Cook TM, Nawoczenski DA. Three-dimensional scapular orientation and muscle activity at selected positions of humeral elevation. *J Orthop Sports Phys Ther*. 1996;24:57-65.
- Lukasiewicz AC, McClure P, Michener L, Pratt N, Sennett B. Comparison of 3-dimensional scapular position and orientation between subjects with and without shoulder impingement. *J Orthop Sports Phys Ther*. 1999;29:574-583.

43. Makin GJV, Brown WF, Ebers GC. C7 radiculopathy: importance of scapular winging in clinical diagnosis. *J Neurol Neurosurg Psychiatry*. 1986;49:640-644.
44. McClure PW, Michener LA, Sennett BJ, Karduna AR. Direct 3-dimensional measurement of scapular kinematics during dynamic movements in vivo. *J Shoulder Elbow Surg*. 2001;10:269-277.
45. McClusky GM, Bigliani L. Partial scapulectomy for disabling scapulothoracic snapping. *Orthop Trans*. 1990;14:252-253.
46. McClusky GM, Bigliani L. Scapulothoracic disorders. In: Andrews JR, Wilk KE, eds. *The Athlete's Shoulder*. New York, NY: Churchill Livingstone; 1994:305-316.
47. McQuade K, Dawson J, Schmidt G. Scapulothoracic muscle fatigue associated with alterations in scapulohumeral rhythm. *J Orthop Sports Phys Ther*. 1998;28:74-80.
48. Michele AA, Eisenberg J. Scapulocostal syndrome. *Arch Phys Med Rehabil*. 1968;49:383-387.
49. Milch H. Partial scapulectomy for snapping of the scapula. *J Bone Joint Surg Am*. 1968;32:561-566.
50. Milch H. Snapping scapula. *Clin Orthop*. 1961;20:139-150.
51. Milch H, Burman MS. Snapping scapula and humerus varus: report of six cases. *Arch Surg*. 1933;26:570-588.
52. Morse JB, Ebraheim NA, Jackson WT. Partial scapulectomy for snapping scapula syndrome. *Orthop Rev*. 1993;22:1141-1144.
53. Moseley JB, Jobe FW, Pink M, Perry J, Tibone J. EMG analysis of the scapular muscles during a shoulder rehabilitation program. *Am J Sports Med*. 1992;20:128-134.
54. Mozes G, Bickels J, Ovadia D, Dekel S. The use of three-dimensional computed tomography in evaluating snapping scapula syndrome. *Orthopedics*. 1999;22:1029-1033.
55. Neer C. *Shoulder Reconstruction*. Philadelphia, Pa: WB Saunders Company; 1990.
56. Neviasser RJ. Painful conditions affecting the shoulder. *Clin Orthop*. 1983;173:63-69.
57. Nicholson GP, Duckworth MA. Scapulothoracic bursectomy for snapping scapula syndrome. *J Shoulder Elbow Surg*. 2002;11:80-85.
58. Paine R, Voight M. The role of the scapula. *J Orthop Sports Phys Ther*. 1993;18:386-391.
59. Panjabi MM. The stabilizing system of the spine, part I: function, dysfunction, adaptation, and enhancement. *J Spinal Disord*. 1992;5:383-389.
60. Pavlik A, Ang K, Coghlan J, Bell S. Arthroscopic treatment of painful snapping of the scapula by using a new superior portal. *Arthroscopy*. 2003;19:608-612.
61. Percy EC, Birbrager D, Pitt MJ. Snapping scapula: a review of the literature and presentation of 14 patients. *Can J Surg*. 1988;31:248-250.
62. Poppen NK, Walker PS. Normal and abnormal motion of the shoulder. *J Bone Joint Surg Am*. 1976;58:195-201.
63. Richards R, McKee MD. Treatment of painful scapulothoracic crepitus by resection of the supero-medial angle of the scapula. *Clin Orthop*. 1989;247:111-116.
64. Rockwood CA, Matsen FA. *The Shoulder*. 2nd ed. Philadelphia, Pa: WB Saunders Company; 2000.
65. Rose DJ, Novak EJ. The painful shoulder: the scapulocostal syndrome in shoulder pain. *J Kans Med Soc*. 1966;67:112-114.
66. Ruland LJ, Ruland CM, Matthews LS. Scapulothoracic anatomy for the arthroscopist. *Arthroscopy*. 1995;11:52-56.
67. Russek AS. Diagnosis and treatment of scapulocostal syndrome. *J Am Med Assoc*. 1952;150:25-27.
68. Saha AK. Mechanism of shoulder movements and a plea for the recognition of "zero position" of glenohumeral joint. *Indian J Surg*. 1950;12:153.
69. Scovazzo M, Browne A, Pink M, Jobe F, Kerrigan J. The painful shoulder during the freestyle stroke. *Am J Sports Med*. 1991;19:577-582.
70. Sisto DJ, Jobe FW. The operative treatment of scapulothoracic bursitis in professional pitchers. *Am J Sports Med*. 1986;14:192-194.
71. Steindler A. *Traumatic Deformities and Disability of the Upper Extremity*. Springfield, Ill: CC Thomas Publishing; 1946.
72. Strizak AM, Cowen MH. The snapping scapula syndrome: a case report. *J Bone Joint Surg Am*. 1982;64:941-942.
73. Voight ML, Thompson BC. The role of the scapula in the rehabilitation of shoulder injuries. *J Athl Train*. 2000;35:364-372.
74. Wood VE, Verska JM. The snapping scapula in association with the thoracic outlet syndrome. *Arch Surg*. 1989;124:1335-1337.