

Novel solutions applied in transeptal puncture: a systematic review

Pedro Morais^{a, b, c}, MSc, João L. Vilaça^{a, d}, PhD, Joris Ector^e, M.D. PhD,
Jan D'hooge^b, PhD and João Manuel R. S. Tavares^c, PhD

^aICVS/3B's - PT Government Associate Laboratory, Braga/Guimarães, Portugal

^bLab on Cardiovascular Imaging and Dynamics, KU Leuven, Belgium

^cInstituto de Ciência e Inovação em Engenharia Mecânica e Engenharia Industrial,
Faculdade de Engenharia, Universidade do Porto, Portugal

^dDIGARC – Polytechnic Institute of Cávado and Ave, Barcelos, Portugal

^eDepartment of Cardiovascular Sciences, KU Leuven, Leuven, Belgium

Name and Address for Correspondence:

Prof. João Manuel R. S. Tavares

Faculdade de Engenharia da Universidade do Porto (FEUP)

Departamento de Engenharia Mecânica (DEMec)

Rua Dr. Roberto Frias, s/n, 4200-465 PORTO - PORTUGAL

Telf.: +315 22 5081487, Fax: +315 22 5081445

Email: tavares@fe.up.pt, Url: www.fe.up.pt/~tavares

Conflict of Interest

The authors declare that they have no conflict of interest

Novel solutions applied in transseptal puncture: a systematic review

Abstract

Purpose: Access to the left atrium is required for several minimally invasive cardiac interventions in the left heart. For this purpose, transseptal puncture (TSP) technique is often performed, perforating the atrial septum under fluoroscopic or/and ultrasound imaging guidance. Although this approach has been used for many years, complications/failures are not uncommon mainly in patients with abnormal atrial anatomy and repeated TSP. Thus, this study presents an overview of methods and techniques that have been proposed to increase the safety and feasibility of the TSP.

Methods: A systematic review of literature was conducted through the analysis of the articles published between 2008 and 2015. The search was performed in PubMed, Scopus and ISI Web of Knowledge using the expression “transseptal puncture”.

Results: A total of 354 articles were retrieved from the databases, and 64 articles were selected for this review. Moreover, these 64 articles were divided into four categories, namely: 1) incidence studies; 2) intra-procedural guidance techniques; 3) pre-procedural planning methods and 4) surgical instruments. A total of 36 articles focused on incidence studies, 24 articles suggested novel intra-procedural guidance techniques, 5 works focused on pre-procedural planning strategies and 21 works proposed surgical instruments.

Conclusions: The novel 3D guidance techniques, radio-frequency surgical instruments and pre-interventional planning approaches showed potential to overcome the main procedural limitations/complications, through the reduction of the intervention time, radiation, number of failures and complications.

Keywords: Transseptal Puncture; Left Atrium Access; Systematic Review; Optimal Puncture Position.

1. Background

Percutaneous access of the left atrium (LA) is required in a large number of minimally invasive procedures, such as catheter ablation for atrial fibrillation, paravalvular leakage repair, percutaneous mitral valve replacement and left atrial appendage closure [1, 2]. These procedures are frequently performed (Table 1) being a preferred practice to the traditional open-chest surgery, due to the lower costs and lower complication rate. Nonetheless, these procedures are not free of risks being highly dependent of physician experience and medical devices/instruments used [3].

Two techniques are commonly used to gain access to the LA, namely: transaortic (TA) and transseptal puncture (TSP). In TA, a catheter inserted in the femoral artery is retrogradely advanced through the aortic valve towards the left ventricle (LV). Subsequently, the catheter is rotated 180° and advanced through the mitral valve (MV) into the LA chamber. In contrast, in TSP a catheter is inserted into the right-atrium (RA) via the venous system, through which a needle can be moved forward, in order to puncture the interatrial septum (IAS) and consequently gain access to the LA. Yet, the puncture should be performed through the thinnest region of the IAS wall, termed fossa ovalis (FO). Thus, the TSP technique establishes a “more direct” access route, when compared with TA approach. Nevertheless, in complex situations TSP can result in serious complications, such as perforation of large vessels [3].

Despite the similar safety between the two techniques [3, 4], the TA route requires a 180° rotation of the catheter, hampering its manipulation and the procedure. Moreover, the TA uses an access route through the high-pressure arterial system. Contrarily, TSP uses simple routes and enters into the LA using the low-pressure venous system. As such, in the last years, a higher number of procedures based on TSP were suggested [3]. However, determining the optimal puncturing site is not straightforward, as not only the ease of puncturing depends on the location, but also the target site to be reached in the LA has to be taken into account, as crossing the septum limits the maneuverability of the catheters and, thus, their ability to reach the LA target sites. To date, this decision is entirely based on the physician’s experience and secondary punctures are usually required as the first one turns out inadequate [3].

New strategies have been proposed to overcome the main-complications of the TSP, through the inclusion of novel guidance, planning methods and surgical instruments. In the current study we present an overview of these new strategies and summarize their advantages.

Briefly, the current work introduces four novelties, namely: 1) an incidence study about the TSP; 2) a review of the recent guidance methods applied in TSP; 3) a review of intra-procedural planning methods for safe puncture zone recognition; and 4) an overview of novel surgical instruments recently used to puncture the IAS wall.

The current article is divided into six main sections: 1) description of the traditional TSP procedure; 2) method used to identify the relevant articles for the review; 3) aims and main

conclusions of the selected articles; 4) discussion of the relevant articles, presenting their advantages and main drawbacks; 5) future trends; and, 6) conclusions.

1.1 - Traditional transeptal puncture procedure

The TSP has been widely addressed in literature [1, 3, 5], reporting the guidance equipment and catheters used to safely puncture the IAS wall. This is typically guided using bi-dimensional fluoroscopy and is performed using a mechanical Brockenbrough needle (BRK, St. Jude Medical, Minneapolis) [3]. Furthermore, several auxiliary catheters are used to prevent puncture of vital structures. For instance, catheters at the aorta, coronary sinus (CS) and His bundle are commonly used. Regarding the procedural time, 1 to 15 minutes have been reported [6-10].

The procedure starts with the insertion of a guidewire (0.032-0.035 inch) into the inferior vena cava using the right femoral vein access (Fig. 1a). The guidewire defines a safe route between the femoral vein and the superior vena cava (SVC). It should be noticed that some works presented a variant of the TSP, where the needle is inserted via right internal jugular vein until SVC instead the traditional femoral access [11]. A dilator and sheath are also positioned into the SVC using the guidewire. At this stage, the guidewire is replaced by the BRK needle, maintaining it inside the sheath to prevent inadvertent punctures. Then, the assembly (needle-sheath-dilator) is positioned at the FO. The assembly is rotated to 4-5 o'clock position and posteriorly pulled-down. At this point, two movements will be detected: the first indicates the entrance of the assembly into the RA (Fig. 1b); and the second, which is less perceptible, occurs when the assembly is inside the FO (Fig. 1c). Since puncture outside the FO increases the risk of perforating vital structures and limits the maneuverability of the catheter in the LA, confirmation of the needle position should be performed (Fig. 1d-e) [12]. Furthermore, a confirmation of the actual position of the aorta, CS and His bundle is required to ensure safety of the puncture.

Finally, the puncture can be performed (Fig. 1e) and the surgical tool can be introduced into the LA. The position of the needle is confirmed using the left atria pressure variation or contrast agents. It should be noted that a repetition of the entire procedure is required when the assembly is not aligned with the FO or when the expert has doubts about the assembly position.

As a final remark, during the entire procedure the expert should be aware of the possible anatomic variations that hamper the identification of the optimal puncture position. An overview of the most common anatomic variations of the atrial region is presented in Table 2. A different access site is required when an abnormal anatomy is identified, being this recognition only performed based on the physician's experience. Note that these modifications are crucial to ensure the maximum safety of the procedure and reduce the number of complications [13].

2. Materials and Methods

In this section, we report the criteria used to identify the relevant works for the review performed. We followed the PRISMA statement for the design, implementation, analysis and reporting of the results [14].

2.1. Selection Method

A search was performed on PubMed, Scopus and ISI Web of Sciences databases between 9 and 10 of April 2015. The search used the exact expression “transseptal puncture”. Only works published between January of 2008 and April of 2015 were considered. A total of distinct 354 articles were obtained and evaluated.

2.2. Data Collection and Processing

The identification of the relevant works was performed through double-stage strategy, as explained below and previously reported in PRISMA guidelines [14].

First, the title and the abstract of all 354 articles obtained during section 2.1 were analyzed by the first author of the current study. All the works with aims different of the main topic of this review were removed, resulting in a total of 141 articles eligible for this study. It should be noticed that works not written in English and patents were automatically discarded.

Second, the obtained 141 articles were completely read and analyzed, and the following criteria were used to identify the relevant studies: 1) the selected studies should focus on novel technical innovations of the TSP procedure, discarding small case-to-case adaptations of the traditional approach due to difficult intervention or strange anatomies; 2) incidence studies about the current TSP technique were also considered as valid for this review; 3) short clinical reports about difficult procedure, letters between editor, author or reader and short communications without technical description were discarded; and 4) previously presented reviews about TSP and similar topics were also rejected. Table 3 presents an overview of the excluded reviews. As such, a total of 64 articles were selected for the review. Note that, the identification of the relevant works was done by the first author of this review.

2.3. Data Analysis

The 64 selected articles were fully analyzed and classified into different categories: incidence studies, intra-procedural guidance techniques, pre-procedural planning methods and surgical instruments (Fig. 2). Each publication could be included in more than one category.

3. Results

In this section, an overview of the main topic addressed by the selected articles is presented.

3.1. Study characteristics

Thirty-six articles reported TSP procedure previous experience, describing the technique applied and the failure/complication rate achieved. Regarding the novel strategies proposed to overcome the limitations of TSP, twenty-four studies suggested new intra-procedural guidance techniques, five studies focused on pre-procedural planning methods and twenty-one works presented novel surgical equipments.

3.2. Incidence Study

Table 4 presents a review of the total number of TSP performed between 2008 and April of 2015. Several studies use heterogeneous populations, which includes: children's [15-17], abnormal atria anatomy [10, 18-26] and patients with previous TSP [7, 8, 27-32]. The number of puncture attempts, failures and complications were registered. The results show that approximately 12% of the procedures require more than one puncture attempt, and complications/failures rate are lower than 1%. It may be noted that, since studies (see Table 4) with different operator's expertise (i.e. expert and trainee), heterogeneous populations and multiple surgical equipments were included in this analysis, high variation of complication and failure rate was found.

3.3. Intra-procedural guidance techniques

In order to overcome the limitations of the procedures only guided by fluoroscopy, several authors exploited the application of new imaging modalities in TSP (Table 5), namely: transesophageal echocardiography (TEE) [19, 33-38], intracardiac echocardiography (ICE) [9, 39-43], real-time magnetic resonance (MR) [44] and direct color visualization [45]. Furthermore, needle tracking based on electromagnetic sensors [46] and electroanatomic mapping (EAM) [17, 47-52] were also presented. These novel guidance techniques increase the safety of the TSP procedure [9, 33, 39, 50], reduce or completely eliminate the radiation from the procedure [17, 39, 40, 46, 47] and remove the contrast injection to confirm correct LA access [40]. Moreover, faster procedures were performed [40] and higher success rates in difficult situations were achieved [9, 33].

3.4. Pre-procedural planning techniques

Some authors proposed pre-interventional planning techniques, namely: identification of a safe zone for TSP [32, 53-55] and recognition of the optimal puncture position, which guarantee maximum catheter dexterity inside the LA [56]. This planning step relies on pre-interventional image acquisitions, namely, by: CT [53, 54, 56], MR [56] or TEE [32, 55]. The authors agreed that these novel planning methods allow accurate planning of the TSP therefore, increasing the safety of TSP and reducing complication/failures rate [53, 56].

Table 6 presents the aims, validation and conclusion of these novel studies.

3.5. Surgical instruments

A high number of studies focused on the traditional BRK needle. This crosses the septum using a mechanical process, based on pressure applied on FO. Nonetheless, in abnormal septal wall high pressure can result in inadvertent puncture and consequently, intervention complication [8]. As such, novel needles were proposed, specifically: RF (radio-frequency) rigid NRG needle (Baylis Medical) [7, 8, 28, 30, 57-60], RF flexible Toronto needle (Baylis Medical) [18], electrocautery needle technique [27, 61-64] and coaxial transseptal (CTS) needle [65].

Furthermore, some authors proposed novel solutions for the remaining surgical equipment's, particularly: dilator, guidewire and catheters. Thereby, a new dilator approach [66], a laser catheter and a nitinol guidewire with "J" shape [21, 22, 67] were suggested to prevent inadvertent puncture and reduce complication rate.

A robotic remote navigation system was also suggested to perform safe LA interventions. This system was applied on TSP and ablation of atrial fibrillation [52].

Table 7 presents an overview of these novel equipment's.

4. Discussion

4.1. Incidence Study

Between 2008 and 2015, an average complication and failure rate lower than 1% was reported (Table 4). These results are in accordance with previous studies [3], proving that TSP is a safe and feasible technique in clinical practice. Nevertheless, since TSP is required as an intermediate step for several procedures, a high number of patients with complications still being reported.

Multiple studies proved that cardiac tamponade is the major complication of the TSP procedure, being also common transient ischemic attack and transient ST elevation [3, 18, 25, 68, 69]. Furthermore, we investigated the number of situations where a second attempt was required to access the LA. This analysis is interesting to assess the feasibility of the current guidance techniques and instruments used. Approximately 12% of the procedures required more than one puncture attempt, which increases the procedural time and the radiation exposure [6, 16, 18-22, 27, 63]. This last result indicates that FO recognition/puncture is not straightforward, claiming for novel guidance strategies and smart surgical equipment's [15, 68, 70].

In 2012, Yao *et al.* published a clinical experience article about TSP [20]. A total of 539 punctures were reported, with success of 100% and first attempt puncture of 98.9%. Similarly, Alvensleben *et al.* and Elayi *et al.* proved that TSP can be safely applied on children's [15, 16] with a low complication rate (2%) [15]. Yao *et al.* and Bayrak *et al.* discussed the difficulties of TSP on unexperienced hands [6, 19], proving that higher failure rate and large procedural time are achieved by trainees. Moreover, Schwagten *et al.* presented

a comparison between LA access through TSP and TA approach. 22 patients were used in this experiment and similar complication/failure rate was achieved by the two strategies [4].

Several authors focused on clinical studies to identify the main complications and limitations of the TSP [13, 24, 25, 29, 31, 68-70]. The authors reported that:

- 1) Any consensus was found between LA access through patent foramen ovale (PFO) or TSP procedure. Lehrmann *et al.* and Knecht *et al.* agreed that TSP procedure results in lower complication rate [29] and allow simple maneuverability of the catheter inside the LA [13] when compared with PFO access. However, Koermendy *et al.* and Miyazaki *et al.* published clinical reports proving that LA access through PFO is safe with higher success rate and lower complication rate when compared with TSP [26, 69];
- 2) Repeated TSP presented higher complication rate and higher number of puncture attempts [31] when compared with patients without any previous procedure;
- 3) Anterior, medial and posterior FO are the optimal puncture position, with equal complication rate and maximum catheter dexterity [70].

In order to facilitate left heart procedures, multiple catheters placed through double TSP have been suggested [10, 71]. Haegeli *et al.* performed 269 procedures using double puncture with a complication rate of approximately 3% [71]. Similarly, Lakkireddy *et al.* applied the same technique in 90 patients with only one failure and a complication rate of 4% [10]. Thus, the authors agreed that double TSP increases the maneuverability of the catheters inside the LA [71] and it is a feasible technique in normal clinical practice.

Finally, a high number of studies focused on novel TSP techniques and its comparison against the traditional technique [7-9, 17, 18, 21, 22, 28, 30, 35, 39, 50, 52, 59, 63, 66, 71]. The novel methods reduced the number of complications, failure rate, procedural time and radiation exposure.

4.2. Intra-procedural guidance techniques

Several authors proposed novel guidance techniques, based on TEE or ICE, to overcome the main limitations of the fluoroscopy-based procedures, namely: 1) bidimensional acquisition with low contrast between the relevant structures and the neighbors, and 2) continuous radiation exposure.

Wu *et al.* and Chierchia *et al.* suggested the application of 2D [38] and 3D [35] TEE, respectively, in TSP to correct the alignment between the needle and FO. The authors validated this novel image guidance approach in humans. A low complication rate and no failure were reported, proving therefore the safety and feasibility of the new method in clinical practice. Furthermore, lower procedural time was reported [35, 38]. Faletra *et al.* presented extended reports about atrial anatomy interpretation in 3D TEE [33, 36]. They proposed that TEE is useful in pre-procedural planning step and during the TSP, due to the clear definition of the “true” septum border. Moreover, Bayrak *et al.* proved that TEE allows

simple recognition of the anatomical structures, namely FO, and it is essential to safe TSP in unexperienced hands [19]. Finally, Gafoor *et al.* recently proposed the application of the novel EchoNavigator system (Philips Inc., Netherlands) on the TSP procedure [34]. The EchoNavigator automatically combines 3D TEE image with fluoroscopy, which allows simple catheter guidance until the target site. Note that TEE and fluoroscopy ease FO recognition and instruments tracking/identification, respectively. As such, the physician can introduce landmarks on the image obtained from TEE (e.g. FO position) and accurately visualize them in the fluoroscopic image. Although this system presented promising results, no validation study was reported [34].

Since TEE generally requires high level of sedation with high costs to facilitate the manipulation of the thick TEE probe, micro-TEE probe was suggested. Stec *et al.* applied the novel method in 12 non-sedated patients without any failure. Moreover, a clear image of IAS wall was achieved, proving that this guidance approach can be safely used in TSP [37].

Similarly, ICE imaging was also proposed as an interesting solution for safe TSP. Instead the traditional esophageal route required for TEE imaging, which requires anesthesia in order to increase the patient comfort during the long-period of the intervention, an intravascular route is used, consequently removing the need of high sedation levels. Since ICE provides a clear definition of the IAS wall in real-time, identification of the FO position is facilitated. Ferguson *et al.* proved that ICE guaranteed safe TSP, through the application of this technique in 21 situations without any complication [39]. Liang *et al.* compared two ICE techniques in order to identify the optimal strategy for TSP, namely mechanical ICE and phased-array ICE. Mechanical ICE uses a non-flexible catheter, with a bidimensional image generated perpendicularly to the catheter. In contrast, phased-array ICE uses a flexible catheter, shows color Doppler functions and uses multiple transducers controlled electronically to produce a wedge shaped image. Both methods showed a clear image of the IAS and FO [40]. However, since mechanical ICE has a better near field view, needle guidance inside the RA is simpler. Additionally, mechanical ICE is a lower cost strategy [40]. Finally, some authors presented interesting extended reports about ICE image guidance during TSP procedures, where a detailed explanation about atrial anatomy interpretation in ICE is presented [41-43].

Mitchell-Heggs *et al.* proposed a different guidance technique, where the ICE probe (smaller than TEE probe) is used through the esophageal route instead the traditional intravascular one. The authors reported that this new strategy, termed ICE-TEE, reduces the risks associated with femoral hematoma (common in traditional ICE), ease the catheter manipulation and facilitate the identification of the relevant anatomical structures. The technique was successfully in 79 patients with a complication rate of 11% [9].

Elagha *et al.* and Thiagalingam *et al.* proposed different image-guidance strategies based on real-time MRI [44] and direct full color visualization [45], respectively. Regarding the first strategy, the authors applied interactive, multi-slice real-time MRI using steady free precession pulse sequences. Since the patient is positioned inside the MRI machine, some

equipment's (e.g. catheters) were modified. As a result, the authors proved that the transseptal needle and FO can be accurately identified with this imaging technique. Moreover, fast identification of possible complications was easily observed, namely perforation of aorta and of atrial free wall. The method was successfully tested (100%) in animal models [44]. Thiagalingam *et al.* proposed direct visualization of the IAS through a fiber optic catheter. A real-time visualization of IAS was achieved through a connection between the fiber optic and a monitor. Moreover, a pressurized bag of saline solution, connected to the fiber optic, was used to clean the blood from the top of the camera. TSP was performed in animal models without any complication. Furthermore, post-mortem analysis showed a high correlation between puncture site and real FO. However, although these methodologies presented large potential to a safe and quick TSP, human validation is missing [44, 45].

Instead of novel image guidance methods, Yao *et al.* proposed a modification of the traditional TSP. Similarly to the traditional approach, this new method is also guided by fluoroscopy, being therefore an inexpensive and attractive solution [6]. Nevertheless, in this solution, a distal CS catheter is positioned on the lateral marginal of the heart, consequently defining the level of FO at posterior-anterior projection of fluoroscopy. Thus, after an initial alignment between the needle and FO, using the traditional procedure, a confirmation of the needle site is performed using the CS catheter site. In this confirmation, the physician verifies if the TSP needle is positioned between the distal CS catheter and the peak posterior margin of the LA at right anterior oblique direction of fluoroscopy. Finally, the needle can safely puncture the FO until LA. Three trainee and one expert applied this method in 120 patients with a mean failure rate of 4% [6].

Several studies proposed novel guidance methodologies based on EAM [17, 47, 51, 52] and electromagnetic sensors [46], respectively. The authors suggested that fluoroscopy time can be notably reduced [47, 51] or removed [17] from TSP, presenting therefore clear advantages for the physician and the patient. Shepherd *et al.* used the EAM technique to generate a 3D model of the atria and to guide the transseptal needle until the FO. Nonetheless, no clinical validation was performed. Moreover, since EAM technique does not provide real-time geometries, a sub-optimal guidance approach was achieved [47]. As such, Mah *et al.* suggested the combination of EAM and ICE to reduce the fluoroscopy exposure time. The proposed approach was applied in clinical practice, where a significant reduction of the fluoroscopy dose/time was observed [51]. Saliba *et al.* applied the same technique in a robotic remote navigation system to perform the TSP procedure. This framework was tested in 40 patients, showing similar complication/failure results when compared with the traditional approach [52].

Instead of ICE imaging, Clark *et al.* presented a novel system where EAM data is fused with TEE. The optimal puncture is performed in two steps: 1) identification of the optimal puncture position using the RA geometry generated by EAM; 2) confirmation of the correct alignment between the needle and puncture site using TEE. The system was applied in 10

patients without any complication or failure. Furthermore, fluoroscopy time and exposure was not required [17]. Finally, Jeevan *et al.* proposed a different strategy to guide TSP procedure. In this strategy, an electromagnetic sensor was positioned on the tip of the catheter and it was rigidly aligned with a patient specific atrial model obtained from a pre-interventional MRI. This register was performed through a set of fiducial markers positioned on the real and virtual model, being the FO also represented by a fiducial marker. As such, during the intervention the electromagnetic system indicates the optimal trajectory until the puncture site. The system was tested using one phantom, being the procedure performed quickly and without any complication. However, it was only tested using a static model being far from being applied in real situations [46].

Recent studies suggested that left-sided catheter dwelling time appears to be associated with bleeding, clotting, endothelial dysfunction or char particle embolization [50]. As such, repeated/multiple LA access through TSP is required to reduce the catheter dwelling time in the LA, and consequently reduce these complications [50, 72]. However, multiple LA access is time-consuming, frustrating, require large radiation dose and can originate serious complications [48]. Interesting solutions to quick and safe LA reaccess without any radiation were proposed in [48-50]. All the strategies use EAM to generate geometry of the atrial region and create a marker of the TSP site. Unnithan *et al.* and Pavlović *et al.* validated this methodology in 10 and 5 patients, respectively. Quick access (approximately 14 seconds) with low complication rate was reported [49, 50]. Additionally, Nguyen *et al.* proposed a new remote magnetic catheter navigator system that allows “manual” and “automatic” LA reaccess [48]. The automatic remote navigator system relies on 8 electromagnetics positioned along the patient. These electromagnetics modify the magnetic field applied when a correction of needle position or pose is required to achieve the target site. This technique was applied with success in 5 patients, taking 6.2 ± 8.1 and 30.4 ± 28.4 seconds in automatic and manual operation mode, respectively [48].

4.3. Pre-procedural planning techniques

The novel pre-procedural planning methods for TSP focused on pre-interventional imaging, specifically: CT [53, 56], MR [56] or TEE [32, 55]. Wagdi *et al.* reported that TSP is challenging in situations where larger device sizes (e.g. amplatzer) have been applied to close an IAS defect. As such, they suggested the analysis of CT datasets to define a “safe zone” for TSP. This study was performed on 20 patients, and the results proved that CT data can predict the feasibility and safety of TSP. Similarly, Scherthner *et al.* used TEE to predict the feasibility of TSP, proving that TEE can be used to identify patients with abnormal IAS wall anatomy [55]. Tomlinson *et al.* suggested that FO thickness is a predictor of the difficulty of TSP procedure. Thus, during the pre-procedural stage, 42 patients were assessed by TEE and classified as difficult or not difficult procedure. It should be noted that wall thickness can be easily observed in TEE. This initial classification was subsequently

compared with the difficulty of the real procedure, where no correlation was found between the pre-procedural classification and the difficulty of the procedure. Finally, Jayender *et al.* proposed a novel approach for optimal puncture location estimation. This strategy combines pre-interventional anatomical models with a mechanical model of the catheter to simulate the TSP. As such, a finite element method was used to estimate the optimal puncturing site based on the thickness of the septal wall and the mechanical maneuverability of the catheter at all positions of the LA. [56]. The current system was only tested in one offline dataset, missing application in clinical practice.

4.4. Surgical instruments

New surgical instruments have also been presented to increase the efficiency of the TSP, with a notable focus on the needles. Although the mechanical BRK needle appears to be safe in non-complex procedures, the same is not observed in abnormal atrial anatomy or in patients with previous procedure. As such, NRG needles [7, 8, 18, 28, 30, 57-60] and electrocautery needles [27, 61-64] were proposed.

NRG is a rigid needle that uses RF energy to diminish the septal wall resistance, reducing therefore the force required for FO puncture. This needle presents a novel design, with an oval tip to prevent inadvertent puncture. Furthermore, a radiopaque marker was incorporated inside this equipment to simplify needle guidance in fluoroscopy-based methods [58]. Regarding the clinical practice, no significant modification of the traditional puncture procedure is required, therefore facilitating the introduction of this instrument [8].

In 2010, some authors demonstrated that NRG needles can be used to perform safe TSP, principally in difficult procedures [28, 57]. The method was validated in: 1) animal model [57], and 2) 35 patients [28]. Although animals with complex anatomy were used, no complications were found [57]. Regarding the clinical validation, only one failure was registered. Thus, the results showed that the NRG needle can be used to perform safe TSP even in difficult cases [28, 57].

Subsequently, several authors presented large clinical studies where a comparison between the NRG needle and the conventional one is performed [7, 8, 18, 30, 59, 60, 73]. The authors agreed that NRG reduces the procedural time, the complication/failure rate, and facilitates the procedure in presence of complex anatomies when compared with the traditional strategy [8, 30, 59, 60]. Additionally, randomized single blinded studies have also been used to validate these conclusions [7]. Moreover, Feld *et al.* proved that BRK needle can introduce plastic particles into the circulatory system of the patient, which can be the origin of microinfarcts and left ventricular dysfunction. These particles are created due to a process of skiving when the needle is advanced along the plastic dilator. The NRG needle was also tested and no plastic particles were found [58]. Although the NRG needle appears to present a superior performance when compared with the traditional equipment, several theoretical risks should be considered, particularly: 1) inadvertent cardiac puncture using RF can result in more

serious complications; 2) puncture site is less likely to close spontaneously; and 3) the RF puncture can be more traumatic for the FO [28].

Recently, a novel RF powered flexible needle, termed Toronto needle, was proposed [18]. The advantage of this new tool is the specific shape of the instrument, where a flexible catheter with large “J” shaped distal curve is used, consequently preventing inadvertent punctures. Moreover an RF system is used to ease TSP, as previously described in literature [7]. Jauvert *et al.* compared the Toronto and BRK needle in humans. 125 punctures were performed with Toronto needle, and 100 punctures with the traditional approach. The results demonstrated that the Toronto needle has a superior performance, lower number of failures (5% for BRK and 0% for Toronto) and lower complication rate (3% for BRK and 0% for Toronto) [18].

An electrocautery pen combined with traditional BRK needle was also proposed to ease septal wall crossing [27, 61-64]. In this method, the traditional TSP is initially performed to align the needle with the FO region. Subsequently, the cautery pen is applied on the proximal portion of the needle [61, 62], cauterizing the FO and reducing the pressure required to perform the FO crossing. Similarly to the NRG and Toronto needles, this novel approach reduces the complication/failure rates when compared with the BRK needle, mainly in highly elastic, aneurysmal, or fibrotic septal walls [27, 61-63]. Finally, Greenstein *et al.* compared both techniques to verify the incidence of tissue coring into the needle tip [64]. It should be noticed that coring of the septal wall can result in complications, such as systemic embolization. The study was performed in animal models and the results showed a similar number of tissues coring (~35% of the punctures) with both approaches, raising questions about the real safety of the TSP.

In opposition, Uchida *et al.* proposed a novel mechanical needle, termed CTS needle. This needle is longer than the traditional one, showing high safety (100%) and feasibility in 10 animals. It may be noted that TSP was not successfully with the BRK needle due to the particular anatomy of the animal [65].

Although several authors proposed and validated novel needles to safely perform TSP, novel solutions were also presented for the remaining equipment: nitinol guidewires [21, 22, 67, 74] and laser catheters [44]. Nitinol guidewire (SafeSept™, Pressure Products Inc., San Pedro, USA) presents a “J” preformed with 0.014” wire and a sharp-distal tip. This novel equipment is positioned inside the needle assuming two different shapes: 1) a straight shape when the guidewire is completely positioned inside the needle, and 2) a “J” shape when the guidewire is outside of the needle. The straight guidewire shape facilitates catheter manipulation and the “J” guidewire shape prevents inadvertent punctures. Furthermore, this novel guidewire has a radiopaque marker at the guidewire tip, facilitating instrument identification in fluoroscopy. This novel solution was compared with the traditional TSP strategies in humans, showing a high success rate even in difficult procedures [21, 22, 67, 74].

Moreover, Wadehra *et al.* suggested that the nitinol guidewire is a safe and useful alternative for the expensive TSP procedures based on 3D image guidance [21].

Elagha *et al.* proposed a laser catheter for TSP guided by real-time MRI. A receiver coil, positioned at the catheter tip, was used to generate a bright spot that can be detected on MRI. This new system was validated in animal models, proving that the laser catheter can be accurately detected in real-time MRI [44]. Furthermore, the novel system proved to be feasible, with a success rate of 100%.

Some authors suggested that robotic remote navigation system can be used in TSP interventions. The robotic system allows better catheter stability, precise positioning of the surgical equipment and simple catheter maneuverability, increasing therefore the safety of the procedures. Clinical validation was reported, being reported only one complication [52].

Finally, Wang *et al.* proposed a different TSP strategy, where a different surgical tool configuration is used. This strategy, termed dilator method, presents the following modifications: 1) the outer sheath was removed from the procedure, being only required the dilator and a transseptal needle; and 2) the needle was kept inside the dilator during the entire guidance procedure [66]. As such, the identification of the lip edge of the FO was performed using the dilator. Since the dilator presents a blunt tip, the FO identification was eased. A comparison between the novel method and the traditional one was performed in a total of 4443 patients. The results suggested that the dilator technique is much safer than the traditional approach, with a reduction of the complication rate. Nevertheless, an increase of the procedure time and radiation time was registered [66].

5. Future Trends

Several studies have explored the major technical limitations of the traditional TSP approach, specifically: 1) incorrect visualization of IAS; 2) difficulty in identifying the surgical tools; 3) incorrect estimation of the puncture position, mainly in patients with PFO; 4) inadequate needles for patients with abnormal anatomy; and 5) difficulty in confirming successful puncture or even procedural complications.

In this sense, multiple improvements have been introduced to the traditional technique, namely: 1) new guidance approaches through real-time imaging modalities or electromagnetic tracking sensors; 2) new pre-planning strategies based on CT or MRI; and 3) new surgical instruments, mostly new TSP needles. In particular, RF needles and puncture guidance using 3D ultrasound showed its added-value to the current TSP technique, mainly in difficult anatomies. The first one uses RF energy to reduce the septal wall resistance, facilitating the puncture in patients with thick (caused by repeated TSP procedure) or aneurismal walls. While the second one relies on a radiation-free imaging technique that allows real-time visualization of the 3D anatomy, being typically used to confirm the correct alignment between the transseptal needle and the fossa ovalis. However, large randomized and comparative studies between the aforementioned imaging modalities still missing.

Furthermore, TSP merely guided through ultrasound imaging is not typically used, due to the difficulty to understand the anatomy and to visualize the surgical instruments. As such, ultrasound combined with fluoroscopy is applied.

Although some planning solutions have been proposed to accurately identify the puncture position and the optimal needle trajectory, extensive validations of the available technique still missing, hampering its application in the real clinical practice. Furthermore, several studies are not tested in patients with abnormal anatomy, consequently not proving the adequacy of the proposed technique in challenging cases. As such, the current clinical practice still being largely dependent on physician experience. As a result, suboptimal locations that reduce the catheter dexterity at the left heart or even multiple puncture attempts, which increase the procedural time (and thus costs) and radiation exposure, are often used.

In the near future, the development of integrated image guidance tools that combine pre-procedural planning with intra-procedural imaging appears as an attractive solution to guide the physician until the optimal puncture position. Due to the high anatomic detail obtained with pre-planning imaging (such as CT and MR), accurate identification and planning of the optimal puncture position based on the target position at the left heart and septal wall thickness can be performed. Moreover, accurate simulation of the optimal puncture position and measurement of the catheter dexterity through computational simulation methods (e.g. finite element modeling) are important tools to plan the entire intervention. Then, the entire pre-procedural stage can be ported to the real interventional world, through image fusion solutions between CT/MR and 3D ultrasound imaging. This stage is vital, since all the annotations generated during the planning stage are superimposed on the patient anatomy (obtained in real-time by US), easing the identification of the optimal puncture position, consequently facilitating the puncture (enhancing several anatomic structures such as IAS and fossa ovalis) and increasing the level of confidence of the physician. One may note that, ultrasound imaging seems as an interesting solution to align the intra and pre-procedural stages, due to the 3D acquisition of the cardiac anatomy in real-time and also due to the clear definition of the IAS wall and cardiac chambers. Moreover, since this imaging modality is currently integrated in the operating room and traditionally is required to confirm correct alignment of the needle with fossa ovalis, simple integration of this new system in the current surgical setup is possible. Finally, the fused 3D world should be aligned with biplane fluoroscopy imaging, in order to accurately identify the needle (and remaining surgical instruments) position. Although, needle tracking through ultrasound imaging or external sensors appears as an interesting solution with clear advantages for the patient and the medical team, robust solutions with high accuracy are still a research topic, failing to prove its advantages in the real clinical scenario. Moreover, long learning curves and significant modifications of the traditional clinical procedure are required, hampering its application in the near future. In this sense, the synergy between richly-detailed models and anatomic references obtained from CT/MR data, live anatomic information extracted from US and

accurate catheter tracking obtained from fluoroscopy, appears as a potential optimal strategy to perform TSP, increasing the procedural safety, avoiding procedural complications and removing the need for secondary punctures due to low catheter dexterity. Furthermore, the integrated guidance tool can decrease the interventional time (and thus cost) and radiation dose exposition.

6. Conclusions

An overview of novel techniques recently applied in TSP procedure was presented. TSP is safe and feasible in clinical practice, with complication and failure rate lower than 1% of the total number of interventions. Nonetheless, the traditional procedure uses radiation and it is highly dependent of the physician's experience.

During the last years, the novel RF needles and the recent 3D TEE/ICE imaging guidance approaches showed a notable reduction of procedural time and radiation exposure time. A lower number of procedural complications/failures were also reported even in the presence of complex atrial anatomy, proving the advantages of these novel methodologies. Furthermore, pre-procedural planning based on high-resolution imaging showed potential to predict the feasibility of the TSP procedure and to identify a safe puncture zone that guarantees maximum catheter dexterity throughout the remaining LA intervention. Nevertheless, integrated guidance tools able to fuse pre-procedural with intra-procedural planning still not being described. Moreover, the current needles are only adequate for fluoroscopy guidance, being required several modifications in order to allow/ease intervention guidance without radiation.

Acknowledgments

This work was supported by Fundação para a Ciência e a Tecnologia, in Portugal, and the European Social Found, European Union, for funding support through the Programa Operacional Capital Humano (POCH) in through the first author's PhD grant with reference SFRH/BD/95438/2013. This work was supported by ON.2 SR&TD Integrated Program (NORTE-07-0124-FEDER-000017)" co-funded by Programa Operacional Regional do Norte (ON.2- O Novo Norte), Quadro de Referência Estratégico Nacional (QREN), through Fundo Europeu de Desenvolvimento Regional (FEDER).

Authors gratefully acknowledge the funding of Project NORTE-01-0145-FEDER-000022 - SciTech - Science and Technology for Competitive and Sustainable Industries, cofinanced by "Programa Operacional Regional do Norte" (NORTE2020), through "Fundo Europeu de Desenvolvimento Regional" (FEDER).

References

- [1] Babaliaros, V. C., Green, J. T., Lerakis, S., Lloyd, M., and Block, P. C., 2008, "Emerging Applications for Transseptal Left Heart Catheterization Old Techniques for New Procedures," *Journal of the American College of Cardiology*, 51(22), pp. 2116-2122.
- [2] Matsumoto, T., and Kar, S., 2013, "Latest advances in transseptal structural heart interventions," *Circulation journal: official journal of the Japanese Circulation Society*, 78(8), pp. 1782-1790.
- [3] Earley, M. J., 2009, "How to perform a transseptal puncture," *Heart*, 95(1), pp. 85-92.
- [4] Schwagten, B., Jordaens, L., RIVERO-AYERZA, M., Van Belle, Y., Knops, P., THORNTON, I., and SZILI-TOROK, T., 2010, "A Randomized Comparison of Transseptal and Transaortic Approaches for Magnetically Guided Ablation of Left-Sided Accessory Pathways," *Pacing and Clinical Electrophysiology*, 33(11), pp. 1298-1303.
- [5] Ross, J., 2008, "Transseptal left heart catheterization: a 50-year odyssey," *Journal of the American College of Cardiology*, 51(22), pp. 2107-2115.
- [6] Yao, Y., Ding, L., Chen, W., Guo, J., Bao, J., Shi, R., Huang, W., Zhang, S., and Wong, T., 2013, "The training and learning process of transseptal puncture using a modified technique," *Europace*, p. eut078.
- [7] Hsu, J. C., Badhwar, N., Gerstenfeld, E. P., Lee, R. J., Mandyam, M. C., Dewland, T. A., Imburgia, K. E., Hoffmayer, K. S., Vedantham, V., and Lee, B. K., 2013, "Randomized Trial of Conventional Transseptal Needle Versus Radiofrequency Energy Needle Puncture for Left Atrial Access (the TRAVERSE-LA Study)," *Journal of the American Heart Association*, 2(5), p. e000428.
- [8] Fromentin, S., Sarrazin, J.-F., Champagne, J., Nault, I., Philippon, F., Molin, F., Blier, L., and O'Hara, G., 2011, "Prospective comparison between conventional transseptal puncture and transseptal needle puncture with radiofrequency energy," *Journal of Interventional Cardiac Electrophysiology*, 31(3), pp. 237-242.
- [9] Mitchell-Heggs, L., Lellouche, N., Deal, L., Elbaz, N., Hamdaoui, B., Castanié, J.-B., Dubois-Randé, J.-L., Guéret, P., and Lim, P., 2010, "Transseptal puncture using minimally invasive echocardiography during atrial fibrillation ablation," *Europace*, 12(10), pp. 1435-1438.
- [10] Lakkireddy, D., Rangisetty, U., Prasad, S., Verma, A., Biria, M., Berenbom, L., Pimentel, R., Emert, M., Rosamond, T., and Fahmy, T., 2008, "Intracardiac Echo-Guided Radiofrequency Catheter Ablation of Atrial Fibrillation in Patients with Atrial Septal Defect or Patent Foramen Ovale Repair: A Feasibility, Safety, and Efficacy Study," *Journal of cardiovascular electrophysiology*, 19(11), pp. 1137-1142.
- [11] Lim, H. E., Pak, H.-N., Tse, H.-F., Lau, C.-P., Hwang, C., and Kim, Y.-H., 2009, "Catheter ablation of atrial fibrillation via superior approach in patients with interruption of the inferior vena cava," *Heart Rhythm*, 6(2), pp. 174-179.
- [12] Ho, S. Y., McCarthy, K. P., and Faletra, F. F., 2011, "Anatomy of the left atrium for interventional echocardiography," *European Heart Journal-Cardiovascular Imaging*, 12(10), pp. i11-i15.
- [13] Knecht, S., Wright, M., Lellouche, N., Nault, I., Matsuo, S., O'NEILL, M. D., Lomas, O., Deplagne, A., Bordachar, P., and Sacher, F., 2008, "Impact of a patent foramen ovale on paroxysmal atrial fibrillation ablation," *Journal of cardiovascular electrophysiology*, 19(12), pp. 1236-1241.
- [14] Moher, D., Liberati, A., Tetzlaff, J., Altman, D. G., and Group, P., 2010, "Preferred reporting items for systematic reviews and meta-analyses: the PRISMA statement," *International journal of surgery*, 8(5), pp. 336-341.
- [15] von Alvensleben, J. C., Dick II, M., Bradley, D. J., and LaPage, M. J., 2014, "Transseptal access in pediatric and congenital electrophysiology procedures: defining risk," *Journal of Interventional Cardiac Electrophysiology*, 41(3), pp. 273-277.
- [16] Elayi, C. S., Gurley, J. C., Di Sessa, T. G., and Kakavand, B., 2011, "Surgical electrocautery facilitated transseptal puncture in children," *Pacing and Clinical Electrophysiology*, 34(7), pp. 827-831.
- [17] Clark, J., Bockoven, J., Lane, J., Patel, C., and Smith, G., 2008, "Use of Three-Dimensional Catheter Guidance and Trans-Esophageal Echocardiography to Eliminate Fluoroscopy in Catheter Ablation of Left-Sided Accessory Pathways," *Pacing and Clinical Electrophysiology*, 31(3), pp. 283-289.

- [18] Jauvert, G., Grimard, C., Lazarus, A., and Alonso, C., 2014, "Comparison of a Radiofrequency Powered Flexible Needle with a Classic Rigid Brockenbrough Needle for Transseptal Punctures in Terms of Safety and Efficacy," *Heart, Lung and Circulation*.
- [19] Bayrak, F., Chierchia, G.-B., Namdar, M., Yazaki, Y., Sarkozy, A., de Asmundis, C., Muller-Burri, S. A., Rao, J., Ricciardi, D., and Sorgente, A., 2012, "Added value of transoesophageal echocardiography during transseptal puncture performed by inexperienced operators," *Europace*, 14(5), pp. 661-665.
- [20] Yao, Y., Guo, J., Ding, L., Bao, J., Huang, W., Shi, R., Wu, L., and Zhang, S., 2012, "Improved approach to atrial septum puncture: experience in 539 cases," *Chinese medical journal*, 125(6), pp. 1179-1181.
- [21] Wadehra, V., Buxton, A. E., Antoniadis, A. P., McCreedy, J. W., Redpath, C. J., Segal, O. R., Rowland, E., Lowe, M. D., Lambiase, P. D., and Chow, A. W., 2011, "The use of a novel nitinol guidewire to facilitate transseptal puncture and left atrial catheterization for catheter ablation procedures," *Europace*, p. eur155.
- [22] Wiczorek, M., Hoeltgen, R., Akin, E., and Salili, A. R., 2010, "Use of a novel needle wire in patients undergoing transseptal puncture associated with severe septal tenting," *Journal of Interventional Cardiac Electrophysiology*, 27(1), pp. 9-13.
- [23] Mulder, A. A., Balt, J. C., Wijffels, M. C., Wever, E. F., and Boersma, L. V., 2012, "Safety of pulmonary vein isolation and left atrial complex fractionated atrial electrograms ablation for atrial fibrillation with phased radiofrequency energy and multi-electrode catheters," *Europace*, 14(10), pp. 1433-1440.
- [24] Tang, R.-B., Dong, J.-Z., Long, D.-Y., Yu, R.-H., Liu, X.-P., Cheng, Y.-L., Sang, C.-H., Ning, M., Jiang, C.-X., and Avula, U. M. R., 2014, "Incidence and clinical characteristics of transient ST-T elevation during transseptal catheterization for atrial fibrillation ablation," *Europace*, p. euu278.
- [25] Zellerhoff, S., Daly, M., Lim, H. S., Denis, A., Komatsu, Y., Jesel, L., Derval, N., Sacher, F., Cochet, H., and Knecht, S., 2014, "Pulmonary vein isolation using a circular, open irrigated mapping and ablation catheter (nMARQ): a report on feasibility and efficacy," *Europace*, p. euu133.
- [26] Miyazaki, S., Shah, A. J., Nault, I., Wright, M., Jadidi, A. S., Forclaz, A., Liu, X., Linton, N., Xhaet, O., and Rivard, L., 2011, "Impact of patent foramen ovale on left atrial linear lesions in the context of atrial fibrillation ablation," *Journal of cardiovascular electrophysiology*, 22(8), pp. 846-850.
- [27] Knecht, S., Jaïs, P., Nault, I., Wright, M., Matsuo, S., Madaffari, A., Lellouche, N., O'Neill, M. D., Derval, N., and Deplagne, A., 2008, "Radiofrequency puncture of the fossa ovalis for resistant transseptal access," *Circulation: Arrhythmia and Electrophysiology*, 1(3), pp. 169-174.
- [28] Smelley, M. P., Shah, D. P., Weisberg, I., Kim, S. S., Lin, A. C., Beshai, J. F., Burke, M. C., and Knight, B. P., 2010, "Initial experience using a radiofrequency powered transseptal needle," *Journal of cardiovascular electrophysiology*, 21(4), pp. 423-427.
- [29] Lehrmann, H., Schneider, J., Jadidi, A. S., PARK, C. I., SCHIEBELING-RÖMER, J., Allgeier, J., Arentz, T., and Weber, R., 2014, "Transseptal Access for Left Atrial Ablation: The Catheter-Probing Techniques Are Not Without Risk," *Journal of cardiovascular electrophysiology*, 25(5), pp. 479-484.
- [30] Esch, J. J., Triedman, J. K., Cecchin, F., Alexander, M. E., and Walsh, E. P., 2013, "Radiofrequency-assisted transseptal perforation for electrophysiology procedures in children and adults with repaired congenital heart disease," *Pacing and Clinical Electrophysiology*, 36(5), pp. 607-611.
- [31] Hu, Y.-F., Tai, C.-T., Lin, Y.-J., Chang, S.-L., Lo, L.-W., Wongcharoen, W., Udyavar, A. R., Tuan, T.-C., and Chen, S.-A., 2008, "The change in the fluoroscopy-guided transseptal puncture site and difficult punctures in catheter ablation of recurrent atrial fibrillation," *Europace*, 10(3), pp. 276-279.
- [32] Tomlinson, D. R., Sabharwal, N., Bashir, Y., and Betts, T. R., 2008, "Interatrial septum thickness and difficulty with transseptal puncture during redo catheter ablation of atrial fibrillation," *Pacing and Clinical Electrophysiology*, 31(12), pp. 1606-1611.
- [33] Faletra, F. F., Nucifora, G., and Ho, S. Y., 2011, "Imaging the atrial septum using real-time three-dimensional transesophageal echocardiography: technical tips, normal anatomy, and its role in transseptal puncture," *Journal of the American Society of Echocardiography*, 24(6), pp. 593-599.

- [34] Gafoor, S., Schulz, P., Heuer, L., Matic, P., Franke, J., Bertog, S., Reinartz, M., Vaskelyte, L., Hofmann, I., and Sievert, H., 2015, "Use of EchoNavigator, a Novel Echocardiography-Fluoroscopy Overlay System, for Transseptal Puncture and Left Atrial Appendage Occlusion," *Journal of interventional cardiology*.
- [35] Chierchia, G. B., Capulzini, L., de Asmundis, C., Sarkozy, A., Roos, M., Paparella, G., Boussy, T., Van Camp, G., Kerkhove, D., and Brugada, P., 2008, "First experience with real-time three-dimensional transoesophageal echocardiography-guided transseptal in patients undergoing atrial fibrillation ablation," *Europace*.
- [36] Faletra, F. F., Pedrazzini, G., Pasotti, E., Muzzarelli, S., Dequarti, M. C., Murzilli, R., Schlossbauer, S. A., Slater, I. P., and Moccetti, T., 2014, "3D TEE during catheter-based interventions," *JACC: Cardiovascular Imaging*, 7(3), pp. 292-308.
- [37] Stec, S., Zaborska, B., Sikora-Frać, M., Kryński, T., and Kułakowski, P., 2011, "First experience with microprobe transoesophageal echocardiography in non-sedated adults undergoing atrial fibrillation ablation: feasibility study and comparison with intracardiac echocardiography," *Europace*, 13(1), pp. 51-56.
- [38] Wu, T.-G., Wang, L.-X., Chen, S.-W., Lin, Z.-Q., Yan, C.-J., and Huang, L.-P., 2007, "Value of radiographic esophageal imaging in determining an optimal atrial septal puncture site for percutaneous balloon mitral valvuloplasty," *Medical principles and practice: international journal of the Kuwait University, Health Science Centre*, 17(4), pp. 280-283.
- [39] Ferguson, J. D., Helms, A., Mangrum, J. M., Mahapatra, S., Mason, P., Bilchick, K., McDaniel, G., Wiggins, D., and DiMarco, J. P., 2009, "Catheter ablation of atrial fibrillation without fluoroscopy using intracardiac echocardiography and electroanatomic mapping," *Circulation: Arrhythmia and Electrophysiology*, 2(6), pp. 611-619.
- [40] Liang, K.-W., Fu, Y.-C., Lee, W.-L., Wang, K.-Y., Ting, C.-T., Jan, S.-L., Lin, W.-W., and Lin, I.-H., 2010, "Comparisons of mechanical versus phase-array intracardiac echocardiography-assisted transseptal puncture in patients with dilated left atrium undergoing percutaneous transvenous mitral commissurotomy," *Journal of the Chinese Medical Association*, 73(9), pp. 471-476.
- [41] Ruisi, C. P., Brysiewicz, N., Asnes, J. D., Sugeng, L., Marieb, M., Clancy, J., and Akar, J. G., 2013, "Use of intracardiac echocardiography during atrial fibrillation ablation," *Pacing and Clinical Electrophysiology*, 36(6), pp. 781-788.
- [42] Russo, A. D., Russo, E., Fassini, G., Casella, M., Innocenti, E., Zucchetti, M., Cefalú, C., Solimene, F., Mottola, G., and Colombo, D., 2013, "Role of Intracardiac Echocardiography in Atrial Fibrillation Ablation," *JAFIB: Journal of Atrial Fibrillation*, 5(6).
- [43] Biermann, J., Bode, C., and Asbach, S., 2012, "Intracardiac echocardiography during catheter-based ablation of atrial fibrillation," *Cardiology research and practice*, 2012.
- [44] Elagha, A. A., Kocaturk, O., Guttman, M. A., Ozturk, C., Kim, A. H., Burton, G. W., Kim, J. H., Raman, V. K., Raval, A. N., and Wright, V. J., 2008, "Real-Time MR Imaging-guided Laser Atrial Septal Puncture in Swine," *Journal of Vascular and Interventional Radiology*, 19(9), pp. 1347-1353.
- [45] Thiagalingam, A., D'AVILA, A., Foley, L., Fox, M., Rothe, C., Miller, D., Malchano, Z., Ruskin, J. N., and Reddy, V. Y., 2008, "Full-Color Direct Visualization of the Atrial Septum to Guide Transseptal Puncture," *Journal of cardiovascular electrophysiology*, 19(12), pp. 1310-1315.
- [46] Jeevan, M., Jebaraj, R., and Krishnakumar, R., "In-vitro Validation of Image Guided Surgery System with 3D Pre-Operative Visualization for Atrial Transseptal Puncture," *Proc. 18th International Conference on Information Visualisation (IV)*, 2014, IEEE, pp. 342-345.
- [47] Shepherd, E. J., Gall, S. A., and Furniss, S. S., 2008, "Interatrial septal puncture without the use of fluoroscopy—reducing ionizing radiation in left atrial ablation procedures," *Journal of Interventional Cardiac Electrophysiology*, 22(3), pp. 183-187.
- [48] Nguyen, B., Merino, J., Shachar, Y., Estrada, A., Doiny, D., Castrejon, S., Marx, B., Johnson, D., Marfori, W., and Gang, E. S., 2013, "Non-fluoroscopic transseptal catheterization during electrophysiology procedures using a remote magnetic navigation system," *JAFIB: Journal of Atrial Fibrillation*, 6(4), pp. 6-9.

- [49] Pavlović, N., Reichlin, T., Kühne, M., Knecht, S., Osswald, S., and Sticherling, C., 2014, "Fluoroscopy-free recrossing of the interatrial septum during left atrial ablation procedures," *Journal of Interventional Cardiac Electrophysiology*, 41(3), pp. 261-266.
- [50] Unnithan, A. G., Dexter, B. C., Law, I. H., and Von Bergen, N. H., 2014, "Limiting left-sided catheter dwelling time using 3-D NavX to mark and reaccess the left atrium via prior transseptal puncture site," *Journal of Interventional Cardiac Electrophysiology*, 40(2), pp. 125-128.
- [51] Mah, D. Y., Miyake, C. Y., Sherwin, E. D., Walsh, A., Anderson, M. J., Western, K., Abrams, D. J., Alexander, M. E., Cecchin, F., and Walsh, E. P., 2014, "The use of an integrated electroanatomic mapping system and intracardiac echocardiography to reduce radiation exposure in children and young adults undergoing ablation of supraventricular tachycardia," *Europace*, 16(2), pp. 277-283.
- [52] Saliba, W., Reddy, V. Y., Wazni, O., Cummings, J. E., Burkhardt, J. D., Haissaguerre, M., Kautzner, J., Peichl, P., Neuzil, P., and Schibgilla, V., 2008, "Atrial fibrillation ablation using a robotic catheter remote control system: initial human experience and long-term follow-up results," *Journal of the American College of Cardiology*, 51(25), pp. 2407-2411.
- [53] Wagdi, P., and Alkadhi, H., 2012, "Can computer tomography help predict feasibility of transseptal puncture after percutaneous closure of an interatrial septal communication?," *Journal of Interventional Cardiac Electrophysiology*, 34(2), pp. 167-172.
- [54] Verma, S., Adler, S., Berman, A., Duran, A., and Loar, D., 2011, "Localization of fossa ovalis and Brockenbrough needle prior to left atrial ablation using three-dimensional mapping with EnSite Fusion™," *Journal of Interventional Cardiac Electrophysiology*, 30(1), pp. 37-44.
- [55] Scherthaner, C., Danmayr, F., Daburger, A., Eichinger, J., Hammerer, M., and Strohmer, B., 2013, "High incidence of echocardiographic abnormalities of the interatrial septum in patients undergoing ablation for atrial fibrillation," *Echocardiography*, 30(4), pp. 402-406.
- [56] Jayender, J., Patel, R. V., Michaud, G. F., and Hata, N., 2011, "Optimal transseptal puncture location for robot-assisted left atrial catheter ablation," *The International Journal of Medical Robotics and Computer Assisted Surgery*, 7(2), pp. 193-201.
- [57] Crystal, M. A., Mirza, M. A., and Benson, L. N., 2010, "A radiofrequency transseptal needle: initial animal studies," *Catheterization and Cardiovascular Interventions*, 76(5), pp. 769-773.
- [58] Feld, G. K., Tiongson, J., and Oshodi, G., 2011, "Particle formation and risk of embolization during transseptal catheterization: comparison of standard transseptal needles and a new radiofrequency transseptal needle," *Journal of Interventional Cardiac Electrophysiology*, 30(1), pp. 31-36.
- [59] Winkle, R. A., Mead, R. H., Engel, G., and Patrawala, R. A., 2011, "The use of a radiofrequency needle improves the safety and efficacy of transseptal puncture for atrial fibrillation ablation," *Heart Rhythm*, 8(9), pp. 1411-1415.
- [60] Karagöz, T., Akin, A., and Aykan, H. H., 2014, "NRGTM RF powered transseptal needle: a useful technique for transcatheter atrial septostomy and Fontan fenestration: report of three cases," *Bosnian Journal of Basic Medical Sciences*, 14(4), pp. 259-262.
- [61] McWILLIAMS, M. J., and Tchou, P., 2009, "The use of a standard radiofrequency energy delivery system to facilitate transseptal puncture," *Journal of cardiovascular electrophysiology*, 20(2), pp. 238-240.
- [62] Capulzini, L., Paparella, G., Sorgente, A., de Asmundis, C., Chierchia, G. B., Sarkozy, A., Muller-Burri, A., Yazaki, Y., Roos, M., and Brugada, P., 2010, "Feasibility, safety, and outcome of a challenging transseptal puncture facilitated by radiofrequency energy delivery: a prospective single-centre study," *Europace*, 12(5), pp. 662-667.
- [63] Abed, H. S., Alasady, M., Lau, D. H., Lim, H. S., and Sanders, P., 2012, "Approach to the difficult transseptal: diathermy facilitated left atrial access," *Heart, Lung and Circulation*, 21(2), pp. 108-112.
- [64] Greenstein, E., Passman, R., Lin, A. C., and Knight, B. P., 2012, "Incidence of tissue coring during transseptal catheterization when using electrocautery and a standard transseptal needle," *Circulation: Arrhythmia and Electrophysiology*, 5(2), pp. 341-344.
- [65] Uchida, B. T., Pavcnik, D., Shimohira, M., Choi, Y. H., Jeromel, M., Keller, F. S., and Rösch, J., 2011, "New coaxial transseptal needle for creation of atrial septal defects in adult sheep," *Cardiovascular and interventional radiology*, 34(3), pp. 620-625.

- [66] Wang, Y., Xue, Y. M., Mohanty, P., Natale, A., Li, L., Wu, W. F., Zhu, C. M., Liu, H., Zhong, G. Q., and Zhu, L. G., 2012, "Dilator method and needle method for atrial transseptal puncture: a retrospective study from a cohort of 4443 patients," *Europace*, 14(10), pp. 1450-1456.
- [67] Giudici, M. C., Mickelsen, S. R., Bhave, P. D., Arteaga, R. B., and Iqbal, O. J., 2015, "A Safe, Simple Technique for Transseptal Catheterization," *Pacing and Clinical Electrophysiology*.
- [68] Katritsis, G. D., Siontis, G. C., Giazitzoglou, E., Fragakis, N., and Katritsis, D. G., 2013, "Complications of transseptal catheterization for different cardiac procedures," *International journal of cardiology*, 168(6), pp. 5352-5354.
- [69] Koermendy, D., Nietlispach, F., Shakir, S., Gloekler, S., Wenaweser, P., Windecker, S., Khattab, A. A., and Meier, B., 2014, "Amplatzer left atrial appendage occlusion through a patent foramen ovale," *Catheterization and Cardiovascular Interventions*, 84(7), pp. 1190-1196.
- [70] Chierchia, G.-B., Casado-Arroyo, R., de Asmundis, C., Rodriguez-Manero, M., Sarkozy, A., Conte, G., Sieira, J., Levinstein, M., Baltogiannis, G., and Di Giovanni, G., 2013, "Impact of transseptal puncture site on acute and mid-term outcomes during cryoballoon ablation: A comparison between anterior, medial and posterior transatrial access," *International journal of cardiology*, 168(4), pp. 4098-4102.
- [71] Haegeli, L. M., Wolber, T., Ercin, E., Altwegg, L., Krasniqi, N., Novak, P. G., Sterns, L. D., Brunckhorst, C. B., Lüscher, T. F., and Leather, R. A., 2010, "Double transseptal puncture for catheter ablation of atrial fibrillation: safety of the technique and its use in the outpatient setting," *Cardiology research and practice*, 2010.
- [72] Medi, C., Evered, L., Silbert, B., Teh, A., Halloran, K., Morton, J., Kistler, P., and Kalman, J., 2013, "Subtle post-procedural cognitive dysfunction after atrial fibrillation ablation," *Journal of the American College of Cardiology*, 62(6), pp. 531-539.
- [73] Feld, G. K., and Yao, B., 2014, "Evaluation of the safety and effectiveness of the CryoMedix cryoablation catheter system for the treatment of atrial flutter and fibrillation," *Journal of Interventional Cardiac Electrophysiology*, 39(1), pp. 37-44.
- [74] De Ponti, R., Marazzi, R., Picciolo, G., and Salerno-Uriarte, J. A., 2010, "Use of a novel sharp-tip, J-shaped guidewire to facilitate transseptal catheterization," *Europace*, 12(5), pp. 668-673.
- [75] Krijthe, B. P., Kunst, A., Benjamin, E. J., Lip, G. Y., Franco, O. H., Hofman, A., Wittteman, J. C., Stricker, B. H., and Heeringa, J., 2013, "Projections on the number of individuals with atrial fibrillation in the European Union, from 2000 to 2060," *European heart journal*, 34(35), pp. 2746-2751.
- [76] Taramasso, M., Maisano, F., Latib, A., Denti, P., Guidotti, A., Sticchi, A., Panoulas, V., Giustino, G., Pozzoli, A., and Buzzatti, N., 2014, "Conventional surgery and transcatheter closure via surgical transapical approach for paravalvular leak repair in high-risk patients: results from a single-centre experience," *European Heart Journal—Cardiovascular Imaging*, p. jcu105.
- [77] Baldus, S., Schillinger, W., Franzen, O., Bekeredjian, R., Sievert, H., Schofer, J., Kuck, K. H., Konorza, T., Möllmann, H., and Hehrlein, C., 2012, "MitraClip therapy in daily clinical practice: initial results from the German transcatheter mitral valve interventions (TRAMI) registry," *European journal of heart failure*, 14(9), pp. 1050-1055.
- [78] Reddy, V. Y., Holmes, D., Doshi, S. K., Neuzil, P., and Kar, S., 2011, "Safety of percutaneous left atrial appendage closure results from the watchman left atrial appendage system for embolic protection in patients with AF (PROTECT AF) clinical trial and the continued access registry," *Circulation*, 123(4), pp. 417-424.
- [79] Rana, B. S., Shapiro, L. M., McCarthy, K. P., and Ho, S. Y., 2010, "Three-dimensional imaging of the atrial septum and patent foramen ovale anatomy: defining the morphological phenotypes of patent foramen ovale," *European Journal of Echocardiography*, 11(10), pp. i19-i25.
- [80] Gard, J., Swale, M., and Asirvatham, S., 2011, "Transseptal access for the electrophysiologists: anatomic considerations to enhance safety and efficacy," *J Innov Cardiac Rhythm Manage*, 2, pp. 332-338.
- [81] Kautzner, J., and Peichl, P., 2012, "The role of imaging to support catheter ablation of atrial fibrillation," *Cor et Vasa*, 54(6), pp. e375-e385.

[82] Sy, R. W., Klein, G. J., LEONG-SIT, P., Gula, L. J., Yee, R., Krahn, A. D., and Skanes, A. C., 2011, "Troubleshooting difficult transseptal catheterization," *Journal of cardiovascular electrophysiology*, 22(6), pp. 723-727.

[83] Tzeis, S., Andrikopoulos, G., Deisenhofer, I., Ho, S. Y., and Theodorakis, G., 2010, "Transseptal catheterization: considerations and caveats," *Pacing and Clinical Electrophysiology*, 33(2), pp. 231-242.

List of Abbreviations

BRK – Brockenbrough

CS – Coronary sinus

CT – Computed Tomography

CTS - Coaxial transseptal

EAM – Electroanatomic mapping

FO – Fossa ovalis

IAS - interatrial septum

ICE – Intracardiac echocardiography

LA – Left atrium

LV – Left Ventricle

MR – Magnetic Resonance

MV – Mitral Valve

RA – Right atria

RF - Radio-frequency

SVC – Superior Vena Cava

TEE – Transesophageal echocardiography

TSP – Transseptal puncture

Table 1 – Application rate of different percutaneous procedures that require TSP technique.

Procedure	Application rate
Catheter ablation for atrial fibrillation	In 2010, 8.8 million of patients had atrial fibrillation in the Europe Union. A projection study estimated a total of 17.9 million of patients at 2060 [75].
Paravalvular leakage repair	Affects 5%-17% of all implanted prosthetic heart valves [76].
Percutaneous mitral valve replacement	Mitral valve diseases present an estimated prevalence of 7% in subjects ≥ 75 years old [77].
Left atrial appendage closure	Left atrial appendage is the primary source of the thromboemboli causing stroke in nonvalvular atrial fibrillation patients [78].

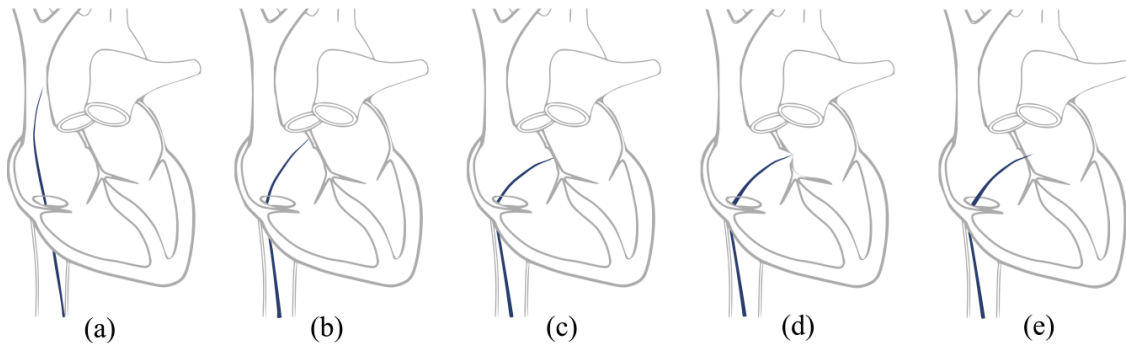


Fig. 1 - Transseptal puncture traditional technique. (a) A catheter (blue) is placed into the SVC; the catheter is pull-down and two movements are detected, namely: (b) entrance into the RA and (c) entrance into FO, (d) after the FO identification, (e) the puncture is performed.

Table 2 – Overview of the main anatomic variations of the atria.

Anatomic variations	Description	Difficulties	Solution
Patent foramen ovale (PFO)	<ul style="list-style-type: none"> - Direct route between the RA and the LA (prevalence of 27% of the population) [79]. - LA access without any puncture [79]. 	Since the PFO is located at the anterior and superior part of the IAS, access to the pulmonary veins are hampered [13, 79].	TSP procedure should be used, even in the presence of PFO [13].
Left atrium dilation	<ul style="list-style-type: none"> - LA dilation results in a posterior position of the FO [80]. 	Higher risk of puncture an adjacent structure [80].	Different TSP position should be used [80].
Abnormal mechanical properties of the IAS	<ul style="list-style-type: none"> - Heart diseases can result in aneurysmal, elastic or thickened IAS wall [8]. - Patients with previous TSP procedure, present a thickened IAS wall [7]. 	TSP procedure can result in serious complications for the patient, such as, atrial roof puncture or aortic route puncture. Furthermore, TSP procedure can fail [8].	Application of radio-frequency (RF) needles [8].
Abnormal position of the FO	<ul style="list-style-type: none"> - Superior position of the FO is detected [12]. 	Superior LA access reduces the maneuverability of catheters in pulmonary veins and mitral valve procedures [12].	Puncture the inferior part of the FO [12].

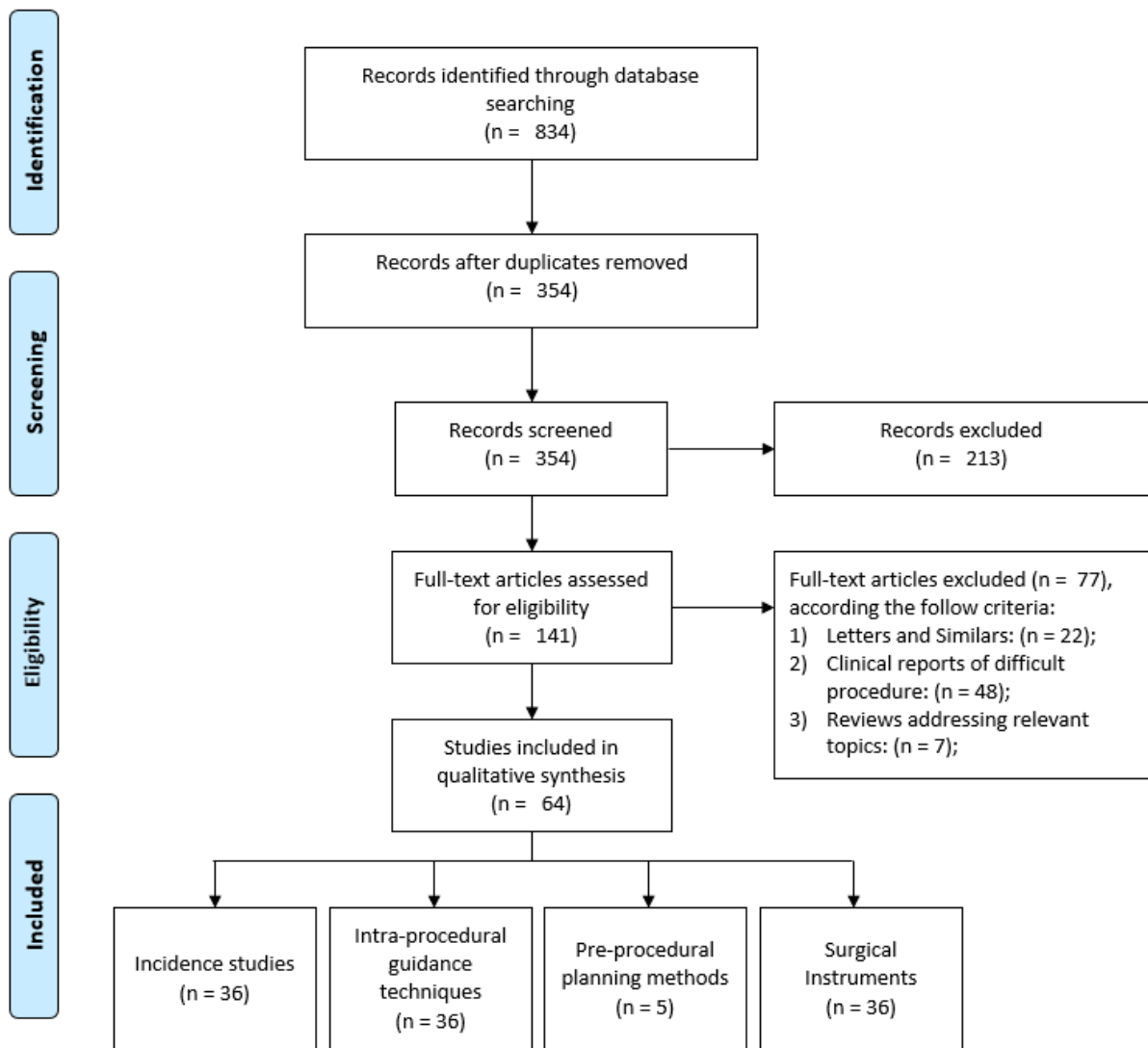


Fig. 2 - Overview of the methodology used to select the relevant articles for the current review. The identification of the relevant works was performed using Prisma Statement [13].

Table 3 – Topics addressed in different reviews published between 2008 and 2015.

Year	Authors	Aims
2014	Matsumoto <i>et al.</i> [2]	Recent advances in transseptal left heart interventions.
2012	Kautzner <i>et al.</i> [81]	Review of imaging techniques used in LA procedures.
2011	Sy <i>et al.</i> [82]	Overview of difficulties and possible solutions throughout TSP procedure.
2010	Tzeis <i>et al.</i> [83]	Exhaustive review of TSP procedure and overview of tips and caveats with relevant value for safe TSP.
2009	Earley <i>et al.</i> [3]	Review of TSP procedure complications and possible solutions.
2008	Babaliaros <i>et al.</i> [1]	Review of novel techniques used in TSP intervention and emerging indications of this intervention.
2008	Ross <i>et al.</i> [5]	Overview of transseptal left heart catheterization procedures.

Table 4 – Number of TSP, percentage of repeated procedure, failures and complications reported between 2008 and 2015.

Year	Authors	Number of TSP	Repeated puncture	Failure	Complications
2015	Jauvert <i>et al.</i> [18]	225	5.78%	5	3
2014	Alvensleben <i>et al.</i> [15]	365	-	0	8
2014	Koermendy <i>et al.</i> [69]	147	-	4	20
2014	Lehrmann <i>et al.</i> [29]	678	-	0	0
2014	Tang <i>et al.</i> [24]	3452	-	0	10
2014	Unnithan <i>et al.</i> [50]	54	-	0	1
2014	Zellerhoff <i>et al.</i> [25]	39	-	0	1
2013	Chierchia <i>et al.</i> [70]	103	-	0	9
2013	Esch <i>et al.</i> [30]	10	-	1	0
2013	Hsu <i>et al.</i> [7]	72	-	10	2
2013	Katritsis <i>et al.</i> [68]	393	-	0	5
2013	Yao <i>et al.</i> [6]	120	14.17%	5	0
2012	Bayrak <i>et al.</i> [19]	205	46.34%	1	3
2012	Wang <i>et al.</i> [66]	4443	-	0	27
2012	Yao <i>et al.</i> [20]	539	1.11%	0	0
2011	Abed <i>et al.</i> [63]	543	1.84%	10	10
2011	Fromentin <i>et al.</i> [8]	241	-	0	2
2011	Miyazaki <i>et al.</i> [26]	114	-	-	1
2011	Wadehra <i>et al.</i> [21]	210	18.57%	5	0
2011	Winkle <i>et al.</i> [59]	1550	-	13	9
2011	Elayi <i>et al.</i> [16]	13	15.38%	0	0
2010	Capulzini <i>et al.</i> [62]	162	11.73%	18	0
2010	Haegeli <i>et al.</i> [71]	269	-	0	8
2010	Mitchell-Heggs <i>et al.</i> [9]	79	-	0	9
2010	Schwagten <i>et al.</i> [4]	11	-	1	0
2010	Smelley <i>et al.</i> [28]	41	31.70%	1	2
2010	Wieczorek <i>et al.</i> [22]	158	4.44%	0	0
2009	Ferguson <i>et al.</i> [39]	21	-	0	0
2008	Chierchia <i>et al.</i> [35]	24	0%	0	0
2008	Clark <i>et al.</i> [17]	10	-	0	0
2008	Hu <i>et al.</i> [31]	29	-	0	0
2008	Knecht <i>et al.</i> [27]	269	4.47%	0	0
2008	Knecht <i>et al.</i> [13]	154	-	0	0
2008	Lakkireddy <i>et al.</i> [10]	90	-	1	4
2008	Saliba <i>et al.</i> [52]	40	-	2	1
2008	Wu <i>et al.</i> [38]	468	27.1	0	1
2008	Tomlinson <i>et al.</i> [32]	42	-	0	4
Mean (%):			12.07%	0.51	0.88

Table 5 – Novel intra-procedural guidance techniques applied in TSP procedures between 2008 and 2015.

		Year	Authors	Aims	Guidance technique	Validation	Conclusion
Purely image-based	Ultrasound Image	2015	Gafoor <i>et al.</i> [34]	Use of EchoNavigator in TSP.	TEE with fluoroscopy.	-	This image fusion strategy eased the identification of the relevant anatomical structures and showed potential for TSP.
		2014	Faletta <i>et al.</i> [36]	Application of 3D TEE in TSP.	3D TEE	-	3D TEE eases TSP when compared with remaining guidance approach, such as 2D TEE or fluoroscopy.
		2013	Ruisi <i>et al.</i> [41]	Application of ICE in TSP procedure	ICE	-	ICE allows an accurate visualization of RA anatomy and can be used to guide TSP.
		2013	Russo <i>et al.</i> [42]	Application of ICE in TSP procedure	ICE	-	ICE contributes to improve the efficacy of TSP procedure.
		2012	Bayrak <i>et al.</i> [19]	Application of 2D TEE in TSP.	TEE and fluoroscopy.	105 patients	TEE proved to be useful to guide TSP performed by inexperienced operators.
		2012	Biermann <i>et al.</i> [43]	Application of ICE in TSP.	ICE	-	ICE contributed to improve the efficacy of TSP procedure.
		2011	Faletta <i>et al.</i> [33]	Advantages of 3D-TEE in TSP.	3D TEE.	-	3D TEE allows simple FO identification.
		2011	Stec <i>et al.</i> [37]	Application of micro-TEE in TSP.	Micro-TEE probe	12 patients	Micro-TEE can guide TSP in non-sedated patients.
		2010	Liang <i>et al.</i> [40]	Comparison between mechanical versus phase-array ICE in TSP.	ICE.	6 patients	Mechanical ICE has a better image of the FO, being therefore more adequate to perform TSP.
		2010	Mitchell-Heggs <i>et al.</i> [9]	Advantages of ICE-TEE in TSP.	ICE via esophageal route	79 patients	This technique is safe for TSP and is done without sedation.
		2009	Ferguson <i>et al.</i> [39]	Application of ICE to perform TSP.	ICE.	21 patients	Succeed TSP was achieved using ICE guidance technique.
		2008	Chierchia <i>et al.</i> [35]	Application of 3D-TEE in TSP	3D TEE	24 patients	TEE facilitated TSP, and lower procedural time was reported.
		2008	Wu <i>et al.</i> [38]	Application of TEE in TSP.	TEE.	468 patients	TEE eased the identification of optimal puncture position.
		Other modalities	2013	Yao <i>et al.</i> [6]	Validation of a new TSP procedure.	Fluoroscopy.	120 patients
2008	Elagha <i>et al.</i> [44]		Application of real-time MRI in TSP.	Real-time MRI.	7 animals	MRI-guided can be used to perform safe TSP procedure.	
2008	Thiagalingam <i>et al.</i> [45]		Full color visualization of FO.	Fiber optic with fluoroscopy.	6 swine	Direct full color visualization can be used to identify FO.	
Electroanatomic mapping (EAM)	2014	Mah <i>et al.</i> [51]	EAM with ICE to ease TSP.	EAM with ICE	25 patients	The system reduced the radiation exposure and time.	
	2014	Pavlović <i>et al.</i> [49]	Simple reaccess of FO without radiation.	EAM (Carto 3).	25 patients	A radiation-free recrossing of the IAS wall was achieved.	
	2014	Unnithan <i>et al.</i> [50]	Simple reaccess of FO without radiation.	EAM (3D NavX).	54 patients	The method reduced the time that catheter dwells in LA.	
	2013	Nguyen <i>et al.</i> [48]	Strategy to manual or automatic reaccess of FO without radiation.	EAM (Ensite/NavX).	5 patients	Manual and automatic reaccess of the LA is viable and fast. Moreover, radiation exposure was removed.	
	2008	Clark <i>et al.</i> [17]	EAM combined with TEE in TSP can be used to perform TSP	EAM with TEE	10 patients	The proposed method can be used to eliminate the fluoroscopy used throughout TSP procedure.	
	2008	Saliba <i>et al.</i> [52]	Combination of EAM-ICE in TSP.	EAM and ICE.	40 patients	This system ensured safe TSP procedure.	
	2008	Shepherd <i>et al.</i> [47]	Application of EAM in TSP.	EAM (EnSite NavX).	-	EAM can reduce the fluoroscopy time requires in TSP.	
Other	2014	Jeevan <i>et al.</i> [46]	Validation of a new guided method for radiation-free TSP.	Electromagnetic sensor with MRI.	1 phantom	This system reduced the procedure time, had no learning curve and can reduce the number of complications.	

FO – Fossa Ovalis, IAS – Interatrial septum ICE – Intracardiac echocardiography, LA – Left atrium, MRI – Magnetic Resonance Imaging, TEE - transesophageal echocardiography, TSP – Transseptal puncture.

Table 6 – Pre-procedural planning methods applied in TSP procedures between 2008 and 2015.

	Year	Authors	Aims	Planning method	Validation	Conclusion
Richly detailed images	2013	Schernthaner <i>et al.</i> [55]	Preprocedural TEE can be used to identify abnormal atria anatomy	TEE	100 patients	Pre-planning TEE provided accurate information of patient-specific anatomy, which increases the efficacy and safety of TSP procedure. CT can be used to predict feasibility of TSP procedure. Moreover, CT image can be used to identify a safe puncture region. A safe puncture position, that ensures maximum dexterity of catheter, was achieved.
	2012	Wagdi <i>et al.</i> [53]	Identification of a “safe zone” to perform TSP.	CT.	20 patients	
	2011	Jayender <i>et al.</i> [56]	Identification of optimal puncture position.	MR/CT.	One dataset	
Ultrasound images	2011	Verma <i>et al.</i> [54]	Identification of FO region in CT.	CT.	49 patients	It was possible to detect FO in CT. Confirmation of the FO position was performed using intra-procedural EAM.
	2008	Tomlinson <i>et al.</i> [32]	FO thickness is a predictor of difficult TSP procedure.	TEE.	42 patients	No relation was found between difficult TSP procedure and FO thickness. The only valid predictor was the presence of diabetes.

CT – Computed Tomography, EAM – Electroanatomic mapping, FO – Fossa Ovalis, MR – Magnetic Resonance, TEE - transesophageal echocardiography, TSP – Transseptal puncture.

Table 7 - Surgical instruments used in various TSP works between 2008 and April of 2015.

	Year	Authors	Aims	Instruments/Methods	Validation	Conclusion		
Needles	Radio-frequency (RF)	2015	Jauvert <i>et al.</i> [18]	Evaluate the safety of a new RF powered flexible needle.	RF powered flexible needle and BRK needle.	125 patients	Flexible needle was safer and more efficient than BRK needle.	
		2014	Karagöz <i>et al.</i> [60]	Advantages of NRG needle.	NRG and BRK needle.	3 patients	NRG needle eased the TSP procedure in patients with pulmonary hypertension.	
		2013	Esch <i>et al.</i> [30]	Application of RF needle in patients with congenital heart disease.	NRG and BRK needle.	10 patients	NRG needle can be used to LA access in patients with congenital heart disease, even when BRK needle failed.	
		2013	Hsu <i>et al.</i> [7]	Comparison of NRG and BRK needle.	NRG and BRK needle.	72 patients	NRG needle allowed shorter procedure time and lower failure rate.	
		2011	Feld <i>et al.</i> [58]	Comparison of NRG and BRK needle.	NRG RF and BRK needle.	In vitro	NRG needle appears to be safer than traditional needle, presenting a more adequate needle shape that reduce the risk of embolization.	
		2011	Fromentin <i>et al.</i> [8]	Comparison of NRG and BRK needle.	NRG RF and BRK needle.	241 patients	NRG needle showed superior performance than BRK, reducing the procedural time and the number of complications.	
		2011	Winkle <i>et al.</i> [59]	Comparison of NRG and BRK needle.	NRG RF and BRK needle.	1167 patients	NRG needle showed superior performance than BRK, with reduced procedural time and greater efficacy during the puncture.	
		2010	Crystal <i>et al.</i> [57]	Validation of NRG needle.	NRG needle	Animal model	RF needle eased TSP procedure, presenting newer devices and shapes to improve the LA access technique.	
		2010	Smelley <i>et al.</i> [28]	Validation of NRG needle.	NRG needle.	41 patients	NRG needle was safe with low failure rate.	
		Needles	Electrocautery	2012	Greenstein <i>et al.</i> [64]	Difference of tissue coring between electrocautery and traditional TSP.	Electrocautery and traditional TSP.	Swine hearts
2011	Abed <i>et al.</i> [63]			Comparison between electrocautery techniques and traditional one.	Electrocautery technique and BRK needle.	10 patients	Electrocautery method was safe and cost-effective when compared with traditional one.	
2010	Capulzini <i>et al.</i> [62]			Comparison of electrocautery technique and traditional needle.	Electrocautery technique and BRK needle.	162 patients	Electrocautery method is a safe and reproducible technique, being useful in patients with abnormal anatomy.	
2009	McWilliams <i>et al.</i> [61]			Comparison of electrocautery technique and traditional needle.	Electrocautery technique and BRK needle.	350 procedures	The electrocautery technique showed potential to facilitate TSP.	
2008	Knecht <i>et al.</i> [27]			Application of electrocautery needle technique in TSP.	Electrocautery needle technique	269 procedures	Electrocautery provided simple and safe LA access, even in situations where BRK needle failed.	
Needles	Other	2011	Uchida <i>et al.</i> [65]	Validation of a novel CTS needle.	CTS needle	Animal model	CTS needle performed safe TSP in animal model, even in difficult situations.	
Other instruments	Guidewire	2015	Giudici <i>et al.</i> [67]	Experience with nitinol guidewire.	Nitinol guidewire.	100 patients	This method is simple, inexpensive, quick and safe.	
		2011	Wadehra <i>et al.</i> [21]	Assess safety and efficacy of a novel puncture method.	Nitinol guidewire and BRK needle.	210 patients	The new method showed high success rate, presenting potential to overcome puncture failures caused by unusual/distorted anatomy.	
		2010	Ponti <i>et al.</i> [74]	Comparison of a novel transseptal guidewire and traditional method.	Nitinol guidewire.	19 patients	The novel guidewire eased TSP procedure in 23% of the patients.	
		2010	Wieczorek <i>et al.</i> [22]	Validation of a novel nitinol guidewire in TSP procedure.	Nitinol guidewire and BRK needle.	158 patients	Nitinol guidewire appears to be safe and effective in a subset of patients at higher risk for complications.	
	Other instruments	Other	2012	Wang <i>et al.</i> [66]	Comparison of dilator method with the traditional puncture strategy.	New dilator method and traditional TSP.	2292 patients	The new dilator technique was safer than the traditional one, but required longer procedure time.
			2008	Saliba <i>et al.</i> [52]	Robotic remote steerable sheath system to perform TSP puncture.	Robotic remote navigation system	40 patients	This new robotic system was safe with similar results when compared with the conventional approach.

BRK – Brockenbrough (mechanical needle), CTS – Coaxial transseptal needle, NRG – RF needle designed by (Baylis medical), TSP – Transseptal puncture.