

PDF hosted at the Radboud Repository of the Radboud University Nijmegen

The following full text is a publisher's version.

For additional information about this publication click this link.

<http://hdl.handle.net/2066/24541>

Please be advised that this information was generated on 2022-08-23 and may be subject to change.

*Original Article***Nucleosomes and histones are present in glomerular deposits in human lupus nephritis**

M. C. J. van Bruggen¹, C. Kramers¹, B. Walgreen¹, J. D. Elema², C. G. M. Kallenberg³, J. van den Born¹, R. J. T. Smeenk⁴, K. J. M. Assmann⁵, S. Muller⁶, M. Monestier⁷ and J. H. M. Berden¹

¹Division of Nephrology, ⁵Department of Pathology, University Hospital Nijmegen; Departments of ²Pathology and ³Clinical Immunology, University Hospital Groningen; ⁴Department of Autoimmune Diseases, CLB, Amsterdam, the Netherlands; ⁶Institut de Biologie Moléculaire et Cellulaire, CNRS, Strasbourg, France; ⁷Dept. of Microbiology and Immunology, Temple University School of Medicine, Philadelphia, PA, USA

Abstract

Background. Recently we showed that antinuclear autoantibodies complexed to nucleosomes can bind to heparan sulphate (HS) in the glomerular basement membrane (GBM) via the histone part of the nucleosome. Histones have been identified in glomerular deposits in human and murine lupus nephritis. In addition, a decreased HS staining in the GBM was found, most probably due to masking by deposition of antibodies complexed to nucleosomes.

Methods. In this study we first investigated whether histones or nucleosomes could be identified in glomerular deposits in human lupus nephritis, and secondly whether the presence of these nuclear components was correlated with absence of HS staining. Kidney biopsies of SLE patients (11 with diffuse proliferative glomerulonephritis (DPGN) and six with membranous glomerulonephritis (MGN)) and of non-SLE glomerular diseases were stained for histones, DNA, nucleosomes, IgG and HS.

Results. Using a polyclonal anti-H3 1–21 antiserum, histones were detected in all patients with DPGN and in two of six patients with SLE-MGN ($P < 0.01$). Using a monoclonal antihistone antibody, histones were stained in three patients with DPGN, but in none of the biopsies with MGN. Using nucleosome specific monoclonal antibodies, nucleosomes were detected in five patients with DPGN, in two patients with MGN, but in none of the biopsies with non-SLE glomerulonephritis. HS staining was nearly absent in DPGN, whereas staining was only moderately reduced in patients with MGN and controls ($P = 0.001$).

Conclusion. Using polyclonal and monoclonal antihistone antisera, histones were identified in all patients with DPGN and their presence was associated with a decrease of HS staining. Nucleosomes were identified

in five of 11 patients with DPGN and in two of six patients with MGN. This is the first demonstration of nucleosomes in glomerular deposits in SLE nephritis.

Key words: DNA; histones; lupus; nucleosomes; SLE

Introduction

In systemic lupus erythematosus (SLE) about 50% of patients develop renal disease [1]. Antinuclear antibodies and more specifically anti-dsDNA antibodies are regarded as a hallmark of the disease [2]. Since a rise in titre of anti-dsDNA antibodies often precedes a renal exacerbation [3–5] and renal eluates of patients with lupus nephritis are enriched for anti-dsDNA antibodies [6,7], these antibodies are thought to play a pathogenic role in the initiation of the glomerular disease. Some years ago we showed that certain anti-dsDNA antibodies are able to bind to heparan sulphate (HS), an intrinsic constituent of the glomerular basement membrane (GBM). [8]. In subsequent experiments we showed that this HS cross-reactivity was a property of antibodies complexed to nucleosomal antigens (i.e. DNA and histones) [9] and that antinucleosome antibodies complexed to nucleosomal antigens were able to bind to HS in the GBM, whereas pure antibodies did not bind [10].

In the meantime it was reported that histones are present in immune deposits of both human [11] and murine [12] lupus nephritis, whereas in murine lupus an association between histone deposits and albuminuria was found [12].

Recently we found that in the majority of patients with lupus nephritis HS staining was absent, whereas staining for the heparan sulphate proteoglycan (HSPG) core protein was intact [13]. In subsequent studies in MRL/l mice we found that HS staining disappeared in albuminuric mice, and that there was

Correspondence and offprint requests to: M. C. J. van Bruggen, Division of Nephrology, University Hospital, St Radboud, P O Box 9101, 6500 HB Nijmegen, The Netherlands.

an inverse correlation between HS staining and albuminuria as well as between HS staining and GBM Ig deposits. Since glomerular HS content was not decreased in mice in which GBM-HS staining was absent, we suggested that HS was masked by nucleosome containing immune complexes [14]. Although other investigators showed histones [11,12] or DNA [15] in glomerular deposits in lupus nephritis, nucleosomes were never identified.

In the present study we first tested whether nucleosomes were present in the glomerular immune deposits in human lupus nephritis and secondly whether presence of histones or nucleosomes correlated with loss of GBM-HS staining. Since we investigated the interaction between immune deposits and HS in the GBM, SLE patients with diffuse proliferative (DPGN) and membranous glomerulonephritis (MGN) were selected.

Subjects and methods

Renal biopsies

Renal biopsies of 11 SLE patients with DPGN and of six SLE patients with MGN were selected (Table 1). All patients fulfilled at least four ARA criteria for SLE. From all renal biopsies 2-mm cryostat sections were cut. As controls renal biopsies of four patients with non-SLE mesangiocapillary glomerulonephritis and of five patients with non-SLE MGN were evaluated.

Immunohistology

All sections were stained in direct immunofluorescence (IF) for IgG deposits and in indirect IF for HS, HSPG core protein, histones, DNA, and nucleosomes. The characteristics of the antisera used are given in Table 2. After the staining procedure, the sections were embedded in Aquamount (BDH Ltd. Poole, UK) and examined with a Zeiss fluorescence microscope.

Human IgG

Deposits of human IgG were studied by incubating sections with FITC-labelled F(ab)₂ rabbit anti-human IgG (CLB, Amsterdam, the Netherlands) 5 mg/ml diluted 1:400 in PBS containing 1% (wt/vol) BSA (PBS/BSA) for 30 min at room temperature.

HS and HSPG core protein

HS was stained by incubating the sections with a mouse anti-rat HS monoclonal antibody (mAb, JM 403) that only recognizes HS in basement membranes and cross-reacts with human HS [16] (Table 2). HSPG core protein was stained by incubating with a mouse monoclonal anti-human HSPG-core protein (JM-72, [16], Table 2). HS and HSPG-core protein were stained simultaneously on the same slide using double-staining as described before [16].

Histones

Histones were stained by incubating the sections with a polyclonal rabbit antiserum raised against the N-terminal 1–21 peptide of histone H3 [17] and with mAb KM2 against histones derived from a lupus prone mouse (Table 2). MAb KM2 is directed against H2A and H4. It reacts equally well with the N-terminal peptides 1–20 of H2A and 1–29 of H4 which have a large sequence homology. The IF using the polyclonal rabbit antiserum was performed as described before [11,12]. The IF using the mAb was performed by incubating the sections with mAb KM2 (10 mg/ml) in PBS/BSA for 30 min at room temperature. Next, sections were incubated with FITC labelled F(ab)₂ sheep anti-mouse Ig (Cappel, Organon Technika, Turnhout, Belgium) 10 mg/ml, diluted 1:750 in PBS/BSA for 30 min at room temperature. In addition, sections of all biopsies were incubated with an irrelevant mouse IgG (IgG2a or IgG2b) antibody (as a primary antibody control) and with FITC-labelled F(ab)₂ sheep anti-mouse Ig without the primary antibodies (as a conjugate control).

DNA and nucleosomes

DNA and nucleosomes were stained by incubating the sections with mAbs derived from lupus-prone mice. The anti-dsDNA mAb (#42) was derived from a panel of anti-dsDNA mAbs described previously [18]. The anti-nucleosome mAbs (LG8–1 and LG10–1) (Table 2) only recognize the intact nucleosome and not DNA or histones separately as described before [19]. The antinucleosome mAb #34 shows strong reactivity with nucleosomes [10] and for this mAb the nucleosomal epitope is primarily located on (H3-H4)/DNA (Kramers *et al.*, in press). For IF the sections were incubated with mAb #42, mAb #34, mAb LG8-1 or mAb LG10-1 (10 mg/ml) in PBS/BSA for 30 min at room temperature. Further procedures were identical to the procedure described for mAb KM2.

We also performed a double staining for IgG and nucleosomes using FITC-labelled F(ab)₂ rabbit anti-human IgG followed by antinucleosome mAb LG 10–1 with TRITC-labelled anti-mouse IgG2b as secondary antibody to compare the localization of the IgG and nucleosome deposits.

Attempts were made to elute Ig from the sections, which might improve the detection of nucleosomes, histones and DNA. To this end sections were incubated with either pepsin (Sigma) 10 mg/ml in 0.1M acetate pH4.5, 0.1M glycine or 2M NaCl for 1 h or overnight at 37°C. These procedures failed to remove Ig from the sections and no improvement of the detection of nucleosomes, histones, and DNA was observed.

Staining of histones using the polyclonal rabbit antiserum and HS-staining was scored semiquantitatively on a 0–4+ scale on coded sections by two independent investigators (regression analysis yielded a good correlation between the scores of both investigators, $P < 0.0001$).

Importantly, all MAbs used were purified to remove bound nucleosomal antigens, since this may produce spurious binding reactions [10].

Statistical analysis

Comparison of the presence of histones in kidney biopsies of patients with DPGN or MGN was done with the Fisher exact test. HS staining (scored semiquantitatively on a 0–4+ scale) was compared between kidney biopsies of patients

Table 1. Clinical characteristics of SLE patients

Patient no.	Sex	Age	Duration of disease	Non-renal disease manifestations	F/R ^a	Treatment	Creat. (mmol/l)	Urinary protein (g/24 h)	C3 (mg/l)	C4 (mg/l)	anti-dsDNA	
											Farr ^b	Critithidia ^c
<i>Diffuse proliferative glomerulonephritis (DPGN)</i>												
1	F	29	8 years	Thrombopenia	R	Prednisone 60 mg	111	12	330			80
2	M	15	<1 year ^d	Leukopenia	F		128	8.8	670	180		320
3	F	46	<1 year	Thrombopenia, anaemia	F		117	5.4	990	160		0
4	F	18	4 years	—	R	Prednisone 50 mg azathioprine 75 mg	95	9.8	390	120		0
5	F	34	6 years	Pericarditis, pleuritis	R	Chloroquine 250 mg	111	4.7	225	29		>320
6	F	41	15 years	—	R		90	8.6	410	ND		80
7	F	26	8 years	Leukopenia	F		81	3.2	390	80		160
8	F	21	2 months	Leukopenia, thrombopenia, arthralgias, fever	R	Prednisone 60 mg	172	12.0	464	120	17	
9	F	37	11 years	Arthralgias, fever, xerostomia, xerophthalmia, butterfly rash, leukopenia, anaemia	R	Prednisone 15 mg	84	5.9	510	174		neg.
10	F	27	1 month	Arthritis, anaemia	R	Prednisone 30 mg Hydroxychloroquine 400 mg	81	0.8	500	100		1420
11	F	38	10 years	Butterfly rash, arthritis, pleuritis	R	Prednisone 15 mg cyclophosphamide 150 mg	116	10.3	500	100		2340
<i>Membranous glomerulonephritis (MGN)</i>												
12	F	29	<1 year	Discoid skin lesions, oral ulcers, alopecia, thrombopenia	F	Prednisone 10 mg and chloroquine	60	2.5	300	80		0
13	F	29	<1 year	discoid skinlesions, oral ulcers, arthritis, psychosis, thrombopenia	F	No	57	2.5	580	160		0
14	M	51	<1 year	—	F	No	85	1	520	110		0
15	F	37	<1 year	discoid skinlesions	F	Hydroxychloroquine 200 mg		1.3	720	130		0
16	F	29	9 years	thrombopenia, anaemia, cerebral infarction	R	Prednisone 7.5 mg	94	0.3	683	29		0
17	F	54	14 years	—	R	No	279	2.3	375	76		0

a, F, first manifestation; R, relapse. b, U/ml or titre; c, titre; d, renal disease at presentation.

Table 2. Characteristics of the monoclonal and polyclonal antisera used

Antiserum	Subclass	Specificity	Origin	Reference
<i>Monoclonal</i>				
LG8-1	IgG2b	a-nucleosome (H2A-H2B/DNA)	MRL/lpr	[19]
LG10-1	IgG2b	a-nucleosome (H3-H4/DNA)	MRL/lpr	[19]
34	IgG2a	a-nucleosome (H3-H4/DNA)	NZB/W	[10]
KM2	IgG2a	a-histone (1–20 H2A;1–29 H4)	MRL/lpr	This manuscript
42	IgG2a	a-dsDNA	NZB/W	[18]
JM403	IgM	a-HS-GAG		[16]
JM72	IgG1	a-HSPG core protein		[16]
<i>Polyclonal</i>				
Oostende	IgG	a-histone (1–21 H3)	Rabbit	[11,12,17]

with DPGN and MGN using the Mann–Whitney U test. The correlation between HS staining and staining of histones with the polyclonal rabbit antiserum was tested by Spearman's correlation test.

Results

Staining of IgG, histones, nucleosomes and DNA in glomerular deposits

Using the polyclonal anti-H3 (1–21) peptide antiserum, histones were detected in all kidney biopsies of patients with DPGN and in two of six patients (patient no 12 and 17) with SLE-MGN ($P < 0.01$) (Table 3). Histone deposits were present in the walls of the capillary loops and followed the pattern of IgG deposition (Figure 2a, b). Using the antihistone mAb KM2, histones were identified in the immune deposits in three kidney biopsies of DPGN patients (patients no. 2, 4 and 6) and in none of the MGN patients (Table 3). Nucleosomes were identified in immune deposits of five renal biopsies of patients with DPGN (Figures 1, 2c) and in two of the biopsies with SLE-MGN

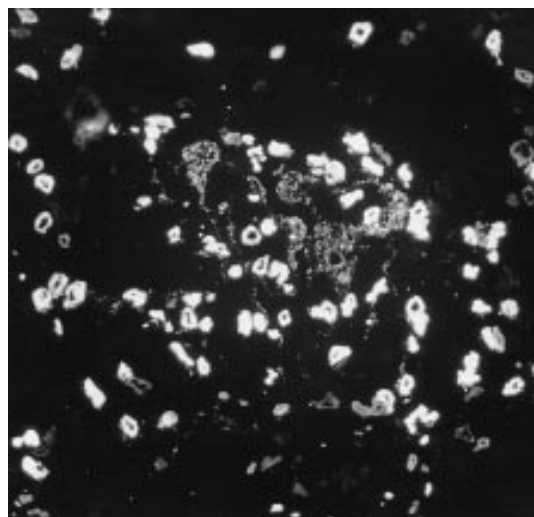


Fig. 1. Immunofluorescence of a kidney biopsy of an SLE patient with DPGN stained with a mouse antinucleosome mAb (LG10-1). Besides staining of the capillary loops and the mesangium, prominent nuclear staining can be seen ($\times 300$).

Table 3. Immunofluorescence findings in renal biopsies of SLE patients with either diffuse proliferative glomerulonephritis (DPGN; WHO class IV) or membranous glomerulonephritis (MGN; WHO class V) and non-SLE controls with either mesangiocapillary glomerulonephritis (MCGN) or idiopathic MGN

Antibodies	SLE nephritis		Non-SLE nephritis	
	DPGN class IV	MGN class V	MCGN	MGN
<i>mAbs^a</i>				
Antinucleosome	5/11 ^c	2/6	0/4	0/5
Anti-dsDNA	0/11	0/6	0/4	0/5
Antihistone	3/11	0/6	0/4	0/5
<i>Polyclonal^b</i>				
Anti-H3(1–21)	11/11 ^d	2/6	1/4	0/5

a, Staining of nucleosomes in glomerular deposits using mAbs #34, LG8-1 or LG10-1. Staining of histones using mAb KM2; staining of DNA using mAb #42. b, Staining of histones using a polyclonal rabbit anti-H3 1–21 serum. c, Number of positive biopsies/number of biopsies tested. d, $P < 0.01$ (Fisher exact test) for SLE-MGN compared to DPGN.

(Table 3). The two positive MGN biopsies (stained by mAb #34) were also positive with the polyclonal anti-H3 peptide antiserum. MAb LG10-1 stained deposits in four renal biopsies of DPGN patients (patients no. 2, 5, 6 and 10), mAb LG8-1 in two biopsies of DPGN patients (patients no. 1 and 2) and mAb #34 in five biopsies of DPGN patients (patients no. 1, 2, 5, 6 and 10). In some biopsies IgG deposits were observed without positive staining of histones and nucleosomes (Figure 2d–f), indicating that the positive staining in the DPGN and SLE-MGN biopsies is not due to aspecific binding of the antibodies to deposited Ig. In kidneys with nucleosome staining we found that nucleosome deposits were present in 20–80% of the Ig positive glomeruli. The localization of the nucleosome deposits was the same as the IgG deposition (as assessed by double staining). In the IF analysis with the antihistone or antinucleosome mAbs, staining in the walls of capillary loops was focal and segmental. Furthermore, the antihistone and antinucleosome mAbs showed bright nuclear staining. Due to this bright staining, the staining in the capillary

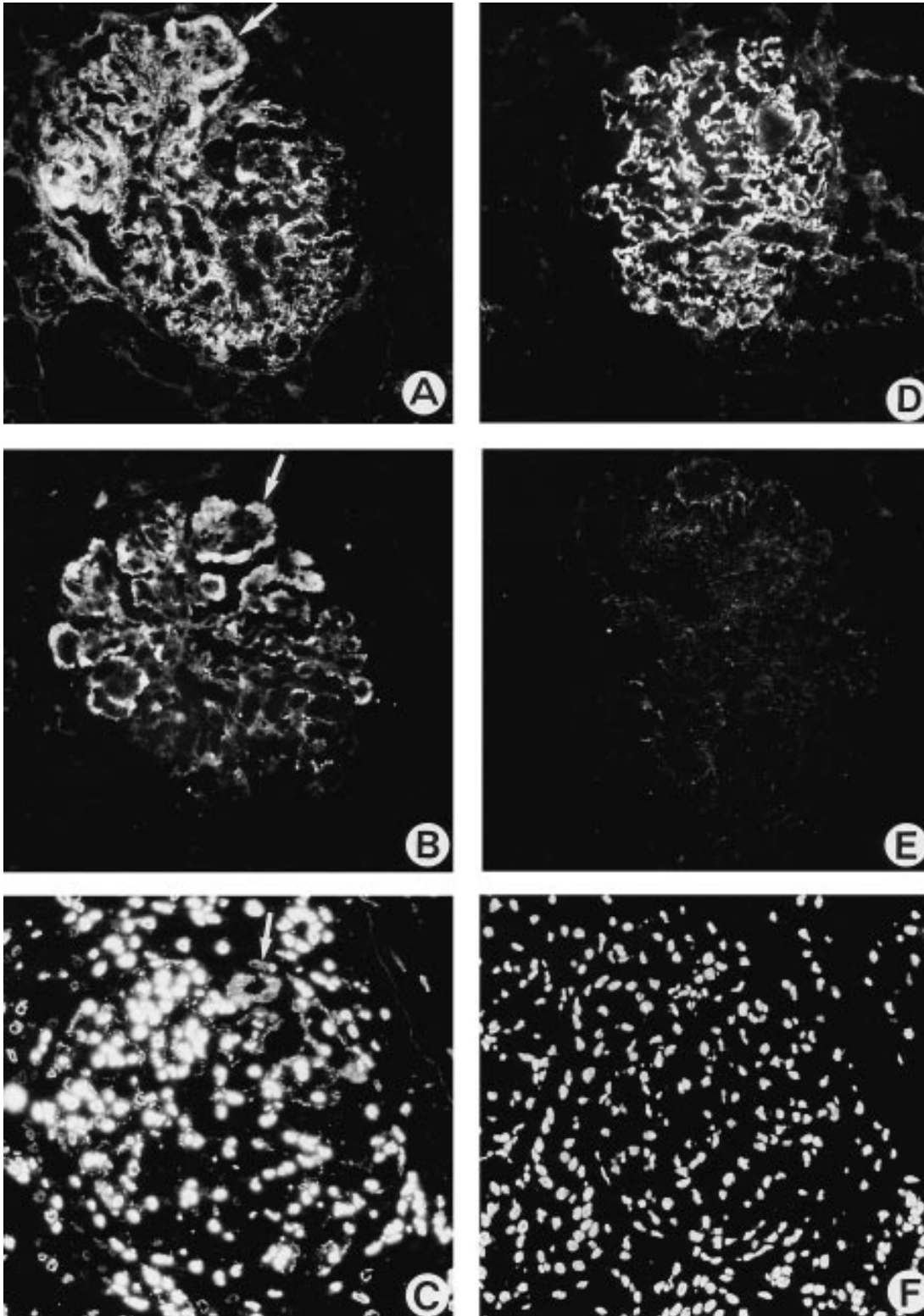


Fig. 2. Immunofluorescence of kidney biopsies of SLE patients. Staining for immunoglobulins (with an anti-Ig antiserum (A and D)), histones (with a polyclonal rabbit anti-H3 1–21 serum (B and E)), and nucleosomes (with a mouse antinucleosome mAb (LG10–1) (E and F)) in the same glomerulus on consecutive sections. Fig. 2a–c show positive staining. Ig deposits are located along the glomerular capillary walls and in the mesangium. Histone and nucleosome deposits are seen in a similar distribution to Ig. Fig. 2D–F show a glomerulus positive for Ig but negative for nucleosomes and histones, ruling out an aspecific binding of the probing antibodies to Ig in the immune deposits ($\times 300$).

loops is less prominent (weaker than that obtained with the polyclonal antihistone antiserum, which gave no nuclear staining). Anti-dsDNA antibodies (mAb #42) did not stain deposits in any of the biopsies (Table 3) (Figure 3). Also with other anti-dsDNA antibodies (mAbs #36 and #56) we were not able to detect glomerular DNA deposits (data not shown).

There was no correlation between the presence of nuclear deposits and sex, duration of disease, primary manifestation, or flare of glomerulonephritis, serology or proteinuria.

In the control experiments (non-SLE glomerulonephritis) none of the mAbs stained glomerular deposits, whereas the polyclonal rabbit anti-H3 (1–21) serum stained glomerular immune deposits in one patient with non-SLE mesangiocapillary glomerulonephritis (Table 3).

In all biopsies tested, no staining was observed with conjugated secondary antibodies alone or after incubation with non-relevant mouse IgG mAbs and conjugate.

Staining of glomerular HS and HSPG core protein

Staining of HSPG core protein was normal in all kidney biopsies studied (Figure 4a,d,g). GBM-HS staining was normal (Figure 4b) or only moderately reduced (Figure 4e) in renal biopsies of patients with SLE-MGN, whereas staining was strongly reduced or nearly absent (Figure 4h) in patients with DPGN ($P=0.001$). When GBM-HS staining was normal, no staining for histones was observed (Figure 4c). The appearance of histone deposits (Figure 4f,i) is paralleled by the disappearance of GBM-HS staining. There was a significant inverse correlation between HS staining and histone deposition as found by the polyclonal rabbit

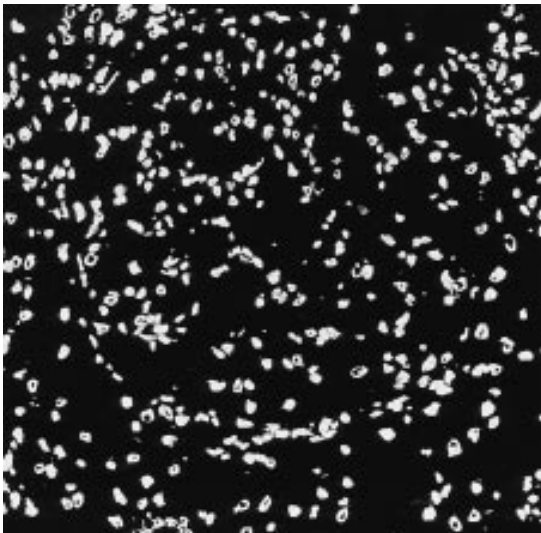


Fig. 3. Representative example of a kidney biopsy of an SLE patient with MGN, stained with a mouse anti-dsDNA mAb (#42). Only nuclei stain, and no staining in the walls of the capillary loops or the mesangium is observed ($\times 300$).

anti-H3 1–21 antiserum ($r_s = -0.77$, $P < 0.0001$, Figure 5).

Discussion

In recent years evidence has emerged that nucleosomes may play an important role in the initiation of lupus nephritis [20], by interaction of the histone part of the nucleosome with the GBM [21]. Histones are positively charged ($pI=10$) and most probably interact with the negatively charged HS in the GBM. We showed that after subsequent renal perfusion in the rat of histones, DNA and anti-dsDNA mAbs, these antibodies bind to the GBM, whereas subsequent perfusion of DNA and anti-dsDNA leads to limited mesangial binding of antibody, and anti-dsDNA antibodies perfused alone do not bind at all [22]. An interaction with HS in the GBM was suggested by the finding that anti-dsDNA antibodies complexed to DNA and histones were able to bind to HS in ELISA [9,10]. Subsequently we showed in the same rat kidney perfusion model that antinucleosome antibodies complexed to nucleosomes are also able to bind to the GBM. When HS was removed from the GBM by prior perfusion with the HS-degrading enzyme heparinase, the binding of subsequently perfused complexed antinucleosome antibodies was greatly reduced [10]. Taken together, these experiments show that HS in the GBM is an important ligand for the binding of these nucleosome complexed antibodies. It is assumed that histones in these complexes interact with HS, based on charge.

Although histones have been found in the sera of humans [23], it is not very likely that they exist as separate molecules devoid of DNA. In the nucleus, histones are bound to DNA, within the nucleosome. These nucleosomes have been found in the circulation of lupus patients [24]. It is assumed that they are released from apoptotic cells, since apoptosis leads to release of oligonucleosomes [25,26], whereas necrosis yields less well-defined histone/DNA complexes. It is presently unknown what happens with nuclear material after release in the circulation. DNase and proteinases are present in plasma [27] so partial degradation of the nucleosome particle is possible.

In the present study we analysed in more detail whether nuclear material was present in glomerular deposits in human lupus nephritis by staining for histones, DNA, and nucleosomes. Using the polyclonal anti-H3 1–21, antiserum deposits were found in all kidney biopsies of patients with DPGN and in two of six patients with MGN. This is in accordance with the findings of Stöckl *et al.* who also found glomerular staining with this anti-H3 1–21 antiserum in SLE patients [11]. However, in Stöckl's study deposits were found in 69% of the biopsies with DPGN and in 77% of the MGN biopsies, whereas we found deposits in 100% of the DPGN and in 33% of the MGN patients. Using the antihistone mAb KM2, histone deposits were found in three renal biopsies of patients with DPGN and in none of the patients with MGN. Because of a

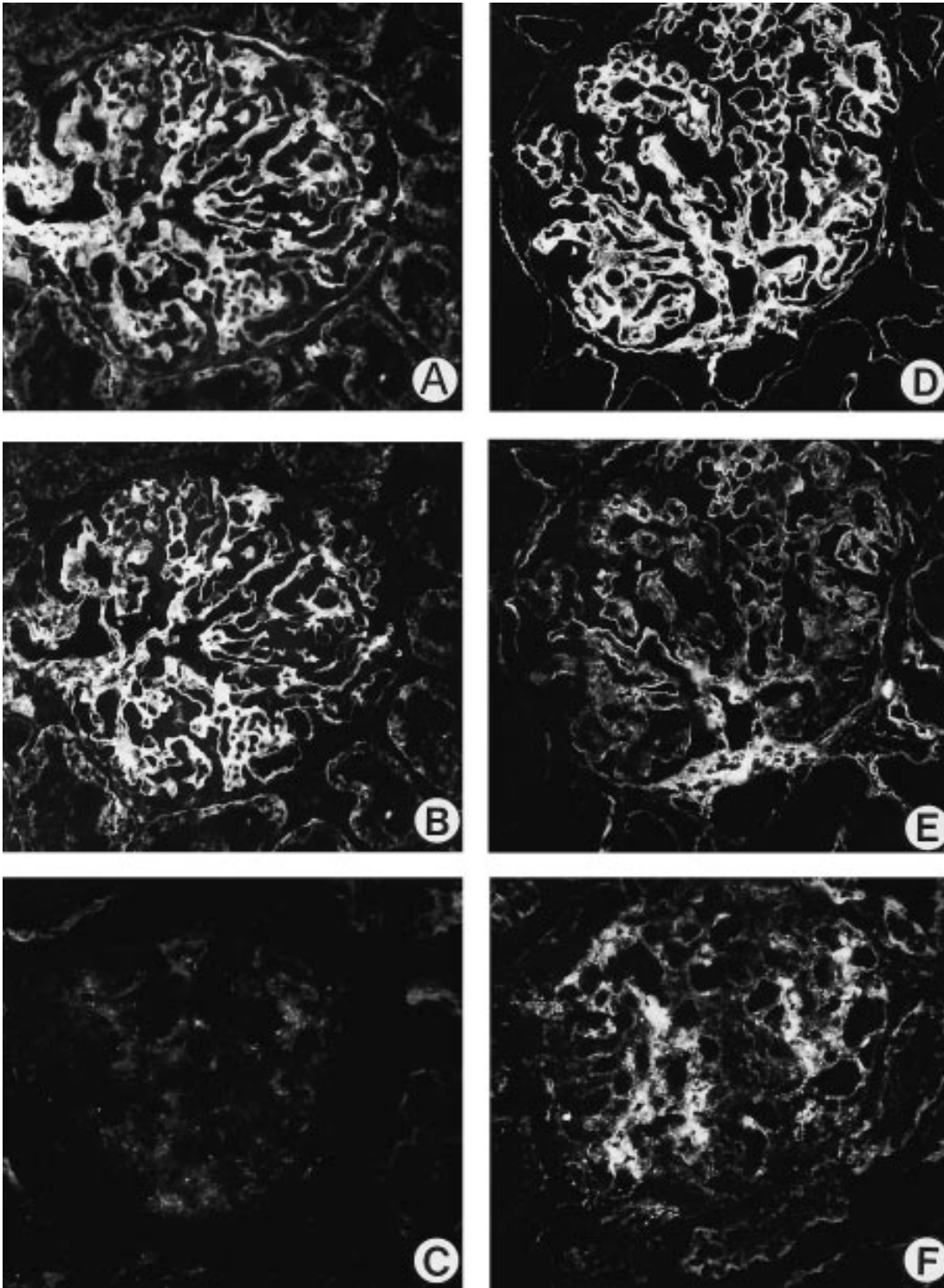


Fig. 4. Representative examples of double staining of a kidney biopsy of two patients with MGN (Fig. 4A, 4B and 4D, 4E) and of a patient with DPGN (Fig. 4G, 4H), with the mouse anti-HS mAb JM-403 and with the mouse anti-HSPG core protein mAb JM-72. In Fig. 4A, 4D and 4G the biopsies are stained with JM-72, showing intact HSPG-staining. In Fig. 4B, 4E and 4H the same biopsies are stained with JM-403, showing normal (4B) or moderately reduced (4E) GBM-HS staining in the MGN patients, and almost absent GBM-HS staining in the patient with DPGN (4H). Same glomeruli (successive sections) are stained with polyclonal rabbit anti-H3 1–21 serum (Fig. 4C, 4F and 4I). The appearance of histone deposits (Fig. 4F and 4I) is paralleled by the disappearance of GBM-HS staining (Fig. 4E and 4H) ($\times 300$).

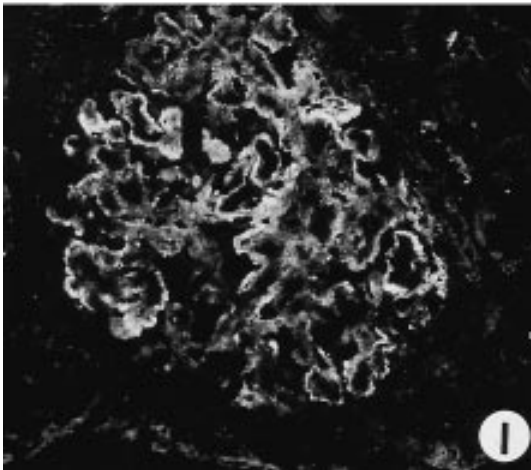
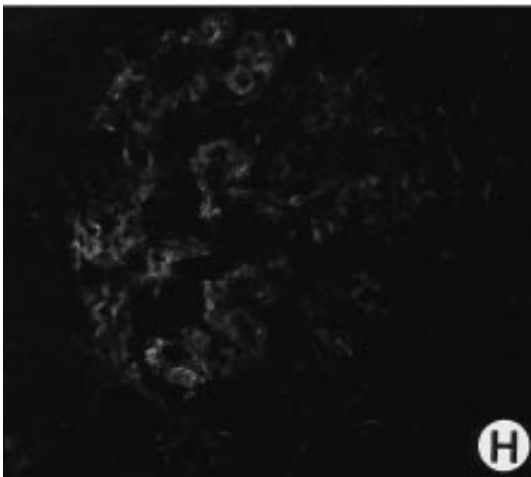
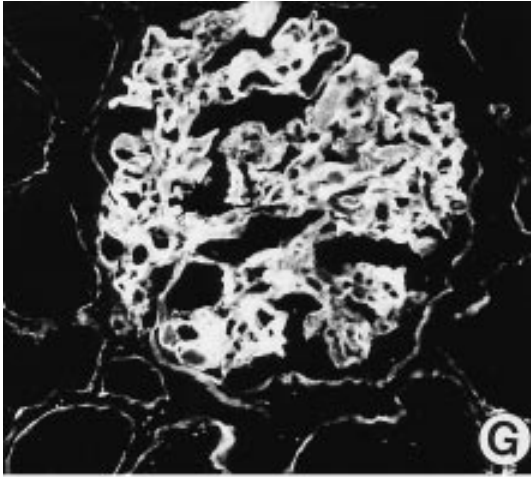


Fig. 4. (*cont.*)

broader reactivity of the polyclonal antibodies reacting with different epitopes in the H3 1–21 peptide, this polyclonal antiserum has apparently a greater sensitivity for the detection of histone deposits. Nucleosomes were found in five of eleven kidney biopsies of DPGN patients and in two of six patients with MGN. The anti-dsDNA antibodies did not stain any deposits. In

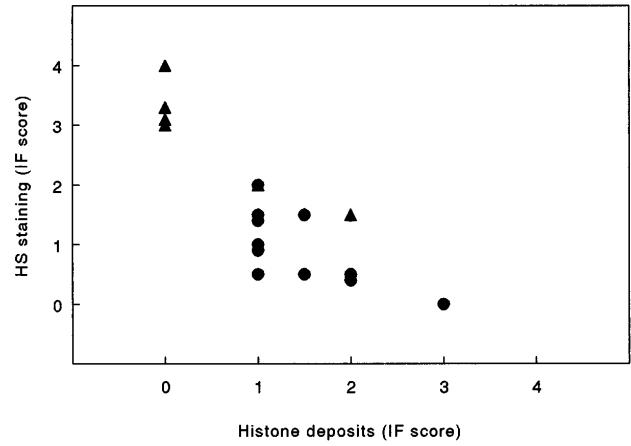


Fig. 5. Correlation between HS staining and staining of histone deposits (as assessed with the polyclonal rabbit anti H3(1–21) serum) in the walls of the capillary loops. Staining was scored on a 0–4 scale. DPGN (◻), SLE-MGN (+).

the IF analysis with the anti-dsDNA, antihistone and antinucleosome mAbs, nuclear staining was observed in all biopsies since the epitopes these mAbs recognize are exposed in the nuclei. However, using the polyclonal antiserum, no nuclear staining was observed, suggesting that the H3 1–21 epitope is not exposed in the nucleus *in vivo*.

Localization of autoantibodies in the GBM can arise along two different mechanisms. First, they can deposit from the circulation as complexes. Localization via this mechanism leads mainly to subendothelial or mesangial deposits, as is found mainly in DPGN. The other possibility is an *in situ* immune complex formation in which the antibody reacts with an intrinsic GBM antigen or an exogenous planted antigen. This mechanism takes mainly place in the formation of subepithelial deposits as seen in MGN. It is unlikely that the nucleosome binds to the GBM in free non-complexed form and acts as a planted antigen, since renal perfusion of intact nucleosomes leads mainly to mesangial and not to GBM localization [20,28]. This is due to the pI of the native nucleosome which is about 7. Furthermore, the negatively charged DNA is located on the outside of the nucleosome which reduces the possibility that native nucleosomes interact with the negatively charged GBM. Such a direct binding can only be envisaged if nuclear material is enzymatically modified by plasma or tissue DNase and proteinases which creates a nuclear particle with less DNA and relatively more histones. Such a particle is theoretically able to bind to the GBM leading to *in situ*-immune complex formation. Such a mechanism could explain the higher frequency of histone deposits that we observed.

Another, more likely, possibility is that DNA or nucleosome-specific epitopes of the nucleosome are masked by anti-dsDNA or nucleosome specific autoantibodies. When nucleosomes are released in the circulation of lupus patients they will bind to these antibodies and form nucleosome-antibody complexes. Only when

these antibodies cover the negatively charged DNA in the nucleosome, the complex is able to bind to the GBM. In this view the overall pI and thus the nephritogenicity of the complex is determined by the antigen specificity of the bound antibody. This view is confirmed by the fact that glomerular eluates are greatly enriched for anti-dsDNA and anti-nucleosome antibodies [6,7,29].

In contrast, antihistone antibodies would cover the histone part of the nucleosome, thereby reducing the positive charge which prevents it from binding to the GBM. Interestingly, in drug induced lupus, in which antihistone antibodies are abundantly present and anti-dsDNA antibodies are absent, nephritis is seldom seen [30]. Antihistone Abs are found in glomerular eluates of lupus mice [29,31]. However, in our experience, the eluates contain only small quantities of antihistone antibodies which show no correlation with albuminuria [29]. The mechanism of *in vivo* masking of nucleosome and DNA specific epitopes with a relative preservation of histone-specific epitopes could explain the lower frequency of nucleosome specific staining and the higher incidence of histone specific staining that we observed.

Formal proof for this assumption could have come from elution studies on kidney sections, which could lead to uncovering of these nucleosome specific epitopes. However, attempts to achieve this were, for technical reasons, unsuccessful as we have described previously [14].

The second aim of our study was to find out whether loss of GBM-HS staining in human lupus nephritis was associated with histone or nucleosome deposition. In a recent study we found in murine lupus a decrease of glomerular HS staining without loss of HS content. *In-vitro* experiments showed that histones, nucleosomes and antinucleosome antibodies complexed to nucleosomes were all able to mask HS in ELISA [14]. In the present study this *in vitro* finding was extended since the loss of HS staining correlated with histone deposition. Very interestingly, histone deposition was only found in two of six kidney biopsies of SLE-MGN patients, and in these patients HS staining was not or only moderately reduced. This may be due to quantitative differences in glomerular IgG deposition between DPGN and MGN patients, since in DPGN heavier IgG deposits are present. This is in line with our observation in murine lupus nephritis, where an inverse correlation between IgG deposition and GBM-HS staining was found [14].

In conclusion, we show for the first time that nucleosomes can be identified in immune deposits of patients with SLE nephritis. This finding underlines the importance of nucleosomes for the pathogenesis of SLE [20, 32]. Histones are present in all lupus patients with DPGN and their presence correlates with a loss of GBM-HS staining, which is probably due to masking of HS.

Acknowledgements. This study was supported by grants from the Dutch Kidney Foundation (C91.1081 and C95-1513), the Dutch

League Against Rheumatism (90/CR/287), and the EC Biomed I program (BMH1-CT92-1766). We thank Dr Marc Bijl (Dept. of Clinical Immunology, University Hospital Groningen) for providing clinical data of some patients shown in Table 1.

References

1. Lahita RG. *Systemic Lupus Erythematosus*. Churchill Livingstone Inc., New York, 1992; 1-1000
2. Tan EM. Antinuclear antibodies: diagnostic markers for autoimmune diseases and probes for cell biology. *Adv Immunol* 1989; 44: 93-149
3. Swaak AJG, Aarden LA, Staius van Eps LW, Feltkamp TEW. Anti-dsDNA and complement profiles as prognostic guides in SLE. *Arthritis Rheum* 1979; 22: 226-235
4. ter Borg EJ, Horst G, Hummel EJ, Limburg PC, Kallenberg CGM. Predictive value of rises in anti-double-stranded DNA antibody levels for disease exacerbations in systemic lupus erythematosus: a long term prospective study. *Arthritis Rheum* 1990; 33: 634-643
5. Bootsma H, Spronk P, Derksen R *et al*. Prevention of relapses in systemic lupus erythematosus. *Lancet* 1995; 345: 1595-1599
6. Winfield JB, Faiferman I, Koffler D. Avidity of anti-DNA antibodies in serum and IgG glomerular eluates from patients with systemic lupus erythematosus. *J Clin Invest* 1977; 59: 90-96
7. Kalunian KC, Panosian-Sahakian N, Ebling FM *et al*. Idiotypic characteristics of immunoglobulins associated with systemic lupus erythematosus. *Arthritis Rheum* 1989; 32: 513-522
8. Faaber P, Rijke GPM, Van de Putte LBA, Capel PJA, Berden JHM. Crossreactivity of human and murine anti-DNA antibodies with heparan sulphate: the major glycosaminoglycan in glomerular basement membrane. *J Clin Invest* 1986; 77: 1824-1830
9. Termaat RM, Brinkman K, van Gompel F *et al*. Cross-reactivity of monoclonal anti-DNA antibodies with heparan sulfate is mediated via bound DNA/histone complexes. *J Autoimmun* 1990; 3: 531-545
10. Kramers C, Hylkema MN, van Bruggen MCJ *et al*. Antinucleosome antibodies complexed to nucleosomal antigens show anti-DNA reactivity and bind to rat glomerular basement membrane *in vivo*. *J Clin Invest* 1994; 94: 568-577
11. Stöckl FW, Muller S, Batsford S *et al*. A role for histones and ubiquitin in lupus nephritis. *Clin Nephrol* 1994; 41: 10-17
12. Schmiedeke TMJ, Stöckl FW, Muller S *et al*. Glomerular immune deposits in murine lupus models may contain histones. *Clin Exp Immunol* 1992; 90: 453-458
13. van den Born J, van den Heuvel LPWJ, Bakker MAH *et al*. Distribution of GBM heparan sulphate proteoglycan core protein and side chains in human glomerular diseases. *Kidney Int* 1993; 43: 454-463
14. van Bruggen MCJ, Kramers C, Hylkema MN *et al*. Decrease of heparan sulfate staining in the glomerular basement membrane in murine lupus nephritis. *Am J Pathol* 1995; 146: 753-763
15. Malide D, Londono I, Russo P, Bedayan M. Ultrastructural localization of DNA in immune deposits of human lupus nephritis. *Am J Pathol* 1993; 143: 304-311
16. van den Born J, van den Heuvel LPWJ, Bakker MAH, Veerkamp JH, Assmann KJM, Berden JHM. Monoclonal antibodies against the core protein and the glycosaminoglycan side chain of glomerular basement membrane heparan sulfate proteoglycan. Characterization and immunohistochemical application in human tissues. *J Histochem Cytochem* 1994; 42: 89-102
17. Muller S, Plaue S, Couppez M, van Regenmortel HMV. Comparison of different methods for localising antigenic regions in histone H2A. *Mol Immunol* 1986; 23: 593-599
18. Smeenk RJT, Brinkman K, Van den Brink HG, Westgeest AAA. Reaction patterns of monoclonal antibodies to DNA. *J Immunol* 1988; 140: 3786-3792
19. Monestier M, Novick KE. Specificities and genetic characteristics of nucleosome-reactive antibodies from autoimmune mice. *Mol Immunol* 1996; 33: 89-99
20. Tax WJM, Kramers C, van Bruggen MCJ, Berden JHM.

- Apoptosis, nucleosomes, and nephritis in SLE. *Kidney Int* 1995; 48: 666–673
21. Schmiedeke TMJ, Stöckl FW, Weber R, Sugisaki Y, Batsford SR, Vogt A. Histones have high affinity for the glomerular basement membrane. *J Exp Med* 1989; 169: 1879–1894
 22. Termaat RM, Assmann KJM, Dijkman HBPM, Smeenk RJT, Berden JHM. Anti-DNA antibodies can bind to the glomerulus via two distinct mechanisms. *Kidney Int* 1992; 42: 1363–1371
 23. Waga S, Tan EM, Rubin RL. Identification and isolation of soluble histones from bovine milk and serum. *Biochem J* 1987; 244: 675–682
 24. Rumore PM, Steinman CR. Endogenous circulating DNA in systemic lupus erythematosus. *J Clin Invest* 1990; 86: 69–74
 25. Bell DA, Morrison B, Vandenbygaart P. Immunogenic DNA-related factors. Nucleosomes spontaneously released from murine lymphoid cells stimulate proliferation and immunoglobulin synthesis of normal mouse lymphocytes. *J Clin Invest* 1990; 85: 1487–1496
 26. Emlen W, Niebur J, Kadera R. Accelerated *in vitro* apoptosis of lymphocytes from patients with systemic lupus erythematosus. *J Immunol* 1994; 152: 3685–3692
 27. Peitsch MC, Hesterkamp T, Polzar B, Mannherz HG, Tschopp J. Functional characterisation of serum DNase I in MRL-lpr/lpr mice. *Biochem Biophys Res Commun* 1992; 186: 739–745
 28. Coritsidis GN, Beers BC, Rumore PM. Glomerular uptake of nucleosomes: Evidence for receptor-mediated mesangial cell binding. *Kidney Int* 1995; 47: 1258
 29. van Bruggen MCJ, Kramers C, Hylkema MN, Smeenk RJT, Berden JHM. Significance of anti-nuclear and anti-extracellular matrix auto-antibodies for albuminuria in MRL/l mice. A longitudinal study on plasma and glomerular eluates. *Clin Exp Immunol* 1996; 105: 132–139
 30. Hess E. Drug-related lupus. *N Engl J Med* 1988; 318: 1460–1462
 31. Elouaai F, Lule J, Benoist H *et al.* Autoimmunity to histones, ubiquitin, and ubiquitinated histone H2a in NZBxNZW and MRL-lpr/lpr mice. Anti-histone antibodies are concentrated in glomerular eluates of lupus mice. *Nephrol Dial Transplant* 1994; 9: 362–366
 32. Mohan C, Datta SK. Short analytical review. Lupus: key pathogenic mechanisms and contributing factors. *Clin Immunol Immunopathol* 1995; 77: 209–220

Received for publication: 4.6.96

Accepted in revised form: 19.6.96