

## MUCOSAL DISEASES SERIES

# Number VI Recurrent aphthous stomatitis

S Jurge<sup>1</sup>, R Kuffer<sup>2</sup>, C Scully<sup>1</sup>, SR Porter<sup>1</sup>

<sup>1</sup>Oral Medicine, Eastman Dental Institute, University College London, UK; <sup>2</sup>Division of Stomatology, Faculty of Medicine, University of Geneva, Switzerland

**Recurrent aphthous stomatitis (RAS; aphthae; canker sores) is a common condition which is characterized by multiple recurrent small, round or ovoid ulcers with circumscribed margins, erythematous haloes, and yellow or grey floors typically presenting first in childhood or adolescence. RAS occurs worldwide although it appears most common in the developed world. The aetiology of RAS is not entirely clear. Despite many studies trying to identify a causal microorganism, RAS does not appear to be infectious. A genetic predisposition is present, as shown by strong associations with genotypes of IL-1 $\beta$ ; IL-6 in RAS patients, and a positive family history in about one-third of patients with RAS. Haematinic deficiency is found in up to 20% of patients. Cessation of smoking may precipitate or exacerbate RAS in some cases. Ulcers similar to RAS may be seen in human immunodeficiency virus disease and some other immune defects, and drugs, especially non-steroidal anti-inflammatory drugs and nicorandil may produce lesions clinically similar to RAS. Topical corticosteroids can often control RAS. However, the treatment of RAS remains unsatisfactory, as most therapies only reduce the severity of the ulceration and do not stop recurrence.**

*Oral diseases* (2006) 12, 1–21

**Keywords:** mouth ulcers; aphthae; corticosteroids; immunosuppressants; oral

### Introduction

Recurrent aphthous stomatitis (RAS; aphthae; canker sores) is a common condition which is characterized by multiple recurrent small, round or ovoid ulcers with circumscribed margins, erythematous haloes, and yellow

or grey floors, appearing first in childhood or adolescence.

### Epidemiology

Depending upon the group examined, RAS may affect 5–60%. In the USA the highest incidence (60%) was found in female student nurses, male student dentists (56%) and professional school students (55%). The lowest incidence (5%) was found in male hospital patients (Ship, 1972). 56% of Danish dental students (Donatsky, 1973) have had a history compatible with RAS. 46.7% of one group of dental patients in Thailand were found to have had RAS (Pongissawanun and Laohapand, 1991).

Population studies have found RAS in about 2% of Swedish (Axell and Henricsson, 1985b), 1.9% of Spanish (Garcia-Pola Vallejo *et al*, 2002) and 0.5% of Malaysian (Zain, 2000) examined adults, although 17.7% of Swedish and 9.7% of adults in Ljubljana (Slovenia) (Kovac-Kovacic and Skaleric, 2000) have a history of possible RAS. RAS seems to be infrequent in Kuwaiti Bedouins (5%; Fahmy, 1976) and it has been found in only 0.1% of Indians in Malaysia (Zain, 2000). However, RAS may be especially common in North America (Embil *et al*, 1975).

There may be female predominance of RAS in adults (Ship, 1972; Fahmy, 1976; Axell and Henricsson, 1985b; Pongissawanun and Laohapand, 1991; Donatsky, 1973; Kovac-Kovacic and Skaleric, 2000) and in children (Field *et al*, 1992; Kleinman *et al*, 1994). In the USA, white people are three times more frequently affected than black people (Kleinman *et al*, 1994).

In a population study about 1% of children in the USA were found to have recurrent oral ulcers (Kleinman *et al*, 1994), but about 35–40% may have a history of RAS-like disease (Miller *et al*, 1980; Kleinman *et al*, 1994), with ulceration beginning before 5 years of age [19.7% (Miller *et al*, 1980); 21.7% (Kleinman *et al*, 1994)] and the frequency of affected patients rising with age. However, a study of elderly dental patients in

Correspondence: Stephen Porter MD PhD RCS FDS RCSE, Eastman Dental Institute, University College London, 256 Gray's Inn Road, London WC1X 8LD, UK. Tel: +44 (0)20 7915 1197, Fax: +44 (0)20 7915 2341, E-mail: s.porter@eastman.ucl.ac.uk  
Received 27 November 2004; accepted 10 January 2005

Thailand found RAS in only 0.7% of persons over 70 years of age (Jainkittivong *et al*, 2002).

Children of higher socioeconomic status may be more commonly affected [21.4% (Axell, 1975; Axell and Henricsson, 1985b); 19% (Crivelli *et al*, 1988)] than those from low socioeconomic groups [5% (de Muniz *et al* 1981); 2% (Crivelli *et al*, 1988)].

### Aetiopathogenesis

A genetic predisposition is present, as shown by an increased frequency of certain human leucocyte antigen (HLA) types, and a positive family history in some patients with RAS. Attempts to implicate a variety of bacteria or viruses in the aetiology have failed. Reactions to heat shock proteins (hsp) are one possibility: patients with RAS have circulating lymphocytes reactive with peptide 91–105 of hsp 65–60.

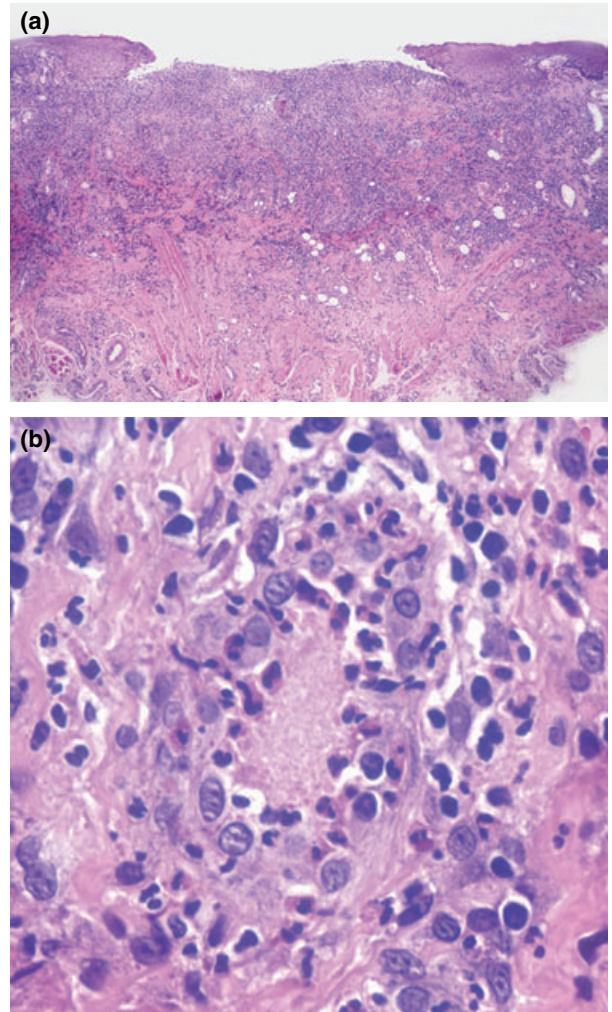
Haematinic deficiency is found in up to 20% of patients, cessation of smoking may precipitate or exacerbate RAS in some cases, and stress may underlie RAS in some individuals. It has been suggested in some, but not all, studies that sodium lauryl sulphate (SLS), a detergent in some oral healthcare products may give rise to ulceration akin to that of RAS. Ulcers similar to RAS may be seen in human immunodeficiency virus (HIV) and some other immune defects, and drugs, especially non-steroidal anti-inflammatory drugs (NSAIDs) and nicorandil may produce lesions clinically similar to RAS in appearance, but not periodicity.

In RAS, microscopically, mononuclear (lymphocytic) cells begin to infiltrate the epithelium and oedema develops (Figures 1–3). This preulcerative stage is followed by an increase of pain and the development of a localized papular swelling because of keratinocyte vacuolization surrounded by a reactive erythematous halo representing localized vasculitis with a dense mononuclear cell infiltrate.

The painful papule then ulcerates and a fibrous membrane covers the ulcer which is infiltrated mainly by neutrophils, lymphocytes and plasma cells. Finally there is healing with epithelial regeneration and coverage of the ulcer.

The immunopathogenesis probably involves a cell-mediated immune response mechanism, and involves generation of T-cells and tumour necrosis factor alpha (TNF- $\alpha$ ) by these other leucocytes (macrophages and mast cells) (Natah *et al*, 2000). The TNF- $\alpha$  cytokine, a major inflammatory mediator, induces initiation of the inflammatory process by its effect on endothelial cells adhesion and a chemotactic effect on neutrophils (Natah *et al*, 2000). Studies have shown that RAS can be prevented by treatments that prevent the synthesis of endogenous TNF- $\alpha$  such as thalidomide (Sampaio *et al*, 1991) and pentoxifylline (Natah *et al*, 2000).

Elevated levels of interleukin-2 (IL-2) (Sun *et al*, 2000) as well as those of TNF- $\alpha$  (Taylor *et al*, 1992) (both pro-inflammatory cytokines) and lower levels of IL-10 (an anti-inflammatory cytokine) (Buno *et al*, 1998) have been reported in lesional mucosa of RAS

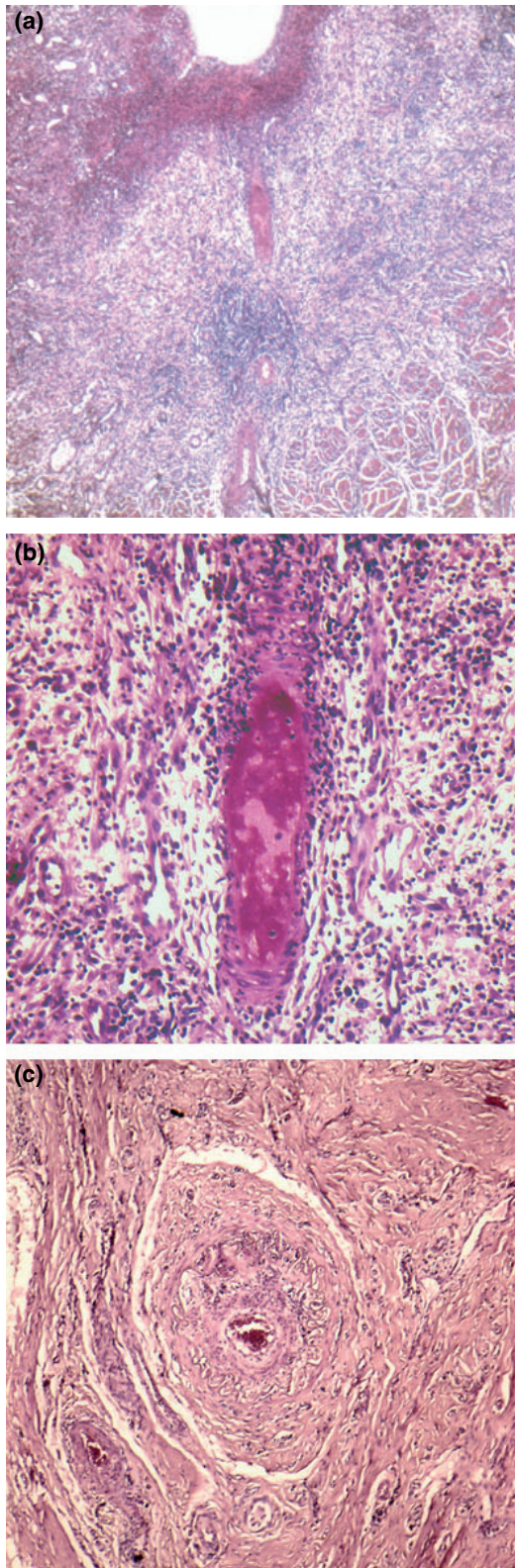


**Figure 1** Minor aphthous ulcer (tongue, 33-year-old female). (a) Dense inflammatory infiltrate in the ulcer floor, and lateral dilated vessels. (b) Vasculitis with small thrombus in a postcapillary venule beneath the ulcer

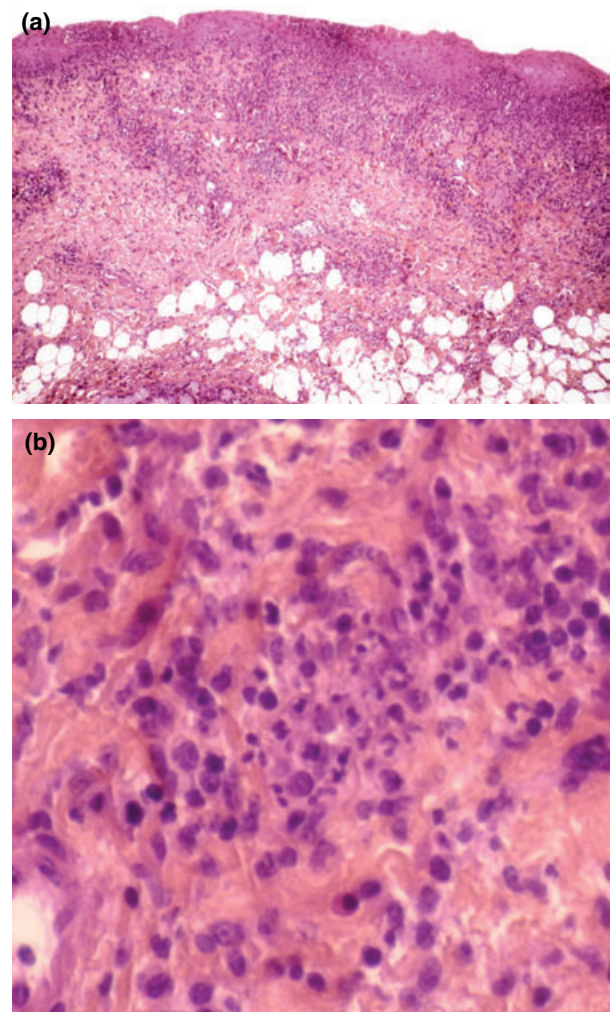
patients. IL-10 usually stimulates epithelial proliferation in a healing process therefore its low levels in RAS patients may delay epithelization and prolong the duration of the ulcers.

TNF- $\alpha$  also has some important immune regulatory activities including stimulation of class I major histocompatibility (MHC) expression. An increase in class I and class II MHC antigen expression has been detected in the basal epithelial cells in the preulcerative and ulcerative stages of the RAS lesion (Savage *et al*, 1986). As almost no MHC antigens were detected after healing (Savage *et al*, 1986), they probably play a role in the local tissue damage by targeting these cells for attack by cytotoxic T-cells (CD8+ cells) in the ulcerative process.

A markedly increased plasma level of IL-2 was recorded in the active stage of RAS (Sun *et al*, 2000). Natural killer (NK) cells activated by IL-2 may play a role in the process of this disease. An increased activity of these cells was noted in active lesions, diminishing during periods of remission (Sun *et al*,



**Figure 2** Major aphthous ulcer, active phase (lower lip, HIV positive 44-year-old male). (a) Segmental arteritis deeply located beneath the ulcer. (b) Detail of arteritis, with occlusive thrombosis of the vessel lumen. (c) Recurrent major aphthous ulcer, cicatricial fibrous artery in scar tissue (58-year-old female)



**Figure 3** Herpetiform ulcers (lower lip mucosa, 48-year-old female). (a) Small erosions and foci of heavy inflammatory exocytosis in the epithelium. (b) Polymorphous infiltrate and pyknotic neutrophils around occluded capillaries

1991). As NK cells are also associated with antiviral activity against varicella zoster virus (VZV) and cytomegalovirus (CMV) (Hayward *et al*, 1986), a viral antigenic source may be considered for RAS in some patients. Other studies, however, failed to demonstrate any significant difference in fractions of NK subsets between patients with RAS and controls (Pedersen and Pedersen, 1993).

Studies have shown circulating autoantibodies against the cytoplasm of autologous oral epithelial cells of RAS patients. Enhanced cytotoxic destruction of epithelial cells by TNF produced by peripheral blood mononuclear cells (lymphocytes) (Dolby, 1969) and leucocytes (Taylor *et al*, 1992) from RAS subjects was demonstrated by *in vitro* studies. As a similar enhanced cytotoxicity has been shown against a fibroblast cell line (Thomas *et al*, 1988), the damage to the underlying connective tissue may also be part of the pathogenesis of the disease.

## Genetic basis

At least 40% of RAS patients have a vague familial history of RAS (Sircus *et al*, 1957). It has been suggested that patients with a positive family history of possible RAS may develop oral ulcers at an earlier age and have more severe symptoms than affected individuals with no family history of oral ulceration (Ship, 1965). The probability of a sibling developing RAS may be influenced by the parents' RAS status (Ship, 1972) and there is a high correlation of RAS in monozygote but not dizygote twins (Miller *et al*, 1977).

A variety of associations or non-associations with HLA antigens and RAS have been reported. An association with HLA-B12 was reported (Lehner *et al*, 1982; Malmstrom *et al*, 1983) but not confirmed by others (Gallina *et al*, 1985; Ozbakir *et al*, 1987). In groups of RAS patients of different ethnic origin a significant association between HLA-DR2 (usually in the haplotype HLA-DR2/B12) and RAS was observed, but the study groups were only comprised of a few patients (Lehner *et al*, 1982; Albanidou-Farmaki *et al*, 1988). In a study of Turkish patients with RAS the frequency of HLA-B5 was not significantly raised compared with healthy control subjects (Ozbakir *et al*, 1987). The frequency of HLA-DR4 was reduced in a cohort of Greek patients (Albanidou-Farmaki *et al*, 1988). In Sicilian patients with RAS the frequency of HLA-B5 was reduced, but HLA-DR7 was significantly increased (Gallina *et al*, 1985). A small study of 22 Israeli Arabs with probable RAS found a non-significantly raised frequency of HLA-B52 and B44 (Jaber *et al*, 2001). In some, but not all groups (Shohat-Zabarski *et al*, 1992), there may be a negative association of RAS with MT2 and MT3 (now HLA-DQ series). A comparison of HLA phenotypes of patients of Chinese origin established that the frequency of HLA-DR5; DRw8; DQw1 were increased in mucocutaneous Behcet's disease, compared with RAS as well as haplotypes DR5/DRw1 and DRw8/DRw1 (Sun *et al*, 2001). There would seem to be no consistent significant association between RAS and any particular serologically determined HLA antigen haplotypes except possibly HLA-B51 (Shohat-Zabarski *et al*, 1992).

The close association both of Behcet's syndrome and RAS with HLA-B51 (Shohat-Zabarski *et al*, 1992) suggests a relationship in which this locus may not be the primary locus responsible – rather some other gene close to those controlling hsp and TNF (Mizuki *et al*, 1995). However no association was observed in polymorphism of TNF $\alpha$ , TNF $\beta$  or vitamin D receptor genes in a study of 95 white patients with RAS attending a clinic in London (Bazrafshani *et al*, 2002a) but a strong correlation was observed in the inheritance of an allele of interleukin-1 (IL-1 $\beta$ -51). In addition, the allele of IL-6-174 was strongly associated with RAS, this being greatest with a/a homozygosity. Other less strong associations occurred with IL-iIRN-wNTR 1/1 homozygosity.

Such strong associations with these genotypes of IL-1 $\beta$  and IL-6 thus suggest that RAS does indeed have some sort of genetic basis (Bazrafshani *et al*, 2002b). It

may be that an unopposed or excessive production of IL-1 $\beta$  or IL-6 (e.g. response to local trauma) may be pivotal to the development of RAS (see below).

There is evidence that patients with RAS have changes in cell-mediated immunity. Patients with RAS may have increased levels of peripheral blood CD8+ T lymphocytes and/or decreased CD4+ T lymphocytes (Bachtiar *et al*, 1998; Sistig *et al*, 2002) although levels of total (CD3+) lymphocytes may be reduced (Sistig *et al*, 2002). There may be a reduced percentage of CD4+ (CD5+ 2H4T) 'virgin' T cells and an increased percentage of CD4+ (CD29+4B4+) 'memory' T lymphocytes (Pedersen *et al*, 1989). Patients with active RAS have an increased proportion of  $\gamma\delta$  cells compared with healthy control subjects and RAS patients with inactive disease (Pedersen and Ryder, 1994). The  $\gamma\delta$  T cells may play a role in antibody-dependent cell-mediated cytotoxicity (ADCC), however, the exact stimulus for the increased generation of  $\gamma\delta$  T cells in RAS is unclear.

In contrast to peripheral blood there is a decrease in the number of mononuclear cells, including CD4+ and CD8+ T lymphocytes in the affected and non-affected oral mucosa of RAS patients (Hayrinen-Immonen *et al*, 1991). In the preulcerative phase of RAS there is a local mononuclear infiltrate consisting initially of large granular lymphocytes (LGL) and T4 (CD4+) helper-induced lymphocytes (Hayrinen-Immonen *et al*, 1991). The ulcerative phase is associated with the appearance of CD4+ cytotoxic suppressor cells, but these are replaced by CD4+ cells during healing (Savage *et al*, 1985). Polymorphonuclear lymphocytes (PMNL) also appear in the lesion (Figures 1, 2 and 3).

As noted above, there can be an increase in  $\gamma\delta$  T cells, important in ADCC. *In vitro* studies have indicated that peripheral blood leucocytes of patients with RAS may demonstrate increased cytotoxicity towards oral mucosal epithelium (Lehner, 1967; Dolby, 1969; Rogers *et al*, 1974, 1976; Greenspan *et al*, 1981; Burnett and Wray, 1985) or sheep red blood cells (Sistig *et al*, 2002), and it is thus possible that RAS may represent an ADCC-type reaction to the oral mucosa. This concept is supported by the knowledge that peripheral blood mononuclear cells of patients with RAS (but no active disease) lyse oral mucosal cells expressing class I and II MHC antigens. More importantly peripheral blood CD4+ T cells from RAS patients can also cause epithelial lysis (Savage and Seymour, 1994). It is thus feasible that CD4+ and CD8+ T cell mediated cytotoxic reactions occur in RAS.

The aggregation of lymphocytes is likely to be mediated by the adhesion molecules intercellular adhesion molecule 1 (ICAM-1) and lymphocyte function-antigen-3 (LFA-3) binding to their counterpart ligands LFA-1 and CD-2 on lymphocytes (Hayrinen-Immonen *et al*, 1992; Verdickt *et al*, 1992). ICAM-1 is expressed on the submucosal capillaries and venules suggesting that it may control the trafficking of leucocytes into the submucosa (Savage *et al*, 1986; Eversole, 1994) while LFA-3 and its lingual counterpart CD-2 are likely to be involved in T-cell activation in RAS.

There is an elevation of serum levels of IL-6, IL-2R and soluble ICAM compared with controls, but these changes do not correlate with disease activity, and their pathogenic significance remains unclear (Yamamoto *et al*, 1994).

The HLA class I and II antigens appear on basal epithelial and then perilesional cells in all layers of the epithelium in the early phases of ulceration (Savage *et al*, 1986) presumably mediated by interferon gamma (IFN- $\gamma$ ) released by T-cells. Such MHC antigens may target these cells for attack by cytotoxic cells: indeed, activated mononuclear cells infiltrate the epithelium, especially the prickle cell layer (Honma, 1976) and are in contact with apoptotic prickle cells, which they and neutrophils sometimes phagocytose (Honma *et al*, 1985). Factor XIIIa – positive (FXIIIa+) cells are present in significantly greater numbers in RAS lesions than traumatic ulcers (Natah *et al*, 1997). The FXIIIa+ cells are present in the mononuclear – rich inflammation cell infiltrate and perivascular areas of the RAS lesions. As FXIIIa cells are considered to have antigen presenting functions these observations do suggest that the pathogenic trigger of RAS may indeed be some as yet unknown local factor. A local trigger for RAS may also be suggested by the increased number of activated mast cells in RAS as compared with traumatic ulcers (Natah *et al*, 1998).

Although there are cell-mediated immune changes within RAS, a B lymphocyte-mediated mechanism involving ADCC and, possibly, immune complexes have also been observed. Although circulating immune complexes have not reliably been demonstrated in RAS (Levinsky and Lehner, 1978; Lehner *et al*, 1979; Burton-Kee *et al*, 1981; Bagg *et al*, 1987), immune deposits do occur in lesional biopsy specimens (Ullman and Gorlin, 1978) especially in the stratum spinosum (Schroeder *et al*, 1984) and there can be evidence of leucocytoclastic or immune complex vasculitis (Lunderschmidt, 1982; Schroeder *et al*, 1984) leading to the non-specific deposition of immunoglobulins and complement.

Serum immunoglobulin (Ig) levels are generally normal although increases in serum IgA, IgG, IgD and IgE have all been reported in different groups of RAS patients (Lehner, 1969a,b; Ben Aryeh *et al*, 1976; Scully *et al*, 1983). Normal or reduced immunoglobulin levels have been observed in other groups of RAS patients. Serum levels of C9 have been reported to be raised in some patients (Adinolfi and Lehner, 1976; Lehner and Adinolfi, 1980) and, together with elevated serum levels of  $\beta_2$  microglobulin, (Scully, 1982) may represent a non-specific acute phase response. IgG subclass deficiencies were not observed in one study of UK patients with quiescent RAS (Porter *et al*, 1992b), but a significant reduction in IgG<sub>2</sub> (important in bacterial immunity) was observed in a study of Spanish patients (Vicente *et al*, 1996). The IgG<sub>2</sub> subclass deficiency may predispose to infection by (an unknown) bacteria and the resultant immune response raises IgG<sub>2</sub> antibody levels. However, oral ulceration is not a common feature of patients with known IgG<sub>2</sub> subclass deficiency and is uncommon in selective IgA deficiency – where IgG<sub>2</sub> and IgG<sub>4</sub> can

predispose to significant bacterial infection (Porter *et al*, 1992b). Salivary levels of total IgA are not abnormal in RAS (Lehner, 1969b; Bennet and Reade, 1982).

In the ulcerative phase of RAS salivary levels of IgG<sub>1-4</sub> as well as IgA<sub>1</sub> and IgA<sub>2</sub> may increase, but levels of IgA<sub>2</sub>, IgG<sub>1</sub>, IgG<sub>3</sub> remain increased in the non-ulcerative phase of disease (Sistig *et al*, 2002). However, it remains unclear if such changes have any true bearing upon the pathogenesis of RAS. If local humoral immunity was to be of relevance to the development of RAS it would be expected that patients with xerostomia would develop RAS-like ulcers – but they do not.

Salivary prostaglandin E<sub>2</sub> and epidermal growth factor (that may potentially aid mucosal healing) are reportedly reduced in the early stages of ulceration of RAS and then rise in the healing phase (Wu-Wang *et al*, 1995). A stage-dependent fall in salivary levels of vascular endothelial growth factor (VEGF) was also observed in patients with major (but not minor) RAS (Brozovic *et al*, 2002). It remains to be determined however, if the fluctuation in these potentially tissue-healing agents is of any true significance to the pathogenesis of RAS. It would seem more likely that these changes are merely the normal homeostatic response to the tissue damage of RAS. Such a notion would also explain the increase in levels of circulatory vascular cell adhesion molecule-1 (VCAM-1) and E-selectin (Healy *et al*, 1997) in patients with RAS.

The role of NK cells seems doubtful in the pathogenesis of RAS. In RAS levels of peripheral blood NK cells may be increased (Thomas *et al*, 1990) or similar to those of control subjects and NK subsets (e.g. CD16+, CD56+ and CD14+) are not altered in RAS (Pedersen and Pedersen, 1993). Likewise the function of NK cells in RAS shows no consistent pattern, baseline NK cell function is not notably altered in RAS (Pedersen and Pedersen, 1993; Ueta *et al*, 1993), although may be reduced during exacerbation of major RAS, late ulcerative stage of minor RAS (Sun *et al*, 1991) or indeed during quiescent phases of disease (Sistig *et al*, 2002).

In contrast to Behcet's disease, peripheral blood neutrophils of patients with RAS do not have any enhanced *in vitro* chemotaxis (Dagalis *et al*, 1987). Phagocytosis by neutrophils has likewise been reported to be not significantly defective, though one recent study reported that peripheral blood neutrophil haemotaxis and phagocytosis may be reduced in the ulcerative phase of RAS, although ingestion may be enhanced during the non-ulcerative phase (Sistig *et al*, 2002).

It is thus evident, that although there is no unifying theory of the immunopathogenesis of RAS, it would seem that the ulceration is because of the cytotoxic action of lymphocytes and monocytes upon the oral epithelium, but the trigger for these responses remains unclear. Patients with RAS may be liable to uncontrolled or excessive release of locally active inflammatory mediators, perhaps in response to local trauma (Bazrafshani *et al*, 2002a). Levels of IL-2, IFN- $\gamma$  and TNF- $\alpha$  mRNA are raised in lesional tissue of RAS (Buno *et al*, 1998), while levels of IL-10 mRNA were

reduced in the normal mucosa of RAS patients when compared with that of control subjects. Local levels of IFN- $\gamma$  are higher in the mucosa of RAS patients as compared with suitable controls, and in contrast IL-10 levels remain low in the former but not the latter. Local production of TNF- $\alpha$  is higher in RAS lesions than traumatic ulcers (Natah *et al*, 2000) and unstimulated peripheral blood leucocytes of patients with RAS produce much greater amounts of TNF- $\alpha$  than healthy controls (Taylor *et al*, 1992).

### Microbial aspects of RAS

A local microbial basis for RAS might explain why only the oral mucosa is affected in patients with RAS. However, as there is no evidence of clustering of affected patients (other than via vague family associations), an infectious basis for RAS seems unlikely.

Oral streptococci were previously suggested as important in the pathogenesis of RAS, either as direct pathogens or as antigenic stimuli in the genesis of antibodies that may conceivably cross-react with the oral mucosa (Martin *et al*, 1979; Lindemann *et al*, 1985). An L-form streptococcus isolated from RAS patients was initially typed as *S. sanguis* (Barile *et al*, 1963) (but later this was found to be *S. mitis* (Hoover and Greenspan, 1983). While some studies have disclosed elevated serum antibody titres to viridans streptococci among RAS patients, other investigations have yielded contradictory results (Barile *et al*, 1968; Donatsky, 1976). Furthermore, lymphocyte mitogenic responses to *S. sanguis* and *S. mitis* in RAS patients are not significantly different from those in control subjects (Barile *et al*, 1968; Gadol *et al*, 1985; Greenspan *et al*, 1985), although this may simply indicate that there is no predominant cell-mediated pathogenesis to RAS.

Cross-reactivity between a streptococcal 60–65 kDa hsp and the oral mucosa has been demonstrated and significantly elevated levels of serum antibodies to hsp have been detected in patients with RAS (Lehner *et al*, 1991). Lymphocytes of RAS patients have reactivity to peptide 91–105 (Hasan *et al*, 1995), and there is a significantly increased lymphoproliferative response to this peptide in the ulcerative stage as opposed to the period of remission. There is some cross-reactivity between the 65 kDa hsp and the 60 kDa human mitochondrial hsp. As monoclonal antibodies to part of the 65 kDa hsp of *Mycobacterium tuberculosis* react with *S. sanguis* (Lehner *et al*, 1991), it has been suggested that RAS may be a T-cell mediated response to antigens of *S. sanguis* that cross-react with the mitochondrial hsp and induce oral mucosal damage (Hasan *et al*, 1995).

An association between RAS and *Helicobacter pylori* has also been suggested, but the evidence suggests such a link is unlikely. A study of 39 patients with both RAS and HIV disease found that 71.8% of samples of ulcers had polymerase chain reaction (PCR) evidence of local *H. pylori* carriage, and that 68.8% of the patients had circulating antibodies to *H. pylori* (Birek *et al*, 1999). In contrast no raised frequency of local carriage of *H. pylori*

has been detected in four other studies of non-HIV infected individuals with RAS (Mravak-Stipetic *et al*, 1998; Pavelic *et al*, 2000; Shimoyama *et al*, 2000; Victoria *et al*, 2003) and no raised frequency of *H. pylori* seropositivity was observed in a study of patients from the UK (Porter *et al*, 1997).

It has been suggested that viruses may play a role in RAS (Hooks, 1978). An association with adenoviruses (Sallay *et al*, 1971, 1973, 1975) has been suggested, but these are ubiquitous organisms and the results need confirmation. The possible association of RAS with herpes viruses 1–6 has been reviewed (Pedersen, 1993). Herpes virus virions and antigens are not demonstrable in RAS (Dodd and Ruchman, 1950; Driscoll *et al*, 1961; Ship *et al*, 1961a; Griffin, 1963). RNA complimentary to herpes simplex virus (HSV) has been detected in circulating mononuclear cells (Eglin *et al*, 1982) and HSV-1 in circulating immune complexes (Hussain *et al*, 1986) in some RAS patients. However, serum levels of IFN- $\gamma$  which tend to rise in viral infections, are not increased in RAS (Hooks *et al*, 1979). HSV has not been successfully isolated from lesional material (Donatsky *et al*, 1977; Rothe *et al*, 1978), only about a third of RAS patients are HSV seropositive (Ship *et al*, 1967), and HSV is rarely detected in lesional tissue by PCR (Studd *et al*, 1991).

IgM and IgG antibodies to VZV may be elevated in some RAS patients (Pedersen and Hornsleth, 1993) suggesting an association between reactivation of VZV and RAS. Furthermore VZV-DNA can be detected in lesional tissue by PCR (Pedersen *et al*, 1993), but contamination is possible and may underlie these observations (Pedersen *et al*, 1993). The evidence on the potential therapeutic benefits of aciclovir also requires further investigation (Wormser *et al*, 1988; Pedersen, 1992).

Antibodies to CMV may be significantly elevated in some RAS patients (Pedersen and Hornsleth, 1993) and CMV-DNA has been detected in ill-defined oral ulceration in non-HIV-infected persons (Leimola-Virtanen *et al*, 1995). Additional support for a link with CMV was suggested by the detection of elevated levels of circulating antibodies to CMV in patients with RAS (Sun *et al*, 1996). However, CMV was not detected more frequently in RAS when compared with the titres in some of the same group of patients (Sun *et al*, 1996). Two further studies did not report an increased local carriage of CMV (as detected by PCR) in patients with RAS (Ghodratnama *et al*, 1997; Brice *et al*, 2000). Human herpes virus 6 (HHV-6) and HHV-7 DNA have not been demonstrated in RAS, but HHV-8 DNA is present in HIV-related oral ulcers (Di Alberti *et al*, 1998). However, the detection of herpes viruses in oral lesions may well not be of clinical relevance as these viruses are commonly latent, and can often be detected in oral fluids of even healthy individuals.

There are thus no definitive data to support the notion of RAS having an infectious aetiology. A viral cause seems unlikely. Current evidence suggests that cross-reactivity between bacterial heat shock proteins and epithelial components may play a role.

## Local factors predisposing to RAS

Local, physical trauma may initiate ulcers in susceptible people (Ross *et al*, 1958; Wray *et al*, 1981) and RAS are uncommon where mucosal keratinization is present (Sallay, 1968; Banoczy and Sallay, 1969) or in patients who smoke tobacco (Brookman, 1960; Dorsey, 1964; Chellemi *et al*, 1970; Shapiro *et al*, 1970; Axell and Henricsson, 1985a; Salonen *et al*, 1990). A recent study of 34 patients in Turkey with minor and/or major RAS found a significantly reduced frequency of tobacco smoking in individuals with RAS compared with an appropriate control group (8.8% vs 25.2% respectively) (Tuzun *et al*, 2000). In an effort to correct for any error caused by the self-reporting of patients about their tobacco habits, cotinine levels of 84 UK patients with RAS were compared with a group of 81 control subjects. The study found that the frequency of tobacco smokers was significantly less in RAS than control group. In addition, the mean cotinine levels of RAS patients who smoked, was significantly less than that of healthy control smokers (Atkin *et al*, 2002). Of course it may be that these individuals who did smoke may be less psychologically stressed than those did not smoke and thus some psychological trigger may be at play.

An increased frequency of recurrent oral ulceration because of use of SLS-containing toothpaste was previously reported, together with some reduction in ulceration following the use of SLS-free toothpaste. This supposed adverse effect of SLS does not reflect any increased oral retention of SLS (Fakhry-Smith *et al*, 1997). However, while another study also suggested that SLS-free dentifrice might reduce the number of ulcers that patients with RAS might develop (Chahine *et al*, 1997), a large double-blind study did not observe any significant change in the frequency or severity of RAS (Healy *et al*, 1999). In view of the widespread use of SLS in dentifrices it seems unlikely that this agent truly predisposes to, or causes, most RAS.

## Systemic factors predisposing to RAS

Most patients with RAS appear otherwise well. Oral ulceration similar in clinical appearance to RAS can arise in a number of disorders in which the patient has other systemic problems (Table 1). These include Behcet's disease (Hoopen-Neumann *et al*, 1999; Krause *et al*, 1999; Whallett *et al*, 1999; Al-Otaibi *et al*, 2005); mouth and genital ulcers with inflamed cartilage (MAGIC) syndrome (Orme *et al*, 1990; Le Thi *et al*, 1993); Sweet's syndrome (acute febrile neutrophilic dermatosis) (Delke *et al*, 1981; Driban and Alvarez, 1984; Mizoguchi *et al*, 1988; von den Driesch *et al*, 1989; Bruyn *et al*, 1990; von den Driesch, 1994; Femi-ano *et al*, 2003a, b); cyclic neutropenia (Lange and Jones, 1981; Scully *et al*, 1982; Sucker and Djawari, 1999; Lubitz *et al*, 2001), benign familial neutropenia (Porter *et al*, 1994); a periodic fever with aphthae, pharyngitis and adenitis (sometimes termed PFAPA syndrome) (Marshall *et al*, 1987; Feder, 2000; Kawashima *et al*, 2001) various nutritional deficiencies with or without underlying gastrointestinal disorders (Grattan and Scully, 1986; Eversole, 1994); and some other primary immunodeficiencies (Porter and Scully, 1993a-d) and secondary immunodeficiencies (Porter *et al*, 1994) including infection with HIV (MacPhail and Greenspan, 1997; Zakrzewska *et al*, 1997). Rarely, drugs such as NSAIDs can give rise to oral ulcers, similar to RAS, along with genital ulceration (Healy and Thornhill, 1995). Superficial ulceration similar to that of RAS can arise in response to nicorandil therapy (Cribier *et al*, 1998; Scully *et al*, 2001; Boulinguez *et al*, 2003). However, unlike RAS, this drug associated ulceration is not recurrent and resolves upon cessation of nicorandil therapy.

There is particular interest in the association between RAS and Behcet's disease. RAS-like ulceration can occur in Behcet's disease, however patients with the latter have multisystem disease, particularly affecting

**Table 1** Some disorders with similar characteristics to recurrent aphthous stomatitis

Disease	Comment
Behcet's disease	RAS-like ulceration is a cardinal feature of Behcet's disease. The ulceration may be more severe, and more likely to comprise major and/or herpetiform ulcers from RAS. Patients with Behcet's disease also have recurrent genital ulceration, cutaneous disease (usually papulopustular lesions or erythema nodosum), ocular disease (typically posterior uveitis) and a range of other gastrointestinal, neurological, renal, joint and haematological abnormalities
MAGIC syndrome	Comprises major aphthae and generalized inflamed cartilage. A variant of Behcet's disease
Sweet's syndrome	Also termed acute neutrophilic dermatosis. Affected patients have superficial ulceration similar to RAS. In addition, there is sudden onset fever, leucocytosis and well demarcated cutaneous, plum-coloured papules or plaques. Usually arises in middle-aged females. In 50% of patients there is an associated malignancy (e.g. acute myeloid leukaemia)
PFAPA syndrome	Comprises periodic fever, aphthae like oral mucosal ulceration, pharyngitis and cervical adenitis. Although rare, PFAPA tends to occur in young children. Tends to be self-limiting, and non-recurrent. May respond to cimetidine (via suppression of T lymphocyte function)
Cyclic neutropenia	Cyclic reduction in circulating levels of neutrophils about every 21 days. Affected patients develop oral ulceration, fever, cutaneous abscesses, upper respiratory tract infections and lymphadenopathy. Other oral complications include severe gingivitis and aggressive periodontitis. Treated with recombinant granulocyte colony stimulating factor (rG-CSF). Other neutropenias (e.g. chronic neutropenia) can give rise to superficial oral mucosal ulceration without any significant periodicity
HIV disease	Aphthous-like ulceration may occasionally arise in HIV disease. However, it remains unclear, if there is a significantly raised frequency of recurrent idiopathic oral ulceration in HIV disease

other mucocutaneous surfaces, the eyes (e.g. uveitis), and musculoskeletal, neurological, haematological, gastrointestinal, and other systems. As detailed in this paper, RAS does not have a notable geographic distribution, has no HLA associations similar to those of Behcet's disease and has few of the immunological abnormalities that arise in Behcet's disease. Unlike Behcet's disease, RAS does not lead to significant morbidity nor mortality (Mittal *et al*, 1985; Schreiner and Jorizzo, 1987; Arbesfeld and Kurban, 1988; Janowski *et al*, 1992; Stratigos *et al*, 1992).

Haematinic (iron, folic acid or vitamin B<sub>12</sub>) deficiencies may be twice as common in some groups of patients with RAS as in healthy control subjects (Wray *et al*, 1975; Challacombe *et al*, 1977a, 1983; Hutcheon *et al*, 1978; Tyldesley, 1983; Rogers and Hutton, 1986; Field *et al*, 1987; Porter *et al*, 1988). About 20% of patients with RAS may have a haematinic deficiency, although one US study did not report any haematinic problem (Olson *et al*, 1982). A study of Japanese patients with RAS suggested that affected individuals may have reduced dietary intake of iron and vitamin B<sub>1</sub>, which might underlie some of the aforementioned observations (Ogura *et al*, 2001). However, this investigation did not examine for correlations between dietary intake and haematological evidence of deficiency.

A novel study of Indian patients reported a correlation between high nitrate concentration of drinking water, resultant increased blood cytochrome b<sub>5</sub> reductase activity, and susceptibility to recurrent episodes of 'stomatitis' (presumed to be RAS) (Gupta *et al*, 1999). The rationale for these associations was that excess oxidation of NADH would predispose to oral mucosal inflammation (Courtois *et al*, 1994).

Deficiencies in vitamin B<sub>1</sub> (thiamine), B<sub>2</sub> and B<sub>6</sub> were observed in 28.2% of a group of patients with RAS from Scotland (Nolan *et al*, 1991), but the cause of the deficiencies was never established, and it is interesting to note, that this group of workers found vitamin B complex deficiencies in other patients with quite disparate clinical disease. Low levels of thiamine were observed in substantial number of adult patients from Israel with RAS (Haisraeli-Shalish *et al*, 1996). The reasons why thiamine deficiency could cause RAS are not known.

Reduced iron storage is the most commonly reported relevant abnormality, arising in up to 37% of reported patient groups (Porter *et al*, 1988, 1993) and can affect children (Field *et al*, 1987) as well as adults. Vitamin B<sub>12</sub> deficiency has been observed in 1–6% of adults or children with RAS (Field *et al*, 1987; Porter *et al*, 1988, 1993; Barnadas *et al*, 1997; Weusten and van de Weil, 1998) in developed countries, but a more recent study observed low serum vitamin B<sub>12</sub> levels in about 23% of a group of teenagers and adults with RAS (Piskin *et al*, 2002). The reasons for such a high frequency of vitamin B<sub>12</sub> deficiency in this group of patients were not established.

The present evidence thus suggests that some patients with RAS may have deficiency of one or more haematinics, or occasionally an unrelated vitamin. That these

deficiencies are truly important in the pathogenesis of RAS however, seems doubtful, as current data suggest that iron or vitamin supplement significantly only infrequently produce resolution of RAS (Nolan *et al*, 1991; Porter *et al*, 1992a; Haisraeli-Shalish *et al*, 1996).

Oral ulceration akin to RAS can be a feature of gluten sensitive enteropathy (GSE; coeliac disease) but only 5% of outpatients who initially present with RAS (Ferguson *et al*, 1976, 1980; Veloso and Saleiro, 1987; Nolan *et al*, 1991) have GSE. Folate deficiency can occur in RAS and reticulin antibodies (Ferguson *et al*, 1980) including IgA class reticulin antibodies (Merchant *et al*, 1986) and/or antigliadin antibodies (O'Mahony *et al*, 1985) are occasionally detected in patients with RAS. The haplotype of HLA-DRw10 and DQw1 has been suggested to predispose patients with GSE to RAS (Majorana *et al*, 1992; Meini *et al*, 1993), but this haplotype is not similar to the suggested HLA associations of RAS (see above). There may also be occasional patients who have RAS with no detectable clinical or histological evidence of coeliac disease on jejunal biopsy, yet who may respond to dietary withdrawal of gluten (Wray, 1981; Wright *et al*, 1986). However, the withdrawal of gluten does not often result in significant benefit (Hunter *et al*, 1993), may be difficult for the patient to comply with and may simply reflect the pronounced placebo response in RAS.

Hypersensitivity reactions to other identifiable exogenous antigens appear not to have a significant aetiological role in RAS. There is no consistent association with atopy (Tuft and Ettleson, 1956; Spouge and Diamond, 1963; Wilson, 1980; Eversole *et al*, 1982; Wray *et al*, 1982; Hay and Reade, 1984). Some RAS patients correlate the onset of ulcers with exposure to certain foods, but controlled studies have failed to disclose a causal role (Wilson, 1980) and dietary manipulation rarely produces clinical improvement (Spouge and Diamond, 1963; Eversole *et al*, 1982; Hay and Reade, 1984).

Aphthous-like ulceration can be a feature both of Crohn's disease (Rehberger *et al*, 1998; Hegarty *et al*, 2003) and ulcerative colitis (Thornhill *et al*, 1992) but this ulceration may reflect associated haematinic deficiencies.

It is unlikely that an association between RAS and zinc deficiency exists, although one reported patient with RAS and zinc deficiency did have clinical benefit from zinc supplementation (Endre, 1991).

A minority of women with RAS have cyclical oral ulceration related to the luteal phase of the menstrual cycle, presumed progestogen driven defective oral mucosal epithelial turnover (Dolby, 1968; Segal *et al*, 1974; Ferguson *et al*, 1984). However, a detailed review of relevant data did not find any association between RAS and altered female sex corticosteroids (McCartan and Sullivan, 1992). It is of course possible, that occasional patients with RAS-like disease may have autoimmune progesterone dermatitis (Moghadam *et al*, 1998).

Psychological illness has been suggested to initiate some episodes of RAS (Ship *et al*, 1961b; Miller and Ship, 1977) but there has never been an appropriate study to



examine this possible link. A study of Irish patients with RAS, using the hospital anxiety and depression (HAD) scale, observed an increased level of anxiety (and increased salivary cortisol levels) in some patients (McCartan *et al*, 1996). There are sparse data to suggest that antidepressant therapy may lessen symptoms of RAS (Yaacob and Ab, 1985). Nevertheless, no significant objective measure of neurosis has been observed in patients with RAS (Pedersen, 1989; Buajeeb *et al*, 1990).

### Clinical features

RAS comprises recurrent bouts of one or several rounded, shallow, painful ulcers at intervals of a few months to a few days. RAS has three main presentations – minor (MiRAS), major (MaRAS) or herpetiform (HU) ulcers.

The MiRAS is the most common (Field *et al*, 1992), affecting about 80% of patients with RAS: ulcers are round or oval usually < 5 mm in diameter with a grey-white pseudomembrane and an erythematous halo (Figure 4). MiRAS usually occur on the labial and buccal mucosa and floor of mouth, but are uncommon on the gingiva, palate or dorsum of the tongue. The ulcers heal within 10–14 days without scarring.

Major RAS is a rare, severe form of RAS, sometimes termed periaidenitis mucosa necrotica recurrens (Figure 5). These ulcers are oval and may exceed 1 cm in diameter and have a predilection for the lips, soft palate and fauces. The ulcers persist for up to 6 weeks and often heal with scarring. MaRAS usually has its onset after puberty and is chronic, persisting for up to 20 or more years (Scully and Porter, 1989).

Herpetiform ulceration is the least common variety and is characterized by multiple recurrent crops of widespread small, painful ulcers. As many as 100 ulcers may be present at a given time, each measuring 2–3 mm in diameter (Figure 6), although they tend to fuse producing large irregular ulcers. HU may have a predisposition for women and have a later age of onset than other types of RAS (Lehner, 1977; Scully and Porter, 1989).

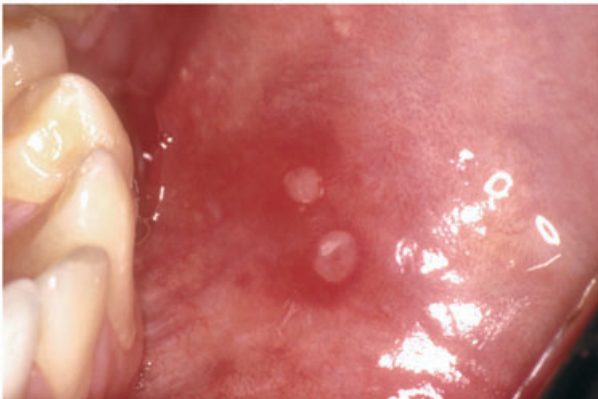


Figure 4 Typical minor aphthae (buccal mucosa, 22-year-old male)

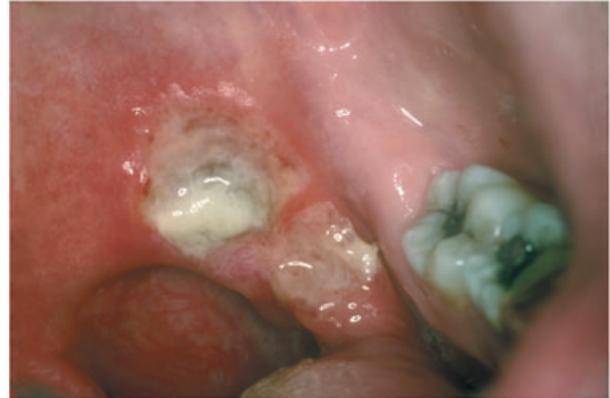

Figure 5 Major aphthae (soft palate and fauces, 32-year-old male)

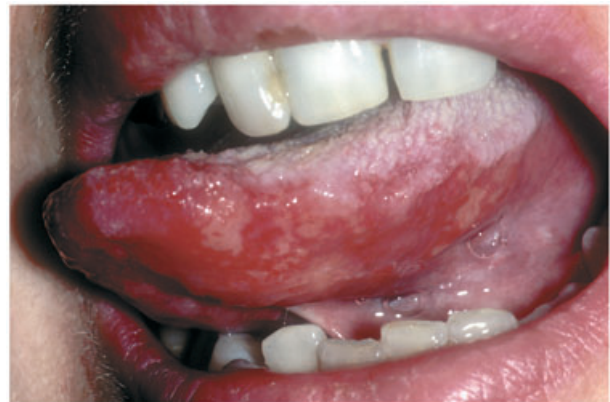

Figure 6 Herpetiform ulcers (tongue, 42-years-old female)

### Management

The diagnosis of RAS is invariably based upon the history and clinical findings. It is essential however to always consider a possible systemic cause, especially when adult patients suddenly develop what appears to be RAS. It is common practice to assess the full blood cell count, red cell folate and serum levels of ferritin (or equivalents) and vitamin B<sub>12</sub> (Porter *et al*, 1993). These investigations may also reveal potential gastrointestinal causes of oral ulceration but, in the absence of other manifestations, screening of patients with RAS for GSE is usually fruitless (Sedghizadeh *et al*, 2002).

There are currently few agents that have been found in randomized controlled trials (RCTs) to be clinically effective in the management of RAS. Nevertheless there is a need to provide patients with treatment to lessen the severity and/or frequency the associated painful symptoms, and reduce the likelihood of associated tissue damage. A wide variety of different agents have been suggested for the treatment of RAS (Table 2) (Porter and Scully, 2005). A consensus approach to the management of RAS was recently published (Scully *et al*, 2003). There is no curative treatment available. The best that can be achieved is to suppress the local immune

**Table 2** Some reported therapies for recurrent aphthous stomatitis (RAS)

Local physical treatment	Surgical removal Debridement Laser ablation Low dense ultrasound Chemical cautery (e.g. silver nitrate sticks) Physical barriers (e.g. cyanoacrylate adhesives)
Antimicrobials	Chlorhexidine gluconate (mouthrinse) Triclosan (mouthrinse) Topical tetracyclines (e.g. aureomycin, chlortetracycline, tetracycline)
Topical corticosteroids	Hydrocortisone hemisuccinate (pellets) Triamcinolone acetonide (in adhesive paste) Flucinonide (cream) Betamethasone valerate (mouthrinse) Betamethasone-17-benzoate (mouthrinse) Betamethasone-17-valerate (mouthrinse) Flumethasone pivalate (spray) Beclomethasone dipropionate (spray) Clobetasol propionate (cream) Mometasone furoate (cream)
Topical analgesics	Benzydamine hydrochloride (spray or mouthrinse) Topical anaesthetics (gel)
Other topical anti-inflammatory agents	Amlexanox Sodium cromoglycate (lozenges) Carbenoxolone sodium mouthrinse Azalestine Human alpha-2-interferon (cream) Ciclosporin (mouthrinse) Deglycyrhizinated liquorice Topical 5-aminosalicylic acid Prostaglandin E2 (gel) Topical granulocyte-macrophage colony-stimulating factor Aspirin mouthrinse Diclofenac in hyaluronase Sucralfate
Systemic immunosuppression	Prednisolone Azathioprine Levamisole Colchicine Thalidomide Pentoxifylline Dapsone Cimetidine

response, to ease discomfort and to prevent secondary infection. Presently topical corticosteroids, or topical chlorhexidine, or topical amlexanox if used with care, may be advantageous and systemic steroids or thalidomide would seem to be of possible clinical benefit in recalcitrant cases.

### Topical corticosteroids

Topical corticosteroids are the mainstay of RAS treatment in most countries (Siegel, 1999), but there are few well-controlled studies. There is only one systematic review of aspects of therapy of RAS (Porter and Scully, 2005), showing topical corticosteroids to be the most frequent means of treating RAS, although the available data do not demonstrate consistent benefits.

The corticosteroids vary in their degree of potency and may be given as mouth rinses, ointments, creams or in adhesive vehicles. Several different topical corticosteroids may reduce symptoms and hasten healing of RAS (Cooke and Armitage, 1960; Zegarelli *et al*, 1960; Merchant *et al*, 1978; Yeoman *et al*, 1978; Fisher, 1979; Pimlott and Walker, 1983; Scaglione *et al*, 1985; Miles *et al*, 1993). The major concern of possible adrenal suppression with long-term and/or repeated application has rarely been addressed, although there is evidence that even some of the more potent, such 0.05% fluocinonide in adhesive paste and betamethasone-17-valerate mouth rinse do not cause this problem (Porter *et al*, 2000).

Cyclodextrin-based corticosteroid mouthrinses may be useful as corticosteroids are better released from the cyclodextrin preparations than from carboxymethylcellulose-based pastes (Holbrook *et al*, 1998). Topical clobetasol propionate 0.05% in an adhesive denture paste seems to be even more effective and does not cause adverse effects (Lo *et al*, 2001), however, some authors disagree (Gonzales-Moles *et al*, 2002). A 0.1% solution of mometasone furoate has been suggested as an effective treatment of RAS (Teixeira *et al*, 1999). However, corticosteroids applied topically do not stop the recurrence of RAS.

### Other topical anti-inflammatory agents

#### *Benzydamine*

Benzydamine hydrochloride mouthwash may provide transient relief of painful symptoms but does not aid ulcer healing (Matthews *et al*, 1987) and is the only 'over the counter' topical agent (Edres *et al*, 1997) to have been formally assessed.

#### *Amlexanox*

Amlexanox has been suggested to be of some benefit in the treatment of RAS. Amlexanox has anti-allergic and anti-inflammatory activities, but its exact mode of action in the treatment of RAS remains unknown (Khandwala *et al*, 1997). One RCT of 335 patients with RAS in the US reported that 5% amlexanox significantly reduced the pain and time of healing. Other open studies have also suggested that amlexanox may result in some improvement in the signs and symptoms (Greer *et al*, 1993; Binnie *et al*, 1997; Khandwala *et al*, 1997).

#### *Cromoglycate*

Lozenges of the anti-allergic sodium cromoglycate may provide mild symptomatic relief (Dolby and Walker, 1975; Kowolik *et al*, 1978), but cromoglycate-containing toothpaste is not of benefit (Potts *et al*, 1984). In one double blind study carbenoxolone sodium mouthwash reduced the severity of RAS (Poswillo and Partridge, 1984).

#### *Others*

Topical non-corticosteroid based immunomodulatory agents which have been suggested to be of some benefit in the management of RAS include azelastine (Ueta

*et al*, 1994), human alpha-2-interferon in cream (Hamuryudan *et al*, 1990, 1991), topical ciclosporin (Eisen and Ellis, 1990), deglycyrhizinated liquorice (Das *et al*, 1989), topical 5-aminosalicylic acid (5-ASA; Collier *et al*, 1992), prostaglandin E2 (PGE2) gel (Taylor *et al*, 1993) and topical granulocyte-macrophage colony-stimulating factor (at least in HIV disease) (Herranz *et al*, 2000). However, few of these agents have been subjected to detailed clinical evaluation. Despite the knowledge that non-steroidal anti-inflammatory agents can cause oral ulceration, one study suggests that aspirin mouth rinse may reduce the pain of RAS (Angirish, 1996). A more detailed RTC observed that diclofenac in hyaluronase reduced the pain associated with RAS; indeed this preparation was more effective than lidocaine (Saxen *et al*, 1997).

In a double-blind study sucralfate mouth rinse was found to reduce the duration of pain and healing time of RAS (Ricer, 1989). A recent study of Italian patients suggested that 20% sucralfate is of some benefit in reducing the symptoms of RAS (Campisi *et al*, 1997).

A gel of silicone dioxide, aloe and allantoin – suggested to be useful in aiding wound healing – failed to significantly influence the clinical course of RAS (Garnick *et al*, 1998).

### Systemic immunomodulation

Patients with especially frequent or severe RAS may require systemic immunosuppressive therapy.

#### Corticosteroids

Prednisolone (Stanley, 1973) and/or azathioprine (Brown and Bottomley, 1990) can help healing of large ulcers but their long-term use should be avoided as the risk of their many associated adverse systemic side-effects will usually outweigh any clinical benefit.

#### Anti-TNF agents

As TNF- $\alpha$  may be implicated in the pathogenesis of RAS (see above), it might be expected that anti-TNF- $\alpha$  agents could be beneficial in the treatment of RAS.

Results of limited open studies from two centres suggested that the anti-TNF- $\alpha$  agent pentoxifylline (400 mg three times daily) significantly reduced the number of RAS for up to 9 months after 1 month of therapy (Pizarro *et al*, 1995, 1996; Wahba-Yahav, 1995a,b). Nevertheless, this interesting carry-over effect was not confirmed in a more recent study (Chandrasekhar *et al*, 1999) and furthermore, about 10% of treated patients had some degree of gastrointestinal upset. Thalidomide is effective and is proven to be the most reliably effective agent for the management of RAS, producing remission in almost 50% (Revuz *et al*, 1990). Thalidomide probably acts by virtue of its anti-TNF- $\alpha$  actions but, in one study, the reduction in blood TNF- $\alpha$  levels did not correlate with ulcer healing (Jacobson *et al*, 1997), suggesting that thalidomide could also be acting via its action upon Th<sub>1</sub>/Th<sub>2</sub> immune response and/or its anti-angiogenic properties (Porter and Jorge, 2002).

Open and double-blind studies on patients with HIV-related oral ulceration (Nicolau and West, 1990; Paterson *et al*, 1995), and non-HIV-related RAS (de Wazieres *et al*, 1999), and several case studies, confirm that thalidomide (e.g. 50–100 mg daily) is of clinical benefit (Mascaro *et al*, 1979; Grinspan, 1985; Grinspan *et al*, 1989). Nevertheless, its adverse effects seriously limit its application to short-term use. The main concern is the real risk of teratogenicity (just one tablet taken about day 20 of pregnancy can cause phocomelia) (Porter and Jorge, 2002), particularly as most females with RAS are of childbearing age. Polyneuropathy – typically a peripheral neuropathy, is an unpredictable but significant adverse effect of long-term thalidomide treatment, necessitating regular assessment of sensory nerve action potentials (SNAPs) (Porter and Jorge, 2002). Recently the risk of polyneuropathy has been shown to be minimal at doses below 25 mg day<sup>-1</sup> (Bastuji-Garin *et al*, 2002). Somnolence is common but can be reduced by dosing prior to sleep.

#### Levamisole

In the 1970s there was considerable interest in the possible benefits of levamisole in the management of RAS (Sun *et al*, 1994). The exact mode of action of levamisole remains unclear but the current data do not suggest this agent to be the clinical panacea once suggested. Five RCTs did not report a significant benefit with levamisole while four suggested that this agent might decrease the duration, number, size and frequency of ulceration of RAS. However the benefit, while statistically significant, was not likely to be of clinical significance, and the associated adverse effects (nausea, hyperosmia, dysgeusia and agranulocytosis) discourage its use (Lehner *et al*, 1976; Meyer *et al*, 1977; Drinnan and Fischman, 1978; Gier *et al*, 1978; Kaplan *et al*, 1978; Miller *et al*, 1978; Olson and Silverman, 1978). Levamisole combined with Chinese medical herbs has produced a decrease in the frequency, duration and number of oral ulcers (Sun *et al*, 2003).

#### Colchicine

Results of one open study and several smaller investigations suggested that colchicine may be of some clinical benefit in the management of RAS, causing a significant reduction in pain scores and frequency of self-reported ulcers (Gatot and Tovi, 1984; Ruah *et al*, 1988). It was suggested that colchicine shortens the recovery period of RAS by reducing neutrophil phagocytic function (Altinor *et al*, 2003). Unfortunately, not all patients benefit from colchicine, and at least 20% can have painful gastrointestinal symptoms or diarrhoea (Katz *et al*, 1994) and long-term use can induce infertility in young males. Combined colchicine and thalidomide therapy has been suggested to be of occasional benefit in the treatment of recalcitrant RAS (Genvo *et al*, 1984), although long-term therapy might be expected to give rise to clinically significant adverse side-effects.

### Others

Dapsone (Handfield-Jones *et al*, 1985), transfer factor (Schulkind *et al*, 1984), sulodexide (Femiano *et al*, 2003a,b) and gammaglobulin therapy (Kaloyannides, 1971) have been suggested to be beneficial but more detailed studies are needed to confirm this preliminary observation. Cimetidine has been suggested to be useful (Feder, 1992), (presumably via some suppression of T-cell function) but there is little supportive evidence.

## Antimicrobials

### Chlorhexidine

Despite there being no evidence that RAS is caused by any bacterial infection there are good data to indicate that some topical antimicrobials (particularly chlorhexidine gluconate) will lessen the duration of ulceration of RAS. Several RCTs have established that chlorhexidine either as a 0.2% w/w mouth rinse or a 1% gel can reduce the duration of ulcers and increase the number of ulcer-free days (Addy *et al*, 1974, 1976; Addy, 1977; Hunter and Addy, 1987) in patients with RAS. However, one study found little objective benefit of chlorhexidine mouth rinse over placebo (Matthews *et al*, 1987).

### Tetracyclines

Placebo-controlled studies of topical tetracyclines (e.g. aureomycin, chlortetracycline and tetracycline) suggest that these may also reduce healing times and/or reduce the associated pain of RAS (Guggenheimer *et al*, 1968; Graykowski and Kingman, 1978; Denman and Schiff, 1979; Hayrinen-Immonen *et al*, 1994). An open study indicated that the local application of doxymycin under cyanoacrylate caused rapid healing of the ulceration of RAS (Ylikontiola *et al*, 1997). However this approach is of limited clinical application (dental professionals or patients have to apply the agent to the lesions) (Ludlow *et al*, 2000; Kutcher *et al*, 2001) and the other agents may cause dysgeusia, oral candidosis and a burning-like sensation of the pharynx, and/or are not suitable for young children who might ingest the antibiotic leading to later dental staining. One placebo-controlled study of 25 patients with RAS suggested that the oxygenating agent carbamide peroxide in glycerol was not effective in the treatment of RAS (Miller and Chilton, 1980). In a study by Skaare *et al* (1996a) triclosan-containing mouthrinse was found to significantly reduce the number of ulcers, relief pain and shorten the ulcerative phase. It has been suggested that triclosan has not only antimicrobial, but also anti-inflammatory and analgesic effects (Kjaerheim *et al*, 1995).

## Other agents

Monoamine oxidase inhibitor (antidepressant) therapy in the treatment of three patients with RAS produced benefit (Rosenthal, 1984; Lejonc and Fourestie, 1985) but this may have been because of accompanying dietary modifications rather than any alteration in psychological status. The lack of association between

significant mental illness and RAS suggests that therapeutic approaches of this type are likely to be fruitless.

There are reports that systemic zinc sulphate (Orbak *et al*, 2003), irsogladine maleate (Hara *et al*, 1999), *Eupatorium laevigatum* (Paulo *et al*, 2000) paste and photophoresis of oxolin ointment (Prikuls, 2000) may be of benefit in the treatment of RAS, but any real benefit from these agents is unclear.

## Physical treatment

A range of physical methods of locally managing RAS have been proposed for the treatment of RAS, but most are impractical. Suggested physical therapies have included surgical removal, debridement or laser ablation of ulcers (Potoky, 1981; Howell *et al*, 1988; Convissar and Massoumi-Sourey, 1992), low dense ultrasound (Brice, 1997) chemical cautery (Debacterol) (Rhodus and Bereuter, 1998) and the use of physical barriers such as cyanoacrylate adhesives (Yel *et al*, 1994).

## Conclusion

Although common, RAS remains an elusive disorder, as the precise aetiology and long-term behaviour of disease are ill understood. No therapies are available to stop the bouts of ulceration and not give rise to adverse side-effects. The management of RAS is thus presently directed towards lessening physical trauma to the oral mucosa, and reducing the inflammatory response.

## References

- Addy M (1977). Hibitane in the treatment of aphthous ulceration. *J Clin Periodontol* **4**: 108–116.
- Addy M, Tapper-Jones L, Seal M (1974). Trial of astringent and antibacterial mouthwashes in the management of recurrent aphthous ulceration. *Br Dent J* **136**: 452–455.
- Addy M, Carpenter R, Roberts WR (1976). Management of recurrent aphthous ulceration. A trial of chlorhexidine gluconate gel. *Br Dent J* **141**: 118–120.
- Adinolfi M, Lehner T (1976). Acute phase proteins and C9 in patients with Behcet's syndrome and aphthous ulcers. *Clin Exp Immunol* **25**: 36–39.
- Al-Otaibi LM, Porter SR, Poate TW (2005). Behcet's disease: a review. *J Dent Res* **84**: 209–222.
- Albanidon-Farmaki E, Kayavis IG, Polymenidis Z, Papanayoton P (1988). HLA-A, B, C, and DR antigens in recurrent oral ulcers. *Ann Dent* **47**: 5–8.
- Altinor S, Ozturkcan S, Hah MM (2003). The effects of colchicine on neutrophil function in subjects with recurrent aphthous stomatitis. *J Eur Acad Dermatol Venereol* **17**: 469–470.
- Angirish A (1996). Aspirin-mouthwash relieves pain of oral lesions. *J R Soc Health* **116**: 105–106.
- Arbesfeld SJ, Kurban AK (1988). Behcet's disease. New perspectives on an enigmatic syndrome. *J Am Acad Dermatol* **19**: 767–779.
- Atkin PA, Xu X, Thornhill MH (2002). Minor recurrent aphthous stomatitis and smoking: an epidemiological study measuring plasma cotinine. *Oral Dis* **8**: 173–176.

- Axell T (1975). A preliminary report on prevalences of oral mucosal lesions in a Swedish population. *Community Dent Oral Epidemiol* **3**: 143–145.
- Axell T, Henricsson V (1985a). Association between recurrent aphthous ulcers and tobacco habits. *Scand J Dent Res* **93**: 239–242.
- Axell T, Henricsson V (1985b). The occurrence of recurrent aphthous ulcers in an adult Swedish population. *Acta Odontol Scand* **43**: 121–125.
- Bachtiar EW, Cornain S, Siregar B, Raharjo TW (1998). Decreased CD4+/CD8+ ratio in major type of recurrent aphthous ulcers: comparing major to minor types of ulcers. *Asian Pac J Allergy Immunol* **16**: 75–79.
- Bagg J, Williams BD, Amos N, Dagalys P, Walker DM (1987). Absence of circulating IgG immune complexes in minor recurrent aphthous ulceration. *J Oral Pathol* **16**: 53–56.
- Banoczy J, Sallay K (1969). Comparative cytologic studies in patients with recurrent aphthae and leukoplakia. *J Dent Res* **48**: 271–273.
- Barile M, Graykowski E, Driscoll E, Riggs D (1963). L-form of bacteria isolated from recurrent aphthous stomatitis lesions. *Oral Surg* **16**: 1395–1402.
- Barile M, Francis T, Graykowski EA (1968). *Streptococcus sanguis* in the pathogenesis of recurrent aphthous stomatitis. In: Guze LB, ed. *Microbial protoplasts, spheroplasts and L-forms*. Williams and Wilkins: Baltimore, pp. 444.
- Barnadas MA, Remacha A, Condomines J, de Moragas JM (1997). [Hematologic deficiencies in patients with recurrent oral aphthae]. *Med Clin (Barc)* **109**: 85–87.
- Bastuji-Garin S, Ochonicky S, Bouche P et al (2002). Incidence and risk factors for thalidomide neuropathy: a prospective study of 135 dermatological patients. *J Invest. Dermatol.* **119**: 1020–1026.
- Bazrafshani MR, Hajeer AH, Ollier WE, Thornhill MH (2002a). IL-1B and IL-6 gene polymorphisms encode significant risk for the development of recurrent aphthous stomatitis (RAS). *Genes Immun* **3**: 302–305.
- Bazrafshani MR, Hajeer AH, Ollier WE, Thornhill MH (2002b). Recurrent aphthous stomatitis and gene polymorphisms for the inflammatory markers TNF-alpha, TNF-beta and the vitamin D receptor: no association detected. *Oral Dis* **8**: 303–307.
- Ben Aryeh H, Malberger E, Gutman D, Szargel R, Anavi Y (1976). Salivary IgA and serum IgG and IgA in recurrent aphthous stomatitis. *Oral Surg Oral Med Oral Pathol* **42**: 746–752.
- Bennet KR, Reade PC (1982). Salivary immunoglobulin A levels in normal subjects, tobacco smokers, and patients with minor aphthous ulceration. *Oral Surg Oral Med Oral Pathol* **53**: 461–465.
- Binnie WH, Curro FA, Khandwala A, Van Inwegen RG (1997). Amlexanox oral paste: a novel treatment that accelerates the healing of aphthous ulcers. *Compend Contin Educ Dent* **18**: 1116–1124.
- Birek C, Grandhi R, McNeill K, Singer D, Ficarra G, Bowden G (1999). Detection of *Helicobacter pylori* in oral aphthous ulcers. *J Oral Pathol Med* **28**: 197–203.
- Boulinguez S, Sommet A, Bedane C, Viraben R, Bonnetblanc JM (2003). Oral nicorandil-induced lesions are not aphthous ulcers. *J Oral Pathol Med* **32**: 482–485.
- Brice SL (1997). Clinical evaluation of the use of low-intensity ultrasound in the treatment of recurrent aphthous stomatitis. *Oral Surg Oral Med Oral Pathol Oral Radiol Endod* **83**: 14–20.
- Brice SL, Cook D, Leahy M, Huff JC, Weston WL (2000). Examination of the oral mucosa and peripheral blood cells of patients with recurrent aphthous ulceration for human herpesvirus DNA. *Oral Surg Oral Med Oral Pathol Oral Radiol Endod* **89**: 193–198.
- Brookman R (1960). Relief of cancer sores on resumption of cigarette smoking. *Calif Med* **93**: 235–236.
- Brown RS, Bottomley WK (1990). Combination immunosuppressant and topical steroid therapy for treatment of recurrent major aphthae. A case report. *Oral Surg Oral Med Oral Pathol* **69**: 42–44.
- Brozovic S, Vucicevic-Boras V, Mravak-Stipetic M, Jukic S, Kleinheinz J, Lukac J (2002). Salivary levels of vascular endothelial growth factor (VEGF) in recurrent aphthous ulceration. *J Oral Pathol Med* **31**: 106–108.
- Bruyn GA, Missier ET, Toonstra J, Bijlsma JW (1990). Sweet's syndrome. *Neth J Med* **36**: 62–68.
- Buajeeb W, Laohapand P, Vongsavan N, Kraivaphan P (1990). Anxiety in recurrent aphthous stomatitis patients. *J Dent Assoc Thai* **40**: 253–258.
- Buno IJ, Huff JC, Weston WL, Cook DT, Brice SL (1998). Elevated levels of interferon gamma, tumor necrosis factor alpha, interleukins 2, 4, and 5, but not interleukin 10, are present in recurrent aphthous stomatitis. *Arch Dermatol* **134**: 827–831.
- Burnett PR, Wray D (1985). Lytic effects of serum and mononuclear leukocytes on oral epithelial cells in recurrent aphthous stomatitis. *Clin Immunol Immunopathol* **34**: 197–204.
- Burton-Kee JE, Mowbray JF, Lehner T (1981). Different cross-reacting circulating immune complexes in Behcet's syndrome and recurrent oral ulcers. *J Lab Clin Med* **97**: 559–567.
- Campisi G, Spadari F, Salvato A (1997). [Sucralfate in odontostomatology. Clinical experience]. *Minerva Stomatol* **46**: 297–305.
- Chahine L, Sempson N, Wagoner C (1997). The effect of sodium lauryl sulfate on recurrent aphthous ulcers: a clinical study. *Compend Contin Educ Dent* **18**: 1238–1240.
- Challacombe SJ, Barkhan P, Lehner T (1977a). Haematological features and differentiation of recurrent oral ulceration. *Br J Oral Surg* **15**: 37–48.
- Challacombe SJ, Scully C, Keevil B, Lehner T (1983). Serum ferritin in recurrent oral ulceration. *J Oral Pathol* **12**: 290–299.
- Chandrasekhar J, Liem AA, Cox NH, Paterson AW (1999). Oxypentifylline in the management of recurrent aphthous oral ulcers: an open clinical trial. *Oral Surg Oral Med Oral Pathol Oral Radiol Endod* **87**: 564–567.
- Chellemi S, Olson D, Shapiro S (1970). The association between smoking and aphthous ulcers: a preliminary report. *Oral Surg* **29**: 832–836.
- Collier PM, Neill SM, Copeman PW (1992). Topical 5-aminosalicylic acid: a treatment for aphthous ulcers. *Br J Dermatol* **126**: 185–188.
- Convissar RA, Massoumi-Sourey M (1992). Recurrent aphthous ulcers: etiology and laser ablation. *Gen Dent* **40**: 512–515.
- Cooke B, Armitage P (1960). Recurrent Mikulicz's aphthae treated with topical hydrocortisone hemisuccinate sodium. *Brookhaven Symp Biol* **5175**: 764–766.
- Courtois P, Vanden Abeele A, Moguilevsky N, Amrani N, Pourtois M (1994). Hypotheses for a re-evaluation of peroxidase activity in the oral inflammation: NAD(P)H-dependent hypohalite reduction in human neutrophils. *Acta Stomatol Belg* **91**: 73–81.

- Cribrier B, Marquart-Elbaz C, Lipsker D, Alt M, Grosshans E (1998). Chronic buccal ulceration induced by nicorandil. *Br J Dermatol* **138**: 372–373.
- Crivelli MR, Aguas S, Adler I, Quarracino C, Bazerque P (1988). Influence of socioeconomic status on oral mucosa lesion prevalence in schoolchildren. *Community Dent Oral Epidemiol* **16**: 58–60.
- Dagalís P, Bagg J, Walker DM (1987). Spontaneous migration and chemotactic activity of neutrophil polymorphonuclear leukocytes in recurrent aphthous ulceration. *Oral Surg Oral Med Oral Pathol* **64**: 298–301.
- Das SK, Das V, Gulati AK, Singh VP (1989). Deglycyrrhizinated liquorice in aphthous ulcers. *J Assoc Physicians India* **37**: 647.
- Delke I, Veridiano NP, Tancer ML, Gomez L, Diamond I (1981). Sweet syndrome with involvement of the female genital tract. *Obstet Gynecol* **58**: 394–396.
- Denman AM, Schiff AA (1979). Recurrent oral ulceration treated with Mysteclin: a controlled study. *Br Med J* **1**: 1248–1249.
- Di Alberti L, Porter SR, Piatelli A, Scully CM, Teo CG (1998). Human herpesvirus 8 and sarcoidosis. *Lancet* **351**: 1589–1590.
- Dodd K, Ruchman I (1950). Herpes simplex virus not the aetiologic agent of recurrent stomatitis. *Pediatrics* **5**: 883–887.
- Dolby AE (1968). Recurrent Mikulicz's oral aphthae. Their relationship to the menstrual cycle. *Br Dent J* **124**: 359–360.
- Dolby AE (1969). Recurrent aphthous ulceration. Effect of sera and peripheral blood lymphocytes upon oral epithelial tissue culture cells. *Immunology* **17**: 709–714.
- Dolby AE, Walker DM (1975). A trial of cromoglycic acid in recurrent aphthous ulceration. *Br J Oral Surg* **12**: 292–295.
- Donatsky O (1973). Epidemiologic study on recurrent aphthous ulcerations among 512 Danish dental students. *Community Dent Oral Epidemiol* **1**: 37–40.
- Donatsky O (1976). A leucocyte migration study on the cell-mediated immunity against adult human oral mucosa and streptococcal antigens in patients with recurrent aphthous stomatitis. *Acta Pathol Microbiol Scand [C]* **84**: 227–234.
- Donatsky O, Justesen T, Lind K, Vestergaard BF (1977). Microorganisms in recurrent aphthous ulcerations. *Scand J Dent Res* **85**: 426–433.
- Dorsey C (1964). More observation on relief of aphthous stomatitis on resumption of cigarette smoking. *Calif Med* **101**: 377–378.
- Driban NE, Alvarez MA (1984). Oral manifestations of Sweet's syndrome. *Dermatologica* **169**: 102–103.
- von den Driesch DP (1994). Sweet's syndrome (acute febrile neutrophilic dermatosis). *J Am Acad Dermatol* **31**: 535–556.
- von den Driesch DP, Gomez RS, Kiesewetter F, Hornstein OP (1989). Sweet's syndrome: clinical spectrum and associated conditions. *Cutis* **44**: 193–200.
- Drinnan AJ, Fischman SL (1978). Randomized, double-blind study of levamisole in recurrent aphthous stomatitis. *J Oral Pathol* **7**: 414–417.
- Driscoll EJ, Ship II, Barow S, Stanley HR, Utz JP (1961). Chronic aphthous stomatitis, herpes labialis and related conditions. *Ann Intern Med* **50**: 1475–1496.
- Edres MA, Scully C, Gelbier M (1997). Use of proprietary agents to relieve recurrent aphthous stomatitis. *Br Dent J* **182**: 144–146.
- Eglin RP, Lehner T, Subak-Sharpe JH (1982). Detection of RNA complementary to herpes-simplex virus in mononuclear cells from patients with Behcet's syndrome and recurrent oral ulcers. *Lancet* **2**: 1356–1361.
- Eisen D, Ellis CN (1990). Topical cyclosporine for oral mucosal disorders. *J Am Acad Dermatol* **23**: 1259–1263.
- Embil JA, Stephens RG, Manuel FR (1975). Prevalence of recurrent herpes labialis and aphthous ulcers among young adults on six continents. *Can Med Assoc J* **113**: 627–630.
- Endre L (1991). Recurrent aphthous ulceration with zinc deficiency and cellular immune deficiency. *Oral Surg Oral Med Oral Pathol* **72**: 559–561.
- Eversole LR (1994). Immunopathology of oral mucosal ulcerative, desquamative, and bullous diseases. Selective review of the literature. *Oral Surg Oral Med Oral Pathol* **77**: 555–571.
- Eversole LR, Shopper TP, Chambers DW (1982). Effects of suspected foodstuff challenging agents in the etiology of recurrent aphthous stomatitis. *Oral Surg Oral Med Oral Pathol* **54**: 33–38.
- Fahmy MS (1976). Recurrent aphthous ulcerations in a mixed Arab community. *Community Dent Oral Epidemiol* **4**: 160–164.
- Fakhry-Smith S, Din C, Nathoo SA, Gaffar A (1997). Clearance of sodium lauryl sulphate from the oral cavity. *J Clin Periodontol* **24**: 313–317.
- Feder HM Jr (1992). Cimetidine treatment for periodic fever associated with aphthous stomatitis, pharyngitis and cervical adenitis. *Pediatr Infect Dis J* **11**: 318–321.
- Feder HM Jr (2000). Periodic fever, aphthous stomatitis, pharyngitis, adenitis: a clinical review of a new syndrome. *Curr Opin Pediatr* **12**: 253–256.
- Femiano F, Gombos F, Scully C (2003a). Sweet's syndrome: Recurrent oral ulceration, pyrexia, thrombophlebitis, and cutaneous lesions. *Oral Surg Oral Med Oral Pathol Oral Radiol Endod* **95**: 324–327.
- Femiano F, Gombos F, Scully C (2003b). Recurrent aphthous stomatitis unresponsive to topical corticosteroid: a study of the comparative therapeutic effects of systemic prednisolone and systemic sulodexide. *Int J Dermatol* **44**: 888–889.
- Ferguson R, Basu MK, Asquith P, Cooke WT (1976). Jejunal mucosal abnormalities in patients with recurrent aphthous ulceration. *Br Med J* **1**: 11–13.
- Ferguson MM, Wray D, Carmichael HA, Russell RI, Lee FD (1980). Coeliac disease associated with recurrent aphthae. *Gut* **21**: 223–226.
- Ferguson MM, Carter J, Boyle P (1984). An epidemiological study of factors associated with recurrent aphthae in women. *J Oral Med* **39**: 212–217.
- Field EA, Rotter E, Speechley JA, Tyldesley WR (1987). Clinical and haematological assessment of children with recurrent aphthous ulceration. *Br Dent J* **163**: 19–22.
- Field EA, Brookes V, Tyldesley WR (1992). Recurrent aphthous ulceration in children—a review. *Int J Paediatr Dent* **2**: 1–10.
- Fisher N (1979). Bextasol and aphthous ulcers. *Br Med J* **1**: 1357.
- Gadol N, Greenspan JS, Hoover CI, Olson JA (1985). Leukocyte migration inhibition in recurrent aphthous ulceration. *J Oral Pathol* **14**: 121–132.
- Gallina G, Cumbo V, Messina P, Caruso C (1985). HLA-A, B, C, DR, MT, and MB antigens in recurrent aphthous stomatitis. *Oral Surg Oral Med Oral Pathol* **59**: 364–370.
- Garcia-Pola Vallejo MJ, Martinez Diaz-Canel AI, Garcia Martin JM, Gonzalez GM (2002). Risk factors for oral soft tissue lesions in an adult Spanish population. *Community Dent Oral Epidemiol* **30**: 277–285.
- Garnick JJ, Singh B, Winkley G (1998). Effectiveness of a medicament containing silicon dioxide, aloe, and allantoin on aphthous stomatitis. *Oral Surg Oral Med Oral Pathol Oral Radiol Endod* **86**: 550–556.

- Gatot A, Tovi F (1984). Colchicine therapy in recurrent oral ulcers. *Arch Dermatol* **120**: 994.
- Genvo MF, Faure M, Thivolet J (1984). [Treatment of aphthosis with thalidomide and with colchicine]. *Dermatologica* **168**: 182–188.
- Ghodratnama F, Riggio MP, Wray D (1997). Search for human herpesvirus 6, human cytomegalovirus and varicella zoster virus DNA in recurrent aphthous stomatitis tissue. *J Oral Pathol Med* **26**: 192–197.
- Gier RE, George B, Wilson T *et al* (1978). Evaluation of the therapeutic effect of levamisole in treatment of recurrent aphthous stomatitis. *J Oral Pathol* **7**: 405–413.
- Gonzales-Moles MA, Morlaes P, Rodrigues-Archilla A (2002). The treatment of oral aphthous ulceration or erosive lichen planus with topical clobetasol propionate in three preparations. *J Oral Pathol Med* **31**: 284–285.
- Grattan CE, Scully C (1986). Oral ulceration: a diagnostic problem. *Br Med J (Clin Res Ed)* **292**: 1093–1094.
- Graykowski EA, Kingman A (1978). Double-blind trial of tetracycline in recurrent aphthous ulceration. *J Oral Pathol* **7**: 376–382.
- Greenspan JS, Gadol N, Olson JA, Talal N (1981). Antibody-dependent cellular cytotoxicity in recurrent aphthous ulceration. *Clin Exp Immunol* **44**: 603–610.
- Greenspan JS, Gadol N, Olson JA *et al* (1985). Lymphocyte function in recurrent aphthous ulceration. *J Oral Pathol* **14**: 592–602.
- Greer RO Jr, Lindenmuth JE, Juarez T, Khandwala A (1993). A double-blind study of topically applied 5% amlexanox in the treatment of aphthous ulcers. *J Oral Maxillofac Surg* **51**: 243–248.
- Griffin J (1963). Fluorescent antibody study of herpes simplex virus lesions and recurrent aphthae. *Oral Surg* **16**: 945–952.
- Grinspan D (1985). Significant response of oral aphthosis to thalidomide treatment. *J Am Acad Dermatol* **12**: 85–90.
- Grinspan D, Blanco GF, Aguero S (1989). Treatment of aphthae with thalidomide. *J Am Acad Dermatol* **20**: 1060–1063.
- Guggenheimer J, Brightman VJ, Ship II (1968). Effect of chlortetracycline mouthrinses on the healing of recurrent aphthous ulcers: a double-blind controlled trial. *J Oral Ther Pharmacol* **4**: 406–408.
- Gupta SK, Gupta RC, Seth AK *et al* (1999). Epidemiological evaluation of recurrent stomatitis, nitrates in drinking water, and cytochrome b5 reductase activity. *Am J Gastroenterol* **94**: 1808–1812.
- Haisraeli-Shalish M, Livneh A, Katz J, Doolman R, Sela BA (1996). Recurrent aphthous stomatitis and thiamine deficiency. *Oral Surg Oral Med Oral Pathol Oral Radiol Endod* **82**: 634–636.
- Hamuryudan V, Yurdakul S, Serdaroglu S, Tuzun Y, Rosenkaimer F, Yazici H (1990). Topical alpha interferon in the treatment of oral ulcers in Behcet's syndrome: a preliminary report. *Clin Exp Rheumatol* **8**: 51–54.
- Hamuryudan V, Yurdakul S, Rosenkaimer F, Yazici H (1991). Inefficacy of topical alpha interferon in the treatment of oral ulcers of Behcet's syndrome: a randomized, double blind trial. *Br J Rheumatol* **30**: 395–396.
- Handfield-Jones S, Allen BR, Littlewood SM (1985). Dapsone use with oral-genital ulcers. *Br J Dermatol* **113**: 501.
- Hara A, Murata T, Uemura R *et al* (1999). Identification of connexins in human oral mucosa and therapeutic effect of irsogladine maleate on aphthous stomatitis. *J Gastroenterol* **34**: 1–6.
- Hasan A, Childerstone A, Pervin K *et al* (1995). Recognition of a unique peptide epitope of the mycobacterial and human heat shock protein 65–60 antigen by T cells of patients with recurrent oral ulcers. *Clin Exp Immunol* **99**: 392–397.
- Hay KD, Reade PC (1984). The use of an elimination diet in the treatment of recurrent aphthous ulceration of the oral cavity. *Oral Surg Oral Med Oral Pathol* **57**: 504–507.
- Hayrinen-Immonen R, Nordstrom D, Malmstrom M, Hietanen J, Konttinen YT (1991). Immune-inflammatory cells in recurrent oral ulcers (ROU). *Scand J Dent Res* **99**: 510–518.
- Hayrinen-Immonen R, Malmstrom M, Nordstrom D, Sorsa T, Konttinen YT (1992). Distribution of adhesion receptors in recurrent oral ulcers. *J Oral Pathol Med* **21**: 199–202.
- Hayrinen-Immonen R, Sorsa T, Pettila J, Konttinen YT, Teronen O, Malmstrom M (1994). Effect of tetracyclines on collagenase activity in patients with recurrent aphthous ulcers. *J Oral Pathol Med* **23**: 269–272.
- Hayward AR, Herberger M, Lazslo M (1986). Cellular interactions in the lysis of varicella-zoster virus infected human fibroblasts. *Clin Exp Immunol* **63**: 141–146.
- Healy CM, Thornhill MH (1995). An association between recurrent oro-genital ulceration and non-steroidal anti-inflammatory drugs. *J Oral Pathol Med* **24**: 46–48.
- Healy CM, Enobakhare B, Haskard DO, Thornhill MH (1997). Raised levels of circulating VCAM-1 and circulating E-selectin in patients with recurrent oral ulceration. *J Oral Pathol Med* **26**: 23–28.
- Healy CM, Paterson M, Joyston-Bechal S, Williams DM, Thornhill MH (1999). The effect of a sodium lauryl sulfate-free dentifrice on patients with recurrent oral ulceration. *Oral Dis* **5**: 39–43.
- Hegarty A, Hodgson T, Porter S (2003). Thalidomide for the treatment of recalcitrant oral Crohn's disease and orofacial granulomatosis. *Oral Surg Oral Med Oral Pathol Oral Radiol Endod* **95**: 576–585.
- Herranz P, Arribas JR, Navarro A *et al* (2000). Successful treatment of aphthous ulcerations in AIDS patients using topical granulocyte-macrophage colony-stimulating factor. *Br J Dermatol* **142**: 171–176.
- Holbrook WP, Kristmundsdottir T, Loftsson T (1998). Aqueous hydrocortisone mouthwash solution: clinical evaluation. *Acta Odontol Scand* **56**: 157–160.
- Honma T (1976). Electron microscopic study on the pathogenesis of recurrent aphthous ulceration as compared to Behcet's syndrome. *Oral Surg Oral Med Oral Pathol* **41**: 366–377.
- Honma T, Saito T, Fujioka Y (1985). Possible role of apoptotic cells of the oral epithelium in the pathogenesis of aphthous ulceration. *Oral Surg Oral Med Oral Pathol* **59**: 379–387.
- Hooks JJ (1978). Possibility of a viral etiology in recurrent aphthous ulcers and Behcet's syndrome. *J Oral Pathol* **7**: 353–364.
- Hooks JJ, Moutsopoulos HM, Geis SA, Stahl NI, Decker JL, Notkins AL (1979). Immune interferon in the circulation of patients with autoimmune disease. *N Engl J Med* **301**: 5–8.
- Hoopen-Neumann H, van der Meijden WI, van Hagen PM (1999). [Behcet's disease]. *Ned Tijdschr Geneesk* **143**: 177–180.
- Hoover CI, Greenspan JS (1983). Immunochemical comparison of cell-wall antigens of various viridans streptococci, including strain 2A2+3 hot from recurrent oral aphthous ulceration in man. *Arch Oral Biol* **28**: 917–922.
- Howell RM, Cohen DM, Powell GL, Green JG (1988). The use of low energy laser therapy to treat aphthous ulcers. *Ann Dent* **47**: 16–18.
- Hunter L, Addy M (1987). Chlorhexidine gluconate mouthwash in the management of minor aphthous ulceration. A double-blind, placebo-controlled cross-over trial. *Br Dent J* **162**: 106–110.

- Hunter IP, Ferguson MM, Scully C, Galloway AR, Main AN, Russell RI (1993). Effects of dietary gluten elimination in patients with recurrent minor aphthous stomatitis and no detectable gluten enteropathy. *Oral Surg Oral Med Oral Pathol* **75**: 595–598.
- Hussain L, Ward R, Lehner T, Barnes CG (1986). Herpes simplex virus IgG, IgM and IgA subclass from sera of patients with Behçet's disease and controls. In Lehner T, Barnes CG, eds. *Recent advances in Behçet's disease*. Royal Society of Medicine: London, pp. 73–77.
- Hutcheon AW, Wray D, Dagg JH, Ferguson MM, Mason DK, Lucie NP (1978). Clinical and haematological screening in recurrent aphthae. *Postgrad Med J* **54**: 779–783.
- Jaber L, Weinberger A, Klein T, Yaniv I, Mukamel M (2001). Close association of HLA-B52 and HLA-B44 antigens in Israeli Arab adolescents with recurrent aphthous stomatitis. *Arch Otolaryngol Head Neck Surg* **127**: 184–187.
- Jacobson JM, Greenspan JS, Spritzler J et al (1997). Thalidomide for the treatment of oral aphthous ulcers in patients with human immunodeficiency virus infection. National Institute of Allergy and Infectious Diseases AIDS Clinical Trials Group. *N Engl J Med* **336**: 1487–1493.
- Jainkittivong A, Aneksuk V, Langlais RP (2002). Oral mucosal conditions in elderly dental patients. *Oral Dis* **8**: 218–223.
- Jankowski J, Crombie I, Jankowski R (1992). Behçet's syndrome in Scotland. *Postgrad Med J* **68**: 566–570.
- Kaloyannides TM (1971). Treatment of recurrent aphthous stomatitis with gamma globulin: report of five cases. *J Can Dent Assoc* **37**: 312–313.
- Kaplan B, Cardarelli C, Pinnell SR (1978). Double-blind study of levamisole in aphthous stomatitis. *J Oral Pathol* **7**: 400–404.
- Katz J, Langevitz P, Shemer J, Barak S, Livneh A (1994). Prevention of recurrent aphthous stomatitis with colchicine: an open trial. *J Am Acad Dermatol* **31**: 459–461.
- Kawashima H, Nishimata S, Shimizu T, Kashiwagi Y, Takekuma K, Hoshika A (2001). Highly suspected case of FAPA (periodic fever, aphthous stomatitis, pharyngitis and adenitis) syndrome. *Pediatr Int* **43**: 103–106.
- Khandwala A, Van Inwegen RG, Charney MR, Alfano MC (1997). 5% amlexanox oral paste, a new treatment for recurrent minor aphthous ulcers: II. Pharmacokinetics and demonstration of clinical safety. *Oral Surg Oral Med Oral Pathol Oral Radiol Endod* **83**: 231–238.
- Kjaerheim V, Roed A, Brodin P, Rolla G (1995). Effects of triclosan on the rat phrenic nerve-diaphragm preparation. *J Clin Periodontol* **22**: 488–493.
- Kleinman DV, Swango PA, Pindborg JJ (1994). Epidemiology of oral mucosal lesions in United States schoolchildren: 1986–87. *Community Dent Oral Epidemiol* **22**: 243–253.
- Kovac-Kovacic M, Skaleric U (2000). The prevalence of oral mucosal lesions in a population in Ljubljana, Slovenia. *J Oral Pathol Med* **29**: 331–335.
- Kowolik MJ, Muir KF, MacPhee IT (1978). Di-sodium cromoglycate in the treatment of recurrent aphthous ulceration. *Br Dent J* **144**: 384–386.
- Krause I, Rosen Y, Kaplan I et al (1999). Recurrent aphthous stomatitis in Behçet's disease: clinical features and correlation with systemic disease expression and severity. *J Oral Pathol Med* **28**: 193–196.
- Kutcher MJ, Ludlow JB, Samuelson AD, Campbell T, Pusek SN (2001). Evaluation of a bioadhesive device for the management of aphthous ulcers. *J Am Dent Assoc* **132**: 368–376.
- Lange RD, Jones JB (1981). Cyclic neutropenia. Review of clinical manifestations and management. *Am J Pediatr Hematol Oncol* **3**: 363–367.
- Le Thi HD, Wechsler B, Piette JC et al (1993). Aortic insufficiency and recurrent valve prosthesis dehiscence in MAGIC syndrome. *J Rheumatol* **20**: 397–398.
- Lehner T (1967). Stimulation of lymphocyte transformation by tissue homogenates in recurrent oral ulceration. *Immunology* **13**: 159–166.
- Lehner T (1969a). Characterization of mucosal antibodies in recurrent aphthous ulceration and Behçet's syndrome. *Arch Oral Biol* **14**: 843–853.
- Lehner T (1969b). Immunoglobulin estimation of blood and saliva in human recurrent oral ulceration. *Arch Oral Biol* **14**: 351–364.
- Lehner T (1977). Oral ulceration and Behçet's syndrome. *Gut* **18**: 491–511.
- Lehner T, Adinolfi M (1980). Acute phase proteins, C9, factor B, and lysozyme in recurrent oral ulceration and Behçet's syndrome. *J Clin Pathol* **33**: 269–275.
- Lehner T, Wilton JM, Ivanyi L (1976). Double blind crossover trial of levamisole in recurrent aphthous ulceration. *Lancet* **2**: 926–929.
- Lehner T, Losito A, Williams DG (1979). Cryoglobulins in Behçet's syndrome and recurrent oral ulceration: assay by laser nephelometry. *Clin Exp Immunol* **38**: 436–444.
- Lehner T, Welsh KI, Batchelor JR (1982). The relationship of HLA-B and DR phenotypes to Behçet's syndrome, recurrent oral ulceration and the class of immune complexes. *Immunology* **47**: 581–587.
- Lehner T, Lavery E, Smith R, van der ZR, Mizushima Y, Shinnick T (1991). Association between the 65-kilodalton heat shock protein, *Streptococcus sanguis*, and the corresponding antibodies in Behçet's syndrome. *Infect Immun* **59**: 1434–1441.
- Leimola-Virtanen R, Happonen RP, Syrjanen S (1995). Cytomegalovirus (CMV) and *Helicobacter pylori* (HP) found in oral mucosal ulcers. *J Oral Pathol Med* **24**: 14–17.
- Lejonec JL, Fourestie V (1985). Phenelzine in the treatment of aphthous ulcers of the mouth. *N Engl J Med* **312**: 859–860.
- Levinsky RJ, Lehner T (1978). Circulating soluble immune complexes in recurrent oral ulceration and Behçet's syndrome. *Clin Exp Immunol* **32**: 193–198.
- Lindemann RA, Riviere GR, Sapp JP (1985). Serum antibody responses to indigenous oral mucosal antigens and selected laboratory-maintained bacteria in recurrent aphthous ulceration. *Oral Surg Oral Med Oral Pathol* **59**: 585–589.
- Lo ML, della VA, Mignogna MD et al (2001). The treatment of oral aphthous ulceration or erosive lichen planus with topical clobetasol propionate in three preparations: a clinical and pilot study on 54 patients. *J Oral Pathol Med* **30**: 611–617.
- Lubitz PA, Dower N, Krol AL (2001). Cyclic neutropenia: an unusual disorder of granulopoiesis effectively treated with recombinant granulocyte colony-stimulating factor. *Pediatr Dermatol* **18**: 426–432.
- Ludlow JB, Kutcher MJ, Samuelson A (2000). Intraoral digital imaging documenting recurrent aphthous ulcer healing in 2-octyl cyanoacrylate versus sham-treated lesions. *Oral Surg Oral Med Oral Pathol Oral Radiol Endod* **89**: 425–431.
- Lunderschmidt C (1982). Immunologische Aspekt in der Pathogenese der oralen Aphthosen. *Dtsch Z Mund-Kiefer-Gesichts-Chir* **119**: 31–34.
- MacPhail LA, Greenspan JS (1997). Oral ulceration in HIV infection: investigation and pathogenesis. *Oral Dis* **3** (Suppl. 1): S190–S193.



- O'Mahony C, O'Farrelly C, Weir DG, et al (1985) Gluten-sensitive oral ulceration in the absence of coeliac diseases. *Gut* **26**: A1137.
- Majorana A, Sapelli PL, Malagoli A et al (1992). [Celiac disease and recurrent aphthous stomatitis. The clinical and immunogenetic aspects]. *Minerva Stomatol* **41**: 33–40.
- Malmstrom M, Salo OP, Fyhrquist F (1983). Immunogenetic markers and immune response in patients with recurrent oral ulceration. *Int J Oral Surg* **12**: 23–30.
- Marshall GS, Edwards KM, Butler J, Lawton AR (1987). Syndrome of periodic fever, pharyngitis, and aphthous stomatitis. *J Pediatr* **110**: 43–46.
- Martin DK, Nelms DC, Mackler BF, Peavy DL (1979). Lymphoproliferative responses induced by streptococcal antigens in recurrent aphthous stomatitis and Behcet's syndrome. *Clin Immunol Immunopathol* **13**: 146–155.
- Mascaro JM, Lecha M, Torras H (1979). Thalidomide in the treatment of recurrent, necrotic, and giant mucocutaneous aphthae and aphthosis. *Arch Dermatol* **115**: 636–637.
- Matthews RW, Scully CM, Levers BG, Hislop WS (1987). Clinical evaluation of benzydamine, chlorhexidine, and placebo mouthwashes in the management of recurrent aphthous stomatitis. *Oral Surg Oral Med Oral Pathol* **63**: 189–191.
- McCartan BE, Sullivan A (1992). The association of menstrual cycle, pregnancy, and menopause with recurrent oral aphthous stomatitis: a review and critique. *Obstet Gynecol* **80**: 455–458.
- McCartan BE, Lamey PJ, Wallace AM (1996). Salivary cortisol and anxiety in recurrent aphthous stomatitis. *J Oral Pathol Med* **25**: 357–359.
- Meini A, Pillan MN, Plebani A, Ugazio AG, Majorana A, Sapelli PL (1993). High prevalence of DRW10 and DQW1 antigens in celiac disease associated with recurrent aphthous stomatitis. *Am J Gastroenterol* **88**: 972.
- Merchant HW, Gangarosa LP, Glassman AB, Sobel RE (1978). Betamethasone-17-benzoate in the treatment of recurrent aphthous ulcers. *Oral Surg Oral Med Oral Pathol* **45**: 870–875.
- Merchant NE, Ferguson MM, Ali A, Hole DJ, Gillis CR (1986). The detection of IgA-reticulin antibodies and their incidence in patients with recurrent aphthae. *J Oral Med* **41**: 31–34.
- Meyer JD, Degraeve M, Clarysse J, De Loose F, Peremans W (1977). Levamisole in aphthous stomatitis: evaluation of three regimens. *Br Med J* **1**: 671–674.
- Miles DA, Bricker SL, Razmus TF, Potter RH (1993). Triamcinolone acetonide versus chlorhexidine for treatment of recurrent stomatitis. *Oral Surg Oral Med Oral Pathol* **75**: 397–402.
- Miller MF, Chilton NW (1980). The effect of an oxygenating agent upon recurrent aphthous stomatitis – a double-blind clinical trial. *Pharmacol Ther Dent* **5**: 55–58.
- Miller MF, Ship II (1977). A retrospective study of the prevalence and incidence of recurrent aphthous ulcers in a professional population, 1958–1971. *Oral Surg Oral Med Oral Pathol* **43**: 532–537.
- Miller MF, Garfunkel AA, Ram C, Ship II (1977). Inheritance patterns in recurrent aphthous ulcers: twin and pedigree data. *Oral Surg Oral Med Oral Pathol* **43**: 886–891.
- Miller MF, Silvert ME, Laster LL, Green P, Ship II (1978). Effect of levamisole on the incidence and prevalence of recurrent aphthous stomatitis. A double-blind clinical trial. *J Oral Pathol* **7**: 387–392.
- Miller MF, Garfunkel AA, Ram CA, Ship II (1980). The inheritance of recurrent aphthous stomatitis. Observations on susceptibility. *Oral Surg Oral Med Oral Pathol* **49**: 409–412.
- Mittal R, Chopra A, Handa F (1985). Sutton's aphthae and Behcet's syndrome. *Indian J Dermatol* **30**: 17–21.
- Mizoguchi M, Matsuki K, Mochizuki M et al (1988). Human leukocyte antigen in Sweet's syndrome and its relationship to Behcet's disease. *Arch Dermatol* **124**: 1069–1073.
- Mizuki N, Ohno S, Sato T et al (1995). Microsatellite polymorphism between the tumor necrosis factor and HLA-B genes in Behcet's disease. *Hum Immunol* **43**: 129–135.
- Moghadam BK, Hersini S, Barker BF (1998). Autoimmune progesterone dermatitis and stomatitis. *Oral Surg Oral Med Oral Pathol Radiol Endod* **85**: 537–541.
- Mravak-Stipetic M, Gall-Troselj K, Lukac J, Kusic Z, Pavelic K, Pavelic J (1998). Detection of *Helicobacter pylori* in various oral lesions by nested polymerase chain reaction (PCR). *J Oral Pathol Med* **27**: 1–3.
- de Muniz BR, Crivelli MR, Paroni HC (1981). Clinical study of oral soft tissue lesions in boys in a children's home. *Rev Assoc Odontol Argent* **69**: 405–408.
- Natah SS, Hayrinen-Immonen R, Hietanen J, Malmstrom M, Kontinen YT (1997). Factor XIIIa-positive dendrocytes are increased in number and size in recurrent aphthous ulcers (RAU). *J Oral Pathol Med* **26**: 408–413.
- Natah SS, Hayrinen-Immonen R, Hietanen J, Malmstrom M, Kontinen YT (1998). Quantitative assessment of mast cells in recurrent aphthous ulcers (RAU). *J Oral Pathol Med* **27**: 124–129.
- Natah SS, Hayrinen-Immonen R, Hietanen J et al (2000). Increased density of lymphocytes bearing gamma/delta T-cell receptors in recurrent aphthous ulceration (RAU). *Int J Oral Maxillofac Surg* **29**: 375–380.
- Nicolau DP, West TE (1990). Thalidomide: treatment of severe recurrent aphthous stomatitis in patients with AIDS. *DICP* **24**: 1054–1056.
- Nolan A, McIntosh WB, Allam BF, Lamey PJ (1991). Recurrent aphthous ulceration: vitamin B1, B2 and B6 status and response to replacement therapy. *J Oral Pathol Med* **20**: 389–391.
- Ogura M, Yamamoto T, Morita M, Watanabe T (2001). A case-control study on food intake of patients with recurrent aphthous stomatitis. *Oral Surg Oral Med Oral Pathol Radiol Endod* **91**: 45–49.
- Olson JA, Silverman S Jr (1978). Double-blind study of levamisole therapy in recurrent aphthous stomatitis. *J Oral Pathol* **7**: 393–399.
- Olson JA, Feinberg I, Silverman S Jr, Abrams D, Greenspan JS (1982). Serum vitamin B12, folate, and iron levels in recurrent aphthous ulceration. *Oral Surg Oral Med Oral Pathol* **54**: 517–520.
- Orbak R, Cicek Y, Tezel A, Dogru Y (2003). Effects of zinc treatment in patients with recurrent aphthous stomatitis. *Dent Mater J* **22**: 21–29.
- Orme RL, Nordlund JJ, Barich L, Brown T (1990). The MAGIC syndrome (mouth and genital ulcers with inflamed cartilage). *Arch Dermatol* **126**: 940–944.
- Ozbakir F, Yazici H, Mat C, Tuzun Y, Yurdakul S, Yilmazer S (1987). HLA antigens in recurrent oral ulceration: evidence against a common disease spectrum with Behcet's syndrome. *Clin Exp Rheumatol* **5**: 263–265.
- Paterson DL, Georghiou PR, Allworth AM, Kemp RJ (1995). Thalidomide as treatment of refractory aphthous ulceration related to human immunodeficiency virus infection. *Clin Infect Dis* **20**: 250–254.
- Paulo FW, Ribeiro JE, Pinto DS (2000). Safety and efficacy of *Eupatorium laevigatum* paste as therapy for buccal aphthae: randomized, double-blind comparison with triamcinolone 0.1% orabase. *Adv Ther* **17**: 272–281.

- Pavelic J, Gall-Troselj K, Jurak I, Mravak-Stipetic M (2000). *Helicobacter pylori* in oral aphthous ulcers. *J Oral Pathol Med* **29**: 523–525.
- Pedersen A (1989). Psychologic stress and recurrent aphthous ulceration. *J Oral Pathol Med* **18**: 119–122.
- Pedersen A (1992). Acyclovir in the prevention of severe aphthous ulcers. *Arch Dermatol* **128**: 119–120.
- Pedersen A (1993). Recurrent aphthous ulceration: virological and immunological aspects. *APMIS Suppl* **37**: 1–37.
- Pedersen A, Hornsleth A (1993). Recurrent aphthous ulceration: a possible clinical manifestation of reactivation of varicella zoster or cytomegalovirus infection. *J Oral Pathol Med* **22**: 64–68.
- Pedersen A, Pedersen BK (1993). Natural killer cell function and number of peripheral blood are not altered in recurrent aphthous ulceration. *Oral Surg Oral Med Oral Pathol* **76**: 616–619.
- Pedersen A, Ryder LP (1994). Gamma delta T-cell fraction of peripheral blood is increased in recurrent aphthous ulceration. *Clin Immunol Immunopathol* **72**: 98–104.
- Pedersen A, Klausen B, Hougen HP, Stenvang JP (1989). T-lymphocyte subsets in recurrent aphthous ulceration. *J Oral Pathol Med* **18**: 59–60.
- Pedersen A, Madsen HO, Vestergaard BF, Ryder LP (1993). Varicella-zoster virus DNA in recurrent aphthous ulcers. *Scand J Dent Res* **101**: 311–313.
- Peretz B (1994). Major recurrent aphthous stomatitis in an 11-year-old girl: case report. *J Clin Pediatr Dent* **18**: 309–312.
- Pimlott SJ, Walker DM (1983). A controlled clinical trial of the efficacy of topically applied fluocinonide in the treatment of recurrent aphthous ulceration. *Br Dent J* **154**: 174–177.
- Piskin S, Sayan C, Durukan N, Senol M (2002). Serum iron, ferritin, folic acid, and vitamin B12 levels in recurrent aphthous stomatitis. *J Eur Acad Dermatol Venereol* **16**: 66–67.
- Pizarro A, Navarro A, Fonseca E, Vidaurrezaga C, Herranz P (1995). Treatment of recurrent aphthous stomatitis with pentoxifylline. *Br J Dermatol* **133**: 659–660.
- Pizarro A, Herranz P, Navarro A, Casado M (1996). Recurrent aphthous stomatitis: treatment with pentoxifylline. *Acta Derm Venereol* **76**: 79–80.
- Pongissawaranun W, Laohapand P (1991). Epidemiologic study on recurrent aphthous stomatitis in a Thai dental patient population. *Community Dent Oral Epidemiol* **19**: 52–53.
- Porter SR, Jorge J Jr (2002). Thalidomide: a role in oral oncology? *Oral Oncol* **38**: 527–531.
- Porter SR, Scully C (1993a). Orofacial manifestations in primary immunodeficiencies involving IgA deficiency. *J Oral Pathol Med* **22**: 117–119.
- Porter SR, Scully C (1993b). Orofacial manifestations in primary immunodeficiencies: common variable immunodeficiencies. *J Oral Pathol Med* **22**: 157–158.
- Porter SR, Scully C (1993c). Orofacial manifestations in primary immunodeficiencies: polymorphonuclear leukocyte defects. *J Oral Pathol Med* **22**: 310–311.
- Porter SR, Scully C (1993d). Orofacial manifestations in primary immunodeficiencies: T lymphocyte defects. *J Oral Pathol Med* **22**: 308–309.
- Porter SR, Scully C (2005). Aphthous ulcers: (recurrent) *Clin Evid* **13**: 380–381.
- Porter SR, Scully C, Flint S (1988). Hematologic status in recurrent aphthous stomatitis compared with other oral disease. *Oral Surg Oral Med Oral Pathol* **66**: 41–44.
- Porter S, Flint S, Scully C, Keith O (1992a). Recurrent aphthous stomatitis: the efficacy of replacement therapy in patients with underlying hematinic deficiencies. *Ann Dent* **51**: 14–16.
- Porter SR, Scully C, Bowden J (1992b). Immunoglobulin G subclasses in recurrent aphthous stomatitis. *J Oral Pathol Med* **21**: 26–27.
- Porter SR, Kingsmill V, Scully C (1993). Audit of diagnosis and investigations in patients with recurrent aphthous stomatitis. *Oral Surg Oral Med Oral Pathol* **76**: 449–452.
- Porter SR, Scully C, Standen GR (1994). Autoimmune neutropenia manifesting as recurrent oral ulceration. *Oral Surg Oral Med Oral Pathol* **78**: 178–180.
- Porter SR, Barker GR, Scully C, Macfarlane G, Bain L (1997). Serum IgG antibodies to *Helicobacter pylori* in patients with recurrent aphthous stomatitis and other oral disorders. *Oral Surg Oral Med Oral Pathol Oral Radiol Endod* **83**: 325–328.
- Porter SR, Hegarty A, Kaliakatsou F, Hodgson TA, Scully C (2000). Recurrent aphthous stomatitis. *Clin Dermatol* **18**: 569–578.
- Poswillo D, Partridge M (1984). Management of recurrent aphthous ulcers. A trial of carbenoxolone sodium mouthwash. *Br Dent J* **157**: 55–57.
- Potoky JR (1981). Recurrent aphthous stomatitis; a proposed therapeutic regimen. *J Oral Med* **36**: 44–46.
- Potts AJ, Frame JW, Bateman JR, Asquith P (1984). Sodium cromoglycate toothpaste in the management of aphthous ulceration. *Br Dent J* **156**: 250–251.
- Prikuls VF (2000). [Photophoresis of oxolin ointment in combined therapy of patients with chronic relapsing aphthous stomatitis]. *Vopr Kurortol Fizioter Lech Fiz Kult* **6**: 39–42.
- Rehberger A, Puspok A, Stallmeister T, Jurecka W, Wolf K (1998). Crohn's disease masquerading as aphthous ulcers. *Eur J Dermatol* **8**: 274–276.
- Revuz J, Guillaume JC, Janier M et al (1990). Crossover study of thalidomide vs placebo in severe recurrent aphthous stomatitis. *Arch Dermatol* **126**: 923–927.
- Rhodus NL, Bereuter J (1998). An evaluation of a chemical cautery agent and an anti-inflammatory ointment for the treatment of recurrent aphthous stomatitis: a pilot study. *Quintessence Int* **29**: 769–773.
- Ricer RE (1989). Sucralfate vs. placebo for the treatment of aphthous ulcers: a double-blinded prospective clinical trial. *Fam Pract Res J* **9**: 33–41.
- Rogers RS III, Hutton KP (1986). Screening for haematinic deficiencies in patients with recurrent aphthous stomatitis. *Australas J Dermatol* **27**: 98–103.
- Rogers RS III, Sams WM Jr, Shorter RG (1974). Lymphocytotoxicity in recurrent aphthous stomatitis. Lymphocytotoxicity for oral epithelial cells in recurrent aphthous stomatitis and Bechet syndrome. *Arch Dermatol* **109**: 361–363.
- Rogers RS III, Movius DL, Pierre RV (1976). Lymphocyte-epithelial cell interactions in oral mucosal inflammatory diseases. *J Invest Dermatol* **67**: 599–602.
- Rosenthal SH (1984). Does phenelzine relieve aphthous ulcers of the mouth? *N Engl J Med* **311**: 1442.
- Ross R, Kutscher AH, Zegarelli EV, Silvers H, Piro JD (1958). Relationship of mechanical trauma to recurrent ulcerative (aphthae) stomatitis. *N Y State Dent J* **24**: 101–102.
- Rothe G, Wutzler P, Sprossig M, Farber J (1978). [Etiology of chronic recurring aphthous stomatitis]. *Stomatol DDR* **28**: 325–328.
- Ruah CB, Stram JR, Chasin WD (1988). Treatment of severe recurrent aphthous stomatitis with colchicine. *Arch Otolaryngol Head Neck Surg* **114**: 671–675.

- Sallay K (1968). [Recurrent aphtha]. *Fogorv Sz* **61**: 18–22.
- Sallay K, Dan P, Geck P, Kulcsar G, Nasz I (1971). Immunofluorescent studies on circulating lymphocytes in oral mucosal diseases. *Arch Dermatol Forsch* **241**: 15–21.
- Sallay K, Kulcsar G, Nasz I, Dan P, Geck P (1973). Adenovirus isolation from recurrent oral ulcers. *J Periodontol* **44**: 712–714.
- Sallay K, Kulcsar G, Dan P, Nasz I, Geck P (1975). [Etiology and prevention of recurring aphthous stomatitis]. *Dtsch Zahnarztl Z* **30**: 570–575.
- Salonen L, Axell T, Hellden L (1990). Occurrence of oral mucosal lesions, the influence of tobacco habits and an estimate of treatment time in an adult Swedish population. *J Oral Pathol Med* **19**: 170–176.
- Sampaio EP, Sarno EN, Galilly R, Cohn ZA, Kaplan G (1991). Thalidomide selectively inhibits tumor necrosis factor alpha production by stimulated human monocytes. *J Exp Med* **173**: 699–703.
- Savage NW, Seymour GJ (1994). Specific lymphocytotoxic destruction of autologous epithelial cell targets in recurrent aphthous stomatitis. *Aust Dent J* **39**: 98–104.
- Savage NW, Seymour GJ, Kruger BJ (1985). T-lymphocyte subset changes in recurrent aphthous stomatitis. *Oral Surg Oral Med Oral Pathol* **60**: 175–181.
- Savage NW, Seymour GJ, Kruger BJ (1986). Expression of class I and class II major histocompatibility complex antigens on epithelial cells in recurrent aphthous stomatitis. *J Oral Pathol* **15**: 191–195.
- Saxen MA, Ambrosius WT, Rehemtula a, Russell AL, Eckert GJ (1997). Sustained relief of oral aphthous ulcer pain from topical diclofenac in hyaluronan: a randomized, double-blind clinical trial. *Oral Surg Oral Med Oral Pathol Oral Radiol Endod* **84**: 356–361.
- Scaglione F, Falchi M, Bichisao E, Fraschini F (1985). Flumethasone pivalate (Locorten) in the treatment of oral diseases. *Drugs Exp Clin Res* **11**: 523–526.
- Schreiner DT, Jorizzo JL (1987). Behçet's disease and complex aphthosis. *Dermatol Clin* **5**: 769–778.
- Schroeder HE, Muller-Glauser W, Sallay K (1984). Pathomorphologic features of the ulcerative stage of oral aphthous ulcerations. *Oral Surg Oral Med Oral Pathol* **58**: 293–305.
- Schulkind ML, Heim LR, South MA, Jeter WS, Small PA Jr (1984). A case report of the successful treatment of recurrent aphthous stomatitis with some preparations of orally administered transfer factor. *Cell Immunol* **84**: 415–421.
- Scully C (1982). Serum beta 2 microglobulin in recurrent aphthous stomatitis and Behçet's syndrome. *Clin Exp Dermatol* **7**: 61–64.
- Scully C, Porter S (1989). Recurrent aphthous stomatitis: current concepts of etiology, pathogenesis and management. *J Oral Pathol Med* **18**: 21–27.
- Scully C, MacFadyen E, Campbell A (1982). Oral manifestations in cyclic neutropenia. *Br J Oral Surg* **20**: 96–101.
- Scully C, Yap PL, Boyle P (1983). IgE and IgD concentrations in patients with recurrent aphthous stomatitis. *Arch Dermatol* **119**: 31–34.
- Scully C, Azul AM, Crighton A, Felix D, Field A, Porter SR (2001). Nicorandil can induce severe oral ulceration. *Oral Surg Oral Med Oral Pathol Oral Radiol Endod* **91**: 189–193.
- Scully C, Gorsky M, Lozada-Nur F (2003). The diagnosis and management of recurrent aphthous stomatitis: a consensus approach. *J Am Dent Assoc* **134**: 200–207.
- Sedghizadeh PP, Shuler CF, Allen CM, Beck FM, Kalmar JR (2002). Celiac disease and recurrent aphthous stomatitis: a report and review of the literature. *Oral Surg Oral Med Oral Pathol Oral Radiol Endod* **94**: 474–478.
- Segal AL, Katcher AH, Brightman VJ, Miller MF (1974). Recurrent herpes labialis, recurrent aphthous ulcers, and the menstrual cycle. *J Dent Res* **53**: 797–803.
- Shapiro S, Olson DL, Chellemi SJ (1970). The association between smoking and aphthous ulcers. *Oral Surg Oral Med Oral Pathol* **30**: 624–630.
- Shimoyama T, Horie N, Kato T, Kaneko T, Komiyama K (2000). *Helicobacter pylori* in oral ulcerations. *J Oral Sci* **42**: 225–229.
- Ship II (1965). Inheritance of aphthous ulcers of the mouth. *J Dent Res* **44**: 837–844.
- Ship II (1972). Epidemiologic aspects of recurrent aphthous ulcerations. *Oral Surg Oral Med Oral Pathol* **33**: 400–406.
- Ship II, Asche W, Scherp H (1961a). Recurrent 'fever blister' and 'canker sore'. Tests for herpes simplex virus and other viruses with mammalian cell cultures. *Arch Oral Biol* **3**: 117–124.
- Ship II, Morris AL, Surocher RT, Burket L (1961b). Recurrent aphthous ulceration in a professional school student population. I.V. twelve month study of natural disease patterns. *Oral Surg Oral Med Oral Pathol* **14**: 30–39.
- Ship II, Brightman VJ, Laster LL (1967). The patient with recurrent aphthous ulcers and the patient with recurrent herpes labialis: a study of two population samples. *J Am Dent Assoc* **75**: 645–654.
- Shohat-Zabarski R, Kalderon S, Klein T, Weinberger A (1992). Close association of HLA-B51 in persons with recurrent aphthous stomatitis. *Oral Surg Oral Med Oral Pathol* **74**: 455–458.
- Siegel MA (1999). Strategies for management of commonly encountered oral mucosal disorders. *J Calif Dent Assoc* **27**: 210–219.
- Sircus W, Church R, Kelleher J (1957). Recurrent aphthous ulceration of the mouth. *Quarterly Journal of Medicine* **26**: 235–249.
- Sistig S, Vucicevic-Boras V, Lukac J, Kusic Z (2002). Salivary IgA and IgG subclasses in oral mucosal diseases. *Oral Dis* **8**: 282–286.
- Skaare AB, Herlofson BB, Barkvoll P (1996a). Mouthrinses containing triclosan reduce the incidence of recurrent aphthous ulcers (RAU). *J Clin Periodontol* **23**: 778–781.
- Spouge J, Diamond H (1963). Hypersensitivity reactions in mucous membranes. I. The statistical relationship between hypersensitivity diseases and recurrent oral ulcerations. *Oral Surg* **16**: 412–421.
- Stanley HR (1973). Management of patients with persistent recurrent aphthous stomatitis and Sutton's disease. *Oral Surg Oral Med Oral Pathol* **35**: 174–179.
- Stratigos AJ, Laskaris G, Stratigos JD (1992). Behçet's disease. *Semin Neurol* **12**: 346–357.
- Studd M, McCance DJ, Lehner T (1991). Detection of HSV-1 DNA in patients with Behçet's syndrome and in patients with recurrent oral ulcers by the polymerase chain reaction. *J Med Microbiol* **34**: 39–43.
- Sucker C, Djawari J (1999). [Recurrent episodes of ulcerative gingivostomatitis associated with cyclic neutropenia]. *Hautarzt* **50**: 503–506.
- Sun A, Chu CT, Wu YC, Yuan JH (1991). Mechanisms of depressed natural killer cell activity in recurrent aphthous ulcers. *Clin Immunol Immunopathol* **60**: 83–92.
- Sun A, Chiang CP, Chiou PS, Wang JT, Liu BY, Wu YC (1994). Immunomodulation by levamisole in patients with recurrent aphthous ulcers or oral lichen planus. *J Oral Pathol Med* **23**: 172–177.

- Sun A, Chang JG, Kao CL *et al* (1996). Human cytomegalovirus as a potential etiologic agent in recurrent aphthous ulcers and Behcet's disease. *J Oral Pathol Med* **25**: 212–218.
- Sun A, Chu CT, Liu BY, Wang JT, Leu JS, Chiang CP (2000). Expression of interleukin-2 receptor by activated peripheral blood lymphocytes upregulated by the plasma level of interleukin-2 in patients with recurrent aphthous ulcers. *Proc Natl Sci Counc Repub China B* **24**: 116–122.
- Sun A, Hsieh RP, Chu CT, Wang JT, Liu BY, Chiang CP (2001). Some specific human leukocyte antigen (HLA)-DR/DQ haplotypes are more important than individual HLA-DR and -DQ phenotypes for the development of mucocutaneous type of Behcet's disease and for disease shift from recurrent aphthous stomatitis to mucocutaneous type of Behcet's disease. *J Oral Pathol Med* **30**: 402–407.
- Sun A, Chia JS, Chang YF, Chiang CP (2003). Levamisole and Chinese medicinal herbs can modulate the serum interleukin-6 level in patients with recurrent aphthous ulcerations. *J Oral Pathol Med* **32**: 206–214.
- Taylor LJ, Bagg J, Walker DM, Peters TJ (1992). Increased production of tumour necrosis factor by peripheral blood leukocytes in patients with recurrent oral aphthous ulceration. *J Oral Pathol Med* **21**: 21–25.
- Taylor LJ, Walker DM, Bagg J (1993). A clinical trial of prostaglandin E2 in recurrent aphthous ulceration. *Br Dent J* **175**: 125–129.
- Teixeira F, Mosqueda-Taylor A, Montano S, Dominguez-Soto L (1999). Treatment of recurrent oral ulcers with mometasone furoate lotion. *Postgrad Med J* **75**: 574.
- Thomas DW, Bagg J, Walker DM (1988). The in vitro cytotoxic effect of leukocytes from patients with recurrent aphthous ulceration upon mouse 3T3 fibroblasts. *J Oral Pathol* **17**: 421–425.
- Thomas DW, Bagg J, Walker DM (1990). Characterisation of the effector cells responsible for the in vitro cytotoxicity of blood leucocytes from aphthous ulcer patients for oral epithelial cells. *Gut* **31**: 294–299.
- Thornhill MH, Zakrzewska JM, Gilkes JJ (1992). *Pyostomatitis vegetans*: report of three cases and review of the literature. *J Oral Pathol Med* **21**: 128–133.
- Tuft L, Ettleson L (1956). Canker sores from allergy to weak organic acids (citric and acetic). *J Allergy* **536–543**.
- Tuzun B, Wolf R, Tuzun Y, Serdaroglu S (2000). Recurrent aphthous stomatitis and smoking. *Int J Dermatol* **39**: 358–360.
- Tyldesley WR (1983). Stomatitis and recurrent oral ulceration: is a full blood screen necessary? *Br J Oral Surg* **21**: 27–30.
- Ueta E, Umazume M, Yamamoto T, Osaki T (1993). Leukocyte dysfunction in oral mucous membrane diseases. *J Oral Pathol Med* **22**: 120–125.
- Ueta E, Osaki T, Yoneda K, Yamamoto T, Kato I (1994). A clinical trial of Azelastine in recurrent aphthous ulceration, with an analysis of its actions on leukocytes. *J Oral Pathol Med* **23**: 123–129.
- Ullman S, Gorlin RJ (1978). Recurrent aphthous stomatitis. An immunofluorescence study. *Arch Dermatol* **114**: 955–956.
- Veloso FT, Saleiro JV (1987). Small-bowel changes in recurrent ulceration of the mouth. *Hepatogastroenterology* **34**: 36–37.
- Verdict GM, Savage NW, Dodd NM, Walsh LJ (1992). Expression of the CD54 (ICAM-1) and CD11a (LFA-1) adhesion molecules in oral mucosal inflammation. *J Oral Pathol Med* **21**: 65–69.
- Vicente M, Soria A, Mosquera A *et al* (1996). Immunoglobulin G subclass measurements in recurrent aphthous stomatitis. *J Oral Pathol Med* **25**: 538–540.
- Victoria JM, Kalapothakis E, Silva JF, Gomez RS (2003). *Helicobacter pylori* DNA in recurrent aphthous stomatitis. *J Oral Pathol Med* **32**: 219–223.
- Wahba-Yahav AV (1995a). Pentoxifylline in intractable recurrent aphthous stomatitis: an open trial. *J Am Acad Dermatol* **33**: 680–682.
- Wahba-Yahav AV (1995b). Severe idiopathic recurrent aphthous stomatitis: treatment with pentoxifylline. *Acta Derm Venereol* **75**: 157.
- de Wazieres B, Gil H, Magy N, Berthier S, Vuitton DA, Dupond JL (1999). [Treatment of recurrent ulceration with low doses of thalidomide. Pilot study in 17 patients]. *Rev Med Interne* **20**: 567–570.
- Weusten BL, van de Weil WA (1998). Aphthous ulcers and vitamin B12 deficiency. *Neth J Med* **53**: 172–175.
- Whallett AJ, Thurairajan G, Hamburger J, Palmer RG, Murray PI (1999). Behcet's syndrome: a multidisciplinary approach to clinical care. *QJM* **92**: 727–740.
- Wilson CW (1980). Food sensitivities, taste changes, aphthous ulcers and atopic symptoms in allergic disease. *Ann Allergy* **44**: 302–307.
- Wormser GP, Mack L, Lenox T *et al* (1988). Lack of effect of oral acyclovir on prevention of aphthous stomatitis. *Otolaryngol Head Neck Surg* **98**: 14–17.
- Wray D (1981). Gluten-sensitive recurrent aphthous stomatitis. *Dig Dis Sci* **26**: 737–740.
- Wray D, Ferguson MM, Mason DK, Hutcheon AW, Dagg JH (1975). Recurrent aphthae: treatment with vitamin B12, folic acid, and iron. *Br Med J* **2**: 490–493.
- Wray D, Graykowski EA, Notkins AL (1981). Role of mucosal injury in initiating recurrent aphthous stomatitis. *Br Med J (Clin Res Ed)* **283**: 1569–1570.
- Wray D, Vlagopoulos TP, Siraganian RP (1982). Food allergens and basophil histamine release in recurrent aphthous stomatitis. *Oral Surg Oral Med Oral Pathol* **54**: 388–395.
- Wright A, Ryan FP, Willingham SE *et al* (1986). Food allergy or intolerance in severe recurrent aphthous ulceration of the mouth. *Br Med J (Clin Res Ed)* **292**: 1237–1238.
- Wu-Wang CY, Patel M, Feng J, Milles M, Wang SL (1995). Decreased levels of salivary prostaglandin E2 and epidermal growth factor in recurrent aphthous stomatitis. *Arch Oral Biol* **40**: 1093–1098.
- Yaacob HB, Ab HJ (1985). Use of antidepressants in aphthous ulceration – a clinical experience. *Dent J Malays* **8**: 33–38.
- Yamamoto T, Yoneda K, Ueta E, Osaki T (1994). Serum cytokines, interleukin-2 receptor, and soluble intercellular adhesion molecule-1 in oral disorders. *Oral Surg Oral Med Oral Pathol* **78**: 727–735.
- Yel L, Tezcan I, Hasturk H, Ersoy F, Sanal O, Yavuzilmaz E (1994). Oral findings, treatment and follow-up of a case with major aphthous stomatitis (Sutton's disease). *J Clin Pediatr Dent* **19**: 49–53.
- Yeoman CM, Greenspan JS, Harding SM (1978). Recurrent oral ulceration. A double-blind comparison of treatment with betamethasone valerate aerosol and placebo. *Br Dent J* **144**: 114–116.
- Ylikontiola L, Sorsa T, Hayrinen-Immonen R, Salo T (1997). Doxymycine-cyanoacrylate treatment of recurrent aphthous ulcers. *Oral Surg Oral Med Oral Pathol Oral Radiol Endod* **83**: 329–333.

Zain RB (2000). Oral recurrent aphthous ulcers/stomatitis: prevalence in Malaysia and an epidemiological update. *J Oral Sci* **42**: 15–19.

Zakrzewska JM, Robinson P, Williams IG (1997). Severe oral ulceration in patients with HIV infection: a case series. *Oral Dis* **3** (Suppl. 1): S194–S196.

Zegarelli E, Kutscher A, Silver H (1960). Triamcinolone acetonide in the treatment of acute and chronic lesions of the oral mucous membranes. *Oral Surg* **13**: 170–175.