

## Occult Sources of Bleeding in Blunt Trauma: A Narrative Review

Tetsuya Yumoto\*, Yoshinori Kosaki, Yasuaki Yamakawa, Atsuyoshi Iida,  
Hirotsugu Yamamoto, Taihei Yamada, Kohei Tsukahara, Hiromichi Naito,  
Takaaki Osako, and Atsunori Nakao

*Advanced Emergency and Critical Care Medical Center, Okayama University Hospital, Okayama 700-8558, Japan*

Worldwide, hemorrhagic shock in major trauma remains a major potentially preventable cause of death. Controlling bleeding and subsequent coagulopathy is a big challenge. Immediate assessment of unidentified bleeding sources is essential in blunt trauma patients with hemorrhagic shock. Chest/pelvic X-ray in conjunction with ultrasonography have been established classically as initial diagnostic imaging modalities to identify the major sources of internal bleeding including intra-thoracic, intra-abdominal, or retroperitoneal hemorrhage related to pelvic fracture. Massive soft tissue injury, regardless of whether isolated or associated with multiple injuries, occasionally causes extensive hemorrhage and acute traumatic coagulopathy. Specific types of injuries, including soft tissue injury or retroperitoneal hemorrhage unrelated to pelvic fracture, can potentially be overlooked or be considered “occult” causes of bleeding because classical diagnostic imaging often cannot exclude such injuries. The purpose of this narrative review article is to describe “occult” or unusual sources of bleeding associated with blunt trauma.

**Key words:** soft tissue injury, subcutaneous hematoma, non-cavitary hemorrhage, retroperitoneal hemorrhage, hemorrhagic shock

Hemorrhagic shock is a major cause of death among trauma patients [1, 2]. Failure to initiate the appropriate control of bleeding contributes to preventable trauma death [3]. Early acute traumatic coagulopathy, which has been recognized in recent years, complicates hemostasis and is associated with worse outcomes [4, 5]. Massive soft tissue injury (STI) exacerbates acute traumatic coagulopathy by activating anti-coagulant and fibrinolytic pathways [6-9]. STI also induces immunosuppression and increased susceptibility to sepsis and/or subsequent multiple organ failure [10-13]. Specific types of injuries, including extensive STI and retroperitoneal hemorrhage unrelated to pelvic fracture, tend to be underestimated or missed initially,

which may lead to irreversible hemorrhagic shock [14-16]. These injuries cannot be excluded by chest/pelvic X-ray or a focused assessment with sonography for trauma (FAST), which are recommended during the primary survey to immediately identify bleeding sources in hemorrhagic shock patients [17, 18].

These injuries can thus be occult and occasionally lead to hemorrhagic shock, unless the patient is carefully examined or computed tomography (CT) is completed. Injuries such as ‘non-cavitary’ hemorrhage or ‘occult’ causes of bleeding should be recognized, especially among elderly patients; intra-thoracic, intra-abdominal, and retroperitoneal hemorrhage related to pelvic fracture respectively represent the major sources of hemorrhage in trauma [19, 20]. In the present narra-

tive review, we focus on 'occult' sources of bleeding associated with extensive STI or 'non-cavitary' hemorrhage in blunt trauma, which can be vulnerable to diagnostic delay, and we present informative cases from our institution.

## Methods

We conducted a PubMed and Google Scholar literature search for reports published in English from these services' inception until December 2016. The following keywords were selected to identify publications: "soft tissue injury," "soft tissue injuries," "subcutaneous hematoma," "subcutaneous hemorrhage," "retroperitoneal hematoma," "retroperitoneal hemorrhage" or "occult," each in combination with "shock." Citations that were relevant to the subject were also searched.

## Results and Discussion

The types of injuries included Morel-Lavallée lesion (MLL), blunt breast trauma, retroperitoneal hemorrhage due to lumbar artery injury, corona mortis artery avulsion, and other miscellaneous causes of bleeding, which we summarize below, focusing on clinical aspects. Supplementing our summaries are descriptions of illustrative cases from our institution.

### Morel-Lavallée Lesion

MLL is a closed degloving injury induced by shearing force, which is characterized by a filled cystic cavity created by separation of the subcutaneous tissue from the underlying fascia [21]. The lesions classically occur over the greater trochanter, but may also occur in the flank or lumbosacral region [14,22]. Although the development of subcutaneous fluid collection with blood, lymphatic, or necrotic tissue may take several hours or even days and is associated with a delayed diagnosis or a mistaken tumor diagnosis, this development is occasionally complicated by hemodynamic instability or hemorrhagic shock as an initially unidentified origin of bleeding [21-23].

Mao *et al.* reported a patient with a massive subcutaneous hematoma extending from the flank to the pelvic region after being hit by a forklift, causing hemorrhagic shock [22]. Hefny *et al.* reported a case of extensive hematoma in the deep subcutaneous soft tis-

ues of the back after a car crash, causing hemorrhagic shock, in which an obvious source of bleeding was absent in the early phase [24]. Yumoto *et al.* reported a case of subcutaneous hemorrhagic in an extensive area of the lower back after a patient was hit by a car; the patient required transcatheter arterial embolization (TAE) and massive transfusion to resolve shock [25]. The embolization of affected vessels is required when conservative treatment including adequate blood products or compressive bandaging is ineffective or the patient's condition is complicated with other sources of bleeding [25]. Subsequently, percutaneous drainage or surgical debridement and skin grafting should be considered to treat hematoma, fluid collection, or soft tissue infection [22]. Although only three cases have been reported, classic/lumbar MLL can contribute to hemorrhagic shock or acute traumatic coagulopathy in severely injured blunt trauma patients.

### Blunt Breast Trauma

Blunt breast trauma is an uncommon type of chest trauma. In a review of 5,305 female blunt trauma patients at a level I trauma center, only 108 patients (2%) were diagnosed with blunt breast trauma [26]. This STI to the female breast is caused by a vehicle's seat belt. The mechanism of injury is both the shearing force and crush injury that results from the seat belt's shoulder restraint [27]. While most blunt breast trauma cases can be managed conservatively, TAE or surgical hemostat is essential to control hemorrhage with evidence of active arterial extravasation [26,28]. The choice of hemostatic intervention depends on the severity of injury and the availability of the trauma team. The application of an abdominal binder to provide external compression on the breast could be effective for the control of bleeding [27].

**Case presentation.** A 74-year-old woman with no significant medical history was transferred to our emergency department presenting hemorrhagic shock after a motor vehicle accident. She had been wearing a seat belt in the front passenger seat, and her front airbag had deployed. Since the patient responded to fluid resuscitation, she was moved to the CT suite for further investigation of bleeding sources. Contrast-enhanced CT scanning detected a massive hematoma with active arterial bleeding in her right breast, as well as ipsilateral multiple rib fractures and pneumothorax (Fig.1). She

was managed with an elastic compression bandage on her breast and a massive transfusion, which successfully resolved the shock.

### Retroperitoneal Hemorrhage due to Lumbar Artery Injury

Retroperitoneal hemorrhage can cause life-threatening conditions in blunt trauma. Although it is often associated with pelvic fracture, other origins can be potentially occult sources of bleeding due to poor sensitivity of the primary physical exam, X-ray of the chest and pelvis, and FAST [29]. Contrast-enhanced CT scanning is necessary to identify these bleeding sources. Since there are a number of review articles on retroperitoneal hemorrhage associated with pelvic fracture, we focus here on lumbar artery injury.

Lumbar artery injury, an unusual cause of bleeding after blunt trauma, is often complicated, with multiple injuries. It is often overlooked or underestimated as a cause of hemorrhage and leads to a high mortality rate [30,31]. The lumbar arteries are paired branches that arise from the dorsal surface of the abdominal aorta, encircle the vertebral bodies, and divide into small branches to the psoas muscle and to the radicular medullary artery [32]. Transverse process fractures and/or vertebral fractures of the lumbar can cause lumbar artery injury, resulting in a psoas hematoma [33]. When it has been possible to perform, selective embolization of the lumbar artery has appeared to be a safe and effective treatment to control active arterial extravasation [15,30-33]. Otherwise, open surgery often fails to identify the source of the bleeding and can cause further hemorrhage due to decompression [15,30-33].

**Case presentation.** A 62-year-old man with no significant medical history was transferred to our emergency department presenting with hemorrhagic shock after being run over by a car. Chest X-ray and FAST excluded cavitory hemorrhage or pericardial effusion. A pelvic X-ray showed the unstable type of pelvic fracture. The patient was resuscitated with blood transfusions. Contrast-enhanced CT scans revealed multiple transverse process fractures of the lumbar vertebrae with a massive psoas hematoma, as well as a pelvic retroperitoneum hematoma related to the unstable pelvic fracture (Fig. 2). Immediate angiography detected multiple contrast extravasations in the retroperitoneum. The affected lumbar arteries and internal iliac artery were embolized, which successfully resolved his hem-

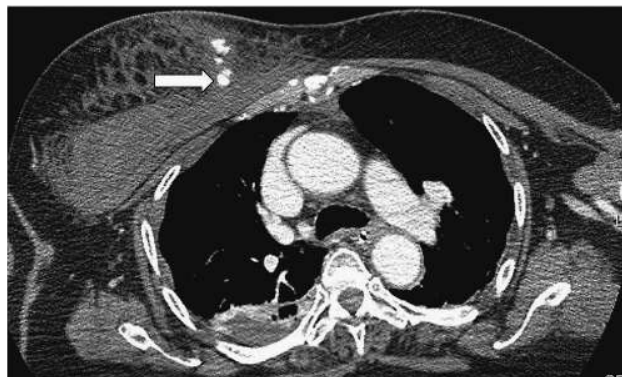

Fig. 1 A contrast-enhanced CT scan showing a massive hematoma in the right breast with contrast extravasation (arrow).

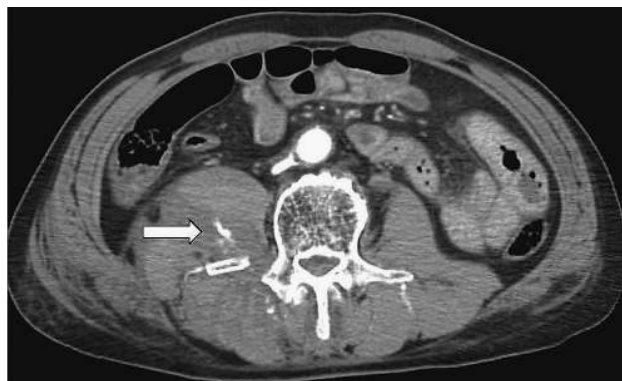

Fig. 2 Contrast extravasation and a massive psoas hematoma associated with a transverse process fracture of the lumbar vertebra (arrow).

orrhagic shock.

### Corona Mortis Artery Avulsion

Exsanguination due to pelvic fracture is one of the major causes of morbidity and mortality among blunt trauma patients. Major pelvic fractures are most likely to be the result of high-energy injuries such as high-speed motor vehicle accidents and high-altitude falls.

In elderly patients, pelvic fractures commonly cause hemorrhagic shock despite low-energy mechanisms of injuries [34]. Although pelvic X-rays in the primary survey may be useful for detecting unstable pelvic fractures that require massive blood products and/or early TAE, the fracture pattern on pelvic X-ray does not consistently predict ongoing hemorrhagic shock or the need for TAE [35-37].

A pubic ramus fracture occasionally causes life-threatening hemorrhage secondary to corona mortis artery avulsion. It often occurs in elderly patients after trivial ground-level falls [38]. The corona mortis, which is located behind the superior pubic ramus, is a common anatomical variant, an anastomosis between the obturator artery, which branches from internal iliac artery, and the external iliac or inferior epigastric artery [39]. Embolization of the obturator artery and/or inferior epigastric artery (which can be additional sources of bleeding) should be performed to resolve hemorrhagic shock secondary to corona mortis artery avulsion due to a pubic ramus fracture [38, 40-42]. Physicians should be aware of this pitfall that can be encountered in a simple pelvic fracture especially in elderly patients, even after a ground-level fall.

**Case presentation.** A 74-year-old woman with a history of chronic hepatitis C virus infection fell at a nursing home. She became hemodynamically unstable 4 h after the injury and was transferred to our emergency department. The pelvic X-ray showed a minimally displaced simple pubic ramus fracture on her right side (Fig. 3A). The consequent contrast-enhanced CT scan revealed a significant hematoma neighboring the right pubic ramus fracture with multiple contrast extravasations (Fig. 3B). The patient was taken to the angiography suite immediately. Selective embolization of a branch of the right obturator artery was carried out, which successfully resolved her shock.

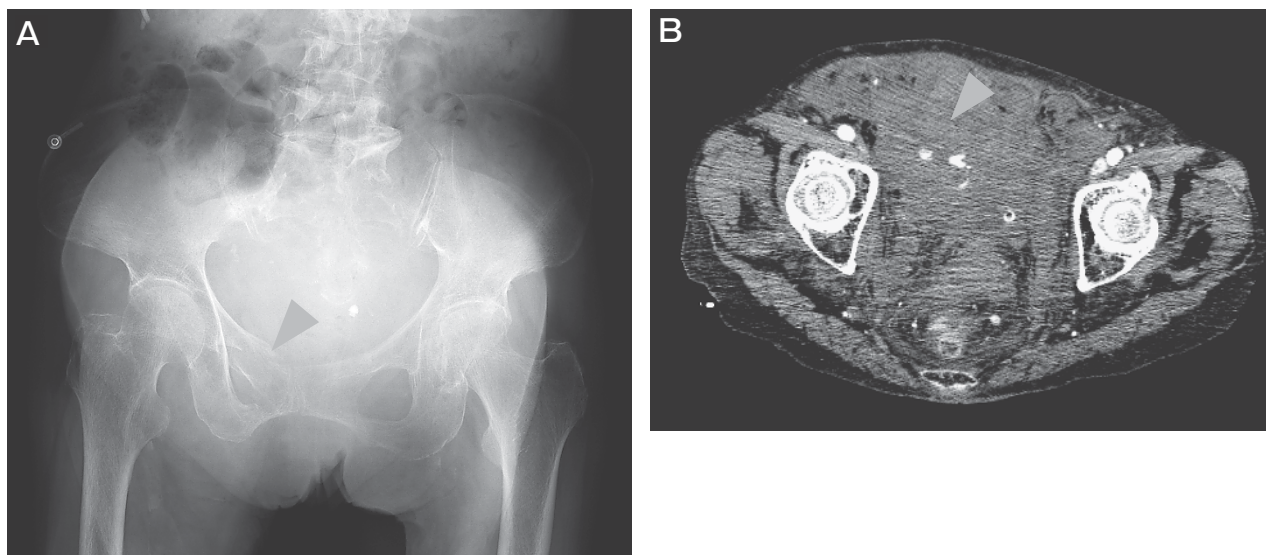
### Other Miscellaneous Causes of Bleeding

The following is a brief review of other miscellaneous potentially occult or unusual causes of bleeding, including scalp lacerations, rectus sheath hematoma, and others.

Since the scalp has a rich blood supply, even isolated scalp lacerations can lead to fatal blood loss. Under circumstances in which a patient exhibits hypotension, scalp injuries may be overlooked or underestimated. Even a simple laceration can contribute to hemorrhagic shock in a patient with multiple injuries. The application of Raney clips, which is a quick and simple technique, is effective to control bleeding [43-45].

Rectus sheath hematoma (RSH) is a relatively uncommon condition associated with anticoagulation and/or induced by abdominal trauma, exercise, cough, or surgical procedures. RSH caused by trauma actually accounted for only 2.4% of cases in a series [46]. RSH is an accumulation of blood in the rectus sheath of the abdominal wall due to disruption of inferior or superior epigastric vessels or rectus muscle caused by direct abdominal trauma [47]. An early diagnosis made with CT is essential to avoid an unnecessary laparotomy and to reduce the development of complications [48]. Most patients can be treated conservatively. TAE is required in patients with persistent bleeding and hemodynamically unstable conditions [49].

Blunt trauma in the inguinal region to the lateral



**Fig. 3** **A**, Pelvic X-ray showing a right pubic ramus fracture with minimal displacement (arrowhead); **B**, Multiple contrast extravasations and massive hematomas were seen around the region of the right pubic ramus fracture (arrowhead).



abdominal wall can cause a massive subcutaneous hematoma. The deep circumflex iliac artery, which arises from the external iliac artery, can be responsible for severe bleeding; TAE of this artery is effective to resolve shock [50-52].

### Optimal Strategies for STI

First, STIs should be recognized in a timely manner. A delay in the diagnosis of STIs may be associated with high morbidity and mortality and may lead to longer hospital stays [53]. Thus, in addition to a careful physical exam, a contrast-enhanced CT scan is necessary for identifying the sources of bleeding [54]. Second, regarding the treatment of a retroperitoneal hemorrhage after a lumbar artery injury, open surgery often fails to identify the source(s) of bleeding, which induces a further hemorrhage due to decompression [30]. Since an extended STI often limits the complete hemostatic compression, the embolization of affected vessels and/or hemostatic resuscitation is required in hemodynamically unstable patients as well as hemodynamically stable patients complicated with acute coagulopathy [25].

Higher D-dimer levels were reported to be associated with poor outcomes in severely injured trauma patients [55]. Another study suggested that the aggressive administration of fresh frozen plasma improves coagulopathy and survival in severely injured blunt-trauma patients [56]. Therefore, patients with STI presenting with hemorrhagic shock and higher d-dimer levels may need both catheter intervention and hemostatic resuscitation.

In conclusion, we summarized unusual, potentially 'occult' sources of bleeding or non-cavitary hemorrhage resulting in hemorrhagic shock in blunt trauma. Specific types of injuries, including massive STI, subcutaneous hematoma, and retroperitoneal hemorrhage should be taken into consideration regardless of the cause of bleeding, as traditional chest/pelvic X-ray and FAST screenings cannot exclude such injuries. In addition to a careful physical examination, an immediate contrast-enhanced CT scan is necessary to detect the bleeding sources. Otherwise, the diagnostic delay can lead to unfavorable outcomes. Angioembolization of the affected vessels, as well as hemostatic resuscitation, are effective to resolve hemorrhagic shock.

### References

1. Kauvar DS and Wade CE: The epidemiology and modern management of traumatic hemorrhage: US and international perspectives. *Crit Care* (2005) 9: S1-9.
2. Kauvar DS, Lefering R and Wade CE: Impact of hemorrhage on trauma outcome: an overview of epidemiology, clinical presentations, and therapeutic considerations. *J Trauma* (2006) 60: 3-11.
3. Tien HC, Spencer F, Tremblay LN, Rizoli SB and Brennen FD: Preventable deaths from hemorrhage at a level I Canadian trauma center. *J Trauma* (2007) 62: 142-146.
4. Maegele M, Lefering R, Yucel N, Tjardes T, Rixen D, Paffrath T, Simanski C, Neugebauer E and Bouillon B; AG Polytrauma of the German Trauma Society (DGU): Early coagulopathy in multiple injury: an analysis from the German Trauma Registry on 8724 patients. *Injury* (2007) 38: 298-304.
5. Mitra B, Cameron PA, Mori A and Fitzgerald M: Acute coagulopathy and early deaths post major trauma. *Injury* (2012) 43: 22-25.
6. Hess JR, Brohi K, Dutton RP, Hauser CJ, Holcomb JB, Kluger Y, Mackway-Jones K, Parr MJ, Rizoli SB, Yukioka T, Hoyt DB and Bouillon B: The coagulopathy of trauma: a review of mechanisms. *J Trauma* (2008) 65: 748-754.
7. Johansson PI, Stensballe J and Ostrowski SR: Current management of massive hemorrhage in trauma. *Scand J Trauma Resusc Emerg Med* (2012) 20: 47.
8. Whelihan MF, Kiankhooy A and Brummel-Ziedins KE: Thrombin generation and fibrin clot formation under hypothermic conditions: an in vitro evaluation of tissue factor initiated whole blood coagulation. *J Crit Care* (2014) 29: 24-30.
9. Pidcoke HF, Isbell CL, Herzig MC, Fedyk CG, Schaffer BS, Chung KK, White CE, Wolf SE, Wade CE and Cap AP: Acute blood loss during burn and soft tissue excisions: An observational study of blood product resuscitation practices and focused review. *J Trauma Acute Care Surg* (2015) 78: 39-47.
10. Wichmann MW, Ayala A and Chaudry IH: Severe depression of host immune functions following closed-bone fracture, soft-tissue trauma, and hemorrhagic shock. *Crit Care Med* (1998) 26: 1372-1378.
11. Streckler W, Gebhard F, Rager J, Brückner UB, Steinbach G and Kinzl L: Early biochemical characterization of soft-tissue trauma and fracture trauma. *J Trauma* (1999) 47: 358-364.
12. Flohé SB, Bangen JM, Flohé S, Agrawal H, Bergmann K and Schade FU: Origin of immunomodulation after soft tissue trauma: potential involvement of extracellular heat-shock proteins. *Shock* (2007) 27: 494-502.
13. Howard BM, Miyazawa BY, Dong W, Cedron WJ, Vilardi RF, Ruf W and Cohen MJ: The tissue factor pathway mediates both activation of coagulation and coagulopathy after injury. *J Trauma Acute Care Surg* (2015) 79: 1009-1013.
14. Buyukkaya A, Güneş H, Özel MA, Buyukkaya R, Onbas Ö and Saritas A: Lumbar Morel-Lavallee lesion after trauma: a report of 2 cases. *Am J Emerg Med* (2015) 1116: e5-6.
15. Sofocleous CT, Hinrichs CR, Hubbi B, Doddakashi S, Bahramipour P and Schubert J: Embolization of isolated lumbar artery injuries in trauma patients. *Cardiovasc Intervent Radiol* (2005) 28: 730-735.
16. Akpınar E, Peynircioglu B, Turkbey B, Cil BE and Balkanci F: Endovascular management of life-threatening retroperitoneal bleeding. *ANZ J Surg* (2008) 78: 683-687.
17. Rossaint R, Bouillon B, Cerny V, Coats TJ, Duranteau J, Fernández-Mondéjar E, Filipescu D, Hunt BJ, Komadina R, Nardi G, Neugebauer EA, Ozier Y, Riddez L, Schultz A, Vincent JL and Spahn DR: The European guideline on management of major bleeding and coagulopathy following trauma: fourth edition. *Crit Care* (2016) 20: 100.

18. American College of Surgeons Committee on Trauma: ATLS® Student Manual 9th Edition. Chicago (2012) pp65-68.
19. Pedowitz RA and Shackford SR: Non-cavitary hemorrhage producing shock in trauma patients: incidence and severity. *J Trauma* (1989) 29: 219-222.
20. Ohmori T, Kitamura T, Tanaka K, Saisaka Y, Ishihara J, Onishi H, Nojima T, Yamamoto K, Matsumoto T and Tokioka T: Bleeding sites in elderly trauma patients who required massive transfusion: a comparison with younger patients. *Am J Emerg Med* (2016) 34: 123-127.
21. Li H, Zhang F and Lei G: Morel-Lavallee lesion. *Chin Med J (Engl)* (2014) 127: 1351-1356.
22. Mao RD, Tan EP and Goh HK: An unusual cause of haemorrhagic shock from a subcutaneous haematoma: a Morel-Lavallée lesion. *Singapore Med J* (2015) 56: 62-64.
23. Jalota L, Ukaigwe A and Jain S: Diagnosis and Management of Closed Internal Degloving Injuries: The Morel-Lavallée Lesion. *J Emerg Med* (2015) 49: 1-4.
24. Hefny AF, Kaka LN, Salim el NA and Al Khoury NN: Unusual case of life threatening subcutaneous hemorrhage in a blunt trauma patient. *Int J Surg Case Rep* (2015) 15: 119-122.
25. Yumoto T, Sato K, Ugawa T and Ujike Y: An unusual case of a patient who presented with haemorrhagic shock following massive subcutaneous haematomas of the lower back due to blunt trauma. *BMJ Case Rep* (2015) pii: bcr2015211645.
26. Sanders C, Cipolla J, Stehly C and Hoey B: Blunt breast trauma: is there a standard of care? *Am Surg* (2011) 77: 1066-1069.
27. Madden B, Phadtare M, Ayoub Z and Chebl RB: Hemorrhagic shock from breast blunt trauma. *Int J Emerg Med* (2015) 8: 83.
28. Song CT, Teo I and Song C: Systematic review of seat-belt trauma to the female breast: a new diagnosis and management classification. *J Plast Reconstr Aesthet Surg* (2015) 68: 382-389.
29. Wang F and Wang F: The diagnosis and treatment of traumatic retroperitoneal hematoma. *Pak J Med Sci* (2013) 29: 573-576.
30. Yuan KC, Hsu YP, Wong YC, Fang JF, Lin BC and Chen HW: Management of complicated lumbar artery injury after blunt trauma. *Ann Emerg Med* (2011) 58: 531-535.
31. Hamid RS, ul HT, Chishti I and Azeemuddin M: Post traumatic avulsion of lumbar artery: a rare cause of retroperitoneal haemorrhage treated by glue embolization. *J Pak Med Assoc* (2010) 60: 487-489.
32. Janik V, Martinek V, Pádr R, Lisy J, Neuwirth J, Pafcugová J, Vanecek T and Stejskal J: Embolization of lumbar artery due to retroperitoneal bleeding following renal biopsy. *Nephrol Dial Transplant* (2005) 20: 820-822.
33. Eun JP and Oh YM: Traumatic lumbar artery rupture after lumbar spinal fracture dislocation causing hypovolemic shock: An endovascular treatment. *Br J Neurosurg* (2015) 29: 742-744.
34. Henry SM, Pollak AN, Jones AL, Boswell S and Scalea TM: Pelvic fracture in geriatric patients: a distinct clinical entity. *J Trauma* (2002) 53: 15-20.
35. Obaid AK, Barleben A, Porral D, Lush S and Cinat M: Utility of plain film pelvic radiographs in blunt trauma patients in the emergency department. *Am Surg* (2006) 72: 951-954.
36. Fu CY, Wu SC, Chen RJ, Wang YC, Chung PK, Yeh CC and Huang HC: Evaluation of pelvic fracture stability and the need for angioembolization: pelvic instabilities on plain film have an increased probability of requiring angioembolization. *Am J Emerg Med* (2009) 27: 792-796.
37. Sarin EL, Moore JB, Moore EE, Shannon MR, Ray CE, Morgan SJ, and Smith WR: Pelvic fracture pattern does not always predict the need for urgent embolization. *J Trauma* (2005) 58: 973-977.
38. Ten Broek RP, Bezemer J, Timmer FA, Mollen RM and Boekhoudt FD: Massive haemorrhage following minimally displaced pubic ramus fractures. *Eur J Trauma Emerg Surg* (2014) 40: 323-330.
39. Darmanis S, Lewis A, Mansoor A and Bircher M: Corona mortis: an anatomical study with clinical implications in approaches to the pelvis and acetabulum. *Clin Anat* (2007) 20: 433-439.
40. Garrido-Gómez J, Pena-Rodríguez C, Martín-Noguerol T and Hernández-Cortés P: Corona mortis artery avulsion due to a stable pubic ramus fracture. *Orthopedics* (2012) 35: 80-82.
41. Kong WM, Sun CK and Tsai IT: Delayed presentation of hypovolemic shock after a simple pubic ramus fracture. *Am J Emerg Med* (2012) 30: 1-4.
42. Daeubler B, Anderson SE, Leunig M and Triller J: Hemorrhage secondary to pelvic fracture: coil embolization of an aberrant obturator artery. *J Endovasc Ther* (2003) 10: 676-680.
43. Lemos MJ and Clark DE: Scalp lacerations resulting in hemorrhagic shock: case reports and recommended management. *J Emerg Med* (1988) 6: 377-379.
44. Sykes LN Jr and Cowgill F: Management of hemorrhage from severe scalp lacerations with Raney clips. *Ann Emerg Med* (1989) 18: 995-996.
45. Turnage B and Maul KI: Scalp laceration: an obvious 'occult' cause of shock. *South Med J* (2000) 93: 265-266.
46. Cherry WB and Mueller PS: Rectus sheath hematoma: review of 126 cases at a single institution. *Medicine (Baltimore)* (2006) 85: 105-110.
47. Trujillo L, Naranjo S, Cardozo A and Alvarez B: Ultrasound-guided percutaneous drainage of a traumatic abdominal wall hematoma in the emergency department. *World J Emerg Med* (2012) 3: 308-310.
48. Hatjipetrou A, Anyfantakis D and Kastanakis M: Rectus sheath hematoma: a review of the literature. *Int J Surg* (2015) 13: 267-271.
49. Rimola J, Perendreu J, Falcó J, Fortuño JR, Massuet A and Branera J: Percutaneous arterial embolization in the management of rectus sheath hematoma. *AJR Am J Roentgenol* (2007) 188: 497-502.
50. Lefere P, Gryspeerdt S, Van Holsbeeck B and Baekelandt M: Diagnosis and treatment of expanding haematoma of the lateral abdominal wall after blunt abdominal trauma. *Eur Radiol* (1999) 9: 1553-1555.
51. Nishiuchi T, Horikawa H, Hinami J and Yokota J: An unusual case of noncavitary hemorrhage revealed by intravenous contrast-enhanced computed tomography. *J Emerg Med* (2002) 22: 21-25.
52. Yumoto T, Sato K, Tanaka R and Ujike Y: Seat belt injury to the inguinal region presenting with hemorrhagic shock. *J Emerg Med* (2013) 45: 828-830.
53. Pfeifer R and Pape HC: Missed injuries in trauma patients: A literature review. *Patient Saf Surg* (2008) 2: 20.
54. Maturen KE, Adusumilli S, Blane CE, Arabi S, Williams DM, Fitzgerald JT and Vine AA: Contrast-enhanced CT accurately detects hemorrhage in torso trauma: direct comparison with angiography. *J Trauma* (2007) 62: 740-745.
55. Hayakawa M, Maekawa K, Kushimoto S, Kato H, Sasaki J, Ogura H, Matauoka T, Uejima T, Morimura N, Ishikura H, Hagiwara A, Takeda M, Kaneko N, Saitoh D, Kudo D, Kanemura T, Shibusawa T, Furugori S, Nakamura Y, Shiraishi A, Murata K, Mayama G, Yaguchi A, Kim S, Takasu O and Nishiyama K: HIGH D-DIMER LEVELS PREDICT A POOR OUTCOME IN PATIENTS WITH SEVERE TRAUMA, EVEN WITH HIGH FIBRINOGEN LEVELS ON ARRIVAL: A MULTICENTER RETROSPECTIVE STUDY. *Shock* (2016) 45: 308-314.
56. Hagiwara A, Kushimoto S, Kato H, Sasaki J, Ogura H, Matsuoaka T, Uejima T, Hayakawa M, Takeda M, Kaneko N, Saitoh D, Otomo Y, Yokota H, Sakamoto T, Tanaka H, Shiraishi A, Morimura N and Ishikura H: Can Early Aggressive Administration of Fresh Frozen Plasma Improve Outcomes in Patients with Severe Blunt Trauma?--A Report by the Japanese Association for the Surgery of Trauma. *Shock* (2016) 45: 495-501.