

LETTERS TO THE EDITOR

Diffuse intraepithelial sebaceous carcinoma of the conjunctiva

EDITOR.—Recently, Margo and coworkers¹ described a case of intraepithelial sebaceous carcinoma of the conjunctiva and eyelid erroneously diagnosed as a unilateral blepharoconjunctivitis for 10 years. This was reported to be the first published case of de novo sebaceous carcinoma in the conjunctival epithelium without evidence of a tumour focus within the eyelid. We present another case of diffuse intraepithelial sebaceous carcinoma of the conjunctiva presenting as blepharoconjunctivitis and superior limbic keratitis of 10 months' duration.

CASE REPORT

A 70-year-old woman presented with a 10 month history of left sided, unilateral redness, tearing, and swelling of the lids. Examination showed marked conjunctival injection and thickening along the superior temporal and inferotemporal limbus, with moderate lid thickening, and pale corneal changes (Fig 1). There was mild foreshortening and scarring of the inferior fornix. A presumptive diagnosis of carcinoma in situ was considered with a secondary diagnosis of sebaceous gland carcinoma with intraepithelial spread. Biopsies of several sites of limbal, bulbar, and palpebral conjunctiva (Fig 2) revealed a diffuse intraepithelial malignancy with pagetoid and bowenoid growth and moderate chronic non-granulomatous inflammation in the underlying substantia propria but no evidence of stromal invasion. The tumour cells were markedly polymorphic and often exhibited multiple nucleoli. Mitotic figures were frequent (Fig 2B). Occasional dyskeratosis was noted but in many tumour cells the cytoplasm appeared foamy. Stains for mucin, mucopolysaccharides, and melanin within tumour cells were inconclusive, nor could lipid be demonstrated in either frozen or paraffin sections. Staining with OM1 antibody (kindly provided by Dr H Grossniklaus, Emory University, Atlanta, GA, USA) against sebaceous gland antigen, however, revealed positive labelling of tumour cells.

Exenteration was performed and histology showed diffuse infiltration of the tarsal and bulbar conjunctiva by tumour cells, extending intraepithelially across the superior, and to a lesser degree the inferior, limbus onto the cornea. The inferior tarsal plate was largely destroyed and replaced by irregular fibrotic scar tissue, within which a small focus of tumour cells in a sebaceous gland was

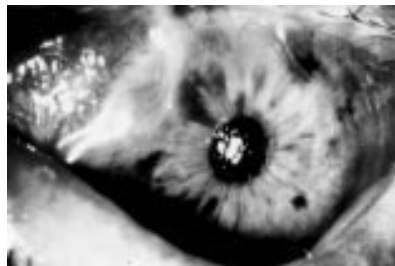

Figure 1 Clinical photograph of the patient's eye before enucleation. Note diffusely inflamed conjunctiva, loss of lower lid lashes, and corneal opacification near the superior limbus.

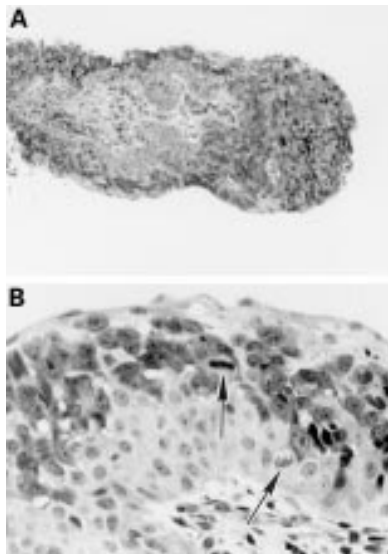


Figure 2 Representative light microscopic appearance of first conjunctival biopsy (Histology No B91-281). (A) Note irregularly thickened epithelium and moderate inflammatory cell infiltrate in the substantia propria. (Haematoxylin and eosin, $\times 70$.) (B) Higher magnification of intraepithelial malignant cells infiltrating between apparently normal conjunctival epithelium. Numerous mitotic figures (arrows) are present. (Haematoxylin and eosin, $\times 280$.)

observed. At the inferior medial lid margin intraepithelial tumour spread into the punctum lacrimale and upper canaliculus was present but the lacrimal sac was free of malignant infiltration. In this area, another focus of intraepithelial malignancy was detected at the base of a pilosebaceous follicle while the overlying surface epithelium was apparently normal.

COMMENT

The origin of the intraepithelial form of sebaceous carcinoma of the eyelid is still uncertain.¹⁻⁴ While some believe that sebaceous metaplasia of the epithelium must precede neoplastic transformation, Margo *et al*¹ have suggested that the tumour may arise de novo within the conjunctival epithelium since, in their case, no clear focus of neoplasia could be demonstrated in sebaceous glands of the eyelid.

In the present case, serial sections revealed evidence of a connection of the intraepithelial changes to a focus of neoplasia in a sebaceous gland of the lower lid. However, the surrounding basal lamina of this sebaceous gland remained intact. In addition, invasion of the basal lamina could not be demonstrated in any of the multiple biopsies or in the exenteration specimen. This pattern of spread is of particular interest as extensive intraepithelial neoplasia of the conjunctiva and cornea was most prevalent superiorly, and the meibomian glands of the upper lid appeared unremarkable. Rao *et al*² have suggested that intraepithelial spread from a nidus of sebaceous tumour demonstrates decreasing epithelial involvement furthest from the tumour. This case appears to contradict the logic of this pattern of spread.

These findings, however, do not exclude the possibility of multicentric origin of the tumour. The additional focus of carcinomatous change in a pilosebaceous unit of the caruncle is suggestive of multicentricity as serial sections revealed no contiguity with surface intraepithelial neoplasia. This may represent separate origins of carcinoma as a result of some innate cellular abnormality of epithelium in this patient.

Intraepithelial spread of sebaceous carcinoma is associated with a poor prognosis.⁵ Despite the absence of invasion in this case, exenteration was considered the appropriate therapy since a localised conjunctival and corneal epithelial excision in this case was not feasible. The presence of a tumour nidus in the lower lid suggests that this latter course of action would not have proved definitive. The presence of extension into the lacrimal punctum lends further credence to this hypothesis.

KARIN U LOEFFLER

Universitäts-Augenklinik, Killianstrasse 5,
D-79106 Freiburg, Germany

JAY I PERLMAN

Department of Ophthalmology, University of Illinois,
1855 W Taylor Street, Chicago IL 60612,
and Department of Ophthalmology,
Loyola University Chicago, 2160 S First Avenue,
Maywood IL 60153, USA

Correspondence to: Karin U Loeffler, MD,
Universitäts-Augenklinik Sigmund-Freud-Strasse
5, D-53105 Bonn, Germany.

Accepted for publication 14 October 1996

- Margo CE, Lessner A, Stern GA. Intraepithelial sebaceous carcinoma of the conjunctiva and skin of the eyelid. *Ophthalmology* 1992;99:227-31.
- Rao NA, Hidayat AA, McLean IW, Zimmerman LE. Sebaceous carcinomas of the ocular adnexa. A clinicopathologic study of 104 cases, with five-year follow-up data. *Hum Pathol* 1982;13:113-22.
- Kass LG, Hornblass A. Sebaceous carcinoma of the ocular adnexa. *Surv Ophthalmol* 1989;33:477-90.
- Leibsohn J, Bullock J, Waller R. Full-thickness eyelid biopsy for presumed carcinoma-in-situ of the palpebral conjunctiva. *Ophthalmic Surg* 1982;13:840-2.
- Rao NA, McLean IW, Zimmerman LE. Sebaceous carcinoma of the eyelid and caruncle. Correlation of clinicopathologic features with prognosis. In: Jakobiec FA, ed. *Ocular and adnexal tumors*. Birmingham, AL: Aesculapius, 1978:461-76.

Diagnosis of Dieffenbachia induced corneal injury by confocal microscopy

EDITOR.—*Dieffenbachia*, a tropical house plant, belongs to the family Araceae. Throughout the plant, specialised cells release needle-like crystals of calcium oxalate (raphides) in an explosive manner upon breaking the stem or the branches.¹ These may penetrate skin and mucous membranes, and also involve the cornea. We present the first follow up of *Dieffenbachia* induced corneal lesions using a real time confocal in vivo slit scanning microscope.^{2,3}

CASE REPORT

A 26-year-old woman presented herself at the emergency room with pain, photophobia, and foreign body sensation in her right eye. These symptoms appeared immediately after breaking a leaf of the house plant *Dieffenbachia* 1 day earlier. She was otherwise healthy, except

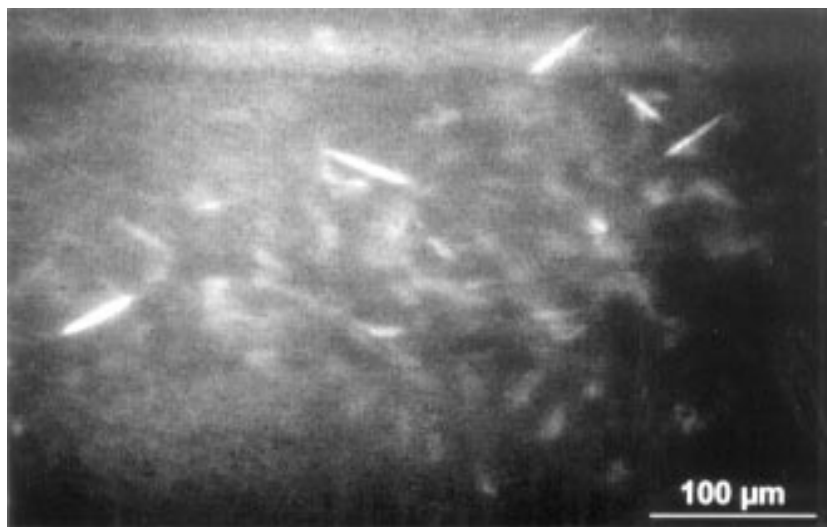


Figure 1 Confocal microscopy 1 month after the injury. Numerous raphides could still be found in the corneal stroma. The keratocytes demonstrated normal reflectivity. There was no inflammatory cell infiltration.

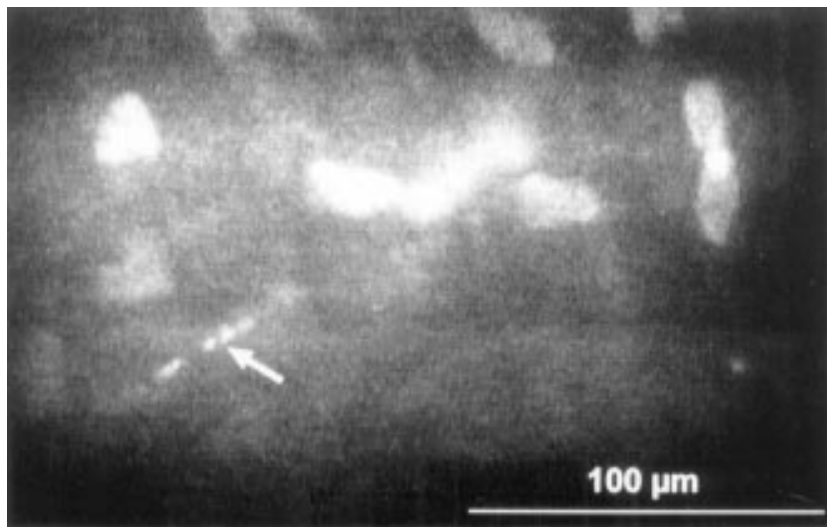


Figure 2 Two months after the injury, confocal microscopy demonstrated fragmentation of the raphides (arrow).

for an adenovirus keratoconjunctivitis 4 years earlier in her left eye. The patient's ocular examination on presentation showed a best corrected visual acuity of 20/25 in the right eye and 20/20 in the left eye. Slit-lamp biomicroscopy of the right eye showed fine punctate opacities throughout the corneal stroma. The remainder of the ocular examination was normal, except for subepithelial opacities in the left cornea related to the previous adenovirus infection.

The patient underwent confocal in vivo slit scanning video microscopy, which offers real time non-invasive and non-contact serial imaging of corneal segments with resolution and imaging contrast.² A 25/0.60 water immersion objective was used. For higher optical resolution, we used a 50/1.00 water immersion objective. Confocal microscopy, performed at 1, 4, and 8 weeks after the trauma, demonstrated highly reflective elongated structures (Fig 1) in all layers of the cornea. The cornea's architecture remained globally undisturbed. There was no inflammatory cell infiltration. We observed diminution and fragmentation of the raphides (Fig 2) at 2 months, probably as a consequence of resorption.

COMMENT

Dieffenbachia induced corneal lesions represent a benign affection of the anterior segment of the eye. Treatment should be aimed at relieving pain using mild steroids and cycloplegics. Confocal microscopy highly improved visualisation of the raphides. Usually there is a good history of trauma such as this so that establishing the diagnosis should not be problematic. However, in cases of ocular irritation with unknown aetiology, particularly with a history of contact with plant, confocal microscopy can establish the diagnosis of *Dieffenbachia* induced injury by demonstrating the crystals of calcium oxalate.

AUGUSTE G-Y CHIOU
ROBIN CADEZ
MATTHIAS BÖHNKE

Department of Ophthalmology,
University Hospital of Bern, 3010 Bern, Switzerland

Correspondence to: Auguste G-Y Chiou, MD, Edward S Harkness Eye Institute, Columbia Presbyterian Medical Center, 635 W 165th Street, Suite 303, New York, NY 10032, USA.

Accepted for publication 14 October 1996

- 1 Rauber A. Observations on the idioblasts of *Dieffenbachia*. *J Toxicol Clin Toxicol* 1985;23:79-90.
- 2 Wiegand W, Thaeer AA, Kroll P, Geyer OC, Garcia AJ. Optical sectioning of the cornea with a new confocal in-vivo slit-scanning video-microscope. *Ophthalmology* 1995;102:568-75.
- 3 Böhnke M, Thaeer AA. Untersuchung der Kornea mit einem neuen konfokalen Mikroskop. In: Lund O-E, Waubke TN, eds. *Bildgebende Verfahren in der Augenheilkunde*. Stuttgart: Ferdinand Enke Verlag, 1994:47-53.

Elevation of serum IGF-1 precedes proliferative diabetic retinopathy in Mauriac's syndrome

EDITOR.—Mauriac's syndrome is a rare condition of insulin dependent diabetic children with long standing poor glycaemic control, growth retardation, and liver enlargement in whom improvement of diabetes control accelerates diabetic retinopathy.¹ The cause of this paradoxical progression of diabetic retinopathy is unknown.

CASE REPORT

A 21-year-old man, diabetic since the age of 2, was first admitted to our hospital because of short stature and delayed sexual maturation. He presented with all signs of Mauriac's syndrome: height 155 cm (below third percentile), body weight 41 kg, prepubertal sexual development (pubic hair Tanner stage 3, genital stage 2), liver enlargement, and subnormal serum concentration of insulin-like growth factor 1 (IGF-1) of 162 ng/ml. His diabetes had been poorly controlled ever since, the actual HbA_{1c} (normal < 5.6%, high performance liquid chromatography) being 13.3%, corresponding to an average glycaemia of about 20 mmol/l. Alkaline phosphatase was elevated (317 U/l) indicating delayed bone maturation; total cholesterol (314 mg/dl), low density lipoprotein cholesterol (263 mg/dl), triglycerides (375 mg/dl), and proteinuria (587 mg/l) were also abnormal as a consequence of poor diabetes control. Basal and stimulated levels of growth hormone, gonadotrophins, prolactin, and thyroid stimulating hormone were normal, as were testosterone, 'free' thyroxine and triiodothyronine, parathyroid hormone, osteocalcin, and vitamin D metabolites. Funduscopy revealed mild non-proliferative diabetic retinopathy, corresponding to retinopathy level 1.² Visual acuity was 1.0. Treatment aimed at improving diabetes control was initiated by increasing the insulin dosage. Serum IGF-1, HbA_{1c}, and retinopathy levels were followed prospectively. Eight months after intensifying insulin therapy, HbA_{1c} had declined to 11.9% (corresponding to an average glycaemia of 18 mmol/l), serum IGF-1 had increased to 326 ng/ml, and the patient had grown by 2 cm. However, retinopathy had progressed to a severe non-proliferative state with substantial ischaemia at the posterior pole and diffuse macular oedema (level 3) with a drop in visual acuity to 0.8 (Fig 1A and B). Limited central laser coagulation was commenced, followed by panretinal laser coagulation. After a further 2 months, IGF-1 had further increased to 482 ng/ml (Fig 2), while longitudinal growth was continuing. Simultaneously, diabetic retinopathy progressed to the proliferative state (level 5). All neovascularisations regressed upon completion of panretinal laser coagulation, and visual acuity was restored (level 4). Shortly after that, growth velocity declined (yielding a final height after 2 years of observation of 161.5 cm) as did the IGF-1 concentration (227 ng/ml).

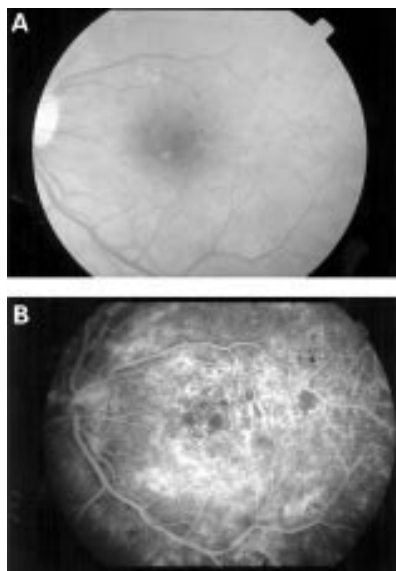


Figure 1 (A) Fundus of the left eye after 8 months of improved insulin therapy; severe non-proliferative diabetic retinopathy with diffuse maculopathy. (B) Same eye, fluorescein angiogram showing IRMAs and areas of capillary non-perfusion at the posterior pole.

COMMENT

This is the first prospective and close follow up of serum IGF-1 concentrations and HbA_{1c} in a poorly controlled diabetic patient, in whom deterioration of diabetic retinopathy in response to improving glycaemia was to be expected.^{1,3} IGF-1, which has growth promoting and angiogenic effects, was shown to increase after inducing improved glycaemic control, and this surge in serum IGF-1 concentration preceded retinal neovascularisation by 2 months. Exogenous IGF-1 can have serious side effects on the retinal circulation and can cause 'papillopathy', as has been described by Gallagher *et al.*⁴ and others.⁵ Endogenous IGF-1 has been linked to proliferative retinopathy by other authors.⁶ Consistent with previous observations in diabetic patients^{7,8} we hypothesise from our case that an acceleration of diabetic retinopathy after abruptly improving glycaemic control in patients with IDDM and Mauriac's syndrome may be induced by a surge in serum IGF-1 concentration. This may also explain progres-

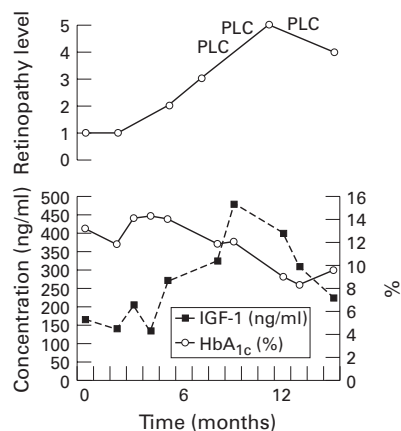


Figure 2 Retinopathy level (1 = background, 5 = proliferative retinopathy), serum IGF-1, and HbA_{1c} in a patient with Mauriac's syndrome 0-14 months after improving diabetes control. PLC = panretinal laser coagulation.

sion of diabetic retinopathy in puberty⁹ and in pregnancy¹⁰; both conditions are associated with increasing IGF-1 levels. Increasing serum IGF-1 may, thus, have a role in the progression of diabetic retinopathy to the proliferative state.

E CHANTELAU
H EGGERT
T SEPPEL
E SCHÖNAU

Department of Internal Medicine,
Heinrich Heine University of Dusseldorf, Germany

C ALTHAUS
Department of Ophthalmology,
Heinrich Heine University of Dusseldorf, Germany

Correspondence to: Ernst Chantelau, Diabetesambulanz MNR-Klinik, Heinrich-Heine University, PO Box 10 10 07, D-40001 Dusseldorf, Germany.
Accepted for publication 14 October 1996

- Daneman D, Drash AL, Lobes LA, Becker DJ, Baker LM, Travis LB. Progressive retinopathy with improved control in diabetic dwarfism (Mauriac's syndrome). *Diabetes Care* 1981;4:360-5.
- Aldington SJ, Kohner EM, Meurer S, Klein R, Sjolie AK for the EURODIAB-IDDM Complications Study Group. Methodology for retinal photography and assessment of diabetic retinopathy: the EURODIAB IDDM Complications Study. *Diabetologia* 1995;38:437-44.
- Chantelau E. Rapidly progressing diabetic retinopathy upon improved metabolic control. (*Letter*) *J Diab Comp* 1993;7:63-4.
- Gallagher AP, Bell E, Davidson J, MacCuish AC, Quin JD. Bilateral central retinal vein occlusion (CRVO) following chronic administration of recombinant insulin-like growth factor-1 (rIGF-1) in the Rabson-Mendenhall syndrome. (*Abstract*) *Diabetic Med* 1996;13 (Suppl 3): S11.
- Guevara-Aguirre J, Vasconez O, Martinez V, Martinez AL, Rosenbloom AL, Diamond FB, *et al.* A randomized, double blind, placebo-controlled trial on safety and efficacy of recombinant human insulin-like growth factor-1 in children with growth hormone receptor deficiency. *J Clin Endocrinol Metab* 1995;80:1393-8.
- Meyer-Schwickerath R, Pfeiffer A, Blum WF, Freyberger H, Klein M, Lösche C, *et al.* Vitreous levels of insulin-like growth factors I and II and the insulin-like growth factor binding proteins 2 and 3 increase in neovascular eye disease. *J Clin Invest* 1993;92:2620-5.
- Merimee TJ, Zapf J, Froesch ER. Insulin-like growth factors: studies in diabetics with and without retinopathy. *N Engl J Med* 1983;309:527-30.
- Hyer SL, Sharp PS, Sleightholm M, Burrin JM, Kohner EM. Progression of diabetic retinopathy and changes in serum insulin-like growth factor 1 (IGF-1) during continuous subcutaneous insulin infusion (CSII). *Horm Metabol Res* 1989;21:18-22.
- Dunger DB. Insulin and insulin-like growth factors in diabetes mellitus. *Arch Dis Child* 1995;72:469-71.
- Chew EY, Mills JL, Metzger BE, Remaley NA, Jovanovic-Peterson L, Knopp RH, *et al.* Metabolic control and progression of retinopathy. The Diabetes in Early Pregnancy Study. *Diabetes Care* 1995;18:631-7.

Morganella morganii postoperative endophthalmitis

EDITOR.—Postoperative bacterial endophthalmitis is an uncommon but potentially blinding complication of intraocular surgery.¹ Most postoperative endophthalmitis results from Gram positive organisms,² although Gram negative organisms are now recognised to constitute from 15 to 30% of cases in some series.³ This stated, few cases of *Morganella morganii* (formerly known as *Proteus*) postoperative endophthalmitis have been reported, and all but one³ have had poor visual outcomes.²⁻⁶ We now describe a patient who developed *M. morganii* endophthalmitis following uncomplicated extracapsular cataract extraction, and in whom early, aggressive treatment resulted in good initial visual recovery.

CASE REPORT

A 68-year-old Filipino woman with well controlled adult onset diabetes mellitus underwent uncomplicated extracapsular cataract extraction by phacoemulsification followed by placement of a posterior chamber intraocular lens. The skin and eye were prepared with povidone-iodine preoperatively. The patient failed to return for follow up for 3 days, at which time she presented with hand movement vision, marked corneal oedema, and a 4+ anterior chamber cell and flare with hypopyon (Hogan, Kimura, and Thygeson grading⁷). The intraocular pressure was normal. The fundus was not visible but ultrasound failed to demonstrate vitritis. The diagnosis of early postoperative endophthalmitis was made, and anterior chamber and vitreous aspirates were taken for Gram stain and culture. The patient was then treated with: (1) intravitreal vancomycin (1 mg/0.1 ml), ceftazidime (2.25 mg/0.1 ml), and dexamethasone (0.4 mg/0.1 ml); (2) subconjunctival vancomycin (25 mg/0.5 ml) and ceftazidime (100 mg/0.5 ml); (3) intravenous vancomycin (500 mg, every 6 hours) and ceftazidime (1000 mg, every 6 hours); and (4) topical hyoscine (scopolamine) (0.25%, one drop, four times a day) and prednisolone acetate (1%, one drop, every hour). Initial Gram stains were negative. On the sixth day after cataract surgery the streak culture of the anterior chamber aspirate grew a few *M. morganii* colonies sensitive to ceftazidime, ciprofloxacin, and tobramycin (automated identification and sensitivity testing by Microscan, Dade International Inc, West Sacramento, CA, USA). The intravenous vancomycin was discontinued and the patient was placed on fortified, topical tobramycin (14 mg/ml, one drop, every 2 hours). The patient was discharged on the eighth day after cataract surgery on topical, fortified tobramycin (14 mg/ml, one drop, every 2 hours), prednisolone acetate (1%, one drop, every 2 hours), and hyoscine (0.25%, one drop, four times per day), and a 7 day course of oral ciprofloxacin (250 mg, four times a day). Examination just before discharge revealed a vision of brisk hand movement, moderate corneal oedema, and 2+ cell and flare in the anterior chamber with no residual hypopyon. The fundus remained poorly visible.

Over the 2 months following surgery, the patient's vision gradually improved to 20/80, and the anterior chamber reaction decreased to less than 1+ cell and flare. Antibiotics were discontinued and topical prednisolone acetate 1% was tapered to one drop, four times a day. As the view of the fundus improved, scattered intraretinal haemorrhages were visualised, and thought to represent the well recognised phenomenon of accelerated background diabetic retinopathy following cataract surgery.^{8,9}

Two weeks after examination, when she was found to have a visual acuity of 20/80 and 10 weeks after cataract surgery, the patient presented with counting fingers vision and a 4+ anterior chamber reaction with a small hypopyon, having 2 days earlier abruptly discontinued her topical prednisolone acetate drops. The posterior pole was again poorly visualised. Both rebound uveitis and recurrent endophthalmitis were considered as possibilities. However, given the need for prompt and aggressive treatment of endophthalmitis, the decision was made to perform a pars plane vitrectomy for Gram stain, culture, and intravitreal delivery of vancomycin and ceftazidime, antibiotics chosen for broad spectrum coverage in the event of infection with a second, perhaps initially unidentified,

organism. In addition, subconjunctival and intravenous vancomycin and ceftazidime, as well as topical prednisolone acetate, were also given, all at the doses used on initial presentation more than 10 weeks earlier. No capsular abscess or plaque was seen. All Gram stains and cultures were negative. Two weeks after the vitrectomy the patient developed a non-clearing vitreous haemorrhage and was noted to have rubeosis iridis sparing the angle. Intraocular pressure remained normal. A second pars plana vitrectomy was performed revealing intraretinal haemorrhages in all four quadrants consistent with a central retinal vein occlusion. Endolaser panretinal photocoagulation was given intraoperatively. Following surgery and for the ensuing 7 months, the patient's vision remained poor at counting fingers, despite complete regression of rubeosis and clear media.

COMMENT

Morganella morganii is a rare but usually devastating cause of postoperative endophthalmitis.²⁻⁶ In those few reported cases the visual outcome has been poor, the one exception being the patient reported by Smolin,¹ who, like our patient, received early and aggressive intervention. However, unlike Smolin's patient, our patient developed an acute increase in anterior chamber inflammation after abruptly discontinuing her topical prednisolone acetate. While there are many possible causes of delayed, postoperative intraocular inflammation,¹⁰ the most likely causes in our patient were recurrent endophthalmitis, either due to *M morganii* or perhaps a second, initially unidentified, organism, and rebound uveitis in response to the patient abruptly discontinuing topical prednisolone acetate. Given the possibility of endophthalmitis and the importance of prompt treatment in this setting, we chose early pars plana vitrectomy for Gram stain, culture, and to deliver intravitreal antibiotics. Since the presentation and treatment of our patient, the results of the Endophthalmitis Vitrectomy Study (EVS) Group, a randomised trial of immediate pars plana vitrectomy and systemic antibiotics for the treatment of postoperative bacterial endophthalmitis,¹¹ have suggested that systemic antibiotics as used in our patient may not be necessary, and that immediate vitrectomy appears to add no benefit unless the presenting visual acuity is down to light perception. However, the patients reported in this study all had acute, postoperative endophthalmitis, and so these results may not be applicable to the type of delayed, postoperative endophthalmitis considered in our patient.

Most organisms implicated in postoperative endophthalmitis exist as normal ocular flora. In contrast, *M morganii* is an uncommon isolate from normal ocular flora. Okumoto and associates¹² isolated *Proteus* species, including *M morganii* and *M mirabilis*, from 26 of 1000 (2.6%) normal preoperative human eyes, of which five (0.5%) were *M morganii*. In fact, *M morganii* is most typically enteric and, as such, is often associated with urinary tract infections. However, our patient denied urinary or constitutional symptoms suggesting either a urinary tract infection or bacteraemia.

Our patient ultimately developed a vitreous haemorrhage and was noted to have rubeosis 10 weeks after her initial presentation with endophthalmitis. Scattered intraretinal haemorrhages were seen after cataract surgery, and were attributed to accelerated, background diabetic retinopathy. In retrospect, however,

these haemorrhages would seem most consistent with a mild central retinal vein occlusion, possibly at the time of the initial endophthalmitis, leading 10 weeks later to neovascularisation of the retina and iris.

In summary, *M morganii* is an uncommon cause of postoperative endophthalmitis. Prompt recognition and treatment of postoperative endophthalmitis, whether due to *M morganii* or other more common organisms, can lead to good visual recovery, as observed initially in our patient.

EMMETT T CUNNINGHAM JR
The Francis I Proctor Foundation and
Department of Ophthalmology,
University of California,
San Francisco School of Medicine,
San Francisco, CA 94143, USA

JOHN P WHITCHER
The Francis I Proctor Foundation and
Department of Ophthalmology,
University of California,
San Francisco School of Medicine,
San Francisco, CA 94143, USA

ROBERT Y KIM
Department of Ophthalmology, University of California,
San Francisco School of Medicine,
San Francisco, CA 94143, USA

Correspondence to: Robert Y Kim, MD, Department of Ophthalmology, K-301, UCSF, School of Medicine, 10 Kirkham Street, San Francisco, CA 94143-0730, USA.

Accepted for publication 14 October 1996

- Mandelbaum S, Forster RK. Exogenous bacterial endophthalmitis. In: Holland G, Pepose J, Wilhelmus K, eds. *Ocular infection and immunity*. Philadelphia: Mosby Year Book, 1996; Chapter 93, 1298-320.
- Han DP, Wisniewski SR, Wilson LA, Barza M, Vine AK, Doft BH, et al. Spectrum and susceptibilities of microbiologic isolates in the Endophthalmitis Vitrectomy Study. *Am J Ophthalmol* 1996;122:1-17.
- Irvine WD, Flynn HW, Miller D, Pflugfelder SC. Endophthalmitis caused by gram-negative organisms. *Arch Ophthalmol* 1992;110:1450-4.
- Smolin G. Proteus endophthalmitis. *Arch Ophthalmol* 1974;91:419-20.
- Peyman GA, Vastine DW, Raichand M. (Symposium) Postoperative endophthalmitis: experimental aspects and their clinical application. *Ophthalmology* 1978;85:374-85.
- Puliafito CA, Baker AS, Haaf J, Foster CS. Infectious endophthalmitis: review of 36 cases. *Ophthalmology* 1982;89:921-9.
- Hogan MJ, Kimura SJ, Thygeson P. Signs and symptoms of uveitis. I Anterior uveitis. *Am J Ophthalmol* 1959;46:155-61.
- Pollack A, Dotan S, Oliver M. Course of diabetic retinopathy following cataract surgery. *Br J Ophthalmol* 1991;75:2-8.
- Straatsma BR. Cataract surgery in diabetic patients: progression of retinopathy after cataract surgery. In: Lewis H, Ryan SJ, eds. *Medical and surgical retina: advances, controversies, and management*. St Louis: CV Mosby, 1994; Chapter 24, 283-9.
- Mamalis N. Inflammation. In: Charlton JE, Weinstein GW, eds. *Ophthalmic surgery complications: prevention and management*. Philadelphia: JB Lippincott, 1995; Chapter 14, 313-37.
- Endophthalmitis Vitrectomy Study Group. Results of the Endophthalmitis Vitrectomy Study: a randomized trial of immediate vitrectomy and of intravenous antibiotics for the treatment of postoperative bacterial endophthalmitis. *Arch Ophthalmol* 1995;113:1479-96.
- Okumoto M, Smolin G, Belfort R Jr, Kim HB, Siverio CE. Proteus species isolated from human eyes. *Am J Ophthalmol* 1976;81:495-501.

Lateral rectus variant mimicking orbital pathology

EDITOR.—We present the case of a patient with unilateral lateral rectus muscle anomaly on computed tomography (CT) scan mimicking orbital pathology. A repeat scan 3 months later and a literature search confirmed this to be an anatomical variant of the involved muscle.

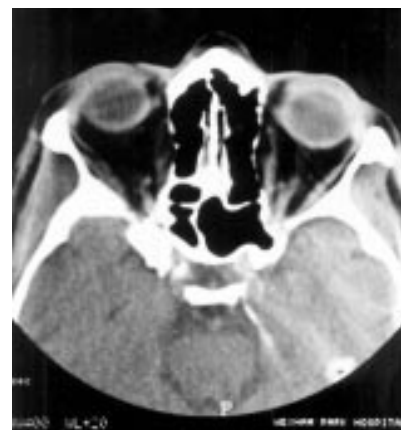

Figure 1 Linear opacity of soft tissue density arising from the right lateral rectus muscle and inserting onto the lateral orbital wall.

CASE REPORT

A 79-year-old man presented with a 4 day history of right side periorcular swelling, erythema, and mild diplopia on upgaze. A clinical diagnosis of preseptal cellulitis secondary to maxillary sinusitis was made. In view of his diplopia and a possible right proptosis he underwent a CT scan examination of his orbits. This confirmed the preseptal soft tissue swelling on the right with no orbital involvement of the inflammation. The scan also revealed a linear opacity of soft tissue density lateral to the right lateral rectus muscle, probably arising from the proximal part of its belly and inserting onto the lateral orbital wall, raising the suspicion of a neoplastic plaque. As the patient's cellulitis resolved on a 10 day course of oral antibiotics no further surgical intervention was considered at this stage. A repeat CT scan performed 3 months later showed no change in his previous orbital finding (Fig 1). A literature search confirmed this linear opacity to be an anatomical variant of the lateral rectus.

COMMENT

Anomalies of the extrinsic musculature of the human orbit are rare and their identification on postmortem dissections is difficult.¹ A number of modifications in orbital connective tissue and muscular attachments have been reported and have been shown to vary between individuals.² Bergman *et al*³ demonstrated muscular fasciculi passing from the lateral rectus and inserting into the lateral wall of the orbit while Koornneef⁴ described connective tissue attachments between the lateral rectus muscle and the lateral orbital wall. Other anomalous fibrous and muscular attachments of the lateral rectus muscle to the inferior tarsal plate, inferior rectus, medial rectus,³ and lateral canthus⁵ have also been reported. These anatomical variants are thought to influence eye movements and to have a stabilising role on lateral rectus action.

It is important to be aware of these rare orbital anomalies and recognise them on CT or magnetic resonance imaging scans. This would save the patient unnecessary further investigations.

A ASSI
Prince Charles Eye Unit, King Edward 7 Hospital,
Windsor SL4 3DP

S GHIACY
Department of Radiology, King Edward 7 Hospital,
Windsor SL4 3DP

Correspondence to: Mr A Assi, 6 The Mount, 76 Bedford Gardens, London W8 7EJ.

Accepted for publication 4 November 1996

- Whitnall SE. *The anatomy of the human orbit*. Oxford: Oxford University Press, 1932:284-5.
- Koornneef L. Eyelid and orbital fascial attachments and their clinical significance. *Eye* 1988; 2:130-4.
- Bergman RA, Thompson SA, Afifi AK, Saadeh FA. *Compendium of human anatomic variation*. Baltimore: Urban and Schwarzenberg, 1988: 33-4.
- Koornneef L. New insights in the human orbital connective tissue. Results of a new anatomical approach. *Arch Ophthalmol* 1977;95:1269-73.
- Lewis SJ, Tasker HN. Mechanism related to the lateral rectus muscle capable of retracting the outer canthus of the eye. *Br J Ophthalmol* 1994; 78:799-800.

Oculoglandular syndrome in Mediterranean spotted fever acquired through the eye

EDITOR.—We examined a 33-year-old woman with a week long history of a progressively inflamed left eye who showed oculoglandular conjunctivitis and a marginal corneal ulcer. Three days later she presented with fever and cutaneous maculopapular exanthema. The patient revealed that 2 weeks earlier a jet of blood had splashed into her left eye as she accidentally crushed a tick on her dog. Blood samples from the patient were positive to the Weil-Felix test; therefore, Mediterranean spotted fever was diagnosed. Systemic and topical treatment with tetracyclines was successful. The possibility that spotted fever may be acquired through the eye should be kept in mind.

CASE REPORT

A previously healthy 33-year-old woman was admitted with a week long history of a progressively painful and inflamed left eye. She had eyelid erythema and swelling, mucopurulent discharge, marked conjunctival hyperaemia, chemosis, and a granulomatous nodule on the lower half of the bulbar conjunctiva. At the 4 o'clock position there was a 1 mm corneal marginal ulcer. Visibly swollen preauricular and submandibular lymph nodes were present on the same side of the eye in question (Parinaud's oculoglandular syndrome). No other abnormality was detected in the anterior and posterior segments of the eye. Her visual acuity was 6/6.

Conjunctival swabs for bacterial, fungal, and chlamydial cultures collected before starting the treatment were all found to be negative.

Initial therapy consisted of eyedrops containing chloramphenicol (0.4%) and rolitetracycline (0.5%) every 2 hours and 2 g of piperacillin intramuscularly every 12 hours.

The day after her admission, the patient started having fever (38.5°C), headache, arthralgia, myalgia, and malaise; within 48 hours the corneal ulcer fully resolved, whereas chemosis and the granulomatous nodule were still present. Blood tests showed an increased erythrocyte sedimentation rate (33 mm after the first hour) and a lower number of white cells ($3.52 \times 10^9/l$). A computed tomographic scan of the head was normal.

By her third day in hospital, she developed a maculopapular exanthema on her trunk, limbs, and the soles of her feet. After careful questioning, the patient revealed that 2 weeks earlier, while removing ticks from her dog, she accidentally crushed a tick and a jet of blood splashed into her left eye. A blood sample taken on this day was positive to the Weil-Felix test (agglutination of *Proteus vulgaris* strain OX-19 at 1:80 dilution). On the

basis of these data, the diagnosis of Mediterranean spotted fever was made. As a result, piperacillin was discontinued and the patient was given oral doxycycline (100 mg daily). After 2 weeks of treatment, there was a complete resolution of the ocular and systemic disease. A second blood sample, taken during week 2 after the onset of the disease, showed a fourfold rise in OX-19 agglutinins, thus confirming the diagnosis.

COMMENT

Members of the genus *Rickettsia* are small Gram negative organisms often intimately associated with arthropod tissues.^{1,2} They may be parasitic in humans and other vertebrates, causing diseases transmitted by arthropods. Species in the genus *Rickettsia* have been subdivided into three groups of antigenically related organisms: spotted fever, typhus, and scrub typhus.

R. conorii, the most ubiquitous *Rickettsia* of the spotted fever group, is the aetiological agent of Mediterranean spotted fever (also called *fièvre boutonneuse*) in humans. The brown dog tick, *Rhipicephalus sanguineus*, is the prevalent vector and the disease is normally transmitted by the bite of the tick. In this report we describe a case of Mediterranean spotted fever acquired through the eye by means of a jet of blood coming from a crushed tick. The disease, which varies in severity but is seldom fatal, is considered endemic during the spring and summer in most of the regions bordering on the Mediterranean and Black seas, in Kenya and other parts of central Africa, South Africa, and certain parts of India. Over the past decade, outbreaks have been reported in Italy³ and Spain.⁴

When a patient presents with Parinaud's oculoglandular syndrome in areas where Mediterranean spotted fever is endemic, the possibility that the rickettsial disease may have been acquired through the eye should be kept in mind.

ANTONIO PINNA
MARIO SOTGIU
FRANCESCO CARTA

Institute of Ophthalmology, University of Sassari, Italy

STEFANIA ZANETTI
GIOVANNI FADDA

Institute of Microbiology and Virology, University of Sassari, Italy

Correspondence to: Dr Antonio Pinna, Istituto di Clinica Oculistica, Università degli Studi di Sassari, Viale San Pietro 43A, 07100 Sassari, Italy.

Accepted for publication 15 November 1996

1 Weiss E, Moulder JM. Genus I. *Rickettsia* da Rocha-Lima 1916, 567^{AL}. In: Kriek NR, Holt JG, eds. *Bergey's manual of systematic bacteriology*. Vol 1. Baltimore: Williams & Wilkins, 1984:688-98.

2 Olson JG, McDade JE. *Rickettsia* and *Coxiella*. In: Murray PR, Baron EJ, Pfaller MA, Tenover FC, Tenover RH, eds. *Manual of clinical microbiology*. 6th ed. Washington DC: American Society for Microbiology, 1995:678-85.

3 Scaffidi V. Attuale espansione endemico-epidemiologica della febbre bottonosa in Italia. *Minerva Med* 1981;72:2063-70.

4 Segura F, Font B. Resurgence of Mediterranean spotted fever in Spain. *Lancet* 1982;2:280.

Postoperative endophthalmitis due to *Pasteurella multocida*

EDITOR.—We present a rare case of endophthalmitis due to *Pasteurella multocida*, a bacterium commonly pathogenic to animals but

rare in humans. This is the first reported case of *P. multocida* endophthalmitis in which the infection occurred as an immediate postoperative complication following an uneventful cataract surgery.

CASE REPORT

A 93-year-old white woman underwent endocapsular cataract extraction with posterior chamber intraocular lens in the right eye under local anaesthesia in August 1995. On the second postoperative day she developed endophthalmitis.

Vitreous biopsy/intravitreal antibiotic injection could not be done as the patient immensely disliked the idea of any further surgical or anaesthetic procedures and refused to consent. After much persuasion, she agreed to an aqueous tap which was done by her bedside. A conjunctival swab was also taken. She was given subconjunctival cefuroxime 150 mg, intensive topical cefuroxime 5% and fortified gentamicin drops, and intravenous cefuroxime 750 mg 8 hourly.

Cultures of the conjunctival swab and the anterior chamber material showed *P. multocida* sensitive to chloramphenicol, penicillin, and cefuroxime. Despite antibiotic therapy, the eye became completely purulent within a few days (Fig 1). There was no sign of systemic infection clinically. The eye was eventually enucleated. A swab from the conjunctival sac of the opposite eye taken 20 days after the enucleation grew *P. multocida*.

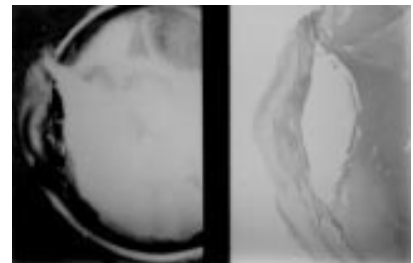

Figure 1 Macroscopic and microscopic (haematoxylin and eosin) appearance of the right eye (vertical section, nasal aspect) showing the gaping superior limbal surgical wound. Pus is present within the partially collapsed anterior chamber, in the posterior chamber, and around the lens implant, which has dissolved during processing for histology.

COMMENT

To our knowledge only three cases of *P. multocida* endophthalmitis have been reported in the literature so far, two of which were from cat scratch injuries.^{1,2}

Hoffman *et al*³ reported the third case in a 61-year-old man who developed the infection 8 years after phacoemulsification with implantation of an iris plane lens. There was no history of animal bite and the infection was considered to be endogenous. Pars plana vitrectomy was performed but the visual outcome was poor despite antibiotic therapy.

P. multocida is a Gram negative coccobacillus which usually causes infection in animals such as cats, dogs, and cattle and it is a frequent commensal in animals. It is not a usual human commensal but it has been found as part of bacterial flora in the upper respiratory tract of apparently healthy people who have been exposed to animals with no history of injuries such as bites or scratches.⁴ Human infection due to *P. multocida* occurs more frequently after exposure to cats than dogs and presents as focal cellulitis at the site

of injury caused by animals, chronic respiratory infections, intra-abdominal infections, or bacteraemia with or without metastatic lesions.⁴ Conjunctivitis⁵ and corneal ulcer following injury by a dog⁶ have also been reported.

Our patient has had a pet cat for 2 years and we believe that it is highly possible that the infection could have been acquired from the cat although there was no history of bites or scratches. Swabs from the nose and nasopharynx did not grow *P multocida* in our patient but it was cultured from the conjunctival sac of her other eye 20 days after the enucleation of the infected eye.

We thank to Dr L A Jewes for microbiology work and advice.

B BASKAR
S P DESAI

Department of Ophthalmology,
Doncaster Royal Infirmary

M A PARSONS

University of Sheffield Ophthalmic Sciences Unit, Royal
Hallamshire Hospital, Glossop Road, Sheffield

Correspondence to: S P Desai, Department of
Ophthalmology, Doncaster Royal Infirmary,
Armthorpe Road, Doncaster, South Yorkshire DN2
5LT.

Accepted for publication 25 November 1996

1 Weber DJ, Wolfson JS, Swartz MN, Hooper DC.
Pasteurella multocida infections: report of 34

cases and review of the literature. *Medicine (Baltimore)* 1984;**63**:133–54.

- 2 Galloway NR, Robinson GE. Panophthalmitis due to *Pasteurella septica*. *Br J Ophthalmol* 1973;**57**:153–5.
- 3 Hoffman ME, Sorr EM, Barza M. *Pasteurella multocida* endophthalmitis. *Br J Ophthalmol* 1987;**71**:609–10.
- 4 Boyce JM. *Pasteurella* species. In: Mandell GL, Douglas RG, Bennett JE, eds. *Principles and practice of infectious diseases*. New York: John Wiley, 1995:2068–70.
- 5 Hubbert WT, Rosen MN, II. *Pasteurella multocida* infection in man unrelated to animal bites. *Am J Publ Health* 1970;**60**:1109.
- 6 Purcell Jr JJ, Krachmer JH. Corneal ulcer caused by *Pasteurella multocida*. *Am J Ophthalmol* 1977;**83**:540.

CORRESPONDENCE

Descemet's membrane detachment

EDITOR.—The report on Descemet's membrane detachment by Mulhern and coauthors¹ requires comment.

In a report last year, we detailed three cases of Descemet's membrane (DM) detachment after intraocular surgery, one of which occurred after preparation of a phacoemulsification scleral pocket.² The detachment involved the visual axis, was recognised intraoperatively, and an attempt at primary repair was made. After a successful secondary repair, final visual acuity attained was 6/6. We suggested that efforts should be made at the time of primary surgery to repair a recognised large DM detachment, and that an expanding gas such as SF₆, with or without suture fixation, should be used.

The management of the case reported by Mulhern and coauthors involved primary excision of a large fragment of detached DM. This action takes no account of the possibility that the detachment may settle spontaneously postoperatively, nor of the varied techniques available for secondary repair which we summarised.²

None of the potential complications of DM repair mentioned by the authors precludes later penetrating keratoplasty if the outcome of the repair is sufficiently unsatisfactory, and it is difficult to imagine how a subsequent penetrating keratoplasty could be 'facilitated' by excising the membrane.¹ Similarly, it seems implausible to suggest that sutures transfixing the membrane would induce unacceptable astigmatism, when they would straddle no corneal incision, could be removed within months of the repair, and when the alternative, by excising DM and its attendant endothelium, is to irrevocably commit the patient to a procedure with a much higher potential to generate astigmatism, which has a visual rehabilitation in excess of 1 year and a lifetime follow up.

Our cases were repaired under general anaesthesia, but this is almost certainly not essential, and topical, sub-Tenon's, or regional block anaesthesia could be employed: if required, a series of relatively brief attempts to reattach the membrane could be undertaken before considering surgery as major as penetrating keratoplasty.

With the range of options available it is difficult to envisage any situation in which primary excision of a large fragment of detached Descemet's membrane can be justified.

MARK J WALLAND

Royal Victorian Eye and Ear Hospital,
East Melbourne 3002, Australia

1 Mulhern M, Barry P, Condon P. A case of Descemet's membrane detachment during phacoemulsification surgery (letter). *Br J Ophthalmol* 1996;80:185-6.

2 Walland MJ, Stevens JD, Steele ADMcG. Repair of Descemet's membrane detachment after intraocular surgery. *J Cataract Refract Surg* 1995;21:250-3.

Reply

EDITOR.—We welcome Walland's recent letter concerning our case of Descemet's membrane detachment during phacoemulsification surgery. In our article, we did allude to the various techniques which may help reappose

Descemet's membrane to the stroma; and to the fact that spontaneous reattachment of small planar detachments can occur. However, if our case report was read carefully, it can be seen that, given the tiny apical residual attachment of the involved fragment, and the fact that the detachment involved almost 40% of the corneal surface, reattachment was unlikely. Furthermore, if the decision is reached that the fragment cannot be reattached, this fragment should be excised as the extent of the detachment may increase further during trephining in a subsequent penetrating keratoplasty procedure, thus increasing the detachment and potentially extending it into the peripheral cornea.

M MULHERN
Mater Hospital, Dublin

Author's reply

EDITOR.—Thank you for the opportunity to offer further comments in relation to Mulhern's report and his letter of reply.

I would assure Mr Mulhern that his case report was read carefully: part of the difficulty with the report lies in the fact that the text makes no mention of a tear XY (Fig 1), while the illustration footnote makes no mention of a tear YZ. Either the membrane was torn along three sides and secured only at an apex point (Z), in which case it would be highly unlikely that the tear would extend peripherally upon trephination for penetrating keratoplasty (PK) (as suggested in his reply), but would rather complete its detachment at point Z; or the membrane was detached along two sides with the flap based along the third, in which case it would be ideally suited to a trial of either spontaneous reattachment or active intervention. In neither situation is excision of the DM fragment helpful, and excision commits the patient to a PK.

There have been several reports in the literature (some cited in our article, ref 2 in my original letter) of DM detachment in excess of the 40% area in Mulhern's case including subtotal, non-planar detachments, which have successfully resolved either spontaneously, or with active intervention, and these criteria therefore offer no justification for excision of a detached DM fragment.

MARK J WALLAND

NOTICES

XVI Congress of the Asia Pacific Academy of Ophthalmology

The XVI Congress of the Asia Pacific Academy of Ophthalmology will be held in Kathmandu, Nepal from 2-6 March 1997. Further details: The Secretariat, XVI Congress of APAO, Nepal Eye Hospital Building, Tripureswor, PO Box 335, Kathmandu, Nepal. (Fax: +977 1 227505/518.)

Conferences on Angiography in Créteil

A review of the literature on retinal and choroidal vascular pathology will take place on 10 March 1997 at the University of Créteil. Further details: Professor Gisèle Soubrane, Clinique Ophtalmologique Universitaire de Créteil, 40 Avenue de Verdun, 94010 Créteil Cédex, France. (Tel: 45 17 52 22.)

Glaucoma Meeting Basel '97

A teaching meeting on NO and endothelin in the pathogenesis of glaucoma will be held on 21-22 March 1997 at the Zentrum für Lehre und Forschung (ZLF), Kantonsspital Basel, Hebelstrasse 20, Basel, Switzerland. Further details: Daniela Stumpf, University Eye Clinic Basel, Mittlere Strasse 91, PO Box, CH-4012 Basel, Switzerland. (Tel: ++41-61-321 59 62 or ++44-61-321 77 77; fax: ++41-61-322 40 01.)

International Symposium on Ocular Tumors

The International Symposium on Ocular Tumors will be held on 6-10 April 1997 in Jerusalem, Israel. Further details: Professor J Pe'er, Tumors, PO Box 50006, Tel Aviv 61500, Israel. (Tel: 972 3 5140000; fax: 972 3 5175674 or 514007.)

2nd International and 4th European Congress on Ambulatory Surgery

The 2nd International and 4th European Congress on Ambulatory Surgery will be held at the Queen Elizabeth II Conference Centre, Westminster, London on 15-18 April 1997. Further details: Congress Secretariat, Kite Communications, The Silk Mill House, 196 Huddersfield Road, Meltham, West Yorkshire HD7 3AP. (Tel: +44 1484 854575; fax: +44 1484 854576.)

Second European Forum on Quality Improvement in Health Care

The Second European Forum on Quality Improvement in Health Care will take place on 24-26 April 1997 in Paris, France. The forum will consist of one day teaching courses, invited presentations, posters and presentations selected from submissions, and a scientific session. Further details: BMA, Conference Unit, PO Box 295, London WC1H 9TE. (Tel: +44 (0) 171 383 6478; fax: +44 (0) 171 383 6869.)

Association for Research in Vision and Ophthalmology (ARVO)

The Association for Research in Vision and Ophthalmology (ARVO) is holding its annual meeting on 11-16 May 1997 at the Fort Lauderdale Convention Center, Fort Lauderdale, Florida, USA. Further details: ARVO, 9650 Rockville Pike, Bethesda, MD 20814-3998. (Tel: (301) 571-1844; fax: (301) 571-8311.)

30th Panhellenic Ophthalmological Congress

The 30th Panhellenic Ophthalmological Congress organised by the Hellenic Ophthalmological Society will be held at the Astir Palace Hotel, Vouliagmeni on 28 May to 1 June 1997. Further details: T Kouris, CT Congress, Creta Travel, 19 Amerikis 106 72 Athens, Greece. (Tel: (01) 3607 120, 3635 104; fax: 3603392.)

Conferences on Angiography in Créteil

A conference on clinical cases in ICG will be held on 9 June 1997 at the University of Créteil. Further details: Professor Gisèle Soubrane, Clinique Ophtalmologique Universi-

taire de Créteil, 40 Avenue de Verdun, 94010 Créteil Cédex, France. (Tel: 45 17 52 22.)

British Council International Seminar

A British Council international seminar (number 97031) entitled 'Corneal and external eye disease: new surgical techniques' with Professor D L Easty as director will be held on 29 June to 5 July 1997 in Bristol, UK. The seminar will be of particular interest to all young eye surgeons from the developing and developed world. Further details: Promotions Manager, International Seminars, The British Council, 1 Beaumont Place, Oxford OX1 2PJ, UK (Tel: +44 (0) 1865 316636; fax: +44 (0) 1865 557368/516590; E-mail: International.Seminars@britcoun.org).

European Association for the Study of Diabetic Eye Complications (EASDEC)

The 7th meeting of EASDEC will be held on 18–19 July 1997 at the Okura Hotel, Amsterdam, the Netherlands, as a pre-congress symposium of the 16th International Diabetic Federation (IDF) congress. Further details: Professor BCP Polak, Rotterdam Eye Hospital, PO Box 70030, 3000 LM Rotterdam, the Netherlands. (Fax: (31) 10 4017655.)

Continuing Medical Education

The 17th annual current concepts in ophthalmology will be held on 25–27 July 1997 at the San Diego Marriott Mission Valley, San

Diego, California, USA. Further details: Marie Krygier, Medical Education Coordinator, San Diego Eye Bank, 9444 Balboa Avenue, Suite 100, San Diego, CA 92123, USA. (Fax: (619) 565-7368.)

5th International Symposium on Ocular Circulation and Neovascularisation

The 5th International Symposium on Ocular Circulation and Neovascularisation will be held on 15–19 September 1997 in Kyoto, Japan. Further details: Professor Dr Masanobu Uyama, Secretary General of the Organising Committee, Department of Ophthalmology, Kansai Medical University, Moriguchi, Osaka 570, Japan. (fax: 81-6-997-3475.)

2nd International Symposium on ARMD

The 2nd International Symposium on ARMD will be held at Glasgow University, Scotland under the auspices of the Royal College of Ophthalmologists on 16–18 September 1997. Further details: Dr G E Marshall, Eye Department, Western Infirmary, 38 Church Street, Glasgow G11 6NT, UK. (Tel: 0141 211 2094; fax: 0141 339 7485; email: gem1b@clinmed.gla.ac.uk)

XXVIIIth International Congress of Ophthalmology

The XXVIIIth International Congress of Ophthalmology will be held in Amsterdam on

21–26 June 1998. Further details: Eurocongres Conference Management, Jan van Goyenkade 11, 1075 HP Amsterdam, the Netherlands. (Tel: +31-20-6793411; fax: +31-20-6737306; internet <http://www.solution.nl/ico-98/>)

2nd International Conference on Ocular Infections

The 2nd International Conference on Ocular Infections will be held on 22–26 August 1998 in Munich, Germany. Further details: Professor J Frucht-Pery, Ocular Infections, PO Box 50006, Tel Aviv, 61500, Israel. (Tel: 972 3 5140000; fax: 972 3 5175674 or 5140077.)

Corrections

The December issue of the *BjO* unfortunately included two incorrect figures. This was caused by a computer error during the production of the issue. The first error appeared in the paper by Otto *et al* (1996;80:1042–5). Figure 2 on p 1043 was distorted; the correct version appears below. The second error occurred in the paper by Harper *et al* (1996;80:1068–72). The upper part of Figure 2C on p 1070 should read '28-year-old woman' not '20-year-old woman'. We apologise to the authors for these errors.

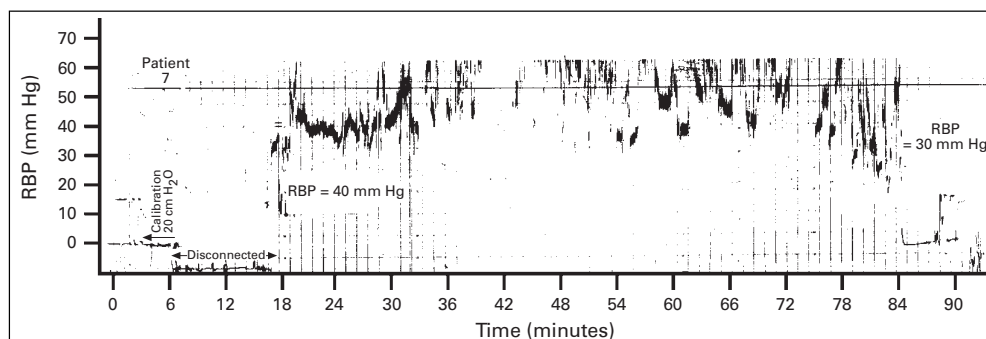


Figure 2 Retrolubar pressures (RBPs) recorded during surgical decompression in patient no 7 with Graves' ophthalmopathy. After connecting a sterile pressure transducer catheter an initial RBP of plus or minus 7 mm Hg was measured. Excessive peaks and roughness of the graphs is caused by spatula manipulation. Spatula force induced pressures of over 70 mm Hg. At the 78th minute of surgery incisions were made in the periorbit and the RBP decreased.