

Review

Olfactory transmission of neurotropic viruses

Isamu Mori,^{1,2,3} Yukihiro Nishiyama,² Takashi Yokochi,¹ and Yoshinobu Kimura³

¹Department of Microbiology and Immunology, Research Center for Infectious Disease, Aichi Medical University School of Medicine, Aichi, Japan; ²Laboratory of Virology, Research Institute for Disease Mechanism and Control, Nagoya University Graduate School of Medicine, Nagoya, Japan; ³Department of Microbiology, Fukui Medical University School of Medicine, Fukui, Japan

Olfactory receptor neurons are unique in their anatomical structure and function. Each neuron is directly exposed to the external environment at the site of its dendritic nerve terminals where it is exposed to macromolecules. These molecules can be incorporated into by olfactory receptor neurons and transported transsynaptically to the central nervous system. Certain neurotropic pathogens such as herpes simplex virus and Borna disease virus make use of this physiological mechanism to invade the brain. Here the authors review the olfactory transmission of infectious agents and the resulting hazards to human and animal health. *Journal of NeuroVirology* (2005) 11, 129–137.

Keywords: axon; dendrite; nervous system; olfactory receptor neuron; prion; virus

Introduction

To gain access to the central nervous system (CNS), neurotropic viruses exploit a variety of peripheral neural pathways. A neuron is a highly polarized cell with structurally and functionally distinct processes known as dendrites and axons, which can be separated by large distances. Cytoskeletal elements including microtubules also exhibit a polarized distribution in neurons. In axons, microtubules are oriented with their growing (+) ends toward the cell periphery, whereas in dendrites (+) ends are observed pointing in both directions. Kinesin and dynein serve as motor proteins for anterograde and retrograde transport, respectively, of macromolecules along microtubules in axons. Toxic substances and infectious agents can also be transported by the same mechanism. A battery of studies has established that herpes

simplex virus (HSV) can be transported along axons and that drugs that interfere with microtubule transport can block this process (Kristensson, 1996).

The olfactory system

The olfactory mucosa lines the posterodorsal nasal cavity in terrestrial animals (Schwob, 2002). This neuroepithelium consists of a limited number of cell types, which are arranged in a roughly laminar pattern (Figure 1), with sustentacular cells in the most apical location, followed by olfactory receptor neurons (ORNs) and then basal cells. The sustentacular cell is a non-neuronal supporting cell that expresses multiple cytochrome P450s and other biotransforming enzymes at levels higher than the liver, suggesting a role in detoxification. A mature ORN is bipolar in shape, with an apical dendrite that ends in a knob that elaborates into 12 or more cilia that splay out over the surface of the epithelium. The basal cell, a multipotent progenitor, gives rise to ORNs throughout the life of the animal. The axons of ORNs leave the epithelium, penetrate the cribriform plate, enter the olfactory bulb, and synapse in glomeruli with the dendrites of second-order neurons called mitral cells. Mitral cells, in turn, project to the olfactory system (e.g., olfactory and entorhinal cortices) and the limbic system (e.g., amygdala and hippocampus). Collectively, ORNs detect a large variety of odor molecules

Address correspondence to Isamu Mori, Department of Microbiology and Immunology, Research Center for Infectious Disease, Aichi Medical University School of Medicine, 23 Karimata, Yazako, Nagakute-cho, Aichi, Japan. E-mail: isamor@aichi-med-u.ac.jp

The authors thank Professor K. Asamoto for his helpful advice on neuroanatomy. This work was supported in part by JSPS KAKENHI (15590424). I. Mori is the recipient of an Encouragement of Young Scientist Award (2003) from the Nakanihon Infectious Diseases Research Foundation, Japan.

Received 13 July 2004; revised 25 August 2004; accepted 3 December 2004.

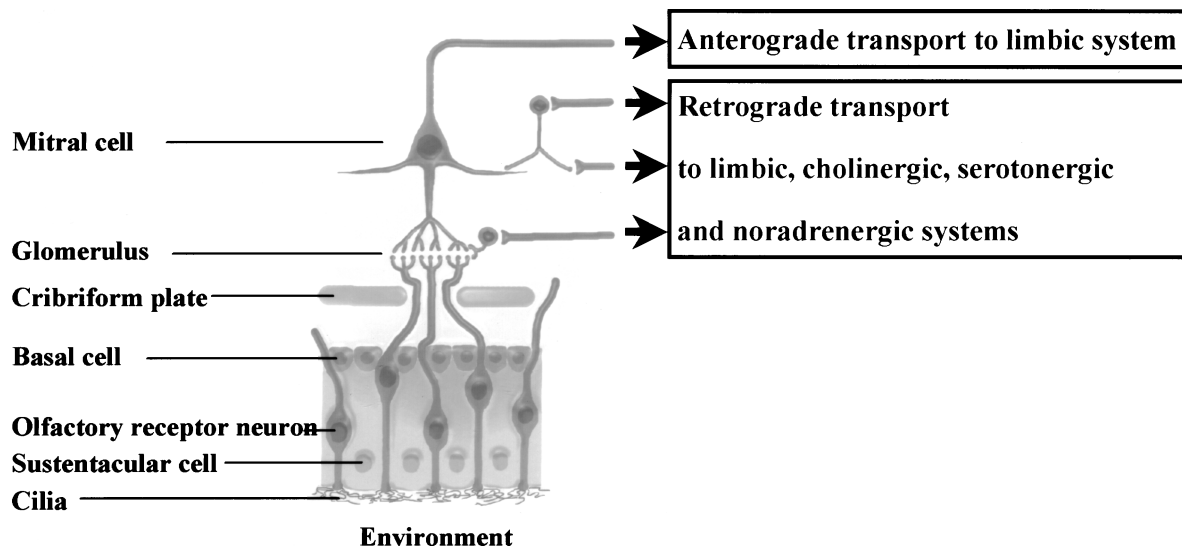


Figure 1 Olfactory receptor neurons, whose dendritic terminals are directly exposed to the external environment, provide neurotropic viruses with a pathway for invasion into the central nervous system. Viruses are transsynaptically transmitted in the anterograde direction to second-order neurons in the olfactory bulb called mitral cells and then further into regions of the limbic system, including the amygdala and hippocampus. Viruses in the olfactory bulb may also be transmitted to the limbic system, as well as to the cholinergic diagonal band, serotonergic dorsal raphe, and noradrenergic locus coeruleus in a retrograde manner.

and send information through their axons to the olfactory bulb (Mori *et al*, 1999). To cope with the diversity of odor molecules, the mammalian genome contains up to 1000 odorant receptors, which are expressed on the cilia membrane surface of ORNs. Axons of ORNs expressing the same odorant receptor converge to only a few defined glomeruli in the olfactory bulb.

The olfactory system exhibits several unique properties that are not typical of sensory systems. First, ORNs directly expose the receptor molecules to the external environment so that they are able to catch volatile chemical stimuli. Second, these neurons have the capacity for uptake and transsynaptic transport of exogenous substances to the CNS. Third, the olfactory system forms direct connections to the frontal cortex without thalamic relay, whereas other sensory pathways of the visual, auditory, and somatosensory modalities pass through the thalamus, which acts as a gateway to the cerebral cortex. Finally, like cells in other epithelia, but unlike other neurons, ORNs undergo apoptosis and neurogenesis with a half-life of about 90 days as part of a normal turnover process that continues throughout the adult life (Cowan and Roskams, 2002). The physiological processes of uptake and transsynaptic transport of molecules from the periphery to the olfactory bulb put the CNS at risk for neurological damage induced by environmental factors. For instance, neurofibrillary tangles observed in the brains of patients with Alzheimer's disease show a striking propensity for distribution throughout a specific set of structures in the limbic system, including the amygdala and hippocampus, leading to the belief that airborne environmental factors such as aluminum might be responsible (Perl and Good, 1991). In this article, the invasion

of infectious agents through this peripheral route is of primary concern. Accumulating evidence supports the notion that an olfactory transmission mechanism can explain the ability of certain infectious agents to enter the human brain.

Herpes simplex virus

HSV-1 and HSV-2 belong to the family *Herpesviridae*, subfamily *Alphaherpesvirinae*, genus *Simplexvirus*. Herpes simplex encephalitis (HSE) is associated with a high mortality rate and significant neuropsychological and neurobehavioral sequelae, which afflict patients for life even if they have been treated very early and have made a good recovery (Kennedy and Chaudhuri, 2002). HSE is usually caused by HSV-1. HSV-2 can also be responsible for HSE, especially in neonates and immunocompromised hosts. HSV-1 is transmitted through saliva and respiratory secretions. Usually, primary HSV-1 asymptotically infects the respiratory and oropharyngeal mucosa in children. Approximately 90% of adults are seropositive for HSV-1 and carry the viral genome in a latent form in peripheral ganglions (Kennedy and Chaudhuri, 2002). Reactivation, which may result in herpetic lesions in the skin and mucous membranes, takes place upon exposure to one of several types of stress, including ultraviolet (UV) exposure, menses, lactation, malnutrition, fatigue anxiety, and immunosuppression.

The view that HSV-1 can invade the CNS through the olfactory route stems from the site-specificity of HSE: the propensity of the virus to localize to the frontotemporal region of the brain (Kennedy and

Chaudhuri, 2002). The virus may also spread from the trigeminal ganglion to the temporal and frontal cortices, by traveling along the tentorial branches of the trigeminal ganglion to the meninges that cover the frontal and temporal lobes (Davis and Johnson, 1979); however, there has been no direct evidence to support this assumption (Love and Wiley, 2002). Furthermore, because neurons in the trigeminal ganglion principally project to sensory nuclei in the brainstem, the trigeminal pathway can only account for infrequent atypical cases of HSE with brainstem involvement (Rose *et al*, 1992; Hamilton *et al*, 1995; Tyler *et al*, 1995).

A number of lines of evidence favor the olfactory route of neuroinvasion in humans. Postmortem immunohistochemical mapping analysis of 29 HSE subjects demonstrated the presence of HSV-1 antigen in the olfactory tract and olfactory cortex, as well as the limbic system, but not in regions that relate to the potential trigeminal invasion pathway (Esiri, 1982). Further support for olfactory entry into the CNS has been inferred from the presence of HSV-related histopathological alterations in the olfactory neuroepithelium, olfactory nerve, and olfactory bulb (Twomey *et al*, 1979; Dinn, 1980; Ojeda *et al*, 1983), but not in the trigeminal ganglion (Ojeda *et al*, 1983).

The virus may establish a latent infection in the olfactory bulb and a particular set of limbic structures. The polymerase chain reaction (PCR) detected HSV-1 DNA in 15.5% of the olfactory bulbs collected from 109 individuals during forensic postmortem analyses (Liedtke *et al*, 1993). The PCR also disclosed the presence of the HSV genome in 17.5% of the olfactory bulbs, 5.0% of the amygdalae, and 2.5% of the hippocampi collected from 40 patients dying of non-neurological causes, providing evidence in support of the olfactory neuroinvasion presumably in the course of a neurologically silent infection (Baringer and Pisani, 1994). Importantly, these testimonies indicate that HSV reactivation may originate in the olfactory bulb as well as in limbic structures. It is conceivable that HSE in children springs up in the course of primary HSV infection, whereas in adults HSE arises from the reactivation of the virus in olfactory and/or limbic structures. It should be noted that HSV infection of the CNS through the olfactory pathway, even if it takes place silently, may bring about learning and behavioral deficiencies in children and adults (Becker, 1995).

These observations are well reproduced in animal experiments using strains of HSV-1. Following intranasal inoculation of Lewis rats with HSV-1 strain +GC, animals contract acute encephalitis that involves regions of the olfactory and limbic systems, including the olfactory bulb, amygdala, hippocampus, and olfactory and entorhinal cortices (Beers *et al*, 1993), causing deficits in spatial recognition memory (Beers *et al*, 1995). Swiss CD-1 mice intranasally infected with HSV-1 strain SC16 develop an asymptomatic and transitory CNS infection where

the olfactory bulb, amygdala, hippocampus, and olfactory, cingulate, frontal, temporal, and entorhinal cortices are attacked by the virus (Boggian *et al*, 2000). Interestingly, in the course of this infection the virus also establishes a latent infection in the olfactory bulb and neuroepithelium, creating a hypothetical source of reactivated virus. HSV-1 latency in the murine olfactory bulb has also been corroborated by other investigations (Drummond *et al*, 1994).

The routes of infection of other herpesviruses of veterinary interest have also been studied. Equine herpesvirus 1 establishes a latent infection in mitral cells in the murine olfactory bulb following intranasal challenge (Marshall and Field, 1997). Intriguingly, bovine herpesvirus 5 travels down, via retrograde transport, to the dorsal raphe and locus coeruleus in addition to brain structures in the olfactory and limbic systems (Chowdhury *et al*, 2000a, 2000b). Equine herpesvirus 9, the newest member of equine herpesvirus family, has also been evidenced to travel along olfactory processes to the CNS following intranasal inoculation in horses, pigs, cats, and dogs, attacking the olfactory and limbic systems (Taniguchi *et al*, 2000; Narita *et al*, 2001; Yanai *et al*, 2003a, 2003b).

Specific viral proteins are thought to control neuroinvasiveness, neurovirulence, and targeting. A Us9-deletion mutant of bovine herpesvirus 5 replicates in ORNs as efficiently as the Us9-rescued virus but is not transported to the olfactory bulb, indicating a critical role for Us9 in the anterograde spread of the virus from the periphery to the CNS (Chowdhury *et al*, 2002; Al-Mubarak *et al*, 2004). This is consistent with the results of another study that proves that the Us9 protein is responsible for the translocation of nascent viral membrane glycoproteins into the axon (Tomishima and Enquist, 2001). In this paradigm, viral membrane glycoproteins and other viral components are transported into the axon by separate mechanisms. The bovine herpesvirus-5 glycoprotein E (gE) has been shown to play a role in CNS infection along the olfactory projection pathways in the rabbit; interestingly, gE from nonneurovirulent bovine herpesvirus 1 is not able to replace herpesvirus-5 gE in this experiment (Chowdhury *et al*, 2000a). Glycoprotein C-deleted bovine herpesvirus 5 can invade the caudate nucleus, substantia nigra, and ventral tegmentum, although these are not attacked by the wild-type virus (Chowdhury *et al*, 2000b). Pseudorabies virus is a highly neurotropic alphaherpesvirus that precipitates Aujeszky's disease in domestic and wild animals. gE-negative pseudorabies virus replicates less efficiently in olfactory receptor neurons and has a reduced capacity to transmit to second-order (mitral/tufted cells) and third-order (granule cells) neurons in the olfactory pathway in porcine CNS (Mulder *et al*, 1994). Finally, it should be noted that the olfactory neuron-specific transcription factor (Olf-1) activates the infected cell protein 0 (ICP0)

promoter (Devireddy and Jones, 2000), which facilitates productive infection and reactivation from latency in the olfactory system. Specific humoral immunity raised against the herpesvirus appears operative in halting transneuronal transmission of the virus in the CNS. In 1-week-old pigs with maternally derived neutralizing antibody, the Ka strain of suid herpesvirus 1 remains in the olfactory neuroepithelium and bulb following intranasal challenge, whereas in control piglets, the virus invades deep into the olfactory cortex (Kritas *et al*, 1999).

Borna disease virus

Borna disease virus (BDV) belongs to the order *Mononegavirales*, family *Bornaviridae*, genus *Bornavirus*. Borna disease results from the persistent infection of BDV in the CNS. Natural Borna disease has been recognized as a fatal behavioral and movement disorder of horses and sheep in endemic areas of Central Europe for more than a century. In 1885, a large outbreak of the disease took place among horses and sheep in the town of Borna, Saxony, Germany, which precipitated awareness of the disease. Recent studies suggest a broader host range and geographic distribution of BDV infection (Hornig *et al*, 2003).

The disease is immune mediated: the infection of newborn rats results in lifelong viral persistence without precipitating disease, which can be explained by a thymic clonal deletion of BDV-specific T cells. The virus causes noncytolytic infection, displays a highly neurotropic nature, and has the ability to spread into axons and cross synapses. Injection of the virus intravenously or into the feet of neurectomized animals does not result in infection, demonstrating a strict dependence on the neural conduit for virus transmission (Carbone *et al*, 1987).

Reservoirs and the transmission routes have yet to be elucidated (Hornig *et al*, 2003). Transmission of BDV from infected horses or sheep to naïve animals is unlikely to take place. Rodents are recognized as a candidate for the maintenance of a BDV reservoir; the virus establishes persistent infection in neonatal rats following intranasal infection and is secreted in saliva, urine, and feces for life. BDV has also been detected in bird excrement, indicating the plausible existence of an avian reservoir (Berg *et al*, 2001).

The olfactory route of transmission has been proposed on the basis of the inflammatory response in the olfactory bulb of naturally infected horses. It has been shown that effective BDV transmission through the olfactory route takes place upon cohabitation of persistently infected rats with naïve rats, which are probably infected by virus due to its abundant presence in the fresh urine of the carrier rats (Sauder and Staeheli, 2003). The spread of BDV through olfactory

neurons to the limbic system has been demonstrated in rats (Carbone *et al*, 1987; Morales *et al*, 1988).

The clinical manifestations of infected adult rats closely parallel the changes in CNS pathology (Hornig *et al*, 2003). In the acute phase, animals show exaggerated startle responses and hyperactivity, reflecting the inflammation in limbic structures. In the chronic phase, animals display highly stereotyped motor behaviors (scratching, self-biting, and so on), dyskinesias, and dystonias, which can be explained by the dysfunction of dopamine circuits, as is observed in many neuropsychiatric disorders.

Accumulating serology-based and molecular epidemiology-based evidence has suggested that, though the issue remains controversial, infection with BDV may be associated with neuropsychiatric disorders in humans, including schizophrenia, affective disorders, and other neuropsychiatric disorders with dopamine or serotonin substrates. The hippocampi of patients with clinical histories of mental disorders involving memory loss and depression in conjunction with pathological evidence of hippocampal sclerosis have been shown to harbor BDV p40 RNA (de la Torre *et al*, 1996). Haga *et al* examined 30 normal brains for the presence of the BDV p24 genome and two brains were found to harbor the virus (Haga *et al*, 1997). In one brain, BDV DNA was found in the olfactory bulb, implying that the virus can also invade the human olfactory system without causing neurological or neuropsychiatric symptoms.

Rabies virus and other lyssaviruses

The lyssaviruses belong to the order *Mononegavirales*, family *Rabdoviridae*, genus *Lyssavirus*. *A priori*, all mammals are susceptible to rabies infection (Gibbons, 2002), but reservoirs important for the maintenance and transmission of lyssaviruses are limited to bats. Classical rabies virus (serogenotype 1) is distributed worldwide, except in Scandinavian countries and island countries such as the United Kingdom, Australia, New Zealand, and Japan (McCull *et al*, 2000). Viruses such as the Lagos bat virus (serogenotype 2), the Mokola virus (serogenotype 3), and the Duvenhage virus (serogenotype 4) have only been isolated in Africa, whereas the European bat lyssavirus 1 (genotype 5) and the European bat lyssavirus 2 (genotype 6) have only been found in Europe. The Australian bat lyssavirus (genotype 7) is currently known to exist in Australia. All except serogenotype 2 have been associated with human deaths.

Infection with rabies virus leads to a rapidly progressive and lethal encephalomyelitis. Rabies virus transmission almost always takes place following the introduction of virus into host tissue through a bite from an infected animal. The virus may directly enter the peripheral nerve or may replicate first in

non-neural tissue and then invade the peripheral nerve. The virus is transported by the axoplasmic flow in peripheral nerves to the CNS (Jackson, 2003), where it multiplies, precipitates disease, and then travels down to the salivary glands in order to maintain the transmission cycle.

It is estimated that the rabies virus kills at least 60,000 humans annually (Haupt, 1999), with the vast majority of these deaths associated with canine rabies in developing countries (urban rabies). Rabies is also observed in wild animals (sylvatic rabies), particularly in developed countries where canine rabies is under control. Of note, most human rabies caused by bat lyssaviruses is considered “cryptogenic,” the transmission route is not identified. In these cases, unrecognized bat bites are the most plausible hypothesis (Gibbons, 2002), but aerosol transmission from wildlife may explain a fraction of cases with cryptogenic rabies.

In an experimental setting, the rabies virus can infect ORNs and transneuronally invade the CNS (Lafay *et al*, 1991; Astic *et al*, 1993). Neural cell adhesion molecule, which is abundantly expressed on ORNs, has been shown to be a receptor for rabies virus (Thoulouze *et al*, 1998).

Airborne human rabies encephalitis has been documented (Winkler *et al*, 1973; Conomy *et al*, 1977). A veterinarian developed rabies in the course of laboratory work with homogenates of the rabid goat brain. Strikingly, electron microscopic examination of the olfactory bulb demonstrated that viral particles were abundant within the axoplasm of nerve fibers, strongly suggesting neuroinvasion through the olfactory route.

Influenza A virus

The influenza A virus belongs to the family *Orthomyxoviridae*, genus *Influenzavirus A*. The virus carries eight segmented genes of negative-strand RNA. This characteristic feature enables genetic reassortment between viruses with different genotypes, which can then give rise to new pandemic viruses in the human population. Influenza A virus is a major cause of respiratory diseases in a wide range of susceptible species including humans, horses, swine, whales, and birds. Infection with influenza A virus in humans has been associated with a number of neurological complications ranging from acute encephalitis/encephalopathy to progressive neurodegenerative and neuropsychiatric disorders.

Experts on influenza accept the view that another influenza pandemic is inevitable and imminent (Webby and Webster, 2003). Not only the H1, H2, and H3 subtypes are of concern, but also the H5 and H7 subtypes of avian origin have recently exhibited their potential human pandemic virus. The H5 and H7 viruses have a unique ability to evolve into a highly virulent form targeted to avians by ac-

quiring additional basic amino acids at the hemagglutinin (HA) cleavage site (Mori *et al*, 2002b). Such an HA peptide can easily be cleaved in the Golgi apparatus by ubiquitous intracellular proteases, such as subtilisin-like proteases, including furin and PC6. The A/Qu/HK/G1/97 virus of the H9N2 subtype contains six gene segments, PB2, PB1, PA, NP, M, and NS, which constitute a viral replicative complex, and is a close genetic relative of the HK/156/97 virus (Guan *et al*, 2000). It is of note that both of these viruses are highly neurovirulent for mice.

Experimentally, it has been shown that a recombinant influenza A virus of the 90/Ho1 strain, which has the RNA segment 2 derived from A/Hong Kong/1/68 (H3N2) and the other segments from A/fowl plague/Rostock/34 (H7N1), can enter the brain of neonatal mice through the olfactory as well as the trigeminal route following an intranasal challenge, even in the presence of neutralizing antibody in their serum (Reinacher *et al*, 1983). During the 1997 Hong Kong incident, the Avian H5N1 viruses HK156 and HK483 were respectively isolated from the throat aspirates of a 3-year-old boy who was the index case and who subsequently developed Reye's syndrome and a 13-year-old girl who was the third case. Both strains are known to take the olfactory route for neuroinvasion, although other pathways through the trigeminal, vagal, and sympathetic systems are also possible (Park *et al*, 2002; Tanaka *et al*, 2003). Viremia does not contribute to the dissemination of virus to the CNS.

The behavior of the influenza A virus in the nervous system varies significantly dependent on the strain. The WSN strain of influenza A virus (H1N1) and the R404BP virus (a recombinant virus that possesses the neuraminidase and matrix genes from the WSN strain and the rest from the non-neurovirulent A/Aichi/2/68 strain [H3N2]) induce apoptosis in ORNs upon intranasal infection (Mori *et al*, 2002a, 2004). Viral components including nucleic acids and proteins are not detectable in the olfactory bulb; they are enclosed in apoptotic bodies and cleared by phagocytes in the olfactory neuroepithelium. These observations introduce the novel concept that virus-induced neuronal apoptosis in the peripheral nervous system is a protective host response that hinders virus transmission into the CNS. This phenomenon, however, may be age dependent, because the WSN virus infects ORNs following intranasal introduction and invades the CNS in 7-day-old mice, without inducing apoptosis (Aronsson *et al*, 2003).

Influenza encephalitis/encephalopathy is a serious CNS complication in children, the pathogenesis of which still remains an enigma (Studahl, 2003). A hypothesis has been proposed that influenza virus replicates in the nasal neuroepithelium and transmits through the olfactory pathway to the CNS, which leads to glial activation and cytokine (e.g., tumor necrosis factor) production (Yokota *et al*, 2000). The resulting cytokine storm in the CNS causes brain

edema and neural tissue damage. The subsequent disruption of the blood-brain barrier brings about a systemic cytokine storm, which then induces disseminated intravascular coagulopathy and multiple organ failure.

Parainfluenza viruses

Parainfluenza viruses belong to the order *Mononegavirales*, family *Paramyxoviridae*, subfamily *Paramyxovirinae*, genus *Respirovirus* (types 1 and 3) and *Rubulavirus* (types 2 and 4). Parainfluenza viruses almost exclusively cause respiratory diseases and are a major cause of morbidity in infancy. However, they have rarely been associated with CNS complications such as meningoencephalitis (Slavin *et al*, 2000). Experimentally, parainfluenza viruses infect ORNs of mice upon intranasal inoculation but do not spread to the second-order neurons because of the lack of trypsin-like proteases in nerve tissue (Kristensson *et al*, 1984; Mori *et al*, 1995, 1996, 2004). The virus infection persists in the olfactory bulb for a prolonged period. Importantly, the temperature-sensitive parainfluenza vaccine virus can infect ORNs and gain access to the CNS, pointing to a potential risk for the use of live attenuated virus as an intranasal vaccine (Mori *et al*, 1996).

Prions

Transmissible spongiform encephalopathies (TSE) or prion diseases form a biologically distinct group of fatal neurodegenerative infectious diseases (Prusiner, 2001; Collins *et al*, 2004). TSEs includes scrapie in sheep and goats, bovine spongiform encephalopathy in cattle, chronic wasting disease in mule deer and elk, and kuru, Creutzfeldt-Jakob disease (CJD), and its variant form (vCJD) in humans.

Cellular prion protein (PrP^c) is encoded by the PrP gene (*PRNP*), a small housekeeping gene on chromosome 20. It is expressed abundantly in the olfactory bulb, cerebral cortex, hippocampus, and striatum (Salès *et al*, 1998). PrP^c is a sialoglycoprotein, which is associated with cell membrane through a C-terminal glycosylphosphatidylinositol (GPI)-anchor.

The pathogenesis of TSE involves the accumulation of a structurally aberrant, protease-resistant protein conformation (PrP^{res}) in the nervous system. It has generally been accepted that, after being taken up orally, prions invade the sympathetic and/or parasympathetic neurons in order to access the CNS, although not much is known about this issue (Aguzzi, 2001). Once in the brain, PrP^{res} appears to serve as a template for the conversion of PrP^c to PrP^{res} through cyclic autocatalytic amplification.

In the United Kingdom, there have been several reports describing dairy farmers who may have

contracted CJD from their bovine spongiform encephalopathy (BSE)-affected livestock (Sawcer *et al*, 1993; Davies *et al*, 1993; Smith *et al*, 1995; Delasnerie-Laupretre *et al*, 1995). Shaw mentions the possibility that farmers are exposed to dust from the feed contaminated with PrP^{BSE}, which may invade the CNS through the olfactory pathway (Shaw, 1995). Recently, the analysis of nine autopsy brains of patients with CJD has shown that PrP^{res} is detected selectively in the olfactory neuroepithelium, olfactory bulb glomeruli, olfactory tract, and olfactory, entorhinal, and temporal cortices (Zanusso *et al*, 2003), but not in the optic nerve and the respiratory mucosa. PrP^c is evenly distributed in both the olfactory and respiratory mucosa. One study has shown that PrP^{res} can also be detected in biopsy specimens from the olfactory mucosa of a patient with CJD 45 days after the disease onset (Tabaton, 2004). Specifically, the olfactory cilia and basal cells of the olfactory mucosa were immunopositive for PrP. Another case report documents that a patient with vCJD presented with the initial symptoms of loss of smell and taste, and an olfactory tract that appeared heavily infected with prions (Reuber *et al*, 2001). Taken together, these reports provide important insight into the pathogenesis of CJD. First, the involvement of the olfactory neuroepithelium is an early event in CJD as well as vCJD. Second, the olfactory biopsy may provide excellent diagnostic information in living patients. Third, the olfactory neuroepithelium may represent a point of entry into the CNS for this infectious agent (Zanusso *et al*, 2003). In this respect, it is interesting that abundant amounts of PrP^c are present in olfactory nerve fibers of normal animals, providing a potential source of pathogenic prions (Salès *et al*, 1998).

Concluding remarks

We have presented several neurotropic pathogens that can invade the CNS by way of the olfactory pathway and the currently understood mechanisms of neuroinvasion. HSV is representative of such neurotropic pathogens in humans and displays the characteristic features of latency and reactivation in the nervous system, which are implicated in the pathogenesis of HSE. Borna disease virus, lyssavirus, and avian influenza virus have all primarily attracted attention in veterinary medicine; however, these infectious agents, together with other neurotropic viruses that may emerge in the future, are a potential and substantial threat to human health. To develop operative therapy and preventive measures directed to such neurotropic microorganisms, we need to further our understanding of the mechanisms of neuroinvasion, replication, and axonal transport of these pathogens in both the CNS and the peripheral nervous system.

References

- Aguzzi A (2001). Peripheral prion pursuit. *J Clin Invest* **108**: 661–662.
- Al-Mubarak A, Zhou Y, Chowdhury SI (2004). A glycine-rich bovine herpesvirus 5 (BHV-5) gE-specific epitope within the ectodomain is important for BHV-5 neurovirulence. *J Virol* **78**: 4806–4816.
- Aronsson F, Robertson B, Ljunggren H-G, Kristensson K (2003). Invasion and persistence of the neuroadapted influenza virus A/WSN/33 in the mouse olfactory system. *Viral Immunol* **16**: 415–423.
- Astic L, Saucier D, Coulon P, Lafay F, Flamand A (1993). The CVS strain of rabies virus as transneuronal tracer in the olfactory system of mice. *Brain Res* **619**: 146–156.
- Baringer JR, Pisani P (1994). Herpes simplex virus genomes in human nervous system tissue analyzed by polymerase chain reaction. *Ann Neurol* **36**: 823–829.
- Becker Y (1995). HSV-1 brain infection by the olfactory nerve route and virus latency and reactivation may cause learning and behavioral deficiencies and violence in children and adults: a point of view. *Virus Genes* **10**: 217–226.
- Beers DR, Henkel JS, Kesner RP, Stroop WG (1995). Spatial recognition memory deficits without notable CNS pathology in rats following herpes simplex encephalitis. *J Neurol Sci* **131**: 119–127.
- Beers DR, Henkel JS, Schaefer DC, Rose JW, Stroop WG (1993). Neuropathology of herpes simplex virus encephalitis in a rat seizure model. *J Neuropathol Exp Neurol* **52**: 241–252.
- Berg M, Johansson M, Montell H, Berg A-L (2001). Wild birds as a possible natural reservoir of Borna disease virus. *Epidemiol Infect* **127**: 173–178.
- Boggian I, Buzzacaro E, Calistri A, Calvi P, Cavagioni A, Mucignat-Caretta C, Palu G (2000). Asymptomatic herpes simplex type 1 virus infection of the mouse brain. *J NeuroVirol* **6**: 303–313.
- Carbone KM, Duchala CS, Griffin JW, Kincaid AL, Narayan O (1987). Pathogenesis of Borna disease in rats: evidence that intra-axonal spread is the major route for virus dissemination and the determinant for disease incubation. *J Virol* **61**: 3431–3440.
- Chowdhury SI, Lee BJ, Ozkul A, Weiss ML (2000a). Bovine herpesvirus 5 glycoprotein E is important for neuroinvasiveness and neurovirulence in the olfactory pathway of the rabbit. *J Virol* **74**: 2094–2106.
- Chowdhury SI, Lee BJ, Onderci M, Weiss ML, Mosier D (2000b). Neurovirulence of glycoprotein C (gC)-deleted bovine herpesvirus type-5 (BHV-5) and BHV-5 expressing BHV-1 gC in a rabbit seizure model. *J NeuroVirol* **6**: 284–295.
- Chowdhury SI, Onderci M, Bhattacharjee PS, Al-Mubarak A, Weiss ML, Zhou Y (2002). Bovine herpesvirus 5 (BHV-5) Us9 is essential for BHV-5 neuropathogenesis. *J Virol* **76**: 3839–3851.
- Collins SJ, Lawson VA, Masters CL (2004). Transmissible spongiform encephalopathies. *Lancet* **363**: 51–61.
- Conomy JP, Leibovitz A, McCombs W, Stinson J (1977). Airborne rabies encephalitis: demonstration of rabies virus in the human central nervous system. *Neurology* **27**: 67–69.
- Cowan CM, Roskams AJ (2002). Apoptosis in the mature and developing olfactory neuroepithelium. *Microsc Res Tech* **58**: 204–215.
- Davies PTG, Jahfar S, Ferguson IT, Windl O (1993). Creutzfeldt-Jacob disease in individual occupationally exposed to BSE. *Lancet* **342**: 680.
- Davis LE, Johnson RT (1979). An explanation for the localization of herpes simplex encephalitis? *Ann Neurol* **5**: 2–5.
- de la Torre JC, Gonzalez-Dunia D, Cubitt B, Mallory M, Mueller-Lantzsch N, Grässer FA, Hansen LA, Masliah E (1996). Detection of Borna disease virus antigen and RNA in human autopsy brain samples from neuropsychiatric patients. *Virology* **223**: 272–282.
- Delasnerie-Lauprete N, Poser S, Pocchiari M, Wientjens DPWM, Will R (1995). Creutzfeldt-Jakob disease in Europe. *Lancet* **346**: 898.
- Devireddy LR, Jones CJ (2000). Olf-1, a neuron-specific transcription factor, can activate the herpes simplex virus type 1-infected cell protein 0 promoter. *J Biol Chem* **275**: 77–81.
- Dinn JJ (1980). Transolfactory spread of virus in herpes simplex encephalitis. *Br Med J* **281**: 1392.
- Drummond CWE, Eglin RP, Esiri MM (1994). Herpes simplex virus encephalitis in a mouse model: PCR evidence for CNS latency following acute infection. *J Neurol Sci* **127**: 159–163.
- Esiri MM (1982). Herpes simplex encephalitis. An immunohistological study of the distribution of viral antigen within the brain. *J Neurol Sci* **54**: 209–226.
- Gibbons RV (2002). Cryptogenic rabies, bats, and the question of aerosol transmission. *Ann Emerg Med* **39**: 528–536.
- Guan Y, Shortridge KF, Krauss S, Chin PS, Dyrting KC, Ellis TM, Webster RG, Peiris M (2000). H9N2 influenza viruses possessing H5N1-like internal genomes continue to circulate in poultry in Southeastern China. *J Virol* **74**: 9372–9380.
- Haga S, Yoshimura M, Motoi Y, Arima K, Aizawa T, Ikuta K, Tashiro M, Ikeda K (1997). Detection of Borna disease virus genome in normal human brain tissue. *Brain Res* **770**: 307–309.
- Hamilton RL, Achim C, Grafe MR, Fremont JC, Miners D, Wiley CA (1995). Herpes simplex virus brainstem encephalitis in an AIDS patient. *Clin Neuropathol* **14**: 45–50.
- Haupt W (1999). Rabies—risk of exposure and current trends in prevention of human cases. *Vaccine* **17**: 1742–1749.
- Hornig M, Briese T, Lipkin WI (2003). Borna disease virus. *J NeuroVirol* **9**: 259–273.
- Jackson AC (2003). Rabies virus infection: an update. *J NeuroVirol* **9**: 253–258.
- Kennedy PGE, Chaudhuri A (2002). Herpes simplex encephalitis. *J Neurol Neurosurg Psychiatry* **73**: 237–238.
- Kritas SK, Pensaert MB, Nauwynck HJ, Kyriakis SC (1999). Neural invasion of two virulent suid herpesvirus 1 strains in neonatal pigs with or without maternal immunity. *Vet Microbiol* **69**: 143–156.
- Kristensson K (1996). Sorting signals and targeting of infectious agents through axons: an annotation to the 100 years' birth of the name "axon." *Brain Res Bull* **41**: 327–333.
- Kristensson K, Leestma J, Lundh B, Norrby E (1984). Sendai virus infection in the mouse brain: virus spread and long-term effects. *Acta Neuropathol* **63**: 89–95.

- Lafay F, Coulon P, Astic L, Saucier D, Riche D, Holley A, Flamand A (1991). Spread of the CVS strain of rabies virus and of the avirulent mutant AvO1 along the olfactory pathways of the mouse after intranasal inoculation. *Virology* **183**: 320–330.
- Liedtke W, Opalka B, Zimmermann CW, Lignitz E (1993). Age distribution of latent herpes simplex virus 1 and varicella-zoster virus genome in human nervous tissue. *J Neurol Sci* **116**: 6–11.
- Love S, Wiley CA (2002). Viral diseases. In *Greenfield's neuropathology*, 7th ed, Vol II. Graham DI, Lantos PL (eds). London: Arnold, pp 1–105.
- Marshall KR, Field HJ (1997). Demonstration of equine herpesvirus-1 neuronal latency in murine olfactory bulbs using a novel combined *in situ* PCR and protein synthesis method. *Virology* **229**: 279–282.
- McCull KA, Tordo N, Aguilar Setién A (2000). Bat lyssavirus infections. *Rev Sci Tech Off Int Epiz* **19**: 177–196.
- Morales JA, Herzog S, Kompter C, Frese K, Rott R (1988). Axonal transport of Borna disease virus along olfactory pathways in spontaneously and experimentally infected rats. *Med Microbiol Immunol* **177**: 51–68.
- Mori I, Goshima F, Imai Y, Kohsaka S, Sugiyama T, Yoshida T, Yokochi T, Nishiyama Y, Kimura Y (2002a). Olfactory receptor neurons prevent dissemination of neurovirulent influenza A virus into the brain by undergoing virus-induced apoptosis. *J Gen Virol* **83**: 2109–2116.
- Mori I, Komatsu T, Takeuchi K, Nakakuki K, Sudo M, Kimura Y (1995). Parainfluenza virus type 1 infects olfactory neurons and establishes long-term persistence in the nerve tissue. *J Gen Virol* **76**: 1251–1254.
- Mori I, Nakakuki K, Kimura Y (1996). Temperature-sensitive parainfluenza type 1 vaccine virus directly accesses the central nervous system by infecting olfactory neurons. *J Gen Virol* **77**: 2121–2124.
- Mori I, Nishiyama Y, Yokochi T, Kimura Y (2004). Virus-induced neuronal apoptosis as pathological and protective responses of the host. *Rev Med Virol* **14**: 209–216.
- Mori I, Yokochi T, Kimura Y (2002b). Role of influenza A virus hemagglutinin in neurovirulence for mammals. *Med Microbiol Immunol* **191**: 1–4.
- Mori K, Nagao H, Yoshihara Y (1999). The olfactory bulb: coding and processing of odor molecule information. *Science* **286**: 711–715.
- Mulder WAM, Jacobs L, Priem J, Kok GL, Wagenaar F, Kimman TG, Pol JMA (1994). Glycoprotein gE-negative pseudorabies virus has a reduced capability to infect second- and third-order neurons of the olfactory and trigeminal routes in the porcine central nervous system. *J Gen Virol* **75**: 3095–3106.
- Narita M, Uchimura A, Kawanabe M, Fukushi H, Hirai K (2001). Invasion and spread of equine herpesvirus 9 in the olfactory pathway of pigs after intranasal inoculation. *J Comp Pathol* **124**: 265–272.
- Ojeda VJ, Archer M, Robertson TA, Bucens MR (1983). Necropsy study of the olfactory portal of entry in herpes simplex encephalitis. *Med J Aust* **1**: 79–81.
- Park CH, Ishinaka M, Takada A, Kida H, Kimura T, Ochiai K, Umemura T (2002). The invasion routes of neurovirulent A/Hong Kong/483/97 (H5N1) influenza virus into the central nervous system after respiratory infection in mice. *Arch Virol* **147**: 1425–1436.
- Perl DP, Good PF (1991). Aluminum, Alzheimer's disease, and the olfactory system. *Ann N Y Acad Sci* **640**: 8–13.
- Prusiner SB (2001). Shattuck lecture—Neurodegenerative diseases and prions. *New Engl J Med* **344**: 1516–1526.
- Reinacher M, Bonin J, Narayan O, Scholtissek C (1983). Pathogenesis of neurovirulent influenza A virus infection in mice. Route of entry of virus into brain determines infection of different populations of cells. *Lab Invest* **49**: 686–692.
- Reuber M, Al-Din ASN, Baborie A, Chakrabarty A (2001). New variant Creutzfeldt-Jakob disease presenting with loss of taste and smell. *J Neurol Neurosurg Psychiatry* **71**: 412–413.
- Rose JW, Stroop WG, Matsuo F, Henkel J (1992). Atypical herpes simplex encephalitis: clinical, virologic, and neuropathologic evaluation. *Neurology* **42**: 1809–1812.
- Salès N, Rodolfo K, Hässig R, Faucheux B, Di Giamberardino L, Moya KL (1998). Cellular prion protein localization in rodent and primate brain. *Eur J Neurosci* **10**: 2464–2471.
- Sauder C, Staeheli P (2003). Rat model of Borna disease virus transmission: epidemiological implications. *J Virol* **77**: 12886–12890.
- Sawcer SJ, Yuill GM, Esmonde TFG, Estibeiro P, Ironside JW, Bell JE, Will RG (1993). Creutzfeldt-Jakob disease in an individual occupationally exposed to BSE. *Lancet* **341**: 642.
- Schwob JE (2002). Neural regeneration and the peripheral olfactory system. *Anat Rec (New Anat)* **269**: 33–49.
- Shaw IC (1995). BSE and farmworkers. *Lancet* **346**: 1365.
- Slavin KA, Passaro DJ, Hacker JK, Hendry RM, Kohl S (2000). Parainfluenza virus type 4: case report and review of the literature. *Pediatr Infect Dis J* **19**: 893–896.
- Smith PEM, Zeidler M, Ironside JW, Estibeiro P, Moss TH (1995). Creutzfeldt-Jakob disease in a dairy farmer. *Lancet* **346**: 898.
- Studahl M (2003). Influenza virus and CNS manifestations. *J Clin Virol* **28**: 225–232.
- Tabaton M, Monaco S, Cordone MP, Colucci M, Giaccone G, Tagliavini F, Zanusso G (2004). Prion deposition in olfactory biopsy of sporadic Creutzfeldt-Jakob disease. *Ann Neurol* **55**: 294–296.
- Tanaka H, Park C-H, Ninomiya A, Ozaki H, Takada A, Umemura T, Kida H (2003). Neurotropism of the 1997 Hong Kong H5N1 influenza virus in mice. *Vet Microbiol* **95**: 1–13.
- Taniguchi A, Fukushi H, Matsumura T, Yanai T, Masegi T, Hirai K (2000). Pathogenicity of a new neurotropic equine herpesvirus 9 (gazelle herpesvirus 1) in horses. *J Vet Med Sci* **62**: 215–218.
- Thoulouze M-I, Lafage M, Schachner M, Hartmann U, Cremer H, Lafon M (1998). The neural cell adhesion molecule is a receptor for rabies virus. *J Virol* **72**: 7181–7190.
- Tomishima MJ, Enquist LW (2001). A conserved α -herpesvirus protein necessary for axonal localization of viral membrane proteins. *J Cell Biol* **154**: 741–752.
- Twomey JA, Barker CM, Robinson G, Howell DA (1979). Olfactory mucosa in herpes simplex encephalitis. *J Neurol Neurosurg Psychiatry* **42**: 983–987.
- Tyler KL, Tedder DG, Yamamoto LJ, Klapper JA, Ashley R, Lichtenstein KA, Levin MJ (1995). Recurrent brainstem encephalitis associated with herpes simplex virus type 1 DNA in cerebrospinal fluid. *Neurology* **45**: 2246–2250.

- Webby RJ, Webster RG (2003). Are we ready for pandemic influenza? *Science* **302**: 1519–1522.
- Winkler WG, Fashinell TR, Leffingwell L, Howard P, Conomy JP (1973). Airborne rabies transmission in a laboratory worker. *JAMA* **226**: 1219–1221.
- Yanai T, Fujishima N, Fukushi H, Hirata A, Sakai H, Masegi T (2003a). Experimental infection of equine herpesvirus 9 in dogs. *Vet Pathol* **40**: 263–267.
- Yanai T, Tujioka S, Sakai H, Fukushi H, Hirai K, Masegi T (2003b). Experimental infection with equine herpesvirus 9 (EHV-9) in cats. *J Comp Pathol* **128**: 113–118.
- Yokota S, Imagawa T, Miyamae T, Ito S-I, Nakajima S, Nezu A, Mori M (2000). Hypothetical pathophysiology of acute encephalopathy and encephalitis related to influenza virus infection and hypothermia therapy. *Pediatr Int* **42**: 197–203.
- Zanusso G, Ferrari S, Cardone F, Zampieri P, Gelati M, Fiorini M, Farinazzo A, Gardiman M, Cavallaro T, Bentivoglio M, Righetti PG, Pocchiari M, Rizzuto N, Monaco S (2003). Detection of pathologic prion protein in the olfactory epithelium in sporadic Creutzfeldt-Jakob disease. *New Engl J Med* **348**: 711–719.