

Oncologic Safety of Laparoscopic Wedge Resection with Gastrotomy for Gastric Gastrointestinal Stromal Tumor: Comparison with Conventional Laparoscopic Wedge Resection

Sejin Lee¹, You Na Kim¹, Taeil Son¹, Hyoung-Il Kim¹, Jae-Ho Cheong¹, Woo Jin Hyung^{1,2}, and Sung Hoon Noh¹

¹Department of Surgery, ²Robot and Minimally Invasive Surgery Center, Yonsei University College of Medicine, Seoul, Korea

Purpose: Various laparoscopic wedge resection (LWR) techniques requiring gastrotomy for gastrointestinal stromal tumors (GISTs) of the stomach have been applied to facilitate tumor resection and preserve the remnant gastric volume. However, there is the possibility of cancer cell dissemination during these procedures. The aim of this study was to assess the oncologic safety of LWR with gastrotomy (LWR-G) compared to LWR without luminal exposure.

Materials and Methods: Clinicopathologic and operative results of 193 patients who underwent LWR for gastric GIST were retrospectively analyzed from 2003 to 2013. We stratified the patients into two groups: LWR-G and LWR without gastrotomy (LWR-C). Clinicopathologic features, short-term outcomes, and long-term outcomes were compared.

Results: A total of 26 patients underwent LWR-G, and 167 patients underwent LWR-C. The LWR-G group showed significantly more anterior wall-located (n=10, 38.5%), intraluminal (n=20, 76.9%), and ulcerative (n=13, 50.0%) tumors than the LWR-C group (n=33, 19.8%; n=96, 57.5%; n=46, 27.5%, respectively). Postoperative short-term outcomes did not differ between the two groups. When tumor staging was compared, no statistical difference was noted. There was no recurrence in the LWR-G group, while 2 patients in the LWR-C group experienced recurrence. The two recurrences in the LWR-C group were found in the liver and in the remnant stomach at 63 and 12 months after the operation, respectively. No gastric GIST-related death was recorded in any group during the study period.

Conclusions: LWR-G for gastric GIST is an oncologically safe procedure even for masses with ulcerations.

Key Words: Laparoscopy; Gastrointestinal stromal tumors; Recurrence; Stomach neoplasms

Introduction

Gastrointestinal stromal tumors (GISTs) occur most frequently in the stomach.¹⁻⁴ Wedge resection of the stomach with R0 resection is regarded as a standard treatment because of the low risk of lymph node metastasis from the tumor.^{2,5-7} Relatively small sized tumors have been safely treated by various laparo-

scopic approaches since the first report of laparoscopic wedge resection (LWR) of a gastric submucosal tumor in 1991.⁸⁻¹¹

Although laparoscopic gastric wedge resection for extraluminal tumors can be performed easily, intraluminal or small tumors are difficult to localize laparoscopically, requiring an intragastric approach or gastrotomy for tumor resection.¹²⁻¹⁶ Consequently, the possibility of spreading cancer cells in the abdominal cavity arises due to the additional manipulation of the tumor and luminal exposure during these procedures. Thus, it could be a risk factor for peritoneal recurrence. In addition, if the tumors have ulcerations, the risk of cancer cell dissemination might increase.^{17,18}

So far, there is no report regarding the long-term outcomes of laparoscopic gastric wedge resection with gastrotomy for the

Correspondence to: Taeil Son
Department of Surgery, Yonsei University College of Medicine, 50 Yonsei-ro, Seodaemun-gu, Seoul 03722, Korea
Tel: +82-2-2228-2100, Fax: +82-2-313-8289
E-mail: tison@yuhs.ac
Received October 6, 2015
Revised October 17, 2015
Accepted October 19, 2015

© This is an open-access article distributed under the terms of the Creative Commons Attribution Non-Commercial License (<http://creativecommons.org/licenses/by-nc/4.0>) which permits unrestricted noncommercial use, distribution, and reproduction in any medium, provided the original work is properly cited.

treatment of gastric GISTs. In the current study, we compared the oncologic safety of LWR with gastrotomy (LWR-G) and LWR without luminal exposure. Specifically, the long-term consequences for ulcerative GISTs requiring luminal exposure during operation were investigated. Recurrence patterns were also analyzed.

Materials and Methods

1. Patients

Between March 2003 and December 2013, 205 LWRs of the stomach were performed in patients with histologically confirmed gastric GISTs at the Department of Surgery at Yonsei University College of Medicine. The study included 193 patients who underwent LWR of the stomach. Of the 193 patients, 26 underwent LWR-G, while the other 167 underwent LWR without gastrotomy (LWR-C). Patients were excluded if they had a ruptured tumor at the time of diagnosis, underwent palliative resection or an endoscopic procedure before the operation, or had insufficient data regarding mitotic rate for proper staging (Fig. 1). On the basis of preoperative endoscopy, endoscopic ultrasound, and abdominopelvic computed tomography scanning, LWR was generally indicated for relatively small gastric submucosal tumors up to 5 cm in the early period, and later on, the indication was expanded to include tumors larger than 5 cm. The type

of resection was selected at the surgeon's discretion according to the tumor location and size. Patients who were pathologically classified as high risk according to the National Institutes of Health-Fletcher classification were recommended for treatment with imatinib mesylate (Gleevec®; Novartis, Basel, Switzerland), whenever possible. Clinicopathologic characteristics, short-term outcomes, and long-term outcomes, including recurrence and survival status, were analyzed retrospectively.

This retrospective study to compare outcomes with another surgical techniques was approved by the Institutional Review Board (IRB) of Severance Hospital, Yonsei University College of Medicine (4-2015-0865).

2. Surgical technique

Various laparoscopic gastric wedge resection techniques have been described in the literature.^{1,5,12,13,15,18} When tumors grow outward from the stomach toward the peritoneal cavity, wedge resection using endolinear staplers can be performed easily without considerable manipulation of the tumor.¹²⁻¹⁴ In cases of intraluminal tumors in the posterior wall of the stomach, trans-gastric tumor-everting methods followed by gastrotomy of the anterior wall of the stomach facilitate tumor resection.^{13,14,19,20} When performing this procedure, the lesion was identified by endoscopy or laparoscopic ultrasonography, and the optimal site of the anterior stomach wall for gastrotomy was chosen. After an incision was made, the tumor was removed by transecting the inverted posterior wall using endolinear staplers. The anterior wall was closed with endolinear staplers or with a laparoscopic suture technique.^{14,19} When relatively larger intraluminal tumors are located in the anterior wall, the eversion method can facilitate tumor resection and minimize excessive resection of the normal gastric wall.¹⁵ For this procedure, a gastrotomy was created about 1 cm from the tumor margin by using intraoperative laparoscopic ultrasonography. Then, the tumor was exteriorized via the incision and resected by endolinear staplers. The advantage of this procedure was that the gastrotomy was closed at the same time the endolinear staplers were applied.¹⁵ For intraluminal tumors near the cardia or the pylorus, the preferred procedure may be intragastric wedge resection with single incision intragastric or conventional intragastric procedures to minimize deformity of the esophagogastric junction or the pylorus.^{18,21-23} For the single incision intragastric procedure, two wound protectors were used. The anterior gastrotomy was made and pulled out of the abdominal incision, and then another wound protector

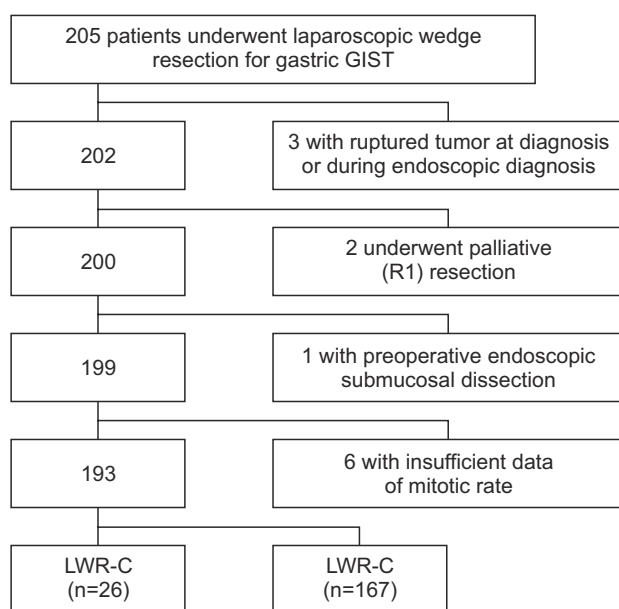


Fig. 1. Patient disposition. GIST = gastrointestinal stromal tumor; LWR-G = laparoscopic wedge resection with gastrotomy; LWR-C = laparoscopic wedge resection without gastrotomy.

was applied via gastrotomy. After laparoscopic removal of the endoluminal tumor, the anterior gastrotomy was closed with endolinear staplers.²³ For small intraluminal tumors, intraoperative endoscopic guidance was sometimes required.^{16,18}

3. Statistical analysis

Clinicopathologic features, short-term outcomes, and long-term outcomes were analyzed using the IBM SPSS statistical software ver. 20 (IBM Co., Armonk, NY, USA). Categorical and continuous variables were analyzed by the χ^2 (or Fisher's exact test) and Student's t test, respectively. Survival curves were depicted by the Kaplan-Meier method and compared by log-rank test. Two-sided P-values of less than 0.05 were considered to be

statistically significant.

Results

The clinicopathologic features are shown in Table 1. Of a total of 193, 26 patients (13.5%) underwent LWR-G, and 167 patients (86.5%) underwent LWR-C. The mean age did not differ between the two groups (P=0.419). The mean body mass index was similar between the two groups (P=0.659). Mean tumor size and longitudinal location between the LWR-G and LWR-C groups were comparable (P=0.696 and P=0.913, respectively). However, more anterior wall-located, intraluminal tumors were found in the LWR-G group compared to the LWR-C group (P=0.022 and P=0.029, respectively). A significantly larger number of tumors (n=13, 50.0%) in the LWR-G group than in the LWR-C group had ulcerations (P=0.021).

Operative outcomes are shown in Table 2. All patients included in the current study underwent complete tumor resection without gross spillage, tumor rupture, or microscopic margin involvement. No open conversion was noted in any patients. The mean operation time for LWR-G was 64.0 minutes compared with a mean of 55.9 minutes for LWR-C (P=0.313). Resumption of soft diet and postoperative hospital stay did not differ between the two groups. No postoperative complications were noted in the LWR-G group, while 3 patients (1.8%) in the LWR-C group

Table 1. Comparison of clinicopathologic features of patients who underwent LWR-G and LWR-C (n=193)

Characteristic	LWR-G (n=26)	LWR-C (n=167)	P-value
Age (yr)	55.3±16.8	58.1±11.4	0.419
<65	18 (69.2)	119 (71.3)	0.832
≥65	8 (30.8)	48 (28.7)	
Sex			0.466
Male	10 (38.5)	77 (46.1)	
Female	16 (61.5)	90 (53.9)	
Body mass index (kg/m ²)	24.0±2.6	24.3±3.1	0.659
Size (mm)	36.3±23.3	37.9±18.0	0.696
Location (longitudinal)			0.913
Upper	16 (61.6)	102 (61.1)	
Middle	5 (19.2)	37 (22.1)	
Lower	5 (19.2)	28 (16.8)	
Location (circular)			0.022
Anterior wall	10 (38.5)	33 (19.7)	
Posterior wall	6 (23.1)	35 (21.0)	
Lesser curvature	8 (30.7)	39 (23.4)	
Greater curvature	2 (7.7)	60 (35.9)	
Macroscopic growth pattern			0.029
Extraluminal	3 (11.5)	59 (35.3)	
Intraluminal	20 (77.0)	96 (57.5)	
Mixed	3 (11.5)	12 (7.2)	
Ulceration			0.021
Yes	13 (50.0)	46 (27.5)	
No	13 (50.0)	121 (72.5)	

Values are presented as mean±standard deviation or number (%). LWR-G = laparoscopic wedge resection with gastrotomy; LWR-C = laparoscopic wedge resection without gastrotomy.

Table 2. Comparison of short-term operative outcomes

Variable	LWR-G (n=26)	LWR-C (n=167)	P-value
Open conversion	0	0	
Operation time (min)	64.0±29.9	55.9±33.4	0.313
Completeness of resection			
R0	26	167	
R1	0	0	
Resumption of soft diet (POD)	1.5±1.2	1.5±1.6	0.958
Hospital stay (POD)	2.6±2.1	2.7±2.1	0.748
Complication			>0.999
Yes	0	3 (1.8)	
No	26	164 (98.2)	
Mortality	0	0	

Values are presented as number only, mean±standard deviation, or number (%). LWR-G = laparoscopic wedge resection with gastrotomy; LWR-C = laparoscopic wedge resection without gastrotomy; POD = postoperative day.

Table 3. Comparison of pathologic outcomes

Variable	LWR-G (n=26)	LWR-C (n=167)	P-value
Size (cm)			0.190
<2	4 (15.4)	13 (7.8)	
≥2, <5	17 (65.4)	119 (71.2)	
≥5, ≤10	4 (15.4)	34 (20.4)	
>10	1 (3.8)	1 (0.6)	
Mitotic rate (mitoses/HPFs)			0.621
≤5/50	23 (88.5)	133 (79.6)	
>5/50 ≤10/50	1 (3.8)	18 (10.8)	
>10/50	2 (7.7)	16 (9.6)	
Resection margin			
Negative	0	0	
Positive	26	167	
NIH-fletcher			0.573
Very low	4 (15.4)	12 (7.2)	
Low	14 (53.9)	97 (58.1)	
Moderate	5 (19.2)	37(22.1)	
High	3 (11.5)	21 (12.6)	
AFIP criteria			0.846
None	4 (15.4)	23 (13.7)	
Very low	15 (57.7)	89 (53.3)	
Low	3 (11.5)	20 (12.0)	
Moderate	4 (15.4)	24 (14.4)	
High	0	11 (6.6)	
TNM classification*			0.193
Stage IA	19 (73.1)	88 (52.7)	
Stage IB	3 (11.5)	18 (10.8)	
Stage II	3 (11.5)	48 (28.7)	
Stage III	1 (3.9)	13 (7.8)	
Adjuvant Imatinib use			0.667
No	24 (92.3)	157 (94.0)	
Yes	2 (7.7)	10 (6.0)	
Recurrence			
No	26 (100)	165 (98.8)	>0.999
Yes	0	2 (1.2)	
Death			
No	26 (100)	164 (98.2)	>0.999
Yes	0	3 (1.8)	

Values are presented as number (%) or number only. LWR-G = laparoscopic wedge resection with gastrotomy; LWR-C = laparoscopic wedge resection without gastrotomy; HPFs = high power fields; NIH = National Institutes of Health; AFIP = American Forces Institute of Pathology. *The seventh edition of the American Joint Committee on Cancer Staging System.

Table 4. Clinical features of patients with recurrence

Patient No.	Age (yr)	Sex	Location (L/C)	Location (L/C)	Growth type	Ulcer	Operation	Size (mm)	Mitotic rate (mitoses/HPFs)	NIH-Fletcher	TNM*	Recurrence site	Time to recurrence (mo)	Survival status
1	44	Male	U/GC	U/GC	Intraluminal	Yes	LWR-C	40	>10/50	High	II	Liver	63	Alive
2	57	Male	U/GC	U/GC	Intraluminal	No	LWR-C	15	2/50	Very low	IA	Remnant stomach	12	Alive

L/C = longitudinal/circular; HPFs = high power fields; NIH = National Institutes of Health; U = upper; GC = greater curvature; LWR-C = laparoscopic wedge resection without gastrotomy. *The seventh edition of the American Joint Committee on Cancer Staging System.

had complications.

Pathologic and long-term outcomes are shown in Table 3. There was no statistically significant difference in the mean tumor size ($P=0.696$). When the tumor size and mitotic rate were stratified according to the current risk criteria of gastric GIST, there was no difference in proportion of the size and mitotic rate between the two groups ($P=0.190$ and $P=0.621$, respectively). Consequently, risk based on National Institutes of Health–Fletcher, American Forces Institute of Pathology criteria, and TNM classification did not differ between the groups ($P=0.573$, $P=0.846$, and $P=0.193$, respectively). Adjuvant therapy with imatinib mesylate was administered to 2 patients (7.7%) and 10 patients (6.0%) in the LWR–G and LWR–C groups, respectively. During the median follow-up period of 36 months, 2 patients in the LWR–C group had recurrence in the liver and in the remnant stomach at 63 and 12 months after surgery, respectively. No patient in the LWR–G group had recurrence. The characteristics of the patients with recurrence are depicted in Table 4. During the follow-up period, 3 patients in the LWR–C group died, but there were no gastric GIST-related deaths.

Discussion

In the current study, we found that peritoneal recurrence due to potential spillage of cancer cells may not happen during LWR–G for gastric GIST. In addition, ulcerative GIST treated with the same procedures did not increase the risk of peritoneal recurrence. Gastrotomy with everting/eversion methods or intragastric procedures may not increase the rate of recurrence due to tumor spillage by luminal exposure during LWR. In addition, we observed that the pattern of recurrence, especially peritoneal recurrence, was significantly low after LWR–G or LWR–C for relatively small GISTs.

GISTs are rare tumors and a distinctive histopathological group of intestinal neoplasms of mesenchymal origin.³ They comprise fewer than 3% of all gastrointestinal cancers, and the most frequently involved site is the stomach, followed by the small intestine.^{3,24} Complete R0 resection without lymphadenectomy for primary non-metastatic GIST remains the only curative treatment.²⁶ Since the first report of LWR of a gastric submucosal tumor, laparoscopic resection of GIST is considered to be feasible and safe from both the technical and the oncologic point of view.^{6,8,17}

Although LWR for gastric GIST has demonstrated accept-

able oncologic outcomes, the current indication is limited to relatively small tumors due to possible rupture of the tumor into the peritoneal cavity during the procedure.^{10,11,25–28} The European Society for Medical Oncology guidelines recommend laparoscopic gastric wedge resection for tumors less than 2 cm in size, while the National Comprehensive Cancer Network and Japanese guidelines recommend the procedure for tumors less than 5 cm by experienced surgeons.^{10,27,28} The risk of possible tumor cell dissemination into the peritoneal cavity can be greatly increased when it is performed in conjunction with more complicated procedures such as those requiring transgastric or intragastric approaches. Transgastric everting for intraluminal masses in the posterior wall of the stomach and eversion methods for intraluminal tumors in the anterior wall have shown satisfactory short-term outcomes.^{14,15} However, during these procedures, tumors can be manipulated more vigorously, and gastric luminal contents can be spilled out into the peritoneal cavity.^{17,18} Furthermore, for tumors with ulcerative lesions, the potential hazard is expected to worsen.¹⁸ If the GIST ruptures into the peritoneal cavity, the recurrence rate increases by almost 100%.²⁹

However, we experienced only 2 cases of recurrence in the LWR–C group during the median follow-up period of 36 months. The overall incidence of recurrence was 1.0% in the studied patients. The results were comparable to other reported series in the literature.^{25,26} Even with ulcerative lesions, which comprised 50% of the lesions in the LWR–G group and had low to intermediate risk in most cases (data not shown), we did not observe any recurrence during the follow-up period. The low incidence of recurrence in the current study might have been achieved by careful manipulation of the tumors to avoid tumor rupture and significant spillage of gastric contents into the peritoneal cavity. There was no intraoperative tumor rupture in the current study. Second, the indications were limited to relatively small tumors so that only a small portion of patients were classified as high-risk. Finally, by using wound protectors to avoid direct contact of the tumors with the surgical wound when retrieving the specimens, the possibility of cancer cell dissemination to the surgical wound was minimized. In addition, all patients who received adjuvant imatinib treatment showed favorable outcomes without recurrence in the study period.

To our knowledge, this is the first study in the literature to investigate the long-term outcomes of LWR–G for gastric GISTs compared to conventional LWR. Our study revealed that gastric lumen exposure during procedures, which facilitate

tumor localization and resection while avoiding excessive resection of the remnant stomach to prevent functional and structural deformities can be safely performed even in ulcerative lesions, given meticulous handling of the tumors and properly indicated patients. However, the study has several limitations. First, the current study was conducted retrospectively in a single center. Second, long-term outcomes, especially recurrence patterns, could not be properly assessed because the number of high-risk patients was small in both groups. Therefore, the results of the current study should be compared to a larger number of cases to determine the exact impact of luminal exposure during LWR for ulcerative lesions in high-risk patients.

In conclusion, LWR-G did not increase overall or peritoneal recurrence for the selected patients. This technique might be safely performed even for ulcerative gastric GISTs.

Conflicts of Interest

No potential conflict of interest relevant to this article was reported.

References

1. Matthews BD, Joels CS, Kercher KW, Heniford BT. Gastrointestinal stromal tumors of the stomach. *Minerva Chir* 2004;59:219-231.
2. Das A, Wilson R, Biankin AV, Merrett ND. Surgical therapy for gastrointestinal stromal tumours of the upper gastrointestinal tract. *J Gastrointest Surg* 2009;13:1220-1225.
3. Pithorecky I, Cheney RT, Kraybill WG, Gibbs JF. Gastrointestinal stromal tumors: current diagnosis, biologic behavior, and management. *Ann Surg Oncol* 2000;7:705-712.
4. Emory TS, Sobin LH, Lukes L, Lee DH, O'Leary TJ. Prognosis of gastrointestinal smooth-muscle (stromal) tumors: dependence on anatomic site. *Am J Surg Pathol* 1999;23:82-87.
5. Privette A, McCahill L, Borrazzo E, Single RM, Zubarik R. Laparoscopic approaches to resection of suspected gastric gastrointestinal stromal tumors based on tumor location. *Surg Endosc* 2008;22:487-494.
6. DeMatteo RP, Lewis JJ, Leung D, Mudan SS, Woodruff JM, Brennan MF. Two hundred gastrointestinal stromal tumors: recurrence patterns and prognostic factors for survival. *Ann Surg* 2000;231:51-58.
7. Hassan I, You YN, Shyyan R, Dozois EJ, Smyrk TC, Okuno SH, et al. Surgically managed gastrointestinal stromal tumors: a comparative and prognostic analysis. *Ann Surg Oncol* 2008;15:52-59.
8. Fowler DL, White SA. Laparoscopic resection of a submucosal gastric lipoma: a case report. *J Laparoendosc Surg* 1991;1:303-306.
9. Berindoague R, Targarona EM, Feliu X, Artigas V, Balagué C, Aldeano A, et al. Laparoscopic resection of clinically suspected gastric stromal tumors. *Surg Innov* 2006;13:231-237.
10. Nishida T, Hirota S, Yanagisawa A, Sugino Y, Minami M, Yamamura Y, et al; GIST Guideline Subcommittee. Clinical practice guidelines for gastrointestinal stromal tumor (GIST) in Japan: English version. *Int J Clin Oncol* 2008;13:416-430.
11. Mochizuki Y, Kodera Y, Fujiwara M, Ito S, Yamamura Y, Sawaki A, et al. Laparoscopic wedge resection for gastrointestinal stromal tumors of the stomach: initial experience. *Surg Today* 2006;36:341-347.
12. Choi YB, Oh ST. Laparoscopy in the management of gastric submucosal tumors. *Surg Endosc* 2000;14:741-745.
13. Basso N, Rosato P, De Leo A, Picconi T, Trentino P, Fantini A, et al. Laparoscopic treatment of gastric stromal tumors. *Surg Endosc* 2000;14:524-526.
14. Avital S, Brascesco O, Szomstein S, Liberman M, Rosenthal R. Technical considerations in laparoscopic resection of gastric neoplasms. *Surg Endosc* 2003;17:763-765.
15. Hyung WJ, Lim JS, Cheong JH, Kim J, Choi SH, Noh SH. Laparoscopic resection of a huge intraluminal gastric submucosal tumor located in the anterior wall: eversion method. *J Surg Oncol* 2005;89:95-98.
16. Tangoku A, Yamamoto K, Hirazawa K, Takao T, Mori N, Tada K, et al. Laparoscopic resection of large leiomyomas of the gastric fundus. *Surg Endosc* 1999;13:1050-1052.
17. Novitsky YW, Kercher KW, Sing RF, Heniford BT. Long-term outcomes of laparoscopic resection of gastric gastrointestinal stromal tumors. *Ann Surg* 2006;243:738-745.
18. Kiyozaki H, Saito M, Chiba H, Takata O, Rikiyama T. Laparoscopic wedge resection of the stomach for gastrointestinal stromal tumor (GIST): non-touch lesion lifting method. *Gastric Cancer* 2014;17:337-340.
19. Motson RW, Fisher PW, Dawson JW. Laparoscopic resection of a benign intragastric stromal tumour. *Br J Surg* 1995;82:1670.
20. Ibrahim IM, Silvestri F, Zingler B. Laparoscopic resection of posterior gastric leiomyoma. *Surg Endosc* 1997;11:277-279.
21. Hwang SH, Park do J, Kim YH, Lee KH, Lee HS, Kim HH,

- et al. Laparoscopic surgery for submucosal tumors located at the esophagogastric junction and the prepylorus. *Surg Endosc* 2009;23:1980-1987.
22. Na JU, Lee SI, Noh SM. The single incision laparoscopic intra-gastric wedge resection of gastric submucosal tumor. *J Gastric Cancer* 2011;11:225-229.
23. Choi CI, Lee SH, Hwang SH, Kim DH, Jeon TY, Kim DH, et al. Single-incision intragastric resection for upper and mid gastric submucosal tumors: a case-series study. *Ann Surg Treat Res* 2014;87:304-310.
24. Miettinen M, Majidi M, Lasota J. Pathology and diagnostic criteria of gastrointestinal stromal tumors (GISTs): a review. *Eur J Cancer* 2002;38 Suppl 5:S39-S51.
25. Kim KH, Kim MC, Jung GJ, Kim SJ, Jang JS, Kwon HC. Long term survival results for gastric GIST: is laparoscopic surgery for large gastric GIST feasible? *World J Surg Oncol* 2012;10:230.
26. Honda M, Hiki N, Nunobe S, Ohashi M, Kiyokawa T, Sano T, et al. Long-term and surgical outcomes of laparoscopic surgery for gastric gastrointestinal stromal tumors. *Surg Endosc* 2014;28:2317-2322.
27. Blay JY, Bonvalot S, Casali P, Choi H, Debiec-Richter M, Dei Tos AP, et al; GIST consensus meeting panelists. Consensus meeting for the management of gastrointestinal stromal tumors. Report of the GIST Consensus Conference of 20-21 March 2004, under the auspices of ESMO. *Ann Oncol* 2005;16:566-578.
28. Demetri GD, Benjamin RS, Blanke CD, Blay JY, Casali P, Choi H, et al; NCCN Task Force. NCCN Task Force report: management of patients with gastrointestinal stromal tumor (GIST): update of the NCCN clinical practice guidelines. *J Natl Compr Canc Netw* 2007;5 Suppl 2:S1-S29.
29. Hohenberger P, Ronellenfitsch U, Oladeji O, Pink D, Ströbel P, Wardelmann E, et al. Pattern of recurrence in patients with ruptured primary gastrointestinal stromal tumour. *Br J Surg* 2010;97:1854-1859.