

## Open Reduction and Internal Fixation of Displaced, Comminuted Intra-Articular Fractures of the Distal End of the Radius<sup>\*†</sup>

BY JOHN K. BRADWAY, M.D.‡, PETER C. AMADIO, M.D.‡, AND WILLIAM P. COONEY, M.D., M.S.‡,  
ROCHESTER, MINNESOTA

*From the Department of Orthopedics, Mayo Clinic and Mayo Foundation, Rochester*

**ABSTRACT:** The results in sixteen patients who had a displaced, comminuted intra-articular fracture of the distal end of the radius and who were treated by open reduction and internal fixation were retrospectively reviewed. At a mean follow-up of 4.8 years, 81 per cent of the patients had a rating of good or excellent by the scoring system of Gartland and Werley, but only 56 per cent had such a rating when the modified scoring system of Green and O'Brien was used. All of the fractures healed at an average of nine weeks. A step-off of two millimeters or more in the distal radial articular surface at the time of healing was important, because the four patients in whom the fracture healed with this amount of incongruity all had post-traumatic arthritis at follow-up, compared with only three of twelve in whom the incongruity was less than two millimeters.

Varying patterns of intra-articular fractures of the distal end of the radius are common in adults. These injuries are commonly referred to as Colles, Barton, or Smith fractures, depending on the pattern of involvement of the distal radioulnar and radiocarpal joint surfaces and the direction of displacement of the fracture fragments<sup>6,11,13,14,20</sup>. Some of these fractures, however, are caused by severe trauma, and the resulting comminution may defy inclusion in a single eponymous group. Treatment of such injuries is often difficult and demanding, particularly when the fracture is severely comminuted or displaced<sup>1-4,7-9,12,16-18,21,22</sup>.

Patients who have a displaced, comminuted intra-articular fracture of the distal end of the radius that has been treated by a closed method, such as pins and plaster or external fixation, have frequently had an unsatisfactory final result<sup>4,5,7-9,12,13,15-18,20,21,24-26</sup>. This is especially true when the

fracture heals with incongruity of the articular surface. Even when radial length was restored and over-all alignment was markedly improved by closed reduction, post-traumatic arthritis developed in 91 per cent of such patients who were followed for a minimum of two years<sup>21</sup>.

In an attempt to improve the results of treatment in these patients, emphasis has been placed on achieving and maintaining an anatomical reduction of the fracture fragments by open reduction and internal fixation<sup>2,8,21,22</sup>; however, only a few reports have documented the efficacy of this approach<sup>21,22</sup>.

This study is a retrospective review of sixteen patients who had a displaced, comminuted intra-articular fracture of the distal end of the radius that was treated by open reduction and internal fixation. We were particularly interested in the long-term clinical and radiographic results.

### Materials and Methods

Between 1976 and 1986, fifty-four displaced intra-articular fractures of the distal end of the radius in fifty-three patients were treated with open reduction and internal fixation at the Mayo Clinic. From this group, we eliminated patients who had been operated on more than thirty days after the injury, patients who had a dorsal or palmar Barton fracture or an isolated fracture of the radial styloid process, and patients who had had less than two years of follow-up after the fracture had united.

Sixteen patients (sixteen fractures), whose ages ranged from eighteen to seventy-five years (average, forty years), met the criteria for inclusion in the study. Each had had a clinical examination and a radiographic evaluation at our institution at a minimum of two years after the injury. There were nine men and seven women. The initial injury had resulted from a fall in eleven patients and from an automobile or motorcycle accident in five.

Concomitant ipsilateral injuries were common. Three patients had had a dislocation of the carpus; two each, a scapholunate ligamentous disruption, tears of the triangular fibrocartilage complex, and a scaphoid fracture; and one, a fracture of the first metacarpal. One fracture was open. Median-nerve compression was noted in four patients, three of whom needed a carpal tunnel release at the time of open

\* No benefits in any form have been received or will be received from a commercial party related directly or indirectly to the subject of this article. Funds were received in total or partial support of the research or clinical study presented in this article. The funding source was the Mayo Foundation.

† Read in part at the Annual Meeting of The American Academy of Orthopaedic Surgeons, Atlanta, Georgia, February 6, 1988, and the Annual Meeting of the Mid-America Orthopaedic Association, Tucson, Arizona, March 16 through 20, 1988.

‡ Mayo Clinic, 200 First Street, S.W., Rochester, Minnesota 55905. Please address requests for reprints to Dr. Amadio.

TABLE I  
ARTICULAR INCONGRUITY\*

Grade	Step-off (mm)
0	0-1
1	1-2
2	2-3
3	>3

\* From Knirk and Jupiter.

treatment of the fracture. In the fourth patient, the median-nerve symptoms had resolved after the initial closed reduction.

Classification of the fractures was based on the AO system<sup>23</sup> (Fig. 1). All sixteen fractures were AO type C2 or C3, both of which have intra-articular extension and comminution. There were ten Colles fractures (nine of which were classified as Frykman type VIII and one, as Frykman type VII), two Smith fractures, and four fractures that could not be eponymically classified. These four comminuted fractures were the result of a high-energy injury and were not well characterized by the Colles and Smith categories. By the AO system, they were classified as C3 injuries. In this type of fracture, some features may be

associated with both dorsal and volar Barton fractures as well as Colles fractures. The direction of carpal displacement is usually directly proximal, with both dorsal and volar displacement of the comminuted fracture fragments, suggesting high-energy axial loading as the mechanism.

Radiographs that were made at the time of injury were studied to assess the extent of intra-articular incongruity, which was graded by the method of Knirk and Jupiter (Table I). This method measures the step-off of the subchondral bone-shadow of the distal end of the radius as seen on plain radiographs and does not reflect any additional irregularity of the articular cartilage surfaces. All patients in this series had at least grade-1 articular incongruity, and twelve had a grade of 2 or worse.

The indication for open reduction and internal fixation in each patient was failure of the initial attempt at closed reduction to achieve or maintain articular congruity (Figs. 2-A through 2-D). We defined articular congruity as a step-off of zero to one millimeter. Any step-off of two millimeters or more was considered incongruent. The timing of the open reduction ranged from the day of injury to twenty-four days after injury (average, 6.5 days).

Access to the fracture of the distal end of the radius was by a dorsal approach in ten patients, a palmar approach

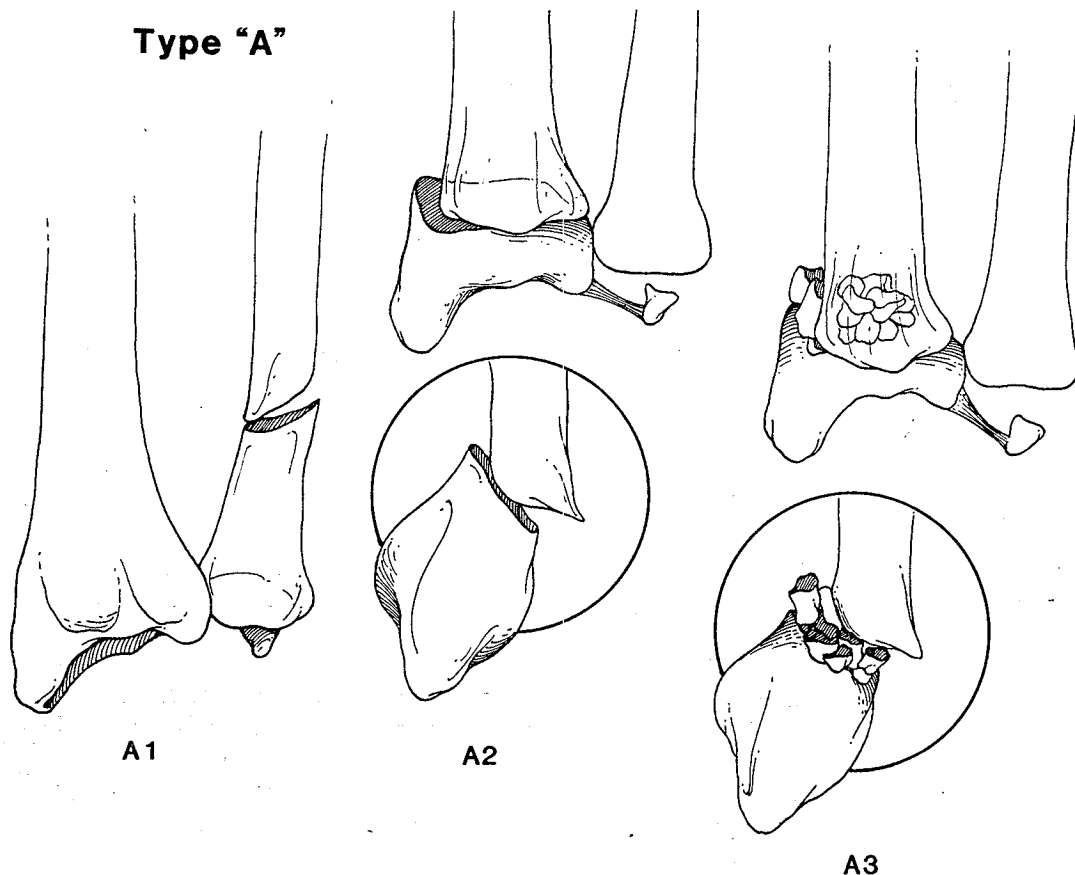


FIG. 1

The AO system for the classification of fractures. Extra-articular fractures are type A and intra-articular fractures, type B or C. Type A includes fractures of the distal end of the ulna (A1) and both uncomminuted (A2) and comminuted (A3) fractures of the distal end of the radius; type B, fractures of the radial styloid process (B1), and Barton (B2) and reverse Barton (B3) fractures; and type C, non-comminuted intra-articular Colles and Smith fractures (C1), those with additional metaphyseal comminution (C2), and those with both metaphyseal and articular comminution (C3).

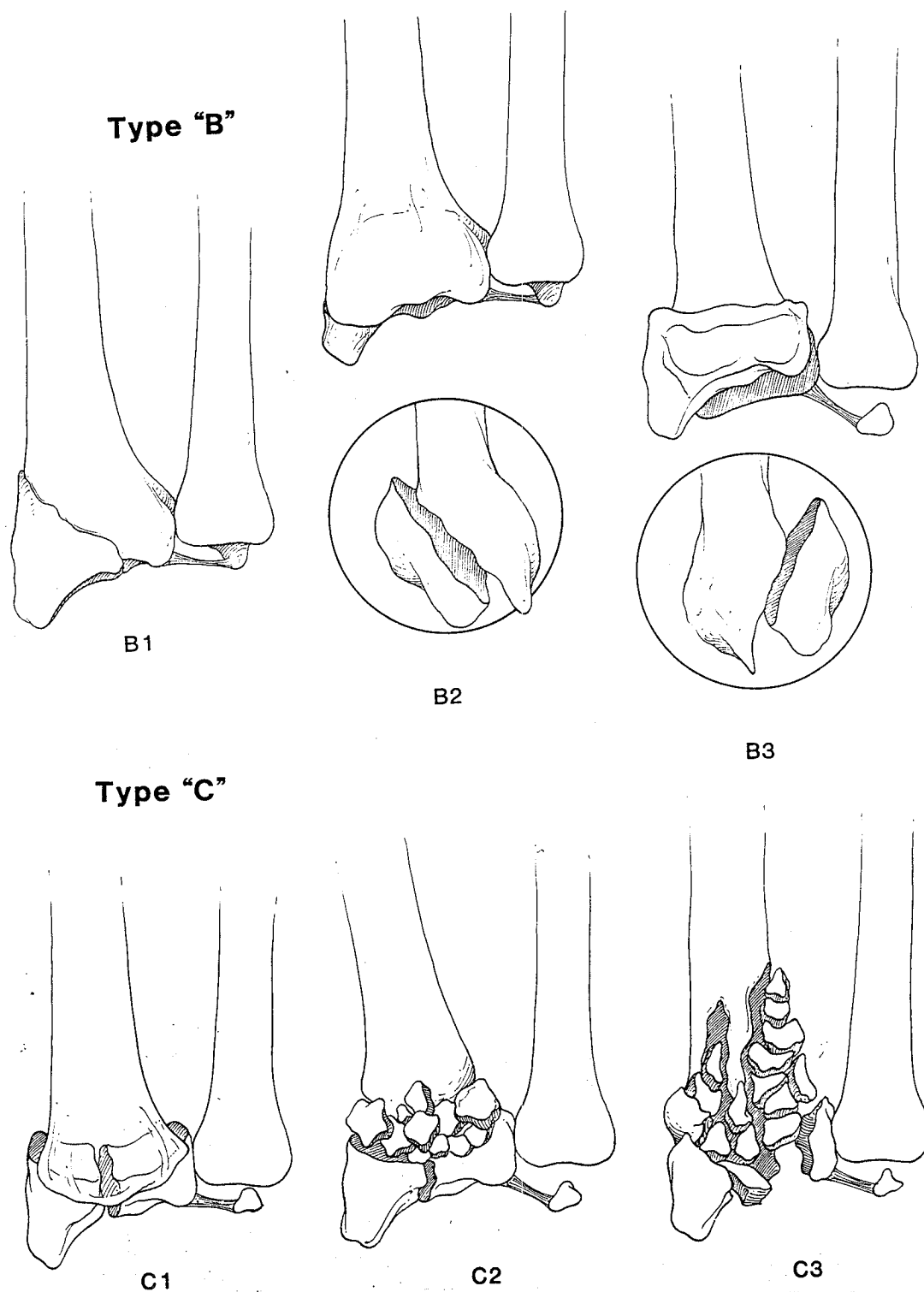


FIG. 1

in two patients, and a combination of these approaches in four patients. The choice of the surgical approach was based on the direction of the displacement of the fracture fragments; combined dorsal and palmar exposures were used for severe bursting fractures that were displaced in both directions.

The fractures were reduced under direct vision and

were internally fixed by the method that seemed most appropriate (Table II). In most of the patients, internal fixation was accomplished with Kirschner wires or an internal fixation plate. Kirschner wires were generally used to stabilize smaller fragments and were particularly helpful in holding articular fragments that had little metaphyseal support. Larger fragments were fixed with a plate and screws. We

as  
ce-  
lar  
ig-  
ere  
ty,  
ble  
lral  
ain  
ity  
ies  
d a  
ion  
sed  
gs.  
ep-  
lli-  
; of  
ity-  
lius  
ach

udes  
tures  
mith

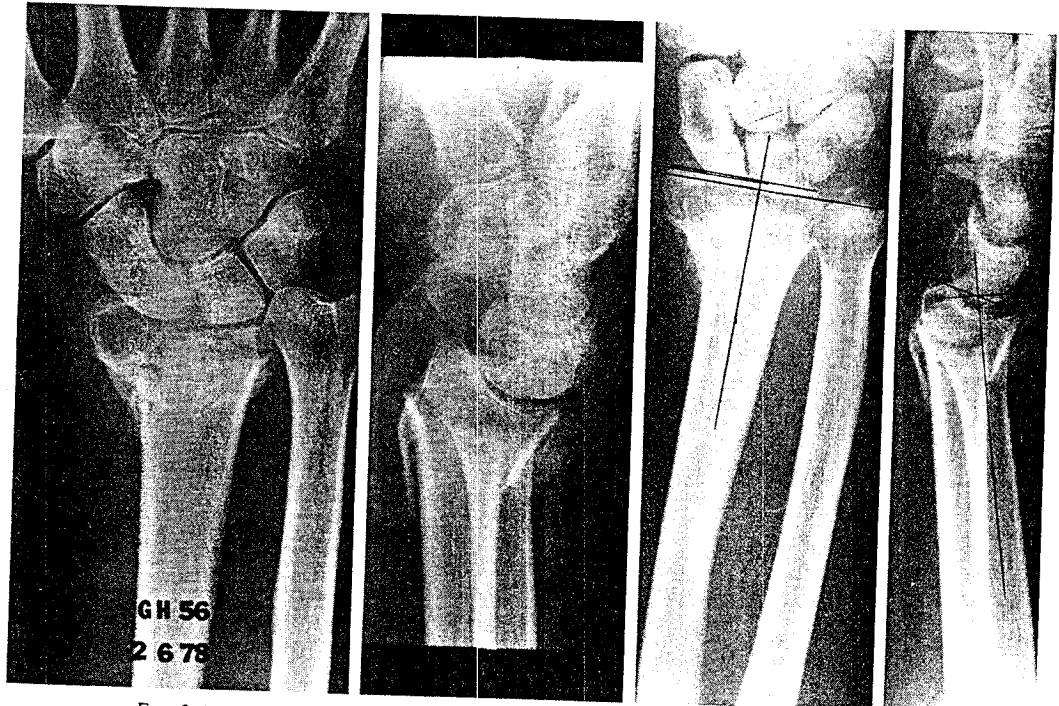


FIG. 2-A

FIG. 2-B

FIG. 2-C

FIG. 2-D

Figs. 2-A through 2-F: Case 1, a fifty-six-year-old woman.

Figs. 2-A and 2-B: The patient sustained a type-C3 fracture of the right wrist in a fall.

Figs. 2-C and 2-D: After unsatisfactory closed reduction and application of a cast, open reduction and internal fixation was performed. A single dorsal plate was used.

usually preferred 3.5-millimeter screws and a small T-plate for such fractures, as shown in Figs. 2-C and 2-D.

More recently, we have found that reduction of the most comminuted fractures can be maintained when an external fixator is applied to provide neutralization of compressive forces acting across the carpus on the small fracture-fragments. For patients who had multiple small fragments,

intraoperative external fixation facilitated reduction of the fracture components and permitted stable fixation with finer wires or screws than would have been possible without neutralization of the axial loading. In these patients, the external fixator was left in place as a neutralization device for eight weeks postoperatively. Cancellous bone-grafting was used in ten patients to support the articular surface when

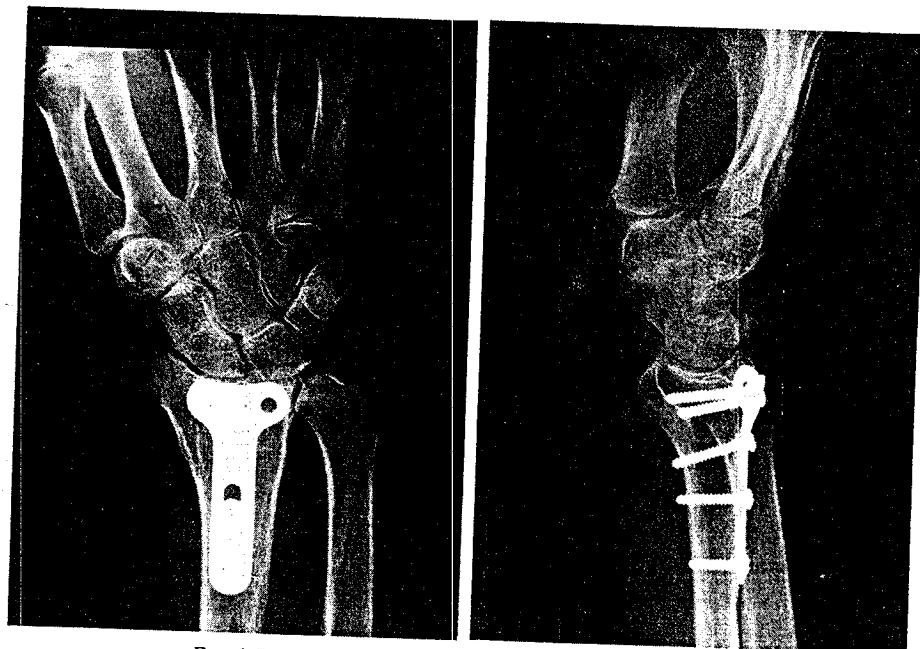


FIG. 2-E

FIG. 2-F

At the nine-year follow-up, the patient had an excellent result by the scoring system of Gartland and Werley, despite a stroke that affected the right side. Because of stroke-related weakness, the modified Green and O'Brien score<sup>10</sup> was only fair.

TABLE II  
FOLLOW-UP DATA

Case	Sex, Age (Yrs.)	Injured Side	Associated Injury*	Reason for Open Reduction and Internal Fixation†	AO Type of Fracture	Type of Fixation†	Complication	Duration of Follow-up (Yrs.)	Grade of Distal-Radial Incongruity		Grade of Arthritic Change at Follow-up	Gartland and Werley Score (Points), and Result	Modified Green and O'Brien Score (Points), and Result
									Preop.	Postop.			
1	F, 56	R		Failed cast	C3	Buttress plate		9	3	0	0	2, excellent	75, fair
2	M, 54	L		Failed CR	C3	Kirschner wire, EF		9.2	2	1	0	1, excellent	90, excellent
3	F, 64	L		Failed cast	C2	2 plates		11.1	2	0	0	4, good	75, fair
4	M, 51	R	Torn TFC; scaphoid fracture	Failed CR, cast	C3	Kirschner wires, EF	Pin-tract infect.	2.1	3	2	3	13, fair	65, fair
			Torn scapho-lunate ligament										
5	M, 19	R		Failed cast	C3	Kirschner wires	Wound infect.	4	1	0	0	0, excellent	100, excellent
6	F, 73	R		Failed EF	C3	Plate		11	3	2	2	8, good	75, fair
7	F, 60	L	Radiocarpal dislocation	Failed splint	C3	Kirschner wires	Pin-tract infect.	6.5	3	2	2	12, fair	70, fair
8	M, 24	L	Radiocarpal dislocation	Failed CR, cast	C3	Kirschner wire, plate		4.5	1	1	2	6, good	75 fair
9	F, 63	L		Failed CR, cast	C2	Kirschner wires		9	1	0	0	4, good	80, good
10	M, 25	L		Primary Rx	C3	Plate		6.8	3	0	0	0, excellent	90, excellent
11	M, 23	L		Failed cast, EF	C2	Kirschner wires	Broken pin	3.5	2	0	0	0, excellent	90, excellent
12	M, 18	R	Fracture of first metacarpal; radiocarpal dislocation	Failed cast	C3	Kirschner wires		2.5	2	0	1	1, excellent	100, excellent
13	M, 27	R		Primary Rx	C3	2 plates, Kirschner wires		2	3	2	3	10, fair	75, fair
14	M, 43	L	Torn scapho-lunate ligament; scaphoid fracture	Primary Rx	C3	Kirschner wires, EF		2	3	0	0	2, excellent	80, good
15	F, 43	R		Primary Rx	C3	Kirschner wire, EF		2	3	0	0	2, excellent	90, excellent
16	F, 30	R	Torn TFC	EF failed	C2	Kirschner wire, EF	Painful ulnar-styloid non-union	2.5	1	0	1	1, excellent	95, excellent

\* TFC = triangular fibrocartilage.

† CR = closed reduction, EF = external fixation, and Rx = treatment.

a defect in the metaphysis remained after reduction. This helped to stabilize the reduction of the articular surface, eliminated the gap between fragments that often is seen after treatment with an external fixator, and appeared to speed fracture-healing.

The clinical evaluation was based on examination of the wrist and the radiographs. The examination of the wrist included visual inspection, measurement of the range of motion, palpation for painful areas, and grip-strength testing with a hand-held dynamometer. The contralateral wrist served as a control. Anteroposterior and lateral radiographs of the involved wrist were made for all patients who returned for examination. These radiographs were evaluated for arthritic changes (Table III), radial and dorsal-volar tilt of the distal radial surface, and non-union of the ulnar styloid process.

The data that were obtained were quantified by two scoring systems, one of which was purely clinical and the other, both clinical and radiographic. The modified system of Green and O'Brien<sup>10</sup> (Table IV), which provides a score based only on subjective and objective clinical information, is a very stringent system, in that normal or near-normal function, strength, and motion are required for an excellent result. It was originally used to rate the results, both radio-

graphically and clinically, after perilunate dislocation. Cooney et al.<sup>10</sup> modified this system by deleting the radiographic score to create a clinical scoring system that can be used to assess various problems of the wrist, similar to the systems that are commonly used to evaluate function of the hip and knee. The demerit system of Gartland and Werley (Table V) provides a score based on subjective and objective clinical data and on radiographic data. This system has the advantage of having been used frequently, but it is much less strict; it gives no demerits, and hence, a perfect score, for dorsiflexion to only 45 degrees, palmar flexion to only 30 degrees, pronation and supination to only 50 degrees each, and grip strength to only 60 per cent of normal. In the system of Green and O'Brien, these findings would at best earn only a fair result (70 points). Each scoring system allows grading of the final outcome as excellent, good, fair, or poor.

Statistical analysis was performed with the rank correlation test of Spearman.

### Results

The patients returned for follow-up examination and radiographs at a mean of 5.7 years (range, two to eleven years).

TABLE III  
GRADING OF ARTHRITIS\*

Grade	Finding
0	None
1	Slight joint-space narrowing
2	Marked joint-space narrowing, formation of osteophytes
3	Bone on bone, formation of osteophytes and cysts

\* From Knirk and Jupiter.

By the criteria of Gartland and Werley, nine (56 per cent) of the wrists were rated as excellent; four, (25 per cent) as good; and three (19 per cent), as fair; no wrist received a poor rating. Thus, thirteen (81 per cent) of the patients had an excellent or good result.

By the modified system of Green and O'Brien<sup>10</sup>, seven wrists (44 per cent) were rated as excellent; two (12 per cent), as good; and seven (44 per cent), as fair. By these criteria, nine patients (56 per cent) had an excellent or good result.

All patients reported that they were able to return to domestic duties or to their occupations after the fracture had healed. No patient, regardless of the grade of injury or the result, considered the sequelae of the injury to be a disability that necessitated modification of activities at work or leisure. Only one patient indicated dissatisfaction with the result of the operation; this was because of a prominent plate and poor appearance of the wrist, although neither the plate nor the cosmetic deformity interfered with any of her normal activities.

The grip strength on the injured side averaged 75 per cent (range, 33 to 100 per cent) of that on the uninjured side. The range of motion of the wrist at the latest follow-up had been recorded for all patients. There was a mean of 21 degrees (range, 10 to 30 degrees) of radial deviation, 32 degrees (range, 15 to 50 degrees) of ulnar deviation, 55 degrees (range, 40 to 75 degrees) of extension, and 55 degrees (range, 30 to 75 degrees) of flexion. Three patients had a major loss of motion by the criteria of Gartland and Werley. Two patients had less than 45 degrees of dorsiflexion; one, less than 15 degrees of radial deviation; and one, less than 45 degrees of supination. Radiographs showed that two of these patients had substantial (grades 2 and 3) arthritic changes in the wrist joint.

The presence or absence of union of the ulnar styloid process did not appear to influence the final result. All of the patients who had non-union of a fracture of the ulnar styloid process had an excellent or good result at the most recent evaluation, although one patient had had an operation for a painful non-union of the ulnar styloid process.

Six patients had a total of nine concomitant injuries of the ipsilateral wrist. Two patients had a scaphoid fracture and partial tears of the scapholunate ligament in addition to the intra-articular fracture of the distal end of the radius. In the other four patients, the carpal articular surface was uninjured. These six patients had three excellent, one good,

and two fair results by the system of Gartland and Werley and two excellent, one good, and three fair results by the modified system of Green and O'Brien<sup>10</sup>.

All of the radial fractures were solidly united at an average of nine weeks after the operation. Only one patient had loss of reduction of the extra-articular alignment, as seen on serial radiographs, after reduction and internal fixation. In this seventy-three-year-old woman (Case 6, Table II), a large fragment of the radial styloid process migrated radially six weeks after internal fixation, creating a 10-degree radial tilt and, more importantly, loss of the intra-articular congruence that had been established surgically. The loss of extra-articular alignment was important because, eleven years later, she complained of deformity of the wrist secondary to the prominence of the ulnar styloid process and radial deviation of the hand. A corticocancellous bone graft from the ipsilateral ulna had been used. Our current practice includes using a larger cancellous graft from the iliac crest to reinforce a comminuted metaphysis in such a patient.

The degree of intra-articular incongruity that was present when the fracture healed had a major bearing on the final outcome. In four fractures, a two-millimeter incongruity still was present despite open reduction. All of these fractures were type C3 preoperatively. Three of the four

TABLE IV  
MODIFIED CLINICAL-SCORING SYSTEM OF GREEN AND O'BRIEN\*

Category	Score (Points)	Findings
Pain (25 points)	25	None
	20	Mild, occasional
	15	Moderate, tolerable
	10	Severe or intolerable
	0	
Functional status (25 points)	25	Returned to regular employment
	20	Restricted employment
	15	Able to work but unemployed
	0	Unable to work because of pain
Range of motion (25 points)		Percentage of normal
	25	100
	15	75-99
	10	50-74
	5	25-49
	0	0-24
		Dorsiflexion-plantar flexion arc (injured hand only)
	25	120° or more
	15	91°-119°
	10	61°-90°
5	31°-60°	
0	30° or less	
Grip strength (25 points)		Percentage of normal
	25	100
	15	75-99
	10	50-74
	5	25-49
0	0-24	
Final result		
	Excellent	90-100
	Good	80-89
	Fair	65-79
Poor	<65	

\* From Cooney et al.

TABLE V  
 DEMERIT-POINT SYSTEM OF GARTLAND AND WERLEY

Category	Points
Residual deformity (range, 0 to 3 points)	
Prominent ulnar styloid process	1
Residual dorsal tilt	2
Radial deviation of hand	2 or 3
Subjective evaluation (range, 0 to 6 points)	
Excellent: no pain, disability, or limitation of motion	0
Good: occasional pain, slight limitation of motion, and no disability	2
Fair: occasional pain, some limitation of motion, feeling of weakness in wrist, no particular disability if careful, and activities slightly restricted	4
Poor: pain, limitation of motion, disability, and activities more or less markedly restricted	6
Objective evaluation* (range, 0 to 5 points)	
Loss of dorsiflexion	5
Loss of ulnar deviation	3
Loss of supination	2
Loss of palmar flexion	1
Loss of radial deviation	1
Loss of circumduction	1
Pain in distal radio-ulnar joint	1
Grip strength 60% or less than on opposite side	1
Loss of pronation	2
Complications (range, 0 to 5 points)	
Arthritic changes	
Slight	1
Slight, with pain	3
Moderate	2
Moderate, with pain	4
Severe	3
Severe, with pain	5
Nerve complications (median)	1 to 3
Poor function of fingers due to cast	1 or 2
Final result (ranges of points)	
Excellent	0 to 2
Good	3 to 8
Fair	9 to 20
Poor	≥21

\* The objective evaluation is based on the following ranges of motion as being the minimum for normal function: dorsiflexion, 45 degrees; palmar flexion, 30 degrees; radial deviation, 15 degrees; ulnar deviation, 15 degrees; pronation, 50 degrees; and supination, 50 degrees.

fractures that had a postoperative articular incongruity of two millimeters or more had only a fair result at the most recent evaluation, and they accounted for all of the fair results by the scoring system of Gartland and Werley (Table II). As might be expected, the presence of intra-articular incongruity was an important factor in the development of degenerative arthritis in these patients. Only one of the twelve patients who had grade-0 or grade-1 incongruity after reduction had appreciable radiographic evidence of arthritis (grade 2 or worse), whereas the four patients who had grade-2 or grade-3 incongruity after reduction all had major arthritis ( $r = 0.849$ ,  $p < 0.001$ ) (Fig. 3).

Post-traumatic arthritis of grade 2 or worse, as determined from the radiographs, had an adverse effect on the final result. The mean modified Green and O'Brien score (86.8 points) for the patients who had grade-0 or grade-1 arthritis was significantly higher ( $p < 0.01$ ) than the mean score (72.9 points) for the patients who had grade-2 or grade-3 arthritis.

The complications of surgical treatment in this series were usually minor. Two patients had a pin-tract infection

related to Kirschner wires, one of whom needed to be hospitalized for débridement and for administration of intravenous antibiotics; the other one needed only removal of the pin. A third patient had a superficial wound infection after plate fixation. There were no documented infections at the site of an external fixator pin, but one patient had a broken Crowe pin, the remnant of which was not retrieved because it was solidly fixed in bone. Two patients complained of problems with the plate; one patient had the plate removed one year postoperatively because of pain and the other, although complaining that the plate interfered with dorsiflexion and was cosmetically objectionable, refused an additional operation. One patient (Case 16, Table II) had a painful ununited ulnar styloid process. Although an attempt at open reduction and internal fixation with cerclage wire did not result in osseous union, she stated that the symptoms resolved after treatment.

#### Discussion

The results of this study support the concept that open reduction and internal fixation of a displaced, comminuted

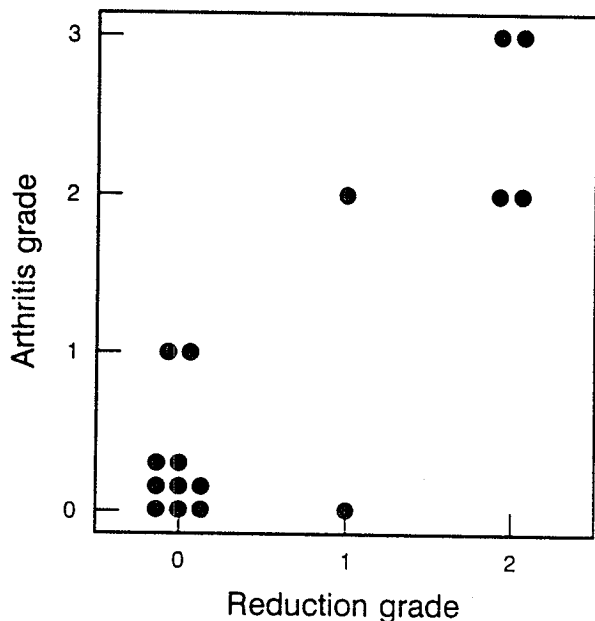


FIG. 3

Grade of arthritis correlated with incongruity of the radial surface at the time of reduction. Each dot represents one patient.

intra-articular fracture of the distal end of the radius is the treatment of choice when alignment of the articular surface cannot be obtained by closed means. It is our opinion that for all such fractures, regardless of their eponymous designation, anatomical restoration of the articular surface is required to prevent the sequela of post-traumatic arthritis. Age and its attendant osteoporosis may prevent achievement of this goal in some patients. Four of the five women in our series who were older than fifty years had only a fair result, and major arthritic changes were noted at follow-up in two of them.

The distinctions that are created by eponyms seem to be artificial when the anatomy of the fracture is closely inspected; the so-called die-punch fragment that is common to a Colles fracture may have a comminuted dorsal-rim fragment that is typical of a dorsal Barton fracture, and a severely comminuted fracture may have components that are more typically associated with both a dorsal and a palmar Barton fracture as well as with a Colles fracture. Such eponyms often give little clue, then, as to the proper treatment of a specific fracture. This is especially true of the broad spectrum of injuries included under the Colles eponym. Factors such as the size, number, and location of articular fracture fragments may be more important prognostically.

There was a difference in the final results between the two scoring systems, but this was not unexpected. The modified system of Green and O'Brien<sup>10</sup> is extremely stringent with respect to the final motion and strength that are needed to achieve an excellent or good result, but it does not take into account radiographic changes. The rating system of Gartland and Werley is far less demanding as to the motion and strength that are needed to achieve a good or excellent result; arthritic changes and deformity are considered, and subjective factors are given more weight. Even when the

stricter modified system of Green and O'Brien was used, however, the percentages of good and excellent results still compared favorably with those that have been reported for other series<sup>1,15,16,18,24-26</sup>.

The worst results in this series tended to be in patients who had the most comminuted fractures, which had resulted from high-energy injury. The prognosis was directly related to the surgeon's ability to reconstruct a congruent distal radial articular surface. There was a striking relationship between the amount of intra-articular incongruity that was present when the fracture united and the later development of post-traumatic arthritis. All of the fractures that healed with a step-off of two millimeters or more had major degenerative changes, as was predicted by Knirk and Jupiter.

Although older age of the patient did not preclude a good or excellent result by either scoring system, satisfactory reduction and stable fixation may be more difficult to achieve in patients who are older than fifty years; four of the seven patients who were more than fifty years old had postoperative incongruity, as compared with two of the nine patients who were younger than fifty. Only two of the seven patients who were older than fifty years had a good or excellent result, as compared with seven good or excellent results in the nine patients who were younger than fifty.

There have been only a few reports on the results of treatment of intra-articular fractures of the distal end of the radius by open reduction and internal fixation. Bassett suggested that displaced intra-articular fractures of the distal end of the radius need anatomical reduction and fixation, and that open treatment can lead to an excellent result if the reduction is anatomical; however, no data on the patients were provided on which to base this conclusion. Melone reported on fifteen patients who had a severely displaced intra-articular fracture of the distal end of the radius that was treated by open reduction and internal fixation, mainly with Kirschner wires. At an average follow-up of almost four years, 80 per cent of the fractures were graded as excellent or good by clinical criteria. Fourteen patients had evidence of articular injury on the radiographs, but the amount of incongruity was not specifically noted, and comparison of the radiographic and clinical results was not discussed.

Knirk and Jupiter reported on three patients who had an intra-articular fracture of the distal end of the radius that was treated with open reduction and internal fixation, all three of whom had a good result by the criteria of Gartland and Werley. This was in striking contrast to the twenty-four patients in whom intra-articular incongruity was not corrected, of whom only ten had a satisfactory clinical result and twenty-two had radiographic evidence of arthritis at follow-up.

On the basis of our experience, we agree with Knirk and Jupiter that patients who have a fracture of the distal end of the radius that has an intra-articular incongruity of two millimeters or more that persists or recurs after closed or percutaneous treatment are at higher risk for post-traumatic arthritis than are those who have no incongruity. Pa-



tients who have such a fracture should be considered candidates for open reduction and some form of internal or combined internal and external fixation. Bone-grafting may be necessary in some severely comminuted fractures in order to provide structural support to the articular surface. External fixation is helpful in neutralizing compressive loading across the wrist, especially in very comminuted fractures.

Such neutralization is useful intraoperatively for reducing articular fragments and postoperatively when the small size of the fragments precludes stable reduction by internal fixation alone. In some severely injured patients and in older patients, reduction of the intra-articular incongruity may be difficult or impossible. These patients should be informed of the risk of post-traumatic arthritis.

### References

1. BACORN, R. W., and KURTZKE, J. F.: Colles' Fracture. A Study of Two Thousand Cases from the New York State Workmen's Compensation Board. *J. Bone and Joint Surg.*, **35-A**: 643-658, July 1953.
2. BASSETT, R. L.: Displaced Intraarticular Fractures of the Distal Radius. *Clin. Orthop.*, **214**: 148-152, 1987.
3. BRUMFIELD, R. H., and CHAMPOUX, J. A.: A Biomechanical Study of Normal Functional Wrist Motion. *Clin. Orthop.*, **187**: 23-25, 1984.
4. CHAPMAN, D. R.; BENNETT, J. B.; BRYAN, W. J.; and TULLOS, H. S.: Complications of Distal Radial Fractures: Pins and Plaster Treatment. *J. Hand Surg.*, **7**: 509-512, 1982.
5. COLE, J. M., and OBLETZ, B. E.: Comminuted Fractures of the Distal End of the Radius Treated by Skeletal Transfixion in Plaster Cast. An End-Result Study of Thirty-three Cases. *J. Bone and Joint Surg.*, **48-A**: 931-945, July 1966.
6. COLLES, A.: On the Fracture of the Carpal Extremity of the Radius. *Edinburgh Med. and Surg. J.*, **10**: 182-186, 1814.
7. COONEY, W. P.: External Fixation of Distal Radial Fractures. *Clin. Orthop.*, **180**: 44-49, 1982.
8. COONEY, W. P., III; DOBYNS, J. H.; and LINSCHIED, R. L.: Complications of Colles' Fractures. *J. Bone and Joint Surg.*, **62-A**: 613-619, June 1980.
9. COONEY, W. P., III; LINSCHIED, R. L.; and DOBYNS, J. H.: External Pin Fixation for Unstable Colles' Fractures. *J. Bone and Joint Surg.*, **61-A**: 840-845, Sept. 1979.
10. COONEY, W. P.; BUSSEY, R.; DOBYNS, J. H.; and LINSCHIED, R. L.: Difficult Wrist Fractures. Perilunate Fracture-Dislocations of the Wrist. *Clin. Orthop.*, **214**: 136-147, 1987.
11. DE OLIVEIRA, J. C.: Barton's Fractures. *J. Bone and Joint Surg.*, **55-A**: 586-594, April 1973.
12. DOBYNS, J. H., and LINSCHIED, R. L.: Complications of Treatment of Fractures and Dislocations of the Wrist. *In Complications in Orthopaedic Surgery*, edited by C. H. Epps, Jr. Ed. 2, vol. 1, pp. 339-352. Philadelphia, J. B. Lippincott, 1978.
13. DOBYNS, J. H., and LINSCHIED, R. L.: Fractures and Dislocations of the Wrist. *In Fractures in Adults*, edited by C. A. Rockwood, Jr., and D. P. Green. Ed. 2, vol. 1, pp. 411-509. Philadelphia, J. B. Lippincott, 1984.
14. ELLIS, JAMES: Smith's and Barton's Fractures. A Method of Treatment. *J. Bone and Joint Surg.*, **47-B(4)**: 724-727, 1965.
15. FRYKMAN, GÖSTA: Fracture of the Distal Radius Including Sequelae — Shoulder-Hand-Finger Syndrome, Disturbance in the Distal Radio-Ulnar Joint and Impairment of Nerve Function. A Clinical and Experimental Study. *Acta Orthop. Scandinavica, Supplementum* 108, 1967.
16. GARTLAND, J. J., JR., and WERLEY, C. W.: Evaluation of Healed Colles' Fractures. *J. Bone and Joint Surg.*, **33-A**: 895-907, Oct. 1951.
17. GRANA, W. A., and KOPTA, J. A.: The Roger Anderson Device in the Treatment of Fractures of the Distal End of the Radius. *J. Bone and Joint Surg.*, **61-A**: 1234-1238, Dec. 1979.
18. GREEN, D. P.: Pins and Plaster Treatment of Comminuted Fractures of the Distal End of the Radius. *J. Bone and Joint Surg.*, **57-A**: 304-310, April 1975.
19. GREEN, D. P., and O'BRIEN, E. T.: Open Reduction of Carpal Dislocations: Indications and Operative Techniques. *J. Hand Surg.*, **3**: 250-265, 1978.
20. HUBBARD, L. F.: Fractures of the Hand and Wrist. *In Surgery of the Musculoskeletal System*, edited by C. McC. Evarts. Vol. 1, pp. 2:85-2:90. New York, Churchill Livingstone, 1983.
21. KNIRK, J. L., and JUPITER, J. B.: Intra-Articular Fractures of the Distal End of the Radius in Young Adults. *J. Bone and Joint Surg.*, **68-A**: 647-659, June 1986.
22. MELONE, C. P., JR.: Open Treatment for Displaced Articular Fractures of the Distal Radius. *Clin. Orthop.*, **202**: 103-111, 1986.
23. MÜLLER, M. E.; NAZARIAN, S.; and KOCH, P.: Classification AO der fracturen. Berlin, Springer, 1987.
24. SARMIENTO, AUGUSTO; PRATT, G. W.; BERRY, N. C.; and SINCLAIR, W. F.: Colles' Fractures. Functional Bracing in Supination. *J. Bone and Joint Surg.*, **57-A**: 311-317, April 1975.
25. SCHECK, MAX: Long-Term Follow-up of Treatment of Comminuted Fractures of the Distal End of the Radius by Transfixation with Kirschner Wires and Cast. *J. Bone and Joint Surg.*, **44-A**: 337-351, March 1962.
26. STEIN, A. H., JR., and KATZ, S. F.: Stabilization of Comminuted Fractures of the Distal Inch of the Radius: Percutaneous Pinning. *Clin. Orthop.*, **108**: 174-181, 1975.