

This is an Open Access article licensed under the terms of the Creative Commons Attribution-NonCommercial-NoDerivs 3.0 License ([www.karger.com/OA-license](http://www.karger.com/OA-license)), applicable to the online version of the article only. Distribution for non-commercial purposes only.

# Optic Nerve Sheath Meningioma in the First Decade of Life: Case Report and Review of the Literature

Mário L.R. Monteiro<sup>a</sup> Allan Christian P. Gonçalves<sup>a</sup>  
Sheila Aparecida C. Siqueira<sup>b</sup> Eloísa M.M. Gebrim<sup>c</sup>

<sup>a</sup>Division of Ophthalmology and Departments of <sup>b</sup>Pathology and <sup>c</sup>Radiology, University of São Paulo Medical School, São Paulo, Brazil

## Key Words

Optic nerve neoplasms · Benign optic nerve sheath neoplasm · Meningioma

## Abstract

**Background/Aim:** Tumors of the optic nerve are mostly either optic nerve gliomas or optic nerve sheath meningiomas (ONSMs). While gliomas occur in children, most meningiomas are slow-growing tumors affecting middle-aged individuals with progressive visual loss, proptosis, disc edema and optociliary veins on fundus examination. ONSMs are extremely rare in children, with only 14 cases reported in children under the age of 10 years. The purpose of this study is to describe an additional case and review clinical, radiologic and histopathological findings that can help differentiate such tumors in children and allow an early and accurate diagnosis.

**Case Report:** An 8-year-old girl had a 2-year history of progressive proptosis and total visual loss on the right side. A computed tomography scan revealed a well-defined intraconal mass with perioptic calcification. Magnetic resonance imaging showed a tumor surrounding the optic nerve and extending intracranially, with enhancement following gadolinium injection. The patient was submitted to fronto-orbital craniotomy for complete tumor excision. Histological studies identified the neoplasm as ONSM.

**Conclusions:** Though unusual, ONSMs may occur in children and, in these cases, present a much more aggressive behavior than in adults. ONSM should therefore be differentiated from optic glioma in children because of its aggressive behavior and need for different treatment modalities.

## Introduction

Tumors of the optic nerve represent approximately 4% of orbital tumors and can occur at any age [1, 2]. Although uncommon tumors such as hemangiopericytomas and medulloepitheliomas are occasionally reported, the great majority are either optic nerve gliomas or optic nerve sheath meningiomas (ONSMs). While gliomas usually occur in children, most ONSMs are slow-growing tumors affecting middle-aged persons with progressive visual loss, proptosis, disc edema and optociliary veins on fundus examination [1].

ONSMs are extremely rare in children; in fact, only 14 cases have been reported in children under the age of 10 years [3–9]. The purpose of this paper was to document the case of a young girl with a rapidly growing ONSM, review clinical findings from similar cases in the literature and stress the importance of early diagnosis in children affected with this aggressive neoplasm.

## Case Report

An 8-year-old girl was referred to our institute with a 2-year history of progressive proptosis, intermittent mild pain and periorbital edema in her right eye (OD). The patient had suffered a penetrating eye injury 3 months prior to the onset of proptosis, resulting in complete visual loss in the injured eye. On examination, visual acuity was no light perception in OD and 20/20 in the left eye (OS). Exophthalmometric measurements were 29 mm for OD and 15 mm for OS. The pupil was 1 mm larger in OD than in OS, and an absolute afferent papillary defect was observed in OD. The extraocular motility examination showed moderate restriction on upgaze. The slit-lamp examination of OD yielded findings (corneal scar, inferiorly deviated pupil and moderate cataract) presumably related to the reported penetrating eye injury. The fundus examination revealed optic disc pallor in OD and normal findings in OS.

An orbital computerized tomography (CT) scan revealed a globular intraorbital mass with linear calcification surrounding the right optic nerve (fig. 1). The mass appeared to originate in the optic nerve sheath and extended intracranially through an enlarged optic canal. In addition, the lesser wing of the sphenoid bone was thickened. The mass showed homogeneous enhancement after iodine contrast injection. Magnetic resonance (MR) imaging disclosed an isointense mass surrounding the right optic nerve, with marked gadolinium enhancement on both T<sub>1</sub>- and T<sub>2</sub>-weighted images. The intracranial involvement was well demonstrated on MR sequences, with an 'en plaque' involvement of the meninges and a dural tail sign lining the right lesser wing (fig. 2).

The patient was submitted to total resection of the lesion via right fronto-orbital craniotomy. Intraoperatively, the tumor was observed to extend into the right cavernous sinus and lesser sphenoid wing. Postoperatively, the patient developed a complete right third cranial nerve palsy. On sectioning, grossly, the specimen consisted of multiple pink-to-brown fragments weighing 13 g and measuring approximately 6.0 × 5.0 × 2.0 cm. A microscopic examination of the tumor revealed oval nuclei, rare mitotic figures and a transitional pattern with oval cells arranged in whorls, resulting in centralized hyalinization and deposition of calcium salts (psammoma bodies). The immunohistochemical analysis evidenced a diffuse pattern of progesterone receptor reactivity. The cytoplasmic expression of vimentin and EMA confirmed the diagnosis of meningioma. The Ki-67 labeling index was less than 4% and the beclin-2 labeling index was negative (fig. 3).

## Discussion

ONSMs are tumors of the anterior optic pathway typically affecting adults. When ONSMs occur in children, they are easily mistaken for more commonly observed

neoplasms such as childhood optic nerve gliomas. Despite the extensive literature on the subject, there is still considerable controversy regarding the natural history of these tumors and their appropriate management. Loss of vision and progressive proptosis are the two most common symptoms, present in the vast majority of patients. Whether proptosis or visual dysfunction is the initial complaint probably depends on the site of the original tumor. However, there appears to be no unequivocal set of clinical criteria for distinguishing ONSM from optic nerve glioma in children.

Walsh [3] was the first to suggest that primary orbital meningiomas are more aggressive in children than in older adults, a hypothesis which was confirmed by other authors [4, 10]. Children generally present a greater optic canal, sphenoid wing and/or intracranial involvement on presentation as well as occasionally bilateral optic nerve involvement, recurrence after treatment and even intraocular extension [11, 12]. Although our patient had lost visual function on the right side due to a previous penetrating eye injury, the aggressive behavior of the tumor – extending into the optic canal and cavernous sinus – required subtotal resection of the optic nerve.

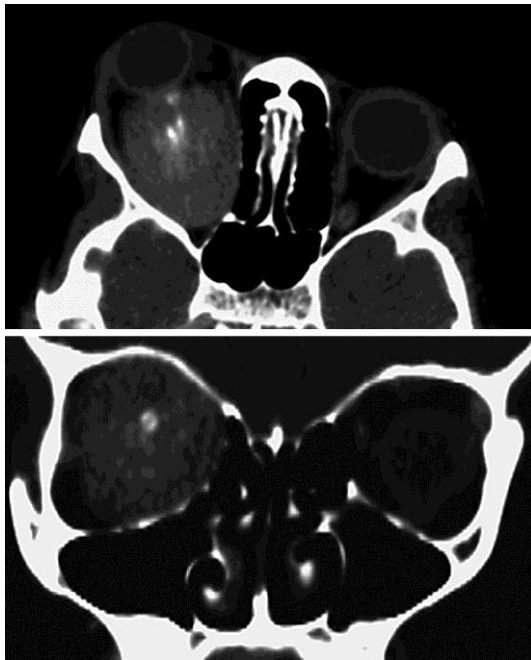The differentiation between ONSM and optic glioma is of crucial importance, especially in pediatric patients. Childhood optic nerve gliomas can often be managed conservatively while the more aggressive and invasive meningiomas should be removed as early as possible. Fortunately, advances in neuroimaging have facilitated differential diagnosis, in most cases obviating the need for tissue biopsy [1]. In the current case, the presence of calcium deposition around the optic nerve disclosed on CT images (fig. 1) was an important indication for the correct diagnosis of optic nerve meningioma since calcifications are not described in optic nerve gliomas and occur frequently in optic nerve meningiomas [1, 7]. Furthermore, the dural extension of the tumor, best shown on coronal post-contrast MR images in our case (fig. 2), strongly indicated the correct diagnosis of optic nerve meningioma since it is not observed in optic gliomas which are usually restricted to the optic pathway.

In the present case, we evaluated tumor behavior by quantifying the markers of cell proliferation and apoptosis (Ki-67 and beclin-2, respectively). Many studies have found a correlation between clinical outcome and the Ki-67 proliferative index, reporting labeling indexes of 0.7–2.2% for benign meningiomas, 2.1–9.3% for atypical meningiomas and 11.0–16.3% for anaplastic meningiomas [13, 14]. In a study correlating the Ki-67 index with the WHO tumor classification, 1% was found to be grade I, 4% grade II and 9.3% grade III [15]. Our patient had a Ki-67 index of less than 4%, classifying the tumor as an atypical meningioma or as WHO grade I. The relationship between tumor grading and beclin-2 expression is not clear. The abnormal expression of beclin-2 observed in patients with meningioma suggests inhibition of apoptosis, but further studies are necessary to confirm this hypothesis. Though aggressive, the tumor of our patient did not express the beclin-2 marker.

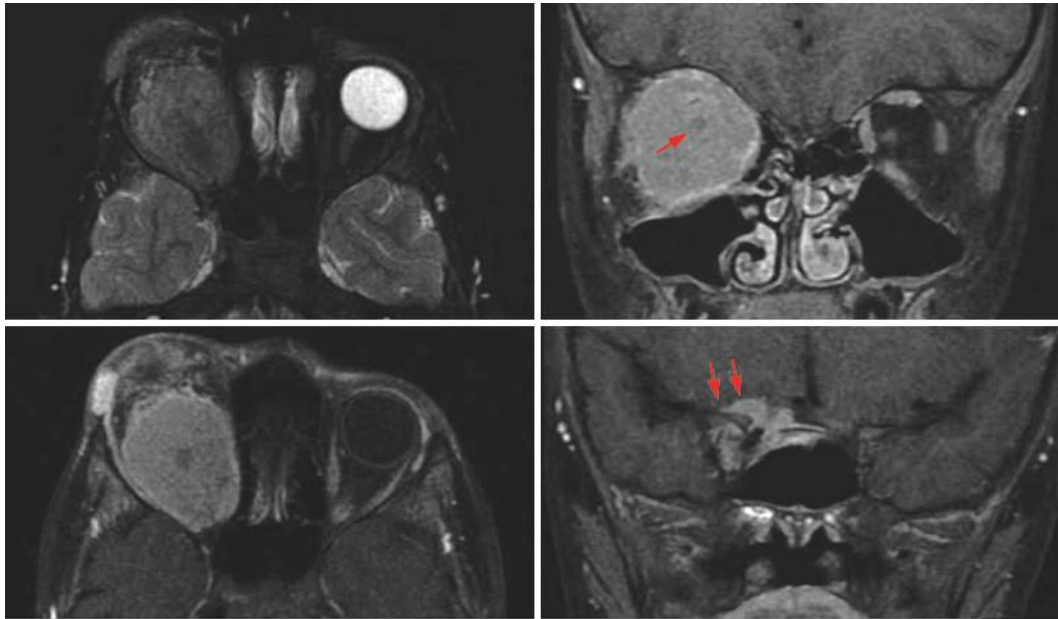
In conclusion, the present case serves as a reminder that ONSM may occur in the first decade of life and tends to manifest a particularly aggressive behavior in pediatric patients, along with an increased risk for progressive visual dysfunction and intracranial extension. We therefore suggest ONSM be included in the differential diagnosis of childhood optic nerve tumors with a view to early diagnosis and appropriate treatment.

### Disclosure Statement

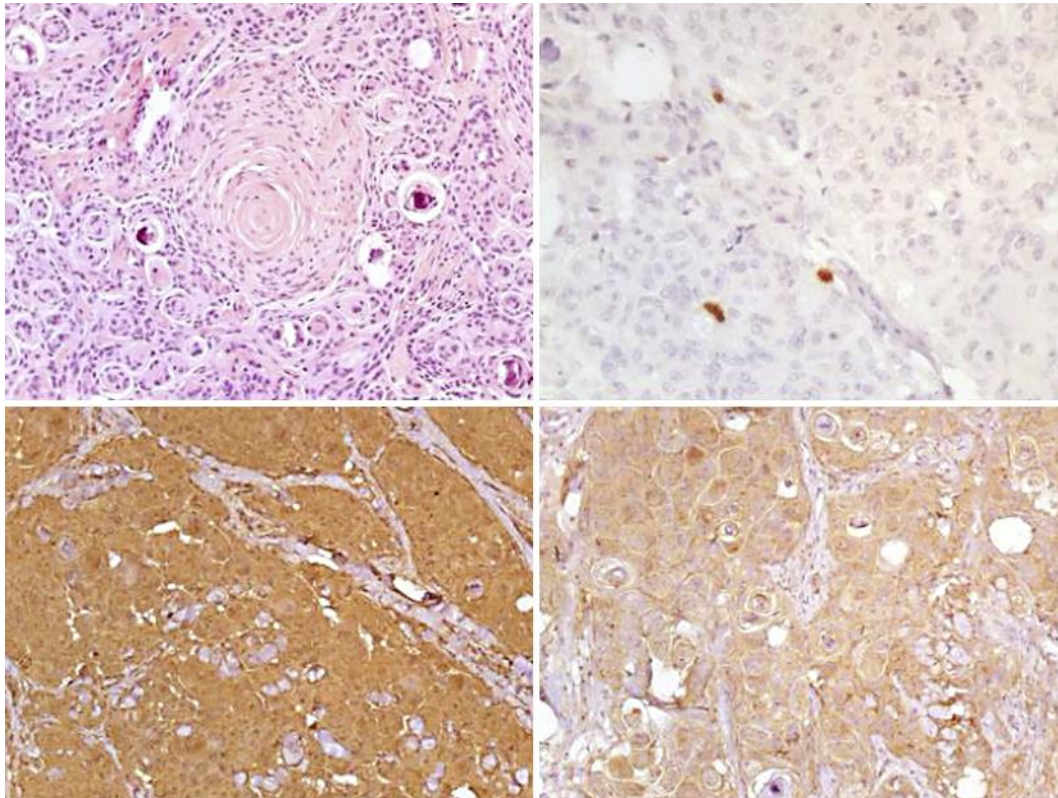
The authors have no conflict of interest related to this paper.



**Fig. 1.** CT scan of an ONSM in an 8-year-old patient. Pre-contrast axial cut (above) and post-contrast coronal cut (below) showing an intraconal well-defined lesion with several patches of linear calcification surrounding the optic nerve.



**Fig. 2.** MR scan of an ONSM in an 8-year-old patient. Left: T<sub>2</sub>-weighted, fat-suppressed (above) and T<sub>1</sub>-weighted, fat-suppressed and gadolinium-enhanced (below) axial cuts showing bulbous enlargement of the optic nerve. The mass appears iso-/hyperintense in relation to the brain tissue in T<sub>1</sub>- and T<sub>2</sub>-weighted images and reveals marked enhancement following gadolinium injection. Right: T<sub>1</sub>-weighted, fat-suppressed and gadolinium-enhanced coronal cuts through the orbit (above) showing a bulbous tumor surrounding the optic nerve (arrow), and at the level of the anterior clinoid process (below) with a dural tail sign suggestive of intracranial tumor extension (arrows).



**Fig. 3.** Histopathological study of an ONSM in an 8-year-old patient. Upper left: oval nuclei, rare mitotic figures and a transitional pattern with oval cells arranged in whorls resulting in centralization and deposition of calcium salts (psammoma bodies) (HE,  $\times 200$  magnification). Upper right: nuclear Ki-67 immunoreactivity with a staining index of less than 4% (streptavidin-biotin peroxidase,  $\times 400$  magnification). Lower row: immunohistochemical staining of meningioma cells with cytoplasmic expression of vimentin (left) and EMA (right) ( $\times 200$  magnification).

## References

- 1 Dutton JJ: Optic nerve sheath meningiomas. *Surv Ophthalmol* 1992;37:167–183.
- 2 Imes RK, Schatz H, Hoyt WF, Monteiro ML, Narahara M: Evolution of optic chiasm meningioma. *Arch Ophthalmol* 1985;103:59–60.
- 3 Walsh FB: Meningiomas, primary within the orbit and optic canal; in *Neuro-ophthalmology Symposium of the University of Miami and the Bascom Palmer Eye Institute*, St. Louis, CV Mosby Co, 1970, pp 240–266.
- 4 Karp LA, Zimmerman LE, Borit A, Spencer W: Primary intraorbital meningiomas. *Arch Ophthalmol* 1974;91:24–28.
- 5 Ito M, Ishizawa A, Miyaoka M, Sato K, Ishii S: Intraorbital meningiomas. Surgical management and role of radiation therapy. *Surg Neurol* 1988;29:448–453.
- 6 Kuroda R, Nakatani J, Yorimae A, Nakao Y, Ohtori T: Clinical experience of intraorbital optic nerve sheath meningioma – report of eight cases. *Neurol Med Chir (Tokyo)* 1990;30:468–475.
- 7 Saeed P, Rootman J, Nugent RA, White VA, Mackenzie IR, Koornneef L: Optic nerve sheath meningiomas. *Ophthalmology* 2003;110:2019–2030.
- 8 Baumert BG, Villa S, Studer G, Mirimanoff RO, Davis JB, Landau K, Ducrey N, Arruga J, Lambin P, Pica A: Early improvements in vision after fractionated stereotactic radiotherapy for primary optic nerve sheath meningioma. *Radiother Oncol* 2004;72:169–174.

- 9 Harold Lee HB, Garrity JA, Cameron JD, Strianese D, Bonavolonta G, Patrinely JR: Primary optic nerve sheath meningioma in children. *Surv Ophthalmol* 2008;53:543–558.
- 10 Alper MG: Management of primary optic nerve meningiomas. Current status – therapy in controversy. *J Clin Neuroophthalmol* 1981;1:101–117.
- 11 Amoli FA, Mehrabani PM, Tari AS: Aggressive orbital optic nerve meningioma with benign microscopic features: a case report. *Orbit* 2007;26:271–274.
- 12 Cibis GW, Whittaker CK, Wood WE: Intraocular extension of optic nerve meningioma in a case of neurofibromatosis. *Arch Ophthalmol* 1985;103:404–406.
- 13 Maiuri F, De Caro MB, Esposito F, Cappabianca P, Strazzullo V, Pettinato G, de Divitiis E: Recurrences of meningiomas: predictive value of pathological features and hormonal and growth factors. *J Neurooncol* 2007;82:63–68.
- 14 Oliveri CV, Wylen EL, Brown MS, Horenstein MG: Pathologic quiz case: a 3-year-old girl with proptosis and rapid visual loss. Primary optic nerve meningioma. *Arch Pathol Lab Med* 2003;127:e434–e435.
- 15 Uzum N, Ataoglu GA: Histopathological parameters with Ki-67 and bcl-2 in the prognosis of meningiomas according to WHO 2000 classification. *Tumori* 2008;94:389–397.