

Optic neuropathy associated with dengue fever

S Sanjay^{1,2}, AM Wagle^{1,2} and KG Au Eong^{1,2,3,4,5}

Abstract

Purpose To report a case series of three patients of optic neuropathy associated with dengue fever.

Methods Observational case series.

Results Three patients aged of 19, 31, and 40 years (cases 1, 2, and 3) complained of unilateral blurring of vision within a week of being diagnosed with dengue fever. Their presenting visual acuities were counting fingers in cases 1 and 2, and 6/6 in case 3, with features suggestive of optic neuropathy. Two of the three patients (cases 2 and 3) had bilateral ocular signs. The visual acuity recovered to 6/9 in case 1, worsened to no light perception in case 2, and remained unchanged in case 3.

Conclusions Although spontaneous visual recovery is possible, optic neuropathy associated with dengue fever may result in severe and permanent visual loss.

Eye (2008) 22, 722–724; doi:10.1038/eye.2008.64; published online 14 March 2008

Keywords: dengue fever; ocular manifestations; optic neuropathy; visual loss

Introduction

Ocular manifestations of dengue fever (DF) are uncommon and may include retinal haemorrhage, cotton wool spot, retinal oedema, and retinal vasculitis/sheathing.¹ Optic neuropathy associated with DF is even rarer. We report three clinically and serologically (IgM) confirmed DF patients to highlight this unusual complication.

Case 1

A 19-year-old Chinese woman presented to her local ophthalmologist with blurring of vision in

her left eye 5 days after she was diagnosed to have DF. She had a visual acuity of counting fingers, impaired colour vision, optic disc swelling, and retinal oedema in the left eye. She was diagnosed to have optic neuropathy and was treated conservatively.

Three months later, she sought a second opinion from us for persistent impaired vision in her left eye. By this time, her visual acuity had improved to 6/9 in the left eye with a relative afferent pupillary defect, impaired colour vision, and paracentral scotoma with a normal fundus examination. The right eye was normal. Multifocal electroretinography disclosed a centrocaecal scotoma and pattern visual evoked potential (pVEP) revealed a delayed P100 latency in the left eye suggestive of retinal and concurrent optic nerve dysfunction in the left eye. At her last follow-up 10 months following her DF, she had a visual acuity of 6/9, persistent impaired colour vision, and a paracentral scotoma in the left eye.

Case 2

A 31-year-old Malay man presented with decreased vision in his right eye 1 week after he was diagnosed with DF. His visual acuity was counting fingers in the right eye and 6/6 in the left. Fundus examination disclosed a cotton wool spots and retinal haemorrhage adjacent to fovea in both eyes. The optic disc appeared normal in both eyes. A diagnosis of right retrobulbar optic neuritis and bilateral maculopathy was made.

The patient's vision in the right eye worsened the following day to no light perception with a relative afferent pupillary defect. In view of the profound visual loss, he was treated empirically with intravenous methylprednisolone 1 g for 3 days followed by oral prednisolone 1 mg/kg body weight for 11 days. Visual field examination could not be done in the right eye but showed an enlarged blind spot in the left eye.

¹Department of Ophthalmology and Visual Sciences, Alexandra Hospital, Singapore, Singapore

²Eye Clinic, Jurong Medical Centre, Singapore, Singapore

³Department of Ophthalmology, Yong Loo Lin School of Medicine, National University of Singapore, Singapore, Singapore

⁴Singapore Eye Research Institute, Singapore, Singapore

⁵Department of Ophthalmology, Tan Tock Seng Hospital, Singapore, Singapore

Correspondence: S Sanjay, Department of Ophthalmology and Visual Sciences, Alexandra Hospital, 378, Alexandra Road, Singapore 159964
 Tel: +65 63793741;
 Fax: +65 63793618.
 E-mail: Sanjay_S@alexhosp.com.sg

Received: 27 December 2007

Accepted in revised form: 11 February 2008

Published online: 14 March 2008

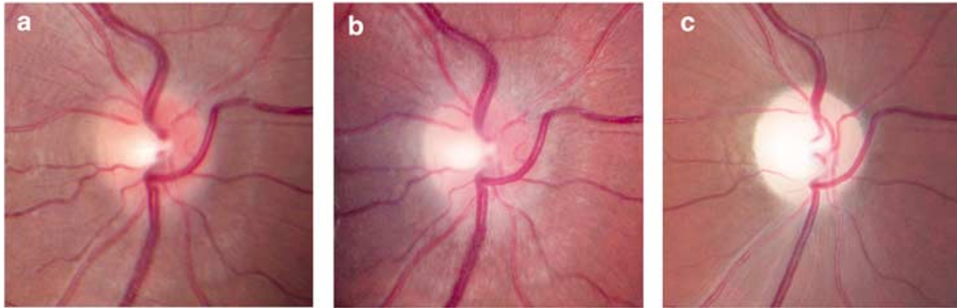


Figure 1 Serial photographs of the right eye in case 2 showing optic disc swelling 3 (a) and 7 (b) days after onset of dengue fever. Optic atrophy is evident 1 month later (c).

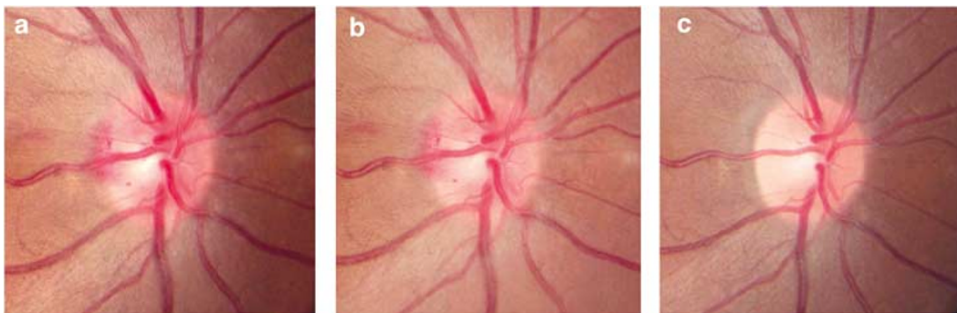


Figure 2 Serial photographs of the right eye in case 3 showing the optic disc 1 (a), 7 (b), and 20 (c) days after onset of dengue fever.

Three days after presentation, optic disc swelling developed in the right eye (Figure 1) and magnetic resonance imaging demonstrated oedema of the optic nerve sheath complex. Pattern electroretinogram revealed a reduced N95:P50 ratio, with no observable response on pVEP in the right eye suggesting severe optic nerve dysfunction. One month later, optic atrophy was seen in the right eye (Figure 1).

The patient's vision in the right eye remained at no light perception 1 year later. This is probably the only case reported in the literature to have developed blindness following DF associated optic neuropathy. The visual field defects in the left eye, however, recovered completely.

Case 3

A 40-year-old Chinese woman presented with blurring of vision in her right eye 5 days after she was diagnosed with DF. Her visual acuity was 6/6 with impaired colour vision in both eyes. Fundus examination disclosed bilateral optic disc oedema with splinter haemorrhages (worse in the right eye), retinal haemorrhages, and cotton wool spots in the macula (Figure 2).

Visual field examination revealed a central scotoma in the right eye and paracentral defects in the left eye. The patient declined electrophysiologic tests.

At her last follow-up 6 weeks later, her visual acuity remained 6/6 bilaterally, colour vision and visual fields were normal, optic disc swelling and haemorrhages had resolved completely.

Discussion

Although rare, DF is known to be associated with a variety of ophthalmic manifestations.¹⁻¹² Optic neuropathy associated with DF is extremely rare and three previously published reports are summarised in Table 1.²⁻⁴ In a recent retrospective series of 41 patients with DF-associated maculopathy, 8 eyes were reported to have disc oedema and 10 eyes had disc hyperaemia.⁵

Optic neuropathy associated with DF is often bilateral. All three previously reported cases had bilateral involvement.²⁻⁴ Although all three patients in our series presented with unilateral visual symptoms, two of them had bilateral involvement. In addition, concurrent macular involvement is common. Two of the three previously reported patients and all patients in this series had concurrent macular signs.^{3,4}

Table 1 Summary of published reports of dengue fever associated optic neuropathy

Author(s)	Age (years)	Sex	Visual acuity at initial presentation	Fundus findings	Intervention	Follow up	Vision at final follow-up
Wen et al ²	Not reported	Not reported	Perception of light in both eyes	Disc oedema in both eyes	High-dose steroids	Not reported	6/12 both eyes
Haritoglou et al ³	25	Female	20/500 in both eyes	Exudative maculopathy, small haemorrhages located in the nerve fiber layer in both eyes	No treatment	8 weeks	6/60 right eye; 6/9.6 left eye
Preechawat and Poonyathalang ⁴	20	Male	Counting fingers in both eyes	Disc hyperaemia in both eyes; flame shaped haemorrhage at fovea in right eye	Intravenous methylprednisolone 250 mg four times per day for 3 days followed by oral prednisolone 60 mg/day tapered over 4 weeks	18 months	6/6 both eyes

The exact mechanism of DF-associated optic neuropathy is currently unknown. It is possible the optic disc inflammation may have an immunogenic origin, and thus empirical treatment with high dose steroid appears reasonable, but should be avoided in the stage of acute viraemia.

The clinical course and prognosis of patients with DF-associated optic neuropathy is variable and may range from improvement in visual function with complete visual recovery to optic atrophy and permanent visual loss.

References

- 1 Lim WK, Mathur R, Koh A, Yeoh R, Chee SP. Ocular manifestations of dengue fever. *Ophthalmology* 2004; **111**: 2057–2064.
- 2 Wen KH, Sheu MM, Chung CB, Wang HZ, Chen CW. The ocular fundus findings in dengue fever. [in Chinese]. *Gaoxiong Yi Xue Ke Xue Za Zhi* 1989; **5**: 24–30.
- 3 Haritoglou C, Dotse SD, Rudolph G. A tourist with dengue fever and visual loss. *Lancet* 2002; **360**: 1070.
- 4 Preechawat P, Poonyathalang A. Bilateral optic neuritis after dengue viral infection. *J Neuroophthalmol* 2005; **25**: 51–52.
- 5 Bacsal KE, Chee SP, Cheng CL, Flores JV. Dengue-associated maculopathy. *Arch Ophthalmol* 2007; **125**: 501–510.
- 6 Haritoglou C, Scholz F, Bialasiewicz A, Klauss V. Ocular manifestation in dengue fever. [in German]. *Ophthalmologe* 2000; **97**: 433–436.
- 7 Cruz-Villegas V, Berrocal AM, Davis JL. Bilateral choroidal effusions associated with dengue fever. *Retina* 2003; **23**: 576–578.
- 8 Siqueira RC, Vitral NP, Campos WR, Orefice F, de Moraes Figueiredo LT. Ocular manifestations in dengue fever. *Ocul Immunol Inflamm* 2004; **12**: 323–327.
- 9 Chlebicki MP, Ang B, Barkham T, Laude A. Retinal hemorrhages in 4 patients with dengue fever. *Emerg Infect Dis* 2005; **11**: 770–772.
- 10 Nainiwal S, Garg P, Prakash G, Nainiwal N. Bilateral vitreous hemorrhage associated with dengue fever. *Eye* 2005; **19**: 1012–1013.
- 11 Chan DP, Teoh SC, Tan CS, Nah GK, Rajagopalan R, Prabhakaragupta MK et al. The eye institute dengue-related ophthalmic complications workgroup. Ophthalmic complications of dengue. *Emerg Infect Dis* 2006; **12**: 285–289.
- 12 Mehta S. Ocular lesions in severe dengue hemorrhagic fever (DHF). *J Assoc Physicians India* 2005; **53**: 656–657.