

NEUROLOGY

Optical coherence tomography and disease subtype in multiple sclerosis

M. Pulicken, E. Gordon-Lipkin, L. J. Balcer, E. Frohman, G. Cutter and P. A. Calabresi

Neurology 2007;69;2085-2092

DOI: 10.1212/01.wnl.0000294876.49861.dc

This information is current as of November 26, 2007

The online version of this article, along with updated information and services, is located on the World Wide Web at:

<http://www.neurology.org/cgi/content/full/69/22/2085>

Neurology® is the official journal of the American Academy of Neurology. Published continuously since 1951, it is now a weekly with 48 issues per year. Copyright © 2007 by AAN Enterprises, Inc. All rights reserved. Print ISSN: 0028-3878. Online ISSN: 1526-632X.



Optical coherence tomography and disease subtype in multiple sclerosis

M. Pulicken, MBBS
E. Gordon-Lipkin, BS
L.J. Balcer, MD,
MSCE
E. Frohman, MD, PhD
G. Cutter, PhD
P.A. Calabresi, MD

Address correspondence and
reprint requests to Dr. Peter A.
Calabresi, Pathology Building,
Suite 627, Johns Hopkins
Hospital, 600 N. Wolfe St.,
Baltimore, MD 21287
calabresi@jhmi.edu

ABSTRACT

Objective: To examine retinal nerve fiber layer (RNFL) thickness, macular volumes (MV), and visual acuity in multiple sclerosis (MS) eyes, with and without history of acute optic neuritis (ON).

Methods: RNFL thickness was measured in 326 MS and 94 control eyes using optical coherence tomography (OCT). MV and vision testing were done in a subset of the cohort. MS subtype was classified as relapsing-remitting (RRMS, $n = 135$), primary progressive (PPMS, $n = 12$), and secondary progressive (SPMS, $n = 16$).

Results: MS ON eyes had decreased RNFL thickness ($84.2 \mu\text{m}$) compared to controls ($102.7 \mu\text{m}$) ($p < 0.0001$). Unaffected fellow eyes of MS ON eyes ($93.9 \mu\text{m}$) ($p < 0.01$) and patients with MS with no history of ON ($95.9 \mu\text{m}$) ($p < 0.05$) also had decreased RNFL. RRMS ($94.4 \mu\text{m}$) ($p < 0.001$), PPMS ($88.9 \mu\text{m}$) ($p < 0.01$), and SPMS ($81.8 \mu\text{m}$) ($p < 0.0001$) (adjusted for age and duration of disease) had decreased RNFL compared to controls. There were significant differences in RNFL thickness within quadrants of peripapillary retina comparing relapsing to progressive MS subtypes. MV was decreased in MS ON eyes (6.2 mm^3) ($p < 0.0001$) and SPMS subjects (6.2 mm^3) ($p < 0.05$) compared to controls (6.8 mm^3).

Conclusion: Retinal nerve fiber layer (RNFL) is significantly decreased in multiple sclerosis (MS) optic neuritis (ON) eyes, unaffected fellow eyes of patients with MS ON, and MS eyes not affected by ON in our cohort. Macular volumes (MV) showed a significant decrease in MS ON eyes. Progressive MS cases showed more marked decreases in RNFL and MV than relapsing-remitting MS. OCT is a promising tool to detect subclinical changes in RNFL and MV in patients with MS and should be examined in longitudinal studies as a potential biomarker of retinal pathology in MS.

Neurology® 2007;69:2085-2092

GLOSSARY

EDSS = Expanded Disability Status Scale; **MS** = multiple sclerosis; **MSFC** = MS Functional Composite; **MV** = macular volumes; **OCT** = optical coherence tomography; **ON** = optic neuritis; **PPMS** = primary progressive MS; **RGC** = retinal ganglion cell; **RNFL** = retinal nerve fiber layer; **RRMS** = relapsing-remitting MS; **SPMS** = secondary progressive MS.

Disease burden and progression in patients with multiple sclerosis (MS) has been monitored using standard measures such as MRI,¹ the Expanded Disability Status Scale (EDSS),² and the MS Functional Composite (MSFC).³ However, there remains a need for more specific measures of axonal damage and neuronal loss in MS.

Axonal loss in MS has been well documented in many neuropathologic studies.^{4,5} There is optic disc pallor and a quantifiable loss of retinal nerve fiber layer (RNFL) axons weeks to months after acute optic neuritis (ON).^{6,7}

Optical coherence tomography (OCT) is an established technique used in the setting of glaucoma and other retinal diseases to measure RNFL thickness and macular volume (MV), a measurement that may provide information relating to the size and number of retinal ganglion cell (RGC) bodies. Using the echo-time-delay of low frequency infrared

From the Department of Neurology (M.P., E.G.-L., and P.A.C.), Johns Hopkins University, School of Medicine, Baltimore, MD; Departments of Neurology and Ophthalmology (L.J.B.), University of Pennsylvania School of Medicine, Philadelphia; Departments of Neurology and Ophthalmology (E.F.), University of Texas Southwestern Medical Center, Dallas; and Department of Biostatistics (G.C.), University of Alabama, Birmingham.

Supported by the Nancy Davis Center and NMSS TR 3760-A-3.

Disclosure: The authors report no conflicts of interest.

Table 1 Demographics

	MS cohort	Controls
Subjects	163	47
Age, y, mean \pm SD	41.4 \pm 10.3	34.5 \pm 10.8
M/F, %	20.9/79.1	36./63.8
H/o ON, %	38	0
Mean RNFL, μ m	92.7	102.7
Macular volume, mm ³	6.5	6.8
MS disease	Phenotype, n (%)	Mean duration of disease, y
Relapsing remitting	135 (82.8)	4.2
Primary progressive	12 (7.4)	2.6
Secondary progressive	16 (9.8)	11.7

MS = multiple sclerosis; ON = optic neuritis; RNFL = retinal nerve fiber layer.

light from a low coherence light source, OCT quantitates the thickness of the retinal layers.⁸ Several recent OCT studies have demonstrated RNFL thinning in patients with MS both with and without a history of acute ON.⁹⁻¹²

The relationships between RNFL thickness or MV and disease phenotype in MS have not been examined. Herein, we report the OCT data from our MS cohort, which consisted of 210 subjects imaged in an outpatient Neurology Clinic setting. RNFL was thinner and MV was smaller in progressive patients as compared to RRMS in our cohort.

METHODS Subjects. Adult patients with MS were recruited from The Johns Hopkins MS Center on the day of their visits for routine clinical assessments. MS diagnosis was confirmed by the treating neurologist based on clinical and radiologic criteria for MS.^{13,14} Patients with any coexisting ocular disease were excluded, but otherwise there was no patient selection bias. Patients with an episode of ON less than 6 months prior to the scan were not included in the analyses. Healthy controls were recruited from family members of patients and from staff at the hospital, and people with known ophthalmologic or other neurologic disease were excluded.

All participants were scanned after the informed consent process. The study protocol and consent process were approved by the Johns Hopkins Institutional Review Boards before the enrollment was started.

Our study cohort included 163 patients with MS and 47 controls, who underwent OCT scanning for measurement of RNFL thickness. A subset of the cohort had measurements of total macular volume (90 patients with MS and 38 controls) and vision acuity (148 patients with MS and 32 controls) as these tests were added on later. The demographics of the study cohort are shown in table 1.

Optical coherence tomography. Retinal imaging was done using the OCT-3 with OCT 4.0 software (Carl Zeiss, Meditec, Dublin, CA). OCT imaging generates cross-sectional tomograms of the retina, using low coherence interferometry with axial resolution of less than $\leq 10 \mu$ m. The Fast RNFL Thickness Protocol, which calculates the average of three circumferential scans of diameter 3.4μ m around the optic disc, was used to compute the overall average RNFL for each eye. Each circumferential scan computes the value from the 256 axial scans at the circumference of the 3.4μ m circle. Macular scans were obtained using the Fast Macular Thickness Protocol, by means of six radial lines, through the fovea, in a starburst pattern. The RGC volume is inferred because retinal thickness in the macula is predominantly contributed by RGC bodies. The MV protocol simulates the topography of a likely map based on the measures from the six radial lines.

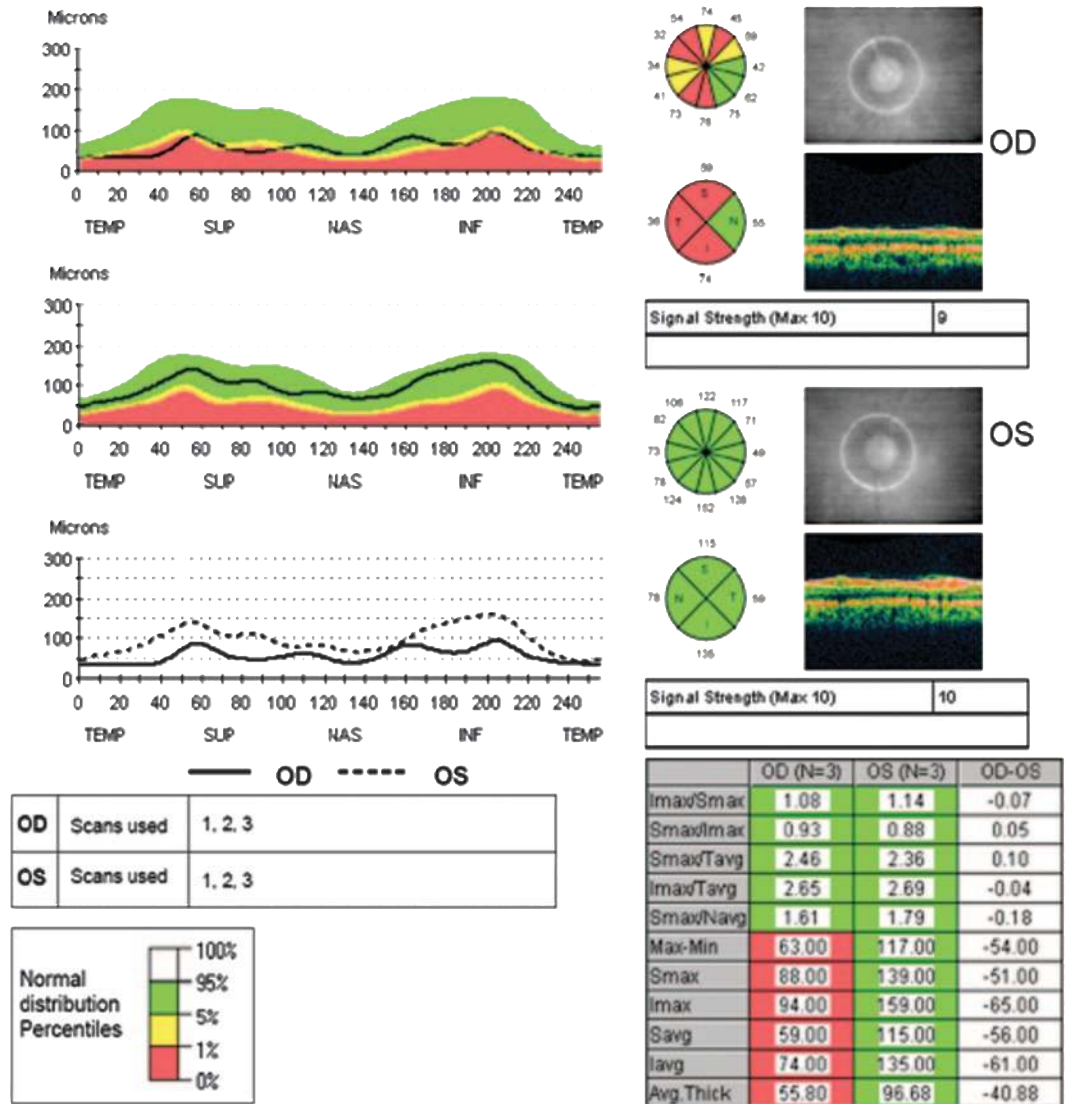
OCT scanning was performed by one of two trained technicians at an outpatient setting at The Johns Hopkins Neurology Department. Because dilation has been shown to have little impact on OCT values and reproducibility,¹⁵ scans were performed without the use of mydriatic eyedrops. The non tested eye was covered with a patch to improve the internal fixation. Only scans with signal strength of 7 or above (max 10), indicating a high-quality scan, was considered acceptable for analysis (rejected one scan with signal strength 6, unrelated to pupil size, and this person was excluded from the study). Fundus photographs were routinely obtained to ensure proper centering of the scan, which is critical for accurate results and reproducibility.

Average RNFL thickness for 360° around the optic disc, and for the superior, nasal, inferior, and temporal quadrants around the optic disc were recorded for each eye of patients and disease-free controls. Total MV for each eye was also recorded in a subset of the patients with MS (180 eyes) and controls (76 eyes) as the testing was added on later.

Visual function tests. Visual function testing was performed in 296 MS eyes and 64 control eyes using low-contrast Sloan letter charts (non-retroilluminated version, Precision Vision, IL) at 2.5% and 1.25% low-contrast levels and at full contrast (100% chart, tests high-contrast visual acuity). All testing was performed monocularly and with both eyes together. If one eye was visually worse, this eye was tested first followed by the better eye; binocular testing was performed last. The results were recorded as the number of letters correctly identified (maximum of 60 letters per chart, each line = 5 letters). Participants were allowed to attempt the letters on a line if they got more than three letters correct on the previous line. Both patients and controls were asked to use their habitual glasses/contact lenses to correct for the testing.

Statistical methods. All analyses were done using the statistical software SAS. Generalized linear models were used for the comparison of different subgroups (MS ON eyes, fellow eyes of patients with a history of unilateral ON, MS eyes with no ON, and controls) and for comparisons between different MS subtypes (RRMS, PPMS, and SPMS). These analyses corrected for the age as well as within-patient, inter-eye correlations between eyes. MS subtype analyses that were corrected for duration of disease used a linear covariate in the generalized linear model regression analyses. SAS Proc Mixed was utilized to make the adjustments to the variances for appropriate testing of differences. No corrections for multiple comparisons were made at the time of testing since

Figure 1 Optical coherence tomography (OCT) data from a patient with the right eye (OD) affected by optic neuritis (ON)



Circle with four quadrants next to optic disc picture of right eye (OD) shows three quadrants (superior [S], temporal [T], and inferior [I]) with retinal nerve fiber layer (RNFL) thicknesses in the (lowest) first percentile for age (red) but the nasal quadrant (N) is normal for age (green). Left eye (OS) has all four quadrants in the green zone. Overall RNFL thickness is shown in the last line of the boxed data with the right eye having an average RNFL of 55.80 showing thinning (red) and left eye 96.68 μm in the normal (green) zone. Graph 3 shows comparison between left (broken line) and right eye (unbroken line) RNFL thickness, with values decreased in all four quadrants for the right eye affected by ON.

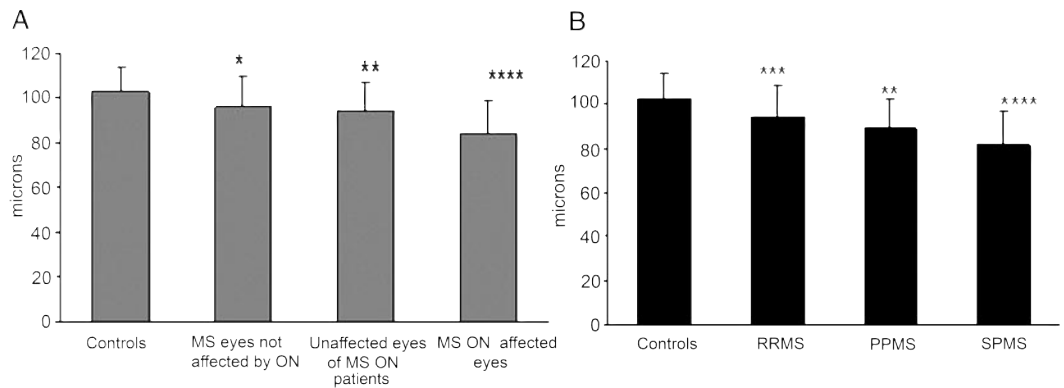
the comparisons among the MS subgroups and comparisons to controls were planned in advance; a type I error of 0.05 was used for significance. We report the *p* values from the analyses which can be used to put the multiple testing issues into context.

RESULTS The average RNFL thickness was reduced ($p < 0.0001$) in MS ON eyes ($84.2 \pm 14.7 \mu\text{m}$) compared to healthy controls ($102.7 \pm 11.5 \mu\text{m}$) (GLM models adjusting for age and within-patient intereye correlations) (representative OCT data shown in figure 1). MS eyes with no history of ON also had decreased RNFL thickness ($95.9 \pm 14 \mu\text{m}$) ($p = 0.04$) compared to controls. Unaffected fellow

eyes of the unilateral MS ON patients showed a decrease in RNFL ($93.9 \pm 13.1 \mu\text{m}$) compared to control eyes ($p < 0.01$) (figure 2A).

We also compared RNFL thickness across the various subtypes of MS. The RRMS group had a mean RNFL thickness ($94.4 \pm 14.6 \mu\text{m}$) which was lower than controls ($102.7 \pm 11.5 \mu\text{m}$) ($p < 0.001$). The progressive subtypes of MS, PPMS and SPMS, showed a more marked decrease in RNFL as compared to controls, with thickness values of ($88.9 \pm 13.3 \mu\text{m}$) and ($81.8 \pm 15.6 \mu\text{m}$) (adjusted for age and duration of disease) (PPMS $p < 0.01$ and SPMS $p < 0.0001$) (figure 2B).

Figure 2 Retinal nerve fiber layer (RNFL) comparisons



(A) RNFL comparisons between controls and multiple sclerosis (MS) subgroups by history of optic neuritis. (B) RNFL comparisons in MS subtypes (y axis is RNFL thickness in microns). *Indicates a significant difference in MS subgroup compared to controls (* $p < 0.05$, ** $p < 0.01$, *** $p < 0.001$, **** $p < 0.0001$).

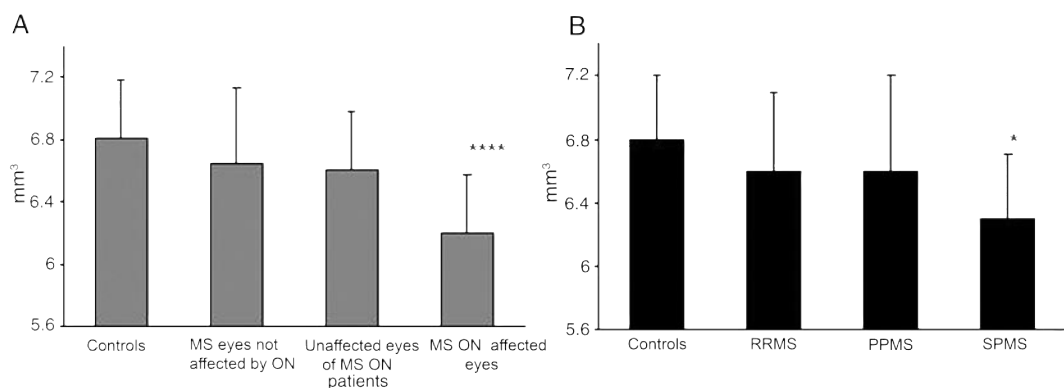
RNFL thicknesses in progressive MS subtypes compared to RRMS (adjusted for age and duration of disease) revealed trends toward thinner RNFL, but these were not significantly different in these small subgroups (RRMS vs PPMS $p = 0.08$ and RRMS vs SPMS $p = 0.11$).

There were significant differences in RNFL thickness within quadrants of peripapillary retina when comparing relapsing to progressive MS subtypes. Patients with RRMS had higher values for thickness in all four quadrants, which was different in the superior ($p = 0.03$) and nasal quadrants ($p = 0.04$) when compared to patients with PPMS. When compared to the SPMS cohort, the RRMS subgroup had higher RNFL thickness in three of the four quadrants (superior $p = 0.005$, inferior $p = 0.004$, and temporal $p = 0.003$) with the nasal quadrant not being significantly different (data not shown).

We next analyzed differences in MV between MS and controls. Healthy controls had a mean MV of $6.8 \pm 0.4 \text{ mm}^3$, and MS ON eyes showed a decreased volume with mean MV of $6.2 \pm 0.4 \text{ mm}^3$ ($p < 0.0001$) (figure 3A) (regardless of whether the eyes were from patients with history of unilateral [one eye] or bilateral [both eyes] ON). MS eyes with no history of ON and unaffected eyes of MS ON patients also showed a decreasing trend in volume compared to controls with values of $6.6 \pm 0.5 \text{ mm}^3$ ($p = 0.06$) and $6.6 \pm 0.4 \text{ mm}^3$ ($p = 0.06$). The MV in MS eyes (all subgroups) had a value of $6.5 \pm 0.5 \text{ mm}^3$ but these values were not significantly different from the control values.

Across the MS subtypes the RRMS showed a mean macular volume of $6.5 \pm 0.5 \text{ mm}^3$, PPMS $6.5 \pm 0.6 \text{ mm}^3$, and SPMS $6.2 \pm 0.4 \text{ mm}^3$ (adjusting for ON, age, and for correlation between eyes within a subject). The decrease seen in the SPMS

Figure 3 Macular volume (MV) comparisons



(A) MV comparisons between controls and multiple sclerosis (MS) subgroups by history of optic neuritis. (B) MV comparisons in MS subtypes (y axis is macular volume in mm^3 ; note truncated y axis). *Indicates a significant difference in MS subgroup compared to controls (* $p < 0.05$, ** $p < 0.01$, *** $p < 0.001$, **** $p < 0.0001$).

Table 2 Retinal nerve fiber layer (RNFL) thickness and visual acuity (VA) in multiple sclerosis (MS) subtypes

	Control (n = 94)	RRMS (n = 270)	PPMS (n = 24)	SPMS (n = 32)
RNFL, μm	102.7	94.4	88.9	81.8
		$p < 0.001$	$p < 0.01$	$p < 0.0001$
Letters correct (max 60)	(n = 64)	(n = 246)	(n = 20)	(n = 30)
VA 100%	56.5	53.4	48.1	45.2
VA 2.5%	36.1	28.5	23.8	24.1
VA 1.25%	13.1	11.6	10.6	8.9

RRMS = relapsing-remitting MS; PPMS = primary progressive MS; SPMS = secondary progressive MS.

subgroup, who had the longest duration of disease (mean average duration 11.7 years), was significantly different from the control population ($p < 0.05$). The PPMS and RRMS subgroups did not show a significant decrease (figure 3B). Macular volumes correlated with the RNFL thickness values ($p < 0.0001$) in the controls and all the MS subgroups.

Visual function tests results are summarized in tables 2 and 3. RNFL thickness was correlated with monocular VA, $r = 0.35$ ($p < 0.001$) for high contrast, $r = 0.39$ ($p < 0.001$) for 2.5% charts, and $r = 0.31$ ($p < 0.001$) for 1.25% charts (figure 4, A through C). We examined the correlation between the temporal sector and VA as compared to the correlations between the superior, inferior, or nasal quadrant and found no differences (data not shown). While these correlation measures do not account for age, duration of disease, or adjust for within-patient intereye correlations, they are consistent with results in other cohorts that have shown significant associations of RNFL thickness and low- and high-contrast acuity using such models (generalized estimating equation models).¹¹

DISCUSSION We confirmed previous reports that the RNFL values in the ON affected and unaffected eyes of patients with MS are significantly reduced as compared to healthy controls.¹⁰ This

has suggested that chronic axon damage can occur in MS eyes distinct from episodes of acute ON. Herein, we extend this observation by showing significant thinning of the RNFL in our cohort of patients with PPMS with no history of any acute attacks, suggesting that subclinical ON can also damage axons in purely progressive forms of MS. Further, the RNFL thinning in both SPMS and PPMS was significantly greater than in RRMS even when adjusting for age and duration of disease, which is consistent with the notion that progressive MS is associated with axonal loss. This could be explained by two possible mechanisms. There could be a microscopic subclinical process of ongoing inflammatory demyelination and axonal damage in progressive MS, which causes chronic demyelination leading to secondary axonal thinning or loss. The other explanation is that the primary pathophysiologic process in MS could be one of neuronal cell death leading to the secondary changes and death of axons. MV data, which provide information about the RGC bodies, may help to discriminate these differing hypotheses.

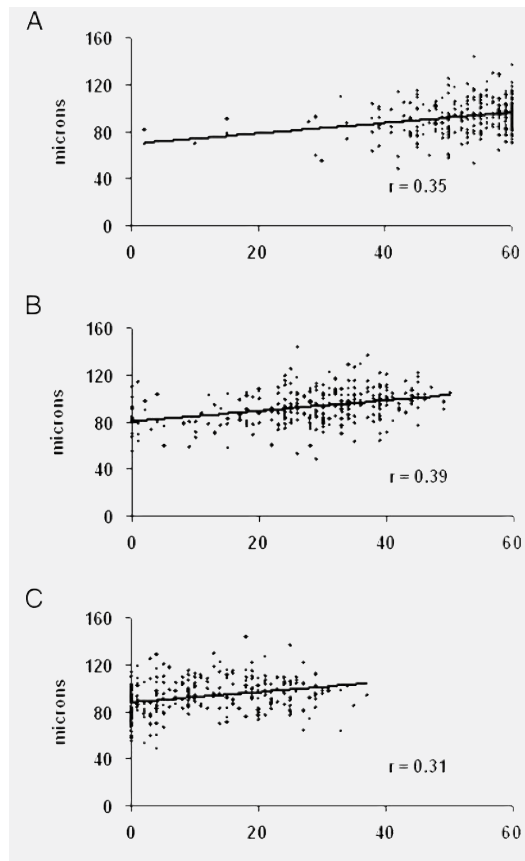
MV measurements were significantly decreased in our unselected MS cohort. Similar changes were reported in a small cohort of 25 patients who failed to normalize vision after an episode of ON.¹¹ When examined by subgroup, only

Table 3 Retinal nerve fiber layer (RNFL) thickness and visual acuity (VA) in multiple sclerosis (MS) subtypes by history of optic neuritis (ON)

	Control (n = 94)	MS eyes with no ON (n = 202)	Unaffected eyes in patients with MS ON (n = 42)	MS ON eyes (n = 82)
RNFL thickness, μm	102.7	95.9	93.9	84.2
		$p < 0.05$	$p < 0.01$	$p < 0.0001$
Letters correct (max 60)	(n = 64)	(n = 184)	(n = 38)	(n = 74)
VA 100%	56.5	53.5	52.3	48.8
VA 2.5%	36.1	30.0	29.0	21.8
VA 1.25%	13.1	12.7	11.7	7.2

x axis = number of letters correct (max = 60) and y axis = RNFL thickness in microns. The correlations seen on all three charts were significant ($p < 0.001$). (A) VA and RNFL correlation on 100% chart, (B) VA and RNFL correlation on 2.5% chart, and (C) VA and RNFL correlation on 1.25% chart.

Figure 4 Correlation between visual acuity (VA) (monocular) and retinal nerve fiber layer (RNFL) thickness



the patients with SPMS, in whom the duration of disease was much longer, had a significant decline in MV as compared to healthy controls. However, the small sample size and short duration of disease in our RRMS and PPMS cohorts likely obscured our ability to show disease dependent changes in these groups. Nonetheless, since all the subgroups had decreased RNFL as compared to controls, these data suggest that the decrease in MV (and possibly RGC loss) only occurs over time and thus may follow RNFL thinning. This suggests the possibility that RGC death may not be the primary event and is more likely secondary to myelin and axon damage in the optic nerve, as has been suggested in animal models.^{16,17} Longitudinal studies of MV and RNFL are necessary to more definitively answer this question. Regardless of the mechanism, this finding is consistent with pathologic reports of neuronal loss in the gray matter of patients with MS and raises the possibility that a similar process might be quantifiable in the macula. However, no OCT-pathologic correlative studies have been done in MS.

The visual acuity tests significantly correlated with the RNFL thickness values, suggesting that

RNFL provides complimentary but not overlapping information related to vision in MS. This provides some face validity to the notion that RNFL measurements are likely to have clinical relevance to patients since worse visual function scores corresponded to lower RNFL thickness scores. While correlations were observed on all charts, the 2.5% charts showed a greater spread than the other charts, in which even the control population patients missed the top (1.25%) and bottom lines (100%). These results are consistent with previously reported studies stressing the importance of vision testing in patients with MS.^{10,18,19} The relatively low r values may relate to imprecision of RNFL measurements and visual acuity testing, but are also consistent with the fact that visual acuity in MS can also be affected by posterior visual pathway pathology and impairment of ocular motility and fixation, which are not measured by OCT. Alternatively, it could be the case that visual acuity is not linearly dependent on the amount of RNFL or RGC loss since some RNFL/RGC loss can occur without affecting the visual acuity.

OCT has been used as a marker of axonal injury in patients with glaucoma.²⁰⁻²² OCT is also proving to be a simple measure in detecting changes in the RNFL and MV, even in patients with no history of ON, and should be examined in longitudinal studies to determine if it could be used as a biomarker in future MS clinical trials.²³

All the testing was done at a neurology outpatient setting and the scanning procedure took less than 5 minutes on average. None of the patients needed to have their pupils dilated, which made it friendlier and noninvasive to the subjects. Our cohort was recruited in as unbiased a fashion as possible with no specific inclusion criteria other than MS.

Limitations of our study include the possibility of recall bias such that patients with remote or mild cases of ON may not have reported them accurately. Since we did not perform VEP as part of this study we cannot definitively rule out the possibility that the RNFL thinning in progressive cases or with no history of ON might be related to alternative disease processes other than optic nerve pathology. Also, there were marked differences in basic demographics in MS subtypes, which is an inevitable part of the cross-sectional study design. In addition, recall bias and inaccurate quantification of recurrent ON attacks as opposed to Uhthoff's phenomenon could have obscured our ability to examine the relationship between attacks and retinal pathology. However, in our experience, patients do tend to accurately recall sustained loss of

visual function. Further, even though the analyses done were adjusted for essential differences, regression values are estimates and could lead to over/underestimation of the effect. The mean RNFL in our study is remarkably similar to a previously published unselected cohort¹⁰ but slightly higher than reports in which patients were selected with ON.^{11,12} Differences in RNFL between quadrants was done without corrections for multiple comparisons and results should not be overemphasized, although similar results have been shown in previous studies.¹⁰

Future studies looking at longitudinal changes will provide valuable data by measuring the rate of change in RNFL and MV in order to better understand the power of this outcome measure in clinical trials of acute ON and in established RRMS or progressive subsets. Our data in PPMS strongly point toward an axon and RGC body degenerative process that is in this subtype independent of clinically recognizable relapses. Although we did not quantify the effect of multiple relapses in SPMS on the OCT measures, these data suggest that future studies in progressive MS subtypes are worthwhile to determine if OCT may be useful as a biomarker of progressive MS-related pathology.

In addition, it is possible that what happens in the eye will reflect similar pathologic changes in the brain as was recently suggested in AD.²⁴ RNFL changes and macular volumes could easily be correlated cross-sectionally with brain volumes as well as specific white and gray matter pathology. Thus, RNFL thinning (axonal damage) in the eye of a patient with acute ON or MS in early stages may reflect the future likelihood of similar axonal pathology occurring in the brain as a result of disseminated cerebral lesions. The simplicity of the OCT and its high sensitivity in picking up changes, which may in part reflect axonal and RGC pathology, make it a potential biomarker in neuroprotective clinical trials and also for monitoring disease-related change in patients with MS.

Received January 25, 2007. Accepted in final form May 25, 2007.

REFERENCES

1. Miller DH, Grossman RI, Reingold SC, McFarland HF. The role of magnetic resonance techniques in understanding and managing multiple sclerosis. *Brain* 1998;121(Pt 1):3–24.
2. Kurtzke JF. Rating neurologic impairment in multiple sclerosis: an expanded disability status scale (EDSS). *Neurology* 1983;33:1444–1452.
3. Rudick R, Antel J, Confavreux C, et al. Recommendations from the National Multiple Sclerosis Society Clinical Outcomes Assessment Task Force. *Ann Neurol* 1997;42:379–382.
4. Trapp BD, Peterson J, Ransohoff RM, et al. Axonal transection in the lesions of multiple sclerosis. *N Engl J Med* 1998;338:278–285.
5. Ferguson B, Matyszak MK, Esiri MM, Perry VH. Axonal damage in acute multiple sclerosis lesions. *Brain* 1997;120(Pt 3):393–399.
6. Kerrison JB, Flynn T, Green WR. Retinal pathologic changes in multiple sclerosis. *Retina* 1994;14:445–451.
7. Trip SA, Schlottmann PG, Jones SJ, et al. Optic nerve atrophy and retinal nerve fibre layer thinning following optic neuritis: evidence that axonal loss is a substrate of MRI-detected atrophy. *Neuroimage* 2006;31:286–293.
8. Chen TC, Cense B, Miller JW, et al. Histologic correlation of in vivo optical coherence tomography images of the human retina. *Am J Ophthalmol* 2006;141:1165–1168.
9. Parisi V, Manni G, Spadaro M, et al. Correlation between morphological and functional retinal impairment in multiple sclerosis patients. *Invest Ophthalmol Vis Sci* 1999;40:2520–2527.
10. Fisher JB, Jacobs DA, Markowitz CE, et al. Relation of visual function to retinal nerve fiber layer thickness in multiple sclerosis. *Ophthalmology* 2006;113:324–332.
11. Trip SA, Schlottmann PG, Jones SJ, et al. Retinal nerve fiber layer axonal loss and visual dysfunction in optic neuritis. *Ann Neurol* 2005;58:383–391.
12. Costello F, Coupland S, Hodge W, et al. Quantifying axonal loss after optic neuritis with optical coherence tomography. *Ann Neurol* 2006;59:963–969.
13. McDonald WI, Compston A, Edan G, et al. Recommended diagnostic criteria for multiple sclerosis: guidelines from the International Panel on the diagnosis of multiple sclerosis. *Ann Neurol* 2001;50:121–127.
14. Polman CH, Reingold SC, Edan G, et al. Diagnostic criteria for multiple sclerosis: 2005 revisions to the “McDonald Criteria.” *Ann Neurol* 2005;58:840–846.
15. Paunescu LA, Schuman JS, Price LL, et al. Reproducibility of nerve fiber thickness, macular thickness, and optic nerve head measurements using Stratus OCT. *Invest Ophthalmol Vis Sci* 2004;45:1716–1724.
16. Guan Y, Shindler KS, Tabuena P, Rostami AM. Retinal ganglion cell damage induced by spontaneous autoimmune optic neuritis in MOG-specific TCR transgenic mice. *J Neuroimmunol* 2006;178:40–48.
17. Shindler KS, Guan Y, Ventura E, Bennett J, Rostami A. Retinal ganglion cell loss induced by acute optic neuritis in a relapsing model of multiple sclerosis. *Mult Scler* 2006;12:526–532.
18. Balcer LJ, Baier ML, Cohen JA, et al. Contrast letter acuity as a visual component for the Multiple Sclerosis Functional Composite. *Neurology* 2003;61:1367–1373.
19. Baier ML, Cutter GR, Rudick RA, et al. Low-contrast letter acuity testing captures visual dysfunction in patients with multiple sclerosis. *Neurology* 2005;64:992–995.
20. Jaffe GJ, Caprioli J. Optical coherence tomography to detect and manage retinal disease and glaucoma. *Am J Ophthalmol* 2004;137:156–169.

21. Kanamori A, Nakamura M, Escano MF, Seya R, Maeda H, Negi A. Evaluation of the glaucomatous damage on retinal nerve fiber layer thickness measured by optical coherence tomography. *Am J Ophthalmol* 2003;135:513–520.
22. Medeiros FA, Zangwill LM, Bowd C, Weinreb RN. Comparison of the GDx VCC scanning laser polarimeter, HRT II confocal scanning laser ophthalmoscope, and Stratus OCT optical coherence tomograph for the detection of glaucoma. *Arch Ophthalmol* 2004;122:827–837.
23. Frohman E, Costello F, Zivadinov R, et al. Optical coherence tomography in multiple sclerosis. *Lancet Neurol* 2006;5:853–863.
24. Danesh-Meyer HV, Birch H, Ku JY, Carroll S, Gamble G. Reduction of optic nerve fibers in patients with Alzheimer disease identified by laser imaging. *Neurology* 2006;67:1852–1854.

Up for recertification? Let the AAN Help You Take the Necessary Steps to Fulfilling Your MOC Requirements

The NEW AAN Self Assessment Examination:

- Content outline based on ABPN cognitive exam for recertification
- 100-item, multiple choice
- Convenient—take anytime and anywhere
- Receive immediate feedback
- Compare your performance to that of other neurologists
- \$99 for AAN members

Visit www.aan.com/sae today.

Optical coherence tomography and disease subtype in multiple sclerosis
M. Pulicken, E. Gordon-Lipkin, L. J. Balcer, E. Frohman, G. Cutter and P. A. Calabresi
Neurology 2007;69;2085-2092
DOI: 10.1212/01.wnl.0000294876.49861.dc

This information is current as of November 26, 2007

Updated Information & Services	including high-resolution figures, can be found at: http://www.neurology.org/cgi/content/full/69/22/2085
Subspecialty Collections	This article, along with others on similar topics, appears in the following collection(s): All Neuro-ophthalmology http://www.neurology.org/cgi/collection/all_neuroophthalmology Optic nerve http://www.neurology.org/cgi/collection/optic_nerve Retina http://www.neurology.org/cgi/collection/retina Multiple sclerosis http://www.neurology.org/cgi/collection/multiple_sclerosis Optic neuritis; see Neuro-ophthalmology/Optic Nerve http://www.neurology.org/cgi/collection/optic_neuritis
Permissions & Licensing	Information about reproducing this article in parts (figures, tables) or in its entirety can be found online at: http://www.neurology.org/misc/Permissions.shtml
Reprints	Information about ordering reprints can be found online: http://www.neurology.org/misc/reprints.shtml

