

# Optical Coherence Tomography Angiography in Glaucoma: A Review

Lukas Van Melkebeke João Barbosa-Breda Marc Huygens Ingeborg Stalmans

Department of Neurosciences, KU Leuven, Leuven, Belgium

## Keywords

Glaucoma · Optical coherence tomography angiography · Diagnosis · Ocular blood flow

## Abstract

**Background:** Glaucoma is the leading cause of irreversible blindness worldwide. Several techniques exist for the diagnosis and follow-up of patients. Optical coherence tomography (OCT) angiography (OCTA) is a recently developed technique that provides a quantitative assessment of the microcirculation of the retina and choroid in a fast, noninvasive way. Despite it being a novel technique, several publications have already been done in the glaucoma field. However, a summary of findings is currently lacking. **Aims:** To perform a literature review to assess the role of OCTA in glaucoma diagnosis and follow-up. **Methods:** A database search was carried out using MEDLINE, Embase, and Web of Science, including all original works registered until July 23, 2017. **Results:** OCTA (1) has a high repeatability and reproducibility, (2) has good discriminatory power to differentiate normal eyes from glaucoma eyes, (3) is more strongly correlated with visual function than conventional OCT, (4) has good discriminatory power to differentiate early-glaucoma eyes from normal eyes (i.e., at least equal to that of OCT), (5) reaches a floor effect at a more advanced disease stage than OCT, and

(6) is able to detect progression in glaucoma eyes. **Conclusion:** OCTA shows potential to become a part of everyday glaucoma management.

© 2018 S. Karger AG, Basel

## Introduction

Glaucoma is the leading cause of irreversible blindness both worldwide and in the Western World [1]. Since glaucomatous damage is preventable but irreversible, an early diagnosis and close follow-up of glaucoma patients are primordial [2]. Optical coherence tomography (OCT) angiography (OCTA) is a recently developed, noninvasive imaging modality that detects blood flow through the motion contrast generated by red blood cells. It can be used to provide a quantitative assessment of the microcirculation of the retina and choroid in various layers. Since glaucoma development and progression are both linked to the loss of retinal vessel density (as either a primary or a secondary effect), this technology has the potential to bring forward new information about the pathophysiology of glaucoma, as well as to help clinicians with glaucoma diagnosis and management [3].

Currently, there are 2 groups of complementary exams used for the diagnosis and follow-up of glaucoma patients:

structural (where OCT has a considerable role) and functional (visual field) optic nerve measurements. Both technologies have strengths and limitations [2, 4, 5]. OCT is not dependent on patient response and therefore provides objective information on retinal layers' thickness, with a high repeatability and reproducibility [6]. However, there is a floor effect for OCT in advanced glaucoma, when the OCT parameters reach a base level beyond which little change is seen with increasing severity of glaucoma [7]. The exact value of this base level varies across different OCT brands and different parameters but generally lies between 50 and 70% of the nerve fiber layer thickness in normal eyes [8–10]. Its not being close to zero can be explained by the presence of nonneural tissue in the retinal layers that remains even in advanced cases of retinal ganglion cell loss [8]. Therefore, OCT is not the best method to detect changes in advanced glaucoma. On the other hand, visual field testing is clinically more relevant since it measures visual function. However, it requires a great amount of concentration and cooperation from the patient, lowering its repeatability and reproducibility. This is especially important in advanced glaucoma cases, with larger fluctuations in perimetric results, rendering it difficult to define actual glaucomatous progression [6]. However, visual field testing remains the preferred exam type in advanced glaucoma due to the nonexistence of the floor effect that exists in OCT. Finally, in most cases, visual field testing can only detect damage after it is already recognizable in the structural exams (preperimetric glaucoma; PPG). It is estimated that at least a 25–35% retinal ganglion cell loss is necessary before abnormalities in automated visual field testing are detectable [11].

A new technology for diagnosis and follow-up that can avoid the limitations summarized above is lacking. OCTA seems to be a good candidate for such a role, and multiple studies have been published regarding its use in glaucoma. However, no review on this subject, with a thorough literature search, has been published so far.

We aimed to conduct a literature review of all published studies that focus on the use of OCTA in the glaucoma field to summarize how OCTA can help the clinician in glaucoma diagnosis and follow-up, complementing the results provided by OCT and visual field testing.

## Materials and Methods

### Study Selection

A literature search (Fig. 1) was carried out using MEDLINE, Embase, and Web of Science (a detailed search query for each database is provided as Appendixes 1, 2, and 3, respectively). All reg-

istered studies published until July 23, 2017 were included. Abstracts from the 2017 abstract book from the Annual Meeting of the Association for Research in Vision and Ophthalmology (ARVO) were included. This resulted in 296 unique references being selected (424 references before duplicate removal; Fig. 1).

Two authors (L. Van Melkebeke and J. Barbosa-Breda) independently screened all of the records in 2 stages using Covidence®. After a title and abstract screening, 89 references remained. Afterwards, a full-text screening led to 80 references. Selection discrepancies were solved through discussion or consultation with a third person.

### Inclusion and Exclusion Criteria

We included studies evaluating the role of OCTA in glaucoma patients. Only original research published in English was included. There were no publication year restrictions. Animal studies, in vitro studies, and reviews were excluded.

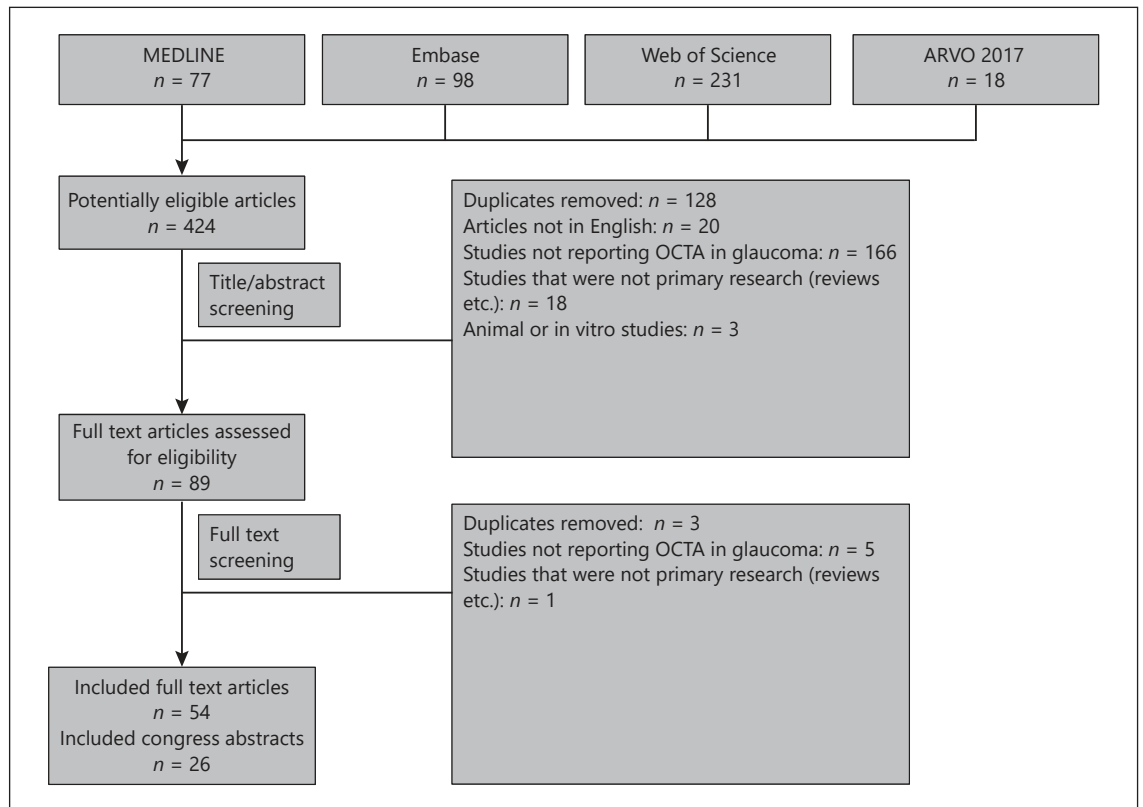
### Terminology

Several types of glaucoma are discussed in this paper. Open-angle glaucoma (OAG) eyes had an open angle on gonioscopy and they had characteristic glaucomatous visual field damage. Primary OAG (POAG) eyes were OAG eyes with an untreated intraocular pressure (IOP) >21 mm Hg and with no structural cause for the elevated IOP. Normal tension glaucoma (NTG) eyes were similar to POAG eyes, with the difference of having an untreated IOP ≤21 mm Hg. Angle closure glaucoma (ACG) eyes differed from OAG eyes in that they had an occludable anterior chamber angle on gonioscopy in 3 or more quadrants. There were cases of eyes with closed angles that experienced an acute primary angle closure (APAC) crisis with a fast IOP rise. Ocular hypertension (OHT) eyes were defined as having a documented IOP >21 mm Hg without evidence of visual or structural glaucomatous damage. PPG eyes had structural optic disc glaucomatous damage (rim defect, cupping, or nerve fiber layer defect) without detectable glaucomatous visual field defects. Glaucoma suspect (GS) eyes had glaucomatous visual field defects or glaucomatous structural defects, but none of the findings were clear enough to allow the diagnosis of glaucoma. In this paper PPG and GS eyes were combined into one group: the preglaucoma group (PrG).

Four types of OCT algorithms were used in the selected studies: the split-spectrum amplitude decorrelation angiography (SSADA) algorithm described in detail by Jia et al. [12], the OCT-based microangiography (OMAG) described in detail by Zhang and Wang [13], the OCTA ratio analysis (OCTARA) described by Stanga et al. [14], and the speckle variance OCTA described in detail by Xu et al. [15].

Several areas of the retina were assessed in the selected studies. Macular scans were centered on the fovea. The “whole image” macula was defined as the whole surface of the scan (generally 3 × 3 or 6 × 6 mm). The fovea was defined as the central 1-mm circle on the macular scan. The parafoveal area was defined as a 1.5- or 2.0-mm-wide circular annulus around the fovea. The foveal avascular zone was defined as the round capillary-free zone within the macula on OCTA images of the superficial vascular network.

Optic disc scans were centered on the optic disc. The neural canal opening, which is the termination of the retinal pigment epithelium/Bruch membrane complex was used to define the optic disc area. “Peripapillary area” was used to describe both the circum-papillary and the whole image peripapillary area. The “cir-



**Fig. 1.** Literature search.

cumpapillary area” was defined as a 0.5-, 0.6-, or 0.75-mm-wide annulus around the optic disc. The whole image peripapillary area was defined as the whole area of the optic disc scan. Scans assessing only the optic disc were generally 2.4 × 2.4 or 3 × 3 mm wide. Scans assessing the optic disc, the peripapillary area, and the whole image peripapillary area were generally 4.5 × 4.5 mm wide. In some cases, the authors divided the parafoveal or circumpapillary area in 8 sectors of 45°.

Vessel density, an OCTA-measured parameter, was defined as the ratio of the area occupied by vessels divided by the total measured area. Blood flow index, a parameter of the OMAG algorithm, was defined as the average flow signal intensity in the vessels. Flow index, a parameter of the SSADA algorithm, was defined as the average decorrelation value, a dimensionless parameter between 0 and 1. Parapapillary deep-layer microvascular dropout (MvD), an OCTA-measured parameter, was defined as a focal sectoral capillary dropout without any visible microvascular network identified in the deep-layer en face images of the peripapillary area. Retinal nerve fiber layer thickness (RNFL), an OCT-measured parameter, was defined as the thickness of the retinal nerve fiber layer in micrometers. Ganglion cell layer complex thickness (GCC), an OCT parameter, was defined as the thickness of the ganglion cell layer complex in micrometers.

Visual field mean deviation (MD) is a parameter that indicated how far from the age-matched results the patient was, and it was

correlated with glaucoma severity; the more severe the glaucoma, the more negative the value.

The coefficient of variation, a standardized measurement of dispersion, was defined as the ratio of the standard deviation to the mean and it was used to express the precision and repeatability of an assay.

## Results and Discussion

For an overview of all of the articles included, see Table 1.

### *Repeatability and Reproducibility*

OCTA had a high repeatability and reproducibility, as shown in Table 2, with the coefficient of variation staying below 7% over a range of parameters, including those from the macula, the optic disc, and the peripapillary region, and for all 3 of the algorithms used (SSADA, OCTARA, and OMAG).

**Table 1.** Overview of all of the articles included

Algorithm	Peripapillary area	Optic disc	Macula
<i>Repeatability and reproducibility (n = 19)</i>			
SSADA	[16–20, 71]	[19, 51–54, 71, 83]	[16, 21, 61]
OMAG	[22]	–	[68]
OCTARA	[23, 85]	[23]	–
<i>Discriminatory ability of OCTA (n = 52)</i>			
SSADA	[16–20, 24–44]	[19, 29, 30, 32, 34, 36, 51–55, 83]	[16, 21, 32, 34, 36–38, 61–63, 69, 70]
OMAG	[6, 22, 45–49]	[56–59]	[47, 64, 68]
OCTARA	[23]	[23, 60]	–
Speckle variance	[50]	–	–
<i>Correlation between OCTA, OCT, and visual function parameters (n = 43)</i>			
SSADA	[17–20, 24, 26, 28–30, 33, 35–39, 41, 71–73, 76, 77]	[19, 29, 30, 36, 51–53, 55, 76, 77]	[21, 36–38, 61, 62, 69, 70, 76]
OMAG	[6, 22, 48, 74, 75, 79]	[57, 58]	[64, 68, 75]
OCTARA	[23]	[23]	[78]
Speckle variance	[50]	–	–
<i>OCTA and the glaucoma spectrum (n = 20)</i>			
SSADA	[7, 19, 24, 25, 28, 29, 33, 35, 80, 81]	[7, 19, 29, 83]	[7, 63, 69]
OMAG	[6, 22, 46, 47, 49]	–	[47]
OCTARA	[23]	[23]	–
Speckle variance	[50]	–	–
<i>Progression (n = 2)</i>			
SSADA	[84]	–	[63]
<i>Layer analysis (n = 60)</i>			
SSADA	[3, 16–20, 25–39, 41, 71, 72, 77, 86, 90, 92, 95]	[16, 19, 29, 30, 32, 34, 36, 51–54, 77, 83]	[21, 32, 34, 36–38, 61–63, 69, 70, 76]
OMAG	[6, 22, 45–48, 75, 87]	[56–59]	[47, 75]
OCTARA	[23, 85, 88, 91, 97, 98]	[23, 60, 88]	–
Speckle variance	[50]	–	–
<i>Different subtypes of glaucoma (n = 10)</i>			
SSADA	[7, 26, 31, 94]	[7]	[7, 69]
OMAG	[22]	[58]	–
OCTARA	[88]	[60, 93]	–

Although the repeatability estimates were slightly worse in glaucoma eyes, the study with the highest sample size found no statistically significant difference between the values of normal and glaucoma eyes [16]. A possible explanation is that the glaucoma group consisted mostly of mild glaucoma and PrG cases [16]. The same study also evaluated the coefficient of repeatability, which represented the test-retest variability of the OCTA measurements [16]. The coefficient of repeatability values of the most relevant peripapillary sectors (inferotemporal and superotemporal) were close to 7% [16]. This means that any change in peripapillary or parafoveal vessel density <7% would fall within the test-retest variability and would be clinically insignificant [16].

In conclusion, OCTA had a high repeatability and reproducibility shown over a range of parameters, ocular

regions, and algorithms. While the repeatability and reproducibility tended to be worse in glaucoma eyes than in normal eyes, no significant difference was found in the largest study included.

#### *Discriminatory Ability of OCTA*

Significantly lower OCTA parameters (vessel density, blood flow index, and flow index) were found in glaucoma eyes in comparison with normal eyes in the peripapillary area [6, 16–50], the optic disc [19, 23, 25, 32, 36, 51–60] and the whole image macular area [16, 21, 32, 34, 36–38, 61–64]. In all of those areas, the diagnostic abilities increased with increasing severity of glaucoma [32, 34, 52]. This illustrated that an increasing severity of glaucoma was correlated with more pronounced vascular and structural damage.

**Table 2.** Repeatability and reproducibility estimates

	Intravisit CV		Intervisit CV	
	control	glaucoma	control	glaucoma
Macula	1.3–4.7	2.4–5.6	–	–
Inside disc	0.7–6.8	3.0–3.4	2.9–6.5	±6.5
Peripapillary area	1.3–6.8	1.8–6.6	0.9–4.3	3.0–6.9

Values are presented as the minimum and maximum CV (in %) of the repeatability and reproducibility estimates. CV, coefficient of variation.

### Peripapillary Area

The area under the curve (AUC) for the best discriminating OCTA parameter (vessel density and blood flow index) ranged between 0.75 and 1.00, while for the OCT parameter (RNFL) the values ranged between 0.76 and 0.97 [17, 19, 20, 22, 23, 25, 27, 31, 32, 34, 36, 37, 41, 49]. Most studies found an AUC above 0.850 both for the OCTA parameters [17, 20, 22, 23, 25, 31, 32, 37, 41] and for the RNFL [19, 20, 22, 25, 31, 34, 37, 49]. Only 2 studies found a significant difference, with a better AUC for the RNFL [19, 34] in both cases. The fact that only 2 studies, both including more than 100 eyes, found a significant difference could mean that OCT and OCTA provided a similar discriminatory ability and that only studies with sufficient power could find a significant difference. A common limitation to all studies was the use of structural parameters to differentiate normal eyes from glaucoma eyes, thus artificially increasing the discriminatory power of OCT parameters.

In the peripapillary area, the greatest differences in OCTA parameters between the normal and glaucoma groups were found in the infero- and superotemporal sectors [6, 18, 25, 35, 37, 42]. This was expected since these 2 sectors are the ones that are the most vulnerable to glaucomatous damage at an early stage [65, 66].

### Macular Area

Several studies found a high AUC for the whole image macular vessel density, (between 0.94 and 0.98), comparable to that of the macular GCC (i.e., 0.95) [21, 37, 61]. However, other studies found only a moderate AUC for the whole image macular vessel density (between 0.69 and 0.80) [32, 34, 36], with a significantly better AUC of the macular GCC (i.e., 0.93) [34].

A possible explanation for this difference in AUC is the size of the macula whole image parameter. The studies

with the lower AUC measured a 3 × 3 mm image, while the studies with the greater AUC measured a 6 × 6 mm image. The macular areas that were found to be the most vulnerable to glaucoma were the superotemporal and inferotemporal areas, lying mostly outside the central 3 × 3 mm area but inside the 6 × 6 mm area [21, 67]. This could explain the higher diagnostic accuracy of the 6 × 6 mm scans.

Significantly lower OCTA parameters were found in the whole image macular area of glaucoma eyes when compared to normal eyes. However, the results regarding the parafoveal and foveal areas were not consensual, with some studies reporting a significant difference [32, 34, 36, 38, 68, 69] and others not [32, 37]. The macular sectors that were found to be the most vulnerable to glaucoma, i.e., the supero- and inferotemporal areas, were lying mostly outside of the central, parafoveal area [21, 67]. This can explain why some studies that measured only the fovea or parafovea found no difference [32, 37]. The finding that the greatest differences between normal and glaucoma eyes were found in the inferotemporal sector further corroborates this theory [36, 47, 62, 70].

### Optic Disc

Several studies found a high AUC for the OCTA parameters (flow index and vessel density) of the optic disc (between 0.93 and 1.00) [23, 51, 55], comparable to that of the peripapillary RNFL [23]. Other studies found only a moderate AUC for the OCTA parameters (flow index and vessel density) of the optic disc (between 0.66 and 0.83) [19, 32, 34, 52], with a significantly better AUC for the OCT parameters (RNFL, GCC, and rim area) [19, 34]. A possible explanation for this discrepancy is the greater number of eyes included in the studies that found a significant difference, which might have resulted from a greater power [19, 34].

All studies assessing the optic disc of nonhighly myopic eyes found significantly different OCTA parameters (flow index, blood flow index, and vessel density) between normal and glaucoma eyes [19, 23, 29, 32, 36, 51–60]. On the other hand, Akagi et al. [30] found no significant difference in optic disc vessel density between groups in highly myopic eyes. A possible explanation is the considerable variation in the optic disc morphology in highly myopic eyes [30], which are usually better evaluated through macular measurements.

Glaucoma eyes with high pretreatment IOP values showed the greatest difference compared to normal eyes in the optic disc, while no difference was found in the macular or peripapillary areas [32, 34]. This suggested that the vessel density decrease in the optic disc in glau-

coma was related to pretreatment IOP values, potentially due to vessel compression [32, 34].

The comparison between different areas showed that the AUC of OCTA parameters (vessel density) in the peripapillary area was equal to that of the 6 × 6 mm whole image macular area [37]. However, it was better than the AUC measured in the 3 × 3 mm whole image macular area and the optic disc [32]. A reason for the difference between the 6 × 6 mm whole image macular area and the 3 × 3 mm whole image area could be the higher diagnostic accuracy of the 6 × 6 mm scans, as described previously. A potential reason for the lower discriminatory power of the OCTA parameters of the optic disc was the considerable heterogeneity in optic disc morphology between different eyes, with tilted discs and varying sizes, making it harder to compare different optic discs. Another possible explanation is the vascular crowding of large vessels in the optic disc, making it harder to specifically examine the microvasculature in the optic disc region. A third possible reason is the existence of a difference in pathophysiology between glaucomatous damage in the optic disc and the other 2 areas.

Gopinath et al. [27] looked at the usefulness of combining peripapillary RNFL and vessel density. While their separate AUC were 0.76 and 0.81, respectively, combining both resulted in an AUC of 0.92, thus proving the usefulness of combining OCT and OCTA [27].

We can conclude that OCTA parameters were significantly lower in glaucoma eyes in comparison to normal eyes in all examined areas. Their discriminatory power was comparable to that of OCT parameters in the peripapillary and 6 × 6 mm macular whole image areas but lower in the optic disc and the 3 × 3 mm macular whole image area. Interestingly, the combination of OCT and OCTA parameters yielded the best discriminatory power.

#### *Correlation between OCTA, OCT, and Visual Function Parameters*

A significant correlation was found between the OCTA parameters and visual field MD, between OCTA parameters and glaucoma stage, and, as previously described, between the OCTA and OCT parameters in the peripapillary area [6, 17–20, 22–24, 26, 28–30, 33, 35, 36, 38, 39, 41, 45, 48, 50, 71–75], the optic disc [19, 23, 29, 36, 51–53, 57, 58], and the macular area [21, 36, 38, 61, 62, 64, 69, 75, 76]. As mentioned above, the results for the parafoveal area were not significant in some of the studies [38, 70]. Vessel density defects (measured with OCTA) were spatially associated with OCT and visual field defects in the

3 above-mentioned regions [6, 17, 18, 20–24, 29, 30, 45, 48, 69, 72, 74, 76–78].

An important finding in multiple studies was that all 3 areas showed a stronger OCTA functional association compared to the OCT functional association [6, 28, 37, 39, 51, 61, 73, 76]. This finding indicated that OCTA parameters (vessel density, flow index, and blood flow index) were better visual function biomarkers in glaucoma eyes than the OCT parameters (RNFL and GCC).

Three studies investigated glaucoma eyes with visual field defects in a single hemifield [30, 76, 79]. Interestingly, their findings regarding the perimetrically intact hemiretina could give information about the pathophysiology of glaucoma. The first study found significantly lower OCTA parameters (vessel density and blood flow index) with normal RNFL in the perimetrically intact hemiretina [79]. The second study found a significantly lower RNFL with normal vessel density in the perimetrically intact hemiretina [30]. The third study found significantly lower vessel density and OCT parameters (RNFL and GCC) in the perimetrically intact hemiretina [76]. In the latter, the correlation between visual field MD and OCTA parameters was stronger than that with OCT parameters [76]. A possible explanation for these differences between studies is that the third study compared considerably larger groups than the first 2 studies, giving it a greater power. A second possible reason is the OCTA algorithm, i.e., OMAG in the first study and SSADA in the other 2 studies. If this were the explanation for the difference, it would mean that the OMAG algorithm is more sensitive to microvascular loss than the SSADA algorithm.

In conclusion, there was a strong spatial correlation between the OCTA parameters, the OCT parameters, and visual function, measured by visual field testing, in glaucoma eyes. The correlation between the OCTA parameters and the visual field MD was stronger than that between the OCT parameters and the visual field MD. This finding indicated that vascular loss was a better biomarker than structural changes for the decrease in visual function in glaucoma eyes.

#### *OCTA and the Glaucoma Spectrum (OHT, Preglaucoma, and Advanced Glaucoma)*

##### *Ocular Hypertension*

Reduced OCTA parameters (vessel density and flow index) were found in treated OHT eyes [19, 24]. Furthermore, changes in vessel density were independent from the change in RNFL and existed in patients with OHT with similar values of IOP when compared to con-

trols [19]. Holló [80] investigated the effect of a large IOP reduction on the OCTA parameters and found that in both glaucoma and OHT eyes the vessel density increased significantly. This corroborated the existence of reduced OCTA parameters in eyes with OHT and the existence of vessel compression caused by a high IOP. In another study, Holló [33] investigated the relationship between vessel density and visual field MD in normal, treated OHT, and treated glaucoma eyes. He found that the OCTA parameters were similar in healthy eyes in comparison to OHT eyes [33]. However, a strong negative relationship was found between the OCTA parameters and visual function in glaucoma and OHT eyes but not in normal eyes [33]. This suggested that at least some OHT eyes had very early glaucomatous alterations in the OCTA parameters and visual function.

In conclusion, the OCTA-measured microvasculature seemed to be reduced in eyes with OHT, which could reflect a dysregulation of the blood flow in these eyes [19]. Another possible explanation for the reduced OCTA parameters is the use of topical eye drops in the OHT group. After treatment, no significant difference in IOP was found between the OHT group and the control group. Therefore, retinal vessel compression caused by a high IOP could no longer explain the reduced microvasculature in eyes with OHT after treatment.

#### Preglaucoma

The following section investigates the ability of OCTA to differentiate normal eyes from preglaucoma eyes (PrG).

*Peripapillary Area.* The majority of studies found a significant difference in OCTA parameters (vessel density and blood flow) between PrG and normal eyes in the peripapillary area [22, 23, 25, 28, 29, 46, 49, 81]. However, significant results were not found for all OCTA parameters. With the SSADA algorithm, the vessel density decreased significantly when measured in the whole image peripapillary area. However, when measured in the circumpapillary area the decrease was often not significant [25, 28]. A possible explanation for this difference is the larger measurement area of the whole image, which may be able to better detect early vessel dropout [82]. With the OMAG algorithm, the blood flow index showed significant results, while vessel density often did not [22, 46]. A possible explanation is that the blood flow (blood flow index) decreased at an earlier stage in the glaucoma disease process than the number of measurable capillaries (vessel density). However, there was no indication that

the OMAG algorithm was more sensitive than the SSADA algorithm.

The AUC for the best OCTA parameters (vessel density and blood flow index) ranged between 0.70 and 0.96, and for the best OCT parameter (RNFL) it ranged between 0.65 and 0.77 [22, 23, 25, 29, 49, 81]. No significant difference was found between the two [22, 25].

*Macular Area.* In the macular area the results were less clear than in the peripapillary area. One study found a significantly lower vessel density in PrG eyes in comparison to normal eyes [63]; a second study found a significantly lower vessel density in the inferior sector [47]; and a third study found a significantly greater vessel density in GS in comparison with control eyes [69]. In the latter, this might be explained by the fact that the GS group was significantly younger than the control group [69].

*Optic Disc.* Two studies found a significant difference between normal and PrG eyes [23, 83], while 1 study did not [29]. In the latter, this might have been caused by the fact that almost half of the included eyes had a closed angle [29]. As ACG has a mechanical motive for the increased IOP, the role of blood flow may differ in ACG and POAG [31]. Only 1 study calculated the discriminatory power of the OCTA parameters and found an AUC value of 0.86 for the difference between normal and PrG eyes [23].

We can conclude that OCTA parameters measured in the peripapillary area were able to differentiate between preglaucoma and normal eyes with a discriminatory power that was at least equal to that of OCT parameters. For the macular area and the optic disc only limited research was available with inconclusive results.

#### Advanced Glaucoma (the Floor Effect Concept)

In this section we will examine the usefulness of OCTA parameters in advanced glaucoma. As discussed in the Introduction, the floor effect limits the ability of OCT to monitor glaucoma in advanced cases. It is therefore interesting to examine the occurrence of the floor effect in OCTA.

Only a few publications, reporting on the peripapillary area, gave information about the occurrence of the floor effect in OCTA, when the parameters reached a base level beyond which little change was seen with increasing severity of glaucoma [7, 35]. Rao et al. [35] showed that vessel density reached a base level beyond a visual sensitivity loss of  $-15$  dB, while the RNFL reached that level at a visual sensitivity loss of  $-10$  to  $-15$  dB. Rao et al. [35] showed, in another study, that in later stages of glaucoma (visual field MD between  $-20$  and  $-30$  dB), the diagnos-

tic ability of vessel density was better than that of the RNFL [7].

In conclusion, OCTA parameters in the peripapillary area appeared to be better biomarkers in advanced glaucoma than OCT parameters, with a less pronounced floor effect in OCTA than in OCT. Therefore, OCTA is another candidate, along with the visual field test, for following advanced-stage glaucoma.

### *Progression*

Because OCTA is a recently developed technique, only limited research has been published about its ability to detect progression [63, 84].

Holló [84] presented a case report of a patient with early POAG in whom IOP elevation, structural progression, and glaucomatous visual field conversion were accompanied by a significant progressive decrease in vessel density. The simultaneous decrease in OCT and OCTA parameters suggested that OCTA parameters could also be used as indicators of early progression in POAG.

We could only find 1 longitudinal cohort study that characterized the rate of macular vessel density loss in POAG, PrG, and healthy eyes [63]. The rate of vessel density loss was significantly different from zero in the POAG group, with a mean rate of change of  $-2.23\%$ , but not in the PrG group or the healthy group. However, the rate of GCC change was not significant in any group. This could probably be explained by the short follow-up time (a mean of 13 months, with a minimum of 12 months).

In conclusion, even in a relatively brief follow-up period, OCTA was able to detect a longitudinal reduction of OCTA parameters in glaucoma eyes while OCT parameters remained stable [63].

We can conclude that OCTA seemed to be able to detect progression in glaucoma and might therefore be useful for glaucoma follow-up. However, only 1 longitudinal study, using the SSADA algorithm, was available and these results therefore need to be confirmed prior to drawing firm conclusions. More studies are needed to examine whether these results can be replicated in other types of glaucoma, in areas other than the macular area, and with other algorithms.

### *Layer Analysis*

#### *Retina*

Most studies investigated the OCTA parameters in the superficial layers (above the inner plexiform layer) [3, 16, 18, 20–22, 25–29, 32–38, 41, 45, 47, 48, 50, 61–63, 69–71, 75–77, 85–88] or in the full-thickness scan [6, 17, 19, 21, 23, 30, 36, 39, 46, 51–54, 56–58, 62, 72, 83].

All of the selected studies (Table 1) found a significant decrease in OCTA parameters in the superficial retinal layers [41, 61, 87, 88] between control and glaucoma eyes. On the other hand, most studies found no significant difference when studying the deeper retinal layers [21, 41, 60, 61, 87, 88]. One study compared vessel density AUC between both layers and found an AUC of 0.78 in the superficial layer, while an AUC of only 0.67 was found in the deeper retinal layer [87]. Two studies found significantly lower vessel density values both in the superficial and in the deep retinal layers [36, 75].

This difference between the results in the superficial and deep vascular layers could reflect a different involvement of each layer in the pathophysiology of glaucoma, but it could also be caused by a flow projection artifact in the deeper layers, which comes from fluctuating shadows cast by flowing blood cells in the more superficial vessels [89]. Recently, techniques became available to remove these flow projection artifacts (e.g., Optovue 3-D projection artifact removal and Spectralis projection artifact removal).

We can conclude that the deeper layers did not have as low values as the superficial retinal layers when compared to control eyes. This could reflect a different involvement of both layers in the pathophysiology of glaucoma or it could have been caused by a flow projection artifact.

#### *Choroid*

Kiyota et al. [85] found significantly lower OCTA parameters in the superficial choroid (0–70  $\mu\text{m}$  below the Bruch membrane) of glaucoma eyes in comparison to healthy eyes, but not in the deep choroid (70–140  $\mu\text{m}$  below the Bruch membrane). Two other studies reporting choroidal results did not find any differences [51, 88].

Parapapillary deep-layer MvD was detected in  $\pm 50\%$  of POAG eyes [90, 91] but not in control eyes [91, 92]. The fact that it corresponded to the perfusion defect shown by indocyanine green angiography indicated that the MvD shown in OCTA represented a true perfusion defect in the choroid or inner sclera [92]. Eyes with an MvD were found to have a higher prevalence of lamina cribrosa defects, a lower vessel density, a lower visual field MD, and lower RNFL and choroidal thicknesses [90, 91]. The MvD were spatially associated with lamina cribrosa defects [90], RNFL defects [91], and visual field defects [30, 92].

The deep-layer microvasculature within the peripapillary area is important because it is downstream from the



short posterior ciliary arteries that also perfuse the prelaminar tissue and the lamina cribrosa [90].

We can conclude that the OCTA-measured parapapillary deep-layer MvD is an important parameter that deserves interest as a potential factor influencing the disease prognosis.

#### Lamina Cribrosa

No studies found a significant difference between control and glaucoma eyes in terms of vessel density or blood flow index in the laminar layer of the optic nerve head [59, 88].

#### *Different Subtypes of Glaucoma*

Most of the studies presented so far focused on OAG or POAG. We selected 10 articles investigating NTG and ACG (Table 1).

#### Normal Tension Glaucoma

As previously mentioned, recent studies comparing POAG eyes with control eyes demonstrated a decreased OCTA-measured microvasculature in glaucoma eyes. In POAG, where the IOP is high, such vascular changes could in part be an effect of high pressure and vessel compression. Also, the pattern of microvascular compromise could differ from that of NTG eyes, where vascular dysfunction potentially plays a greater role in glaucoma damage [88].

The results of the studies comparing NTG eyes and control eyes were comparable to those of the studies comparing POAG eyes and control eyes: the OCTA parameters were significantly lower in NTG eyes and there was a significant correlation with the OCT parameters and visual field MD [22, 26, 58, 69, 88]. One study found no significant correlation between the disc flow index and the visual field MD, but that was a small study, with low power, using an OCTA prototype [93].

When comparing NTG and POAG eyes, Chen et al. [22] found no differences in peripapillary OCTA parameters (blood flow index and vessel density). Sripsema et al. [26] found a significantly higher peripapillary vessel density in the NTG eyes compared to POAG eyes while the structural and functional parameters were not significantly different. Bojikian et al. [58] found a significantly thicker RNFL in NTG eyes, while visual function MD and vessel density, measured within the optic disc, were not significantly different.

We can conclude that OCTA was able to differentiate normal eyes from NTG eyes, as it was able to differenti-

ate between normal and POAG eyes. When comparing NTG and POAG eyes, some differences were found, indicating a possible difference in pathophysiology with a variable effect on the optic nerve head and peripapillary region. Further research is needed to elucidate these differences.

#### Angle Closure Glaucoma

As ACG has a mechanical motive for the increased IOP, the role of blood flow may differ in ACG/APAC and POAG [31].

Wang et al. [94] investigated the peripapillary vessel density in postcrisis APAC eyes using the fellow eyes as controls. The measurements were made 16.5 days (range 2–120) after the acute attack [94]. Compared to the fellow eyes, the APAC eyes had a significantly lower vessel density and a worse visual function MD but comparable OCT parameters [94]. A possible explanation for the preserved OCT parameters is the difference in the course of disease between OAG and closed angle glaucoma, or the preserved OCT-parameters could be caused by retinal edema after the acute attack [94].

Vessel density (macular, optic disc, and peripapillary) was lower in ACG eyes than in control eyes [7, 31]. The AUC of vessel density in ACG were comparable to those of OCT parameters and to the AUC found in POAG eyes [7, 31]. The diagnostic ability of vessel density in PACG was lower than that of OCT parameters in early glaucoma cases, but better in advanced glaucoma cases, indicating that, as found in POAG, the floor effect is less pronounced for OCTA parameters than for OCT parameters [7, 31].

When accounting for the effect of glaucoma severity on diagnostic abilities, the sensitivity of the peripapillary vessel density appeared to be better in POAG, compared to ACG, with increasing severity of the disease [31]. This may indicate a lower prevalence of ocular perfusion abnormality in ACG eyes [31]. One small study with 4 ACG eyes found no significant difference in optic disc microvasculature in ACG compared to POAG, possibly due to insufficient power [60].

In conclusion, OCTA parameters were more affected than OCT parameters after an APAC attack. When comparing POAG and ACG eyes, the results suggested a lower prevalence of ocular perfusion abnormality in ACG.

#### *Study Limitations*

There were several limitations to this review. First, the effect of a publication and selection bias could not be ruled out, especially due to the language restriction. We tried to minimize this risk by not restricting the publica-

**Table 3.** Conclusions

- OCTA has a high repeatability and reproducibility in normal and glaucoma eyes.
- OCTA parameters are significantly lower in glaucoma eyes.
- OCTA has good discriminatory power to differentiate normal and glaucoma eyes, comparable to that of OCT; combining both techniques yields a better AUC than any of them on its own.
- There is a strong spatial correlation among OCTA parameters, OCT parameters, and the visual function measured by visual field testing.
- Visual field MD has a stronger correlation with OCTA parameters than with OCT parameters.
- OCTA parameters in the peripapillary area are able to differentiate between glaucoma suspect/preperimetric glaucoma and normal eyes with a discriminatory power that is at least equal to and possibly better than that of the OCT parameters.
- With a less pronounced floor effect in OCTA than in OCT, OCTA parameters, in the peripapillary area, appear to be better biomarkers in advanced glaucoma than OCT parameters.
- OCTA is able to detect progression in glaucoma eyes.

OCTA, optical coherence tomography angiography; OCT, optical coherence tomography; AUC, area under the curve; MD, mean deviation.

tion year. Second, in several studies a considerable number of patients were excluded because of poor image quality secondary to poor fixation, movement artifacts, or the presence of a visually significant cataract [6, 7, 16, 26, 34, 71, 95]. This potentially limits the clinical usefulness of OCTA in populations with cataract, macular lesions, and advanced glaucoma. Current versions already have real-time eye tracking which can reduce movement artifacts [96]. A third limitation was the cross-sectional design of almost all of the included studies, except for 2 studies about progression. This cross-sectional design made it impossible to establish temporal relationships and hard to assess the effect of potential confounders (e.g., ocular medication). Finally, the broad nature of this review prevented us from advancing into a quantitative pooling of data. Given that this is the first review attempt in the field, we believe that a broad approach is preferable. Future review attempts that can focus on more specific subpopulations or topics are needed.

## Conclusion

In this review we summarize the different ways in which OCTA can impact the glaucoma field. In comparison to visual field testing, OCTA has the advantage

of being a reliable, objective technique with a high repeatability and reproducibility. OCTA is also faster than visual field testing and relies much less on patient cooperation. When compared to standard OCT, (1) OCTA had a comparable discriminatory power to differentiate between normal and glaucoma eyes, (2) OCTA combined with OCT resulted in the best AUC to differentiate between normal and glaucoma eyes, (3) OCTA parameters were more strongly correlated with visual function than OCT parameters, and (4) OCTA offers a clear benefit in GS/PPG and advanced glaucoma cases.

Given these promising results, we believe that OCTA may in the future become a part of everyday glaucoma management, alongside OCT and visual field testing.

For an overview of our conclusions, see Table 3.

## Disclosure Statement

The authors declare no conflict of interest.

## Appendix 1

*Search Conducted on July 23, 2017, in MEDLINE*

("Glaucoma"[Mesh] OR (glaucoma[tiab] OR glaucoma'[tiab] OR glaucoma's[tiab] OR glaucomacase[tiab] OR glaucomacyclitic[tiab] OR glaucomadb[tiab] OR glaucomadrugs[tiab] OR glaucomaellenes[tiab] OR glaucomahtg[tiab] OR glaucomain[tiab] OR glaucomainviewer[tiab] OR glaucomalike[tiab] OR glaucomarioides[tiab] OR glaucomas[tiab] OR glaucomascope[tiab] OR glaucomastudy[tiab] OR glaucomat[tiab] OR glaucomata[tiab] OR glaucomateuses[tiab] OR glaucomatic[tiab] OR glaucomato[tiab] OR glaucomatocyclic[tiab] OR glaucomatocyclitic[tiab] OR glaucomatocyclitis[tiab] OR glaucomatocylitic[tiab] OR glaucomatologist[tiab] OR glaucomatologists[tiab] OR glaucomatologists'[tiab] OR glaucomatology[tiab] OR glaucomatons[tiab] OR glaucomatosa[tiab] OR glaucomatosous[tiab] OR glaucomatosus[tiab] OR glaucomatous[tiab] OR glaucomatous'[tiab] OR glaucomatouse[tiab] OR glaucomatouslike[tiab] OR glaucomatously[tiab] OR glaucomatousprogression[tiab] OR glaucomatreatment[tiab] OR glaucomatuous[tiab] OR glaucomatus[tiab] OR glaucomawas[tiab] OR glaucomax[tiab])) AND (OCTA[tiab] OR octangiography[tiab] OR (optical coherence tomography angiographic[tiab] OR optical coherence tomography angiography[tiab]) OR optical coherence angiography[tiab] OR oct based microangiography[tiab] OR optical coherence tomography based microangiography[All Fields] OR OMAG[tiab] OR optical microangiography[tiab] OR angio-OCT[tiab] OR (OCT[tiab] AND ocular hemodynamics[tiab])).

## Appendix 2

Search Conducted on July 23, 2017, in Embase

Query: (("glaucoma"/exp OR "glaucoma":ti,ab) AND ("octa":ti,ab OR "oct angiography":ti,ab OR "optical coherence tomography angiography":ti,ab OR "optical coherence angiography":ti,ab OR "oct based microangiography":ti,ab OR "optical coherence tomography based microangiography":ti,ab OR "omag":ti,ab OR "optical microangiography":ti,ab OR "angio-oct":ti,ab OR ("oct":ti,ab AND "ocular hemodynamics":ti,ab)).

Mapped terms: "glaucoma" mapped to "glaucoma," term is exploded.

## References

- ▶ 1 Tham Y-C, Li X, Wong TY, Quigley HA, Aung T, Cheng C-Y: Global prevalence of glaucoma and projections of glaucoma burden through 2040. *Ophthalmology* 2014;121:2081–2090.
- ▶ 2 European Glaucoma Society Terminology and Guidelines for Glaucoma, 4th Edition – Chapter 3: treatment principles and options supported by the EGS Foundation. *Br J Ophthalmol* 2017;101:130–195.
- ▶ 3 Lee EJ, Lee KM, Lee SH, Kim T-W: OCT angiography of the peripapillary retina in primary open-angle glaucoma. *Invest Ophthalmol Vis Sci* 2016;57:6265–6270.
- 4 Michelessi M, Lucenteforte E, Oddone F, Brazzelli M, Parravano M, Franchi S, et al: Optic nerve head and fibre layer imaging for diagnosing glaucoma. *Cochrane Database Syst Rev* 2015, p CD008803.
- 5 Prum BE, Rosenberg LF, Gedde SJ, Mansberger SL, Stein JD, Moroi SE, et al: Primary open-angle glaucoma PPP. *Am Acad Ophthalmol* 2015, pp 41–111.
- ▶ 6 Shin JW, Lee J, Kwon J, Choi J, Kook MS: Regional vascular density-visual field sensitivity relationship in glaucoma according to disease severity. *Br J Ophthalmol* 2017;101:1666–1672.
- ▶ 7 Rao HL, Pradhan ZS, Weinreb RN, Riyazuddin M, Dasari S, Venugopal JP, et al: Vessel density and structural measurements of optical coherence tomography in primary angle closure and primary angle closure glaucoma. *Am J Ophthalmol* 2017;177:106–115.
- ▶ 8 Kanamori A, Nakamura M, Tomioka M, Kawaka Y, Yamada Y, Negi A: Structure-function relationship among three types of spectral-domain optical coherent tomography instruments in measuring parapapillary retinal nerve fibre layer thickness. *Acta Ophthalmol* 2013;91:e196–e202.
- ▶ 9 Ueda K, Kanamori A, Akashi A, Kawaka Y, Yamada Y, Nakamura M: Difference in correspondence between visual field defect and inner macular layer thickness measured using three types of spectral-domain OCT instruments. *Jpn J Ophthalmol* 2015;59:55–64.
- ▶ 10 Medeiros FA, Zangwill LM, Bowd C, Mansouri K, Weinreb RN: The structure and function relationship in glaucoma: implications for detection of progression and measurement of rates of change. *Invest Ophthalmol Vis Sci* 2012;53:6939–6946.
- ▶ 11 Kerrigan-Baumrind LA, Quigley HA, Pease ME, Kerrigan DF, Mitchell RS: Number of ganglion cells in glaucoma eyes compared with threshold visual field tests in the same persons. *Invest Ophthalmol Vis Sci* 2000;41:741–748.
- ▶ 12 Jia Y, Tan O, Tokayer J, Potsaid B, Wang Y, Liu JJ, et al: Split-spectrum amplitude-decorrelation angiography with optical coherence tomography. *Opt Express* 2012;20:4710–4725.
- ▶ 13 Zhang A, Wang RK: Feature space optical coherence tomography based micro-angiography. *Biomed Opt Express* 2015;6:1919–1928.
- ▶ 14 Stanga PE, Tsamis E, Papayannis A, Stringa F, Cole T, Jalil A: Swept-Source Optical Coherence Tomography Angio™ (Topcon Corp., Japan): technology review. *Dev Ophthalmol* 2016;56:13–17.
- ▶ 15 Xu J, Wong K, Jian Y, Sarunic MV: Real-time acquisition and display of flow contrast using speckle variance optical coherence tomography in a graphics processing unit. *J Biomed Opt* 2014;19:26001.
- ▶ 16 Venugopal JP, Rao HL, Weinreb RN, Pradhan ZS, Dasari S, Riyazuddin M, et al: Repeatability of vessel density measurements of optical coherence tomography angiography in normal and glaucoma eyes. *Br J Ophthalmol* 2017, DOI: 10.1136/bjophthalmol-2017-310637.
- ▶ 17 Liu L, Jia Y, Takusagawa HL, Pechauer AD, Edmunds B, Lombardi L, et al: Optical coherence tomography angiography of the peripapillary retina in glaucoma. *JAMA Ophthalmol* 2015;133:1045.
- ▶ 18 Mansoori T, Sivaswamy J, Gamalapati JS, Balakrishna N: Radial peripapillary capillary density measurement using optical coherence tomography angiography in early glaucoma. *J Glaucoma* 2017;26:483–443.
- ▶ 19 Chihara E, Dimitrova G, Amano H, Chihara T: Discriminatory power of superficial vessel density and prelaminar vascular flow index in eyes with glaucoma and ocular hypertension and normal eyes. *Invest Ophthalmol Vis Sci* 2017;58:690.
- ▶ 20 Geyman LS, Garg RA, Suwan Y, Trivedi V, Krawitz BD, Mo S, et al: Peripapillary perfused capillary density in primary open-angle glaucoma across disease stage: an optical coherence tomography angiography study. *Br J Ophthalmol* 2017;101:1261–1268.
- ▶ 21 Takusagawa HL, Liu L, Ma KN, Jia Y, Gao SS, Zhang M, et al: Projection-resolved optical coherence tomography angiography of macular retinal circulation in glaucoma. *Ophthalmology* 2017;124:1589–1599.
- ▶ 22 Chen C-L, Zhang A, Bojikian KD, Wen JC, Zhang Q, Xin C, et al: Peripapillary retinal nerve fiber layer vascular microcirculation in glaucoma using optical coherence tomography-based microangiography. *Invest Ophthalmol Vis Sci* 2016;57:OCT475–OCT485.
- ▶ 23 Akil H, Huang AS, Francis BA, Sadda SR, Chopra V: Retinal vessel density from optical coherence tomography angiography to differentiate early glaucoma, pre-perimetric glaucoma and normal eyes. *PLoS One* 2017;12:e0170476.
- ▶ 24 Holló G: Vessel density calculated from OCT angiography in 3 peripapillary sectors in normal, ocular hypertensive, and glaucoma eyes. *Eur J Ophthalmol* 2016;26:e42–e45.
- ▶ 25 Yarmohammadi A, Zangwill LM, Diniz-Filho A, Suh MH, Manalastas PI, Fatehee N, et al: Optical coherence tomography angiography vessel density in healthy, glaucoma suspect, and glaucoma eyes. *Invest Ophthalmol Vis Sci* 2016;57:OCT451–OCT459.
- ▶ 26 Sripsema NK, Garcia PM, Bavier RD, Chui TYP, Krawitz BD, Mo S, et al: Optical coherence tomography angiography analysis of perfused peripapillary capillaries in primary open-angle glaucoma and normal-tension glaucoma. *Invest Ophthalmol Vis Sci* 2016;57:OCT611–OCT620.

## Appendix 3

Search Conducted on July 23, 2017, in Web of Science

Topic: ((Glaucoma OR glaucoma\*) AND (OCTA OR OCT angiograph\* OR Optical coherence tomography angiograph\* OR Optical coherence angiograph\* OR OCT based microangiograph\* OR Optical Coherence Tomography based microangiograph\* OR OMAG OR Optical microangiograph\*))

Time span: all years.

Indexes: SCI-EXPANDED, SSCI, A&HCI, CPCI-S, CPCI-SSH, BKCI-S, BKCI-SSH, ESCI, CCR-EXPANDED, and IC.

- ▶27 Gopinath K, Sivaswamy J, Mansoori T: Automatic glaucoma assessment from angio-OCT images. *Proc Int Symp Biomed Imaging* 2016; 2016:193–196.
- ▶28 Yarmohammadi A, Zangwill LM, Diniz-Filho A, Suh MH, Yousefi S, Saunders LJ, et al: Relationship between optical coherence tomography angiography vessel density and severity of visual field loss in glaucoma. *Ophthalmology* 2016;123:2498–2508.
- ▶29 Kumar RS, Anegondi N, Chandapura RS, Sudhakaran S, Kadambi SV, Rao HL, et al: Discriminant function of optical coherence tomography angiography to determine disease severity in glaucoma. *Invest Ophthalmol Vis Sci* 2016;57:6079–6088.
- ▶30 Akagi T, Iida Y, Nakanishi H, Terada N, Moorooka S, Yamada H, et al: Microvascular density in glaucomatous eyes with hemifield visual field defects: an optical coherence tomography angiography study. *Am J Ophthalmol* 2016;168:237–249.
- ▶31 Rao HL, Kadambi S V, Weinreb RN, Puttaiah NK, Pradhan ZS, Rao DAS, et al: Diagnostic ability of peripapillary vessel density measurements of optical coherence tomography angiography in primary open-angle and angle-closure glaucoma. *Br J Ophthalmol* 2017; 101:1066–1070.
- ▶32 Rao HL, Pradhan ZS, Weinreb RN, Reddy HB, Riyazuddin M, Dasari S, et al: Regional comparisons of optical coherence tomography angiography vessel density in primary open-angle glaucoma. *Am J Ophthalmol* 2016;171:75–83.
- ▶33 Holló G: Relationship between OCT angiography temporal peripapillary vessel-density and octopus perimeter paracentral cluster mean defect. *J Glaucoma* 2017;26:397–402.
- ▶34 Rao HL, Pradhan ZS, Weinreb RN, Riyazuddin M, Dasari S, Venugopal JP, et al: A comparison of the diagnostic ability of vessel density and structural measurements of optical coherence tomography in primary open angle glaucoma. *PLoS One* 2017;12:e0173930.
- ▶35 Rao HL, Pradhan ZS, Weinreb RN, Dasari S, Riyazuddin M, Raveendran S, et al: Relationship of optic nerve structure and function to peripapillary vessel density measurements of optical coherence tomography angiography in glaucoma. *J Glaucoma* 2017;26:548–554.
- ▶36 Kuryshva NI, Maslova E, Trubilina AV, Likhvantseva VG, Fomin AV, Lagutin MB: OCT angiography and color Doppler imaging in glaucoma diagnostics. *Int J Pharm Sci Res* 2017;9:527–536.
- ▶37 Chen HS-L, Liu C-H, Wu W-C, Tseng H-J, Lee Y-S: Optical coherence tomography angiography of the superficial microvasculature in the macular and peripapillary areas in glaucomatous and healthy eyes. *Invest Ophthalmol Vis Sci* 2017;58:3637–3645.
- ▶38 Liu C-H, Wu W-C, Sun M-H, Kao L-Y, Lee Y-S, Chen HS-L: Comparison of the retinal microvascular density between open angle glaucoma and nonarteritic anterior ischemic optic neuropathy. *Invest Ophthalmol Vis Sci* 2017;58:3350–3356.
- 39 Yarmohammadi A, Zangwill LM, Diniz-Filho A, Suh MH, Manalastas PIC, Fatehee N, et al: OCT angiography vessel density in normal, glaucoma suspects and glaucoma eyes: structural and functional associations in the Diagnostic Innovations in Glaucoma Study (DIGS). *Invest Ophthalmol Vis Sci* 2016;57:2958.
- ▶40 Suwan Y, Geyman LS, Fard MA, Tantraworasin A, Chui TY, Rosen RB, et al: Peripapillary perfused capillary density in exfoliation syndrome and exfoliation glaucoma versus POAG and healthy controls: an optical coherence tomography angiography study. *Invest Ophthalmol Vis Sci* 2017;58:718.
- 41 Edmunds B, Liu L, Gao S, Takusagawa H, Morrison J, Huang D: Projection-resolved optical coherence tomography angiography of the peripapillary retina in glaucoma. *Invest Ophthalmol Vis Sci* 2017;58:721.
- 42 Liu L, Jia Y, Tan O, Wang J, Edmunds B, Takusagawa HL, et al: Radial peripapillary capillary plexus perfusion and regional visual field loss in glaucoma. *Invest Ophthalmol Vis Sci* 2017;58:3394.
- ▶43 Fard MA, Moghimi S, Suwan Y, Geyman L, Chui TY, Rosen RB, et al: Peripapillary capillary density in anterior ischemic optic neuropathy compared to that in severe primary open-angle glaucoma. *Invest Ophthalmol Vis Sci* 2017;58:3393.
- 44 Jia Y, Wang J, Liu L, Morrison J, Huang D: Optical coherence tomography angiography of low radial peripapillary capillary density area in glaucoma. *Invest Ophthalmol Vis Sci* 2017;58:717.
- 45 Wen JC, Chen C-L, Bojikian KD, Zhang Q, Xin C, Mudumbai RC, et al: Peripapillary retinal nerve fiber layer (RNFL) vascular microcirculation in glaucomatous eyes with asymmetric hemifield visual field (VF) Loss. *Invest Ophthalmol Vis Sci* 2016;57:357.
- ▶46 Chen C-L, Bojikian KD, Zhang A, Xin C, Wen JC, Mudumbai RC, et al: Peripapillary retinal nerve fiber layer (RNFL) vascular microcirculation in glaucoma using optical coherence tomography-based microangiography (OMAG). *Invest Ophthalmol Vis Sci* 2016;57:5466.
- 47 Triolo G, Rabiolo A, Galasso M, De Vitis L, Sacconi R, Di Matteo F, et al: Assessment of peripapillary and macular vessel density estimated with OCT-angiography in glaucoma suspects and glaucoma patients. *Invest Ophthalmol Vis Sci* 2017;58:715.
- 48 Zaman AS, Sylvester B, Madi I, Chu Z, Kashani AH, Wang R, et al: Quantification of peripapillary microvasculature defects in the retinal nerve fiber layer using optical coherence tomography angiography and correlation with visual field defects in primary open angle glaucoma. *Invest Ophthalmol Vis Sci* 2017;58:719.
- 49 Schweitzer C, Duteil C, De Bosredon Q, Roseng S, Georges N, Fard A, et al: Peripapillary retina nerve fiber layer (RNFL) vascular microcirculation using optical coherence tomography based microangiography to discriminate glaucoma or glaucoma suspect and healthy control patients. *Invest Ophthalmol Vis Sci* 2017;58:720.
- ▶50 Mammo Z, Heisler M, Balaratnasingam C, Lee S, Yu D-Y, Mackenzie P, et al: Quantitative optical coherence tomography angiography of radial peripapillary capillaries in glaucoma, glaucoma suspect, and normal eyes. *Am J Ophthalmol* 2016;170:41–49.
- ▶51 Jia Y, Wei E, Wang X, Zhang X, Morrison JC, Parikh M, et al: Optical coherence tomography angiography of optic disc perfusion in glaucoma. *Ophthalmology* 2014;121:1322–1332.
- ▶52 Wang X, Jiang C, Ko T, Kong X, Yu X, Min W, et al: Correlation between optic disc perfusion and glaucomatous severity in patients with open-angle glaucoma: an optical coherence tomography angiography study. *Graefes Arch Clin Exp Ophthalmol* 2015;253:1557–1564.
- ▶53 Lévêque P-M, Zéboulon P, Brasnu E, Baudouin C, Labbé A: Optic disc vascularization in glaucoma: value of spectral-domain optical coherence tomography angiography. *J Ophthalmol* 2016;2016:1–9.
- ▶54 Liu L, Jia Y, Morrison JC, Parikh M, Edmunds B, Huang D: Angiography of optic disc perfusion in glaucoma with a 70 kHz spectral OCT. *Invest Ophthalmol Vis Sci* 2014;55:221.
- 55 Michelessi M, Manni G, Tanga L, Ferrazza M, Berado F, Roberti G, et al: OCT angiography of the optic nerve head to differentiate normal from glaucoma eyes. *Invest Ophthalmol Vis Sci* 2016;2016:1–9.
- 56 Auyeung K, Auyeung K, Kono R, Chen C-L, Zhang Q, Wang RK: Imaging patients with glaucoma using spectral-domain optical coherence tomography and optical microangiography. *Prog Biomed Opt Imaging Proc SPIE* 2015, p 9322.
- ▶57 Chen C-L, Bojikian KD, Gupta D, Wen JC, Zhang Q, Xin C, et al: Optic nerve head perfusion in normal eyes and eyes with glaucoma using optical coherence tomography-based microangiography. *Quant Imaging Med Surg* 2016;6:125–133.
- ▶58 Bojikian KD, Chen C-L, Wen JC, Zhang Q, Xin C, Gupta D, et al: Optic disc perfusion in primary open angle and normal tension glaucoma eyes using optical coherence tomography-based microangiography. *PLoS One* 2016;11:e0154691.
- 59 Chen C-L, Gupta D, Wen JC, Mudumbai RC, Johnstone MA, Chen PP, et al: Optic disc perfusion in glaucoma with optical microangiography (OMAG). *Invest Ophthalmol Vis Sci* 2015;56:1310.
- 60 Gusto Greig LC, Qiu K, Awasthi S, Miller JB, Brauner S, Greenstein SH, et al: Investigation of optic nerve head microvascular changes in primary open angle glaucoma and chronic angle closure glaucoma using OCT-angiography. *Invest Ophthalmol Vis Sci* 2017;58:3392.
- ▶61 Takusagawa HL, Morrison JC, Jia Y, Liu L, Edmunds B, Lombardi L, et al: OCT angiography of macular ganglion cell complex circulation in glaucoma. *Invest Ophthalmol Vis Sci* 2016, p 57.

- ▶62 Xu H, Yu J, Kong X, Sun X, Jiang C: Macular microvasculature alterations in patients with primary open-angle glaucoma. *Medicine (Baltimore)* 2016;95:e4341.
- ▶63 Shoji T, Zangwill LM, Akagi T, Saunders LJ, Yarmohammadi A, Manalastas PIC, et al: Progressive macula vessel density loss in primary open angle glaucoma: a longitudinal study. *Am J Ophthalmol* 2017;182:107–117.
- 64 Chen C-L, Nobrega P, Wen JC, Mudumbai RC, Menda S, Johnstone MA, et al: Microvasculature changes in macular region in glaucomatous eyes using optical coherence tomography-based angiography. *Invest Ophthalmol Vis Sci* 2017;58:1677.
- ▶65 Quigley HA, Addicks EM: Regional differences in the structure of the lamina cribrosa and their relation to glaucomatous optic nerve damage. *Arch Ophthalmol* 1981;99:137–143.
- ▶66 Leung CKS, Chan W-M, Yung W-H, Ng ACK, Woo J, Tsang M-K, et al: Comparison of macular and peripapillary measurements for the detection of glaucoma. *Ophthalmology* 2005;112:391–400.
- ▶67 Hood DC, Raza AS, de Moraes CG V, Liebmann JM, Ritch R: Glaucomatous damage of the macula. *Prog Retin Eye Res* 2013;32:1–21.
- ▶68 Kwon J, Choi J, Shin JW, Lee J, Kook MS: Alterations of the foveal avascular zone measured by optical coherence tomography angiography in glaucoma patients with central visual field defects. *Invest Ophthalmol Vis Sci* 2017;58:1637–1645.
- 69 Ma J, Nesper P, Anchala A, Fawzi AA: Optical coherence tomography angiography in glaucoma. *Invest Ophthalmol Vis Sci* 2017;58:1678.
- 70 Silva L, Suwan Y, Jarukasetphon R, Rajshkhar R, De Moraes CG, Hood D, et al: Retinal ganglion cell layer by Fourier-domain optical coherence tomography and microvasculature by optical coherence tomography angiography at the macular region in glaucoma. *Invest Ophthalmol Vis Sci* 2017;58:712.
- ▶71 Holló G: Intrasession and between-visit variability of sector peripapillary angioflow vessel density values measured with the Angiovue optical coherence tomograph in different retinal layers in ocular hypertension and glaucoma. *PLoS One* 2016;11:e0161631.
- 72 Scripsema NK, Garcia P, Xu L, Lin Y, Panarelli J, Sidoti PA, et al: Comparing optical coherence tomography angiography (OCTA) radial peripapillary capillary perfusion density maps in glaucoma patients and normal patients. *Invest Ophthalmol Vis Sci* 2016;57:5509.
- 73 Sakaguchi K, Higashide T, Udagawa S, Ohkubo S, Sugiyama K: Comparison of the optic disc microvascular and structure in open angle glaucoma patients and related factors. *Invest Ophthalmol Vis Sci* 2016;57:2960.
- ▶74 Ichiyama Y, Minamikawa T, Niwa Y, Ohji M: Capillary dropout at the retinal nerve fiber layer defect in glaucoma. *J Glaucoma* 2017;26:e142–e145.
- ▶75 Werner JU, Enders C, Lang GK, Lang GE: Optical coherence tomography angiography in glaucoma. *Invest Ophthalmol Vis Sci* 2016;57:2961.
- 76 Yarmohammadi A, Zangwill LM, Diniz-Filho A, Saunders LJ, Suh MH, Wu Z, et al: Peripapillary and macular vessel density in patients with glaucoma and single-hemifield visual defect. *Ophthalmology* 2017;124:709–719.
- ▶77 Zéboulon P, Lévêque P-M, Brasnu E, Aragno V, Hamard P, Baudouin C, et al: Effect of surgical intraocular pressure lowering on peripapillary and macular vessel density in glaucoma patients: an optical coherence tomography angiography study. *J Glaucoma* 2017;26:466–472.
- 78 Wong BJ, Varma R, Patel V, West D, Puliafito CA, Kashani AH, et al: Anatomic correlations between optical coherence tomography angiography microvasculature defects and ganglion cell analysis thinning in glaucomatous and non-glaucomatous optic neuropathy. *Invest Ophthalmol Vis Sci* 2016;57:5465.
- ▶79 Chen C-L, Bojikian KD, Wen JC, Zhang Q, Xin C, Mudumbai RC, et al: Peripapillary retinal nerve fiber layer vascular microcirculation in eyes with glaucoma and single-hemifield visual field loss. *JAMA Ophthalmol* 2017;135:461–468.
- ▶80 Holló G: Influence of large intraocular pressure reduction on peripapillary OCT vessel density in ocular hypertensive and glaucoma eyes. *J Glaucoma* 2017;26:e7–e10.
- ▶81 Cennamo G, Montorio D, Velotti N, Sparnelli F, Reibaldi M, Cennamo G: Optical coherence tomography angiography in pre-perimetric open-angle glaucoma. *Graefes Arch Clin Exp Ophthalmol* 2017;255:1787–1793.
- ▶82 Shiga Y, Kunikata H, Aizawa N, Kiyota N, Maiya Y, Yokoyama Y, et al: Optic nerve head blood flow, as measured by laser speckle flowgraphy, is significantly reduced in preperimetric glaucoma. *Curr Eye Res* 2016;41:1447–1453.
- ▶83 Jia Y, Morrison JC, Tokayer J, Tan O, Lombardi L, Baumann B, et al: Quantitative OCT angiography of optic nerve head blood flow. *Biomed Opt Express* 2012;3:3127–3137.
- ▶84 –Holló G: Progressive decrease of peripapillary angioflow vessel density during structural and visual field progression in early primary open-angle glaucoma. *J Glaucoma* 2017;26:661–664.
- ▶85 Kiyota N, Kunikata H, Shiga Y, Omodaka K, Nakazawa T: Relationship between laser speckle flowgraphy and optical coherence tomography angiography measurements of ocular microcirculation. *Graefes Arch Clin Exp Ophthalmol* 2017;255:1633–1642.
- 86 Marvasti AH, Camp A, Yarmohammadi A, Belghith A, Zangwill LM, Medeiros FA, et al: Optical coherence tomography angiography in patients with focal, diffuse, and sclerotic glaucomatous optic discs. *Invest Ophthalmol Vis Sci* 2017;58:716.
- ▶87 Shin JW, Sung KR, Lee JY, Kwon J, Seong M: Optical coherence tomography angiography vessel density mapping at various retinal layers in healthy and normal tension glaucoma eyes. *Graefes Arch Clin Exp Ophthalmol* 2017;255:1193–1202.
- ▶88 Lee EJ, Kim S, Hwang S, Han JC, Kee C: Microvascular compromise develops following nerve fiber layer damage in normal-tension glaucoma without choroidal vasculature involvement. *J Glaucoma* 2017;26:216–222.
- ▶89 Zhang M, Hwang TS, Campbell JP, Bailey ST, Wilson DJ, Huang D, et al: Projection-resolved optical coherence tomographic angiography. *Biomed Opt Express* 2016;7:816–828.
- ▶90 Suh MH, Zangwill LM, Manalastas PIC, Belghith A, Yarmohammadi A, Medeiros FA, et al: Deep retinal layer microvasculature dropout detected by the optical coherence tomography angiography in glaucoma. *Ophthalmology* 2016;123:2509–2518.
- ▶91 Lee EJ, Lee SH, Kim J-A, Kim T-W: Parapapillary deep-layer microvasculature dropout in glaucoma: topographic association with glaucomatous damage. *Invest Ophthalmol Vis Sci* 2017;58:3004–3010.
- ▶92 Lee EJ, Lee KM, Lee SH, Kim T-W: Parapapillary deep-layer microvasculature dropout in glaucoma. *Ophthalmology* 2017;124:1209–1217.
- 93 Zhu D, Reznik A, Chen C-L, Wang RK, Puliafito CA: Evaluation of optic disc perfusion in normal-tension glaucoma patients by optical coherence tomography angiography. *Invest Ophthalmol Vis Sci* 2015;56:2745.
- ▶94 Wang X, Jiang C, Kong X, Yu X, Sun X: Peripapillary retinal vessel density in eyes with acute primary angle closure: an optical coherence tomography angiography study. *Graefes Arch Clin Exp Ophthalmol* 2017;255:1013–1018.
- ▶95 Suh MH, Zangwill LM, Manalastas PIC, Belghith A, Yarmohammadi A, Medeiros FA, et al: Optical coherence tomography angiography vessel density in glaucomatous eyes with focal lamina cribrosa defects. *Ophthalmology* 2016;123:2309–2317.
- ▶96 Camino A, Zhang M, Gao SS, Hwang TS, Sharma U, Wilson DJ, et al: Evaluation of artifact reduction in optical coherence tomography angiography with real-time tracking and motion correction technology. *Biomed Opt Express* 2016;7:3905–3915.
- ▶97 Lee EJ, Kim T-W, Lee SH, Kim J-A: Underlying microstructure of parapapillary deep-layer capillary dropout identified by optical coherence tomography angiography. *Invest Ophthalmol Vis Sci* 2017;58:1621–1627.
- ▶98 Suh MH, Zangwill LM, Belghith A, Yarmohammadi A, Manalastas PIC, Diniz-Filho A, et al: Diagnostic Innovations in Glaucoma Study (DIGS): OCT angiography vessel density in glaucomatous eyes with focal lamina cribrosa defects. *Invest Ophthalmol Vis Sci* 2016;57.