

Original Investigation

Optical Coherence Tomography Angiography of the Peripapillary Retina in Glaucoma

Liang Liu, MD; Yali Jia, PhD; Hana L. Takusagawa, MD; Alex D. Pechauer, BS; Beth Edmunds, MD, PhD; Lorinna Lombardi, MD; Ellen Davis, MD; John C. Morrison, MD; David Huang, MD, PhD

IMPORTANCE Vascular factors may have important roles in the pathophysiology of glaucoma. A practical method for the clinical evaluation of ocular perfusion is needed to improve glaucoma management.

OBJECTIVE To detect peripapillary retinal perfusion in glaucomatous eyes compared with normal eyes using optical coherence tomography (OCT) angiography.

DESIGN, SETTING, AND PARTICIPANTS Prospective observational study performed from July 24, 2013, to April 17, 2014. Participants were recruited and tested at Casey Eye Institute, Oregon Health & Science University. In total, 12 glaucomatous eyes and 12 age-matched normal eyes were analyzed. The optic disc region was imaged twice using a 3 × 3-mm scan by a 70-kHz, 840-nm-wavelength spectral OCT system. The split-spectrum amplitude-decorrelation angiography algorithm was used. Peripapillary flow index was calculated as the mean decorrelation value in the peripapillary region, defined as a 700- μ m-wide elliptical annulus around the disc. Peripapillary vessel density was the percentage area occupied by vessels. The data statistical analysis was performed from October 30, 2013, to May 30, 2014.

MAIN OUTCOMES AND MEASURES Variability was assessed by the coefficient of variation. The Mann-Whitney test was used to compare the 2 groups of eyes. Correlations between vascular and visual field variables were assessed by linear regression analysis.

RESULTS In 12 normal eyes, a dense microvascular network around the disc was visible on OCT angiography. In 12 glaucomatous eyes, this network was visibly attenuated globally and focally. In normal eyes, between-visit reproducibilities of peripapillary flow index and peripapillary vessel density were 4.3% and 2.7% of the coefficient of variation, respectively, while the population variabilities of peripapillary flow index and peripapillary vessel density were 8.2% and 3.0% of the coefficient of variation, respectively. Peripapillary flow index and peripapillary vessel density in glaucomatous eyes were lower than those in normal eyes ($P < .001$ for both). Peripapillary flow index (Pearson $r = -0.808$) and peripapillary vessel density (Pearson $r = -0.835$) were highly correlated with visual field pattern standard deviation in glaucomatous eyes ($P = .001$ for both). The areas under the receiver operating characteristic curve for normal vs glaucomatous eyes were 0.892 for peripapillary flow index and 0.938 for peripapillary vessel density.

CONCLUSIONS AND RELEVANCE Using OCT angiography, reduced peripapillary retinal perfusion in glaucomatous eyes can be visualized as focal defects and quantified as peripapillary flow index and peripapillary vessel density, with high repeatability and reproducibility. Quantitative OCT angiography may have value in future studies to determine its potential usefulness in glaucoma evaluation.

JAMA Ophthalmol. 2015;133(9):1045-1052. doi:10.1001/jamaophthalmol.2015.2225
Published online July 23, 2015.

← Invited Commentary
page 1052

Author Affiliations: Casey Eye Institute, Oregon Health & Science University, Portland (Liu, Jia, Takusagawa, Pechauer, Edmunds, Lombardi, Davis, Morrison, Huang); Department of Ophthalmology, Peking Union Medical College Hospital, Beijing, China (Liu).

Corresponding Author: David Huang, MD, PhD, Casey Eye Institute, Oregon Health & Science University, 3375 SW Terwilliger Blvd, Portland, OR 97239-4197 (davidhuang@alum.mit.edu).

Glaucoma is the second leading cause of blindness worldwide, affecting more than 60 million people and predicted by 2020 to reach 79.6 million.¹⁻³ Early diagnosis and close monitoring of glaucoma are important given the insidious onset of glaucoma, with irreversible nerve damage associated with vision loss. Visual field (VF) testing remains the criterion standard for glaucoma assessment, but it has substantial variability, with poor reproducibility in some patients.^{4,5} Structural studies⁶⁻¹⁴ of retinal nerve fiber layer (NFL) by optical coherence tomography (OCT) show its promise as an objective quantifiable measure for glaucoma assessment, but it has limited sensitivity for detecting early glaucoma and only moderate correlation with VF loss. Some studies¹⁵⁻²¹ have shown that glaucoma may be associated with vascular dysfunction, suggesting another possible imaging target for early diagnosis and monitoring of glaucoma. Laser Doppler flowmetry (LDF) and laser speckle flowgraphy (LSFG) have demonstrated reduced optic nerve head (ONH) and peripapillary blood flow dynamics in glaucoma.^{20,22-27} Jia et al¹⁸ recently quantified optic disc perfusion using the split-spectrum amplitude-decorrelation angiography (SSADA) algorithm on a custom swept-source OCT system and showed decreased optic disc perfusion in glaucoma. To our knowledge, no attempt has been made to evaluate the peripapillary retinal vasculature using OCT in glaucomatous eyes. For this study, we obtained OCT angiograms of the peripapillary retina on a commercially available spectral OCT system and quantified peripapillary flow index and peripapillary vessel density using the SSADA algorithm. We compared the perfusion indexes between normal and glaucomatous eyes. Correlation of these perfusion indexes with more conventional measures of glaucoma (VF and structural OCT) was also investigated.

Methods

Study Population

This prospective observational study was performed from July 24, 2013, to April 17, 2014, at Casey Eye Institute, Oregon Health & Science University. The research protocols were approved by the Institutional Review Board at Oregon Health & Science University, performed in accord with the tenets of the Declaration of Helsinki. Written informed consent was obtained from each participant.

All participants were enrolled in the Functional and Structural Optical Coherence Tomography for Glaucoma study. The inclusion criteria for perimetric glaucomatous (PG) eyes were (1) an optic disc rim defect (thinning or notching) or NFL defect visible on slitlamp biomicroscopy and (2) a consistent glaucomatous pattern on both qualifying Humphrey Swedish Interactive Threshold Algorithm (SITA) 24-2 VFs with pattern standard deviation (PSD) outside normal limits ($P < .05$) or glaucoma hemifield test results outside normal limits. The inclusion criteria for pre-PG eyes were (1) an optic disc rim or NFL defect visible on slitlamp biomicroscopy and (2) a baseline VF not meeting the criteria for the PG eyes.

There were 7 inclusion criteria for normal eyes. These were (1) no evidence of retinal pathology or glaucoma, (2) a normal

At a Glance

- Using optical coherence tomography angiography, reduced peripapillary retinal perfusion in glaucomatous eyes can be visualized as focal defects and quantified as peripapillary flow index and peripapillary vessel density, with high repeatability and reproducibility.
- The areas under the receiver operating characteristic curve to differentiate values in normal vs glaucomatous eyes were 0.892 for peripapillary flow index and 0.938 for peripapillary vessel density.
- Both peripapillary flow index and peripapillary vessel density were correlated with visual field pattern standard deviation in glaucomatous eyes.
- Quantitative optical coherence tomography angiography may have value in future studies to determine its potential usefulness in the diagnosis, staging, and monitoring of glaucoma.

Humphrey SITA 24-2 VF, (3) intraocular pressure (IOP) less than 21 mm Hg, (4) central corneal pachymetry exceeding 500 μm , (5) no chronic ocular or systemic corticosteroid use, (6) an open angle on gonioscopy, (7) a normal-appearing ONH and retinal NFL, and (8) symmetric ONH between left and right eyes.

The exclusion criteria for all eyes were the following: (1) best-corrected visual acuity less than 20/40, (2) age younger than 30 years or older than 80 years, (3) refractive error greater than +3.00 diopter (D) or less than -7.00 D, (4) previous intraocular surgery except for uncomplicated cataract extraction with posterior chamber intraocular lens implantation, (5) any diseases that may cause VF loss or optic disc abnormalities, or (6) inability to perform reliably on automated VF testing. One eye from each participant was imaged and analyzed.

VF Testing

Visual field tests were performed with the Humphrey Field Analyzer II (Carl Zeiss Meditec, Inc). The system was set for the 24-2 threshold test, size III white stimulus, standard SITA algorithm.

Optical Coherence Tomography

A 70-kHz (840-nm wavelength) spectral OCT system (RTVue-XR; Optovue, Inc) with a 22- μm beam width was used. The tissue resolution was 5 μm axially.

Image Acquisition and Processing

Two sets of imaging were performed at one visit. Each image set comprised 2 raster volumetric patterns (one vertical priority and one horizontal priority) covering 3 \times 3 mm. An orthogonal registration algorithm²⁸ was used to produce merged 3-dimensional OCT angiograms. Each volume was composed of 216 line-scan locations at which 5 consecutive B-scans were obtained. Each B-scan contained 216 A-scans. The SSADA algorithm²⁹ compares the consecutive B-scans at the same location to detect flow using motion contrast. One set of perfusion indexes was obtained from each merged angiogram, and the results of 2 sets were averaged.

The peripapillary region was defined as a 700- μm -wide elliptical annulus extending from the optic disc boundary. An

en face angiogram of the retinal circulation was obtained by the maximum flow (decorrelation value) projection from the inner limiting layer to retinal epithelial pigment. *Peripapillary flow index* was defined as the mean decorrelation value on the en face retinal angiogram. Peripapillary flow index measures the area of large vessels and the area and velocity of retinal microvasculature.¹⁸ Peripapillary vessel density was defined as the percentage area occupied by the large vessels and microvasculature in the peripapillary region.

Image quality was assessed for all OCT angiograms. Poor-quality images with a signal strength index less than 40 or registered image sets with residual motion artifacts (discontinuous vessel pattern or disc boundary) were excluded from the analysis. Because repeatability requires 2 high-quality image sets, both image sets had to meet the quality criteria for an eye to be included in the analysis.

Structural OCT Analysis

Peripapillary NFL thickness was measured from a volumetric 8 × 8-mm scan of the optic disc. Each participant had 3 sets of images obtained at one visit. In each set, NFL thickness was averaged from a circular sampling profile of 3.4-mm diameter centered on the disc, and the results of 3 sets were averaged.

Localization of Focal Vessel Defects With VF Loss

To facilitate focal vessel defects and VF loss correspondence in PG eyes, peripapillary flow index and peripapillary vessel density were divided into superior and inferior parts. All total deviations (TDs) were averaged by decibels in the superior and inferior hemifields to obtain the superior mean TD and inferior mean TD, respectively. If one hemifield had a lower mean TD and the opposite hemifield had a lower peripapillary flow index and peripapillary vessel density, then we considered localization of focal vessel defects with VF loss as corresponding.

Repeatability and Reproducibility

Within-visit repeatability of peripapillary flow index and peripapillary vessel density was calculated with 2 sets of images obtained sequentially at a single visit. Variability was assessed by the coefficient of variation (CV), calculated as the root-mean-square measurement variation divided by the mean of the measured values. Between-visit reproducibility and interoperator reproducibility of 2 operators were calculated from 5 normal eyes using the mean value averaged from 3 sets of images per visit.

Statistical Analysis

Linear regression analysis was used to investigate the effect of age, mean ocular perfusion pressure (MOPP), and IOP on peripapillary flow index and peripapillary vessel density measurements using the following equation: $MOPP = \frac{2}{3}MAP$ minus IOP, where the mean arterial pressure (MAP) is two-thirds of the diastolic blood pressure plus one-third of the systolic blood pressure. Because the study sample was small, the nonparametric Mann-Whitney test was used to compare normal and glaucomatous eyes. Linear regression analysis was

Table 1. Characteristics of Normal Eyes and Glaucomatous Eyes^a

Variable	Study Group	
	Normal Eyes (n = 12)	Glaucomatous Eyes (n = 12)
Age, y	67 (3)	70 (10)
Antiglaucoma eyedrops, No. (%)	0	11 (92)
Intraocular pressure, mm Hg	14.8 (2.7)	14.1 (3.1)
Blood pressure, mm Hg		
Diastolic	82.1 (11.3)	77.5 (8.2)
Systolic	129.6 (17.4)	130.4 (12.3)
Ocular perfusion pressure, mm Hg	50.1 (8.4)	49.3 (6.5)
Visual field mean deviation, dB	0.18 (1.23) [-3.06 to 1.87]	-6.05 (7.07) [-26.20 to 0.15]
Visual field PSD, dB	1.53 (0.39) [1.02 to 2.34]	5.01 (3.53) [1.28 to 10.15]
Mean NFL thickness, μm	95.8 (8.7) [79.8 to 108.9]	71.0 (10.6) [58.5 to 94.2]
Peripapillary flow index	0.082 (0.007) [0.071 to 0.091]	0.066 (0.012) [0.041 to 0.080]
Peripapillary vessel density, % area	93.00 (2.80) [88.21 to 96.90]	80.55 (11.10) [57.89 to 93.87]
Optic disc perfusion peripapillary flow index	0.090 (0.010) [0.073 to 0.111]	0.088 (0.013) [0.067 to 0.105]

Abbreviations: NFL, nerve fiber layer; PSD, pattern standard deviation.

^a Unless otherwise indicated, data are given as the mean (population SD) [range].

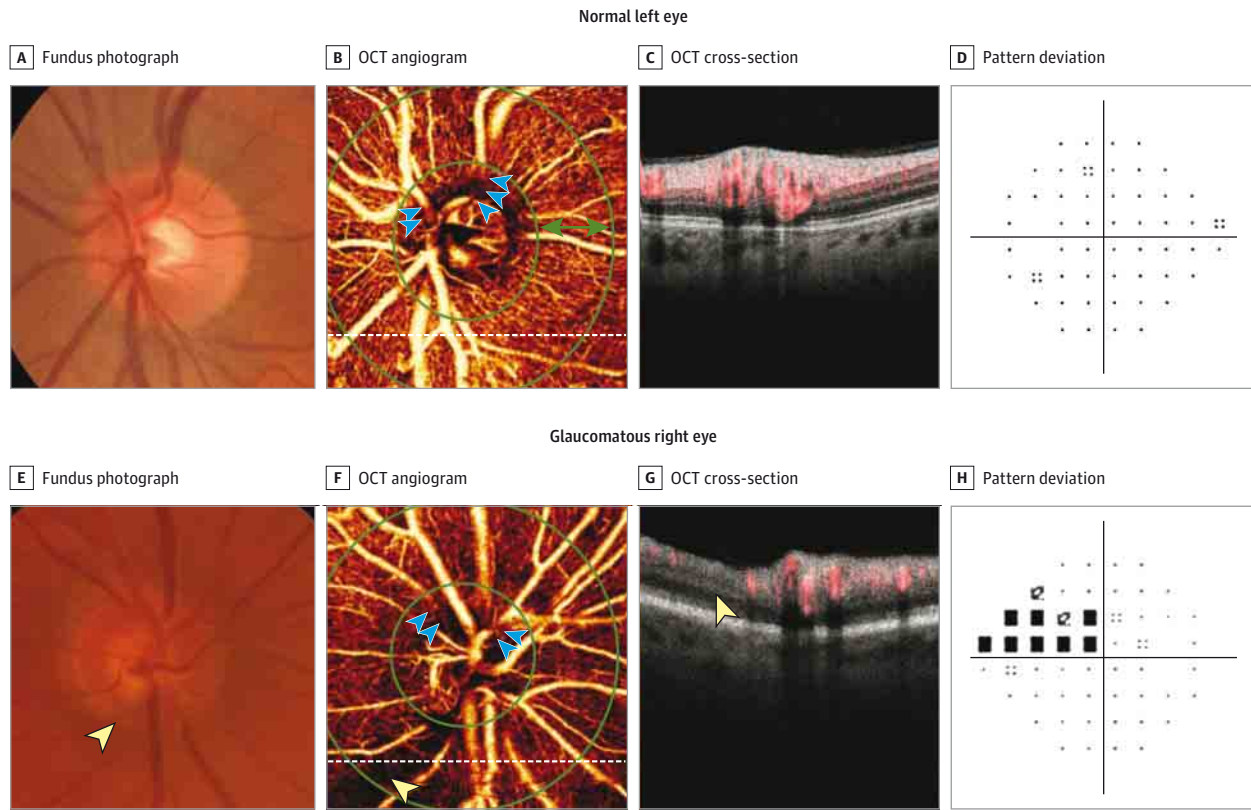
used to determine the relationships between peripapillary flow index and peripapillary vessel density and traditional glaucoma measurements of function and structure such as VF PSD, VF mean deviation, and mean retinal NFL thickness in glaucomatous eyes. All analyses were conducted from October 30, 2013, to May 30, 2014, and performed with statistical software (SPSS, version 20.0; IBM).

Results

Study Population

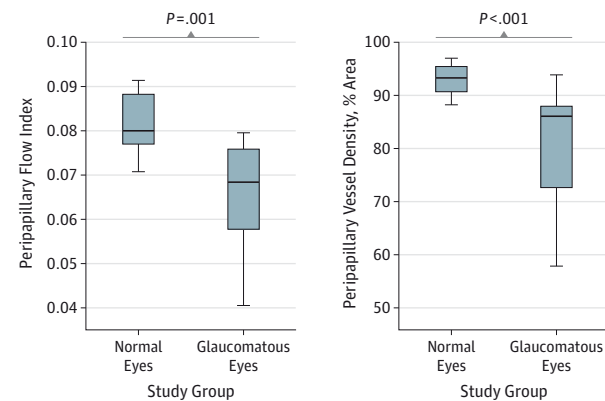
Peripapillary retinal perfusion was studied in 17 normal eyes and 15 glaucomatous eyes. Three glaucomatous eyes were not analyzed because of poor OCT angiography quality, leaving 12 eyes for statistical analysis. The oldest 12 normal eyes were used in the analysis to provide age-matched comparison with the 12 glaucomatous eyes (Table 1). Glaucomatous eyes consisted of 9 PG eyes and 3 pre-PG eyes, all of which had glaucomatous optic neuropathy based on the inclusion criteria. Five glaucomatous eyes had mild glaucoma (stage 0 or 1), 5 had moderate glaucoma (stage 2 or 3), and 2 had advanced glaucoma (stage 4 or 5) according to the enhanced Glaucoma Staging System.³⁰ Among glaucomatous eyes, 2 were receiving 3 glaucoma medications, 6 were receiving 2 medications, and 3 were receiving 1 medication. The twelfth eye was pre-PG, with no treatment at that time. Latanaprost, brimatoprost, or travoprost once daily at bedtime was used in 11 eyes, while timolol maleate once daily was used in 4 eyes, dorzolamide hydrochloride was used in 3 eyes, and brimonidine tartrate once daily was used in 2 eyes. The duration of medication use was 2 to 7 years.

Figure 1. Comparison of Peripapillary Retinal Angiograms



En face optical coherence tomography (OCT) angiograms of the peripapillary retina show a generalized reduction and an infratemporal area of focal capillary dropout (blue arrows) in the glaucomatous eye.

Figure 2. Comparison of Peripapillary Flow Index and Peripapillary Vessel Density



The Mann-Whitney test showed statistically significantly reduced peripapillary flow index and peripapillary vessel density in glaucomatous eyes compared with normal eyes. The mean (SD) peripapillary flow indexes were 0.066 (0.012) in glaucomatous eyes and 0.082 (0.007) in normal eyes. The mean (SD) peripapillary vessel densities were 80.6% (11.1%) in glaucomatous eyes and 93.0% (2.8%) in normal eyes.

There was no correlation of age, MOPP, or IOP with peripapillary flow index or peripapillary vessel density in the normal and glaucomatous eyes. No statistically significant differ-

ence was observed between the normal and glaucomatous eyes for IOP, MOPP, or systolic or diastolic blood pressure (Table 1), although the mean diastolic blood pressure in glaucomatous eyes was 4.6 mm Hg lower than that in normal eyes.

Comparison of Peripapillary Retinal Angiograms

Color fundus photographs of normal eyes and PG eyes are shown in Figure 1A and E. In the normal eye, a dense microvascular network around the disc was visible on OCT angiography (Figure 1B). This network was visibly attenuated in glaucomatous eyes, and focal capillary dropout could be detected (Figure 1F). The OCT cross-sections (Figure 1C and G) with overlaying flow (in red) on OCT reflectance (gray scale) show a focal perfusion defect associated with retinal NFL thinning (yellow arrow in Figure 1G). The VF pattern deviation maps (Figure 1D and H) show supranasal depression matching the location of the perfusion defect in the glaucomatous eye (Figure 1H).

Comparison of Peripapillary Flow Index and Peripapillary Vessel Density

The mean (SD) peripapillary flow index in glaucomatous eyes was 0.066 (0.012), which was lower than the mean (SD) peripapillary flow index in normal eyes of 0.082 (0.007) ($P = .001$) (Figure 2). The mean (SD) peripapillary vessel density in glaucomatous eyes was 80.6% (11.1%), which was also less than the

Table 2. Pearson Correlation Coefficient Matrix on Peripapillary Flow Index, Peripapillary Vessel Density, Visual Field, Structural Variables, and Glaucoma Stage in Glaucomatous Eyes

Variable	Peripapillary Flow Index	Peripapillary Vessel Density	Visual Field Mean Deviation	Visual Field PSD	Mean NFL Thickness
Peripapillary vessel density	$r = 0.977, P < .001^a$				
Visual field mean deviation	$r = 0.643, P = .02^a$	$r = 0.680, P = .02^a$			
Visual field PSD	$r = -0.808, P = .001^a$	$r = -0.835, P = .001^a$	$r = -0.706, P = .01^a$		
Mean NFL thickness	$r = 0.292, P = .36$	$r = 0.355, P = .26$	$r = 0.448, P = .14$	$r = -0.186, P = .56$	
Glaucoma stage ^b	$r = -0.854, P < .001^a$	$r = -0.860, P < .001^a$	$r = -0.842, P = .001^a$	$r = 0.916, P < .001^a$	$r = -0.317, P = .32$

Abbreviations: NFL, nerve fiber layer; PSD, pattern standard deviation.

^a Statistically significant correlation ($P < .05$).

^b Determined by the enhanced Glaucoma Staging System.³⁰

93.0% (2.8%) in normal eyes ($P < .001$). The areas under the receiver operating characteristic curve for differentiating normal and glaucomatous eyes were 0.892 for peripapillary flow index and 0.938 for peripapillary vessel density. When using the 5% cutoff point in normal eyes, the sensitivity and specificity were 58.3% and 100%, respectively, for peripapillary flow index and 83.3% and 91.7%, respectively, for peripapillary vessel density.

Correlation With Traditional Glaucoma Diagnostic Measurements

In glaucomatous eyes, univariate regression analysis using the Pearson correlation coefficient showed that peripapillary flow index ($r = -0.808$) and peripapillary vessel density ($r = -0.835$) were correlated with VF PSD ($P = .001$ for both) (Table 2). Peripapillary flow index ($r = 0.643$) and peripapillary vessel density ($r = 0.680$) were also correlated with VF mean deviation ($P = .02$ for both). As determined by the enhanced Glaucoma Staging System,³⁰ glaucoma stage had an even higher correlation with OCT angiography measures ($r = -0.854$ for peripapillary flow index and $r = -0.860$ for peripapillary vessel density, $P < .001$ for both) than VF PSD or VF mean deviation.

Correlation and Comparison With Other Quantitative Imaging Techniques

In glaucomatous eyes, the mean retinal NFL thickness did not correlate with VF PSD ($r = -0.186, P = .56$) or VF mean deviation ($r = 0.448, P = .14$) (Table 2). Similarly, NFL thickness did not correlate with glaucoma stage ($r = -0.317, P = .32$). Furthermore, neither peripapillary flow index nor peripapillary vessel density correlated with NFL thickness. The area under the receiver operating characteristic curve was 0.970 for the mean retinal NFL thickness. When using the 5% cutoff point in normal eyes, both the sensitivity and specificity were 91.7%.

Localization of Focal Vessel Defects With VF Loss

Of 9 PG eyes, 7 eyes had focal vessel defects, with concordant VF loss. Five eyes had more superior VF loss, with matching decreased inferior peripapillary vessel density and peripapillary flow index. Two eyes had more inferior VF loss, with matching decreased superior peripapillary vessel density and peripapillary flow index.

Repeatability and Reproducibility

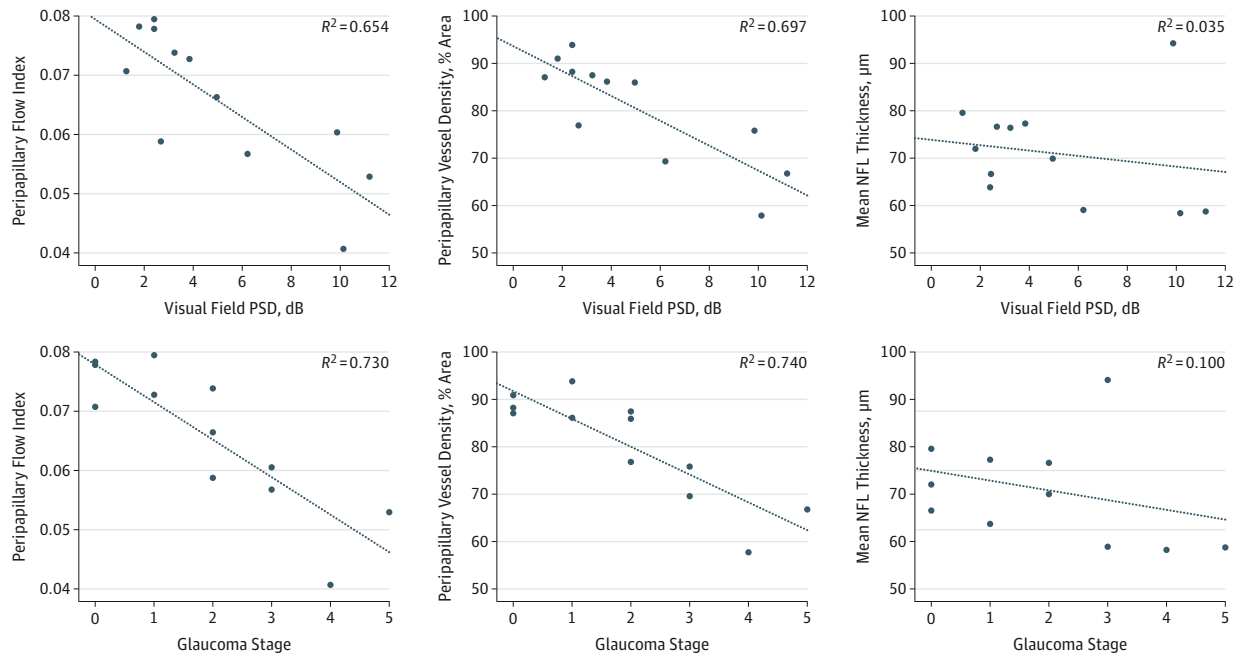
Among 12 normal eyes included in the comparison analyses with glaucomatous eyes, within-visit repeatability CVs were 3.8% for peripapillary flow index and 1.9% for peripapillary vessel density, while the population variabilities were 8.2% for peripapillary flow index and 3.0% for peripapillary vessel density. Among 12 glaucomatous eyes, within-visit repeatability CVs were 5.7% for peripapillary flow index and 4.0% for peripapillary vessel density. In the other 5 normal eyes, between-visit reproducibility and interoperator reproducibility were 4.3% and 2.1%, respectively, for peripapillary flow index and 2.7% and 1.1%, respectively, for peripapillary vessel density.

Discussion

Our group previously showed that quantitative OCT angiography on a swept-source system could differentiate glaucomatous eyes from normal eyes based on reduced ONH peripapillary flow index.¹⁸ On the spectral OCT system used in this study, we found the ONH peripapillary flow index to be less reliable (Table 1) because of the absence of an OCT signal in segments of major blood vessels (blue arrows in Figure 1B and F). The loss of signal in rapidly moving fluids (known as flow voids) occurs due to washout of interferometric fringes within the OCT signal integration time.³¹ Fringe washout occurs at a lower velocity range in spectral OCT compared with swept-source OCT³¹ and would thus interfere with accurate measurement of ONH peripapillary flow index in spectral OCT than in swept-source OCT. Therefore, this study concentrated on the peripapillary microvasculature, which could be visualized with excellent capillary detail using spectral OCT angiography. The peripapillary retina also offers a larger area over which focal perfusion defects can be seen more easily.

We found that peripapillary flow index and peripapillary vessel density were lower in glaucomatous eyes compared with aged-matched normal eyes. These results are in agreement with our group's earlier swept-source OCT study¹⁸ and with previous LDF and LSFG studies^{20,22-27} that showed decreased peripapillary and ONH blood flow in glaucoma. The present study differs from previous studies because we found that OCT angiography technology offers less variation within normal eyes (8.2% for peripapillary flow index and 3.0% for peripapillary

Figure 3. Correlation of Perfusion Indexes and Structural Measurements With Visual Field and Glaucoma Stage



Shown are visual field pattern standard deviation (PSD) and glaucoma stage vs peripapillary flow index, peripapillary vessel density, and mean nerve fiber layer (NFL) thickness in glaucomatous eyes.

vessel density) compared with LDF (range, 43.5%-47.1%) and LSF (range, 23.2%-33.0%).³²⁻³⁶ The decreased variation in measurements may render OCT angiography more viable for use in a clinical setting.

With OCT angiography, we demonstrated high within-visit repeatability (3.8% for peripapillary flow index and 1.9% for peripapillary vessel density) and high between-visit reproducibility (4.3% for peripapillary flow index and 2.7% for peripapillary vessel density) and interoperator reproducibility (2.1% for peripapillary flow index and 1.1% for peripapillary vessel density). This is a marked improvement compared with other noninvasive techniques, such as LDF and LSF. With LSF, the CVs for intravisit repeatability ranged from 1.9% to 11.9%, and intervisit reproducibility was 12.8%.^{32,33,35,37,38} With LDF, the CVs for intravisit repeatability ranged from 6.6% to 21.2%, and intervisit reproducibility ranged from 25.2% to 30.1%.^{34,39-42} The high interoperator reproducibility of OCT angiography in the peripapillary retina demonstrates the potential for a multioperator clinical setting.

In our study, there was no statistically significant difference among the 3 areas under the receiver operating characteristic curve for peripapillary vessel density, peripapillary flow index, and mean NFL thickness. We usually compare sensitivity at fixed specificity values, such as 95%. However, for small sample sizes that could be adversely affected by large sampling error, we used the Shapiro-Wilk test in normal eyes to check for normality and found that these variables did not deviate statistically significantly from a normal distribution. Therefore, we used 1.65 SD below the mean of the reference population (age matched), which is the 5% cutoff point in normal eyes. The speci-

ficity for peripapillary vessel density and mean retinal NFL thickness was the same (91.7%), while the sensitivity for peripapillary vessel density was high (83.3%) but below the mean retinal NFL thickness (91.7%). This finding may point to a loss in peripapillary vessel density as a potentially reliable diagnostic parameter to differentiate normal eyes from glaucomatous eyes.

As our group's previous Doppler OCT and OCT angiography studies on glaucomatous ONH indicated, VF indexes are better correlated with perfusion indexes (total retinal blood flow and ONH peripapillary flow index) than structural measures.^{18,43} Peripapillary flow index and peripapillary vessel density also correlated well with VF PSD. We performed the Pearson product moment correlation and the Spearman rank correlation. The Spearman ρ values were similar to the Pearson r values in Table 2. The P values of the 2 correlation tests were also similar and led to the same conclusions. Our findings of moderate correlation between VF indexes and retinal NFL thickness were similar to other studies.^{6,8,12-14} The disease in glaucomatous eyes ranged from PG to moderate and severe glaucoma, and peripapillary flow index and peripapillary vessel density demonstrated high correlation with glaucoma staging (Figure 3). In contrast, there was no statistically significant correlation of glaucoma staging with retinal NFL thickness. These data suggest that blood peripapillary flow indexes measured by OCT may be more meaningful indicators of glaucoma severity than structural measures. The perfusion indexes may have potential for staging and monitoring glaucoma.

This study had several limitations. First, normal eyes and glaucomatous eyes had small samples. Only 12 glaucomatous eyes and 12 normal eyes were compared. Second, PG eyes and

pre-PG eyes were selected based on optic disc rim or NFL defect, and the high sensitivity of the OCT angiography diagnostic parameters could be biased by high correlation of disc structure with peripapillary perfusion. Third, there is a potential confounding effect of antiglaucoma drugs on the hemodynamics of peripapillary vessels. Most glaucomatous eyes had been receiving multiple antiglaucoma eyedrops for 2 to 7 years. The effect of antiglaucoma eyedrops on peripapillary perfusion is unknown and could not be analyzed herein because of the few participants. However, the focal nature of decreased flow correlates with areas of glaucomatous damage, and we would not expect a focal deficit secondary to medication use (Figure 1F). Furthermore, other vascular imaging modalities have not shown any decrease in ocular blood circulation with antiglaucoma eyedrops.^{24,44-47} This finding suggests that the reduced perfusion in glaucomatous eyes in our study was unlikely the result of antiglaucoma eyedrop effects and was most

likely due to the glaucoma disease process. Nevertheless, the effect of antiglaucoma eyedrops on perfusion indexes deserves further study.

Conclusions

In conclusion, high-quality OCT angiograms of the peripapillary retina were obtained in normal and glaucomatous eyes using the SSADA algorithm with a commercially available OCT system. Reduced peripapillary retinal perfusion in glaucomatous eyes could be visualized as focal defects and quantified as peripapillary flow index and peripapillary vessel density, with high repeatability and reproducibility. Quantitative OCT angiography may have value in future studies to determine its potential usefulness in the diagnosis, staging, and monitoring of glaucoma.

ARTICLE INFORMATION

Submitted for Publication: February 27, 2015; final revision received May 27, 2015; accepted May 28, 2015.

Published Online: July 23, 2015.
doi:10.1001/jamaophthalmol.2015.2225.

Author Contributions: Dr Huang had full access to all the data in the study and takes responsibility for the integrity of the data and the accuracy of the data analysis. Drs Liu and Jia contributed equally to this work.

Study concept and design: Jia, Morrison, Huang.
Acquisition, analysis, or interpretation of data: All authors.

Drafting of the manuscript: Liu, Jia, Takusagawa, Pechauer.

Critical revision of the manuscript for important intellectual content: All authors.

Statistical analysis: Liu.

Obtained funding: Huang.

Administrative, technical, or material support: Jia, Huang.

Study supervision: Jia, Huang.

Conflict of Interest Disclosures: All authors have completed and submitted the ICMJE Form for Disclosure of Potential Conflicts of Interest. Drs Jia and Huang reported having a significant financial interest in Optovue, Inc, a company that may have a commercial interest in the results of this research and technology. Dr Huang also reported having a financial interest in Carl Zeiss Meditec, Inc. These potential conflicts of interest have been reviewed and managed by Oregon Health & Science University. No other disclosures were reported.

Funding/Support: This study was supported by grant R01EY023285 from the National Institutes of Health and by an unrestricted grant from Research to Prevent Blindness.

Role of the Funder/Sponsor: The funders had no role in the design and conduct of the study; collection, management, analysis, or interpretation of the data; preparation, review, or approval of the manuscript; and decision to submit the manuscript for publication.

REFERENCES

1. Quigley HA, Broman AT. The number of people with glaucoma worldwide in 2010 and 2020. *Br J Ophthalmol*. 2006;90(3):262-267.
2. Leske MC. Open-angle glaucoma: an epidemiologic overview. *Ophthalmic Epidemiol*. 2007;14(4):166-172.
3. Congdon NG, Friedman DS, Lietman T. Important causes of visual impairment in the world today. *JAMA*. 2003;290(15):2057-2060.
4. Gillespie BW, Musch DC, Guire KE, et al; CIGTS (Collaborative Initial Glaucoma Treatment Study) Study Group. The Collaborative Initial Glaucoma Treatment Study: baseline visual field and test-retest variability. *Invest Ophthalmol Vis Sci*. 2003;44(6):2613-2620.
5. Tanna AP, Bandi JR, Budenz DL, et al. Interobserver agreement and intraobserver reproducibility of the subjective determination of glaucomatous visual field progression. *Ophthalmology*. 2011;118(1):60-65.
6. Abadia B, Ferreras A, Calvo P, et al. Relationship between spectral-domain optical coherence tomography and standard automated perimetry in healthy and glaucoma patients. *Biomed Res Int*. 2014;2014:514948.
7. Wu H, de Boer JF, Chen TC. Diagnostic capability of spectral-domain optical coherence tomography for glaucoma. *Am J Ophthalmol*. 2012;153(5):815-826.e2. doi:10.1016/j.ajo.2011.09.032.
8. Nilforushan N, Nassiri N, Moghimi S, et al. Structure-function relationships between spectral-domain OCT and standard achromatic perimetry. *Invest Ophthalmol Vis Sci*. 2012;53(6):2740-2748.
9. Garas A, Vargha P, Holló G. Comparison of diagnostic accuracy of the RTVue Fourier-domain OCT and the GDx-VCC/ECC polarimeter to detect glaucoma. *Eur J Ophthalmol*. 2012;22(1):45-54.
10. Sung KR, Lee S, Park SB, et al. Twenty-four hour ocular perfusion pressure fluctuation and risk of normal-tension glaucoma progression. *Invest Ophthalmol Vis Sci*. 2009;50(11):5266-5274.
11. Chang RT, Knight OJ, Feuer WJ, Budenz DL. Sensitivity and specificity of time-domain versus spectral-domain optical coherence tomography in diagnosing early to moderate glaucoma. *Ophthalmology*. 2009;116(12):2294-2299.
12. Mok KH, Lee VW, So KF. Retinal nerve fiber layer measurement by optical coherence tomography in glaucoma suspects with short-wavelength perimetry abnormalities. *J Glaucoma*. 2003;12(1):45-49.
13. El Beltagi TA, Bowd C, Boden C, et al. Retinal nerve fiber layer thickness measured with optical coherence tomography is related to visual function in glaucomatous eyes. *Ophthalmology*. 2003;110(11):2185-2191.
14. Williams ZY, Schuman JS, Gamell L, et al. Optical coherence tomography measurement of nerve fiber layer thickness and the likelihood of a visual field defect. *Am J Ophthalmol*. 2002;134(4):538-546.
15. Wong TY, Mitchell P. The eye in hypertension. *Lancet*. 2007;369(9559):425-435.
16. Harris A, Rechtman E, Siesky B, Jonescu-Cuypers C, McCranor L, Garzozzi HJ. The role of optic nerve blood flow in the pathogenesis of glaucoma. *Ophthalmol Clin North Am*. 2005;18(3):345-353, v.
17. Bonomi L, Marchini G, Marraffa M, Bernardi P, Morbio R, Varotto A. Vascular risk factors for primary open angle glaucoma: the Egna-Neumarkt study. *Ophthalmology*. 2000;107(7):1287-1293.
18. Jia Y, Wei E, Wang X, et al. Optical coherence tomography angiography of optic disc perfusion in glaucoma. *Ophthalmology*. 2014;121(7):1322-1332.
19. Flammer J. The vascular concept of glaucoma. *Surv Ophthalmol*. 1994;38(suppl):53-56.
20. Tobe LA, Harris A, Hussain RM, et al. The role of retrobulbar and retinal circulation on optic nerve head and retinal nerve fibre layer structure in patients with open-angle glaucoma over an 18-month period. *Br J Ophthalmol*. 2015;99(5):609-612.
21. Flammer J, Orgül S, Costa VP, et al. The impact of ocular blood flow in glaucoma. *Prog Retin Eye Res*. 2002;21(4):359-393.
22. Yokoyama Y, Aizawa N, Chiba N, et al. Significant correlations between optic nerve head microcirculation and visual field defects and nerve fiber layer loss in glaucoma patients with myopic glaucomatous disk. *Clin Ophthalmol*. 2011;5:1721-1727.

23. Piltz-seymour JR, Grunwald JE, Hariprasad SM, Dupont J. Optic nerve blood flow is diminished in eyes of primary open-angle glaucoma suspects. *Am J Ophthalmol*. 2001;132(1):63-69.
24. Michelson G, Langhans MJ, Groh MJ. Perfusion of the juxtapapillary retina and the neuroretinal rim area in primary open angle glaucoma. *J Glaucoma*. 1996;5(2):91-98.
25. Hamard P, Hamard H, Dufaux J, Quesnot S. Optic nerve head blood flow using a laser Doppler velocimeter and haemorheology in primary open angle glaucoma and normal pressure glaucoma. *Br J Ophthalmol*. 1994;78(6):449-453.
26. Nizankowska MH, Jamroz-Witkowska A, Asejczyk M. Evaluation analysis of blood flow of peripapillary area in glaucoma patients using scanning laser Doppler flowmetry [in Polish]. *Klin Oczna*. 2002;104(3-4):201-206.
27. Sugiyama TS, Kojima S, Ikeda T. Optic nerve head blood flow in glaucoma. Kofronova M, Kubena T, eds. *The Mystery of Glaucoma*. Rijeka, Croatia: InTech; 2011:209-218.
28. Kraus MF, Potsaid B, Mayer MA, et al. Motion correction in optical coherence tomography volumes on a per A-scan basis using orthogonal scan patterns. *Biomed Opt Express*. 2012;3(6):1182-1199.
29. Jia Y, Tan O, Tokayer J, et al. Split-spectrum amplitude-decorrelation angiography with optical coherence tomography. *Opt Express*. 2012;20(4):4710-4725.
30. Brusini P, Filacorda S. Enhanced Glaucoma Staging System (GSS 2) for classifying functional damage in glaucoma. *J Glaucoma*. 2006;15(1):40-46.
31. Hendargo HC, McNabb RP, Dhalla AH, Shepherd N, Izatt JA. Doppler velocity detection limitations in spectrometer-based versus swept-source optical coherence tomography. *Biomed Opt Express*. 2011;2(8):2175-2188.
32. Yaeoda K, Shirakashi M, Funaki S, Funaki H, Nakatsue T, Abe H. Measurement of microcirculation in the optic nerve head by laser speckle flowgraphy and scanning laser Doppler flowmetry. *Am J Ophthalmol*. 2000;129(6):734-739.
33. Yaeoda K, Shirakashi M, Fukushima A, et al. Relationship between optic nerve head microcirculation and visual field loss in glaucoma. *Acta Ophthalmol Scand*. 2003;81(3):253-259.
34. Luksch A, Lasta M, Polak K, et al. Twelve-hour reproducibility of retinal and optic nerve blood flow parameters in healthy individuals. *Acta Ophthalmol*. 2009;87(8):875-880.
35. Yaeoda K, Shirakashi M, Funaki S, et al. Measurement of microcirculation in optic nerve head by laser speckle flowgraphy in normal volunteers. *Am J Ophthalmol*. 2000;130(5):606-610.
36. Jonescu-Cuyppers CP, Harris A, Bartz-Schmidt KU, et al. Reproducibility of circadian retinal and optic nerve head blood flow measurements by Heidelberg retina flowmetry. *Br J Ophthalmol*. 2004;88(3):348-353.
37. Aizawa N, Yokoyama Y, Chiba N, et al. Reproducibility of retinal circulation measurements obtained using laser speckle flowgraphy-NAVI in patients with glaucoma. *Clin Ophthalmol*. 2011;5:1171-1176.
38. Shiga Y, Asano T, Kunikata H, et al. Relative flow volume, a novel blood flow index in the human retina derived from laser speckle flowgraphy. *Invest Ophthalmol Vis Sci*. 2014;55(6):3899-3904.
39. Lester M, Altieri M, Michelson G, Vittone P, Calabria G, Traverso CE. Intraobserver reproducibility of a two-dimensional mapping of the optic nerve head perfusion. *J Glaucoma*. 2002;11(6):488-492.
40. Jonescu-Cuyppers CP, Harris A, Wilson R, et al. Reproducibility of the Heidelberg retinal flowmeter in determining low perfusion areas in peripapillary retina. *Br J Ophthalmol*. 2004;88(10):1266-1269.
41. Kagemann L, Harris A, Chung HS, Evans D, Buck S, Martin B. Heidelberg retinal flowmetry: factors affecting blood flow measurement. *Br J Ophthalmol*. 1998;82(2):131-136.
42. Nicoleta MT, Hnik P, Schulzer M, Drance SM. Reproducibility of retinal and optic nerve head blood flow measurements with scanning laser Doppler flowmetry. *J Glaucoma*. 1997;6(3):157-164.
43. Hwang JC, Konduru R, Zhang X, et al. Relationship among visual field, blood flow, and neural structure measurements in glaucoma. *Invest Ophthalmol Vis Sci*. 2012;53(6):3020-3026.
44. Faingold D, Hudson C, Flanagan J, et al. Assessment of retinal hemodynamics with the Canon laser blood flowmeter after a single dose of 2% dorzolamide hydrochloride eyedrops. *Can J Ophthalmol*. 2004;39(5):506-510.
45. Janulevičienė I, Šiaudvytė L, Baršauskaitė R, et al. The effect of nebulized dorzolamide/timolol fixed combination mist versus drops on retrobulbar blood flow and intraocular pressure in glaucoma patients. *Medicina (Kaunas)*. 2013;49(7):310-314.
46. Seong GJ, Lee HK, Hong YJ. Effects of 0.005% latanoprost on optic nerve head and peripapillary retinal blood flow. *Ophthalmologica*. 1999;213(6):355-359.
47. Ohguro I, Ohguro H. The effects of a fixed combination of 0.5% timolol and 1% dorzolamide on optic nerve head blood circulation. *J Ocul Pharmacol Ther*. 2012;28(4):392-396.

Invited Commentary

Measuring Blood Flow So What?

Joel S. Schuman, MD

Ocular blood flow and optic nerve injury have been linked and have remained in a chicken-and-egg quandary since the 19th century. The question of which comes first remains unanswered, and the connection has not been revealed.

The concept of blood flow as it relates to glaucoma damage is clearly sound: less blood flow means more nerve damage, with causality unknown.¹⁻³ Imagine a reproducible, quantitative, objective method of assessment of optic nerve or retinal blood flow (global or local), particularly one that does not require an expert technician or observer. Such technology would be a great boon to glaucoma assessment for initial identification, monitoring, and detection of progression.

We have used various devices to assess ocular, optic nerve, and retinal blood flow over the years, with varying degrees of invasiveness, accuracy, and precision. From injectable dyes to

ultrasonography to laser, we have been hopeful and subsequently disappointed. Anticipating that a newly introduced method that performed well in the laboratory would be clinically applicable, we have been disappointed when it was poorly reproducible inherently or because of sensitivity to variations in acquisition of data.

Enter optical coherence tomography (OCT) angiography and blood flow measurement. With sophisticated direct and indirect algorithms, OCT can be used to map retinal and superficial optic nerve vasculature and blood flow. The article by Liu et al⁴ in this issue describes a method of extracting angiographic and blood flow information from OCT, as well as its application in discriminating glaucomatous from nonglaucomatous eyes and its association with conventional clinical variables. Liu et al show a correspondence of blood flow and vessel density with visual function as measured by standard achromatic automated perimetry. They demonstrate accept-



Related article page 1045