

 Open access • Journal Article • DOI:10.1080/05704928.2020.1749651

Optical spectroscopy-based imaging techniques for the diagnosis of breast cancer: A novel approach — [Source link](#)

Uttam M. Pal, Mansi Saxena, G. K. Anil Vishnu, Darshan Parsana ...+8 more authors

Institutions: Indian Institute of Science, Indraprastha Institute of Information Technology, Assam Medical College, University College London

Published on: 09 Apr 2020 - Applied Spectroscopy Reviews (Taylor & Francis)

Topics: Diffuse optical imaging

Related papers:

- [Elastic scattering spectroscopy scanning of sentinel lymph nodes for intraoperative diagnosis of breast cancer metastases](#)
- [Optical tomography: Development of a new medical imaging modality](#)
- [Simulating the performance of a time-of-flight transillumination imaging system](#)
- [Current applications of fetal cardiac imaging technology.](#)
- [A review of structural magnetic resonance neuroimaging](#)

Share this paper:    

View more about this paper here: <https://typeset.io/papers/optical-spectroscopy-based-imaging-techniques-for-the-50vnm1jozx>

Optical spectroscopy-based imaging techniques for the diagnosis of breast cancer: A novel approach

Uttam M. Pal,^a Mansi Saxena,^{a,b} Anil Vishnu GK,^{a,d} Darshan Parsana,^a Sarvani B.S.R.,^a Manoj Varma,^c Mahesh Jayachandra,^d Vishnu Kurpad,^e Deb Baruah,^f Gayatri Gogoi,^g Jayant S Vaidya,^h Hardik J. Pandya^{a,*}

^aDepartment of Electronic Systems Engineering, Indian Institute of Science, Bangalore, India

^bSignal processing and Bio-medical Imaging Lab, Indraprastha Institute of Information Technology Delhi, India

^cCentre for Nano Science and Engineering, Indian Institute of Science, Bangalore, India

^dCenter for BioSystems Science and Engineering, Indian Institute of Science, Bangalore, India

^eDepartment of Surgical Oncology, Sri Shankara Cancer Hospital and Research Center, Bangalore, India

^fDepartment of Radiology, Tezpur Medical College, Assam, India

^g Department of Pathology, Assam Medical College, Dibrugarh, Assam, India

^h Division of Surgery and Interventional Science, University College London, London, UK

Abstract:

There have been substantial advancements in optical spectroscopy-based imaging techniques in recent years. These developments can potentially herald a transformational change in the diagnostic pathway for diseases such as cancer. In this paper we review clinical and engineering aspects of novel optical spectroscopy-based imaging tools. We shall provide a comprehensive analysis of optical and non-optical spectroscopy-based breast cancer diagnosis techniques vis-à-vis the current standard techniques such as X-Ray mammography, ultrasonography and tissue biopsy. The recent advancements in optical spectroscopy-based imaging systems such as Transillumination Imaging (TI) and the various types of Diffuse Optical Imaging (DOI) systems (parallel-plate, bed-based, and handheld) are examined. The engineering aspects including mechanical, electronics, optics, automatic interpretation using artificial intelligence (AI), and ergonomics are discussed. The abilities of these new technologies for measuring several cancer biomarkers such as hemoglobin, water, lipid, collagen, oxygen saturation (SO₂), and tissue oxygenation index (TOI) are investigated. This article critically assesses the diagnostic ability and practical deployment of these new technologies to differentiate between the normal and cancerous tissue.

Keywords: Transillumination imaging, Diffuse optical imaging, Near-infrared spectroscopy, Breast cancer, Rapid diagnosis, Machine learning.

*Hardik J. Pandya, Email: hjpandya@iisc.ac.in

Introduction

Breast cancer is the most common cancer affecting women, with 2 million cases diagnosed annually and over 600,000 fatalities.(1, 2) In developed countries, the incidence is higher compared to developing countries; however, the case fatality rate in developed countries is lower than in developing countries.(1, 2) Data from Globocan 2018, IARC shows that out of 2,088,849 new breast cancer cases reported globally, the incidence rate in high income and low-middle income countries was 823,638 (39%) and 444,728 (21%) respectively; however, the mortality was 178,554 (8.5%) and 205,691 (9.8%) respectively.(1, 2) A significant reason for this difference is due to the diagnosis of breast cancer at an early stage in high-income countries; however, high level of population-based screening facilities for early detection of breast cancer in low-middle income countries are also materializing.(3, 4)

Currently, the methods for diagnosis of breast cancer, whether in a symptomatic or a screening situation are clinical breast examination, imaging with X-ray mammography and ultrasound as well as tissue diagnosis using a needle biopsy. The most common tool used for screening for breast cancer is X-ray mammography has been reported to have sensitivity and specificity of 77% and 97% respectively.(5) However, X-Ray mammography's sensitivity and specificity reduce significantly to 67% and 89% respectively for mammographically dense (relatively radiopaque) breasts.(6, 7) Moreover, X-Ray mammography is expensive, hospital-based, involves small radiation risks, and is less accurate in younger women, under 50 (8–13). Contrast enhanced Magnetic Resonance Imaging (MRI) is reported to have the highest sensitivity between 93% and 100% (14, 15); but is costly, the equipment is bulky and expensive, and needs to be hospital-based.

Ultrasonography (16–18) does not use ionizing radiation, but requires a skilled operator and is less accurate and less reproducible (19, 20) compared to X-ray mammography. Thermography is highly sensitive to ambient and temperature fluctuation, resulting in high false-positive rates, (21–23). low accuracy,(24) and is not used in clinical practice.

Diverse optical and non-optical spectroscopy techniques are used to diagnose breast cancer. The optical spectroscopy techniques involve Transillumination Imaging (TI), Diffuse Optical Imaging (DOI), Raman spectroscopy, and Fluorescence spectroscopy, while non-optical spectroscopy comprises of microwave spectroscopy, Nuclear Magnetic Resonance (NMR) spectroscopy, and molecular mass spectroscopy. The review gives a detailed analysis on optical spectroscopy techniques such as Transillumination Imaging and Diffuse Optical Imaging, which have the potential to be translated to rapid diagnostic tools for breast cancer.

Optical properties of tissue, e.g., absorption and scattering coefficients, have been studied thoroughly (25–28) where the differences in optical properties of breast cancer and normal tissue could potentially be used to diagnose cancer. Spectroscopy instruments measuring optical properties use visible to near-infrared (NIR) light (wavelength from 600 nm to 1100 nm) which propagates through the tissue. As it propagates, there is photon diffusion and scattering and the difference in local blood supply that accompanies cancer leads to higher absorption as compared to the adjacent normal tissue, resulting in distinguishable contrast between the tumor to normal tissue in the acquired image,(26, 29), which forms a basis for tumor detection. Such optical detection uses spectroscopy techniques such as Transillumination Imaging (TI) and Diffuse

Optical Imaging (DOI). Transillumination imaging has been studied using a commercial tool such as Breastlight (30, 31) and has been found to have varying sensitivities between 60% and 93% for breast cancer detection, primarily due to the dependency on the skill of the clinician to visually analyze the transillumination images. (29, 31–37) Mehnati et al. (38) and Edge et al. (39) critically review the transillumination imaging for breast screening and recommended performing more clinical trials.

Spectroscopy based imaging technique such as Diffuse Optical Imaging (DOI) has several theoretical advantages over simple transillumination. DOI can map the relative concentration of different tissue constituents such as oxygenated hemoglobin (HbO), deoxygenated hemoglobin (HbR), total hemoglobin (HbT), lipid (L), water (H₂O), and collagen (C) along with bulk tissue properties such as absorption coefficient (μ_a), reduced scattering coefficient (μ_s), oxygen saturation (SO₂), and tissue oxygenation index (TOI). These parameters can be used as multiple biomarkers to improve accuracy of delineation between normal and abnormal cases.(40–42) However, DOI techniques are still lab-based, expensive, and provide lower resolution images as compared to X-Ray mammography due to comparatively higher scattering of infrared photons within the breast tissue.(43) Tromberg et al. was the first to review the DOI system as a potential diagnostic technique,(44) followed by Godavarty et al., specifically proposing the handheld optical imaging systems as a potential tool for quick diagnosis of breast cancer in the field.(45) However, other configurations such as parallel-plate and bed-based techniques may have a better potential to be translated as a rapid diagnostic tool and are also discussed in this review.

The challenges of such an approach include variation of breast volume between patients, acquisition time, and automatic interpretation of results. In this review, we assess different cancer biomarkers that could be used to delineate between tumor and normal cases. The TI and DOI systems are analyzed with an engineering perspective, including its mechanical, electronics, optics, and ergonomic design. Detailed analysis is performed on different configurations of the lab based DOI systems giving higher sensitivity, albeit with a comparatively small patient sample size. The review also discusses the application of machine learning techniques in DOI based system for automated interpretation of results. Finally, the design of opto-electronics components, which plays a vital role in the overall development cost of the DOI system is discussed.

Low cost rapid diagnosis of breast cancer

Challenges involved in breast cancer diagnosis at low-resource settings

Various challenges of application of the diagnostic tool in low-resource settings include proficiency in imaging breasts with different volume and density, cost, portability, automatic interpretation of results, and optimization of parameters, e.g., time to examine each patient, adequate sensitivity, and specificity.

Breast volume and density variation

One of the pressing challenges when manufacturing a device for breast imaging is its adaptability (46) to accommodate the variation of breast volume between 200 and 1500cc and breast surface area varying from 100 to 500cm² (47–49) while maintaining sensitivity. Moreover, variation in breast texture between patients,(44, 50) or due to the menstrual cycle (51) is also a concern.

Accurate diagnosis of cancer even when the tumor is very small

The diagnostic tool should have high contrast and resolution to be adequately sensitive to detect cancer at an early stage.(52–55) However, the holy grail is the ability to differentiate between early cancers that may never grow and those that could potentially spread and be lethal. Additionally, while detecting these early cancers, the tool should be capable to distinguish between breast abnormalities due to the patient's age, physiological factors, hormonal changes and other abnormalities caused by cancer.(56, 57) Finally, for a tool to be useful, the sensitivity and specificity need to be high and well quantified.(43, 45, 58–60)

Reducing human input and cost

Highly trained human resource is necessary for the current approaches to breast cancer diagnosis, including surgeons, radiographers, radiologists, and pathologists. Furthermore, the intimate examination may lead to hesitancy in women with some socio-cultural backgrounds.(56, 61, 62) If a diagnostic tool requires much less human input, it may be more cost-effective, less time consuming as well as more acceptable in certain cultures. Therefore, a machine learning algorithm with segmentation and classification algorithms could help to differentiate between normal and abnormal cases automatically.

Portability

A tool that is portable and battery operated will facilitate its use in remote locations in the developed world as well as in low and middle-income countries.(29, 33–36, 38)

The complete wish-list of the requirements of a practical tool for the rapid diagnosis of breast cancer is shown in Table 1.

Table 1 List of requirements for breast cancer diagnostic tool.

SN	Description	References
1	Ability to adjust breast volume variation	(46)
2	Ability to adjust breast density variation	(50)
3	High contrast and resolution	(52–55)
4	Reducing human intervention	(56, 61, 62)
5	Low screening fee	(44, 112–120)
6	Screening time	(89, 100)
7	High sensitivity and specificity	(43, 45, 58–60)
8	Automatic interpretation of results using machine learning	(121–127)
9	Portable system and lightweight	(29, 33–36, 38)
10	Battery powered	(29, 33–36, 38)

Spectroscopy based techniques to diagnose breast cancer

The spectroscopy techniques can be classified as optical and non-optical techniques based on the operating wavelength and the type of source used in the spectroscopy technique.

The optical spectroscopy techniques include Transillumination Imaging (TI) technique, Diffuse Optical Imaging (DOI), Raman spectroscopy, and Fluorescence spectroscopy. Transillumination Imaging has been studied extensively for breast cancer screening in Egypt, Iran, Iraq, and Ghana. (29, 30, 32–36) While DOI is still a lab-based technique and portrayed as a promising technique to be used for breast cancer screening in the future. (44, 63) The DOI system is classified as parallel plate geometry, bed-based, and handheld probe techniques, based on the arrangement of the source and detector. Zhao et al. (64) compare bed-based DOI images (Fig. 1a-e) with MRI T2 images, while Gharthey et al. (29) visually analyze the transillumination image for breast cancer detection (Fig. 1f). More advanced optical spectroscopy techniques comprise of Raman spectroscopy and Fluorescence spectroscopy.

Raman spectroscopy is used to detect the Stokes and anti-Stokes scattered photons to quantify chemical composition. This technique is highly sensitive to detect breast cancer; however, it is highly sophisticated and expensive to be deployed at large scale. Fluorescence spectroscopy uses endogenous and exogenous chromophores to re-emit the absorbed photons with a distinct spectral response. Fluorescence spectroscopy using exogenous chromophores such as indocyanine green (ICG) needs to be injected intravenously, (65) which makes the technique invasive, and there are concerns of an allergic reaction due to the presence of sodium iodide in ICG. (66) Fluorescence

spectroscopy using endogenous chromophores such as collagen, elastin, and hemoglobin is non-invasive; however, this technique uses sophisticated optical tools to measure sensitive fluorescence signals, which makes it practically difficult to be used at large scale. (67–69)

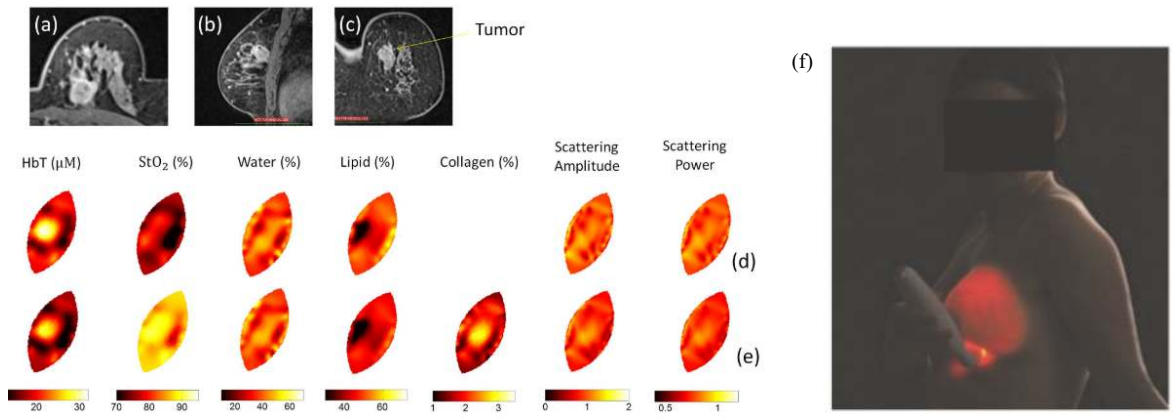


Fig. 1 (a-e) Zhao et al. (64) comparing the MRI T2 images (a-c) with the DOI (d, e) in the bed based DOI system. The tumour pointed in the MRI image (c) was quantified with higher hemoglobin and lower lipid concentration in DOI image (d, e), reprinted from Zhao et al. (64) with permission of OSA, Copyright 2017. (f) Transilluminated view of the breast observed by the clinician during the screening process as proposed by Ghartey et al. (29), where the cancer is represented by dark spots, reprinted from (29) with permission of Hindwai, Copyright 2018.

The non-optical spectroscopy techniques used to diagnose breast cancer includes microwave spectroscopy, Nuclear Magnetic Resonance (NMR) spectroscopy, and molecular mass spectrometry. The microwave spectroscopy uses non-ionizing microwave radiation; however, the technique suffers from low contrast between healthy and malignant fibroglandular tissues. Additionally, the shorter wavelength and significant tissue conductivity limits the penetration depth of the microwave radiation. (69–71) The NMR spectroscopy uses non-ionizing radiofrequency radiation to quantify the composition of chemical biomarkers within the breast tissue, such as phosphocholine, which is about ten times more in cancer tissues as compared to normal tissues. However, the NMR technique suffers from lower sensitivity, and the equipment is expensive. (72–74) The molecular mass spectrometry with the recent advancement of ambient ionization technology provides the molecular signature for differentiating between normal and cancerous regions within the breast; however, the technique is destructive and invasive, and hence appropriate only for advanced diagnosis of breast cancer, such as intraoperative margin assessment. (75–77) The complete analysis of different types of spectroscopy techniques are showcased in Table 2.

Table 2 Analysis of various spectroscopy techniques for diagnosis of breast cancer

Modality	Spectroscopy Techniques	Principle	Advantages	Disadvantages
Optical	Transillumination Imaging (29, 30, 32–36)	Absorption and scattering of visible light source to quantify difference of transmittance	Non-invasive, Inexpensive	Low accuracy, varying sensitivity
	Diffuse Optical Imaging (44, 63)	Visible and infrared absorption spectroscopy to quantify chemical composition	Non-invasive, relatively inexpensive	Low penetration depth, lower spatial resolution
	Raman Spectroscopy (65)	Stokes and anti-Stokes scattered photons to quantify chemical composition	Non-invasive, highly sensitive	Highly sophisticated, expensive and difficult to deploy
	Fluorescence Spectroscopy (66–68)	Re-emission of absorbed photons to differentiate normal and tumor regions	High sensitivity	Needs i.v. injection Exogenous chromophores can cause allergic reactions, endogenous chromophore are expensive
Non- Optical	Microwave Spectroscopy (69–71)	Microwave radiation to quantify the electric properties	Non-invasive	Low contrast between healthy and malignant fibroglandular tissue, and low penetration depth
	Nuclear Magnetic Resonance Spectroscopy (72–74)	RF radiation to quantify the chemical composition	Non-invasive	Low sensitivity and expensive
	Molecular Mass Spectrometry (75–77)	Ionizing tissue to measure molecular signature	Molecular level information, high sensitivity	Destructive technique and invasive.

Transillumination Imaging (TI) systems

The transillumination method has been extensively studied for breast cancer diagnosis, as TI based systems are cost-effective, portable and easy to operate.(29–36) In the transillumination method, the handheld probe (Fig. 2a) consisting of few LEDs, is placed under the breast (Fig. 2b), while the skilled clinician analyzes the transilluminated view of the breast (Fig. 1f).(29) The transilluminated view consists of the light propagating through the breast tissue and the blood vessels. As the LEDs are operated at about 620 nm, overlapping with the absorption peak of red blood cells, the blood vessels appear as dark and tissue appears as light pink or red. In addition to any abnormality of blood vessel diameter, dark patches in the breast tissue due to an abnormality also become a basis for tumor detection.

Vaidya et al. (31) reported the use of Breastlight from a survey of 1500 women, where 1054 returned with their feedback, out of which 3 had mammogram and 1 was diagnosed with cancer. They found that the use of Breastlight did not raise the anxiety nor did it detract women from seeking medical advice. Iwuchukwu et al. (37) screened 300 women and detected 12 out of 18 malignant cases using Breastlight in a screening performed in UK with a sensitivity and specificity of 67% and 85% respectively. Labib et al. (35) screened 310 women in Egypt, reporting



Fig. 2 Transilluminated optical screening system. (a) Breast-I and Breastlight handheld based probes, (b) Handheld probe placed under the breast in the screening process as proposed by Gharthey et al.(29), reprinted from (29) with permission of Hindwai, Copyright 2018.

sensitivity as high as 93% and specificity of 73.7%. Al-Alwan et al. (32) screened 150 women in Iraq, reported a sensitivity of 80.56%. However, the device reported a low specificity of 53.47% and high false positives (46.53%). Shiryazdi et al. (34, 36) screened 500 women in Iran, specifically young women (<30), for whom the use of mammography is inadvisable. The sensitivity of 60.3% and specificity of 92.5% was reported for the device and domiciliary use of the device was proposed as an alternative technique to BSE. Aliasghar et al. (33) screened 100 samples in Iraq and suggested that the technique shouldn't be used exclusively due to high false-positive (46%) and low sensitivity (66.66%), specificity (51.06%) and accuracy (52%). Gharthey et al. (29) screened 2204 women in Ghana and reported a sensitivity of 92.3% with the device as compared to 73% with CBE; however, specificity remains unreported (Fig. 5a-c). We agree with other authors (38, 39) that there is a need for more clinical trials before using the transillumination method as a rapid diagnostic tool as it does offer a potentially accurate tool that is inexpensive and very easy to use. The varying sensitivity showcases the need for the rapid diagnostic tool which can delineate between normal and abnormal breast based on biomarkers such as hemoglobin, lipids, collagen, water and tissue properties such as absorption coefficient, reduced scattering coefficient, oxygen saturation, and tissue oxygenation index. The sample size, age group of subjects, and performance parameters of the studies discussed in this section are tabulated in Table 3.

Table 3. Sensitivity and specificity of transillumination based optical imaging tool

Ref	N	Age group (years)	Sensitivity	Specificity
Vaidya et al. (2009) (31)	1054	543 were less than 50 years and 511 were pre menopause	NA	NA
Iwuchukwu et al. (2010) (37)	300	NA	67%	85%
Labib et al. (2013) (35)	310	18 – 81 (46.3±12.4)	93.0%	73.7%
Al-Alwan et al. (2015) (32)	150	10 – 69	80.56%	53.47%
Shiryazdi et al. (2015) (34, 36)	500	19 – 49 (37±4.2)	60.3%	92.5%
Aliasghar et al. (2017) (33)	100	NA	66.66%	51.06%
Ghartey et al. (2018) (29)	2204	34, 41*	92.3%	NA

* Mean age in two different demographic groups

210 Diffuse Optical Imaging (DOI) systems

211 The DOI systems are based on either continuous wave (CW), frequency domain (FD), or time-
 212 domain (TD) operation. However, considering the cost-effective requirement of rapid diagnosis,
 213 we only review those CW and FD systems performed on large-scale clinical trials, while averting
 214 the TD systems due to its comparatively higher development cost.(78) The CW system can be
 215 developed with lower instrumentation cost as compared to the FD system, primarily due to the
 216 requirement of network analyzer, advance laser/led driver, and bias network.(79) In this section,
 217 we analyze the parallel plate, bed-based and handheld DOI systems tested on large sample size *in-*
 218 *vivo* detection of breast cancer with the perspective of rapid diagnosis and summarized in Table 4.

219 Parallel plate-based DOI system

220 The parallel plate technique involves an array of source and detectors attached to two adjacent
 221 parallel plates with a distance separating them for the placement of breast, similar to the parallel
 222 plate technique of X-Ray mammography. The patient can sit on a chair or stand upright while
 223 placing the breast within the expanded parallel plate. The parallel plate compresses the breast with
 224 a specific pressure to begin the acquisition process.

225 Carp et al. (80) assessed a total of 17 patients by performing compression induced
 226 hemodynamic analysis, with the discriminating factor as total hemoglobin (higher in tumor),
 227 oxygenated hemoglobin, and saturated oxygen. The sensitivity and specificity of the system was

reported to be 88% and 70% respectively. The bottom plate of the system was fixed, while the upper plate could be moved vertically, with forces ranging from 0 to 55 N, to study compression dependent hemodynamics (Fig. 3a-b). The compression was measured using strain gauge fixed to the upper plate. The system used a periodic cycle to perform coupled continuous wave (CW) and frequency domain (FD) operation, with a total acquisition time of about 7 mins. Mastanduno et al. (81) dealt explicitly with the variation in breast volume by adjusting to breasts with different cup sizes. The system involved three parallel plates with 6 degrees of freedom to consider different breast volume.

Anderson et al. (82) specifically developed a cost-effective CW system, most suitable for rapid diagnosis of breast cancer. An assessment of 26 patients was reported by optical characterization of breast and creation of breast maps. As compared to the surrounding tissues, the tumor regions had a higher concentration of hemoglobin and water, along with lower lipid concentration and oxygen saturation. Anderson et al. (83) further assessed 80 patients with oxygenation saturation maps and used the Dice coefficient as a main discriminating factor.




Fig. 3. Parallel plate based DOI system performing *in-vivo* clinical studies: (a) Instrumentation and (b) Imaging system of the parallel plate system by Carp et al. (80), reprinted from (80) with permission of OSA, Copyright 2013.

Bed based DOI system

The bed-based systems are adapted from the parallel plate configuration, where the patient lies in a prone position with breast pendant in a chamber enclosed by parallel plates. The breast is usually immersed in a scattering fluid, having a similar refractive index that of fatty breast tissue.(84) The chamber holding the fluid and breast is surrounded by an array of sources and detectors, embedded within the plates. The fluid mainly consists of intralipid and/or India ink which has a similar refractive index to that of breast tissue so that the photons getting scattered within the breast do not refract while propagating away from the breast. Additionally, there are configurations,(85)

replacing the scattering fluid with an arrangement of optical fibers to get direct contact with the breast surface.

The system proposed by Choe et al. (41) consisted of a fixed plate and a movable compression plate. Based on the size of the breast, the compression plate could be moved between 5.5 cm to 7.5 cm (Fig. 4d). The total acquisition time for a single breast took about 12 mins. The study assessed a total of 51 patients and reported the sensitivity and specificity of 98% and 90% respectively. The cancer regions were reported higher total hemoglobin, oxygenated hemoglobin, and scattering coefficient as compared to normal cases. Busch et al. (86) expanded Choe et al. system (41) and converted the 2D images into 3D DOT (Diffuse Optical Tomography) images using multiparameter, multivoxel and multisubject statistical analysis to overcome the image artifacts. The study reported the assessment of 35 patients with a sensitivity and specificity of 89% and 94%, with HbT contrast ratio (T/N) cutoff of 1.2.

The system proposed by Wang, James et al. (87) reported higher absorption coefficient, reduced scattering coefficient, and refractive index in tumor regions as compared to the surrounding regions. The system was based on the work by Iftimia et al.,(88) which took about 4 minutes for the acquisition of an image. The specificity and accuracy of the system developed by Iftimia et al., (88) was improved by Wang, James et al. (87) by the employment of machine learning algorithm (support vector machine classification) for automated delineation of normal and tumor cases. The study (87) assessed a total of 33 patients and reported the sensitivity and specificity of 81.8% and 91.7% respectively.

Pogue et al. (25) assessed a total of 39 healthy patients and quantified hemoglobin concentration, oxygen saturation, water, absorption, and scattering coefficient. The system used optical fibers to deliver the light source directly to the breast surface. Sixteen optical fibers were arranged circularly to cover the breast surface uniformly. The variation of breast volume was adjusted by varying the diameter of this circular arrangement. The acquisition time for a single breast took about 5 mins. Force transducers were placed explicitly for safety as well to measure optical images based on different applied pressures. Wang, Jia et al. (85) extended this approach by using a coupled frequency domain (FD) and continuous wave (CW) operation along with a broadband light source with a reasonable development cost. The study reported more accurate tissue constituents with this coupled approach as compared to FD data alone. The study assessed 9 patients and reported 1.5 to 2-fold increase in water and hemoglobin concentration in the tumor

as compared to the surrounding normal region. The study also reported lower lipid concentration in lipid as compared to the normal region.

Ban et al. (89) introduced real-time camera-based DOT technique to quantify tissue properties along with 3D image reconstruction of the breast. The camera could detect any error rising due to motion artifacts. The system was extended by Cochran et al. (90), an assessment of 222 patients was done and the accuracy of 86% was reported. The FD system developed by Zhao et al. (91) consisted of a movable football-shaped fiber breast interface to facilitate different breast volume. The system reported an assessment of 11 patients with hemoglobin and water contrast ratios of 1.4 and 1.2 respectively (Fig. 4a-c). The acquisition time in this system of about 90 sec was reduced to 55 sec in the updated system (64) by applying a prospective gain setting scheme. The updated system reported an increase of contrast in total hemoglobin to 1.7 by the inclusion of the collagen concentration in image reconstruction.

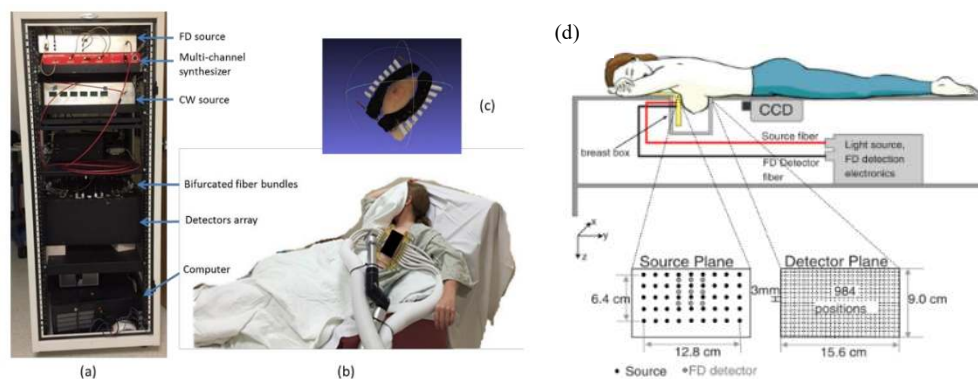


Fig. 4 Different configurations of bed-based systems performing *in-vivo* clinical studies: (a) The NIRST imaging system proposed by Zhao et al. (91), (b) The patient lies in a supine position for taking the measurement, and (c) Interface of fiber with the breast surface, reprinted from Zhao et al.(91) with permission of SPIE, Copyright 2016. (d) Patient lies in the prone position and places the breast in the breast box consisting of intralipid scattering agent and India ink absorption agent in the system by Choe et al. (41), reprinted from Choe et al. (41) with permission of SPIE, Copyright 2009.

Handheld based DOI system

Unlike X-Ray mammography, the Diffuse Optical Imaging (DOI) system use smaller light sources and detectors that can be configured within a handheld system. The handheld probe is scanned point by point to cover the complete breast surface area. This process increases acquisition time for both breasts, and hence, the handheld device is primarily used in conjunction with complementary techniques, e.g., Ultrasound (42, 92, 93) and X-Ray.(94) With the help of such

complementary techniques, the operator can focus on a specific suspicious breast area for higher image contrast and resolution.

Zhu et al. (92) assessed a total of 19 patients with an ultrasound-guided diffuse optical imaging handheld probe. The study reported a 2-fold higher total hemoglobin in the tumor as compared to the benign region. The system first localizes the lesion using ultrasound and then scans the suspected region at higher resolution using DOI. Chen et al. (93) expanded the system proposed by Zhu et al., by reducing the weight and converting it into a portable system weighing ~26.5 lb (12 kg) with an acquisition time of about 5 minutes. Cheng et al. (95) assessed a total of 50 patients with a real-time time continuous-wave handheld DOI probe, and reported the sensitivity and specificity of 92% and 67% respectively. The study reported a higher total hemoglobin and oxygen saturation in tumor cases as compared to the normal.

The study by Chance et al. (96) used a multiwavelength LED at the center circularly surrounded by eight detectors with a radius of 4 cm. This arrangement gave a circular measurement area with a diameter of about 9 cm over the breast. The integration of a pressure transducer preserved the accuracy by maintaining the pressure of ~3 mmHg throughout the measurement process. The study used hemoglobin concentration as a main discriminating factor to identify the cancerous region. The system assessed a total of 116 patients and reported the sensitivity and specificity of 96% and 93% respectively.

Cerussi et al. (96) proposed the handheld probe system which consisted of the source optical fiber attached to a movable plastic attachment along with the casing of the probe consisting of an Avalanche photodiode (APD) detector. This arrangement helped to measure data at different source-detector distances. The point by point scan was performed on a line with a spacing of 10 mm, and source-detector separation of 28 mm. The study assessed a total of 58 patients, and reported higher water, oxy- and deoxygenated hemoglobin (more than 50% each), and lower lipid (~ 20%) concentration in the tumor as compared to normal region. The study also reported TOI with a 2-fold contrast of malignant tissue as compared to the surrounding regions. The system required prior knowledge of tumor location through X-ray mammography. The system developed by O'Sullivan et al. (79) extended Cerussi et al. work, by printing the PCB circuit thereby replacing the network analyzer with equivalent accuracy while proving 5x faster acquisition time and 10x less cost (Fig 5d-f).

Kukreti et al. (97) introduced self-referencing differential spectroscopy technique to report an absence or presence of molecular disposition in spectral fingerprint rather than the molecular concentration. The study retrospectively assessed a total of 60 patients and used malignancy index (MI) as a discriminating factor, which was higher in the malignant as compared to benign. The study reported a sensitivity and specificity of 91% and 94% respectively. The system required the location of the tumor beforehand using an ultrasound technique, and the probe was vertically scanned with a spacing of 10 mm across the tumor. The acquisition time for each spatial location was ~10 seconds. Zhang et al. (94) compared the DOT with Ultrasound Elastography (UE) and X-Ray Mammography. The study assessed a total of 67 patients and reported a sensitivity and specificity of DOT as 95.4% and 73.44% respectively, UE as 81.82% and 93.33% respectively, and Mammography as 68.18% and 57.78% respectively. The DOT and UE were reported to have higher specificity and accuracy as compared to conventional mammography. The DOT images were recorded using a scanner (Xinao-MDT, Beijing, China) and used discriminating factors as total hemoglobin concentration (high in tumor) and oxygen saturation (low in tumor).

Gonzalez et al. (98, 99) introduced a fork design (Gen-2 system) which performed sequential and simultaneous bilateral reflectance and transmittance measurements. The probe head (4 x 5 cm²) was flexible to conform to breast tissue surfaces with minimal compression. The probe head was integrated with 3 source fibers and 96 detector fiber connected to the laser source and ICCD camera. Erickson et al. (100) compared the Gen-2 system proposed by Gonzalez et al. (98, 99) with an updated Gen-1 system, using a flexible probe head (4 x 9 cm²) with 6 source fibers and 165 detector fibers. Real-time images with an updated Gen-1 system were gathered with processing time for each image of about 2 seconds. The study by Erickson et al. (100) assessed a total of 5 patients using the discriminating factor as total hemoglobin concentration (higher in tumor).

Zhu et al. (42) assessed a total of 288 patients based on the different stages of breast cancer (T1, T2, T4, Tis), and reported a sensitivity and specificity of 96.6%–100% and 77.3%–83.3% respectively. Mostafa et al. (101) proposed a real-time semi-automated process that automatically identified tumor location and fed to the optical imaging reconstruction process. The study assessed

a total of 20 patients and reported the discriminating factor as total hemoglobin concentration (high in tumor).

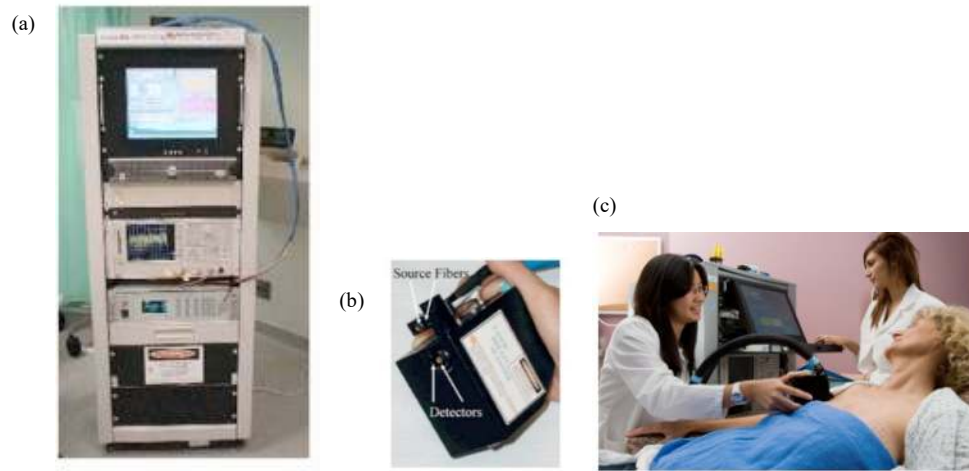


Fig. 5 Different hand-held devices performing *in-vivo* clinical studies: (a) Broadband DOSI system constituting of instrumentation as proposed by O'Sullivan et al. (79) and Cerussi et al. (128), (b) Handheld probe, and (c) Patient lying in supine position for the measurement, reprinted from O'Sullivan et al. (79) with permission of SPIE, Copyright 2012.

Challenges of different configurations of DOI systems for routine diagnostic applications.

The parallel plate techniques were the earliest studied configuration, because of its similarity with mammography. The advantage of using this technique is the availability of the sophisticated mechanical rail system that can facilitate breast volume variation. However, a significant challenge faced by the parallel plate is the breast density variation of the compressed breast within the plate area. When the breast is under compression using parallel plates, the orthogonal density towards the chest will be relatively high. This gradient in density must be taken into consideration while performing image reconstruction. Additionally, the compression of the breast causes pain and inconvenience to the patient. (82) Considering a large-scale clinical trial, the mechanical parts of the system will be more prone to failure. Moreover, due to the mechanical arrangement of the vertical railing, subtle vibration due to motion artifacts while taking measurement also induces errors in the acquired image. (80)

Table 4. Analysis of DOI systems performed on large sample size with rapid diagnostic perspective

Ref	Operation type	Acquisition time	ML	N	Sensitivity	Specificity	Tissue types	DF (T/N)	Comparative analysis
Parallel plate									
Carp et al., 2013 (80)	CW, FD	~ 7 min	No	17	88%	70%	Normal and IDC	HbT ↑	Single biomarker, low specificity, and high cost
Anderson et al., 2015 (82)	CW	4 - 10 min	No	26	NA	NA	IDC, DCIS	HbT ↑ H ₂ O ↑ L ↓	Cost effective and rapid acquisition
Anderson et al., 2016 (83)	CW	NA	No	80	NA	NA	IDC, DCIS, ILC, and LCIS	HbT ↑ H ₂ O ↑ L ↓ SO ₂ ↓	Cost effective and multiple biomarkers
Bed based									
Choe et al., 2009 (41)	FD	8 to 12 mins per breast	No	51	98% (95% CI=87–100%)	90% (95% CI of wide range: 55–100%)	IDC, DCIS, ILC, LCIS, FB, cyst and FBC.	HbT ↑ HbO ↑ μ _s ↑	High sensitivity, high specificity, but with large acquisition time and costly
Ifimtia et al., 2003 (88) and Wang,James et al., 2008 (87)	CW	4 min	Yes	33	81.8 %	91.7%	Benign and IDC	A ↑ μ _s ↑ η ↑	Rapid acquisition, high specificity, integrated with ML, but costly
Busch et al., 2010 (86)	FD	8 to 12 mins per breast	No	35	89%	94%	Benign, IDC, DCIS, and ILC	HbT ↑	High sensitivity, high specificity, but large acquisition time and costly
Wang, Jia et al., 2010 (85)	FD, CW	8 min	No	9	RS	RS	Normal, DCIS, IDC, and IFC	HbT ↑ H ₂ O ↑ L ↓	Reasonable development cost, but low sample size.
Zhao et al., 2016 (91)	CW, FD	90 sec	No	11	RS	RS	Normal and IDC	HbT ↑ H ₂ O ↑	Rapid acquisition, but low sample size
Cochran et al., 2018 (90)	CW, FD	Real-Time	Yes	222	Accuracy of 86%		Benign, IDC, ILC, DCIS, and LCIS	HbR ↑ TOI ↑ H ₂ O ↑ SO ₂ ↑	Real time, integrated with ML, high accuracy, and large sample size.
Handheld									
Zhu et al., 2003 (92)	FD	~13 min	No	19	NA	NA	IC, ADH, LCIS, FB, and FBC	HbT ↑	Single biomarker and low sample size
Cheng et al.,2003 (95)	CW	Real-Time	No	50	92%	67%	Benign, IDC, and DCIS	HbT ↑ SO ₂ ↑	Real time, but low specificity
Chance et al., 2005 (96)	CW	~10 min	No	116	96%	93%	Normal and cancer	HbT ↑ SO ₂ ↓	Large sample size, high sensitivity, high specificity, but with large acquisition time
Cerussi et al., 2006 (128)	FD, CW	20 sec at each spatial location	No	58	NA	NA	Benign and IDC	H ₂ O ↑ HbO ↑ HbR ↑ L ↓ TOI ↑	No data on sensitivity and specificity and costly
Kukreti et al., 2009 (97)	FD, CW	10 sec at each spatial location	No	60	91%	94%	Benign and cancer	MI ↑	High sensitivity, high specificity, but costly
Zhang et al., 2014 (94)	FD	NA	No	67	95.45%	73.33%	FB, FBC, cyst, IDC, CP and MC	HbT ↑ SO ₂ ↓	Low specificity and costly
Erickson et al., 2015 (100)	CW	Real-Time	No	5	RS	RS	IDC, DCIS, MTC	HbT ↑	Low sample size with no data about sensitivity and specificity
Zhu et al., 2016 (42)	NA	5 sec	No	288	96.6%–100%	77.3%–83.3%	Benign, Tis, T1, T2, T3, and T4.	HbT ↑	Large sample size, high sensitivity, high specificity, and rapid acquisition
Mostafa et al., 2017 (101)	FD	Real-Time	No	20	NA	NA	Benign, IDC, DCIS, LC	HbT ↑	Real time, but no data about sensitivity and specificity

RS – Retrospective study, DF(T/N) – Discriminating factor with ratio of tumor to normal, IDC – Invasive ductal carcinoma, DCIS – Ductal carcinoma in-situ, LC – Lobular carcinoma, ILC – Invasive lobular carcinoma, IC – Invasive carcinoma, FB – Fibroadenoma, ICC - Intracystic carcinoma, MP - malignant phyllodes, FBC – Fibrocystic, IFC – Inflammatory carcinoma, IMC - Invasive mammary carcinoma, ADH – Atypical ductal hyperplasia, CP - Cystosarcoma phyllodes, MTC - Metastatic carcinoma, and MC - Mucinous carcinoma, BV – Blood volume, η – Refractive index.

The patient lying in a bed-based system is in a relaxed position, whether in a supine or prone position. Moreover, the bed-based system has been reported to have sensitivity and specificity of more than 90%.(41, 86) However, a significant challenge using a bed based system is using matching fluid-based chambers,(102, 103) which is susceptible to spilling and leakages. Additionally, due to the use of fluid, the issue of hygiene and cleanliness is also a concern. Replacing the fluid-based chamber with a motion-based contact technique requires maintaining optimal pressure and uniform contact with the breast surface, which is a challenge. Additionally, considering large-scale clinical trial for rapid diagnosis, the mechanical motion-based contact technique for different breast size is more prone to failure. Finally, the requirement of a specialized bed with chambers makes the system bulky and decreases portability. The bed-based system can be configured in a modular way to be deployed during the rapid diagnosis. Moreover, with the recent advancements of the bed-based system, taking less than 1 minute (64, 89) to perform imaging, the bed-based techniques seem to be a promising configuration to be used as a rapid diagnostic tool.

The handheld system is a highly researched configuration and a promising technique to be used in breast cancer diagnosis,(45) especially with the recent advancement of real-time imaging of the breast.(95, 100, 101) The handheld systems are easy to use, portable and have been reported with more than 90% sensitivity (42, 94–97) and more than 90% specificity.(96, 97) However, the major challenge is the manual scanning process, where the operator has to scan point-by-point over the breast. The diagnosis involving large sample size, an operator taking such measurements throughout the day would tend to make mistakes and may skip the scanning points due to monotony, which can lead to errors while reconstructing the images. Moreover, the non-uniformity of breast density/volume is a challenge for handheld devices. As the number of sources is limited and the operator must vary the scanning location manually, it is a challenge to automatically vary the intensity of the source based on the breast density/volume, i.e., higher density orthogonally towards the chest. Besides, the manual scanning process requires firm pressure to be applied by the operator (~3mm Hg) to obtain the required contact and manual control over this variable by the operator can lead to inaccurate image.(96) The handheld system is a promising technique to be used for rapid diagnosis; however, due to limited measurement area, the tool can be advantageous and reliable along with complementary techniques such as ultrasound (42, 92, 93) and mammography.(94)

Automatic interpretation of results using machine learning

Transillumination imaging (TI) is performed by a visual interpretation of an image by a skilled clinician; however, machine learning algorithms are yet to be applied in TI. While, the automatic interpretation or detection of breast cancer using DOI has been performed by reconstructing optical signals into images by inverse modeling the diffusion effect, as showcased in-depth in this section. Segmentation and classification of the reconstructed images are difficult due to the presence of noise, motion artifacts, and image degradation because of short acquisition time. Researchers have used several machine learning methods to tackle the above problems and achieve high efficiency while performing different segmentation and classification algorithms, as tabulated in Table 5. Considering the rapid diagnosis, the machine learning algorithm needs to choose between these methods for high quality and low artifact reconstruction of images.

In the latest development, McKinney et al. (104) used three independent Deep Learning Methods (DLM) while training each method with data augmentation applied to each image. Each model reported a cancer risk score between 0 and 1, while the final prediction was based on the mean of the predictions from each of these models. The study reported the use of AI resulted in a reduction of 1.21% in false-positive and 2.7% in false-negative in datasets from UK. Wang et al. (105) utilized absorption and scattering attributes along with a refractive index to isolate the lesion area. Based on mean coefficients and lesion area properties, and with the help of Support Vector Machine SVM, the classification of the lesion as cancerous or non-cancerous was achieved with an accuracy of 88.6%. Entropy and iterative selective methods rather than simple predetermined threshold methods improved performance. Taroni et al. (40) examined different tissue composition, i.e., water, hemoglobin, lipid, collagen, and their absorption parameters as potential input features to a discrete Adaboost classifier to identify malignant invasive ductal carcinomas. The type of collagen and the type of lesion had a significant impact on the performance of the Adaboost classifier.(106)

Cochran et al. (90) used diffuse optical biomarkers' optical properties in the frequency domain as a feature to classify ductal and lobular invasive carcinomas against benign lesions using Logistic Regression. According to Breneisen et al.,(107) the Energy Spectral Density (ESD) can be used to differentiate malignant and healthy tissue, due to scattering properties of the tissue. The

respective ESDs of the scattered incident light was fed to a feed-forward Neural Network (NN), which determined the grade of the lesion. A secondary NN was developed to represent as a “critic” for indecisive cases from the primary feed-forward NN.

Barbour et al. (108) investigated hemoglobin signals from the tissue to characterize the nature of the tissue. The oxygenated state and saturation of hemoglobin were given as input features for finite Markov Chain to determine the grade of the lesion. Zhang et al. (109) used Diffuse Correlation Spectroscopy (DCS) to estimate the Blood Flow Index (BFI), associated with tumors. The study compared three different methods: L1 norm, L2 Norm, and Support Vector Regression (SVR) to estimate BFI, SVR proved to be most efficient with an error rate of 2.23%.

Table 5. Machine Learning used in Diffuse Optical imaging tools to detect breast cancer

Ref	Features	Methods	Classes	N	Accuracy (%)	Sensitivity (%)	Specificity (%)
(105)	Attributes extracted from absorption, scattering, and refractive index images	Support Vector Machine	Cancer and non-cancer	33	88.6	81.8	91.7
(40)	Absorption differences at seven wavelengths	Discrete Boosting algorithm	Benign and malignant	84	NA	80.5 ± 2.3	84.1 ± 5.5
(106)	Absorption differences at seven wavelengths	Discrete Boosting algorithm	Benign and malignant	84	NA	88	79
(90)	Absorption and scattering properties from the frequency domain.	Logistic Regression	Benign and malignant	222	86	NA	NA
(107)	Energy Spectral Density	Feed-forward NN	Probably benign and highly suspicious malignant	NA	NA	NA	NA
(108)	HbO, HbT, SO ₂ , tissue-Hb oxygen exchange	Finite Markov Chain	Benign and malignant	NA	NA	NA	NA
(109)	Blood Flow Index from DCS Signals	Support Vector Regression	-	10	NA	ER:2.23%	NA
(104)	Cancer risk score	Three independent Deep Learning Method	Benign and malignant	28,953	NA	66.66*	96.26*

* AI as second reader

Electronic design for DOI systems

The critical aspect of imaging is the contrast, resolution, and penetration depth. The contrast and resolution of the image depend on the number and type of sources/detectors and spacing between them. LASER or LED is used as a light source, the former generating narrower beamwidth and bandwidth; however, its thermal reliability is a concern. While, LED is comparatively cost-

Table 6. Electronic design specifications of DOI *in-vivo* breast cancer imaging system

Ref	Operation	Source Type	Source power	Detector	Wavelength (nm)
Parallel plate					
(80)	FD: 110 MHz	Laser diode	2mW (FD), 10mW (CW)	PMT	635, 670, 690, 752, 758, 810 and 830
(81)	CW, FD	Laser diode	NA	PMT	660 to 850 and 900 to 950
(82, 83)	CW	Arc Lamp	NA	CCD	650 nm - 950 nm
Bed based					
(41)	FD: 70 MHz	Laser diode	NA	CCD	FD: 690, 750, 786, and 830. CW: 650 and 905
(88, 105)	CW	Laser diode	100 mW	PMT	785, 808, and 830 nm
(86)	FD	Laser diode	NA	CCD	650 - 950 nm
(85)	FD: 100 MHz	Laser diode	NA	PMT	FD: 661, 761, 785, 808, 826, and 849 CW: 903, 912, and 948
(89, 90)	CW, FD: 70 MHz	Laser diode	16 mW	CCD	660, 690, 785, 808, and 830 nm
(64, 91)	CW, FD: 100 MHz	Laser diode	< 120 mW	PMT and PD	661, 785 and 826nm
Handheld					
(92)	FD: 140 MHz	Laser diode	NA	PMT	780 and 830
(95)	CW	Laser diode	100 mW	Si PD	690 and 830 nm
(96)	CW	LED	10 mA	Si PD	760 and 850
(128)	FD: 50 to 500 MHz	Laser diode	20 mW	APD	661, 686, 786, 808, 822, and 852
(97)	FD, CW	FD: Laser diode, CW: tungsten-halogen	20 mW	APD, Spectrometer	FD: 660, 690, 780, 808, 830, and 850.
(94)	NA	Laser diode	NA	NA	NA
(100)	CW	Laser diode	< 5 mW	ICCD	785
(42)	NA	NA	NA	PMT	740, 780, 808, and 830 nm
(101)	FD: 140 MHz	NA	NA	PMT	740, 780, 808, and 830 nm

PMT - Photomultiplier tube, CMOS - Complementary metal-oxide-semiconductor, APD - Avalanche photodiode (APD), Si PD - Silicon photodiode, CCD - coupled charge-coupled device), ICCD - Intensified charge-coupled device (ICCD)

effective, reliable, and robust, but has wider beamwidth and bandwidth. Additionally, a critical challenge is the unavailability of a single detector that is capable to detect light of different wavelengths with the same absolute sensitivity.

The choice of the operating wavelength is based on characterizing specific tissue biomarker, for e.g., selective absorption of oxygenated hemoglobin and deoxygenated hemoglobin occurs between 635nm and 785, lipid absorption peak around 920 nm, water absorption peak around 975 nm, and collagen absorption peak around 1060 nm.(40, 110) Additionally, considering rapid diagnosis, the development cost of the system should be minimal, while being portable. The

TD systems (78, 84, 111) reportedly have higher cost due to expensive detector and source/detector driving system; however, FD (64, 89–91, 97) systems are reported as an alternative, still requiring costly instruments such as source modulation driving circuit and biasing network; while low-cost alternative are considered as CW (81–83, 88, 105) system albeit with lower information (i.e. no tissue scattering property). The electronic design specifications for different configurations, such as parallel plate, bed-based, and handheld probes, are tabulated in Table 6.

Summary

Breast cancer causes the most cancer deaths in middle aged women. Diagnosis of breast cancer using current tools such as X-Ray mammography, ultrasounography and MRI while modestly accurate is complex and expensive. Thermography is not used in clinical practice and non-optical spectroscopy techniques such as microwave spectroscopy, NMR spectroscopy, and molecular mass spectrometry have inherent or practical disadvantages making them unsuitable as a rapid diagnostic tool. Development of an inexpensive, portable tool that requires the least amount of human expertise to operate could greatly improve the accessibility of women to high-quality diagnosis of this dreaded disease. Optical spectroscopy-based imaging modalities appear to be eminently suitable for the rapid diagnosis of breast cancer. The elementary optical spectroscopy-based techniques including Transillumination Imaging (TI) and Diffuse Optical Imaging (DOI) are comparatively more practical for rapid diagnosis of breast cancer in the field as compared to advanced optical spectroscopy techniques such as Raman spectroscopy and Fluorescence spectroscopy. The handheld Transillumination Imaging is inexpensive and easy to use, but its accuracy is not high, and a skilled clinician needs to interpret the transilluminated image. Diffuse Optical Imaging appears to be most promising. It provides a detailed spatial map of relative concentration of different cancer biomarkers and could be amenable to be used within a system of a handheld tool in combination with AI driven rapid analysis. Currently, DOI is lab-based and expensive to manufacture and needs improvement in its image resolution.

The DOI tool is classified as parallel plate, bed-based, and handheld system. The parallel plate system includes both transmission and reflection data and gives results with and without the application of pressure with relatively low acquisition time. The parallel plate system considers breast volume variation and breast density variation. However, due to its mechanical design, it is prone to vibration-induced errors. Additionally, considering rapid diagnosis with large sample

size, it is more prone to failure due to mechanical motion. The parallel plate-based configuration is more advantageous in systems connected to bed-based configuration.

The bed-based technique involves both transmission and reflection analysis while taking breast volume and breast density variation into account. Moreover, the patient is comfortable during the acquisition process, with the bed-based system having the sensitivity and specificity of more than 90%. However, the mechanical design, including a specialized bed decreases portability, and the spilling of chamber fluid and its hygiene is a concern. The motion-based contact bed-based technique is more favorable but is more prone to mechanical failure. With the recent developments in bed-based techniques taking the acquisition time to be less than 1 minute, the bed-based technique is a promising configuration to be used as a rapid diagnostic tool. However, there is a need to configure the bed-based system in a modular approach to improve portability and rapidly deploy the system.

The handheld system primarily provides the reflection data and can compensate for breast volume variation by manually changing the number of scanning points. The sensitivity and specificity of hand-held systems are reported to be more than 90%. However, manually choosing the scanning points makes the process dependent on the operator's skill. Considering an extensive number of tests, the operator can be prone to fatigue and reduced accuracies on skipping the scanning points. Hence, the handheld probe is more advantageous and reliable when used along with ultrasound or mammogram, where the location of the tumor is known beforehand.

The FD and CW based rapid diagnosis systems are reported as an alternative to TD system, while the CW based system was considered as a low-cost alternative; however, with limited information on scattering data. Each of the modalities showcases potential to be used as a rapid diagnostic tool; however, there is a critical need to fully resolve all the challenges of being proficient in maintaining sensitivity with variation in breast volume and density between patients, portable, battery-powered, low-acquisition time, minimum human intervention, and integrated with machine learning techniques for automatic interpretation of the results. Additionally, the rapid diagnostic tool should quantify the main cancer biomarkers, such as total hemoglobin, water, and lipids.

Acknowledgment

Hardik J. Pandya acknowledges Indian Institute of Science, Bangalore for the start-up grant to establish the research and computational facilities at the Department of Electronic Systems Engineering.

Disclosures

The authors declare no conflicts of interest.

References

1. World Health Organization. Global Health Observatory. Geneva: World Health Organization. (2018) Available at: who.int/gho/database/en/ (accessed 5 February 2020).
2. Ferlay, J., Colombet, M., Soerjomataram, I., Mathers, C., Parkin, D. M., Piñeros, M., Znaor, A., and Bray, F. (2019) Estimating the global cancer incidence and mortality in 2018: GLOBOCAN sources and methods. *Int. J. Cancer* 144 (8): 1941–1953.
3. Singh, S., Shrivastava, J., and Dwivedi, A. (2015) Breast cancer screening existence in India: A nonexistent reality. *Indian J. Med. Paediatr. Oncol.* 36 (4): 207–209.
4. Corbex, M., Burton, R., and Sancho-Garnier, H. (2012) Breast cancer early detection methods for low and middle income countries, a review of the evidence. *Breast* 21 (4): 428–34.
5. Skaane, P., Hofvind, S., and Skjennald, A. (2007) Randomized trial of screen-film versus full-field digital mammography with soft-copy reading in population-based screening program: follow-up and final results of Oslo II study. *Radiology* 244 (3): 708–17.
6. Skaane, P., Hofvind, S., and Skjennald, A. (2007) Randomized trial of screen-film versus full-field digital mammography with soft-copy reading in population-based screening program: Follow-up and final results of Oslo II study. *Radiology* 244 (3): 708–717.
7. Carney, P. A., Miglioretti, D. L., Yankaskas, B. C., Kerlikowske, K., Rosenberg, R., Rutter, C. M., Geller, B. M., Abraham, L. A., Taplin, S. H., Dignan, M., Cutter, G., and Ballard-Barbash, R. (2003) Individual and combined effects of age, breast density, and hormone replacement therapy use on the accuracy of screening mammography. *Ann. Intern. Med.* 138 (3): 168–175.
8. Goss, P. E., and Sierra, S. (1998) Current perspectives on radiation-induced breast cancer. *J. Clin. Oncol.* 16 (1): 338–47.
9. Yaffe, M. J., and Mainprize, J. G. (2011) Risk of radiation-induced breast cancer from mammographic screening. *Radiology* 258 (1): 98–105.
10. Mattsson, A., Rudén, B. I., Hall, P., Wilking, N., and Rutqvist, L. E. (1993) Radiation-induced breast cancer: long-term follow-up of radiation therapy for benign breast disease. *J. Natl. Cancer Inst.* 85 (20): 1679–85.
11. Matsumura, S., Wang, B., Kawashima, N., Braunstein, S., Badura, M., Cameron, T. O., Babb, J. S., Schneider, R. J., Formenti, S. C., Dustin, M. L., and Demaria, S. (2008) Radiation-Induced CXCL16 Release by Breast Cancer Cells Attracts Effector T Cells. *J. Immunol.* 181 (5): 3099–3107.
12. Lagarde, C., Vlashi, E., Della Donna, L., Dekmezian, C., and Pajonk, F. (2012) Radiation-induced reprogramming of breast cancer cells. *Stem Cells* 30 (5): 833–44.
13. Miglioretti, D. L., Lange, J., van den Broek, J. J., Lee, C. I., van Ravesteyn, N. T., Ritley, D., Kerlikowske, K., Fenton, J. J., Melnikow, J., de Koning, H. J., and Hubbard, R. A. (2016) Radiation-Induced Breast Cancer Incidence and Mortality From Digital Mammography Screening: A Modeling Study. *Ann. Intern. Med.* 164 (4): 205–14.
14. Kriege, M., Brekelmans, C. T. M., Boetes, C., Besnard, P. E., Zonderland, H. M., Obdeijn, I. M., Manoliu, R. A., Kok, T., Peterse, H., Tilanus-Linthorst, M. M. A., Muller, S. H., Meijer, S., Oosterwijk, J. C., Beex, L. V. A. M., Tollenaar, R. A. E. M., de Koning, H. J., Rutgers, E. J. T., Klijn, J. G. M., and Magnetic Resonance Imaging Screening Study Group. (2004) Efficacy of MRI and mammography for breast-cancer screening in women with a familial or genetic predisposition. *N. Engl. J. Med.* 351 (5): 427–37.
15. Lord, S. J., Lei, W., Craft, P., Cawson, J. N., Morris, I., Waller, S., Griffiths, A., Parker, S., and Houssami, N. (2007) A systematic review of the effectiveness of magnetic resonance imaging (MRI) as an addition to mammography and ultrasound in screening young women at high risk of breast cancer. *Eur. J. Cancer* 43 (13): 1905–17.
16. Gordon, P. B. (2002) Ultrasound for breast cancer screening and staging. *Radiol. Clin. North Am.* 40 (3): 431–41.
17. Stavros, A. T., Thickman, D., Rapp, C. L., Dennis, M. A., Parker, S. H., and Sisney, G. A. (1995) Solid breast nodules: use of sonography to distinguish between benign and malignant lesions. *Radiology* 196 (1): 123–34.
18. Kolb, T. M., Lichy, J., and Newhouse, J. H. (1998) Occult cancer in women with dense breasts: Detection with screening US - Diagnostic yield and tumor characteristics. *Radiology* 207 (1): 191–200.
19. Elmore, J. G. (2005) Screening for Breast Cancer. *JAMA* 293 (10): 1245.
20. Al-Foheidi, M., Al-Mansour, M. M., and Ibrahim, E. M. (2013) Breast cancer screening: Review of benefits and harms, and recommendations for developing and low-income countries. *Med. Oncol.* 30 (2).
21. Sterns, E. E., Curtis, A. C., Miller, S., and Hancock, J. R. (1982) Thermography in breast diagnosis. *Cancer* 50 (2): 323–5.
22. Kennedy, D. A., Lee, T., and Seely, D. (2009) A comparative review of thermography as a breast cancer screening technique. *Integr. Cancer Ther.* 8 (1): 9–16.
23. Arora, N., Martins, D., Ruggerio, D., Tousimis, E., Swistel, A. J., Osborne, M. P., and Simmons, R. M. (2008) Effectiveness of a noninvasive digital infrared thermal imaging system in the detection of breast cancer. *Am. J. Surg.* 196 (4): 523–6.
24. Omranipour, R., Kazemian, A., Alipour, S., Najafi, M., Alidoosti, M., Navid, M., Alikhassi, A., Ahmadinejad, N., Bagheri, K., and

- Izadi, S. (2016) Comparison of the Accuracy of Thermography and Mammography in the Detection of Breast Cancer. *Breast Care (Basel)*. 11 (4): 260–264.
25. Pogue, B., Testorf, M., McBride, T., Osterberg, U., and Paulsen, K. (1997) Instrumentation and design of a frequency-domain diffuse optical tomography imager for breast cancer detection. *Opt. Express* 1 (13): 391.
26. Colak, S. B., Van Der Mark, M. B., 'T Hooft, G. W., Hoogenraad, J. H., Van Der Linden, E. S., and Kuijpers, F. A. (1999) Clinical optical tomography and NIR spectroscopy for breast cancer detection. *IEEE J. Sel. Top. Quantum Electron.* 5 (4): 1143–1158.
27. Delpy, D. T., Cope, M., Van Der Zee, P., Arridge, S., Wray, S., and Wyatt, J. (1988) Estimation of optical pathlength through tissue from direct time of flight measurement. *Phys. Med. Biol.* 33 (12): 1433–1442.
28. Jacques, S. L. (2013) Optical properties of biological tissues: A review. *Phys. Med. Biol.* 58 (11).
29. Ghartey, F. N., Watmough, D., Debrah, S., Morna, M., and Anyanful, A. (2018) Breast-i is an effective and reliable adjunct screening tool for detecting early tumour related angiogenesis of breast cancers in low resource sub-saharan countries. *Int. J. Breast Cancer* 2018. <https://www.breastlightsouthafrica.co.za/>. (2019) How To Detect Breast Cancer | Breast Cancer Diagnosis. Available at: <https://www.breastlightsouthafrica.co.za/> (accessed 22 October 2019).
31. Vaidya, J., and Thorat, M. (2009) Feedback Consumer Research for PWB Health 2008, study in asymptomatic women. *2nd International Meeting Innovations & Progress in Healthcare for Women RCOG London*.
32. Al-Alwan, N. A. S. (2015) Evaluating the accuracy of the 'breast light' as a screening tool for breast cancer in Iraq. *J. Nurs. Care* 04 (04): 169.
33. Dr. Abdullateef Aliasghar; Prof. Dr. Nada A S Alwan; Dr. Khaleel Ibraheem Mohson; Dr. Enam Azez. (2017) Accuracy of Hopelight (Mammolight) Imaging in Detection of Breast Cancer. *Int. J. Sci. Res.* 6 (8): 1731–1734.
34. Shiryazdi, S. M., Kargar, S., Taheri-Nasaj, H., and Neamatzadeh, H. (2015) BreastLight apparatus performance in detection of breast masses depends on mass size. *Asian Pacific J. Cancer Prev.* 16 (3): 1181–1184.
35. Labib, N. A., Ghobashi, M. M., Moneer, M. M., Helal, M. H., and Abdalgaleel, S. A. (2013) Evaluation of BreastLight as a tool for early detection of breast lesions among females attending National Cancer Institute, Cairo University. *Asian Pacific J. Cancer Prev.* 14 (8): 4647–4650.
36. Shiryazdi, S., Kargar, S., Nasaj, H., Neamatzadeh, H., and Ghasemi, N. (2015) The accuracy of Breastlight in detection of breast lesions. *Indian J. Cancer* 52 (4): 513–516.
37. Iwuchukwu O, Keaney N. D. M. (2010) Analysis of Breastlight findings in patients with biopsies. City Hospital Sunderland. *European Institute of Oncology's 12th Milan Breast Cancer Conference*.
38. Mehnati, P., and Tirtash, M. J. (2015) Comparative efficacy of four imaging instruments for breast cancer screening. *Asian Pacific J. Cancer Prev.* 16 (15): 6177–6186.
39. Edge, J., and Roodt, L. (2018) Alternative modalities being promoted for breast screening. *South African Med. J.* 108 (12): 1010–1011.
40. Taroni, P., Paganoni, A. M., Ieva, F., Pifferi, A., Quarto, G., Abbate, F., Cassano, E., and Cubeddu, R. (2017) Non-invasive optical estimate of tissue composition to differentiate malignant from benign breast lesions: A pilot study. *Sci. Rep.* 7 (August 2016): 1–11.
41. Choe, R., Konecky, S. D., Corlu, A., Lee, K., Durduran, T., Busch, D. R., Pathak, S., Czerniecki, B. J., Tchou, J., Fraker, D. L., DeMichele, A., Chance, B., Arridge, S. R., Schweiger, M., Culver, J. P., Schnall, M. D., Putt, M. E., Rosen, M. A., and Yodh, A. G. (2009) Differentiation of benign and malignant breast tumors by in-vivo three-dimensional parallel-plate diffuse optical tomography. *J. Biomed. Opt.* 14 (2): 024020.
42. Zhu, Q., Ricci, A., Hegde, P., Kane, M., Cronin, E., Merkulov, A., Xu, Y., Tavakoli, B., and Tannenbaum, S. (2016) Assessment of Functional Differences in Malignant and Benign Breast lesions and improvement of Diagnostic accuracy by Using Us-guided Diffuse Optical Tomography in conjunction with conventional Us1. *Radiology* 280 (2): 387–397.
43. Grosenick, D., Rinneberg, H., Cubeddu, R., and Taroni, P. (2016) Review of optical breast imaging and spectroscopy. *J. Biomed. Opt.* 21 (9): 091311.
44. Tromberg, B. J., Pogue, B. W., Paulsen, K. D., Yodh, A. G., Boas, D. A., and Cerussi, A. E. (2008) Assessing the future of diffuse optical imaging technologies for breast cancer management. *Med. Phys.* 35 (6): 2443–51.
45. Godavarty, A., Rodriguez, S., Jung, Y.-J., and Gonzalez, S. (2015) Optical imaging for breast cancer prescreening. *Breast cancer (Dove Med. Press)* 7: 193–209.
46. Kato, I., Beinart, C., Bleich, A., Su, S., Kim, M., and Toniolo, P. G. (1995) A nested case-control study of mammographic patterns, breast volume, and breast cancer (New York City, NY, United States). *Cancer Causes Control* 6 (5): 431–8.
47. Liu, Y.-J. (2009) Aesthetics of the Female Breast: Correlation of Pluralistic Evaluations with Volume and Surface Area. *Yale Med. Thesis Digit. Libr.*
48. Katariya, R. N., Forrest, A. P., and Gravelle, I. H. (1974) Breast volumes in cancer of the breast. *Br. J. Cancer* 29 (3): 270–3.
49. Thomson, J. G., Liu, Y.-J., Restifo, R. J., Rinker, B. D., and Reis, A. (2009) Surface area measurement of the female breast: phase I. Validation of a novel optical technique. *Plast. Reconstr. Surg.* 123 (5): 1588–96.
50. Sprague, B. L., Conant, E. F., Onega, T., Garcia, M. P., Beaber, E. F., Herschorn, S. D., Lehman, C. D., Tosteson, A. N. A., Lacson, R., Schnall, M. D., Kontos, S. D., Haas, J. S., Weaver, D. L., Barlow, W. E., and PROSPR Consortium. (2016) Variation in Mammographic Breast Density Assessments Among Radiologists in Clinical Practice: A Multicenter Observational Study. *Ann. Intern. Med.* 165 (7): 457–464.
51. White, E., Velentgas, P., Mandelson, M. T., Lehman, C. D., Elmore, J. G., Porter, P., Yasui, Y., and Taplin, S. H. (1998) Variation in mammographic breast density by time in menstrual cycle among women aged 40–49 years. *J. Natl. Cancer Inst.* 90 (12): 906–10.
52. Wang, L. (2017) Early Diagnosis of Breast Cancer. *Sensors* 17 (7): 1572.
53. Coleman, C. (2017) Early Detection and Screening for Breast Cancer. *Semin. Oncol. Nurs.* 33 (2): 141–155.
54. Milosevic, M., Jankovic, D., Milenkovic, A., and Stojanov, D. (2018) Early diagnosis and detection of breast cancer. *Technol. Health Care* 26 (4): 729–759.
55. Loud, J. T., and Murphy, J. (2017) Cancer Screening and Early Detection in the 21st Century. *Semin. Oncol. Nurs.* 33 (2): 121–128.
56. Vidyarthi, A., Soumya, A., Choudhary, S., and Sinha, B. K. (2013) Barriers to Breast Cancer Screening In Young Indian Women : A Tale of Two Cities. (2): 29–35.
57. Onstad, M. (2013) B e n i g n B r e a s t D i s o r d e r s. 40: 8545.
58. Lee, K. (2011) Optical mammography: Diffuse optical imaging of breast cancer. *World J. Clin. Oncol.* 2 (1): 64–72.
59. Leff, D. R., Warren, O. J., Enfield, L. C., Gibson, A., Athanasiou, T., Patten, D. K., Hebden, J., Yang, G. Z., and Darzi, A. (2008) Diffuse optical imaging of the healthy and diseased breast: A systematic review. *Breast Cancer Res. Treat.* 108 (1): 9–22.

60. Di Leo, G., Trimboli, R. M., Sella, T., and Sardanelli, F. (2017) Optical Imaging of the Breast: Basic Principles and Clinical Applications. *AJR. Am. J. Roentgenol.* 209 (1): 230–238.
61. Bottorff, J. L., Johnson, J. L., Bhagat, R., Grewal, S., Balneaves, L. G., Clarke, H., and Hilton, B. A. (1998) Beliefs related to breast health practices: the perceptions of South Asian women living in Canada. *Soc. Sci. Med.* 47 (12): 2075–85.
62. Kavar, L. N. (2013) Barriers to breast cancer screening participation among Jordanian and Palestinian American women. *Eur. J. Oncol. Nurs.* 17 (1): 88–94.
63. Hadjipanayis, C. G., Jiang, H., Roberts, D. W., and Yang, L. (2011) Current and future clinical applications for optical imaging of cancer: From intraoperative surgical guidance to cancer screening. *Semin. Oncol.* 38 (1): 109–118.
64. Zhao, Y., Burger, W. R., Zhou, M., Bernhardt, E. B., Kaufman, P. A., Patel, R. R., Angeles, C. V., Pogue, B. W., Paulsen, K. D., and Jiang, S. (2017) Collagen quantification in breast tissue using a 12-wavelength near infrared spectral tomography (NIRST) system. *Biomed. Opt. Express* 8 (9): 4217.
65. Lazaro-Pacheco, D., Shaaban, A. M., Rehman, S., and Rehman, I. (2019) Raman spectroscopy of breast cancer. *Appl. Spectrosc. Rev.* 0 (0): 1–37.
66. Alchab, L., Dupuis, G., Balleyguier, C., Mathieu, M. C., Fontaine-Aupart, M. P., and Farcy, R. (2010) Towards an optical biopsy for the diagnosis of breast cancer in vivo by endogenous fluorescence spectroscopy. *J. Biophotonics* 3 (5–6): 373–384.
67. Kandurova, K., Dremine, V. V., Zherebtsov, E. A., Dunaev, A. V., Mamoshin, A. V., Alyanov, A. L., Muradyan, V. F., and Potapova, E. V. (2018) Application of the fluorescence spectroscopy for the analysis of the state of abdominal cavity organs tissues in mini-invasive surgery. (May 2018): 171.
68. Dramicanin, T., and Dramicanin, M. (2016) Using Fluorescence Spectroscopy to Diagnose Breast Cancer. In *Applications of Molecular Spectroscopy to Current Research in the Chemical and Biological Sciences*, InTech.
69. Wang, L. (2018) Microwave sensors for breast cancer detection. *Sensors (Switzerland)* 18 (2): 1–17.
70. Nikolova, N. K. (2011) Microwave imaging for breast cancer. *IEEE Microw. Mag.* 12 (7): 78–94.
71. Lazebnik, M., Zhu, C., Palmer, G. M., Harter, J., Sewall, S., Ramanujam, N., and Hagness, S. C. (2008) Electromagnetic spectroscopy of normal breast tissue specimens obtained from reduction surgeries: Comparison of optical and microwave properties. *IEEE Trans. Biomed. Eng.* 55 (10): 2444–2451.
72. Atta-ur-Rahman, and Chaudhary, M. I. (2019) *Applications of NMR Spectroscopy Volume 7*. Bentham Science Publishers.
73. Shah, N., Sattar, A., Benanti, M., Hollander, S., and Cheuck, L. (2006) Magnetic resonance spectroscopy as an imaging tool for cancer: A review of the literature. *J. Am. Osteopath. Assoc.* 106 (1): 23–27.
74. Bolan, P. J., Nelson, M. T., Yee, D., and Garwood, M. (2005) Imaging in breast cancer: Magnetic resonance spectroscopy. *Breast Cancer Res.* 7 (4): 149–152.
75. Ifa, D. R., and Eberlin, L. S. (2016) Ambient ionization mass spectrometry for cancer diagnosis and surgical margin evaluation. *Clin. Chem.* 62 (1): 111–123.
76. Ciocan-Cartita, C. A., Jurj, A., Buse, M., Gulei, D., Braicu, C., Raduly, L., Cojocneanu, R., Pruteanu, L. L., Iuga, C. A., Coza, O., and Berindan-Neagoe, I. (2019) The relevance of mass spectrometry analysis for personalized medicine through its successful application in cancer “Omics”. *Int. J. Mol. Sci.* 20 (10).
77. Mao, X., He, J., Li, T., Lu, Z., Sun, J., Meng, Y., Abliz, Z., and Chen, J. (2016) Application of imaging mass spectrometry for the molecular diagnosis of human breast tumors. *Sci. Rep.* 6 (January): 1–12.
78. Pifferi, A., Contini, D., Mora, A. D., Farina, A., Spinelli, L., and Torricelli, A. (2016) New frontiers in time-domain diffuse optics, a review. *J. Biomed. Opt.* 21 (9): 091310.
79. O’Sullivan, T. D., Cerussi, A. E., Cuccia, D. J., and Tromberg, B. J. (2012) Diffuse optical imaging using spatially and temporally modulated light. *J. Biomed. Opt.* 17 (7): 071311.
80. Carp, S. A., Sajjadi, A. Y., Wanyo, C. M., Fang, Q., Specht, M. C., Schapira, L., Moy, B., Bardia, A., Boas, D. A., and Isakoff, S. J. (2013) Hemodynamic signature of breast cancer under fractional mammographic compression using a dynamic diffuse optical tomography system. *Biomed. Opt. Express* 4 (12): 2911.
81. Mastanduno, M. A., El-Ghoussein, F., Jiang, S., DiFlorio-Alexander, R., Junqing, X., Hong, Y., Pogue, B. W., and Paulsen, K. D. (2014) Adaptable Near-Infrared Spectroscopy Fiber Array for Improved Coupling to Different Breast Sizes During Clinical MRI. *Acad. Radiol.* 21 (2): 141–150.
82. Anderson, P. G., Kainerstorfer, J. M., Sassaroli, A., Krishnamurthy, N., Homer, M. J., Graham, R. A., and Fantini, S. (2015) Broadband optical mammography: Chromophore concentration and hemoglobin saturation contrast in breast cancer. *PLoS One* 10 (3): 1–23.
83. Anderson, P. G., Sassaroli, A., Kainerstorfer, J. M., Krishnamurthy, N., Kalli, S., Makim, S. S., Graham, R. A., and Fantini, S. (2016) Optical mammography: bilateral breast symmetry in hemoglobin saturation maps. *J. Biomed. Opt.* 21 (10): 101403.
84. Enfield, L. C., Gibson, A. P., Everdell, N. L., Delpy, D. T., Schweiger, M., Arridge, S. R., Richardson, C., Keshtgar, M., Douek, M., and Hebden, J. C. (2007) Three-dimensional time-resolved optical mammography of the uncompressed breast. *Appl. Opt.* 46 (17): 3628–3638.
85. Wang, J., Jiang, S., Li, Z., DiFlorio-Alexander, R. M., Barth, R. J., Kaufman, P. A., Pogue, B. W., and Paulsen, K. D. (2010) In vivo quantitative imaging of normal and cancerous breast tissue using broadband diffuse optical tomography. *Med. Phys.* 37 (7): 3715–3724.
86. Busch, D. R., Guo, W., Choe, R., Durduran, T., Feldman, M. D., Mies, C., Rosen, M. A., Schnall, M. D., Czerniecki, B. J., Tchou, J., Demichele, A., Putt, M. E., and Yodh, A. G. (2010) Computer aided automatic detection of malignant lesions in diffuse optical mammography. *Med. Phys.* 37 (4): 1840–1849.
87. Wang, J. Z., Liang, X., Zhang, Q., Fajardo, L. L., and Jiang, H. (2008) Automated breast cancer classification using near-infrared optical tomographic images. *J. Biomed. Opt.* 13 (4): 044001.
88. Ifimia, N., Gu, X., Xu, Y., and Jiang, H. (2003) A compact, parallel-detection diffuse optical mammography system. *Rev. Sci. Instrum.* 74 (5): 2836–2842.
89. Ban, H. Y., Schweiger, M., Kavuri, V. C., Cochran, J. M., Xie, L., Busch, D. R., Katrašnik, J., Pathak, S., Chung, S. H., Lee, K., Choe, R., Czerniecki, B. J., Arridge, S. R., and Yodh, A. G. (2016) Heterodyne frequency-domain multispectral diffuse optical tomography of breast cancer in the parallel-plane transmission geometry. *Med. Phys.* 43 (7): 4383–4395.
90. Cochran, J. (2018) Diffuse Optical Biomarkers Of Breast Cancer. *Publicly Access. Penn Diss.*
91. Zhao, Y., Pogue, B. W., Haider, S. J., Gui, J., diFlorio-Alexander, R. M., Paulsen, K. D., and Jiang, S. (2016) Portable, parallel 9-wavelength near-infrared spectral tomography (NIRST) system for efficient characterization of breast cancer within the clinical oncology infusion suite. *Biomed. Opt. Express* 7 (6): 2186.

92. Zhu, Q., Huang, M., Chen, N. G., Zarfost, K., Jagjivant, B., Kane, M., Hedget, P., and Kurtzman, S. H. (2003) Ultrasound-Guided Optical Tomographic Imaging of Malignant and Benign Breast Lesions: Initial Clinical Results of 19 Cases. *Neoplasia* 5 (5): 379–388.
93. Chen, N. G., Huang, M., Xia, H., Piao, D., Cronin, E., and Zhu, Q. (2004) Portable near-infrared diffusive light imager for breast cancer detection. *J. Biomed. Opt.* 9 (3): 504.
94. Zhang, H., Qin, D., Yang, Z., Wang, K., Sun, F., Li, B., and Cui, G. (2014) Comparison of diffuse optical tomography, ultrasound elastography and mammography in the diagnosis of breast tumors. *Ultrasound Med. Biol.* 40 (1): 1–10.
95. Cheng, X., Mao, J., Bush, R., Kopans, D. B., and Moore, R. H. (2003) Concentration and Oxygen Saturation. *Appl. Opt.*
96. Chance, B., Nioka, S., Zhang, J., Conant, E. F., Hwang, E., Briest, S., Orel, S. G., Schnall, M. D., and Czerniecki, B. J. (2005) Breast cancer detection based on incremental biochemical and physiological properties of breast cancers: A six-year, two-site study. *Acad. Radiol.* 12 (8): 925–933.
97. Kukreti, S., Cerussi, A. E., Tanamai, W., Hsiang, D., Tromberg, B. J., and Gratton, E. (2010) Characterization of Metabolic Differences between Benign and Malignant Tumors : Purpose : Methods : Results : Conclusion : *Radiology* 254 (1): 277–84.
98. Gonzalez, J., Roman, M., Hall, M., and Godavarty, A. (2012) Gen-2 hand-held optical imager towards cancer imaging: Reflectance and transillumination phantom studies. *Sensors* 12 (2): 1885–1897.
99. Gonzalez, J. (2012) Hand-held optical imager (Gen-2): improved instrumentation and target detectability. *J. Biomed. Opt.* 17 (8): 081402.
100. Erickson-Bhatt, S. J., Roman, M., Gonzalez, J., Nunez, A., Kiszona, R., Lopez-Penalver, C., and Godavarty, A. (2015) Noninvasive Surface Imaging of Breast Cancer in Humans using a Hand-held Optical Imager. *Biomed. Phys. Eng. express* 1 (4).
101. Mostafa, A., Vavadi, H., Uddin, K. M. S., and Zhu, Q. (2017) Diffuse optical tomography using semiautomated coregistered ultrasound measurements. *J. Biomed. Opt.* 22 (12): 1.
102. Pogue, B. W., Jiang, S., Dehghani, H., Kogel, C., Soho, S., Srinivasan, S., Song, X., Tosteson, T. D., Poplack, S. P., and Paulsen, K. D. (2004) Characterization of hemoglobin, water, and NIR scattering in breast tissue: analysis of intersubject variability and menstrual cycle changes. *J. Biomed. Opt.* 9 (3): 541.
103. Corlu, A., Choe, R., Durduran, T., Rosen, M. A., Schweiger, M., Arridge, S. R., Schnall, M. D., and Yodh, A. G. (2007) Three-dimensional in vivo fluorescence diffuse optical tomography of breast cancer in humans. *Opt. Express* 15 (11): 6696.
104. McKinney, S. M., Sieniek, M., Godbole, V., Godwin, J., Antropova, N., Ashrafi, H., Back, T., Chesus, M., Corrado, G. C., Darzi, A., Etemadi, M., Garcia-Vicente, F., Gilbert, F. J., Halling-Brown, M., Hassabis, D., Jansen, S., Karthikesalingam, A., Kelly, C. J., King, D., Ledsam, J. R., Melnick, D., Mostofi, H., Peng, L., Reicher, J. J., Romera-Paredes, B., Sidebottom, R., Suleyman, M., Tse, D., Young, K. C., De Fauw, J., and Shetty, S. (2020) International evaluation of an AI system for breast cancer screening. *Nature* 577 (7788): 89–94.
105. Wang, J. Z., Liang, X., Zhang, Q., Fajardo, L. L., and Jiang, H. (2008) Automated breast cancer classification using near-infrared optical tomographic images. *J. Biomed. Opt.* 13 (4): 044001.
106. Taroni, P., Pifferi, A., Cubeddu, R., Ieva, F., Paganoni, A. M., Abbate, F., and Cassano, E. (2018) *Optical Quantification of Collagen and Breast Cancer: Lesion Classification and Risk Estimate*.
107. Breneisen, M. (2017) (12) Patent Application Publication (10) Pub. No.: US 2017/0096730 A1. 1 (19).
108. Barbour, R. L., Graber, H. L., and Barbour, S. L. S. (2018) *Hemoglobin state-flux: A finite-state model representation of the hemoglobin signal for evaluation of the resting state and the influence of disease*.
109. Zhang, P., Gui, Z., Guo, G., and Shang, Y. (2018) Approaches to denoise the diffuse optical signals for tissue blood flow measurement. *Biomed. Opt. Express* 9 (12): 6170.
110. Taroni, P., Pifferi, A., Quarto, G., Farina, A., Ieva, F., Paganoni, A. M., Abbate, F., Cassano, E., and Cubeddu, R. (2015) Time domain diffuse optical spectroscopy: In vivo quantification of collagen in breast tissue. *Opt. Methods Insp. Charact. Imaging Biomater. II* 9529 (June 2015): 952910.
111. Yoshimoto, K., Ohmae, E., Yamashita, D., Suzuki, H., Homma, S., Mimura, T., Wada, H., Suzuki, T., Yoshizawa, N., Nasu, H., Ogura, H., Sakahara, H., Yamashita, Y., and Ueda, Y. (2017) Development of time-resolved reflectance diffuse optical tomography for breast cancer monitoring. *Opt. Tomogr. Spectrosc. Tissue XII* 10059 (February 2017): 100590M.
112. Sreedevi, A., Quereshi, M. A., Kurian, B., and Kamalamma, L. (2014) Screening for breast cancer in a low middle income country: predictors in a rural area of Kerala, India. *Asian Pac. J. Cancer Prev.* 15 (5): 1919–24.
113. Mishra, G. A., Dhivar, H. D., Gupta, S. D., Kulkarni, S. V., and Shastri, S. S. (2015) A population-based screening program for early detection of common cancers among women in India - methodology and interim results. *Indian J. Cancer* 52 (1): 139–45.
114. Kumar, J. U., Sreekanth, V., Reddy, H. R., Sridhar, A. B., Kodali, N., and Prabhu, A. S. (2017) Screening Mammography: A Pilot Study on Its Pertinence in Indian Population by Means of a Camp. *J. Clin. Diagn. Res.* 11 (8): TC29–TC32.
115. Gutnik, L., Lee, C., Msosa, V., Moses, A., Stanley, C., Mzumara, S., Liomba, N. G., and Gopal, S. (2016) Clinical breast examination screening by trained laywomen in Malawi integrated with other health services. *J. Surg. Res.* 204 (1): 61–7.
116. Gutnik, L., Moses, A., Stanley, C., Tembo, T., Lee, C., and Gopal, S. (2016) From community laywomen to breast health workers: A pilot training model to implement clinical breast exam screening in Malawi. *PLoS One* 11 (3).
117. Reddy, N., Ninan, T., Tabar, L., and Bevers, T. (2012) The results of a breast cancer screening cAMP at a district level in rural India. *Asian Pac. J. Cancer Prev.* 13 (12): 6067–72.
118. Sayed, S., Moloo, Z., Ngugi, A., Allidina, A., Ndumia, R., Mutui, A., Wasike, R., Wahome, C., Abdihakim, M., Kasmani, R., Spears, C. D., Oigara, R., Mwachiro, E. B., Busarla, S. V. P., Kibor, K., Ahmed, A., Wawire, J., Sherman, O., Saleh, M., Zujewski, J. A., and Dawsey, S. M. (2016) Breast Camps for Awareness and Early Diagnosis of Breast Cancer in Countries With Limited Resources: A Multidisciplinary Model From Kenya. *Oncologist* 21 (9): 1138–48.
119. Sayed, S., Ngugi, A., Ochieng, P., Mwenda, A. S., and Salam, R. A. (2017) Training health workers in clinical breast examination for early detection of breast cancer in low- and middle-income countries. *Cochrane Database Syst. Rev.* 2017 (1).
120. Jose, R., Augustine, P., Bindhu, S. A., Sebasitan, S. R., VA, D., John, S., and Haran, J. C. (2018) Clinical Breast Examination Campaign: Experience From Thiruvananthapuram, South India. *J. Glob. Oncol.* (4_suppl_2): 137s-137s.
121. Harvey, H., Karpati, E., Khara, G., Korkinof, D., Ng, A., Austin, C., Rijken, T., and Keckemethy, P. (2019) The Role of Deep Learning in Breast Screening. *Curr. Breast Cancer Rep.* 11 (1): 17–22.
122. Trister, A. D., Buist, D. S. M., and Lee, C. I. (2017) Will machine learning tip the balance in breast cancer screening? *JAMA Oncol.* 3 (11): 1463–1464.
123. Álvarez Menéndez, L., de Cos Juez, F. J., Sánchez Lasheras, F., and Álvarez Riesgo, J. A. (2010) Artificial neural networks applied to

- cancer detection in a breast screening programme. *Math. Comput. Model.* 52 (7–8): 983–991.
124. Nattkemper, T. W., Arnrich, B., Lichte, O., Timm, W., Degenhard, A., Pointon, L., Hayes, C., Leach, M. O., and UK MARIBS Breast Screening Study. (2005) Evaluation of radiological features for breast tumour classification in clinical screening with machine learning methods. *Artif. Intell. Med.* 34 (2): 129–39.
 125. Sepandi, M., Taghdir, M., Rezaianzadeh, A., and Rahimikazerooni, S. (2018) Assessing breast cancer risk with an artificial neural network. *Asian Pacific J. Cancer Prev.* 19 (4): 1017–1019.
 126. Nindrea, R. D., Aryandono, T., Lazuardi, L., and Dwiprahasto, I. (2018) Diagnostic accuracy of different machine learning algorithms for breast cancer risk calculation: A meta-analysis. *Asian Pacific J. Cancer Prev.* 19 (7): 1747–1752.
 127. Sadoughi, F., Kazemy, Z., Hamedan, F., Owji, L., Rahmanikatiqari, M., and Azadboni, T. T. (2018) Artificial intelligence methods for the diagnosis of breast cancer by image processing: A review. *Breast Cancer Targets Ther.* 10: 219–230.
 128. Cerussi, A., Shah, N., Hsiang, D., Durkin, A., Butler, J., and Tromberg, B. J. (2006) In vivo absorption, scattering, and physiologic properties of 58 malignant breast tumors determined by broadband diffuse optical spectroscopy. *J. Biomed. Opt.* 11 (4): 044005.