

Oral manifestations in patients with neurofibromatosis type-1: A comprehensive literature review

Fawad Javed^{a,*,1}, Sundar Ramalingam^{b,**,1}, Hameeda Bashir Ahmed^{c,1}, Bhumija Gupta^d,
Chalini Sundar^e, Talat Qadri^f, Khalid Al-Hezaimi^{a,g}, Georgios E. Romanos^{h,1}

^a Eng. A. B. Research Chair for Growth Factors and Bone Regeneration, 3D Imaging and Biomechanical Laboratory, College of Applied Medical Sciences, King Saud University, Riyadh, Saudi Arabia

^b Department of Oral and Maxillofacial Surgery, College of Dentistry, King Saud University, Riyadh, Saudi Arabia

^c Department of Dentistry, Al-Farabi Dental College, Riyadh, Saudi Arabia

^d Department of Community Dentistry, Eastman Institute for Oral Health, University of Rochester, Rochester, NY, USA

^e Dental Public Health Department, Elite Medical and Surgical Center, Riyadh, Saudi Arabia

^f Department of Dental Medicine, Division of Periodontology, Karolinska Institutet, Huddinge, Sweden

^g Department of Periodontics and Community Dentistry, College of Dentistry, King Saud University, Riyadh, Saudi Arabia

^h Department of Clinical Affairs, School of Dental Medicine, Stony Brook University, Stony Brook, NY, USA

Accepted 28 February 2014

Contents

1. Introduction	124
1.1. Association between oral health status and systemic conditions	124
1.2. Neurofibromatosis – etiology, epidemiology, types and clinical features	124
2. Rationale and objective	124
3. Materials and methods	124
3.1. Focused question	124
3.2. Inclusion and exclusion criteria	124
3.3. Search protocol	125
4. Gingival enlargement and pigmentation in patients with neurofibromatosis type-1	125
5. Dental abnormalities	125
6. Dental caries in patients with neurofibromatosis type-1	126
7. Neoplastic lesions (oral and perioral neurofibromas)	126
8. Osseous lesions of the maxilla, mandible and the temporomandibular joint	126
9. Clinical relevance and recommendations	127
Conflicts of interest statement	127
Reviewers	127
Acknowledgement	127
References	127
Biography	129

* Corresponding author at: Eng. A. B. Research Chair for Growth Factors and Bone Regeneration, 3D Imaging and Biomechanical Laboratory, College of Applied Medical Sciences, King Saud University, P.O. Box 60169, Riyadh 11545, Saudi Arabia. Tel.: +96 6509686328; fax: +96 614678639.

** Corresponding author.

E-mail address: fawjav@gmail.com (F. Javed).

¹ These authors contributed equally to this work.

Abstract

Oral health status is jeopardized in patients with neurofibromatosis (NF) type-1 (NF-1). The aim of the present study was to comprehensively review the oral manifestations in NF-1 patients. PubMed/Medline and Google-Scholar databases were explored using different keywords. Reviews, commentaries, letters to Editor and articles published in languages other than English were excluded.

Results: Neurofibromas of oral and perioral soft tissues with subsequent periodontitis, impacted and supernumerary teeth, enlarged alveolar process with dental spacing, morphological changes in teeth and class III molar relationship have been reported in NF-1 patients. Plexiform neurofibromas were reported both in oral soft tissue, maxilla and mandible with evidence of malignant transformation in some cases. Facial skeletal abnormalities, including enlargement of mandibular foramen, increased dimensions of the coronoid and sigmoid notches and notching of the posterior border of the mandible have also been reported. Association between dental caries and NF-1 remains unclear. Crown Copyright © 2014 Published by Elsevier Ireland Ltd. All rights reserved.

Keywords: Dental; Inflammation; Neurofibromatosis type-I; Oral and periodontal

1. Introduction

1.1. Association between oral health status and systemic conditions

Studies [1–8] have reported that the oral health status is jeopardized among patients with systemic conditions (such as obesity, poorly-controlled diabetes, hematologic disorders and renal disorders) as compared to their systemically healthy counterparts. This has been associated with various factors including immunosuppression, increased formation and accumulation of advanced glycation end-products in the tissues (including oral tissues) and alterations in salivary flow and buffering capacity [9–11]. In addition, genetic disorders, such as neurofibromatosis (NF) have also been reported to exhibit oral manifestations in nearly 72% of the affected individuals [12–16].

1.2. Neurofibromatosis – etiology, epidemiology, types and clinical features

Neurofibromatosis (NF) is a group of autosomal dominant genetic disorders characterized by multiple cutaneous lesions and tumors of the central and peripheral nervous system [17]. NF is categorized into two genetically distinct subtypes namely, NF type-1 (NF-1) and NF type-2 (NF-2) [18]. NF-1, previously called von Recklinghausen disease is the most common type of NF which affects approximately 1/3500 individuals worldwide [17]. NF-1 occurs due to alterations of the NF-1 gene (a tumor suppressor gene located in the long arm of chromosome-17 [17q11.2]) [15,19]. Nearly 50% of patients affected by NF-1 have a positive family history of the disease and the remaining patients represent spontaneous mutations of the NF-1 gene [15,20]. Cutaneous light brown macules of about 10–40 mm in diameter with an ovoid shape are the classical symptoms observed in patients with NF-1. The presence of at least 6 macules is defined as strong diagnostic criterion for NF-1. Nearly 90% patients with NF-1 present with a characteristic axillary and/or inguinal freckling that commonly develops after appearance of cutaneous macules [21,22]. Development of

neurofibromas around or on peripheral nerves and Lisch nodules (pigmented hamartomas of the iris) are also classical features of NF-1 [23–25].

NF-2 (referred to as central NF) occurs less frequently than NF-1 with an incidence of 1/25,000 individuals [26]. Sudden loss of hearing due to the development of unilateral or bilateral vestibular schwannomas is often an early manifestation in patients with NF-2 [27]. In contrast to NF-1 patients, tumors in NF-2 patients are smaller in size. However, these tumors may compress associated nerves and can cause considerable pain, nerve dysfunction and intracranial pressure. Furthermore, patients with NF-2 may develop nervous tissue tumors including meningiomas or gliomas.

2. Rationale and objective

Since NF-1 is a genetic disorder that may present oral symptoms in up to 72% of the affected patients [28,29]; the objective of the present study was to comprehensively review the oral health status in patients with NF-1.

3. Materials and methods

3.1. Focused question

The addressed focused question was “What are the oral manifestations in patients with NF-1?”

3.2. Inclusion and exclusion criteria

The following eligibility criteria were entailed: (a) clinical studies; (b) case-reports, since most of the studies identified during the literature search were based on individual case presentations; (c) intervention: oral manifestations in patients with NF-1; (d) studies published only in English language. Letters to the Editor, historic reviews, unpublished data and commentaries were not sought.

3.3. Search protocol

To address the focused question, PubMed/MedLine (National Library of Medicine, Washington, DC) and Google-Scholar databases were searched from 1965 up to and including January 2014 using different combinations of the following key words: (a) oral; (b) caries; (c) dental; (d) health status; (e) neurofibromatosis; (f) periodontal; and (g) tooth morphology. Titles and abstracts of studies identified using the above-described protocol were screened by the authors and checked for agreement. Full-texts of studies judged by title and abstract to be relevant were read and independently evaluated for the stated inclusion and exclusion criteria. As a next step, reference lists of potentially relevant original and review studies (that were found to be relevant in the previous step) were searched and once again any disagreement among the authors was resolved via discussion (Fig. 1).

Most of the studies that addressed our focused question were case-reports [15,30–36] and only a limited number of original retrospective studies [12,37] were available on indexed databases; therefore, the pattern of the present study was customized to primarily summarize the pertinent information.

4. Gingival enlargement and pigmentation in patients with neurofibromatosis type-1

Gingival enlargement refers to the overgrowth of the attached gingiva due to an increase in the number of cells and is a common manifestation in patients (particularly children) with NF-1. These swellings present as diffuse unilateral gingival enlargement of attached gingivae [13,38,39]. In some cases, interproximal gingivae may also display enlargement [13,38]. The patient usually presents with non-tender

unilateral swelling of the gums [38]. These swellings are fibrous and do not exhibit signs of inflammation [38]. The patients may present with absent, impacted and/or malpositioned teeth [40]. High scores of plaque and gingival bleeding indices and clinical attachment loss (most likely due to excessive plaque accumulation and irregular oral hygiene practices) are among the periodontal manifestations in these patients [40–43].

In rare cases, patients with NF-1 may present with melanin pigmentation of the gingivae [44]. The pigmentation is symmetric and persistent and can occur at any age in all races. To our knowledge from available evidence, there is no significant association of age, race and gender with gingival pigmentation [44]. However, such patients usually consider their “dark gums” as a source of discomfiture within their peer groups. Various surgical and non-surgical treatments (such as laser therapy) have been proposed for the management of melanin pigmentation in affected individuals [44–46].

5. Dental abnormalities

Commonly reported dental abnormalities among adult patients with NF-1 include impacted teeth, supernumerary teeth, missing or displaced teeth and overgrowth of the alveolar process [29,16,47,48]. Periapical cemental dysplasia (PCD) in vital mandibular teeth of patients with NF-1 was reported by Visnapuu et al. [49]. Interestingly out of the 55 patients with NF-1 in their series, only eight female patients had PCD and none of the male patients or children showed similar findings. This probably was the first reported sexual dimorphism among manifestations associated with NF-1 [49]. Longitudinal long-term follow-up studies by Friedrich et al. [47,50] reported plexiform neurofibromas to be associated with aplasia of mandibular second molars, increased spacing between teeth and jaw asymmetries on the affected side in NF-1 patients. In a case-control study involving 50 children with NF-1 and 50 normal children, tooth malformations such as taurodontism, agenesis and enamel hypoplasia were reported among children with NF-1; however, the prevalence of these dental anomalies did not demonstrate a significant difference between children with and without NF-1 [12]. Bardellini et al. [12] reported a significantly increased prevalence of class III molar relationship in children with NF-1 compared to normal children. A retrospective questionnaire based study [51] has reported early eruption of primary teeth in patients affected with NF-1; however, this association has not been reported in other studies. In their case-report, Curtin and McCarthy [34] reported perineural fibrous thickening of pulpal tissues in a patient with oral manifestations of NF-1. Based on the present review, dental abnormalities of the mineralized structures are frequently seen among patients with NF-1 who have concomitant oral manifestations. However, they were not found to significantly compromise the oral health status neither in adults, nor in children.

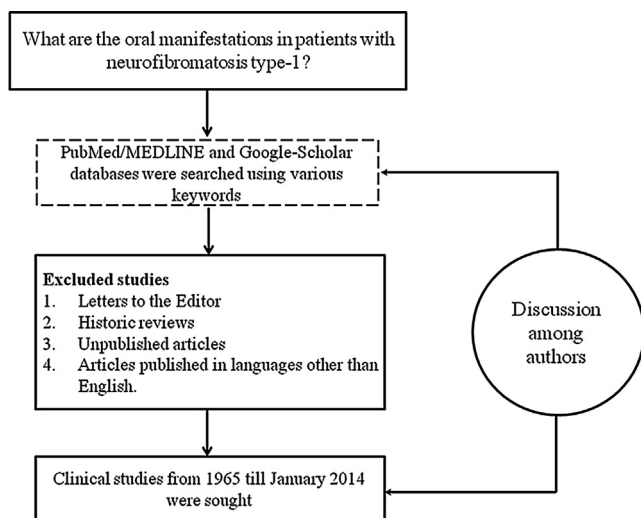


Fig. 1. Study selection protocol.

6. Dental caries in patients with neurofibromatosis type-1

Association between dental caries and NF-1 is debatable. In a retrospective study by Tucker et al. [52], questionnaires regarding dental caries status were sent to families having at least one member with NF-1. According to the results, dental caries was more often reported by siblings with NF-1 as compared to siblings without NF-1 in these families ($P < 0.05$) [52]. Tsang et al. [14] investigated the dental health status among Canadian children with and without NF-1. The results showed no significant difference in the mean ages and prevalence of dental caries among children with (13.9 ± 3.3 years and 44.4% respectively) and without NF-1 (14.9 ± 3.9 years and 27.8% respectively) [14]. On the other hand, Visnapuu et al. [37] assessed the dental health status in 110 Finnish patients with NF-1. The results demonstrated that among individuals <35 years of age, NF1 patients presented lower rate of caries than individuals without NF-1 [37]. The difference in results between the Canada-based [14] and Finland-based [37] studies could be attributed to the well-organized special attention to preventive dental care in Finland. Although dental caries has been associated with various systemic diseases including NF-1 [1,52,53]; it is pertinent to mention that chronic plaque accumulation on teeth surfaces and irregular oral hygiene maintenance plays a primary role in the occurrence of dental caries regardless of the systemic health of the patient.

7. Neoplastic lesions (oral and perioral neurofibromas)

Neurofibromas are benign complex tumors that are composed of all cell types found in the peripheral nerves [17]. Development of neurofibromas on or around peripheral nerves is a distinctive symptom of NF-1 [26]; however, they are observed to a lesser extent in patients with NF-2 [26].

Neurofibromas of the oral cavity mostly involve the tongue and are usually nodular. Other oral regions where neurofibromas have been manifested include the palate, vestibule, buccal mucosa, lip, gingiva and floor of the mouth [54]. Among the soft tissue lesions, the tongue is the most commonly affected site and the neurofibromas [12]. In addition to the presence of neurofibromas within the tongue musculature [19,55], macroglossia as a result of plexiform neurofibroma and enlargement of fungiform papillae have also been reported [29,56,57]. While, gingival neurofibromas have been reported in only 5% of patients with NF1, solitary plexiform neurofibromas of the gingiva have been reported in patients with no relation to NF1 [25,58,59]. Although mostly benign, malignant transformation of neurofibromas associated with NF-1, especially the plexiform variant, cannot be ruled out. Based on a longitudinal population study, Evans et al. [60] reported malignant transformation in 21 patients with NF-1 and deduced an 8–13% life-time risk of

malignant transformation of neurofibromas in such patients. Though malignant transformation has rarely been reported in the intraoral or perioral neurofibromas associated with NF-1; the present review identified at least two reported cases of intraosseous malignant peripheral nerve sheath tumors (one each in the maxilla and the mandible) [61,62] and two cases of neurofibrosarcoma [63]. Neurofibrosarcomas are estimated to occur in 5% of the NF cases with poor prognosis [63].

8. Osseous lesions of the maxilla, mandible and the temporomandibular joint

Skeletal lesions are not only considered pathognomonic of NF-1, but also comprise one of the important diagnostic criteria [18,64,65]. In addition to long bone lesions, osseous manifestations of NF-1 are seen in the facial skeleton, which include sphenoid wing and orbital dysplasia, maxillary and mandibular deformities and rarely temporomandibular joint (TMJ) deformities [65]. Since involvement of long bones in NF-1 could be explained by the mesodermal dysplastic manifestations of NF-1, resulting in frequent lesions of the tibia, fibula and vertebrae [66,67]; the greater frequency of lesions in the mandible associated with NF-1 could be attributed to its similarities with long bones [12]. However, it is pertinent to mention that osseous lesions are not reported in all patients with NF-1, suggesting a common pathogenetic mechanism which is unique for the affected individuals [67]. This is further supported by the fact that there is a generalized increase in osteoclast activity due to NF-1 gene haploinsufficiency [68]. In addition to genetic factors, skeletal malformations could be due to local factors aided by the presence of tumors. In a clinical study on 48 NF-1 patients, Friedrich et al. [47] reported 26 patients with jaw malformations associated with plexiform neurofibromas originating from the branches of the trigeminal nerve.

Nearly 4 decades ago, Koblin and Reil [69], who reported a combined maxilla-zygomatico-temporo-mandibular hypoplasia, based on radiographic findings, in pronounced cases of NF-1. Later, Shapiro et al. [29] reported a high prevalence of oral and radiographic findings among NF-1 patients, with the commonest jaw malformations being intrabony lesions, wide inferior alveolar canals and enlarged mandibular foramina. These findings were further affirmed in studies by Kaplan et al. [70] and Lee et al. [66], both of which were based on radiographic findings of the jaws in patients with NF-1. Other jaw-related malformations associated with NF-1 encompass increased size of coronoid notch, lateral bowing of mandibular ramus, inferior border notching in the mandible and a decrease in the mandibular angle. Furthermore, notching of the posterior border of the mandibular ramus [71], elongated coronoid process with a deep sigmoid notch [32], hypoplasia of the condyle and zygomatic processes [72] and a neurofibroma involving the articular disc of the TMJ [73] have been reported. Jaw manifestations have also been reported in children with

NF-1. Increased size of coronoid notch, condylar deformity, increased bone density and enlarged mandibular foramen were among the jaw malformations reported in children with NF1 [12]. In a recent study reported by Visnapuu et al. [48], radiologic abnormalities of the jaws were found in more than 25% of the NF-1 patients, with enlargement of the mandibular foramen being the commonest finding. Lorson et al. [65] suggested to include mandibular deformities of the coronoid notch as a pathognomonic sign of NF-1. However, aided by the recent advances in radiographic technology, there are a plethora of osseous deformities ranging from a typical radiolucent lesion up to hypoplastic and dysplastic bone malformations involving the jaws in patients with NF1. A long term radiographic assessment of the facial skeleton (particularly TMJ) is recommended in patients with NF-1 and amongst those with solitary neurofibromas.

9. Clinical relevance and recommendations

Since oral manifestations may be encountered in at least 70% of NF-1 patients [29]; it is imperative for oral healthcare providers to be aware of the clinical oral manifestations of NF. Despite no direct correlations between the severity of oral manifestations and oral health status, the psychological effects of a multisystem disorder like NF-1, combined with oral and dental abnormalities results in significant oral health compromise in majority of the patients. Thus, the importance of patient education toward oral hygiene maintenance and regular dental check-ups must be emphasized to improve the oral health status in patients with NF-1.

Conflicts of interest statement

The authors declare that they have no conflicts of interest and there was no external source of funding for the present study.

Reviewers

Toshinari Mikami, DDS, PhD, Iwate Medical University, Department of Pathology, 2-1-1 Nishitokuta, Yahaba Shiwa-gun, Iwate 028-3694, Japan.

Muhammad Sohail Zafar, College of Dentistry, Taibah University, Al-Madinah Almunawwarrah, Saudi Arabia.

Acknowledgement

The authors would like to thank the College of Dentistry Research Center and Deanship of Scientific Research at King Saud University, Saudi Arabia for funding this research project (Project # FR 0123).

References

- [1] Javed F, Utreja A, Bello Correa FO, et al. Oral health status in children with acute lymphoblastic leukemia. *Crit Rev Oncol Hematol* 2012;83:303–9.
- [2] Javed F, Sundin U, Altamash M, Klinge B, Engstrom PE. Self-perceived oral health and salivary proteins in children with type 1 diabetes. *J Oral Rehabil* 2009;36:39–44.
- [3] Azher U, Shiggaon N. Oral health status of children with acute lymphoblastic leukemia undergoing chemotherapy. *Indian J Dent Res* 2013;24:523.
- [4] Nascimento GG, Seerig LM, Vargas-Ferreira F, Correa FO, Leite FR, Demarco FF. Are obesity and overweight associated with gingivitis occurrence in Brazilian schoolchildren. *J Clin Periodontol* 2013;40:1072–8.
- [5] Javed F, Nasstrom K, Benchimol D, Altamash M, Klinge B, Engstrom PE. Comparison of periodontal and socioeconomic status between subjects with type 2 diabetes mellitus and non-diabetic controls. *J Periodontol* 2007;78:2112–9.
- [6] Javed F, Correa FO, Nooh N, Almas K, Romanos GE, Al-Hezaimi K. Orofacial manifestations in patients with sickle cell disease. *Am J Med Sci* 2013;345:234–7.
- [7] Angst PD, Dutra DA, Moreira CH, Kantorski KZ. Periodontal status and its correlation with haematological parameters in patients with leukaemia. *J Clin Periodontol* 2012;39:1003–10.
- [8] Irigoyen-Camacho ME, Sanchez-Perez L, Molina-Frechero N, Velazquez-Alva C, Zepeda-Zepeda M, Borges-Yanez A. The relationship between body mass index and body fat percentage and periodontal status in Mexican adolescents. *Acta Odontol Scand* 2013;72:48–57.
- [9] Vlassara H, Uribarri J. Advanced glycation end products (AGE) and diabetes: cause, effect, or both? *Curr Diabetes Rep* 2014;14:453.
- [10] Subramaniam P, Gupta M, Mehta A. Oral health status in children with renal disorders. *J Clin Pediatr Dent* 2012;37:89–93.
- [11] Tong HJ, Rudolf MC, Muyombwe T, Duggal MS, Balmer R. An investigation into the dental health of children with obesity: an analysis of dental erosion and caries status. *Eur Arch Paediatr Dent* 2013.
- [12] Bardellini E, Amadori F, Flocchini P, Conti G, Piana G, Majorana A. Oral findings in 50 children with neurofibromatosis type 1. A case control study. *Eur J Paediatr Dent* 2011;12:256–60.
- [13] Shetty B, Umesh Y, Kranti K, Seshan H. Periodontal manifestations of von Recklinghausen neuro fibromatosis. *J Indian Soc Periodontol* 2013;17:253–6.
- [14] Tsang ES, Birch P, Friedman JM, Johnston D, Tucker T, Armstrong L. Prevalence of dental caries in children with neurofibromatosis 1. *Clin Oral Investig* 2010;14:479–80, author reply 80.
- [15] Cunha KS, Barboza EP, Dias EP, Oliveira FM. Neurofibromatosis type I with periodontal manifestation. A case report and literature review. *Br Dent J* 2004;196:457–60.
- [16] D'Ambrosio JA, Langlais RP, Young RS. Jaw and skull changes in neurofibromatosis. *Oral Surg Oral Med Oral Pathol* 1988;66:391–6.
- [17] Gerber PA, Antal AS, Neumann NJ, et al. Neurofibromatosis. *Eur J Med Res* 2009;14:102–5.
- [18] Gutmann DH, Aylsworth A, Carey JC, et al. The diagnostic evaluation and multidisciplinary management of neurofibromatosis 1 and neurofibromatosis 2. *JAMA* 1997;278:51–7.
- [19] Bongiorno MR, Pistone G, Arico M. Manifestations of the tongue in Neurofibromatosis type 1. *Oral Dis* 2006;12:125–9.
- [20] Cnossen MH, de Muinck Keizer-Schrama SMPF. Neurofibromatosis. In: Martini L, editor. *Encyclopedia of endocrine diseases*. New York: Elsevier; 2004. p. 307–13.
- [21] Wainer S. A child with axillary freckling and cafe au lait spots. *Can Med Assoc J* 2002;167:282–3.
- [22] Chen W, Fan PC, Happle R. Partial unilateral lentiginosis with ipsilateral Lisch nodules and axillary freckling. *Dermatology* 2004;209:321–4.

- [23] Cassiman C, Legius E, Spileers W, Casteels I. Ophthalmological assessment of children with neurofibromatosis type 1. *Eur J Pediatr* 2013;172:1327–33.
- [24] Tanaka M, Kataoka H, Joh T. Neurofibroma of the esophagus complicating von Recklinghausen's neurofibromatosis. *Am J Gastroenterol* 2013;108:1935–6.
- [25] Suramya S, Shashikumar P, Shreeshyla HS, Kumar GS. Solitary plexiform neurofibroma of the gingiva: unique presentation in the oral cavity. *J Clin Diagn Res* 2013;7:2090–2.
- [26] McClatchey AI. Neurofibromatosis. *Annu Rev Pathol* 2007;2:191–216.
- [27] Baser ME, R Evans DG, Gutmann DH. Neurofibromatosis 2. *Curr Opin Neurol* 2003;16:27–33.
- [28] Geist JR, Gander DL, Stefanac SJ. Oral manifestations of neurofibromatosis types I and II. *Oral Surg Oral Med Oral Pathol* 1992;73:376–82.
- [29] Shapiro SD, Abramovitch K, Van Dis ML, et al. Neurofibromatosis: oral and radiographic manifestations. *Oral Surg Oral Med Oral Pathol* 1984;58:493–8.
- [30] Schaffer R, Goss L, Romer MM, Kalamchi S. Down syndrome and neurofibromatosis: a case report. *Special Care Dent* 2013.
- [31] Sujatha S, Jatti D. Neurofibromatosis and fibrous dysplasia manifesting in the same patient: a rare case report. *J Investig Clin Dent* 2013.
- [32] Dalili Z, Adham G. Intraosseous neurofibroma and concurrent involvement of the mandible, maxilla and orbit: report of a case. *Iran J Radiol* 2012;9:45–9.
- [33] Jaasaari P, Visnapuu V, Nystrom M, Peltonen S, Peltonen J, Happonen RP. Dental age in patients with neurofibromatosis 1. *Eur J Oral Sci* 2012;120:549–52.
- [34] Curtin JP, McCarthy SW. Perineural fibrous thickening within the dental pulp in type 1 neurofibromatosis: a case report. *Oral Surg Oral Med Oral Pathol Oral Radiol Endod* 1997;84:400–3.
- [35] Freeman MJ, Standish SM. Facial and oral manifestations of familial disseminated neurofibromatosis. Report of a case. *Oral Surg Oral Med Oral Pathol* 1965;19:52–9.
- [36] Kurnatowski A, Plewinska H. A case of neurofibromatosis of the face and oral cavity. *Pol Med J* 1967;6:1244–8.
- [37] Visnapuu V, Pienihakkinen K, Peltonen S, Happonen RP, Peltonen J. Neurofibromatosis 1 and dental caries. *Clin Oral Investig* 2011;15:119–21.
- [38] Mahajan A, Dixit J, Bhardwaj A. Gingival enlargement in neurofibromatosis type I: a case report and literature review. *J Contemporary Dent Pract* 2010;11:57–63.
- [39] Bekisz O, Darimont F, Rompen EH. Diffuse but unilateral gingival enlargement associated with von Recklinghausen neurofibromatosis: a case report. *J Clin Periodontol* 2000;27:361–5.
- [40] Doufexi A, Mina M, Ioannidou E. Gingival overgrowth in children: epidemiology, pathogenesis, and complications. A literature review. *J Periodontol* 2005;76:3–10.
- [41] Clementi M, Barbujani G, Turolla L, Tenconi R. Neurofibromatosis-1: a maximum likelihood estimation of mutation rate. *Hum Genet* 1990;84:116–8.
- [42] Huson SM, Harper PS, Compston DA. Von Recklinghausen neurofibromatosis. A clinical and population study in south-east Wales. *Brain J Neurol* 1988;111(Pt 6):1355–81.
- [43] Stokes RW. Neurofibromatosis: review of the literature. *J Am Osteopathic Assoc* 1986;86:49–52.
- [44] Almas K, Sadig W. Surgical treatment of melanin-pigmented gingiva: an esthetic approach. *Indian J Dent Res* 2002;13:70–3.
- [45] Yeh CJ. Cryosurgical treatment of melanin-pigmented gingiva. *Oral Surg Oral Med Oral Pathol Oral Radiol Endod* 1998;86:660–3.
- [46] Ozbayrak S, Dumlu A, Ercalik-Yalcinkaya S. Treatment of melanin-pigmented gingiva and oral mucosa by CO₂ laser. *Oral Surg Oral Med Oral Pathol Oral Radiol Endod* 2000;90:14–5.
- [47] Friedrich RE, Giese M, Schmelzle R, Mautner VF, Scheuer HA. Jaw malformations plus displacement and numerical aberrations of teeth in neurofibromatosis type 1: a descriptive analysis of 48 patients based on panoramic radiographs and oral findings. *J Craniomaxillofac Surg* 2003;31:1–9.
- [48] Visnapuu V, Peltonen S, Tammissalo T, Peltonen J, Happonen RP. Radiographic findings in the jaws of patients with neurofibromatosis 1. *J Oral Maxillofac Surg* 2012;70:1351–7.
- [49] Visnapuu V, Peltonen S, Ellila T, et al. Periapical cemental dysplasia is common in women with NF1. *Eur J Med Genet* 2007;50:274–80.
- [50] Friedrich RE, Giese M, Stelljes C, Froeder C, Scheuer HA. Size of tooth crowns and position of teeth concerning the extension of facial plexiform neurofibroma in patients with neurofibromatosis type 1. *Anti-cancer Res* 2012;32:2207–14.
- [51] Lammert M, Friedrich RE, Friedman JM, Mautner VF, Tucker T. Early primary tooth eruption in neurofibromatosis 1 individuals. *Eur J Oral Sci* 2007;115:425–6.
- [52] Tucker T, Birch P, Savoy DM, Friedman JM. Increased dental caries in people with neurofibromatosis 1. *Clin Genet* 2007;72:524–7.
- [53] Alves C, Menezes R, Brandao M. Salivary flow and dental caries in Brazilian youth with type 1 diabetes mellitus. *Indian J Dent Res* 2012;23:758–62.
- [54] Maruyama M, Fushiki H, Watanabe Y. Solitary neurofibroma of the floor of the mouth: a case report. *Case Rep Otolaryngol* 2011;2011:967896.
- [55] Jouhilahti EM, Visnapuu V, Soukka T, et al. Oral soft tissue alterations in patients with neurofibromatosis. *Clin Oral Investig* 2012;16:551–8.
- [56] Neville BW, Damm DD, Allen CM, Bouquet JE. Oral and maxillofacial pathology. 2nd ed. Philadelphia: Elsevier; 2002. p. 457–61.
- [57] Kumar CA, Jagat Reddy RC, Gupta S, Laller S. Oral hamartomas with von Recklinghausen disease. *Ann Saudi Med* 2011;31:428–30.
- [58] Ohno J, Iwahashi T, Ozasa R, Okamura K, Taniguchi K. Solitary neurofibroma of the gingiva with prominent differentiation of Meissner bodies: a case report. *Diagn Pathol* 2010;5:61.
- [59] Pawar B, Tejnani A, Sodhi NK, Pendyala G. A silent tumor of the gingiva: an unusual case report and surgical management with 1 year follow-up. *J Indian Soc Periodontol* 2013;17:510–3.
- [60] Evans DG, Baser ME, McGaughran J, Sharif S, Howard E, Moran A. Malignant peripheral nerve sheath tumours in neurofibromatosis 1. *J Med Genet* 2002;39:311–4.
- [61] Muraki Y, Tateishi A, Tominaga K, Fukuda J, Haneji T, Iwata Y. Malignant peripheral nerve sheath tumour in the maxilla associated with von Recklinghausen's disease. *Oral Dis* 1999;5:250–2.
- [62] Sham ME, Ghorpade, Shetty A, Hari S, Vinay. Malignant peripheral nerve cell tumour. *J Maxillofac Oral Surg* 2010;9:68–71.
- [63] Neville BW, Hann J, Narang R, Garen P. Oral neurofibrosarcoma associated with neurofibromatosis type I. *Oral Surg Oral Med Oral Pathol* 1991;72:456–61.
- [64] Muller H, Slootweg PJ. Maxillofacial deformities in neurofibromatosis. *J Maxillofac Surg* 1981;9:89–95.
- [65] Lorson EL, DeLong PE, Osbon DB, Dolan KD. Neurofibromatosis with central neurofibroma of the mandible: review of the literature and report of case. *J Oral Surg* 1977;35:733–8.
- [66] Lee L, Yan YH, Pharoah MJ. Radiographic features of the mandible in neurofibromatosis: a report of 10 cases and review of the literature. *Oral Surg Oral Med Oral Pathol Oral Radiol Endod* 1996;81:361–7.
- [67] Alwan S, Armstrong L, Joe H, Birch PH, Szudek J, Friedman JM. Associations of osseous abnormalities in Neurofibromatosis 1. *Am J Med Genet A* 2007;143A:1326–33.
- [68] Stevenson DA, Yan J, He Y, et al. Multiple increased osteoclast functions in individuals with neurofibromatosis type 1. *Am J Med Genet A* 2011;155A:1050–9.
- [69] Koblin I, Reil B. Changes in the facial skeleton in cases of neurofibromatosis. *J Maxillofac Surg* 1975;3:23–7.
- [70] Kaplan I, Calderon S, Kaffe I. Radiological findings in jaws and skull of neurofibromatosis type 1 patients. *Dentomaxillofac Radiol* 1994;23:216–20.
- [71] Krishnamoorthy B, Singh P, Gundareddy SN, Sharma ML, Dhillon M. Notching in the posterior border of the ramus of mandible in a

- patient with neurofibromatosis type I – a case report. *J Clin Diagn Res* 2013;7:2390–1.
- [72] Avcu N, Kansu O, Uysal S, Kansu H. Cranio-orbital-temporal neurofibromatosis with cerebral hemiatrophy presenting as an intraoral mass: a case report. *J Calif Dent Assoc* 2009;37:119–21.
- [73] Van Damme PA, Freihofer HPM, De Wilde PCM. Neurofibroma in the articular disc of the temporomandibular joint: a case report. *J Cranio-Maxillofac Surg* 1996;24:310–3.

Biography

Dr. Fawad Javed completed his doctoral education and post-doctoral training from the Department of Dental Medicine, Karolinska Institutet, Huddinge, Sweden.

Presently, Dr. Javed is a Research Associate at the Engineer Abdullah Bugshan Research Chair for Growth Factors and Bone Regeneration, 3D Imaging and Biomechanical Laboratory, College of Applied Medical Sciences, King Saud University, Riyadh, Saudi Arabia. Dr. Javed's research interests include oral oncology research, connection between oral inflammatory disorders and systemic conditions particularly diabetes mellitus, impact of smoking and use of smokeless tobacco on oral health, cytokine profile in serum and oral fluids in patients with and without systemic conditions, Implant dentistry, guided bone regeneration and saliva research. Dr. Javed is serving on the Editorial board and member of peer-review panels of several ISI-indexed medical and dental journals.