

Oral mucosal disease: Lichen planus

Crispian Scully^{a,*}, Marco Carrozzo^b

^a University College London, Eastman Dental Institute, UK

^b University of Newcastle, UK

Accepted 19 July 2007

Available online 5 September 2007

Abstract

Lichen planus (LP) is a common disorder in which auto-cytotoxic T lymphocytes trigger apoptosis of epithelial cells leading to chronic inflammation. Oral LP (OLP) can be a source of severe morbidity and has a small potential to be malignant.

The diagnosis of OLP can be made from the clinical features if they are sufficiently characteristic, particularly if typical skin or other lesions are present, but biopsy is recommended to confirm the diagnosis and to exclude dysplasia and malignancy.

OLP is treated with anti-inflammatory agents, mainly the topical corticosteroids, but newer agents and techniques are becoming available.

© 2007 The British Association of Oral and Maxillofacial Surgeons. Published by Elsevier Ltd. All rights reserved.

Keywords: Lichen planus; Oral; Skin

Introduction

Oral lichen planus (OLP) is a common disorder that affects stratified squamous epithelium virtually exclusively. It is seen worldwide, mostly in the fifth to sixth decades of life, and is twice as common in women than in men.^{1–3}

Aetiology and pathogenesis

OLP is a T cell-mediated autoimmune disease but its cause is unknown in most cases.⁴ The increased production of TH1 cytokines is a key and early event in LP, it is genetically induced, and genetic polymorphism of cytokines seems to govern whether lesions develop in the mouth alone (interferon-gamma (IFN- γ) associated) or in the mouth and skin (tumour necrosis factor-alpha (TNF- α) associated).⁵ Activated T cells are then attracted and migrate towards the oral epithelium, further attracted by intercellular adhesion

molecules (ICAM-1 and VCAM), upregulation of epithelial basement membrane extracellular matrix proteins, including collagen types IV and VII, laminin and integrins,⁶ and possibly by CXCR3 and CCR5 signalling pathways.⁷ Cytokines secreted by keratinocytes such as TNF- α and interleukins (IL)-1, IL-8, IL-10, and IL-12 are also chemotactic for lymphocytes. The T cells then bind to keratinocytes and IFN- γ , and subsequent upregulation of p53, matrix metalloproteinase 1 (MMP1) and MMP3⁸ leads to programmed death of cells (apoptosis),^{6,9} which destroys the epithelial basal cells.

The chronic course of OLP may result from the activation of the inflammatory mediator nuclear factor kappa B (NF- κ B),¹⁰ and the inhibition of the transforming growth factor control pathway (TGF-beta/smad) may cause keratinocyte hyperproliferation that leads to the white lesions.¹¹

Associations with systemic disease

LP may be associated with many systemic diseases; few have been confirmed, but infection with hepatitis C virus (HCV) can produce extrahepatic signs of which LP is one.¹² HCV-specific T cells may have a role in the pathogenesis of some cases of OLP.^{13,14} In a recent systematic review that included

* Corresponding author at: Eastman Dental Institute, University College London, 256 Gray's Inn Road, London WC1X 8LD, UK.

Tel.: +44 20 7915 1038; fax: +44 20 7915 1039.

E-mail address: cscully@eastman.ucl.ac.uk (C. Scully).

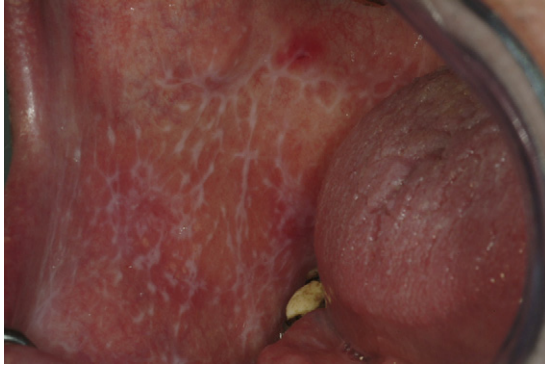

Fig. 1. Reticular lichen planus in the most common site, the buccal mucosa.

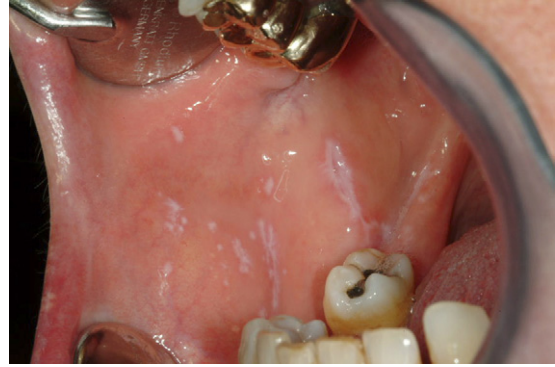

Fig. 3. Papular lichen planus.

controlled studies, the proportion of people infected with HCV was higher in the LP group than in controls in 20 of the 25 studies, and patients with LP had about a five-fold greater risk of being infected with HCV than controls.¹⁵ However, this appears not to be the case in the UK or northern Europe.

HCV-related OLP seems to be associated with the HLA class II allele HLA-DR6 in Italian patients but not in British patients, which could partly explain the peculiar geographical heterogeneity of the association.^{16,17}

Oral lesions

OLP can present as small, raised, white, lacy lesions (Figs. 1 and 2), papules (Fig. 3), or plaques, and can resemble keratotic diseases such as leukoplakia. Atrophic lesions (Fig. 4) and erosions (Fig. 5) are the forms most likely to cause pain.

The most common sites affected are the buccal mucosae, tongue (mainly the dorsum), gingiva, labial mucosa, and vermillion of the lower lip.^{18,2} About 10% of patients with OLP have the disease confined to the gingiva (Fig. 6).¹⁹ Erythematous lesions that affect the gingiva cause desquamative gingivitis, the most common type of gingival LP,²⁰ which can also present as small, raised, white, lacy papules or plaques,

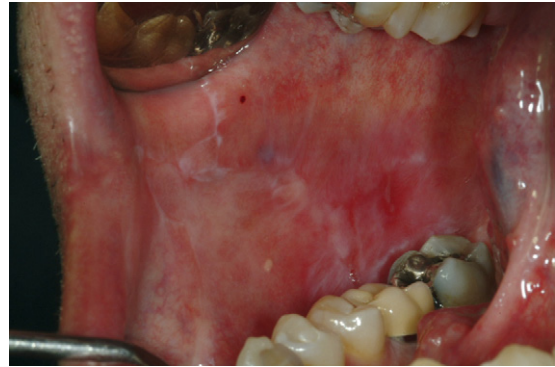

Fig. 4. Atrophic lichen planus.

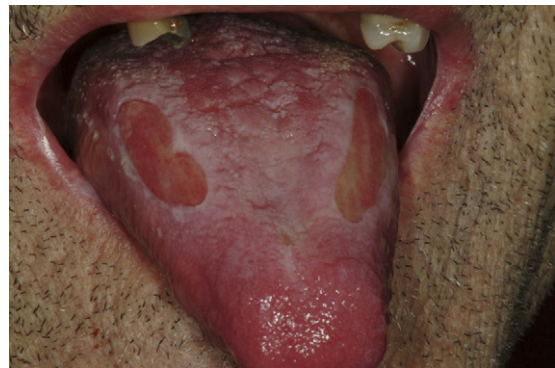

Fig. 5. Erosive lichen planus.

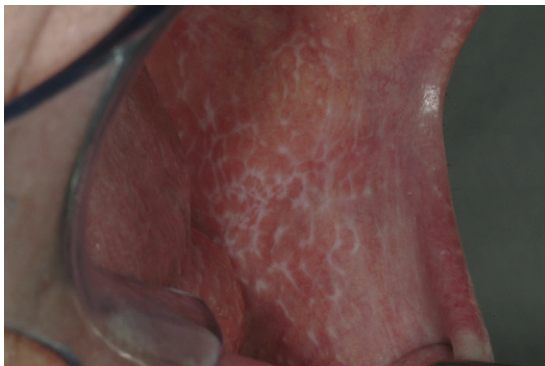


Fig. 2. Reticular lichen planus.

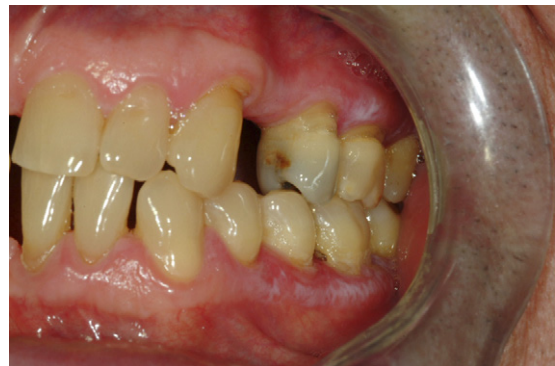

Fig. 6. Gingival lichen planus.

and may resemble keratotic diseases such as frictional keratosis or leukoplakia.

Lesions on the palate, floor of the mouth, and upper lip are uncommon. LP isolated to a single oral site other than the gingiva is also uncommon, but occasional patients with isolated lesions on the lip²¹ or tongue²² have been described. Lichenoid lesions may be isolated (see below).

OLP can be clinically distinctive, though many cases are not. The plaque-like forms of LP may resemble leukoplakia, particularly proliferative verrucous leukoplakia. Striated white lesions, with or without erosions can mimic lupus erythematosus. In rare cases where white lesions cannot be seen in erosive or ulcerated forms, they can be difficult to differentiate clinically from other vesiculoerosive diseases such as pemphigus and pemphigoid. Occasionally lesions may mimic carcinoma.

Malignant potential of OLP

At least three studies using strict diagnostic criteria have shown a significant risk of malignant transformation of OLP to squamous cell carcinoma (SCC).^{24–26} Accumulation of inducible nitric oxide synthase (iNOS) with 8-nitroguanine and 8-oxo-7,8-dihydro-2'-deoxyguanosine (8-oxodG) in oral epithelium in OLP may reflect nitrative and oxidative damage to DNA that could be the basis of malignancy.²⁷

The risk of malignant transformation varies between 0.4 and 5% over periods of observation from 0.5 to 20 years,²⁸ and seems to be independent of the clinical type of OLP or the treatment used.²⁵ However, there remains some concern about treatment with immunosuppressive agents that could theoretically impair defences (see below under Management).

Extraoral lesions

Patients with OLP may develop lesions that affect the skin, skin appendages, or other mucosa.

Skin

About 15% of patients with OLP have or develop cutaneous lesions.²⁹ Typically, these lesions are seen on the flexor surfaces of the forearms and are erythematous to violaceous, flat-topped, pruritic, polygonal papules that have a network of fine lines (Wickham's striae) on the surface, and develop within several months of the appearance of OLP.²⁹ (Fig. 7)

Skin appendages

LP on the scalp can cause scarring alopecia, lichen planopilaris. LP may also affect the nails where it produces thinning and ridging of the nail plate, and splitting of the distal free edge of the nail.

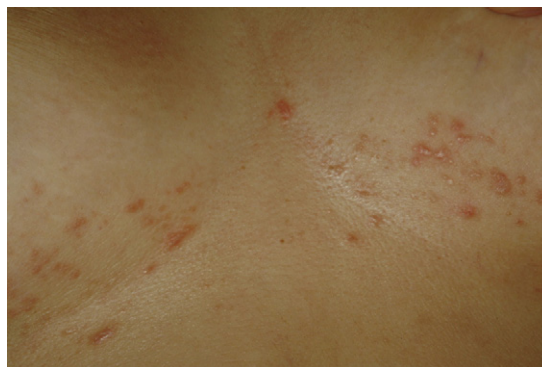

Fig. 7. Cutaneous lichen planus.

Extraoral mucosa

Genital lesions called vulvovaginal-gingival syndrome develop in 20% of women with OLP^{30,31} and present with burning, pain, discharge, and dyspareunia. These lesions may become malignant.^{32,33}

The penogingival syndrome is the male equivalent and may also become malignant.³⁴

Oesophageal LP has been well-documented^{35–37} and is relatively common in patients with oral LP,³⁸ but ocular, urinary, nasal, laryngeal, otic, gastric, and anal mucosa are rarely involved.

Oral lichenoid reactions

Lichenoid reaction is a term used for lesions that resemble OLP clinically and histologically, but have an identifiable aetiology. Precipitants include chronic graft-versus-host disease (cGVHD), some dental materials, and a range of drugs.

There may be a tendency for lichenoid lesions to be unilateral³⁹ and erosive,⁴⁰ and histological examination may show a more diffuse lymphocytic infiltrate with eosinophils and plasma cells, and with more colloid bodies than in classic LP.^{4,39}

Chronic graft-versus-host disease (cGVHD)

Haematopoietic stem cell transplantation is widely used in the treatment of malignant and non-malignant haematological diseases, but is associated with a range of complications, including graft-versus-host disease. Oral lichenoid reactions are often seen in chronic graft-versus-host disease.^{41–43}

Patients who have allogeneic transplantation and are at high risk of developing secondary neoplasms, particularly leukaemias and lymphomas, are also at risk of squamous cell carcinomas, and a number of oral carcinomas have been reported.⁴⁴

Dental restorative materials

Dental restorative materials thought to be causes of oral lichenoid reactions include amalgams, composite resins, cobalt, and gold.⁴⁵ These reactions may be suspected when OLP lesions are confined to the mucosa in close contact with, or in proximity to, the restoration. They are sometimes unilateral. Some authors have suggested that sensitisation to mercury is an important cause,⁴⁶ but others have found few who are sensitised to mercury, with no beneficial effects from removing amalgam restorations,⁴⁷ which suggests that other factors may be involved.⁴⁸

Unfortunately, skin patch testing and biopsy specimens cannot reliably predict the response to the removal of amalgam,^{49,50} but a reaction to a patch test for more than one mercurial allergen can increase the likelihood of an accurate diagnosis.⁵¹

There have also been reports of malignant transformation of restoration-related lichenoid lesions.^{52,53}

Drugs

Drug-induced oral lichenoid reactions are mostly caused by non-steroidal anti-inflammatory agents and angiotensin-converting enzyme inhibitors.^{40,54} Other drugs have also been linked to oral lichenoid reactions, but many of these reports have been based on single cases only.

The most reliable method of diagnosing lichenoid drug reactions is to see if the reaction resolves after the drug has been withdrawn, and if it returns when the drug is taken again. However, this is often not practical and can be potentially dangerous; it may be months before the lichenoid reaction resolves so that empirical withdrawal of the drug in question, and its substitution with another, may be warranted.

Diagnosis of OLP

OLP that presents with classic white lesions may be diagnosed correctly if there are classic skin or other extra-oral lesions. However, an oral biopsy with histopathological examination is recommended both to confirm the clinical diagnosis and particularly to exclude dysplasia and malignancy.

Nevertheless, the histopathological assessment of OLP can be subjective⁵⁵ and, in about half the cases, there is poor clinicopathological correlation.⁵⁶ In these instances it may help to use direct immunofluorescence, which shows a linear pattern of fibrin and shaggy fibrinogen deposits at the epithelial basement membrane or cytooid bodies (Russell bodies), or both, in the absence of deposition of fibrinogen.⁵⁷

Management of OLP

Treatment of LP depends on symptoms, the extent of oral and extra-oral clinical involvement, medical history, and

other factors. In the case of patients with lichenoid lesions, the suspected precipitant should be eliminated.

Patients with reticular and other asymptomatic OLP lesions usually require no active treatment. Mechanical injury or irritants such as rough restoration margins or badly fitting dentures should be given attention, and an optimal programme of oral hygiene instituted, particularly in patients with gingival LP.

Patients with symptomatic lesions may also need treatment, usually with drugs, but occasionally surgery has a role.

Drug treatment

Drug treatment with topical agents is preferred as it has fewer adverse effects. However, systemic agents may be required if lesions are widespread, or there is recalcitrant disease. Drugs for OLP are fundamentally immunosuppressive and few were developed or intended for oral diseases; consequently, we lack adequate studies of their efficacy.⁴ Patients should be warned about the need to follow instructions, particularly when drug instructions state for “external use only”.

Topical corticosteroids

Midpotency topical corticosteroids such as triamcinolone, potent fluorinated steroids such as fluocinolone acetonide and fluocinonide, and superpotent halogenated steroids such as clobetasol, are effective in most patients.^{58–61} Elixirs such as dexamethasone, triamcinolone, and clobetasol can be used as oral rinses for patients with diffuse oral involvement or for those who find it difficult to apply medication to various sites. There are no definitive data to prove that topical steroids in adhesive bases are more effective than other preparations, though they are widely used.^{60,62}

Patients should be instructed to apply the steroid (ointment, spray, rinse, or other form) several times daily, to maintain the drug in contact with the mucosa for a few minutes, and they should refrain from eating and drinking for 1 hour afterwards.

Most studies have shown that topical corticosteroids are safe when applied to mucous membranes for short intervals,^{63,64} and even up to 6 months,⁶⁵ but the potential for adrenal suppression with prolonged use, particularly for a disease that is chronic, necessitates careful and frequent follow-up. Adrenal suppression seems to be more common when steroids are used as mouthwashes.⁶⁶ Few serious adverse effects arise with topical corticosteroids, but up to a third of patients with OLP develop secondary candidiasis, so some clinicians institute antifungal drugs.^{58,59}

Other topical agents

More potent immunosuppressants or immunomodulatory agents such as calcineurin inhibitors (cyclosporin, tacrolimus, or pimecrolimus) or retinoids (tretinoin) can help.

Ciclosporin has been used as a mouth rinse⁶⁷ but is expensive, not particularly effective,⁶⁸ and less effective than topical clobetasol in inducing clinical improvement in OLP, though the two drugs have comparable effects on symptoms.⁶⁸

Tacrolimus, which is up to 100 times more potent than ciclosporin, has been shown to be effective without notable adverse clinical effects in several uncontrolled studies,^{69–74} but accelerates skin carcinogenesis in mice⁷⁵ and so the US Food and Drug Administration (FDA) has restricted its use. Recently an oral cancer has been reported that arose in OLP treated with tacrolimus.⁷⁶

Topical retinoids such as tretinoin or isotretinoin have been used to treat OLP,⁷⁷ particularly atrophic-erosive forms, with considerable improvement,⁷⁸ but retinoids often cause adverse effects and are less effective than topical corticosteroids.⁷⁹

Systemic drug treatment

Some consider systemic corticosteroids to be the most effective treatment for OLP, but a recent comparative study did not find differences in response between systemic prednisone (1 mg/kg/day) with topical clobetasol in an adhesive base and topical clobetasol alone.⁶⁵ Systemic corticosteroids are, therefore, usually reserved for cases where topical approaches have failed, where there is recalcitrant, erosive, or erythematous OLP, or for widespread OLP when skin, genitals, oesophagus, or scalp are also involved. Prednisolone 40 to 80 mg daily is usually sufficient to achieve a response: its toxicity requires that it should be used only when necessary, at the lowest dose, and for the shortest time, possible. It should be taken either for brief periods of time, (5–7 days) and then withdrawn abruptly, or the dose should be reduced by 5–10 mg/day gradually over 2–4 weeks. Adverse effects may be minimised if patients can tolerate the same total dose on alternate days.

Several other systemic immunosuppressive agents have been used in the treatment of OLP, but there has been little evaluation of their efficacy. They include acitretin;⁸⁰ azathioprine;⁸¹ basiliximab;⁸² cyclosporin;⁸³ dapsone;⁸⁴ eiconol;⁸⁵ enoxaparin;⁸⁶ glycyrrhizin;⁸⁷ hydroxychloroquine;²³ interferon alpha;⁸⁸ levamisole;⁸⁹ mycophenolate mofetil;⁹⁰ and thalidomide^{91,92}.

Surgery

Resection has been recommended for isolated plaques or non-healing erosions, because it provides excellent tissue specimens for histopathological confirmation of diagnosis, and is said to cure localised lesions – but there are few data.⁹³ Free soft-tissue grafts have also been used for localised areas of erosive OLP,⁹⁴ and symptomatic OLP disappeared completely after treatment with a free gingival graft after 3.5 years follow-up.⁹⁵ How-

ever, periodontal surgery has also been reported to provoke OLP.⁹⁶

Cryosurgery⁹⁷ has been used particularly in erosive drug-resistant OLP, but lesions may develop in the healing wounds and recur in scars.

Lasers have also been used to treat OLP; carbon dioxide lasers have been used to treat multicentric lesions or difficult areas^{98–100}; and low-dose excimer 308-nm laser seems promising from the results of three small trials,^{101,102} but much more evidence is required to show its efficacy in OLP, as is the case for photodynamic therapy.¹⁰³

Cancer surveillance

In the light of the above, it seems prudent to monitor patients with OLP in the long term.

References

- Carrozzo M, Gandolfo S. The management of oral lichen planus. *Oral Dis* 1999;**5**:196–205.
- Eisen D. The clinical features, malignant potential, and systemic associations of oral lichen planus: a study of 723 patients. *J Am Acad Dermatol* 2002;**46**:207–14.
- Eisen D, Carrozzo M, Bagan Sebastian JV, Thongprasom K. Number V oral lichen planus: clinical features and management. *Oral Dis* 2005;**11**:338–49.
- Scully C, Eisen D, Carrozzo M. Management of oral lichen planus. *Am J Clin Dermatol* 2000;**1**:287–306.
- Carrozzo M, Uboldi de Capei, Dametto E, Fasano ME, Arduino P, Brocoletti R, et al. Tumor necrosis factor-alpha and interferon-gamma polymorphisms contribute to susceptibility to oral lichen planus. *J Invest Dermatol* 2004;**122**:87–94. Erratum in *J Invest Dermatol* 2004;**123**:805.
- Eversole LR. Immunopathogenesis of oral lichen planus and recurrent aphthous stomatitis. *Semin Cutan Med Surg* 1997;**16**:284–94.
- Ichimura M, Hiratsuka K, Ogura N, et al. Expression profile of chemokines and chemokine receptors in epithelial cell layers of oral lichen planus. *J Oral Pathol Med* 2006;**35**:167–74.
- Kim SG, Chae CH, Cho BO, et al. Apoptosis of oral epithelial cells in oral lichen planus caused by upregulation of BMP-4. *J Oral Pathol Med* 2006;**35**:37–45.
- Tanda N, Mori S, Saito K, Ikawa K, Sakamoto S. Expression of apoptotic signaling proteins in leukoplakia and oral lichen planus: quantitative and topographical studies. *J Oral Pathol Med* 2000;**29**:385–93.
- Santoro A, Majorana A, Bardellini E, Festa S, Sapelli P, Facchetti F. NF-kappaB expression in oral and cutaneous lichen planus. *J Pathol* 2003;**201**:466–72.
- Karatsaidis A, Schreurs O, Axell T, Helgeland K, Schenck K. Inhibition of the transforming growth factor-beta/Smad signaling pathway in the epithelium of oral lichen. *J Invest Dermatol* 2003;**121**:1283–90.
- Carrozzo M, Gandolfo S. Oral diseases possibly associated with hepatitis C virus. *Crit Rev Oral Biol Med* 2003;**14**:115–27.
- Carrozzo M, Quadri R, Latorre P, et al. Molecular evidence that the hepatitis C virus replicates in the oral mucosa. *J Hepatol* 2002;**37**:364–9.
- Pilli M, Penna A, Zerbini A, et al. Oral lichen planus pathogenesis: A role for the HCV-specific cellular immune response. *Hepatology* 2002;**36**:1446–52.
- Lodi G, Giuliani M, Majorana A, et al. Lichen planus and hepatitis C virus: a multicentre study of patients with oral lesions and a systematic review. *Br J Dermatol* 2004;**151**:1172–81.

16. Carrozzo M, Francia Di Celle, Gandolfo S, et al. Increased frequency of HLA-DR6 allele in Italian patients with hepatitis C virus-associated oral lichen planus. *Br J Dermatol* 2001;**144**:803–8.
17. Carrozzo M, Brancatello F, Dametto E, et al. Hepatitis C virus-associated oral lichen planus: is the geographical heterogeneity related to HLA-DR6? *J Oral Pathol Med* 2005;**34**:204–8.
18. Silverman Jr S, Gorsky M, Lozada-Nur F. A prospective follow-up study of 570 patients with oral lichen planus: persistence, remission, and malignant association. *Oral Surg Oral Med Oral Pathol* 1985;**60**:30–4.
19. Scully C, el Kom M. Lichen planus: review and update on pathogenesis. *J Oral Pathol* 1985;**14**:431–58.
20. Scully C, Porter SR. The clinical spectrum of desquamative gingivitis. *Semin Cutan Med Surg* 197;**16**:308–13.
21. Allan SJ, Buxton PK. Isolated lichen planus of the lip. *Br J Dermatol* 1996;**135**:145–6.
22. Andreassen JO. Oral lichen planus. 1. A clinical evaluation of 115 cases. *Oral Surg Oral Med Oral Pathol* 1968;**25**:31–42.
23. Eisen D. Hydroxychloroquine sulfate (Plaquenil) improves oral lichen planus: An open trial. *J Am Acad Dermatol* 1993;**28**:609–12.
24. Holmstrup P, Thorn JJ, Rindum J, Pindborg JJ. Malignant development of lichen planus-affected oral mucosa. *J Oral Pathol* 1988;**17**:219–25.
25. Gandolfo S, Richiardi L, Carrozzo M, et al. Risk of oral squamous cell carcinoma in 402 patients with oral lichen planus: a follow-up study in an Italian population. *Oral Oncol* 2004;**40**:77–83.
26. Rodstrom PO, Jontell M, Mattsson U, Holmberg E. Cancer and oral lichen planus in a Swedish population. *Oral Oncol* 2004;**40**:131–8.
27. Chaiyarit P, Ma N, Hiraku Y, et al. Nitrate and oxidative DNA damage in oral lichen planus in relation to human oral carcinogenesis. *Cancer Sci* 2005;**96**:553–9.
28. van der Meij EH, Schepman KP, Smeele LE, van der Wal JE, Bezemer PD, van der Waal I. A review of the recent literature regarding malignant transformation of oral lichen planus. *Oral Surg Oral Med Oral Pathol Oral Radiol Endod* 1999;**88**:307–10.
29. Eisen D. The evaluation of cutaneous, genital, scalp, nail, esophageal, and ocular involvement in patients with oral lichen planus. *Oral Surg Oral Med Oral Pathol Oral Radiol Endod* 1999;**88**:431–6.
30. Rogers III RS, Eisen D. Erosive oral lichen planus with genital lesions: the vulvovaginal-gingival syndrome and the peno-gingival syndrome. *Dermatol Clin* 2003;**21**:91–8.
31. Pelisse M. The vulvo-vaginal-gingival syndrome. A new form of erosive lichen planus. *Int J Dermatol* 1989;**28**:381–4.
32. Dwyer CM, Kerr RE, Millan DW. Squamous carcinoma following lichen planus of the vulva. *Clin Exp Dermatol* 1995;**20**:171–2.
33. Franck JM, Young Jr AW. Squamous cell carcinoma in situ arising within lichen planus of the vulva. *Dermatol Surg* 1995;**21**:890–4.
34. Bain L, Geronemus R. The association of lichen planus of the penis with squamous cell carcinoma in situ and with verrucous squamous carcinoma. *J Dermatol Surg Oncol* 1989;**15**:413–7.
35. Harewood GC, Murray JA, Cameron AJ. Esophageal lichen planus: the Mayo Clinic experience. *Dis Esophagus* 1999;**12**:309–11.
36. Abraham SC, Ravich WJ, Anhalt GJ, Yardley JH, Wu TT. Esophageal lichen planus: case report and review of the literature. *Am J Surg Pathol* 2000;**24**:1678–82.
37. Evans AV, Fletcher CL, Owen WJ, Hay RJ. Oesophageal lichen planus. *Clin Exp Dermatol* 2000;**25**:36–7.
38. Souto P, Sofia C, Cabral JP, et al. Oesophageal lichen planus. *Eur J Gastroenterol Hepatol* 1997;**9**:725–7.
39. Lamey PJ, McCartan BE, MacDonald DG, MacKie RM. Basal cell cytoplasmic autoantibodies in oral lichenoid reactions. *Oral Surg Oral Med Oral Pathol Oral Radiol Endod* 1995;**79**:44–9.
40. Potts AJ, Hamburger J, Scully C. The medication of patients with oral lichen planus and the association of nonsteroidal anti-inflammatory drugs with erosive lesions. *Oral Surg Oral Med Oral Pathol* 1989;**64**:541–3.
41. Nakamura S, Hiroki A, Shinohara M, et al. Oral involvement in chronic graft-versus-host disease after allogeneic bone marrow transplantation. *Oral Surg Oral Med Oral Pathol Oral Radiol Endod* 1996;**82**:556–63.
42. Nicolatou-Galitis O, Kitra V, Van Vliet-Constantinidou C, et al. The oral manifestations of chronic graft-versus-host disease (cGVHD) in paediatric allogeneic bone marrow transplant recipients. *J Oral Pathol Med* 2001;**30**:148–53.
43. Lodi G, Scully C, Carrozzo M, Griffiths M, Sugeran PB, Thongprasom K. Current controversies in oral lichen planus: report of an international consensus meeting. Part 1. Viral infections and etiopathogenesis. *Oral Surg Oral Med Oral Pathol Oral Radiol Endod* 2005;**100**:40–51.
44. Demarosi F, Soligo D, Lodi G, Moneghini L, Sardella A, Carrassi A. Squamous cell carcinoma of the oral cavity associated with graft versus host disease: report of a case and review of the literature. *Oral Surg Oral Med Oral Pathol Oral Radiol Endod* 2005;**100**:63–9.
45. Yiannias JA, el-Azhary RA, Hand JH, Pakzad SY, Rogers III RS. Relevant contact sensitivities in patients with the diagnosis of oral lichen planus. *J Am Acad Dermatol* 2000;**42**:177–82.
46. Koch P, Bahmer FA. Oral lesions and symptoms related to metals used in dental restorations: a clinical, allergological, and histologic study. *J Am Acad Dermatol* 1999;**41**:422–30.
47. Hietanen J, Pihlman K, Forstrom L, Linder E, Reunala T. No evidence of hypersensitivity to dental restorative metals in oral lichen planus. *Scand J Dent Res* 1987;**95**:320–7.
48. Pigatto PD, Guzzi G. Oral lichenoid lesions: more than mercury. *Oral Surg Oral Med Oral Pathol Oral Radiol Endod* 2005;**100**:398–400.
49. Skoglund A. Value of epicutaneous patch testing in patients with oral, mucosal lesions of lichenoid character. *Scand J Dent Res* 1994;**102**:216–22.
50. Ostman PO, Anneroth G, Skoglund A. Amalgam-associated oral lichenoid reactions. Clinical and histologic changes after removal of amalgam fillings. *Oral Surg Oral Med Oral Pathol Oral Radiol Endod* 1996;**81**:459–65.
51. Thornhill MH, Pemberton MN, Simmons RK, Theaker ED. Amalgam-contact hypersensitivity lesions and oral lichen planus. *Oral Surg Oral Med Oral Pathol Oral Radiol Endod* 2003;**95**:291–9.
52. Larsson A, Warfvinge G. Oral lichenoid contact reactions may occasionally transform into malignancy. *Eur J Cancer Prev* 2005;**14**:525–9.
53. Hougeir FG, Yiannias JA, Hinni ML, Hentz JG, el-Azhary RA. Oral metal contact allergy: a pilot study on the cause of oral squamous cell carcinoma. *Int J Dermatol* 2006;**45**:265–71.
54. Robertson WD, Wray D. Ingestion of medication among patients with oral keratoses including lichen planus. *Oral Surg Oral Med Oral Pathol* 1992;**74**:183–5.
55. van der Meij EH, Reibel J, Slootweg PJ, van der Wal JE, de Jong WF, van der Waal I. Interobserver and intraobserver variability in the histologic assessment of oral lichen planus. *J Oral Pathol Med* 1999;**28**:274–7.
56. van der Meij EH, van der Waal I. Lack of clinicopathologic correlation in the diagnosis of oral lichen planus based on the presently available diagnostic criteria and suggestions for modifications. *J Oral Pathol Med* 2003;**32**:507–12.
57. Helander SD, Rogers III RS. The sensitivity and specificity of direct immunofluorescence testing in disorders of mucous membranes. *J Am Acad Dermatol* 1994;**30**:65–75.
58. Lozada-Nur F, Miranda C, Maliksi R. Double-blind clinical trial of 0.05% clobetasol propionate (corrected from propionate) ointment in orabase and 0.05% fluocinonide ointment in orabase in the treatment of patients with oral vesiculoerosive diseases. *Oral Surg Oral Med Oral Pathol* 1994;**77**:598–604.
59. Carbone M, Conrotto D, Carrozzo M, Brocchettoletti R, Gandolfo S, Scully C. Topical corticosteroids in association with miconazole and chlorhexidine in the long-term management of atrophic-erosive oral lichen planus: a placebo-controlled and comparative study between clobetasol and fluocinonide. *Oral Dis* 1999;**5**:44–9.

60. Buajeeb W, Poburksa C, Kraivaphan P. Efficacy of fluocinonone acetone gel in the treatment of oral lichen planus. *Oral Surg Oral Med Oral Pathol Oral Radiol Endod* 2000;**89**:42–5.
61. Thongprasom K, Luengvisut P, Wongwatanakij A, Boonjatturus C. Clinical evaluation in treatment of oral lichen planus with topical fluocinonone acetone: a 2-year follow-up. *J Oral Pathol Med* 2003;**32**:315–22.
62. Lo Muzio L, della Valle A, Mignogna MD, et al. The treatment of oral aphthous ulceration or erosive lichen planus with topical clobetasol propionate in three preparations: a clinical and pilot study on 54 patients. *J Oral Pathol Med* 2001;**30**:611–7.
63. Lehner T, Lyne C. Adrenal function during topical oral corticosteroid treatment. *Br Med J* 1969;**4**:138–41.
64. Plemons JM, Rees TD, Zachariah NY. Absorption of a topical steroid and evaluation of adrenal suppression in patients with erosive lichen planus. *Oral Surg Oral Med Oral Pathol* 1990;**69**:688–93.
65. Carbone M, Goss E, Carrozzo M, et al. Systemic and topical corticosteroid treatment of oral lichen planus: a comparative study with long-term follow-up. *J Oral Pathol Med* 2003;**32**:323–9.
66. Gonzalez-Moles M, Scully C. Vesiculo-erosive oral mucosal disease. Management with topical corticosteroids: 2 Protocols, monitoring of effects and adverse reactions, and the future. *J Dent Res* 2005;**84**:302–8.
67. Eisen D, Ellis CN, Duell EA, Griffiths CE, Voorhees JJ. Effect of topical cyclosporine rinse on oral lichen planus. A double-blind analysis. *N Engl J Med* 1990;**323**:290–4.
68. Conrotto D, Carbone M, Carrozzo M, et al. Cyclosporin vs. clobetasol in the topical management of atrophic and erosive oral lichen planus: a double-blind, randomized controlled trial. *Br J Dermatol* 2006;**154**:139–45.
69. Kaliakatsou F, Hodgson TA, Lewsey JD, Hegarty AM, Murphy AG, Porter SR. Management of recalcitrant ulcerative oral lichen planus with topical tacrolimus. *J Am Acad Dermatol* 2002;**46**:35–41.
70. Olivier V, Lacour JP, Mousnier A, Garraffo R, Monteil RA, Ortonne JP. Treatment of chronic erosive oral lichen planus with low concentrations of topical tacrolimus: an open prospective study. *Arch Dermatol* 2002;**138**:1335–8.
71. Rozycki TW, Rogers III RS, Pittelkow MR, et al. Topical tacrolimus in the treatment of symptomatic oral lichen planus: a series of 13 patients. *J Am Acad Dermatol* 2002;**46**:27–34.
72. Hodgson TA, Sahni N, Kaliakatsou F, Buchanan JA, Porter SR. Long-term efficacy and safety of topical tacrolimus in the management of ulcerative/erosive oral lichen planus. *Eur J Dermatol* 2003;**13**:466–70.
73. Donovan JC, Hayes RC, Burgess K, Leong IT, Rosen CF. Refractory erosive oral lichen planus associated with hepatitis C: response to topical tacrolimus ointment. *J Cutan Med Surg* 2005;**9**:43–6.
74. Shichinohe R, Shibaki A, Nishie W, Tateishi Y, Shimizu H. Successful treatment of severe recalcitrant erosive oral lichen planus with topical tacrolimus. *J Eur Acad Dermatol Venereol* 2006;**20**:66–8.
75. Niwa Y, Terashima T, Sumi H. Topical application of the immunosuppressant tacrolimus accelerates carcinogenesis in mouse skin. *Br J Dermatol* 2003;**149**:960–7.
76. Becker JC, Houben R, Vetter CS, Brocker EB. The carcinogenic potential of tacrolimus ointment beyond immune suppression: a hypothesis creating case report. *BMC Cancer* 2006;**6**:7.[Epub ahead of print].
77. Sloberg K, Hersle K, Mobacken H, Thilander H. Topical tretinoin therapy and oral lichen planus. *Arch Dermatol* 1979;**115**:716–8.
78. Scardina GA, Messina P, Carini F, Maresi E. A randomized trial assessing the effectiveness of different concentrations of isotretinoin in the management of lichen planus. *Int J Oral Maxillofac Surg* 2006;**35**:67–71.
79. Buajeeb W, Kraivaphan P, Poburksa C. Efficacy of topical retinoic acid compared with topical fluocinonone acetone in the treatment of oral lichen planus. *Oral Surg Oral Med Oral Pathol Oral Radiol Endod* 1997;**83**:21–5.
80. Laurberg G, Geiger JM, Hjorth N, et al. Treatment of lichen planus with acitretin. A double-blind, placebo-controlled study in 65 patients. *J Am Acad Dermatol* 1991;**24**:434–7.
81. Lear JT, English JS. Erosive and generalized lichen planus responsive to azathioprine. *Clin Exp Dermatol* 1996;**21**:56–7.
82. Rebora A, Parodi A, Murialdo G. Basiliximab is effective for erosive lichen planus. *Arch Dermatol* 2002;**138**:1100–1.
83. Levell NJ, Munro CS, Marks JM. Severe lichen planus clears with very low-dose cyclosporin. *Br J Dermatol* 1992;**127**:66–7.
84. Beck HI, Brandrup F. Treatment of erosive lichen planus with dapsone. *Acta Derm Venereol* 1986;**66**:366–7.
85. Barer GM, Polovets ML. [The use of eiconol in the combined treatment of lichen ruber planus of the oral mucosa]. *Stomatologiya (Mosk)* 1995;**74**:22–5.
86. Hodak E, Yosipovitch G, David M, et al. Low-dose low-molecular-weight heparin (enoxaparin) is beneficial in lichen planus: a preliminary report. *J Am Acad Dermatol* 1998;**38**:564–8.
87. Da Nagao Y, Sata M, Suzuki H, Tanikawa K, Itoh K, Kameyama T. Effectiveness of glycyrrhizin for oral lichen planus in patients with chronic HCV infection. *J Gastroenterol* 1996;**31**:691–5.
88. Kovesi G. Evaluation of clinical data and immuno-modulating treatment of patients with oral lichen planus. *Fogorvos Sz* 2001;**94**:9–14.
89. Lu SY, Chen WJ, Eng HL. Dramatic response to levamisole and low-dose prednisolone in 23 patients with oral lichen planus: a 6-year prospective follow-up study. *Oral Surg Oral Med Oral Pathol Oral Radiol Endod* 1995;**80**:705–9.
90. Nousari HC, Goyal S, Anhalt GJ. Successful treatment of resistant hypertrophic and bullous lichen planus with mycophenolate mofetil. *Arch Dermatol* 1999;**135**:1420–1.
91. Camisa C, Popovsky JL. Effective treatment of oral erosive lichen planus with thalidomide. *Arch Dermatol* 2000;**136**:1442–3.
92. Macario-Barrel A, Balguerie X, Joly P. [Treatment of erosive oral lichen planus with thalidomide]. *Ann Dermatol Venereol* 2003;**130**:1109–12.
93. Emslie ES, Hardman FG. The surgical treatment of oral lichen planus. *Trans St Johns Hosp Dermatol Soc* 1970;**56**:43–4.
94. Hovick CJ, Kalkwarf KL. Treatment of localized oral erosive lichen planus lesions with free soft tissue grafts. *Periodontal Case Rep* 1987;**9**:21–4.
95. Tamizi M, Moayed M. Treatment of gingival lichen planus with a free gingival graft: a case report. *Quintessence Int* 1992;**23**:249–51.
96. Katz J, Goultschin J, Benoliel R, Rotstein I, Pisanty S. Lichen planus evoked by periodontal surgery. *J Clin Periodontol* 1988;**15**:263–5.
97. Malmstrom M, Leikomaa H. Experiences with cryotherapy in the treatment of oral lesions. *Proc Finn Dent Soc* 1980;**76**:117–23.
98. Frame JW, Das Gupta AR, Dalton GA, Rhys Evans PH. Use of the carbon dioxide laser in the management of premalignant lesions of the oral mucosa. *J Laryngol Otol* 1984;**98**:1251–60.
99. Horch HH, Gerlach KL, Schaefer HE. CO₂ laser surgery of oral premalignant lesions. *Int J Oral Maxillofac Surg* 1986;**15**:19–24.
100. Huerta Leteurtre N, Bagan Sebastian JV, Cardona Tortajada F, Lloria De Miguel E, Jimenez Soriano Y, Basterra Algeria J. Oral lichen planus plaques and homogeneous leukoplakia: comparative results of treatment with CO₂ laser. *Acta Otorrinolaringol* 1999;**50**:543–7.
101. Trehan M, Taylor CR. Low-dose excimer 308-nm laser for the treatment of oral lichen planus. *Arch Dermatol* 2004;**140**:415–20.
102. Kollner K, Wimmershoff M, Landthaler M, Hohenleutner U. Treatment of oral lichen planus with the 308-nm UVB excimer laser—early preliminary results in eight patients. *Lasers Surg Med* 2003;**33**:158–60.
103. Aghahosseini F, Arbabi-Kalati F, Fashtami LA, Djavid GE, Fateh M, Beitollahi JM. Methylene blue-mediated photodynamic therapy: a possible alternative treatment for oral lichen planus. *Lasers Surg Med* 2006;**38**:33–8.