

Immunohistochemical expression of progesterone and estrogen receptors in meningiomas

Aleksandra Omulecka, Wielisław Papierz, Agnieszka Nawrocka-Kunecka, Iwona Lewy-Trenda

Department of Pathology, Medical University of Lodz

Folia Neuropathol 2006; 44 (2): 111-115

Abstract

In this study we present results of investigations of progesterone and estrogen receptors in most frequent, WHO grade I histological types of meningiomas (meningothelial, fibrous, and transitional) and in atypical – WHO grade II variant of these tumors. Samples from 64 tumors were examined. The cohort consisted of 46 WHO grade I (21 transitional, 13 fibrous and 12 meningothelial histologic variants) and of 18 atypical meningiomas. Apart from immunohistochemical examination of progesterone and estrogen receptors, MIB 1 labeling index was estimated. Positive immunoreaction for progesterone receptors was found in 100% meningothelial, 95% transitional, 46% fibrous and 78% atypical variant of meningiomas. Intensity of immunoreaction was stronger in grade I than in grade II tumors. Immunoexpression of estrogen receptors was found in 48% of the investigated meningiomas. No correlation was stated between WHO grade I and grade II tumors, and between meningothelial, transitional and fibrous variants of the neoplasms.

Key words: *estrogen receptors, progesterone receptors, meningiomas, proliferation*

Introduction

Meningiomas are neoplasms which occur more frequently in women than in men. The women/men ratio is estimated as 3:2 for cases with an intracranial localization of tumors, and even 10:1 for tumors localized within the vertebral canal [8]. The majority of meningiomas show the presence of progesterone receptors (PgR). Rarely, estrogen receptors (ER) in these tumors are also revealed [3,4,11,12,14,16,22].

Some authors indicate a correlation between the rate of growth of these neoplasms and pregnancy and the luteal phase of the cycle, as well as coexistence of

meningiomas and breast cancer [1,18,21]. Additionally, there is information about the relation between presence of steroid hormones receptors in meningiomas cells and proliferation index of these tumors [12,19,23,24].

These data suggest a role of sex hormones in the genesis of these neoplasms.

In this study, we present results of investigations of progesterone and estrogen receptors immunoexpression in the most frequent WHO grade I histological types of meningiomas (meningothelial MM, fibrous MF and transitional MT ones) and in atypical MA, WHO grade II variant of these tumors.

Communicating author:

Aleksandra Omulecka, MD, Department of Pathology Medical University of Lodz, Czechosłowacka 8/10, 92-216 Łódź; tel./fax +48 42 679 01 91, e-mail: olaomulecka@poczta.onet.pl

Table I. Meningioma type and age characteristics of the studied tumors

Histologic type of meningioma	Number of cases	Mean age±SD
MA	18	62.56±11.34
MM	12	53.83±15.14
MT	21	50.48±14.84
MF	13	50.92±10.12
total	64	54.59±13.81

Table II. Grade and age characteristics of the examined meningiomas

Histologic grade	Number of cases	Mean age±SD
G1	46	51.48±13.54
G2	18	62.56±11.34
total	64	54.59±13.81

Table III. Expression of progesterone receptors in meningiomas (Chi²=37.852; df=9, p<0.05)

Histologic type	PGR 0	PGR 1	PGR 2	PGR 3	Total
MA	4	11	2	1	18
MT	1	5	6	9	21
MF	7	0	4	2	13
MM	0	2	6	4	12
total	12	18	18	16	64

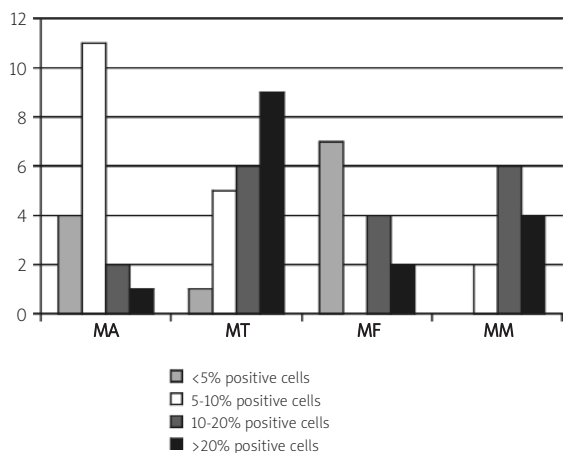


Fig. 1. Progesterone receptor expressions in meningiomas

Material and methods

The postoperative material of tumors was obtained from 64 patients who were operated because of meningioma (28 men and 36 women) (Table I).

Histological diagnosis of tumors was formulated according to the criteria of the WHO 2000 classification [15].

The cohort consisted of 46 WHO grade I meningiomas (21 transitional MT, 13 fibrous MF and 12 meningotheelial MM variants of the tumors) and 18 WHO grade II - atypical meningiomas MA (Table II).

Immunohistochemistry: Immunohistochemical reactions were performed in paraffin slides (4 µm thin). Monoclonal antibodies against ER, PGR, and MIB-1 antibody produced by Novocastra have been used. The reactions were performed according to the procedures suggested by the manufacturer. The MIB-1 labeling index was calculated for every 1000 tumor cells, using a computer analysis system.

The PgR immunopositivity was recognized for cells with a nuclear localization of the reaction product. The nuclear and cytoplasmic localization of reaction present at least in 5% of tumor cells was treated as positive for estrogen receptors. Intensity of the immunoreaction was estimated in 0-3 scale using the following system: less than 5% positive cells - PGR 0; 5-10% positive cells - PGR 1; 11-20% positive cells - PGR 2; more than 20% positive cells - PGR 3.

Statistic analysis: Mean values and standard deviation have been calculated for each histological type of tumor, and for grade 1 and grade 2 group of meningiomas. Non-parametric tests of the Mann-Whitney U-test and Kruskal-Wallis analysis of variance ANOVA, and chi² test have been used. For all tests p<= 0.05 was accepted.

Results

PgR positive nuclear immunoreactivity was found in 83% of the investigated tumors. PGR was shown in 100% cases of meningotheelial, 95.2% transitional, 77.8% atypical and in 42.2% fibrous types of meningiomas (Table III, Fig. 1). A statistically significant relation in PGR expression was revealed between histologic types of the tumors. The number of PgR immunopositive cells in WHO grade I group of tumors was significantly higher than in the group of atypical meningiomas (Fig. 2).

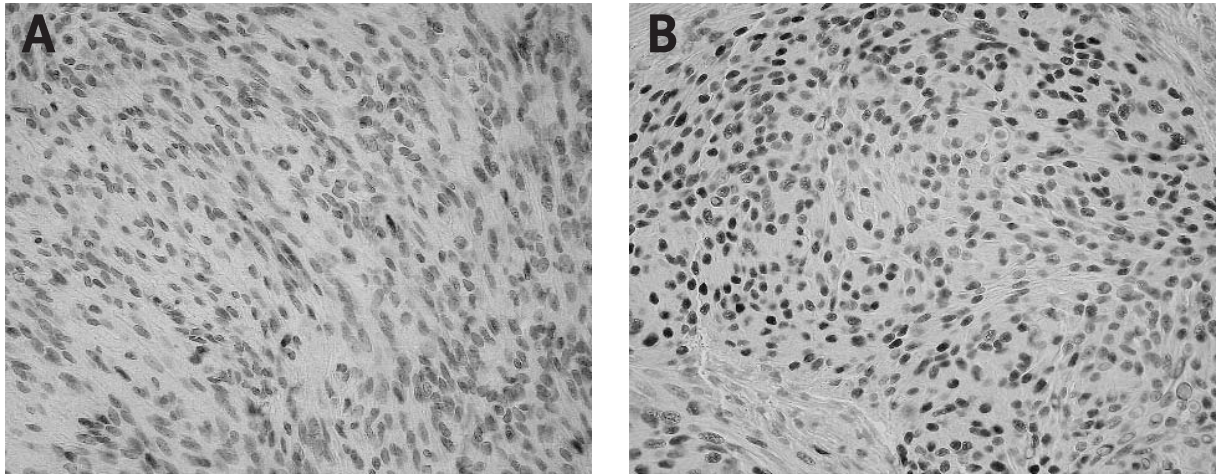


Fig. 2. Nuclear expression for progesterone receptors in atypical (A) and in meningothelial (B) meningiomas. Original magnification 200x

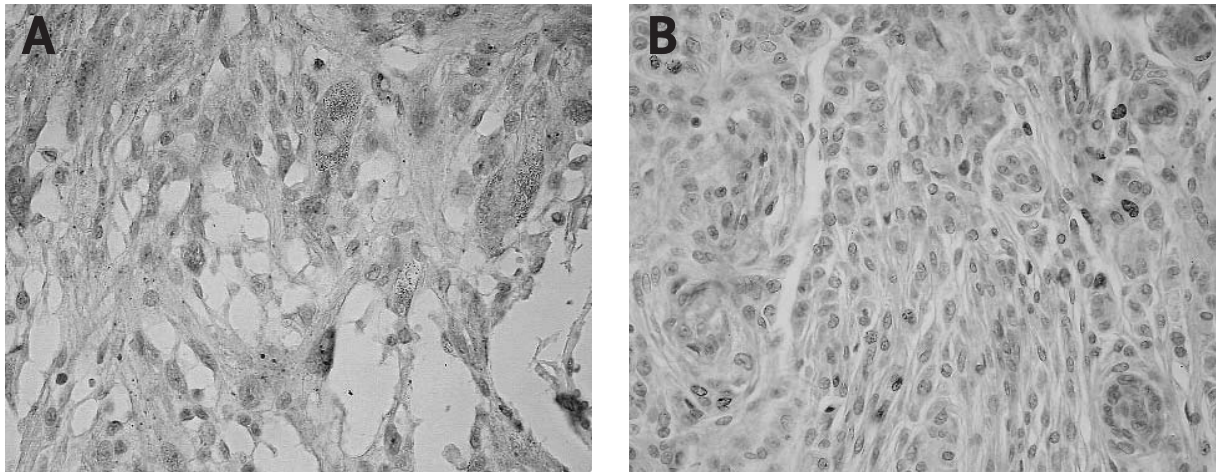


Fig. 3. Immunoreactivity for estrogen receptors: A - cytoplasmic immunoreactivity in atypical meningiomas. Original magnification 400x. B - nuclear expression in transitional meningiomas. Original magnification 200x

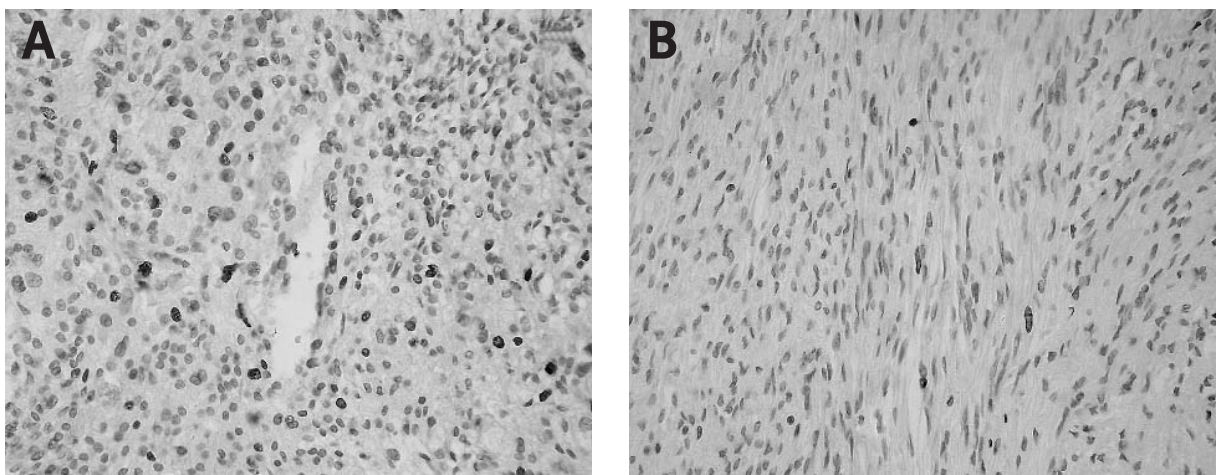


Fig. 4. MIB-1 immunoreactivity in atypical (A) and in fibrous (B) meningiomas. Original magnification 200x

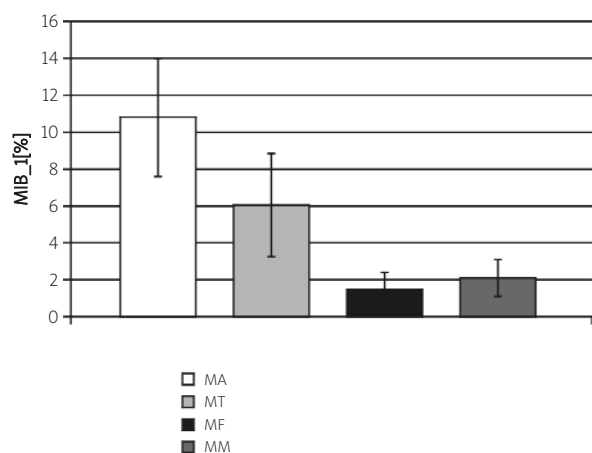


Fig. 5. Expression of MIB-1 in meningiomas

ER was revealed in nuclei and partly in the cytoplasm in 48% of the examined cases, and it had small intensity and focal arrangement (Fig. 3). No statistically significant relation was found between ER and grade of malignancy, nor between ER and histologic variants of tumors. There was also no relation between sex and both of the investigated types of receptors (PgR: $\chi^2=4.092$, $df=3$, $p>0.05$; ER: $\chi^2=2.559$, $df=2$, $p>0.05$).

Additionally, it was shown that the index of proliferation in the group of atypical meningiomas (mean value = 10.8) was significantly higher than in the group of WHO grade I tumors (mean value = 3.7) (Fig. 4 and 5), and that a significant difference exists between the mean age of patients with G I (51.48 ± 13.54), and G II (62.56 ± 11.34) meningiomas.

Discussion

The presence of progesterone and estrogen receptors in cells of meningiomas is well known and has been described for many years [2,5,6,16,20,26].

Like in breast cancer, where the presence of steroids receptors allows to perform additional hormonal therapy, some investigators postulate the possibility of pharmacologic treatment in meningiomas, which would be useful in cases where location of tumor enables total resection, and in cases with a high risk of recurrence like G2 and G3 meningioma [10].

The results of our study confirm that in Polish population PgR immunorexpression is present in above 80% of meningiomas. Most frequently, it is present in the meningioendothelial variant of the tumors. In our study the weakest PgR expression was found in

fibrous meningiomas. This might be explained by the differentiation of cells in these tumors more toward mesenchyme than epithelium-like cells [8,13].

PgR immunorexpression intensity showed a reverse relation of statistic significance with the MIB-1 proliferation index. It was lower in atypical G2 meningiomas comparing to G1 cases. These observations stay in agreement with other studies [12,16,27]. Some authors observed the total loss of PgR in the rate of progression and malignization of meningiomas in G2 and G3 cases [4,12,25]. Fewings et al [9] observed that benign meningiomas, which are PgR positive, are less likely to recur. This finding has prognostic and therapeutic implications. It would be interesting to consider if routine PgR examination in meningioma should not be performed, which might be useful in prediction of recurrence.

Positive ER expression was shown in 48% of the examined tumors. The immunoreaction was focal, and had smaller intensity than reaction with PgR in every examined case. ER immunorexpression did not show any significant relation with histologic type, PgR and MIB-1 expression. It might indicate the independence of two examined receptors in meningiomas. It is possible, however, that weak immunoreaction of ER in paraffin slides may be related to low sensitivity of the method used by us.

In our study we did not find any significant relation between gender and positive ER and PgR immunoreactivity. This result is not in agreement with some other data [15]. Explanation of this discrepancy is difficult, this phenomenon might be related, for example, to wide contraceptive use and hormonal replacement therapy in western population for decades. In Poland, hormonal therapy was introduced about 20 years later, and the number of women using hormones was significantly lower. There are some studies showing that the presence of ER and PgR is more frequent in breast cancer of patients who used hormonal replacement therapy for a long time [17]. Animals research investigations revealed that contraceptives and perinatal treatment with allylestrenol may influence the estrogen receptor state in the uterus [7]. Similar mechanisms may play a role in estrogen and progesterone receptors status in meningiomas.

This study describes the presence and ER and PgR in meningiomas in Polish population for the first time. Results of the investigation bring us closer to answer the question what mechanisms regulate

meningioma growth, and may allow pharmacologic aid in the treatment of these tumors.

Acknowledgement

The study was supported by grant from the Medical University of Lodz No. 502-11-268.

References

- Bickerstaff ER, Small JM, Guest IA. The relapsing course of certain meningiomas in relation to pregnancy and menstruation. *J Neurol Neurosurg Psychiatry* 1958; 21: 89-91.
- Blankenstein MA, Verheijen FM, Jacobs JM, Donker TH, van Duijnhoven MW, Thijssen JH. Occurrence, regulation, and significance of progesterone receptors in human meningioma. *Steroids* 2000; 65: 795-800.
- Bouillot P, Pellissier JF, Devictor B, Graziani N, Bianco N, Grisoli F, Figarella-Branger D. Quantitative imaging of estrogen and progesterone receptors, estrogen-regulated protein, and growth fraction: immunohistochemical assays in 52 meningiomas. Correlation with clinical and morphological data. *J Neurosurg* 1994; 81: 765-773.
- Brandis A, Mirzai S, Tatagiba M, Walter GF, Samii M, Ostertag H. Immunohistochemical detection of female sex hormone receptors in meningiomas: correlation with clinical and histological features. *Neurosurgery* 1993; 33: 212-217.
- Carroll RS, Glowacka D, Dashner K, Black PM. Progesterone receptor expression in meningiomas. *Cancer Res* 1993; 53: 1312-1316.
- Carroll RS, Zhang J, Black PM. Expression of estrogen receptors alpha and beta in human meningiomas. *J Neurooncol* 1999; 42: 109-116.
- Csaba G, Gonda AI, Karabelyos C. Contraceptive treatment increases the affinity of uterine estrogen receptor In adult rat: perinatal gestagen treatment changes the reaction. *Horm Metab Res* 1996; 28: 16-19.
- Ellison D, Love S, Chimelli L, Harding BN, Lowe J, Vinters HV. A reference text of CNS pathology. Mosby, Edinburgh 2004.
- Fewings PE, Battersby RD, Timperley WR. Long-term follow-up of progesterone receptor status in benign meningioma: a prognostic factor of recurrence? *J Neurosurg* 2000; 92: 401-405.
- Grunberg SM, Weiss MH, Spitz IM, Amahdi J, Sadun A, Russell CA, Lucci L, Stevenson LL. Treatment of unresectable meningiomas with the antiprogestosterone agent mifepristone. *J Neurosurg* 1991; 74: 861-866.
- Halper J, Colvard DS, Scheithauer BW, Jiang NS, Press MF, Graham ML, Riehl E, Laws ER, Spelsberg TS. Estrogen and progesterone receptors in meningiomas: comparison of nuclear binding, dextran coated charcoal and immunoperoxidase staining assays. *Neurosurgery* 1989; 25: 546-553.
- Hsu DW, Efrid JT, Hedley-Whyte ET. Progesterone and estrogen receptors in meningiomas: prognostic considerations. *J Neurosurg* 1997; 86: 113-120.
- Kepes JJ. Presidential address: the histopathology of meningiomas. A reflection of origins and expected behavior? *J Neuropathol Exp Neurol* 1986; 45: 95-107.
- Khalid H. Immunohistochemical study of estrogen receptor-related antigen, progesterone and estrogen receptors in human intracranial meningiomas. *Cancer* 1994; 74: 679-685.
- Kleiheus P, Cavenee WK. WHO classification. Tumours of the Nervous System. IARC Press, Lyon 2000.
- Konstantinidou AE, Korkolopoulou P, Mahera H, Kotsiakis X, Hranioti S, Eftychiadis C, Patsouris E. Hormone receptors in non-malignant meningiomas correlate with apoptosis, cell proliferation and recurrence-free survival. *Histopathology* 2003; 43: 280-290.
- Li CI, Malone KE, Porter PL, Weiss NS, Tang M-TC, Cushing-Haugen KL, Daling JR. Relationship between long durations and different regimens of hormone therapy and risk of breast cancer. *JAMA* 2003; 289: 3254-3263.
- Lieu AS, Hwang SL, Howng SL. Intracranial meningioma and breast cancer. *J Clin Neurosci* 2003; 10: 553-556.
- Markwalder TM, Zava DT, Goldhirsch A, Markwalder RV. Estrogen and progesterone receptors in meningiomas in relation to clinical and pathologic features. *Surg Neurol* 1983; 20: 42-47.
- Maxwell M, Galanopoulos T, Neville-Golden J, Antoniadis HN. Expression of androgen and progesterone receptors in primary human meningiomas. *J Neurosurg* 1993; 78: 456-462.
- Mehta D, Khatib R, Patel S. Carcinoma of the breast and meningioma. Association and management. *Cancer* 1983; 51: 1937-1940.
- Moresco RM, Scheithauer BW, Lucignani G, Lombardi D, Rocca A, Losa M, Casati R, Giovanelli M, Fazio F. Oestrogen receptors in meningiomas: a correlative PET and immunohistochemical study. *Nucl Med Commun* 1997; 18: 606-615.
- Nagashima G, Aoyagi M, Wakimoto H, Tamaki M, Ohno K, Hirakawa K. Immunohistochemical detection of progesterone receptors and the correlation with Ki-67 labeling indices in paraffin-embedded sections of meningiomas. *Neurosurgery* 1995; 37: 478-482.
- Perrot-Appianat M, Groyer-Picard MT, Kujas M. Immunohistochemical study of progesterone receptor in human meningioma. *Acta Neurochir (Wien)* 1992; 115: 20-30.
- Perry A, Cai DX, Scheithauer BW, Swanson PE, Lohse CM, Newsham IF, Weaver A, Gutman DM. Merlin, DAL-1 and progesterone receptor expression in clinico pathologic subsets of meningioma: a correlative immunohistochemical study of 175 cases. *J Neuropathol Exp Neurol* 2000; 59: 872-879.
- Speirs V, Boyle-Walsh E, Frazer WD. Constitutive co-expression of estrogen and progesterone receptor in human meningiomas by RT-PCR and response of cell cultures to steroid hormones. *Int J Cancer* 1997; 72: 714-719.
- Tonn JC, Ott MM, Bouterfa H, Kerkan S, Kapp M, Muller-Hemerlink HK, Roosen K. Inverse correlation of cell proliferation and expression of progesterone receptors in tumor spheroids and monolayer cultures of human meningiomas. *Neurosurgery* 1997; 41: 1152-1159.