

Osteonecrosis of the Jaw associated with the Use of Bisphosphonates

¹Rafael Soares Diniz, ²Francisco José Lima Maciel, ³Andreza De Almeida Bastos Maciel, ⁴Marcio Antônio Rodrigues Araújo
⁵Ana Paula Fernandes Lamha, ⁶Matheus Coelho Bandeca, ⁷Erika Martins Pereira

ABSTRACT

The bisphosphonates (BPs) are drugs used to treat metabolic bone diseases involving intense bone resorption. These compounds are capable of altering the bone remodeling by decreasing osteoclast activity. However, the changes that these drugs cause to the bones of patients without a history of cervico-facial radiotherapy can result in a complication called osteonecrosis of the jaw, which is caused by dental surgery, trauma or infections. Osteonecrosis of the jaw is characterized by an exposed necrotic bone in the maxillofacial region, persisting for prolonged periods without complete healing. Based on clinical experience and literature review, the aim of the present study was to describe a clinical case of a patient with osteoporosis taking alendronate (Fosamax[®]) to control the progression of the disease with a characteristic clinical condition of osteonecrosis of the jaw. We evaluated the etiological factors, the relationship between BPs and osteonecrosis of the jaw, the mechanisms of action and possible treatments.

Keywords: Bisphosphonates, Jaws, Osteonecrosis.

How to cite this article: Diniz RS, Maciel FJL, De Almeida Bastos Maciel A, Araújo MAR, Lamha APF, Bandeca MC, Pereira EM. Osteonecrosis of the Jaw associated with the Use of Bisphosphonates. *World J Dent* 2015;6(2):116-122.

Source of support: Nil

Conflict of interest: None

INTRODUCTION

It is common to find patients seeking dental care who take medication that would require special attention and knowledge of the surgeon-dentist because these drugs may interfere and directly change diagnosis, treatment plan or prognosis of the patient.¹

Bisphosphonates (BPs) are responsible for the physiological regulation of calcification and bone resorption and they are unquestionably associated with significant improvement in the quality of life of patients with

various specific disorders involving bone resorption, such as osteoporosis, malignant hypercalcemia, osteolytic lesions, resulting from multiple myeloma, Paget's disease, pathological fractures, spinal cord compression, bone metastasis and soft-tissue tumors.²⁻⁴

This class of drugs has been used worldwide on a large scale and more than 3 million patients diagnosed with cancer or postmenopausal osteoporosis have been treated with intravenous or oral BPs to control the progression of the disease.⁵

Marx et al⁶ was the first to report a peculiar dental manifestation associated with the use of BP-based drugs called osteonecrosis associated with BPs. This clinical alteration is due to exposed necrotic bone in the maxilla, mandible, or both, associated with the chronic use of these drugs, which is most often triggered by injuries to the bone tissue caused by extractions, surgeries involving bone exposure, trauma or infections.^{6,7}

Based on the scientific literature, the aim of this study was to conduct a review of the etiological factors, the relationship between BPs and osteonecrosis of the jaw, the mechanisms of action and possible types of treatments. In addition, this study describes a clinical case of a patient with osteoporosis taking alendronate (Fosamax[®]) to control progression of the disease, who presented clinical conditions of osteonecrosis of the jaw, and was treated in accordance with the protocol of the American Association of Oral and Maxillofacial Surgeons (AAOMS).⁸

LITERATURE REVIEW

Bisphosphonates

Bisphosphonate compounds are stable synthetic analogs of inorganic pyrophosphate that are present in the body and have an endogenous regulatory function in bone mineralization. Because they are structurally very similar, the BPs have the same affinity for calcium due to the presence of a central carbon atom, forming hydroxyapatite crystals in the bone tissue.^{9,10}

By presenting structural changes, the BPs do not act in the regulation of bone mineralization but they inhibit osteoclasts, and show greater resistance to enzymatic degradation and solubility in water due to the central carbon atom.^{3,11,12}

¹Assistant Professor, ²⁻⁷Professor

¹Department of Maxillofacial Surgery, CEUMA University São Luis, Brazil

^{2,3,5,6}Department of Dentistry, CEUMA University, São Luis, Brazil

^{4,7}Department of Dentistry, UFMA, São Luis, Brazil

Corresponding Author: Andreza De Almeida Bastos Maciel Professor, Department of Dentistry, Rua Josue Montello, S/N Renascença, São Luis, Maranhão, Brazil, e-mail: and.bastos@uol.com.br

The BPs are classified into two categories: non-nitrogenous BPs (first generation—Etinodrate, Clorionate) and the nitrogen-containing BPs (second generation—pamidronate, alendronate, ibandronate and risedronate). The non-nitrogenous were the first to be used in the pharmaceutical industry, but because they were found to have weak binding to hydroxyapatite crystals, they were not used due to this low intensity. The nitrogen-containing BPs are the most widely used because they have double potency.²

The mechanism of action of BPs occurs in the bone remodeling process, which consists of a normal and physiological action in which formation and resorption occur in the same proportion. It is of great importance in the repair of fractures, injuries and microdamage that constantly occurs in our body particularly in the region of the jaws due to the masticatory load generated by traction and pressure and penetration of bacteria in the gingival sulcus, or traumatic brushing.^{13,14}

Generally, bone remodeling occurs continuously and it is important in the metabolism of bone tissue, so when there is a decrease in levels of calcium, the osteoclasts resorb bone to send calcium into the circulation.^{3,14}

Basically, BPs inhibit the recruitment and differentiation of osteoclast precursor cells, inducing apoptosis of the differentiated osteoclasts and inhibiting active osteoclasts. Thus bisphosphonate causes the osteoclasts to lose their function leading to cell apoptosis.¹⁵

However, one must bear in mind that since removal of bone tissue will not occur due to the lack of remodeling, the old bone ends up presenting areas of hypermineralization without living cells due to the atrophy of blood capillaries and reduction in the formation of new blood vessels within the bone tissue, making it avascular, thus characterizing the antiangiogenic effect of BPs.^{16,17} Another feature is the induction of apoptosis or programmed cell death of keratinocyte cells, which are responsible for the formation of the oral mucosa and lining of the underlying bone tissue, by BPs.^{1,3,17}

The decision of the physician regarding the administration of BPs depends on the type of disease to be treated. Oral administration is mainly indicated to treat osteoporosis, but it can be indicated in less common pathologies, such as Paget's disease and osteogenesis imperfecta in childhood.⁸ Intravenous administration of BPs is the therapy of choice for patients with cancer who have moderate to severe malignant hypercalcemia, osteolytic bone metastases associated with any solid tumor, in conjunction with antineoplastic drugs, for its use is well tolerated in these patients due to its proven efficacy in controlling bone pain and reduced incidence of pathologic fractures and significantly reducing morbidity originated from the complications of bone metastases.^{6,9}

Another feature of BPs is that when incorporated into the bone tissue of patients with chronic use, it can remain in the body for about 10 years.¹⁸

Alendronate sodium is used by over 190 million people worldwide to treat osteoporosis. It has a relative potency of 1000×, when the route of administration is oral.¹⁹⁻²¹ Pamidronate and zoledronic acid, both with high potency and used intravenously, are the most commonly used to manage patients with malignant bone metastases, most commonly breast or prostate cancer, with a potency of 100× and 10,000× respectively.²⁰

The adverse effects of BPs may cause gastrointestinal intolerance, headache, bone pain, nausea, fever, hypocalcemia, hypophosphatemia, hypercholesterolemia, increased serum creatinine, hypertension, skin rash, dizziness, among other effects.⁴ Currently, a new clinical entity with great relevance to health professionals called bisphosphonate-associated osteonecrosis of the jaw (BONJ)⁹ has been discovered.

Bisphosphonate-associated Osteonecrosis of the Jaw

Despite the benefits of BP therapy, these drugs have been associated with a serious complication that affects only the mandible and maxilla called BONJ.²² Marx et al⁶ reported a series of 36 cases of BONJ in the United States involving patients who were chronic users of intravenous pamidronate (Aredia[®]) and zoledronate (Zometa[®]) used to treat metastatic diseases. Bisphosphonate-associated osteonecrosis of the jaw was found in the mandible of 80% of the cases, in the maxilla in 14% and in both in 5% of the patients. This type of lesion is associated with extractions in 78% of the cases and 22% developed spontaneously, however, the authors were able to control and limit the progression of the disease with intermittent use of antibiotics, use of 0.12% chlorhexidine digluconate-based mouthwashes and surgical debridement followed by bone sequestrectomy.^{7,22}

Since then, several other cases have been reported in the literature; 63 cases were found by the University of Maryland,⁴ Marx et al²³ found 119 cases in 2005 related to the use of oral alendronate sodium (Fosamax[®]) to treat osteoporosis.

Epidemiologically, BONJ is not yet well completely understood. Until 2009, 6,000 cases were recorded at FDA—Food and Drug Administration. It is believed that of all persons who use oral BPs, approximately 0.1% develop BONJ. As for the intravenous use, the estimate increases from 0.8 to 0.12%.^{17,23}

This type of lesion may be caused by trauma due to tooth extraction or after an implant procedure, poorly fitted dentures and orthodontic appliances.^{6,9} The

spontaneous development is characterized by the absence of any apparent cause, being exclusively related to the death of keratinocytes.¹

With respect to the drug, there are two main factors that deserve close attention when assessing the risk of developing BONJ, which is the duration of therapy and drug potency. With regard to the duration of BP therapy, studies show that long-term treatment is associated with a higher risk of lesion, particularly when using oral BPs for 3 or more years. As for the potency, zoledronic acid and pamidronate, both administered intravenously, are more potent than oral Alendronate sodium, which makes the lesion more closely related to the use of intravenous administration.⁴ This characteristic is due to the high bioavailability of intravenous BP (at least 50%) when compared with the oral administration (only 1%) and the relative potency of these drugs.²⁵

Clinically, BONJ first manifests through signs and symptoms, such as bone pain, which can be mild in the case of spontaneous development, small ulcerations in the oral mucosa, exposed bone that does not heal after 8 weeks, after chronic use of BPs and without radiotherapy in the jaws.^{26,27}

According to AAOMS,^{4,8} osteonecrosis is characterized by the following stages: Stage I—presence of exposed necrotic bone in patients who use the drug, but asymptomatic and without any evidence of infection; stage II—exposed necrotic bone associated with infection, pain, and erythema in the region of the lesion with or without purulent drainage; stage III—exposed necrotic bone associated with infection, pain, and one or more alterations, such as pathologic fracture, extraoral fistula or osteolysis/bone sequestration.

Generally, in some cases, the early signs of BONJ are no exposed bone tissue, mottled aspect seen radiographically, bone resorption followed by discontinuation of the affected segment, occasionally in the furcation area and presence of mobility.³ In the patients who use intravenous BP to treat multiple myeloma and other malignant neoplasms, the lesion tends to be more severe and pain is significant followed by secondary infection, involving the maxilla and mandible, which may include the formation of abscesses and extraoral fistulas.¹⁰ It was also noted in the literature that these patients, even those who use oral or intravenous BPs, have a history of tooth extraction but no socket healing after surgery.¹²

According to AAOMS,⁸ there is no well-defined protocol for the treatment of BONJ, which in general should be conservative including antibiotic therapy for a few months, use of 0.12% chlorhexidine digluconate to control secondary infection, resulting in successful

treatment or recurrence of the lesion. Analgesics must be prescribed to control pain, which is accentuated and must be treated first.

Some studies have shown that hyperbaric oxygen therapy is efficient for particular stages of the lesion, since oxygen saturation contributes to increase vascular network and improve the healing process of bone and soft tissues.¹³ Treatments vary depending on the severity of the case and stage of disease. They may be basic and conservative or require partial or total resection of the affected regions.²²

Because the management of patients who use BPs is difficult, prevention is fundamental to avoid the onset of this clinical entity. When initiating therapy with this drug, one should perform previous dental treatment to eliminate infectious foci, impacted teeth and removing areas of frequent trauma.¹³ Recommendations to patients depend on the form of administration of the medication, and patients on intravenous therapy should avoid dental treatment that involves bone injury. For patients taking oral BPs, one should be alert to the risks of bone healing in elective dental surgical procedures, which should be not be contraindicated, but it is recommended to interrupt therapy 3 months before treatment and to resume treatment after 3 months. This is applied to those patients who have been taking the drug for 3 or more years.¹⁸

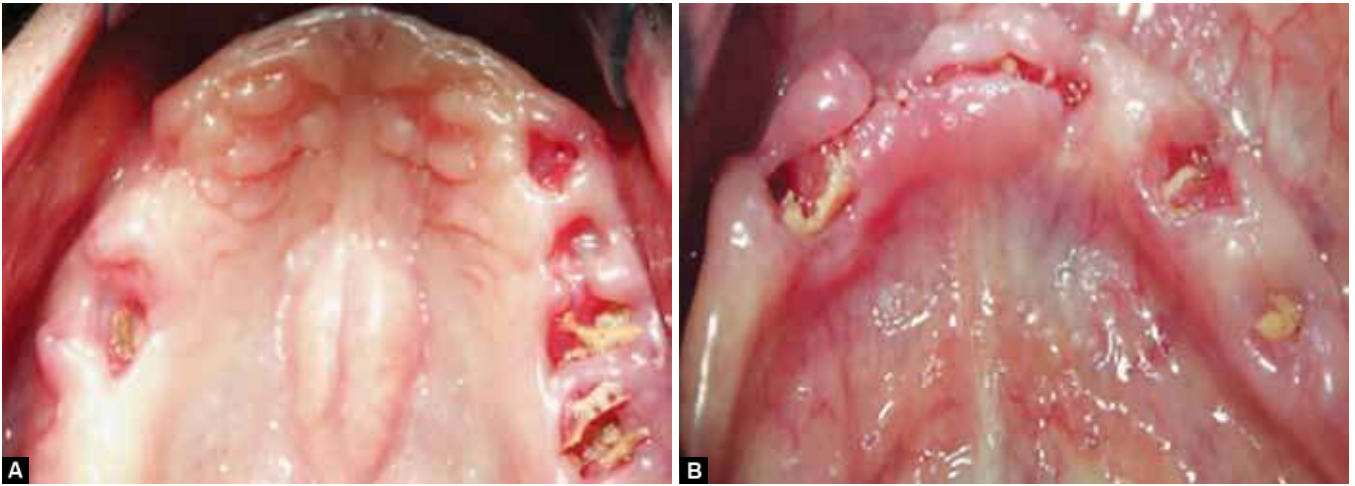
CLINICAL CASE

A 67-year-old patient, MJR, sought the Service of Bucco-Maxillofacial Dental Surgery and Traumatology Center of São José de Ribamar, Maranhão (CEO-SJR/MA) referred for specialized treatment to perform extraction of impacted tooth (mandibular canine) and alveolar ridge regularization for subsequent oral rehabilitation with complete dentures.

After a detailed anamnesis, she reported pain when chewing, osteoporosis, and use of alendronate sodium—70 mg (Fosamax[®]) for 5 years to control progression of disease.

Extraoral clinical examination revealed no significant alteration; intraoral examination revealed absence of all teeth, presence of bone spicules, exposed bone ridge, swollen gums, bleeding to the touch, presence of coated tongue, and palatal torus (Figs 1A and B). With regard to the radiographic examination, the presence of an impacted tooth in the mental region (tooth 43), radiopaque area suggestive of residual root fragment (posterior region on the mandibular right side), presence of trabeculae in the region of the maxillary ridge suggestive of bone healing process after multiple extractions, and great bone resorption in edentulous areas were observed (Fig. 2).





Figs 1A and B: Initial clinical aspect of lesion in the jaw (presence of bone spicule, exposed bone ridge and gingiva with edema)

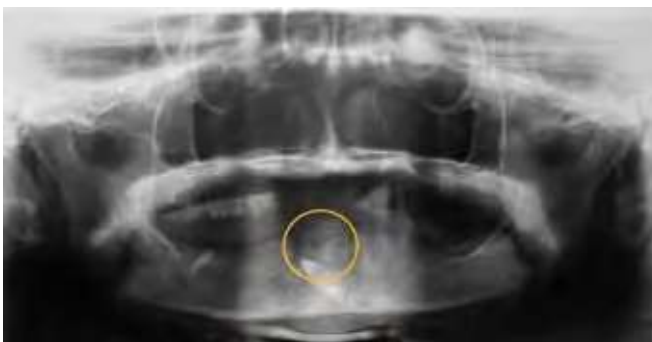


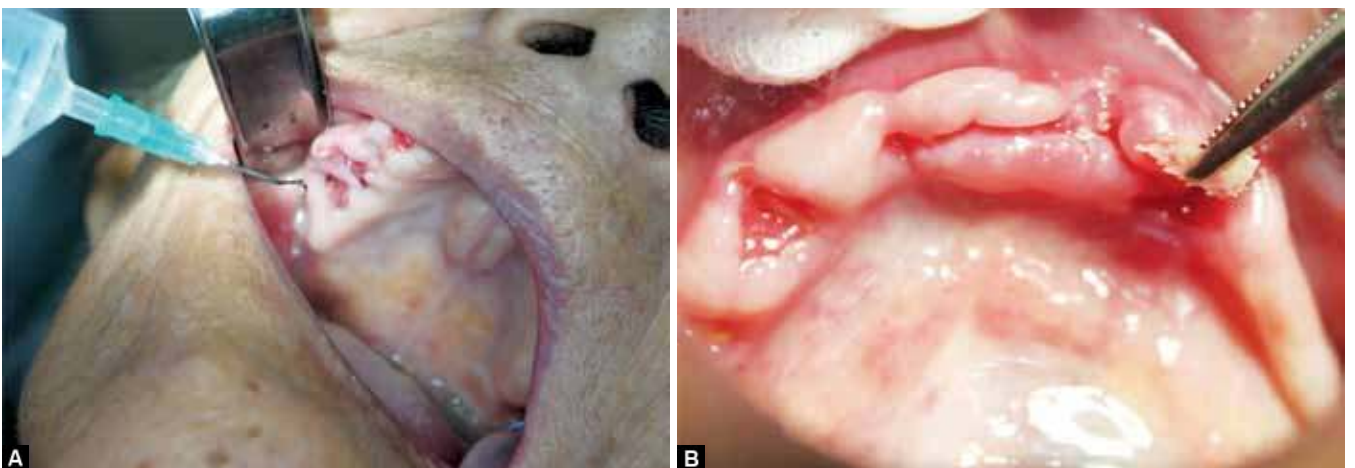
Fig. 2: Panoramic radiography: Presence of an impacted tooth in the mental region (tooth 43), radiopaque area suggestive of residual root fragment and large bone resorption in edentulous areas

Due to the clinical and radiographic findings, the lesion was then diagnosed as being compatible with avascular osteonecrosis, in which local debridement using 0.12% chlorhexidine gluconate was initially performed, followed by partial removal of the exposed bone with mobility (Figs 3A and B), which was stored in a vial containing a formaldehyde solution and sent for histopathological analysis.

Anti-inflammatory-based therapy (oral nimesulide 100 mg, 1 tablet every 12 hours for 3 days), analgesics (dipyrone 500 mg, 35 drops every 6 hours for 3 days) and antimicrobial oral mouthwash (0.12% digluconate chlorhexidine, 30 minutes after brushing for 60 seconds, for 7 days) were used to control pain, inflammation and oral cleansing after surgery.

Fourteen days after the procedure and with the results of the histopathological examination, the patient was diagnosed with avascular osteonecrosis of the jaw as a consequence of the use of BPs. According to her clinical, radiographic and histopathological characteristics, the patient was classified as being in stage III of the disease according to AAOMS,⁸ with exposed necrotic bone associated with infection, pain, halitosis and bone sequestration.

According to the classification of the stage of the disease, we followed the protocol recommended by AAOMS⁸ that consists of debridement of tissue and removal of bone sequestration, causing the margins to bleed to allow them to become accessible to antibiotics,



Figs 3A and B: Debridement and sequestrectomy: (A) Local debridement using 0.12% chlorhexidine digluconate and (B) partial sequestrectomy of exposed bone with mobility

preserving the non-necrotic bone, and local irrigation with 0.12% chlorhexidine digluconate and 0.9% physiological solution.

Bone sequestration was made by removing the mobile exposed bone and bone tissue with necrotic characteristics with the aid of Goyva forceps and curettes for bone regulation and to cover the healthy tissues (Fig. 4). To control pain and infection, analgesics (oral dipyron 500 mg, 35 drops every 6 hours for 3 days), anti-inflammatory (oral nimesulide 100 mg, 1 tablet every 12 hours for 3 days) and antibiotics (oral amoxicillin 500 mg, 1 tablet every 8 hours for 15 days) were prescribed as well as rigorous oral hygiene using mouthwash (0.12% chlorhexidine digluconate).

Fifteen days after the surgery and antibiotic therapy, there was an improvement in the appearance of the initial lesion, a new surgical approach similar to the previous one, except the use of anti-inflammatories (debridement

local, bone sequestration, antibiotic therapy and pain medication) was needed due to the presence of regions with exposed bone margins (Figs 5A and B).

The patient was asked to return for reassessment 21 days after treatment, when we observed a satisfactory improvement of the lesion, with partial closure of the dental alveoli, absence of mobile bone spicule, reduced local pain and halitosis (Figs 6A and B). Irrigation with 0.9% physiological solution and 0.12% chlorhexidine digluconate was performed and the patient was asked to return after 21 days.

After 30 days the patient did not attend the service of buccomaxillofacial surgery of CEO-SJR/MA, so we contacted her family members and they reported that the patient was in a critical condition in intensive care, victim of cerebrovascular accident (CVA). Seventeen days later, the patient died from multiple organ failure as a consequence of CVA.

DISCUSSION

According to reports of Narongroeknawin et al,¹⁷ BPs have become the object of numerous studies in the field of dentistry over the last past years. This is due to the publications of Marx⁶ who first reported painful exposure of bone in the mandible and maxilla in patients who received intravenous pamidronate and zoledronic acid, and Ruggiero et al⁴ who confirmed the relationship between the administration of alendronate sodium, which is the most widely used drug in the treatment of osteoporosis usually administered orally, and exposed bone, as in the present clinical case report.

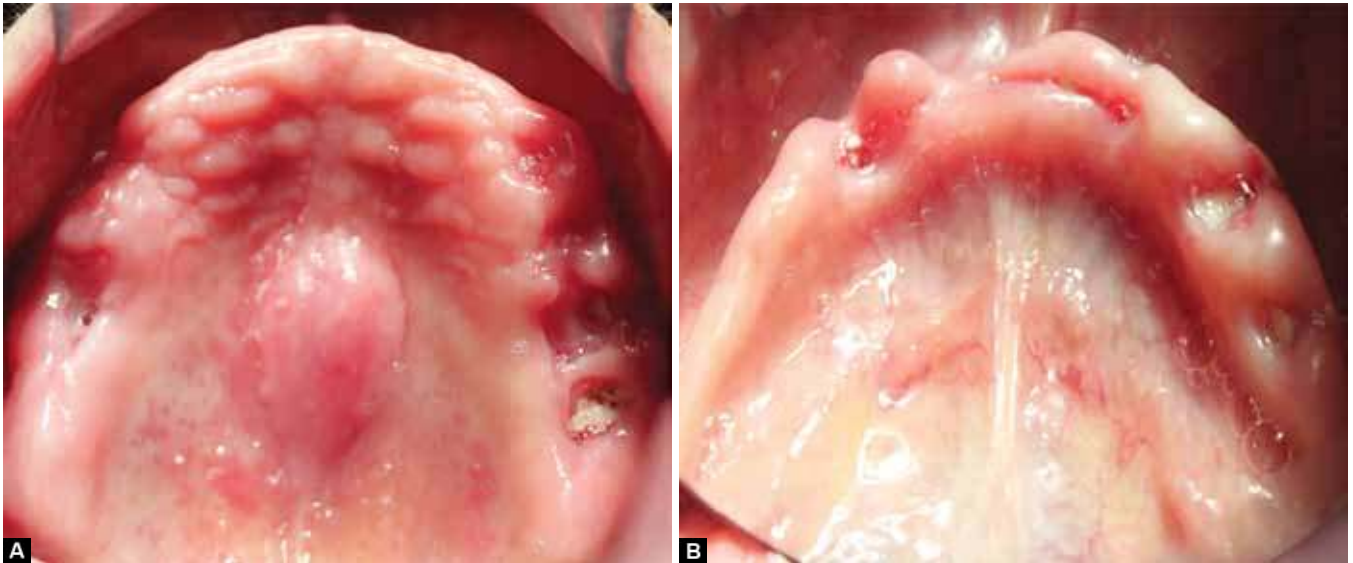
For Bagan et al,⁷ the main factor for the development of osteonecrosis of the jaw is invasive dental procedures, especially dental extractions, as reported in this clinical

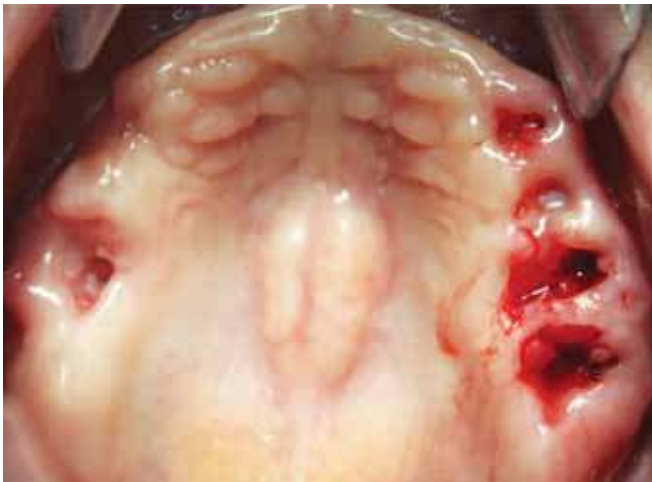
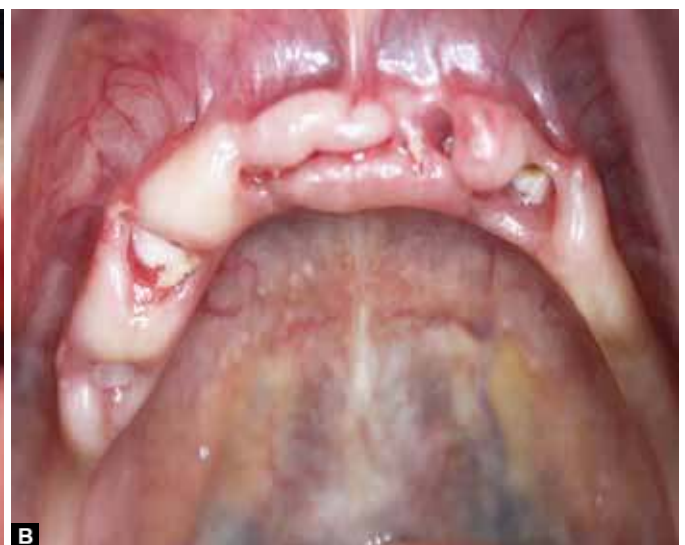
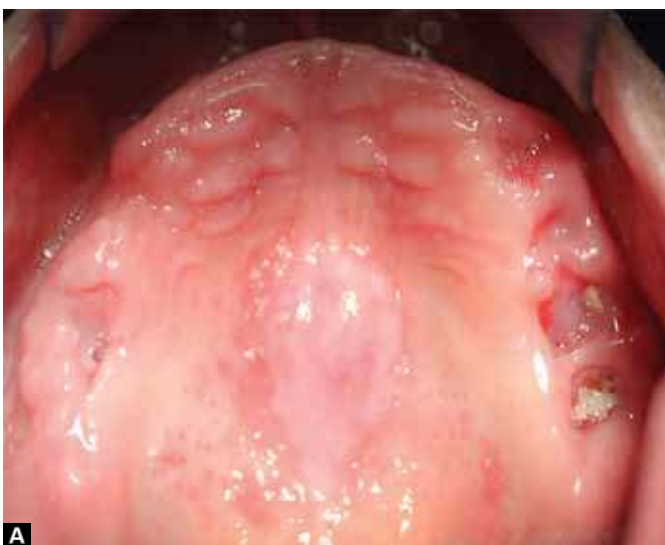Fig. 4: Final aspect of bone sequestrectomy. Removal of bone tissue with mobility, obtaining bleeding margins



Figs 5A and B: Clinical aspect after 15 days: (A and B) Improvement of the initial aspect of the lesion and presence of areas with exposed bone margins



Figs 6A and B: Clinical aspect after 21 days: (A and B) Satisfactory improvement of lesion, partial closure of dental sockets and absence of mobile bone spicule

case. For Ruggiero et al²⁴ and Narongroeknawin et al,¹⁷ in addition to the cases of induced development, there are reports of spontaneous necrosis in areas that have not undergone any prior surgical management and the cause is related to the action of the drug on the bone tissue causing the induction of apoptosis in keratinocytes and antigenic effect of the drug. For Greenberg,² the anatomical changes that affect these bones and quality of the jaw bone may also be an important risk factor for the development of this clinical entity due to the constant presence of microdamage in this region.

Another important factor for the development of osteonecrosis of the jaw is the mode of administration and exposure time to the medication. For Fehm et al,¹⁹ intravenous BPs are the main cause of these changes due to its high potency ranging from 100× to 10,000×, greater resistance to enzymatic degradation and solubility in water, unlike the oral BPs that have a relative potency of 1000× and are easily degraded in the gastrointestinal tissues. According to Bagan et al,⁷ the mean time for the development of this pathology is 29.9 months. Researchers, such as Shah et al¹² and Marx et al¹⁴ stated that it might develop between 30 and 34 months.

In the cases reported by Ruggiero et al,²² treatment recommended for osteonecrosis of the jaw was more invasive, such as curettage of the affected area, bone sequestrectomy and resection. American Association of Oral and Maxillofacial Surgeons⁸ developed a protocol for patients with this lesion according to their clinical stage and recommends conservative procedures, including antibiotics, prescription of analgesics because pain is the most severe symptom, and use of 0.12% chlorhexidine digluconate as an adjuvant to control the progression of the lesion and secondary infections. This

procedure was the same used in the present clinical case and considerable improvements of the signs and symptoms of the pathological change were observed.

The patients classified in stage II and III of the lesion, the hyperbaric oxygen therapy is more effective than the one recommended by AAOMS⁸ because oxygen saturation contributes to the hypervascularization of the area, thus improving repair of the tissue affected. However, according to the authors¹, this type of treatment is not frequently required because of its high cost.

Migliorati et al¹³ found that patients using BP for more than 3 years and who must undergo invasive dental procedures should discontinue use of the medication 3 months before the procedure and resume it only 3 months after the procedure, when the surgical wound is completely healed. But, the physician responsible for the BP-based therapy must be aware that the dentist will perform the procedure and that the patient will interrupt treatment.

In studies of Dannemann et al,³ dental treatment prior to the therapy with BPs is the best way to prevent this type of lesion, as well as guidance on oral hygiene and a careful clinical follow-up, procedures that lead to a better quality of life for these patients that help to prevent the development of osteonecrosis of the jaw.

CONCLUSION

The studies reviewed show that osteonecrosis of the jaw is an adverse effect of the therapy with bisphosphonates. The present clinical case, followed by reports in the literature, show that the most effective way to treat class III patients is the conservative approach to limit the clinical manifestations, followed by prevention to suppress the emergence of such lesion.

REFERENCES

1. McLeod NM, Brennan PA, Ruggiero SL. Bisphosphonate osteonecrosis of the jaw: a historical and contemporary review. *Surgeon* 2012 Feb;10(1):36-42.
2. Greenberg MS. Intravenous bisphosphonates and osteonecrosis. *Oral Surg Oral Med Oral Pathol Oral Radiol Endod* 2004;98:259-260.
3. Dannemann C, Gratz KW, Riener MO, Zwahlen RA. Jaw osteonecrosis related to bisphosphonate therapy a severe secondary disorder. *Bone* 2007;40:828-834.
4. Ruggiero SL, Merotra B, Rosenberg TJ. Osteonecrosis of the jaws associated with the use of bisphosphonates: a review of 63 cases. *J Maxillofac Surg* 2004;62:527-534.
5. Vescovi P, Merigo E, Meleti M, Manfredi M, Guidotti R, Nammour S. Bisphosphonates-related osteonecrosis of the jaws: a concise review of the literature and a report of a single-centre experience with 151 patients. *J Oral Pathol Med* 2012 Mar;41(3):214-221.
6. Marx RE. Pamidronate (Aredia) and zoledronate (Zometa) induced avascular necrosis of jaws: a growing epidemic. *J Oral Maxillofac Surg* 2003;61:1115-1117.
7. Bagan J, Scully C, Sabater V, Jimenez Y. Osteonecrosis of the jaws in patients treated with intravenous bisphosphonates (BRONJ): a concise update. *Oral Oncol* 2009;45:551-554.
8. American Association of Oral and Maxillofacial Surgeons. Position paper on bisphosphonate: related osteonecrosis of the jaws. *J Oral Maxillofac Surg* 2007;65(3):369-374.
9. Rogers MJ, Gordon S, Benford HL, Coxon FP, Luckman SP, Monkkonen J, et al. Cellular and molecular mechanisms of action of bisphosphonates. *Cancer* 2000;88(12):2961-2978.
10. Goytian RN, Salama A, Khanuja HS. Bisphosphonates and osteonecrosis: potential treatment or serious complication. *Orthop Clin N AM* 2009;223-224.
11. Ata-Ali F, et al. Osteonecrosis of the jaws in patients treated with bisphosphonates. *J Clin Exp Dent* 2012;4(1):e60-65.
12. Shah SA, Aslam A, Mirza AI, Ali S. Bisphosphonate related osteonecrosis of the jaws. *J Ayub Med Coll Abbottabad* 2010; 22(3):214-217.
13. Migliorati CA, Casiglia J, Epstein J, Jacobsen PL, Siegel MA, Woo SB. Managing the care of patients with bisphosphonate-associated osteonecrosis: an American Academy of Oral Medicine position paper. *J Am Dent Assoc* 2006;137(1):26.
14. Marx RE, Cillo JE Jr, Ulloa JJ. Oral bisphosphonate-induced osteonecrosis: risk factors, prediction of risk using serum CTX testing, prevention, and treatment. *J Oral Maxillofac Surg* 2007;65(12):2397-2410.
15. Lipton A, Small E, Saad F, Gleason D, Gordon D, Smith M, Rosen L, Kowalski MO, Reitsma D, Seaman J. The new bisphosphonate, Zometa (zoledronic acid), decreases skeletal complications in both osteolytic and osteoblastic lesions: a comparison to pamidronate. *Cancer Invest* 2002;20(Suppl 2):45-54.
16. Crépin S, Laroche ML, Sarry B, Merle L. Osteonecrosis of the jaw induced by clodronate, an alkylbiphosphonate: case report and literature review. *Eur J Clin Pharmacol* 2010 Jun;66(6):547-554.
17. Narongroeknawin P, Danila MI, Humphreys LG Jr, Barasch A, Curtis JR. Bisphosphonate-associated osteonecrosis of the jaw, with healing after teriparatide: a review of the literature and a case report. *Spec Care Dentist* 2010;30(2):77-82.
18. Chacon GE, Stine EA, Larsen PE, Beck FM, McGlumphy EA. Effect of alendronate on endosseous implant integration: a in vivo study. *J Oral Maxillofac Surg* 2006;64:1005-1009.
19. Fehm T, Felsenberg D, Krimmel M, Solomayer E, Wallwiener D, Hadji P. Bisphosphonate-associated osteonecrosis of the jaw in breast cancer patients: recommendations for prevention and treatment. *Breast* 2009 Aug;18(4):213-217.
20. Borelli A, Leite MOR, Corrêa PHS. Paratireóides e doenças ósseas metabólicas. In Wajchenberg BL. *Tratado de endocrinologia clínica*. São Paulo: Roca; 1992. p. 845-907.
21. Almazrooa SA, Woo SB. Bisphosphonate and nonbisphosphonate-associated osteonecrosis of the jaw: a review. *J Am Dent Assoc* 2009 Jul;140(7):864-875.
22. Ruggiero SL, Mehrotra B. Bisphosphonate—related osteonecrosis of the jaw: diagnosis, prevention, and management. *Annu Rev Med* 2009;60:85-96.
23. Marx RE, Sawatari Y, Fortin M, Broumand V. Bisphosphonate—induced exposed bone (osteonecrosis/osteopetrosis) of the jaws: risk factors, recognition, prevention, and treatment. *J Maxillofac Surg* 2005;63(11):1567-1575.
24. Ruggiero SL, Dodson TB, Assael LA, Candesberg R, Marx RE, Mehrotra B. American Association of Oral and Maxillofacial Surgeons position paper on bisphosphonate: related osteonecrosis of the jaws 2009 update. *J Oral Maxillofac Surg* 2009;67(5):2-12.
25. Mc Carthy JG, Schreiber J, Karp N, Thorne CH, Grayson BH. Lengthening the human mandible by gradual distraction. *Plast Reconstr Surg* 1992;89(1):1-8.
26. Narai S. Effects of alendronate on the removal torque of implants in rats with induced osteoporosis. *J Oral Maxillofac Implants* 2003;18:218-223.
27. Sarasquete ME, Gonzalez M, San Miguel JF, Garcia-Sanz R. Bisphosphonate-related osteonecrosis: genetic and acquired risk factors. *Oral Dis* 2009;15:382-387.

