

Otic Lesions and Congenital Hypothyroidism in the Developing Chick *

GERALD J. BARGMAN AND LYTT I. GARDNER

(From the Genetic and Endocrine Unit, Department of Pediatrics, State University of New York Upstate Medical Center, Syracuse, New York)

Abstract. In an effort to elucidate the relation, if any, between thyroid abnormality and congenital deafness in Pendred's syndrome, an experiment was designed to study the effects of hypothyroidism on middle and inner ear hearing structures, including the auditory nerve and its central projection, in developing chick embryos. Propylthiouracil (PTU), 2 mg, was injected into the albumin of fertile chick eggs on the 10th incubation day. Single doses of L-thyroxine (range 1–100 μ g) were inoculated in a similar manner, either alone or with PTU. Control inocula included sterile saline or water. After hatching, each chick was examined for obvious malformations. The thyroid glands, middle and inner ear mechanisms, auditory nerve, and brainstem were studied grossly and with different histologic staining techniques. When compared to controls, chicks exposed to PTU on their 10th incubation day exhibited: increased mortality, delayed hatching, reduced size, incomplete yolk sac absorption, and death within 5 days unless exogenous thyroid hormone was provided in the first 24–48 hr after hatching. Specific, consistent, morphologic alterations were observed in their thyroid glands as well as in the sensory hair cells of the acoustic papilla and cells of the spiral ganglion of the cochlea. Our data also indicate that if 50–75 μ g of L-thyroxine is given simultaneously with (or as long as 120 hr after) the PTU injection on the 10th incubation day, one cannot detect the gross defects, marked thyroid lesions, or abnormal histology in cells of the cochlea and its ganglion. A relationship between embryonic thyroid gland function and the hearing mechanism of the chick embryo is suggested.

Introduction

Trotter (1) has pointed out that three forms of thyroid disease have been repeatedly observed

* Received for publication 26 May 1967 and in revised form 10 July 1967.

A preliminary report appeared in *Lancet*. 11: 1249, 3 December 1966.

Presented at the 37th annual meeting of the Society for Pediatric Research in Atlantic City, N. J., on 28–29 April 1967.

This study was supported by grants T1-AM-5277 and AM-02504, National Institutes of Arthritis and Metabolic Diseases, National Institutes of Health, U. S. Public Health Service.

Address requests for reprints to Dr. Lytt I. Gardner, State University of New York Upstate Medical Center, 750 E. Adams Street, Syracuse, N. Y. 13210.

in association with hearing deficits: myxedema in the adult (2); endemic cretinism (3, 4); and Pendred's syndrome (5, 6). The hearing loss in adult myxedema may be perceptive, conductive, or both, but it is usually not severe and can be improved with exogenous thyroid hormone replacement. Factors implicated in this form of deafness include a general reduction in brain activity as well as myxedema of the tympanic membrane and mucosa of the middle ear (2). The deafness associated with endemic cretinism, as described in the classic work of deQuervain and Wegelin (3), may involve the inner ear but the principal lesions are myxedematous changes in the middle ear with subsequent distortions of the round and oval windows. Increased size, de-

fective shape, and malalignment of the ossicles may also be observed. The nature of the auditory pathology in Pendred's syndrome remains to be defined. We report here the results of an experiment designed to study the effects of hypothyroidism on middle and inner ear hearing structures (including the auditory nerve and its central projection) in developing chick embryos.

Methods

Following techniques reported by Romanoff and Laufer (7), we injected 2 mg of propylthiouracil (PTU) into the albumin of fertile chick eggs on the 10th incubation day. A single dose of L-thyroxine was also inoculated in the same manner, either simultaneously with PTU on the 10th incubation day or on each subsequent day up to and including the 17th incubation day. The concentration of L-thyroxine administered to an individual egg on any given day was varied in increments of 5 μ g from 1 to 100 μ g (Table I). Control inocula included 1 ml of saline into one egg each day from the 10th to the 17th incubation day, 1 ml of sterile water (one egg each day from the 10th to 17th incubation day), and 5 μ g of L-thyroxine (two eggs each day from the 10th to 17th incubation day). All embryos were incubated at

TABLE I
Total number of eggs inoculated with various doses of L-thyroxine

Intraalbumin dose of L-thyroxine	Total number of eggs
μ g	
1	16
5	16
10	16
15	16
20	16
25	16
30	16
35	16
40	16
45	24
50	24
55	24
60	24
65	24
70	24
75	24
80	16
85	16
90	16
95	16
100	16

All eggs indicated above also received 2 mg of intra-albumin PTU on their 10th incubation day. A single dose of L-thyroxine was administered on the 10th incubation day or on each subsequent day up to and including the 17th incubation day.

TABLE II
Effects of various doses of inocula on survival hatch time, weight, and crown to rump length of newly hatched chicks

Inoculum	Incubation day of injection	Dose	Total No. of eggs	Total Survivors	Per cent survival	Mean hatch time of survivors	Mean weight of survivors	Mean crown to rump length of survivors
						days	g	cm
Sterile water	10th-17th	1 ml	8	6	75.0	21.6	41.1	9.8
Sterile saline	10th-17th	1 ml	8	7	87.5	21.5	41.4	9.9
Propylthiouracil (PTU)	10th	2 mg	41	17	41.5	26.5	27.8	7.8
L-Thyroxine	10th-17th	5 μ g	16	0	0	0	0	0
PTU	10th	2 mg	49	17	34.7	24.5	37.7	9.6
L-Thyroxine	10th	1-100 μ g						
PTU	10th	2 mg	49	10	20.4	24.5	37.6	9.4
L-Thyroxine*	11th	1-100 μ g						
PTU	10th	2 mg	49	12	25.5	24.9	37.4	9.2
L-Thyroxine*	12th	1-100 μ g						
PTU	10th	2 mg	49	10	20.4	25.8	37.1	9.4
L-Thyroxine*	13th	1-100 μ g						
PTU	10th	2 mg	49	8	16.3	25.0	38.2	9.2
L-Thyroxine*	14th	1-100 μ g						
PTU	10th	2 mg	49	9	19.3	25.2	37.1	9.2
L-Thyroxine*	15th	1-100 μ g						
PTU	10th	2 mg	49	7	14.2	25.7	36.3	8.8
L-Thyroxine*	16th	1-100 μ g						
PTU	10th	2 mg	49	6	12.2	26.1	35.7	8.9
L-Thyroxine*	17th	1-100 μ g						

* L-Thyroxine administered in divided doses of 5 μ g from 1 to 100 μ g (i.e., 1, 5, 10, 15, etc. . . μ g).




FIG. 1. THE BIRD ON THE LEFT WAS FIXED IMMEDIATELY AFTER HATCHING, AND ILLUSTRATES THE REDUCED SIZE AND UMBILICAL HERNIA (INCOMPLETE ABSORPTION OF THE YOLK SAC) CONSISTENTLY FOUND IN CHICKS EXPOSED TO PROPYLTHIOURACIL ON THE 10TH INCUBATION DAY. The middle chick received 65 μ g of L-thyroxine simultaneously with 2 mg of PTU. It exhibits no obvious gross anomalies when compared to a saline treated specimen (right).

99.5°F (37.7°C) with the humidity maintained at 60–65%. Each egg was turned frequently and candled twice per day. Dead embryos were discarded, whereas the survivors were allowed to continue incubation until hatch time. After hatching, specimens were studied for obvious gross defects. The thyroid glands and middle and inner ear hearing mechanisms, as well as the auditory nerve and brainstem, were then dissected and studied microscopically using hematoxylin and eosin stain (8) or silver impregnation (9). The latter technique was that of Cajal and DeCastro as described by Levi-Montalcini (9). No decalcification methods were employed.

Results

Table II summarizes data concerning the effects of various doses of inoculated material on hatch time and survival time of the chicks. It can be seen that the embryos injected with PTU, compared to control embryos, had a higher mortality rate and required a longer incubation period before hatching occurred. Gross observation of newly hatched chicks who had been injected with sterile water or sterile saline showed no remarkable physical differences when compared to uninjected speci-

mens. However, chicks who survived exposure to PTU as embryos exhibited the following consistent physical changes when compared to the control specimens: shorter crown-rump length, reduced wet weight, and omphacoele with incomplete resorption of the yolk sac (Fig. 1). Death occurred within 5 days unless exogenous thyroid hormone therapy was initiated 24–48 hr after hatching. The thyroid glands of these chicks were found to be markedly enlarged with prominent vascularization. Histologically, these thyroid glands revealed acinar cell hypertrophy and, unlike the findings of Ritter and Lawrence (10), distinct colloid vesicles were not detectable (Figs. 2 and 3). Our microscope findings are consistent with chemically induced hypothyroidism in the chick as described by Mitskevitch (11). Histological examination of the middle and inner ears from PTU-treated chick embryos revealed alterations in the sensory hair cells of the acoustic papilla (Figs. 4 and 5). The cytoplasm of these cells was composed mainly of a semiopaque, glossy,

weakly acidophilic material with a loss or obliteration of intracellular granularity. The nuclei of these cells were found to be relatively small and more centrally located within the individual cells. Chicks showing these cochlear changes also exhibited histologic alterations in the spiral ganglion of the cochlea. The bipolar nerve cells of the ganglion were smaller and relatively widely separated by the accumulation of an intercellular substance resembling, on silver impregnation, the material composing the abnormal cytoplasm of the affected sensory hair cells. Nuclear boundaries and chromatin material within these nerve cells were difficult to identify (Figs. 6 and 7). No consistent histological abnormalities in the axons of the cochlear nerve and their associated nuclear centers in the medulla oblongata were found in hypothyroid specimens. Except for evidence of delayed calcification, no pathological changes were

found in the structures (columella) of the middle ear. The type of morphologic abnormality of the chick organ of Corti described by Ritter and Lawrence (10) was not found.

Our data also indicate that if 50–75 μg of L-thyroxine is given simultaneously with, or as long as 120 hr after, the PTU injection on the 10th incubation day, the mortality rate is increased, but survivors generally hatched earlier than with PTU alone (Table II). The characteristic thyroid lesions and abnormal histological findings of the acoustic sensory hair cells in the cochlea and nerve cells in its ganglion were not detected when L-thyroxine was given with PTU as described above (Figs. 8–10). Six chickens who survived exposure to PTU as embryos and subsequently were started on L-thyroxine during the first 24–48 hr after hatching did not exhibit reversal of the lesions in the acoustic papilla or spiral ganglion

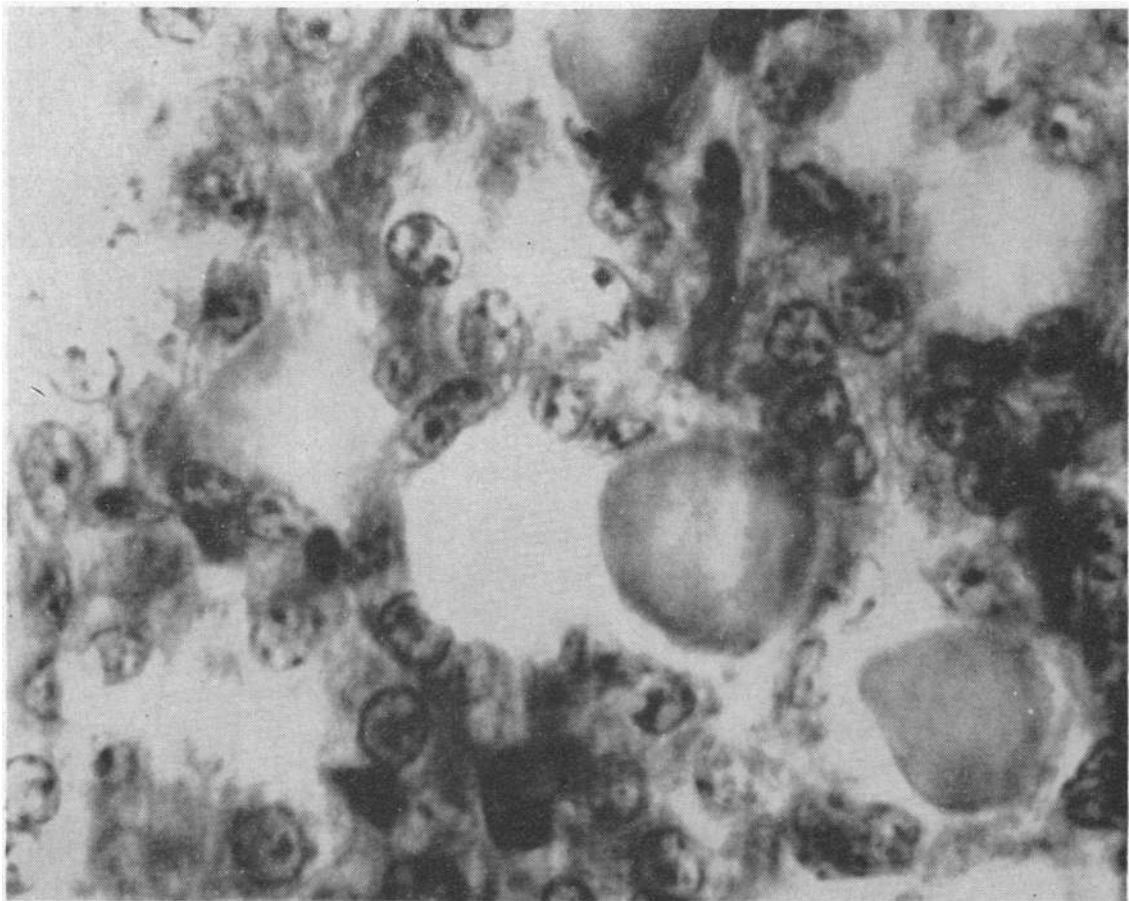


FIG. 2. A 10 μ SECTION OF A CONTROL THYROID GLAND. Note the distinct acinar cell-lined follicles containing colloid. Hematoxylin and eosin, $\times 1000$.

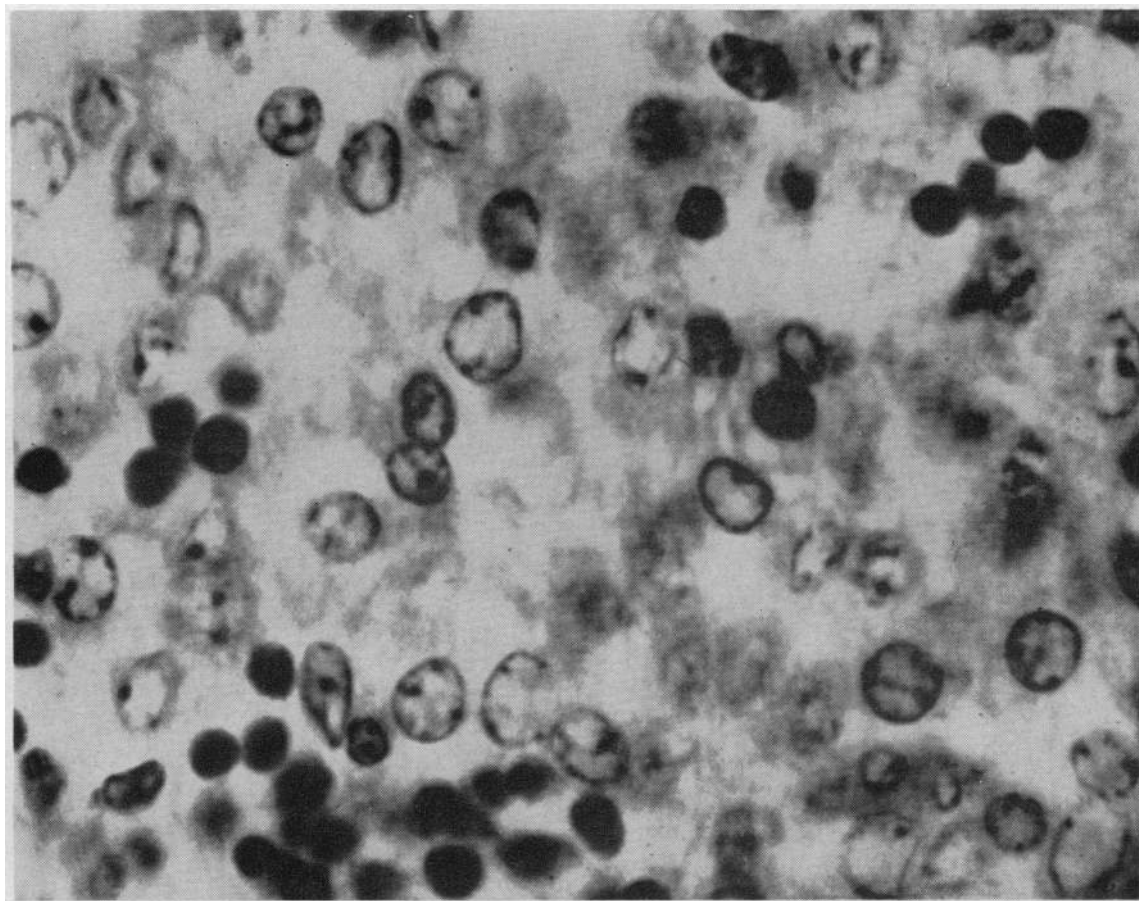


FIG. 3. THIS 10 μ SECTION IS REPRESENTATIVE OF AN ENTIRE THYROID GLAND FROM A PTU-TREATED SPECIMEN. Well-circumscribed, acinar-lined follicles and colloid are not distinguishable. The scattered, darkly stained cells are erythrocytes, demonstrating increased vascularity of the gland. Hematoxylin and eosin, $\times 1000$.

when studied at the end of 8–14 days. Their thyromegaly, however, regressed considerably. In accordance with the work of Stoll and coworkers (12), we found that L-thyroxine appears to be a very toxic agent, at least when inoculated by itself into the albumin of 10–17 day developing chick embryos.

Discussion

To achieve a more comprehensive understanding of our experimental data, a brief review of the embryology of the avian thyroid, cochlea, and central nervous system tissues related to the cochlea seems in order.

On the 2nd incubation day the thyroid glands of the chick embryo begin as a single midline ventral outpouching from the primordial pharyngeal wall, at the level of the first and second

branchial pouches. This outgrowth subsequently differentiates into two separate structures, each migrating laterally to its eventual position at the base of the neck (13). These paired but unattached embryonic glands begin to elaborate thyroxine after approximately 9.75 days of incubation (14). Histologically the chick thyroid resembles the thyroid gland of man (13, 15).

The chicken cochlea is derived from a ventral outgrowth of the otocyst starting at about 6 days of incubation. Growth and differentiation of this structure continue until about 11.75 incubation days when its degree of anatomical maturation is essentially the same as that of the adult. Neuroepithelium confined to the ventral otocyst grows and subdivides into all the necessary sensory tissue including the auditory nerve and its branches. The development of this nervous tissue is con-

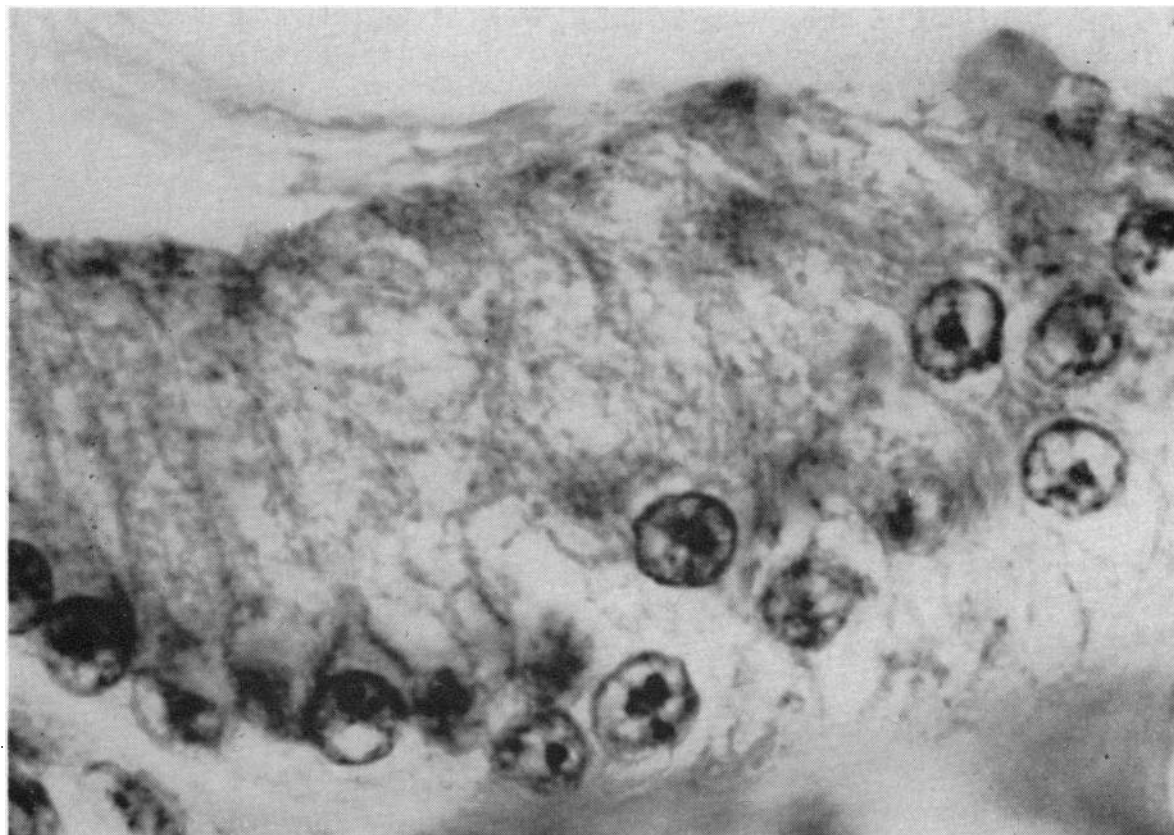


FIG. 4. SENSORY HAIR CELLS FROM THE AREA OF THE ACOUSTIC PAPILLA OF CONTROL CHICKS SHOW DISTINCT NUCLEI AT THEIR BASE AND INTRACELLULAR MATERIAL. Hematoxylin and eosin, $\times 1470$.

comitant with differentiation of the structure derived from the otocyst (16). The chicken cochlea differs morphologically from that of man in several respects. It is a membranous, slightly concave, finger-like tube 5 mm long, within a similarly shaped bony shell. This membranous tube contains a central channel (scala media) that ends blindly in a region called the maculae lagenae. Endolymph from the membranous labyrinth fills the entire scala media while above and below it are perilymph-containing cavities known as the scala vestibuli and scala tympani, respectively. The floor of the scala media is referred to as the basilar membrane while its roof is known as the tegmental membrane or tegmentum vasculosum. Covering the basilar membrane are columnar cells that differentiate into sensory neuroepithelium (sensory hair cells). The sensory hair cells in the area of the maculae lagenae (papillae lagenae) are provided with otoconia and presumably assume the function of a vestibular sense organ.

Lining the basilar membrane between the papillae lagenae and the canal connecting the saccule and cochlea (ductus reuniens) are the sensory hair cells that form the acoustic papilla or papilla basilaris. Lying above, and in close apposition to the cells of the acoustic papilla, is a group of transverse fibers (tectorial membrane) supported at one end by the basilar membrane and its columnar cells. The other end of these fibers is anchored to a small cartilaginous shelf jutting into the scala media. Afferent and efferent fibers from the spiral ganglion of the cochlea penetrate this cartilaginous shelf and ramify among the sensory hair cells (acoustic papilla) just beneath it. The combination of basilar membrane, accessory supporting cells, sensory hair cells, tectorial membrane, and associated nerve fibers is collectively referred to as the organ of Corti. The spiral ganglion of the cochlea, containing bipolar nerve cells, lies just medial to the bony cochlea. Afferent fibers from this ganglion pass through the cochlear branch of

the auditory nerve into the main trunk and then into the specific nuclei within the medulla oblongata. These medullary centers include the ventral cochlear nucleus, nucleus lamnaris, nucleus angularis, and nucleus magnocellularis. In our study auditory nerve tracts were not traced beyond these nuclei.

As alluded to previously, our findings are different from those of Ritter and Lawrence (10). They observed that injection of 2 mg of propylthiouracil into the albumin of 4-9-day old chick embryos produced lesions in the organ of Corti characterized by "toothlike sensory hair cells" separated from supporting tissues by edema. Propylthiouracil inoculation after 9 days presumably had no effect on the cochlea. Morphologic alterations of the spiral ganglion were not mentioned and subsequent thyroid hormone therapy apparently was not attempted.

deVos (17), producing a form of acquired hypothyroidism in mice, rats, and hamsters, found that a daily oral dose of propylthiouracil (0.1% solution), started shortly after birth and maintained for an appropriate period thereafter (6-21 wk), resulted in a "slight degeneration of the spiral ganglion." This degeneration, however, was not consistently observed. He did not demonstrate whether the pathological changes in the spiral ganglion were reversible with exogenous thyroid hormone replacement. The spiral ganglion was not reexamined after stopping the propylthiouracil regime.

Hollander and his associates (18) have described a 28 yr old female with total deafness, presumed to be of congenital origin, and goiter secondary to an apparent inability to synthesize adequate quantities of iodothyronines. Action potentials from the cochlea and eighth cranial nerve could

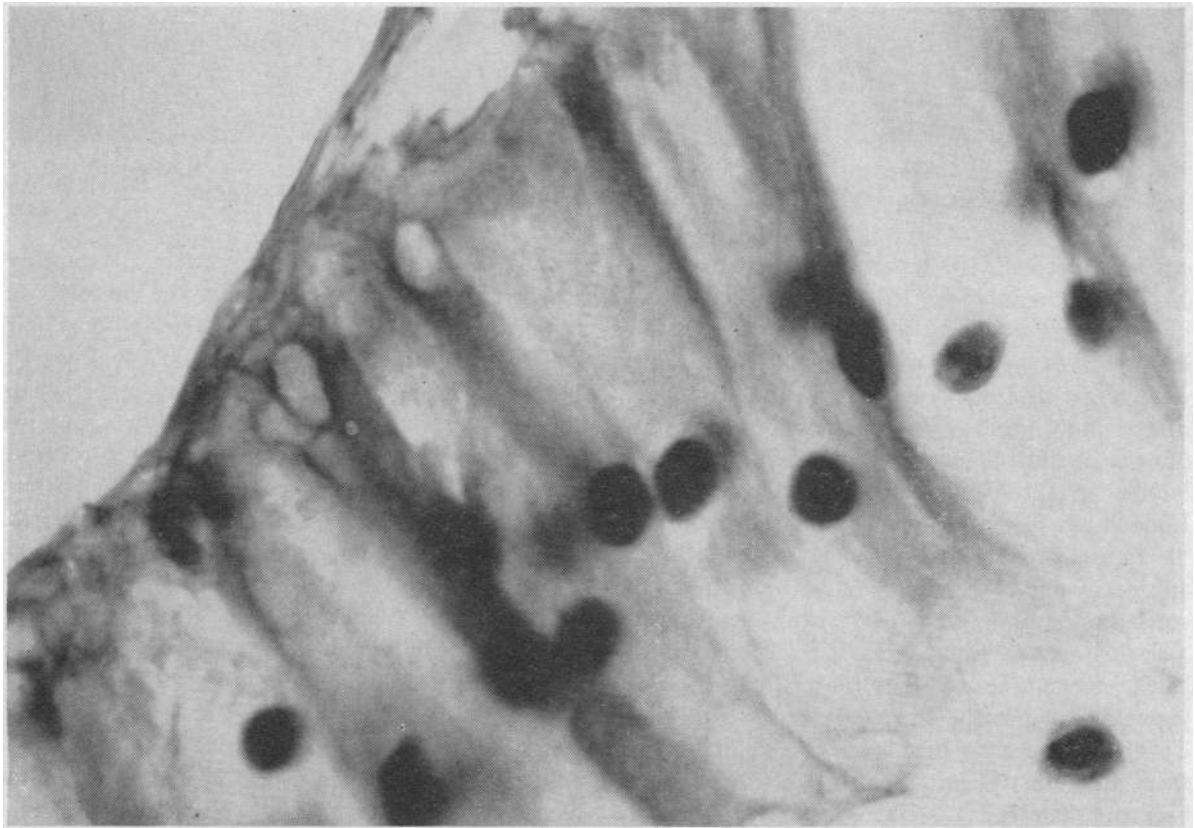


FIG. 5. SENSORY HAIR CELLS FROM THE ACOUSTIC PAPILLA OF A NEWLY HATCHED CHICK INOCULATED WITH PTU ON THE 10TH INCUBATION DAY EXHIBIT SMALL, CENTRALLY PLACED NUCLEI AND OBLITERATION OF INTRACELLULAR MATERIAL. Hematoxylin and eosin, $\times 1470$.

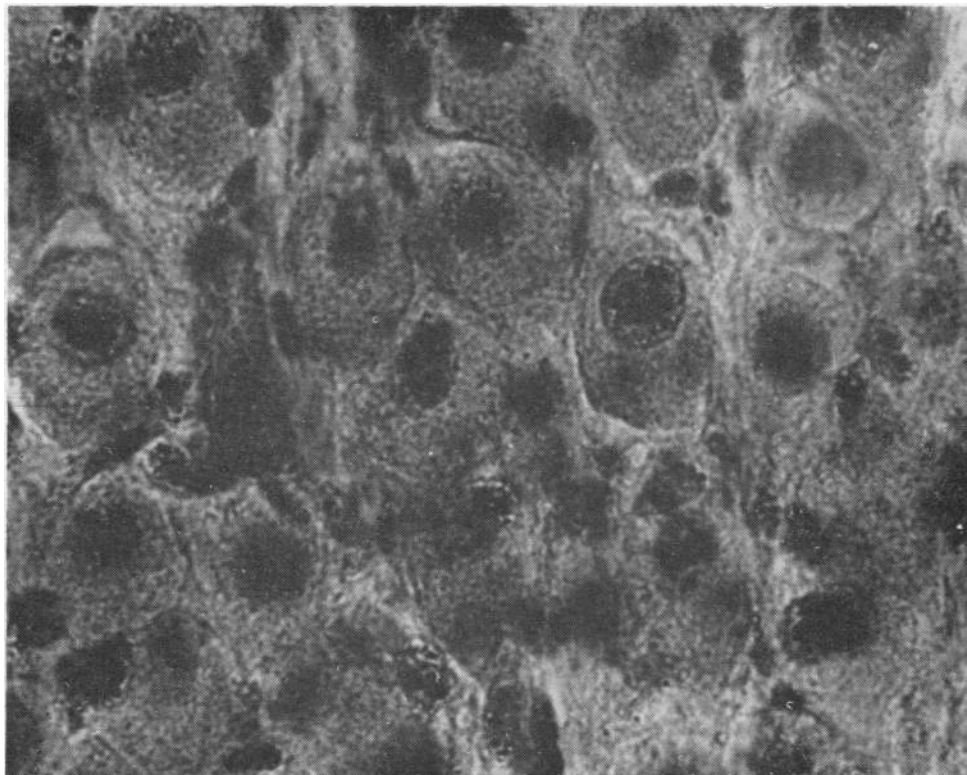


FIG. 6. CELLS FROM THE SPIRAL GANGLION OF THE COCHLEA OF SALINE-TREATED SPECIMEN. Distinct nuclei and rather coarse dark-staining cytoplasmic granules are present. Note how closely "packed" the individual cells are. Silver impregnation, $\times 1000$.

not be evoked upon direct stimulation. Although unable to relate the thyroid disease and deafness, the authors suggest that this patient's hearing loss might be a result of "disease of the Organ of Corti, probably related to a lack of hair cells."

An early written description of the association between goiter, deafness, and environment can be found in the mid-18th century notations of the Jesuit missionary Cosme Bueno (cited in reference 19). He observed "tumors on the throat called cotos," and hearing deficits in the inhabitants of several villages in the Peruvian Andes. Within the framework of our present knowledge the goiters in people of this area were very likely secondary to a deficient iodine intake and the deafness due to subsequent myxedema of the auditory mechanism (20). In 1824, Wood (21) noted the clinical combination of deaf-mutism and goiter. 72 yr later, Vaughan Pendred (5) published his observation of two deaf-mute sisters, both of whom had goiter. Since that time the clinical

findings of congenital deafness and sporadic goiter have been generally defined as Pendred's syndrome (6). This disease is now thought to be transmitted in an autosomal recessive mode. The frequency of the abnormal gene, its mutation rate, and its over-all incidence in the population of the British Isles have been estimated by Fraser (22) to be 0.008, 56 million loci per generation, and 0.000075, respectively.

Available biochemical data suggest that the existence of a specific thyroid lesion in Pendred's syndrome is related to an incomplete enzymatic defect with subsequent inability of the gland to incorporate sufficient quantities of iodide into organic hormone precursors (23-25). The defective enzyme system responsible for this organification block is presumably genetically determined (26), variable in severity, and simulated in the normal human subject with the administration of thiouracil derivatives (1). The deafness in Pendred's syndrome has been found to be of the

perceptive type with a greater hearing loss for high tones (22). As already mentioned, the pathophysiology of this hearing loss is not known.

The relationship, if any, of the auditory and thyroid defects in Pendred's syndrome remains uncertain. Brain, in 1927, first concluded that the expression of a single genetic error produced both the metabolic block in the thyroid and the hearing deficit (27). Later, Wilkins, summarizing the findings of other workers, stated, "The deafness [in Pendred's syndrome] was not due to hypothyroidism, as in many cases the goiters were not accompanied by thyroid deficiency and deafness was not improved by thyroid therapy" (28).

Interpretation of the data derived from our experimental model suggests that production of anatomic lesions of the cochlea and cochlear ganglion, in embryonic chicks exposed to PTU, is related to chemical production of a metabolic error of the thyroid and subsequent hypothyroidism.

The fact that these morphologic otic abnormalities could be prevented or possibly reversed with the appropriate dose and temporal scheduling of thyroxine therapy serves to strengthen this concept. If the cochlear mechanism were directly affected by propylthiouracil, one would not expect thyroxine to have any protective or preventive effect.

The observed lack of improvement of the deafness in treated patients with Pendred's syndrome may be a manifestation of the fact that the therapy is instituted too late. The present study suggests that if the auditory defects are to be "improved" it might be necessary, in some manner, to supply the affected fetus or embryo with adequate thyroxine early in the course of cochlear organogenesis. Thyroid therapy started after this period of time would presumably be of no value as far as prevention or correction of anatomic cochlear pathology is concerned.

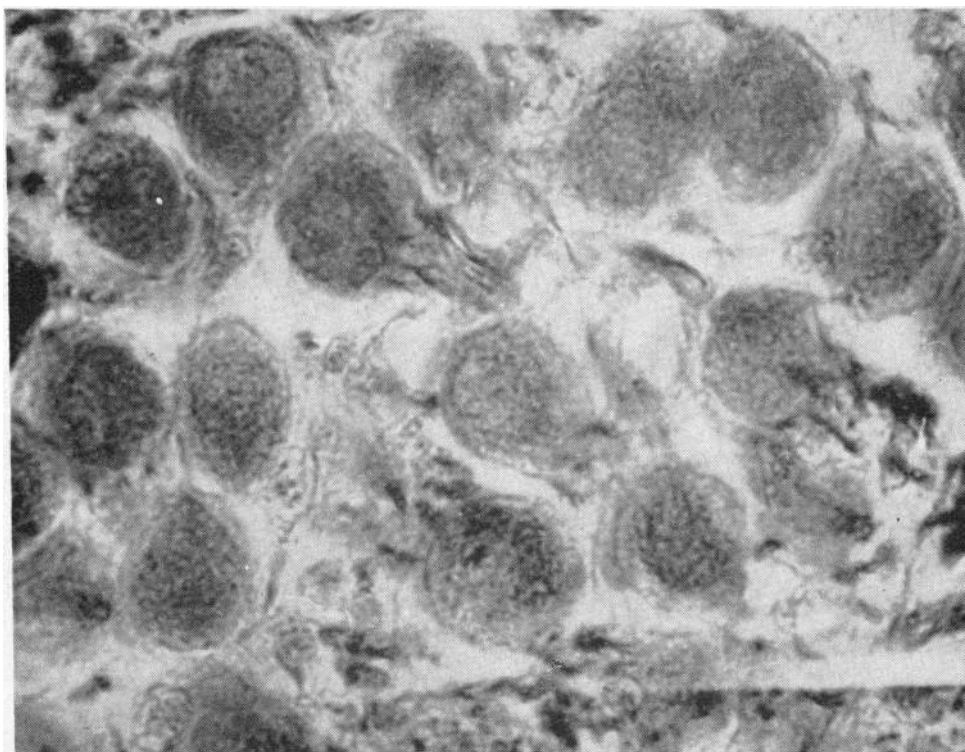


FIG. 7. THE SPIRAL GANGLION OF THE COCHLEA FROM CHICKS EXPOSED TO PTU AS EMBRYOS REVEALS CELLS LACKING DISTINCT NUCLEI AND DARK-STAINING CYTOPLASMIC GRANULARITY. The intercellular space is very obvious and contains a homogenous opaque material. Silver impregnation, $\times 1000$.

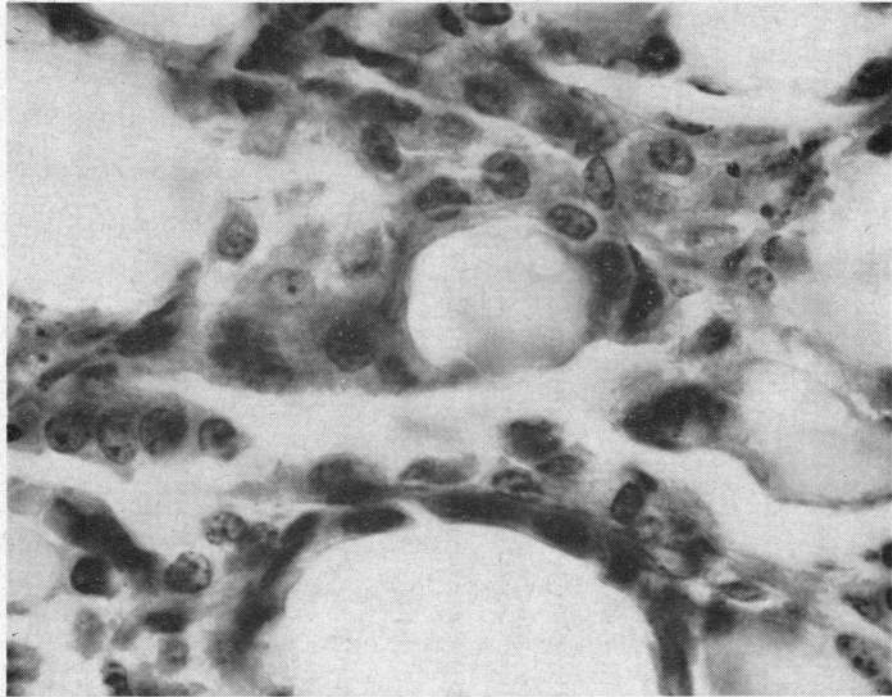


FIG. 8. DISTINCT ACINAR-LINED FOLLICLES CONTAINING COLLOID CAN BE SEEN IN THIS 10 μ SECTION OF THYROID OBTAINED FROM A CHICK WHO RECEIVED PTU (2 MG) AND L-THYROXINE (55 μ G ON THE 12TH INCUBATION DAY). Hematoxylin and eosin, \times 1025.

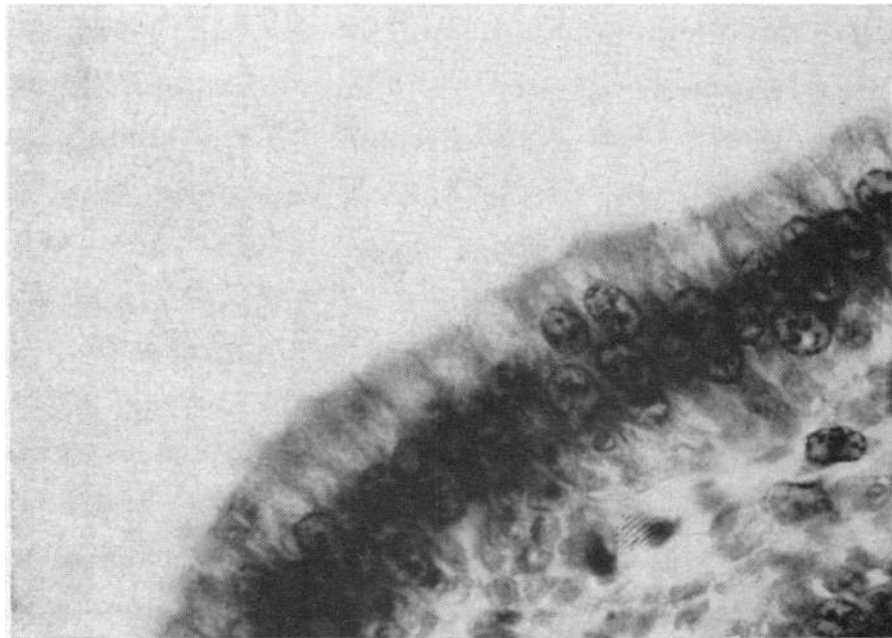


FIG. 9. SENSORY HAIR CELLS FROM THE AREA OF THE ACOUSTIC PAPILLA OF A CHICK TREATED WITH PTU (2 MG ON 10TH INCUBATION DAY) AND L-THYROXINE (60 μ G ON 12TH INCUBATION DAY). DISTINCT BASILAR NUCLEI AND CYTOPLASMIC GRANULATIONS ARE PRESENT. Note the hair-like projections from the top border of these cells. Hematoxylin and eosin, \times 1025.

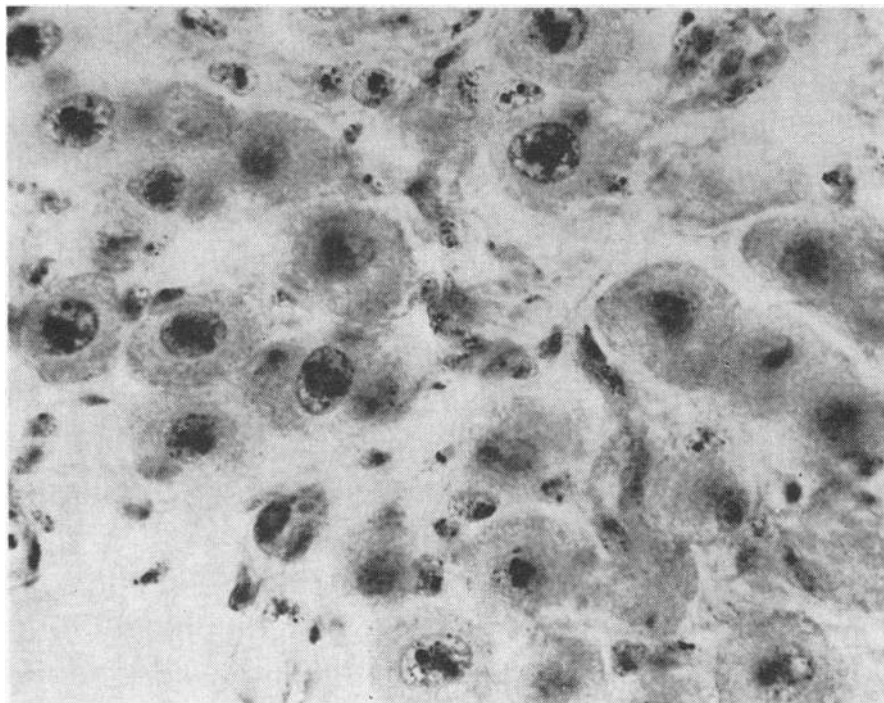


FIG. 10. CELLS IN THE SPIRAL GANGLION OF THE COCHLEA FROM A CHICK INJECTED WITH PTU (2 MG ON 10TH INCUBATION DAY) AND L-THYROXINE (60 μ G ON 12TH INCUBATION DAY) REVEAL WELL DEMARCATED NUCLEI WITH DARK-STAINING CHROMATIN MATERIAL. Dark cytoplasmic granulations are also present. The intercellular space in this photomicrograph has been exaggerated by technical artifact. Silver impregnation, $\times 1025$.

Acknowledgments

We wish to thank Mrs. Patricia Nolan and Mrs. Pamela Katz for their technical assistance.

References

1. Trotter, W. R. 1960. Deafness and thyroid dysfunction. The association of deafness with thyroid dysfunction. *Brit. Med. Bull.* 16: 92.
2. Howarth, A. E., and H. E. D. Lloyd. 1956. Perceptive deafness in hypothyroidism. *Brit. Med. J.* 1: 431.
3. deQuervain, F., and C. Wegelin. 1936. *Der Endemische Kretinismus*. Springer-Verlag, Berlin.
4. Deutsch, M. E. 1960. Endemic cretinism and deaf-mutism. *Lancet*. ii: 769.
5. Pendred, V. 1896. Deaf-mutism and goitre. *Lancet*. ii: 532.
6. Fraser, G. R., M. E. Morgans, and W. R. Trotter. 1960. The syndrome of sporadic goitre and congenital deafness. *Quart. J. Med.* 29: 279.
7. Romanoff, A. L., and H. Laufer. 1956. The effect of injected thiourea on the development of some organs of the chick embryo. *Endocrinol.* 59: 611.
8. U. S. Armed Forces Institute of Pathology. 1960. *Manual of Histologic and Special Staining Techniques*. McGraw-Hill Book Company, New York. 2nd edition. 27.
9. Levi-Montalcini, R. 1949. The development of the acoustico-vestibular centers in the chick embryo in the absence of the afferent root fibers and of descending fiber tracts. *J. Comp. Neurol.* 91: 209.
10. Ritter, F. N., and M. Lawrence. 1960. Reversible hearing loss in human hypothyroidism and correlated changes in the chick inner ear. *Trans. Am. Lar. Rhinol. Otol. Soc. Inc.* 270.
11. Mitskevitch, M. S. 1957. *Glands of Internal Secretion in the Embryonic Development of Birds and Mammals*. Moscow, 111. (Israel Program for Scientific Translations, Jerusalem.)
12. Stoll, R., H. Couland, N. Faucounau, and R. Maraud. 1966. Sur l'action tératogène des hormones thyroïdiennes chez l'embryon de poulet. Les mécanismes morphogénétiques de la strophosomie. *Arch. Anat. Microscop. Morphol. Exptl.* 55: 59.
13. Romanoff, A. L. 1960. *The Avian Embryo*. The Macmillan Company, New York. 867.
14. Trunnell, J. B., and P. Wade. 1955. Factors governing the development of the chick embryo thyroid. II. Chronology of the synthesis of iodinated compounds studied by chromatographic analysis. *J. Clin. Endocrinol. Metab.* 15: 107.

15. diFiore, M. S. H. 1963. An Atlas of Human Histology. Lea and Febiger, Philadelphia. 189.
16. Lillie, F. R. 1908. The Development of the Chick: An Introduction to Embryology. Holt, Rinehart & Winston, Inc., New York. 293.
17. deVos, J. A. 1963. Deafness in hypothyroidism. *J. Laryng.* 77: 390.
18. Hollander, C. S., T. E. Prout, M. Rienhoff, R. J. Ruben, and S. P. Asper, Jr. 1964. Congenital deafness and goiter; studies of a patient with a cochlear defect and inadequate formation of iodothyronines. *Am. J. Med.* 37: 630.
19. Lastres, J. B. 1953. Goiter in Peru. *Bull. Hist. Med.* 27: 484.
20. Salazar Noriega, Servio, T. 1952. Bocio endemico en al Peru. Lima. No publisher. As cited by I. Greenwald. 1957. The history of goiter in Inca Empire: Peru, Chile and the Argentine Republic. *Texas Rep. Biol. Med.* 15: 874.
21. Wood, K. 1824. In *Memoirs of the Literary and Philosophical Society of Manchester*. 2nd series. 9: 83. As cited by A. K. Thould and E. F. Scowen. 1964. The syndrome of congenital deafness and simple goitre. *J. Endocrinol.* 30: 69.
22. Fraser, G. R. 1965. Association of congenital deafness with goitre (Pendred's syndrome). *Ann. Hum. Genet.* 28: 201.
23. Morgans, M. E., and W. R. Trotter. 1958. Association of congenital deafness with goitre: The nature of the thyroid defect. *Lancet.* i: 607.
24. McGirr, E. M., J. H. Hutchison, and W. E. Clement. 1959. Sporadic goitre due to dysmorphogenesis: Impaired utilization of trapped iodide. *Scot. Med. J.* 4: 107.
25. Najjar, S. 1963. Pendred's syndrome in two families living in endemic goitre area. *Brit. Med. J.* 2: 31.
26. Beadle, G. W. 1945. Biochemical genetics. *Chem. Rev.* 37: 15.
27. Brain, R. W. 1927. Heredity in simple goitre. *Quart. J. Med.* 20: 303.
28. Wilkins, L. 1965. *The Diagnosis and Treatment of Endocrine Disorders in Childhood and Adolescence*. Charles C Thomas, Publisher, Springfield. 3rd edition. 95.