

Washington University School of Medicine

Digital Commons@Becker

Open Access Publications

2016

Outcomes following laminoplasty or laminectomy and fusion in patients with myelopathy caused by ossification of the posterior longitudinal ligament: A systematic review

Weerasak Singhatanadgige

Chulalongkorn University and King Chulalongkorn Memorial Hospital

Worawat Limthongkul

Chulalongkorn University and King Chulalongkorn Memorial Hospital

Frank Valone III

Washington University School of Medicine in St. Louis

Wicharn Yingsakmongkol

Chulalongkorn University and King Chulalongkorn Memorial Hospital

K. Daniel Riew

Columbia University

Follow this and additional works at: https://digitalcommons.wustl.edu/open_access_pubs

Recommended Citation

Singhatanadgige, Weerasak; Limthongkul, Worawat; Valone, Frank III; Yingsakmongkol, Wicharn; and Riew, K. Daniel, "Outcomes following laminoplasty or laminectomy and fusion in patients with myelopathy caused by ossification of the posterior longitudinal ligament: A systematic review." *Global Spine Journal*. 6,7. 702-709. (2016).

https://digitalcommons.wustl.edu/open_access_pubs/7255

This Open Access Publication is brought to you for free and open access by Digital Commons@Becker. It has been accepted for inclusion in Open Access Publications by an authorized administrator of Digital Commons@Becker. For more information, please contact vanam@wustl.edu.

Outcomes following Laminoplasty or Laminectomy and Fusion in Patients with Myelopathy Caused by Ossification of the Posterior Longitudinal Ligament: A Systematic Review

Weerasak Singhatanadgige¹ Worawat Limthongkul¹ Frank Valone III² Wicharn Yingsakmongkol¹
K. Daniel Riew³

¹Department of Orthopaedics, Chulalongkorn University and King Chulalongkorn Memorial Hospital, Bangkok, Thailand

²Department of Orthopaedic Surgery, Washington University, St. Louis, Missouri, United States

³Department of Orthopaedic Surgery, Columbia University, New York, New York, United States

Address for correspondence Weerasak Singhatanadgige, MD, MS, Department of Orthopaedics, Faculty of Medicine, Chulalongkorn University and King Chulalongkorn Memorial Hospital, Thai Red Cross Society, 1873 Rama IV Road, Pathumwan, Bangkok, Thailand 10330 (e-mail: dr.weerasaks@gmail.com).

Global Spine J 2016;6:702–709.

Abstract

Study Design Systematic review.

Objective To compare laminoplasty versus laminectomy and fusion in patients with cervical myelopathy caused by OPLL.

Methods A systematic review was conducted using PubMed/Medline, Cochrane database, and Google scholar of articles. Only comparative studies in humans were included. Studies involving cervical trauma/fracture, infection, and tumor were excluded.

Results Of 157 citations initially analyzed, 4 studies ultimately met our inclusion criteria: one class of evidence (CoE) II prospective cohort study and three CoE III retrospective cohort studies. The prospective cohort study found no significant difference between laminoplasty and laminectomy and fusion in the recovery rate from myelopathy. One CoE III retrospective cohort study reported a significantly higher recovery rate following laminoplasty. Another CoE III retrospective cohort study reported a significantly higher recovery rate in the laminectomy and fusion group. One CoE II prospective cohort study and one CoE III retrospective cohort study found no significant difference in pain improvement between patients treated with laminoplasty versus patients treated with laminectomy and fusion. All four studies reported a higher incidence of C5 palsy following laminectomy and fusion than laminoplasty. One CoE II prospective cohort and one CoE III retrospective cohort reported that there was no significant difference in axial neck pain between the two procedures. One CoE III retrospective cohort study suggested that there was no significant difference between groups in OPLL progression.

Conclusion Data from four comparative studies was not sufficient to support the superiority of laminoplasty or laminectomy and fusion in treating cervical myelopathy caused by OPLL.

Keywords

- ▶ cervical spine
- ▶ myelopathy
- ▶ ossification of the posterior longitudinal ligament
- ▶ surgical treatment
- ▶ laminoplasty
- ▶ laminectomy and fusion
- ▶ outcome

received
August 24, 2015
accepted after revision
January 7, 2016
published online
February 19, 2016

DOI <http://dx.doi.org/10.1055/s-0036-1578805>.
ISSN 2192-5682.

© 2016 Georg Thieme Verlag KG
Stuttgart · New York

License terms



Introduction

Currently there is no standard surgical algorithm for treating cervical myelopathy caused by ossification of the posterior longitudinal ligament (OPLL). Surgical options include anterior corpectomy and fusion, laminoplasty, and laminectomy and fusion.¹ The literature has demonstrated a significant complication rate associated with anterior corpectomy and fusion,² which has led to the investigation of posterior-based procedures, including both laminoplasty and laminectomy and fusion. Laminoplasty has been advocated because of its preservation of neck range of motion (ROM) compared with laminectomy and fusion. However, OPLL is unique when compared with other inciting etiologies of myelopathy, in that neck ROM may incite further progression of OPLL.³

The current literature is laden with studies of laminoplasty and laminectomy and fusion, with the majority of studies lacking comparative groups or long-term follow-up. In this study, we performed a systematic review to assess the clinical results and complications of laminoplasty compared with that of laminectomy and fusion for the treatment of cervical myelopathy caused by OPLL.

To compare laminoplasty to laminectomy and fusion, three key questions were devised: (1) In patients with cervical myelopathy caused by OPLL, what is the effectiveness of laminoplasty compared with laminectomy and fusion? (2) In patients with cervical myelopathy caused by OPLL, what is the safety of laminoplasty compared with laminectomy and fusion? (3) In patients with cervical myelopathy caused by OPLL, does OPLL progress after laminoplasty more than laminectomy and fusion?

Materials and Methods

Study design: Systematic review.

Search: A systematic search was conducted of PubMed/Medline, Cochrane, and Google scholar. The search included the use of Medical Subject Heading (MeSH) terms and key words. The terms specific to OPLL were: ossification of posterior longitudinal ligament OR ossified posterior longitudinal ligament OR ossification of the posterior longitudinal ligament OR calcification of the posterior longitudinal ligament OR ligament calcinosis OR ossification of posterior longitudinal ligament [Mesh]. These terms were combined with terms specific to the surgical procedure: (Laminoplasty OR Laminoplast OR Laminoplast) AND (Laminectomy OR Laminectomy [MeSH]).

Date searched: The data was searched through July 17, 2015.

Inclusion criteria: Studies were included that directly compared laminoplasty with laminectomy and fusion for the treatment of cervical myelopathy caused by OPLL.

Exclusion criteria: Studies including patients with cervical trauma/fracture, infection, or tumor were excluded, as were noncomparative studies (case series and case reports), comparative studies with fewer than five patients per group, and animal, in vitro, and biomechanical studies.

Outcome: The outcome parameters included myelopathy improvement (Japanese Orthopedics Association [JOA]),

pain (visual analog scale [VAS]), cervical alignment, cervical ROM, OPLL progression, and complications.

Analysis: Descriptive statistics, means, standard deviations, and ranges were collected from the original reports. The data was not pooled because of the heterogeneity of the studies.

Overall strength of evidence: The risk of bias was determined by the class of evidence (CoE) rating system.⁴ The overall body of the evidence and recommendation was determined using the Grade of Recommendation Assessment, Development and Evaluation (GRADE) system.⁵

No approval from the Institutional Review Board was needed.

Results

One hundred fifty-seven citations were initially reviewed. After application of the inclusion criteria, seven studies were evaluated for review. Three studies were excluded because they had fewer than five patients per group or they did not directly compare laminoplasty to laminectomy and fusion.⁶⁻⁸ Four studies were included in the final analysis in this study (►Fig. 1, ►Table 1). Yuan et al, the single prospective cohort study reviewed (CoE II), compared laminoplasty with laminectomy and fusion.⁹ Lee et al, a retrospective cohort study (CoE III), compared laminoplasty, laminectomy alone, and laminectomy and fusion.¹⁰ The final two articles, each retrospective cohort studies (CoE III), were authored by Chen et al and compared laminoplasty, corpectomy, and fusion with laminectomy and fusion.^{11,12} Each study included a mixture of continuous, segmental, and mixed types of OPLL. The populations in the studies were predominantly middle-aged men, and the follow-up was greater than 12 months in each study (range 12 to 72 months).

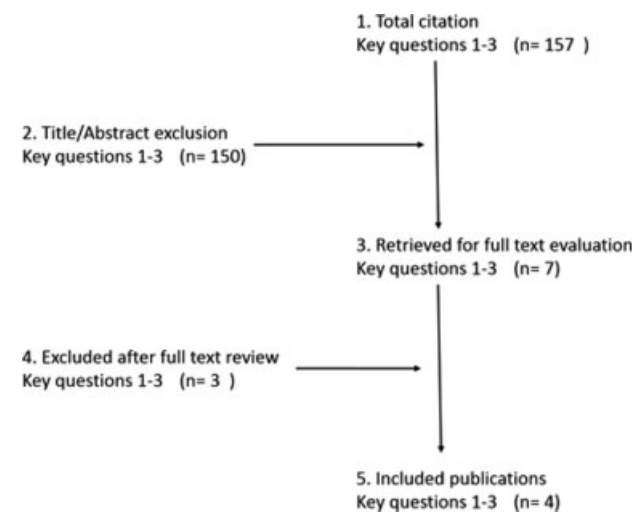


Fig. 1 Flowchart showing result of literature search.

Table 1 Studies comparing laminoplasty with laminectomy and fusion: characteristic of included studies

Study, study design, CoE, and enrollment	Intervention	Demographic	Treatment allocation	OPLL type	Follow-up	Reported outcome
Yuan et al (2015), ⁹ prospective cohort (n = 38), CoE: II (December 2010–December 2012)	Laminoplasty <ul style="list-style-type: none"> • C3–C7 open door laminoplasty • Maintain opened laminar by sutured with contralateral facet capsule Laminectomy and fusion <ul style="list-style-type: none"> • Lateral mass screw (C3, C5, C7) and rod fixation • Autograft • Postoperative collar for 4 wk 	Laminoplasty <ul style="list-style-type: none"> • n = 20 • Male = 30% • Mean age = 59 y (SD 11.6) • Mean disease duration = 22 mo (SD 12.4) Laminectomy and fusion <ul style="list-style-type: none"> • n = 18 • Male = 67% • Mean age = 62 y (SD 11.3) • Mean disease duration = 18 mo (SD 9.3) 	Laminoplasty <ul style="list-style-type: none"> • Transverse diameter of OPLL less than 50% (CT scan) Laminectomy and fusion <ul style="list-style-type: none"> • Transverse diameter of OPLL more than 50% (CT scan) 	Laminoplasty <ul style="list-style-type: none"> • 10 continuous (50%) • 7 mixed (35%) • 3 segmental (15%) Laminectomy and fusion <ul style="list-style-type: none"> • 10 continuous (55.6%) • 6 mixed (33.3%) • 2 segmental (11.1%) 	At least 12 mo	JOA score Recovery rate VAS ROM CROM device (three-dimensional measurement) Complications
Lee et al (2014), ¹⁰ retrospective cohort (n = 57), CoE: III (October 2003–June 2011)	Laminoplasty <ul style="list-style-type: none"> • 16 open door laminoplasty • Maintain opened laminar by miniplate and screw • 5 double door laminoplasty Laminectomy alone Laminectomy and fusion <ul style="list-style-type: none"> • Lateral mass screw and rod fixation • Local autograft 	Laminoplasty <ul style="list-style-type: none"> • n = 21 • Male = 71.4% • Mean age = 54.2 y (SD 10.3) Laminectomy alone <ul style="list-style-type: none"> • n = 15 • Male = 86.7% • Mean age = 61.3 y (SD 6.6) Laminectomy and fusion <ul style="list-style-type: none"> • n = 21 • Male = 90.5% • Mean age = 63.7 y (SD 7.7) 	Surgeons' decision based on <ul style="list-style-type: none"> • Cervical alignment • Severity of OPLL • Surgeons' preference 	Laminoplasty <ul style="list-style-type: none"> • 14 continuous (66.7%) • 7 mixed (33.3%) Laminectomy alone <ul style="list-style-type: none"> • 9 continuous (60%) • 6 mixed (40%) Laminectomy and fusion <ul style="list-style-type: none"> • 15 continuous (71.4%) • 6 mixed (28.6%) 	At least 24 mo	JOA score VAS NDI Cervical alignment • C2–C7 SVA • C2–C7 Cobb angle OPLL progression
Chen et al (2012), ¹¹ retrospective cohort (n = 164), CoE: III (January 2004–December 2007)	Corpectomy and fusion Laminoplasty Laminectomy and fusion	Corpectomy and fusion <ul style="list-style-type: none"> • n = 91 Laminoplasty <ul style="list-style-type: none"> • n = 41 • Male = 80% • Mean age = 46.3 (SD 2.5) Laminectomy and fusion <ul style="list-style-type: none"> • n = 32 • Male = 61.3% • Mean age = 52.6 (SD 1.7) 	Corpectomy and fusion <ul style="list-style-type: none"> • Short segment pathology (≤ 3 vertebral bodies) Laminoplasty <ul style="list-style-type: none"> • Long segment pathology • Cervical lordosis Laminectomy and fusion <ul style="list-style-type: none"> • Long segment pathology • Cervical kyphosis 	No significant difference in OPLL occupying ratio Laminoplasty <ul style="list-style-type: none"> • 41.2% (SD 1.4) Laminectomy and fusion <ul style="list-style-type: none"> • 47.1% (SD 1.1) 	At least 48 mo (range 48–72 mo)	JOA score Recovery rate Complications

Table 1 (Continued)

Study, study design, CoE, and enrollment	Intervention	Demographic	Treatment allocation	OPLL type	Follow-up	Reported outcome
Chen et al (2011), ¹² retrospective cohort (n = 75), CoE: III Corpectomy + fusion (May 2002–June 2004) Laminoplasty (June 1997–June 2004) Laminectomy and fusion (August 1999–April 2002)	Corpectomy and fusion Laminoplasty • 15 open door laminoplasty • 10 double door laminoplasty • Philadelphia collar for 3 mo Laminectomy and fusion • Screw and rod fixation • Local autograft • No postoperative immobilization	Corpectomy and fusion • n = 22 Laminoplasty • n = 25 • Male = 64.0% • Mean age = 54.2 y (range 32–66) Laminectomy and fusion • n = 28 • Male = 67.8% • Mean age = 55.3 y (range 48–69)	Laminoplasty • Economic reason (could not pay for instrumentation) Laminectomy and fusion • Could pay for instrumentation	No significant difference in OPLL occupying ratio. Laminoplasty • 54.3% (SD 4.6) Laminectomy and fusion • 58.2% (SD 6.4)	At least 48 mo	JOA score Recovery rate Cervical lordosis Complications

Abbreviations: CoE, class of evidence; ROM, cervical range of motion; CT, computed tomography; JOA score, Japanese Orthopedic Association Score; NDI, Neck Disability Index; OPLL, ossification of posterior longitudinal ligament; ROM, range of motion; SD, standard deviation; SVA, sagittal vertical axis; VAS, visual analog scale.

Comparison of Clinical Results

Myelopathy

The recovery rate as defined by Hirabayashi et al is based on the equation: $[(\text{postoperative JOA score} - \text{preoperative JOA score}) / (17 - \text{preoperative JOA score})] \times 100\%$.¹³ Yuan et al evaluated neurologic improvement using JOA score and recovery rate (►Table 2).⁹ The study found no significant difference between treatments groups at 1-year follow-up. The mean recovery rate was 43.7% in the laminoplasty group and 50.8% in the laminectomy and fusion group. In agreement, Lee et al did not find any significant difference in recovery between treatment groups.¹⁰ Chen et al additionally assessed the neurologic improvement using the JOA score and recovery rate.¹¹ This study reported a significantly higher recovery following laminoplasty compared with laminectomy and fusion (65.2 versus 50.8%). However, all patients who underwent laminectomy and fusion had preoperative cervical kyphosis and a more severe neurologic deficit preoperatively, which might explain the lower recovery rate in the laminectomy and fusion group of this study. In contrast, Chen et al found that the recovery rate after laminoplasty was significant lower than after laminectomy and fusion (21.1 versus 43.5%).¹² In this study, the preoperative cervical alignment and neurologic status were comparable between groups.

Neck Pain

Yuan et al reported VAS following both laminoplasty and laminectomy and fusion (►Table 2).⁹ The mean VAS of the laminoplasty group decreased from 4.8 to 1.7, and the mean VAS of the laminectomy and fusion group decreased from 4.5 to 2.5. There was no significant difference in the improvement of VAS between these groups. In accordance with these results, Lee et al reported improvements in VAS of neck pain after surgery in both treatments groups, laminoplasty (3.4 to 3) and laminectomy and fusion (2.9 to 1.3), with no significant difference between operative groups.¹⁰

Neck Disability Index

Lee et al assessed functional improvements using the Neck Disability Index (NDI) score (►Table 2).¹⁰ The mean NDI score following laminoplasty decreased from 12.3 to 8.8, and the mean NDI score following laminectomy and fusion decreased from 17.9 to 13.8. Improvement in the NDI score was not significantly different between the two treatment groups.

Cervical Range of Motion Preservation

Yuan et al was the only study to compare ROM between the different surgical interventions (►Table 2).⁹ This study reported significantly greater ROM in flexion, extension, and side bending in the individuals who underwent laminoplasty compared with those who underwent laminectomy and fusion. The greatest loss in ROM seen in both surgical groups was in extension, 59.8 and 54.3% of preoperative values for laminoplasty and laminectomy and fusion groups, respectively. The greatest preservation in ROM was seen in rotation, wherein 90% of preoperative ROM was

Table 2 Studies comparing laminoplasty with laminectomy and fusion: comparison of clinical results

Study and study design	Outcomes	Laminoplasty	Laminectomy and fusion	p Value
Yuan et al (2015), ⁹ prospective cohort	JOA score/mJOA score Preoperative Postoperative (12 mo) Recovery rate (%) Pain improvement (VAS) Preoperative Postoperative (12 mo) VAS change ROM preservation (%)	10.6 13.4 43.7 4.8 1.7 3.1 Flexion 75.1 Extension 59.8 Left flexion 80.9 Right flexion 76.1 Left rotation 89.4 Right rotation 90.8	11.1 14.1 50.8 4.5 2.5 2.0 Flexion 56.2 Extension 54.3 Left flexion 63.8 Right flexion 61.8 Left rotation 81.1 Right rotation 82.0	NR NR NS NR NR NS Significant Significant Significant NS NS
Lee et al (2014), ¹⁰ retrospective cohort	JOA score/mJOA score Preoperative, mean (SD) Postoperative, mean (SD) Recovery rate (%) Pain improvement (VAS) Preoperative, mean (SD) Postoperative, mean (SD) VAS scale change NDI Preoperative, mean (SD) Postoperative, mean (SD) NDI change ROM preservation (%) C2–C7 SVA Preoperative, mean (SD) Postoperative, mean (SD) SVA change (mm) Cervical lordosis Preoperative, degree (SD) Postoperative, degree (SD) Lordosis change (degree) OPLL progression (%)	14.0 (2.8) 13.6 (3.4) –13.3 3.4 (3.5) 3.0 (2.8) 0.4 12.3 8.8 3.5 NR 22.0 (12.1) 28.2 (15.5) 6.2 14.2 (5.8) 8.0 (7.9) 6.2 (decrease lordosis) 45.5 (no clinical)	12.4 (2.9) 13.1 (1.2) 15.2 2.9 (2.8) 1.3 (1.7) 1.6 17.9 13.8 4.1 NR 29.5 (10.7) 29.2 (10.9) –0.3 10.0 (11.6) 5.1 (12.0) 4.9 (decrease lordosis) 30.0 (no clinical)	NR NR NR NS NS NS NR NR NS NR NR Significant NR NR NS NS
Chen et al (2012), ¹¹ retrospective cohort	JOA score/mJOA score Preoperative, mean (SD) Postoperative, mean (SD) Recovery rate, % (SD) Pain improvement (VAS scale) ROM preservation (%)	10.2 (0.3) 14.6 (0.2) 65.2 (5.8) NR NR	9.1 (0.4) 13.0 (0.2) 50.8 (6.4) NR NR	Significant Significant Significant NR NR
Chen et al (2011), ¹² retrospective cohort	JOA score/mJOA score Preoperative, mean (SD) Postoperative, mean (SD) Recovery rate, % (SD) Pain improvement (VAS scale) ROM preservation (%) Cervical lordosis Preoperative, degree (SD) Postoperative, degree (SD) Lordosis change (degree)	8.5 (0.7) 10.9 (0.4) 25.1 (8.5) NR NR 4.9 (0.7) 6.1 (0.6) 1.2 (increase lordosis)	8.7 (1.6) 12.4 (1.2) 43.5 (12.7) NR NR 6.5 (1.8) 11.7 (1.2) 5.2 (increase lordosis)	NS NR Significant NR NR NS Significant Significant

Abbreviations: JOA score, Japanese Orthopedic Association Score; mJOA score, modified Japanese Orthopedic Association Score; NDI, Neck Disability Index; NR, not reported; NS, not significant; ROM, range of motion; SD, standard deviation; SVA, sagittal vertical axis; VAS, visual analog scale.

seen following laminoplasty and 80% following laminectomy and fusion.

Cervical Alignment

Lee et al found a significant loss of cervical lordosis over time following both laminoplasty and laminectomy and fusion:

laminoplasty, change from –14.2 degrees to –8.0 degrees; laminectomy and fusion, change from –10.0 degrees to –5.1 degrees (► **Table 2**).¹⁰ Additionally, this study showed that the mean C2–C7 sagittal vertical axis of patients in the laminoplasty group increased gradually from preoperative to 24 months (change from 22.0 to 28.2 mm). In contrast, there

Table 3 Studies comparing laminoplasty with laminectomy and fusion: postoperative complication rates

Complications	Studies	Laminoplasty, no. of cases (%)	Laminectomy and fusion, no. of cases (%)
C5 palsy	Yuan et al (2015) ⁹	1/20 (5.0%)	2/18 (11.1%)
	Lee et al (2014) ¹⁰	0/21 (0%)	2/21 (9.6%)
	Chen et al (2012) ¹¹	1/41 (2.4%)	8/32 (25.0%)
	Chen et al (2011) ¹²	2/25 (8%)	4/28 (14.2%)
Axial neck pain	Yuan et al (2015) ⁹	3/20 (15%)	4/18 (22.2%)
	Chen et al (2012) ¹¹	6/41 (14.6%)	4/32 (12.5%)
Hematoma	Chen et al (2011) ¹²	1/25 (4%)	0/28 (0%)
Progressive kyphosis	Chen et al (2011) ¹²	4/25 (16%)	0/28 (0%)
Incomplete decompression	Lee et al (2014) ¹⁰	2/21 (9.6%)	0/21(0%)
Screw malposition	Lee et al (2014) ¹⁰	0/21 (0%)	1/21 (4.8%)

was no change in the laminectomy and fusion group for 24 months (change from 29.5 to 29.2 mm). Subgroup analysis showed that a high sagittal vertical axis (>40 mm) was correlated with significant neck pain in the laminoplasty group. Chen et al reported significantly greater lordosis following laminectomy and fusion than laminoplasty.¹²

Complications

Fifth Cervical Nerve Root Palsy

All four studies reported that the incidence of cervical nerve root five (C5) palsy was higher following laminectomy and fusion (range, 9.6 to 25%) than laminoplasty (range, 0 to 8%). The majority of C5 palsy fully recovered at 12 months' follow-up (►Table 3).

Other Complications

Miscellaneous complications were reported following laminoplasty including hematoma (4%),¹² progressive kyphosis (20%),¹² and incomplete decompression (9.6%).¹⁰ Lee et al reported a 4.8% rate of screw malposition following laminectomy and fusion.¹⁰

OPLL Progression

Lee et al reported that the progression rate of OPLL was 45.5, 52.5, and 30.0% in laminoplasty, laminectomy alone, and laminectomy and fusion groups, respectively (►Table 2).¹⁰ This study found no significant difference following laminoplasty compared with laminectomy and fusion. Additionally, no neurologic deterioration was found as a result of OPLL progression in any of the groups.

Evidence Summary

The evidence presented does not establish the superiority of laminoplasty or laminectomy and fusion (►Table 4). The evidence regarding improvements in myelopathy and NDI following laminoplasty or laminectomy and fusion is insufficient. The strength of evidence regarding pain and ROM

following either procedure is low. Additionally, the strength of evidence evaluating the safety of either procedure is insufficient. Finally, the overall strength of evidence evaluating the incidence of OPLL progression following laminoplasty or laminectomy and fusion does not establish the beneficence of one procedure over the other.

Discussion

The gold standard surgical treatment for cervical myelopathy caused by OPLL remains controversial. Anterior corpectomy and fusion surgery, which directly decompresses the spinal cord, is technically demanding and associated with high complication rates, causing surgeons to opt for the posterior approach to address this cervical pathology. In this study, we evaluated the evidence regarding laminoplasty or laminectomy and fusion by analyzing data obtained from PubMed/Medline, Cochrane, and Google scholar. Despite many studies on the surgical treatment of OPLL, few had comparative groups. After application of inclusion criteria, four studies were included for analysis: one prospective cohort and three retrospective cohort studies. Due to the heterogeneity of these studies, we were unable to perform a meta-analysis of the data. Therefore, we performed a systematic review regarding the surgical effectiveness, safety, and risk of OPLL progression comparing laminoplasty and laminectomy and fusion.

Each of the studies reported a JOA score and an individual recovery rate; however, the results diverged. Yuan et al suggested no significant difference in recovery rate between the treatment groups.⁹ Insignificance between the two groups was similarly seen in the study by Lee et al.¹⁰ In contrast, Chen et al reported that laminoplasty was superior. However, all patients who underwent laminectomy and fusion had preoperative cervical kyphosis and more severe neurologic deficits.¹¹ In another study, Chen et al reported conflicting conclusions that favored laminectomy and fusion.¹² Although each study was comparative, each also has significant limitations. All four studies were nonrandomized controlled studies. Additionally, the

Table 4 Evidence summary

Outcome	Strength of evidence	Conclusions/comments
In patients with cervical myelopathy caused by OPLL, what is the effectiveness of laminoplasty compared with laminectomy and fusion?		
Improvement of myelopathy	Insufficient	The CoE II prospective cohort study suggested that there was no significant difference between groups in recovery rate of myelopathy. One CoE III retrospective cohort study reported that the recovery rate was significant higher in laminoplasty group. One CoE III retrospective cohort study reported that the recovery rate was significant higher in laminectomy and fusion group.
Pain (VAS)	Low	The CoE II prospective cohort and one CoE III retrospective cohort studies found no significant difference in pain outcomes between treatment groups.
NDI	Insufficient	One CoE III retrospective cohort study found no significant difference in NDI score improvement between treatment groups.
ROM preservation	Low	The CoE II prospective cohort study found significant better ROMs (flexion, extension, and lateral flexion) preservation in laminoplasty group compared with laminectomy and fusion group.
Cervical sagittal alignment	Insufficient	One CoE III retrospective cohort study found that there was significant increase in C2–C7 SVA in laminoplasty group. One CoE III retrospective cohort study showed that the postoperative lordosis after laminectomy and fusion was significant larger than laminoplasty.
In patients with cervical myelopathy caused by OPLL, what is the safety of laminoplasty compared with laminectomy and fusion?		
C5 palsy	Low	Overall, data from the CoE II prospective cohort and three CoE III retrospective cohorts suggested higher incidence of C5 palsy in laminectomy and fusion group.
Axial neck pain	Low	The CoE II prospective cohort and one CoE III retrospective cohort reported no significant difference in axial pain between groups.
Overall complication rate	Insufficient	Data from two CoE III retrospective cohorts suggested that incidence of hematoma, progressive kyphosis, and incomplete decompression appears to be higher in laminoplasty group. However, data from the CoE II prospective cohort and three CoE III retrospective cohort suggested that incidence of C5 palsy and screw malposition appear to be higher in laminectomy and fusion group.
In patients with cervical myelopathy caused by OPLL, does OPLL progress after laminoplasty more than laminectomy and fusion?		
OPLL progression	Insufficient	One CoE III retrospective cohort study suggested that there was no significant difference between groups in OPLL progression. There was no neurologic deterioration found as a result of OPLL progression.

Abbreviations: CoE, class of evidence; NDI, Neck Disability Index; OPLL, ossification of posterior longitudinal ligament; ROM, range of motion; SVA, sagittal vertical axis; VAS, visual analog scale.

surgeons chose either laminoplasty or laminectomy and fusion with different criteria; therefore, there were significant differences in the populations compared. In conclusion, the current literature does not demonstrate greater effectiveness of laminoplasty or laminectomy and fusion in treating cervical myelopathy caused by OPLL.

There was no one procedure that was found to be superior regarding complications. There was a higher incidence of C5 palsy following laminectomy and fusion. On the other hand, the incidence of postoperative hematoma, progressive kyphosis, and incomplete decompression were higher following laminoplasty. Additionally, OPLL progression was 45.5% following laminoplasty and 30.0% after laminectomy and fusion. However, this result was not statistically significant, and there was no neurologic deterioration found as a result of OPLL progression. Finally, the incidence of axial neck pain was comparable between groups.

The greatest limitation to this current study is that few comparative studies are available, and there were no randomized controlled studies for evaluation. Additionally, the NDI score and ROM preservation were reported in only one study. Data from these four comparative studies is not sufficient to establish the superiority of laminoplasty or laminectomy and fusion in treating cervical myelopathy caused by OPLL. The overall strength of evidence to support any conclusion is low or insufficient. Often, the value of a systematic review is to identify the absence of clear-cut evidence. For example, some surgeons believe that one procedure is superior to the other and cite the few articles on the topic. Our analysis suggests that the evidence for superiority of one over the other is not strong. However, because outcomes of both procedures appear to be equivalent, one might consider the less-invasive nature and lower cost of laminoplasty. Although there is insufficient evidence to make the recommendation

based upon the available literature, surgeons and patients might consider cost and invasiveness when choosing between the two options. Nonetheless, it is a reflection of the state of the literature, and at minimum, this review can be a springboard for future research to fill in the gaps. Well-designed randomized studies are required to answer this question.

Conclusion

The data from four comparative studies is not sufficient to support the superiority of laminoplasty or laminectomy and fusion in treating cervical myelopathy caused by OPLL. The overall strength of evidence to support any conclusion is low or insufficient.

Disclosures

Weerasak Singhatanadgige: none

Worawat Limthongkul: none

Frank Valone III: none

Wicharn Yingsakmongkol: none

K. Daniel Riew: Board member (AOSpine International); Editorial board (*Global Spine Journal*, *Spine Journal*, *Neurosurgery*); Grant (AOSpine, Cerapedics, Medtronic); Honorarium (AOSpine, NASS); Royalties (Medtronic, Biomet); Travel expenses (Broadwater)

Funding

None

References

- 1 An HS, Al-Shihabi L, Kurd M. Surgical treatment for ossification of the posterior longitudinal ligament in the cervical spine. *J Am Acad Orthop Surg* 2014;22(7):420–429
- 2 Shinomiya K, Okamoto A, Kamikozuru M, Furuya K, Yamaura I. An analysis of failures in primary cervical anterior spinal cord decompression and fusion. *J Spinal Disord* 1993;6(4):277–288
- 3 Chiba K, Ogawa Y, Ishii K, et al. Long-term results of expansive open-door laminoplasty for cervical myelopathy—average 14-year follow-up study. *Spine (Phila Pa 1976)* 2006;31(26):2998–3005
- 4 Wright JG, Swiontkowski MF, Heckman JD. Introducing levels of evidence to the journal. *J Bone Joint Surg Am* 2003;85-A(1):1–3
- 5 Atkins D, Best D, Briss PA, et al; GRADE Working Group. Grading quality of evidence and strength of recommendations. *BMJ* 2004; 328(7454):1490
- 6 Nakano N, Nakano T, Nakano K. Comparison of the results of laminectomy and open-door laminoplasty for cervical spondylotic myeloradiculopathy and ossification of the posterior longitudinal ligament. *Spine (Phila Pa 1976)* 1988;13(7):792–794
- 7 Kalb S, Martirosyan NL, Perez-Orribo L, Kalani MY, Theodore N. Analysis of demographics, risk factors, clinical presentation, and surgical treatment modalities for the ossified posterior longitudinal ligament. *Neurosurg Focus* 2011;30(3):E11
- 8 Kommu R, Sahu BP, Purohit AK. Surgical outcome in patients with cervical ossified posterior longitudinal ligament: a single institutional experience. *Asian J Neurosurg* 2014;9(4):196–202
- 9 Yuan W, Zhu Y, Liu X, et al. Postoperative three-dimensional cervical range of motion and neurological outcomes in patients with cervical ossification of the posterior longitudinal ligament: cervical laminoplasty versus laminectomy with fusion. *Clin Neurol Neurosurg* 2015;134:17–23
- 10 Lee CH, Jahng TA, Hyun SJ, Kim KJ, Kim HJ. Expansive laminoplasty versus laminectomy alone versus laminectomy and fusion for cervical ossification of the posterior longitudinal ligament: is there a difference in the clinical outcome and sagittal alignment? *J Spinal Disord Tech* 2014 (Epub ahead of print)
- 11 Chen Y, Liu X, Chen D, Wang X, Yuan W. Surgical strategy for ossification of the posterior longitudinal ligament in the cervical spine. *Orthopedics* 2012;35(8):e1231–e1237
- 12 Chen Y, Guo Y, Lu X, et al. Surgical strategy for multilevel severe ossification of posterior longitudinal ligament in the cervical spine. *J Spinal Disord Tech* 2011;24(1):24–30
- 13 Hirabayashi K, Miyakawa J, Satomi K, Maruyama T, Wakano K. Operative results and postoperative progression of ossification among patients with ossification of cervical posterior longitudinal ligament. *Spine (Phila Pa 1976)* 1981;6(4):354–364