

NCCN

Ovarian Cancer, Version 1.2016

Clinical Practice Guidelines in Oncology

Robert J. Morgan Jr, MD; Deborah K. Armstrong, MD;
 Ronald D. Alvarez, MD; Jamie N. Bakkum-Gamez, MD;
 Kian Behbakht, MD; Lee-may Chen, MD; Larry Copeland, MD;
 Marta Ann Crispens, MD; Maria DeRosa, RN;
 Oliver Dorigo, MD, PhD; David M. Gershenson, MD;
 Heidi J. Gray, MD; Ardeshir Hakam, MD;
 Laura J. Havrilesky, MD; Carolyn Johnston, MD;
 Shashikant Lele, MD; Lainie Martin, MD;
 Ursula A. Matulonis, MD; David M. O'Malley, MD;
 Richard T. Penson, MD, MRCP; Sanja Percac-Lima, MD, PhD;

Mario Pineda, MD, PhD; Steven C. Plaxe, MD;
 Matthew A. Powell, MD; Elena Ratner, MD;
 Steven W. Remmenga, MD; Peter G. Rose, MD;
 Paul Sabbatini, MD; Joseph T. Santoso, MD;
 Theresa L. Werner, MD; Jennifer Burns; and
 Miranda Hughes, PhD

Overview

Ovarian neoplasms consist of several histopathologic entities; treatment depends on the specific tumor type.¹ Epithelial ovarian cancer comprises the majority of malignant ovarian neoplasms (about 90%)²⁻⁴; however, other less common pathologic subtypes may occur. The less common ovarian histopathologies (LCOHs) include carcinosarcomas (malignant mixed Müllerian tumors [MMMTs] of the ovary),

Abstract

This selection from the NCCN Guidelines for Ovarian Cancer focuses on the less common ovarian histopathologies (LCOHs), because new algorithms were added for LCOHs and current algorithms were revised for the 2016 update. The new LCOHs algorithms include clear cell carcinomas, mucinous carcinomas, and grade 1 (low-grade) serous carcinomas/endometrioid epithelial carcinomas. The LCOHs also include carcinosarcomas (malignant mixed Müllerian tumors of the ovary), borderline epithelial tumors (also known as *low malignant potential tumors*), malignant sex cord-stromal tumors, and malignant germ cell tumors.

J Natl Compr Canc Netw 2016;14(9):1134-1163

NCCN Categories of Evidence and Consensus

Category 1: Based upon high-level evidence, there is uniform NCCN consensus that the intervention is appropriate.

Category 2A: Based upon lower-level evidence, there is uniform NCCN consensus that the intervention is appropriate.

Category 2B: Based upon lower-level evidence, there is NCCN consensus that the intervention is appropriate.

Category 3: Based upon any level of evidence, there is major NCCN disagreement that the intervention is appropriate.

All recommendations are category 2A unless otherwise noted.

Clinical trials: NCCN believes that the best management for any cancer patient is in a clinical trial. Participation in clinical trials is especially encouraged.

Please Note

The NCCN Clinical Practice Guidelines in Oncology (NCCN Guidelines®) are a statement of consensus of the authors regarding their views of currently accepted approaches to treatment. Any clinician seeking to apply or consult the NCCN Guidelines® is expected to use independent medical judgment in the context of individual clinical circumstances to determine any patient's care or treatment. The National Comprehensive Cancer Network® (NCCN®) makes no representation or warranties of any kind regarding their content, use, or application and disclaims any responsibility for their applications or use in any way. [The full NCCN Guidelines for Ovarian Cancer are not printed in this issue of JNCCN but can be accessed online at NCCN.org.](#)

© National Comprehensive Cancer Network, Inc. 2016, All rights reserved. The NCCN Guidelines and the illustrations herein may not be reproduced in any form without the express written permission of NCCN.

Disclosures for the NCCN Ovarian Cancer Panel

At the beginning of each NCCN Guidelines panel meeting, panel members review all potential conflicts of interest. NCCN, in keeping with its commitment to public transparency, publishes these disclosures for panel members, staff, and NCCN itself.

Individual disclosures for the NCCN Ovarian Cancer Panel members can be found on page 1163. (The most recent version of these guidelines and accompanying disclosures are available on the NCCN Web site at NCCN.org.)

These guidelines are also available on the Internet. For the latest update, visit [NCCN.org](#).

Journal of the National Comprehensive Cancer Network

clear cell carcinomas, mucinous carcinomas, grade 1 (low-grade) serous carcinomas/endometrioid epithelial carcinomas, borderline epithelial tumors (also known as *low malignant potential tumors*), malignant sex cord-stromal tumors, and malignant germ cell tumors. Fallopian tube cancer and primary peritoneal cancer are less common neoplasms that are managed in a similar manner to epithelial ovarian cancer. However, the LCOHs may be managed differently.

This selection from the NCCN Guidelines for Ovarian Cancer focuses on the LCOHs, because new algorithms were added to the LCOHs for the 2016 update (see LCOH-1, page 1139). The new algorithms include clear cell carcinomas, mucinous carcinomas, and grade 1 (low-grade) serous carcinomas/endometrioid epithelial carcinomas. Other rare his-

tologies had been previously included in the LCOH guidelines and were also revised for 2016. These other rare histologies include MMMTs, borderline epithelial tumors, malignant sex cord-stromal tumors, and malignant germ cell tumors.

The complete version of the NCCN Guidelines for Ovarian Cancer addresses all aspects of management for the different types of ovarian cancer as well as for fallopian tube cancer and primary peritoneal cancer. These NCCN Guidelines for Ovarian Cancer were originally published 20 years ago and have been updated subsequently at least once every year.⁵

A brief introduction to ovarian cancer is provided in the subsequent section. By definition, the NCCN Guidelines cannot incorporate all possible clinical variations and are not intended to replace good clinical judgment or individualization of treat-

Text cont. on page 1148.

NCCN Ovarian Cancer Panel Members

*Robert J. Morgan Jr, MD/Chair††

City of Hope Comprehensive Cancer Center

Deborah K. Armstrong, MD/Vice ChairΩ†

The Sidney Kimmel Comprehensive Cancer Center at Johns Hopkins

Ronald D. Alvarez, MDΩ

University of Alabama at Birmingham
Comprehensive Cancer Center

Jamie N. Bakkum-Gamez, MDΩ

Mayo Clinic Cancer Center

Kian Behbakht, MDΩ

University of Colorado Cancer Center

Lee-may Chen, MDΩ

UCSF Helen Diller Family Comprehensive Cancer Center

Larry Copeland, MDΩ

The Ohio State University Comprehensive Cancer Center –
James Cancer Hospital and Solove Research Institute

Marta Ann Crispens, MDΩ

Vanderbilt-Ingram Cancer Center

Maria DeRosa, RN¥

Oliver Dorigo, MD, PhDΩ

Stanford Cancer Institute

David M. Gershenson, MDΩ

The University of Texas MD Anderson Cancer Center

Heidi J. Gray, MDΩ

University of Washington Medical Center/
Seattle Cancer Care Alliance

Ardeshir Hakam, MD‡

Moffitt Cancer Center

Laura J. Havrilesky, MDΩ

Duke Cancer Institute

Carolyn Johnston, MDΩ

University of Michigan Comprehensive Cancer Center

Shashikant Lele, MDΩ

Roswell Park Cancer Institute

Lainie Martin, MD†

Fox Chase Cancer Center

Ursula A. Matulonis, MDΩ†

Dana-Farber/Brigham and Women's Cancer Center

David M. O'Malley, MDΩ

The Ohio State University Comprehensive Cancer Center -
James Cancer Hospital and Solove Research Institute

Richard T. Penson, MD, MRCPΩ†

Massachusetts General Hospital Cancer Center

Sanja Percac-Lima, MDP

Massachusetts General Hospital Cancer Center

Mario Pineda, MD, PhDΩ

Robert H. Lurie Comprehensive Cancer Center of
Northwestern University

Steven C. Plaxe, MDΩ

UC San Diego Moores Cancer Center

Matthew A. Powell, MDΩ

Siteman Cancer Center at Barnes-Jewish Hospital and
Washington University School of Medicine

Elena Ratner, MDΩ

Yale Cancer Center/Smilow Cancer Hospital

Steven W. Remmenga, MDΩ

Fred & Pamela Buffett Cancer Center

Peter G. Rose, MDΩ

Case Comprehensive Cancer Center/
University Hospitals Seidman Cancer Center and
Cleveland Clinic Taussig Cancer Institute

Paul Sabbatini, MD†‡

Memorial Sloan Kettering Cancer Center

Joseph T. Santoso, MDΩ

St. Jude Children's Research Hospital/
The University of Tennessee Health Science Center

Theresa L. Werner, MD†‡

Huntsman Cancer Institute at the University of Utah

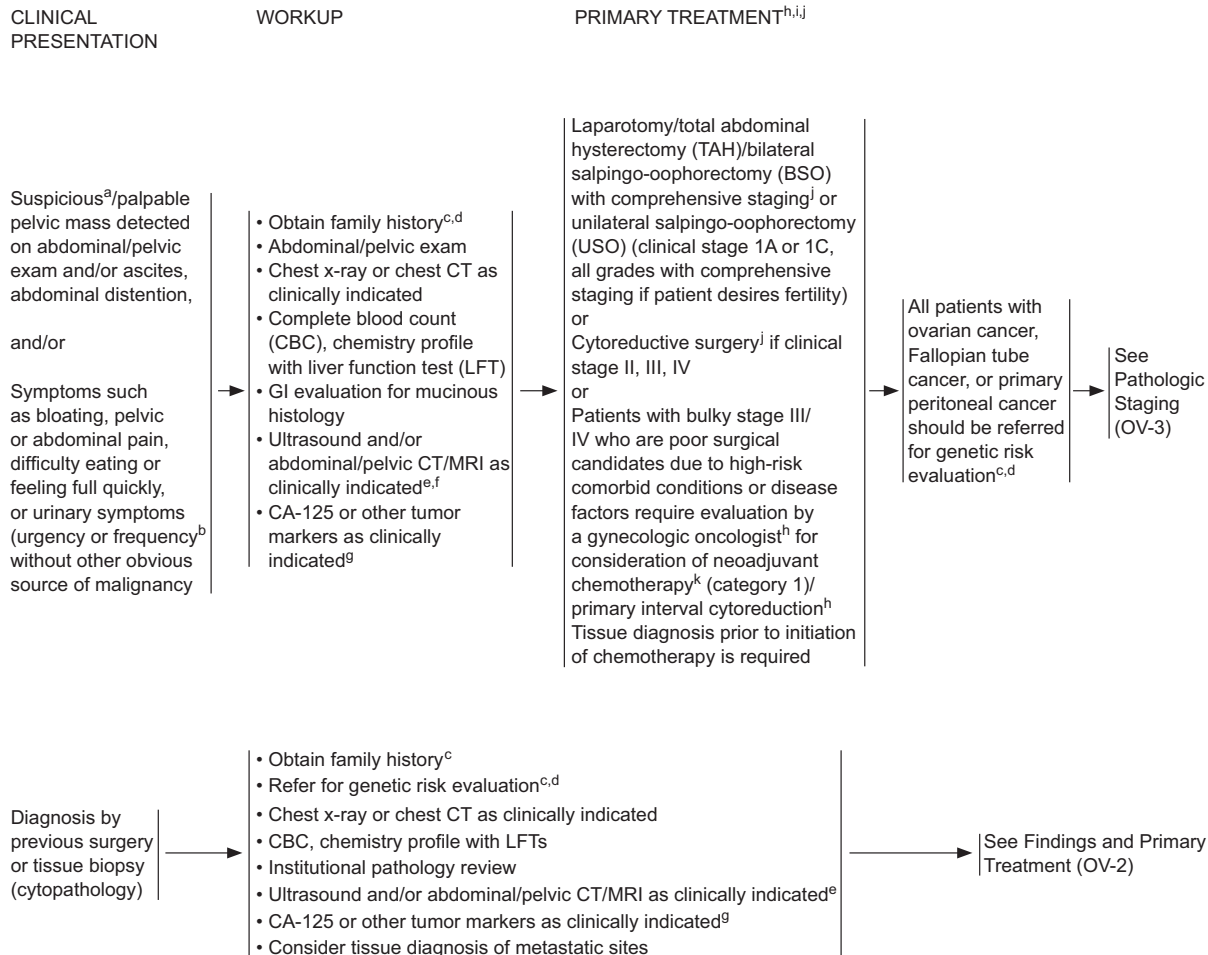
NCCN Staff: Jennifer Burns and Miranda Hughes, PhD

KEY:

*Writing Committee member

Specialties: ΩGynecology Oncology; ‡Hematology/
Hematology Oncology; †Medical Oncology; †Internal
Medicine; ‡Pathology; ¥Patient Advocacy

*EPITHELIAL OVARIAN CANCER/FALLOPIAN TUBE CANCER/PRIMARY PERITONEAL CANCER



*Available online, in these guidelines, at NCCN.org.

^aIm SS, et al. *Obstet Gynecol* 2005;105:35-41. See Discussion.

^bGoff BA, Mandel L, Drescher CW, et al. *Cancer* 2007;109:221-227.

^cSee NCCN Guidelines for Genetic/Familial High-Risk Assessment: Breast and Ovarian and NCCN Guidelines for Genetic/Familial High-Risk Assessment: Colorectal.

^dPrimary treatment should not be delayed for a genetic counseling referral.

^eImaging performed with contrast unless contraindicated.

^fPET/CT scan or MRI may be indicated for indeterminate lesions if results will alter management.

^gOther tumor markers may include inhibin, beta-human chorionic gonadotropin (β-hCG), alpha-fetoprotein, lactate dehydrogenase (LDH), and carcinoembryonic antigen (CEA). See Discussion for usefulness of diagnostic tests.

^hStandard recommendation includes a patient evaluation by a gynecologic oncologist prior to initiating chemotherapy. Published data demonstrate that primary assessment and debulking by a gynecologic oncologist results in a survival advantage. Patients being evaluated for neoadjuvant chemotherapy should be seen by a fellowship-trained gynecologic oncologist prior to being considered a poor surgical candidate. A referral to a gynecologic oncologist is also recommended for management of occult serous tubal intraepithelial carcinomas.

ⁱAll women undergoing surgery for ovarian cancer should be counseled about the clinical benefit associated with combined IV and IP chemotherapy administration prior to surgery. NCI Clinical Announcement.

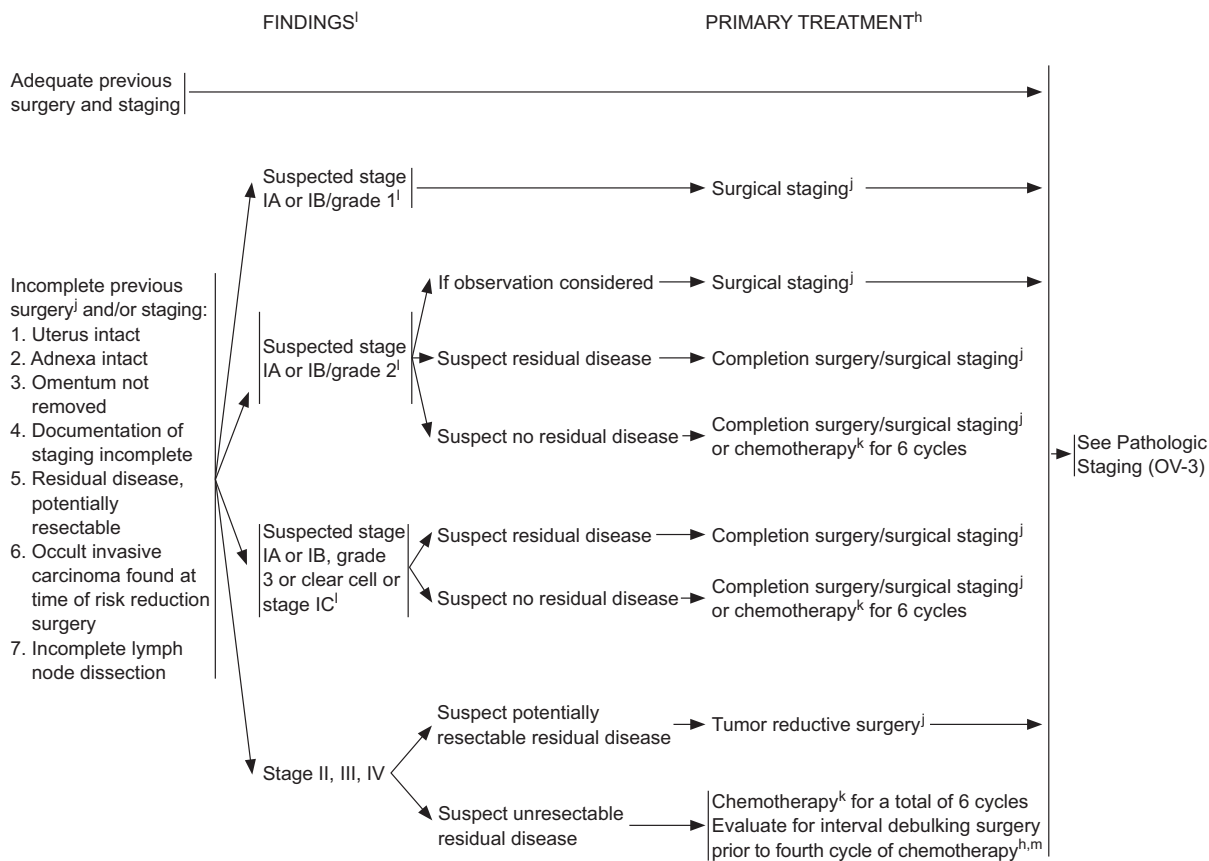
^jSee Principles of Surgery (OV-A*).

^kSee Principles of Chemotherapy (OV-B*) and Management of Drug Reactions (OV-C*).

OV-1

*EPITHELIAL OVARIAN CANCER/FALLOPIAN TUBE CANCER/PRIMARY PERITONEAL CANCER

DIAGNOSIS BY PREVIOUS SURGERY



*Available online, in these guidelines, at NCCN.org.

^hStandard recommendation includes a patient evaluation by a gynecologic oncologist prior to initiating chemotherapy. Published data demonstrate that primary assessment and debulking by a gynecologic oncologist results in a survival advantage. Patients being evaluated for neoadjuvant chemotherapy should be seen by a fellowship-trained gynecologic oncologist prior to being considered a poor nonsurgical candidate. A referral to a gynecologic oncologist is also recommended for management of occult serous tubal intraepithelial carcinomas.

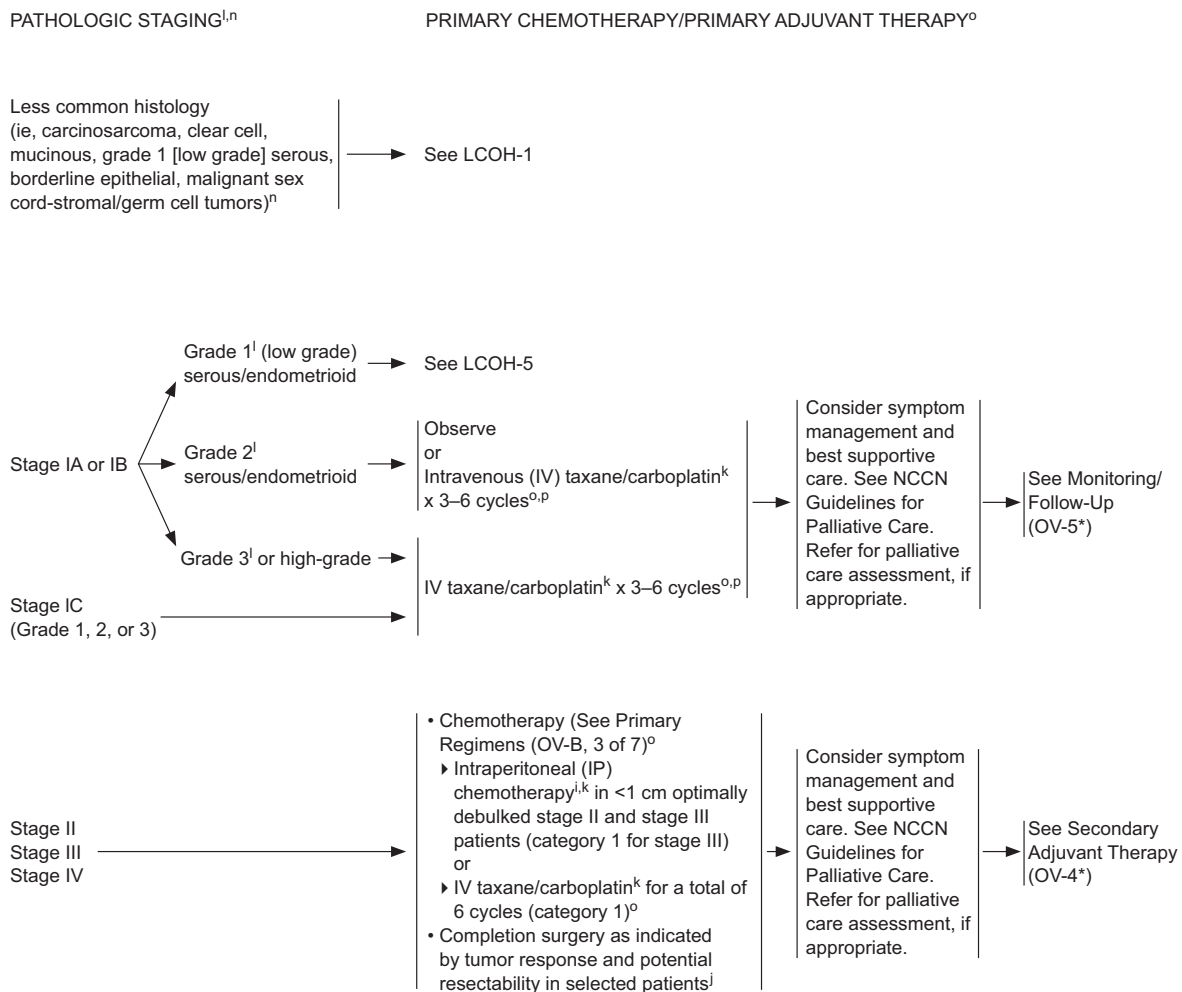
ⁱSee Principles of Surgery (OV-A*).

^kSee Principles of Chemotherapy (OV-B*) and Management of Drug Reactions (OV-C*).

^lPathologists recommend that serous ovarian cancer is either low-grade (most grade 1 serous tumors) or high-grade (most grade 2 or 3 serous tumors). See FIGO Guidelines (ST-5*).

^mCompletion surgery after 3 cycles is preferred; however, surgery may be performed after 4–6 cycles based on the clinical judgment of the gynecologic oncologist.

*EPITHELIAL OVARIAN CANCER/FALLOPIAN TUBE CANCER/PRIMARY PERITONEAL CANCER



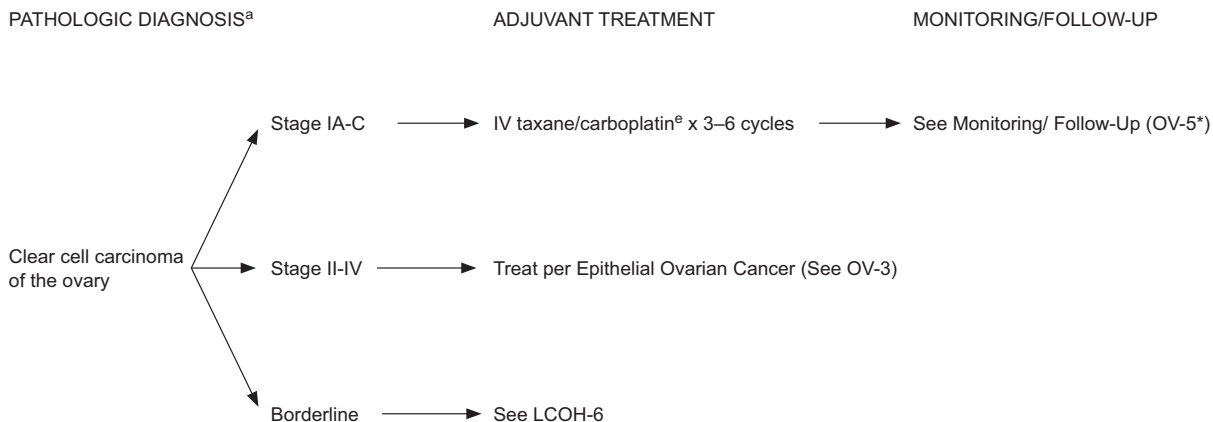
*Available online, in these guidelines, at NCCN.org.

<p>ⁱAll women undergoing surgery for ovarian cancer should be counseled about the clinical benefit associated with combined IV and IP chemotherapy administration prior to surgery. See NCI Clinical Announcement.</p> <p>^jSee Principles of Surgery (OV-A*).</p> <p>^kSee Principles of Chemotherapy (OV-B*) and Management of Drug Reactions (OV-C*).</p> <p>^lPathologists recommend that serous ovarian cancer is either low-grade (most grade 1 serous tumors) or high-grade (most grade 2 or 3 serous tumors). See FIGO Guidelines (ST-5*).</p>	<p>ⁿSee WHO Histologic Classification (OV-D*).</p> <p>^oPatients receiving primary chemotherapy will be monitored as follows:</p> <ol style="list-style-type: none"> 1. Pelvic exams at least every 2–3 cycles 2. Interim CBC with platelets as indicated 3. Chemistry profiles if indicated 4. CA-125 levels or other tumor markers as clinically indicated prior to each cycle of chemotherapy 5. Chest/abdominal/pelvic CT, MRI, PET-CT, or PET as indicated. <p>^pData suggests select patients with serous histology may benefit from 6 cycles. See Discussion.</p>
---	--

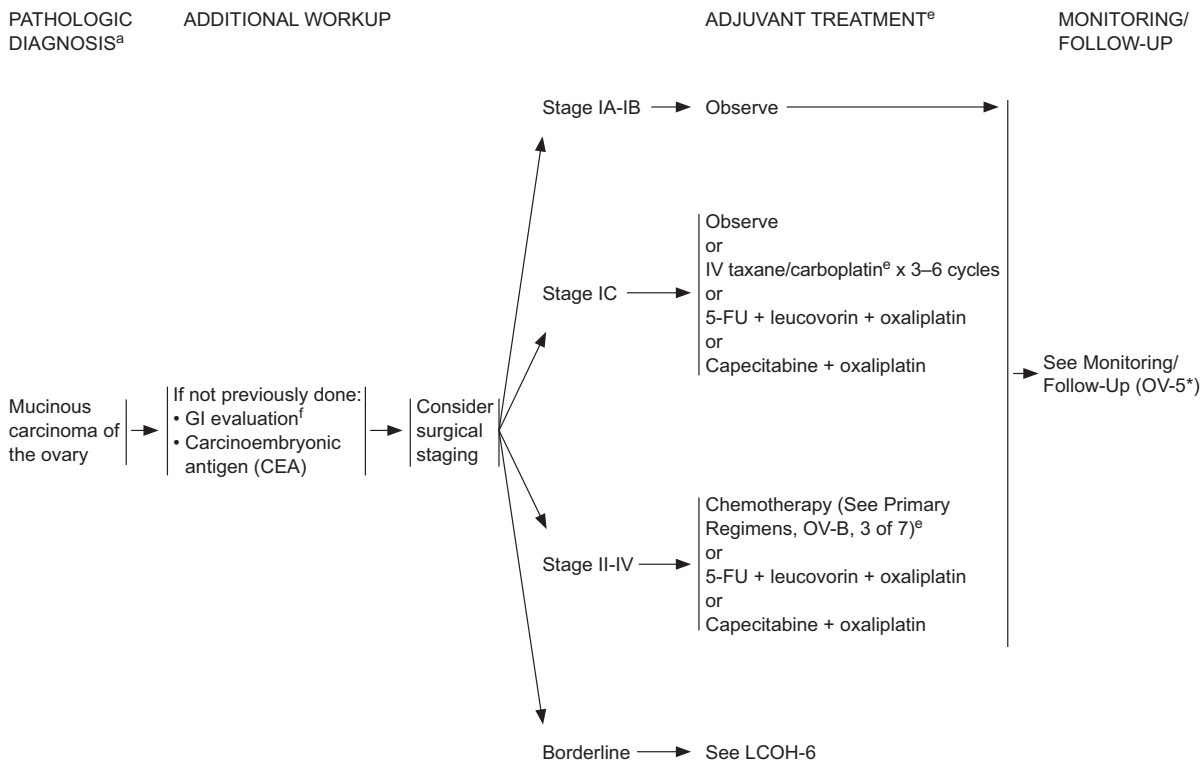
OV-3

Clinical trials: NCCN believes that the best management of any cancer patient is in a clinical trial. Participation in clinical trials is especially encouraged. All recommendations are category 2A unless otherwise indicated.

CLEAR CELL CARCINOMA OF THE OVARY



MUCINOUS CARCINOMA OF THE OVARY



*Available online, in these guidelines, at NCCN.org.

^aSee WHO Histologic Classification (OV-D*).

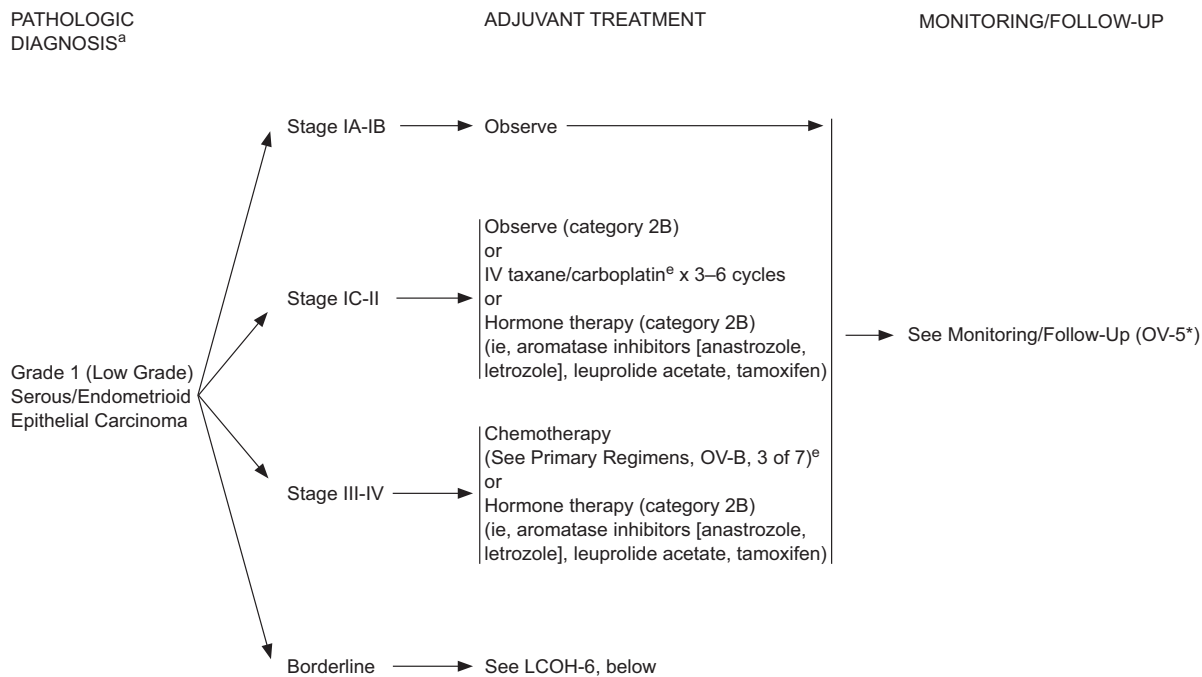
^eSee Principles of Chemotherapy (OV-B*) and Management of Drug Reactions (OV-C*).

^fConsider molecular testing for GI malignancies.

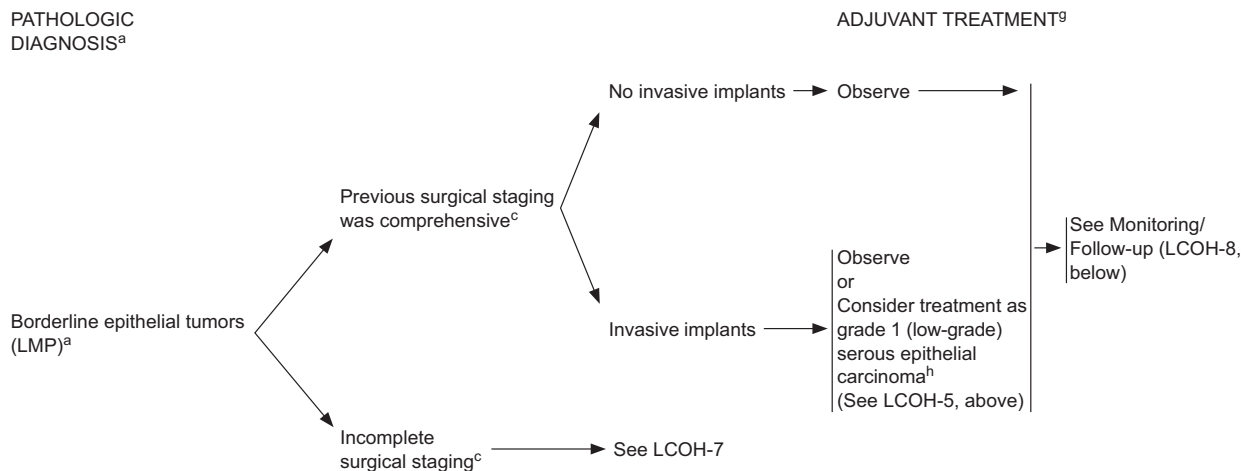
LCOH-3
LCOH-4

Ovarian Cancer, Version 1.2016

GRADE 1 (LOW-GRADE) SEROUS/ENDOMETRIOID EPITHELIAL CARCINOMA



BORDERLINE EPITHELIAL TUMORS (LOW MALIGNANT POTENTIAL)



*Available online, in these guidelines, at NCCN.org.

^aSee WHO Histologic Classification (OV-D*).

^cSee Principles of Surgery (OV-A*).

^eSee Principles of Chemotherapy (OV-B*) and Management of Drug Reactions (OV-C*).

^gStandard recommendation includes a patient evaluation by a gynecologic oncologist.

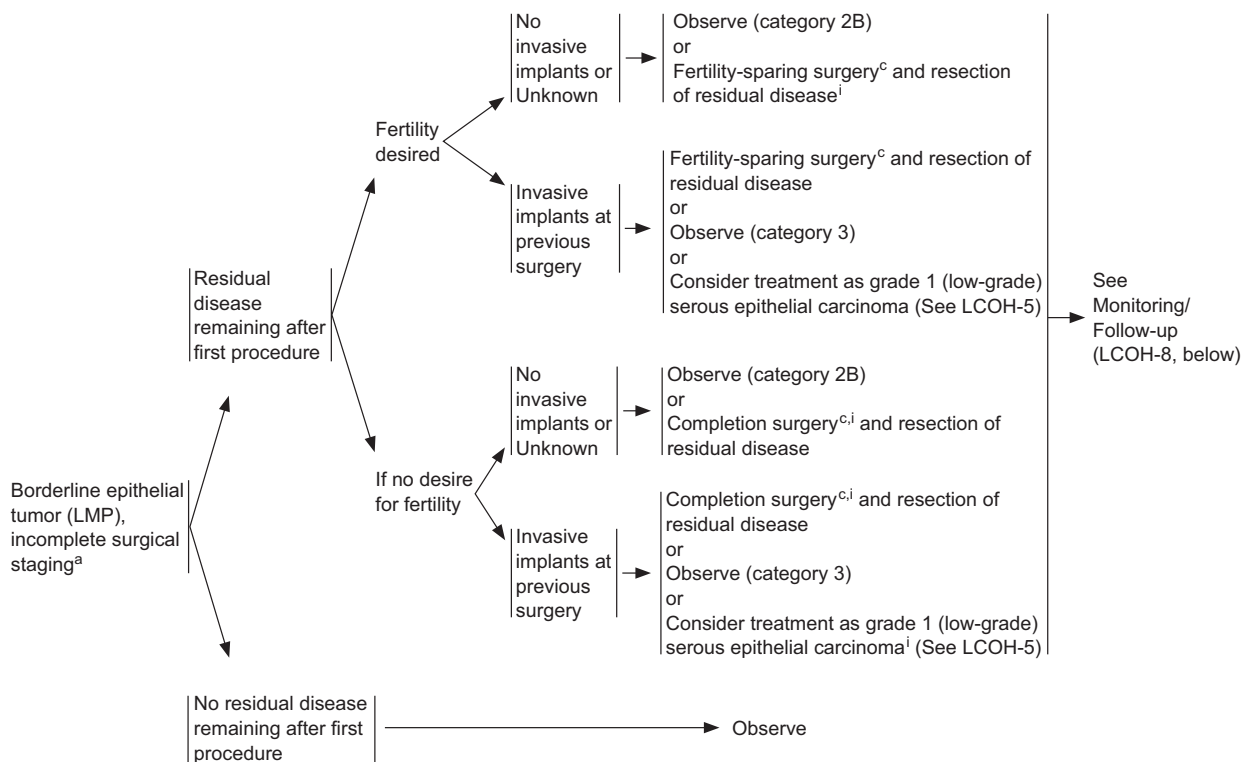
^hChemotherapy (IV or IP) has not been shown to be beneficial in ovarian borderline epithelial tumors (LMP).

LCOH-5
LCOH-6

BORDERLINE EPITHELIAL TUMORS (LOW MALIGNANT POTENTIAL)

PATHOLOGIC DIAGNOSIS^a

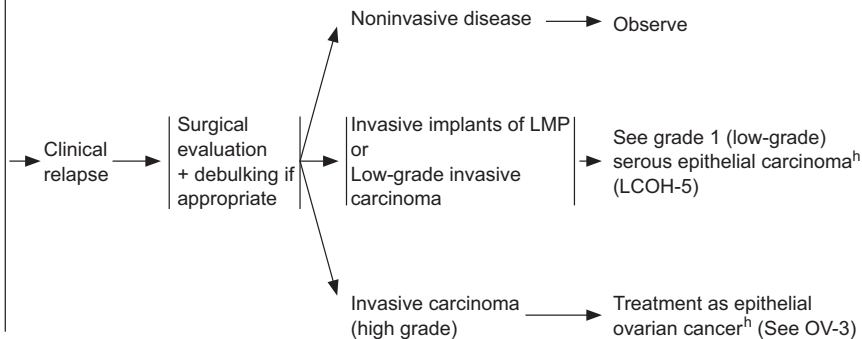
ADJUVANT TREATMENT^g



MONITORING/FOLLOW-UP

- Visits every 3–6 mo for up to 5 y, then annually
- Physical exam including pelvic exam
- CA-125^l or other tumor markers every visit if initially elevated
- After completion of childbearing in patients who underwent USO, consider completion surgery (category 2B)
- CBC, chemistry profile as indicated
- Imaging as clinically indicated: Chest/abdominal/pelvic CT, MRI, PET-CT, or PET^k
- Ultrasound as indicated for patients with fertility-sparing surgery

RECURRENT DISEASE



RECURRENCE THERAPY

*Available online, in these guidelines, at NCCN.org.

^aSee WHO Histologic Classification (OV-D*).

^cSee Principles of Surgery (OV-A*).

^gStandard recommendation includes a patient evaluation by a gynecologic oncologist.

^hChemotherapy (IV or IP) has not been shown to be beneficial in ovarian borderline epithelial tumors (LMP).

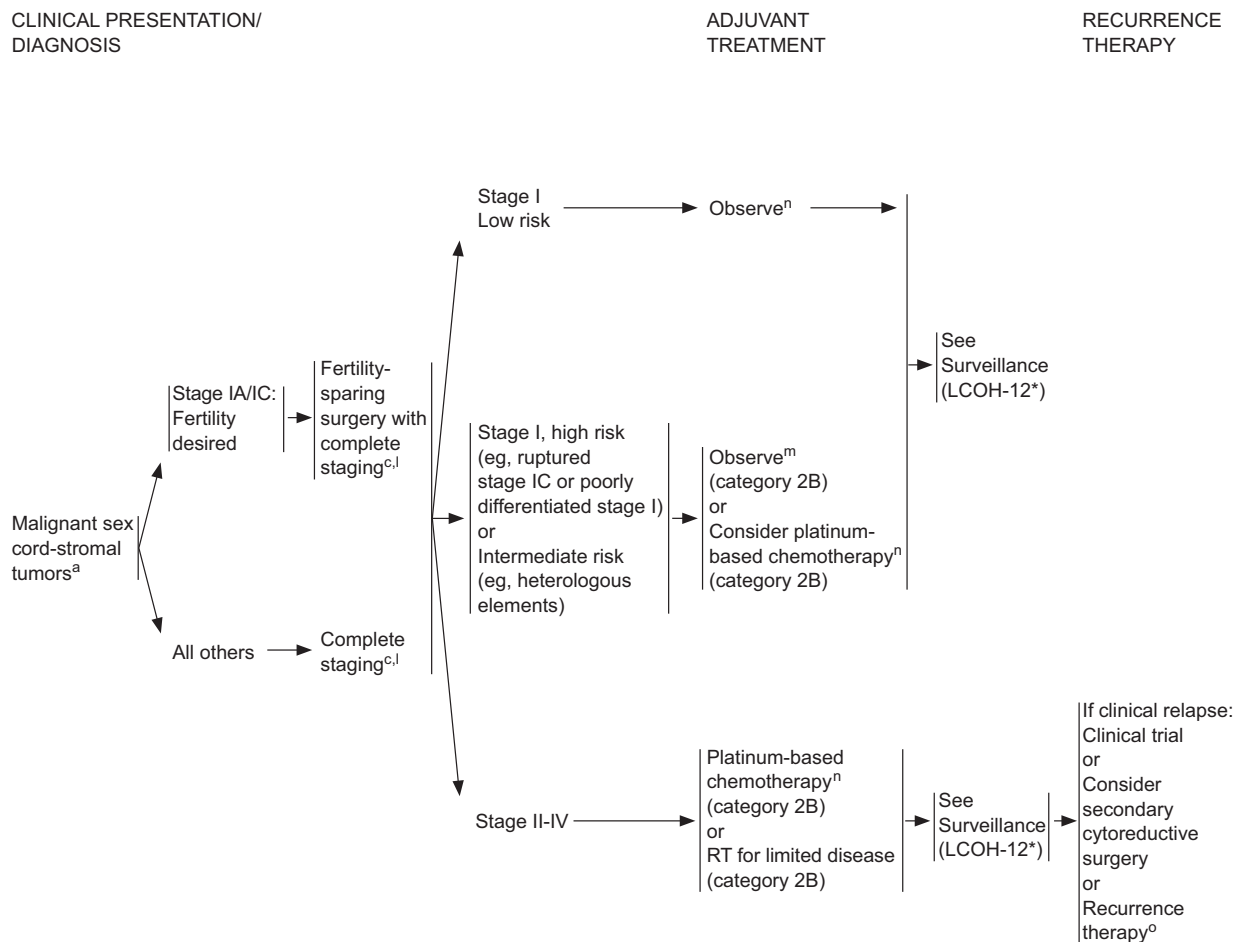
ⁱFor pathologically proven LMP, lymph node evaluation may be considered on a case-by-case basis.

^lThere are data regarding the utility of CA-125 for monitoring of ovarian cancer after completion of primary therapy. See The Society of Gynecologic Oncology (SGO) position statement and Discussion.

^kImaging performed with contrast unless contraindicated.

LCOH-7
LCOH-8

Clinical trials: NCCN believes that the best management of any cancer patient is in a clinical trial. Participation in clinical trials is especially encouraged. All recommendations are category 2A unless otherwise indicated.



*Available online, in these guidelines, at NCCN.org.

^aSee WHO Histologic Classification (OV-D*).

^cSee Principles of Surgery (OV-A*).

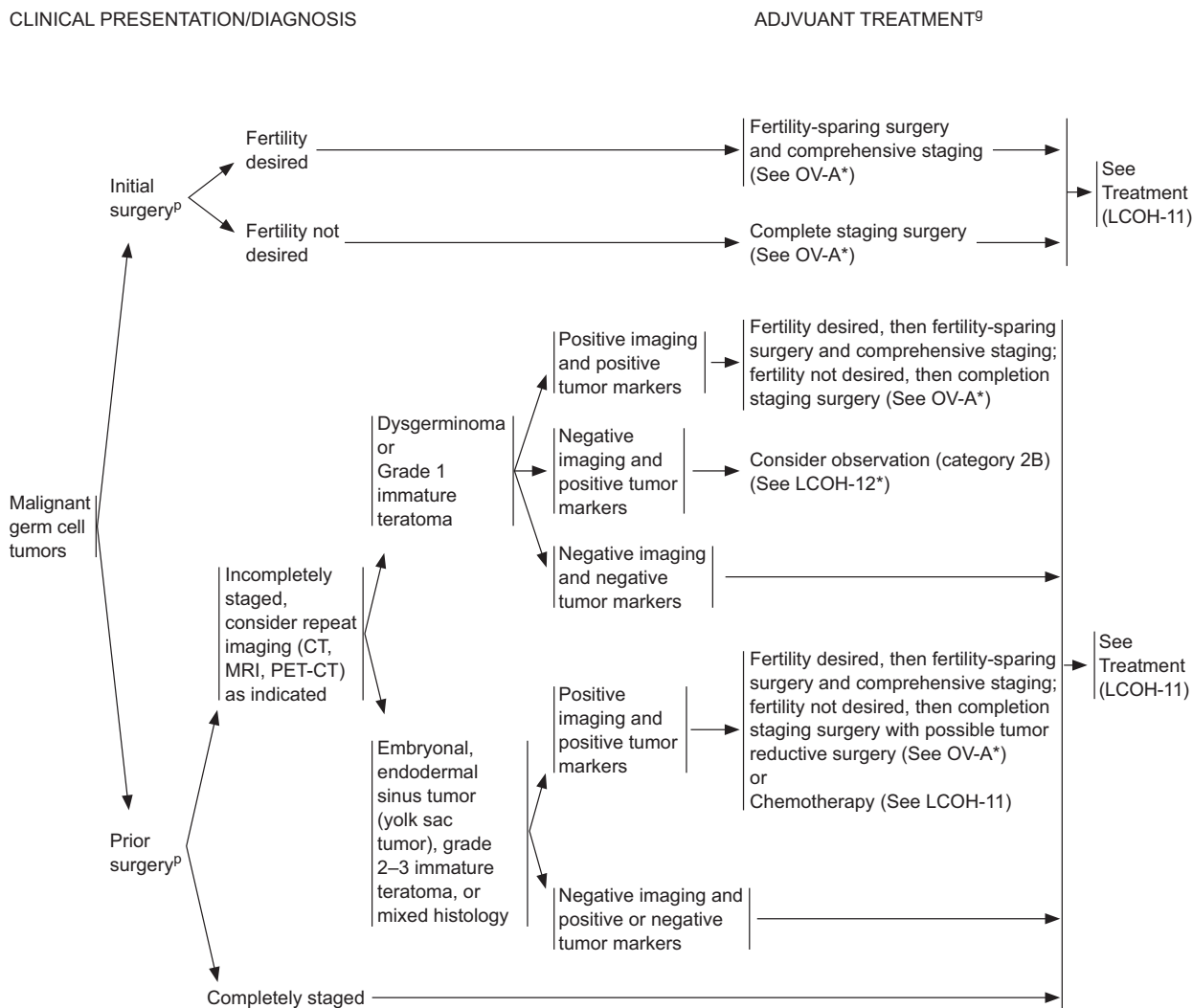
^lLymphadenectomy may be omitted.

^mInhibin levels can be followed if initially elevated for granulosa cell tumors (category 2B).

ⁿMalignant germ cell regimens or paclitaxel/carboplatin regimens are preferred. See Primary Chemotherapy Regimens for Malignant Germ Cell/Sex Cord-Stromal Tumors (OV-B, 4 of 7).

^oSee Acceptable Recurrence Therapies for Malignant Germ Cell/Sex Cord-Stromal Tumors (OV-B, 6 of 7).

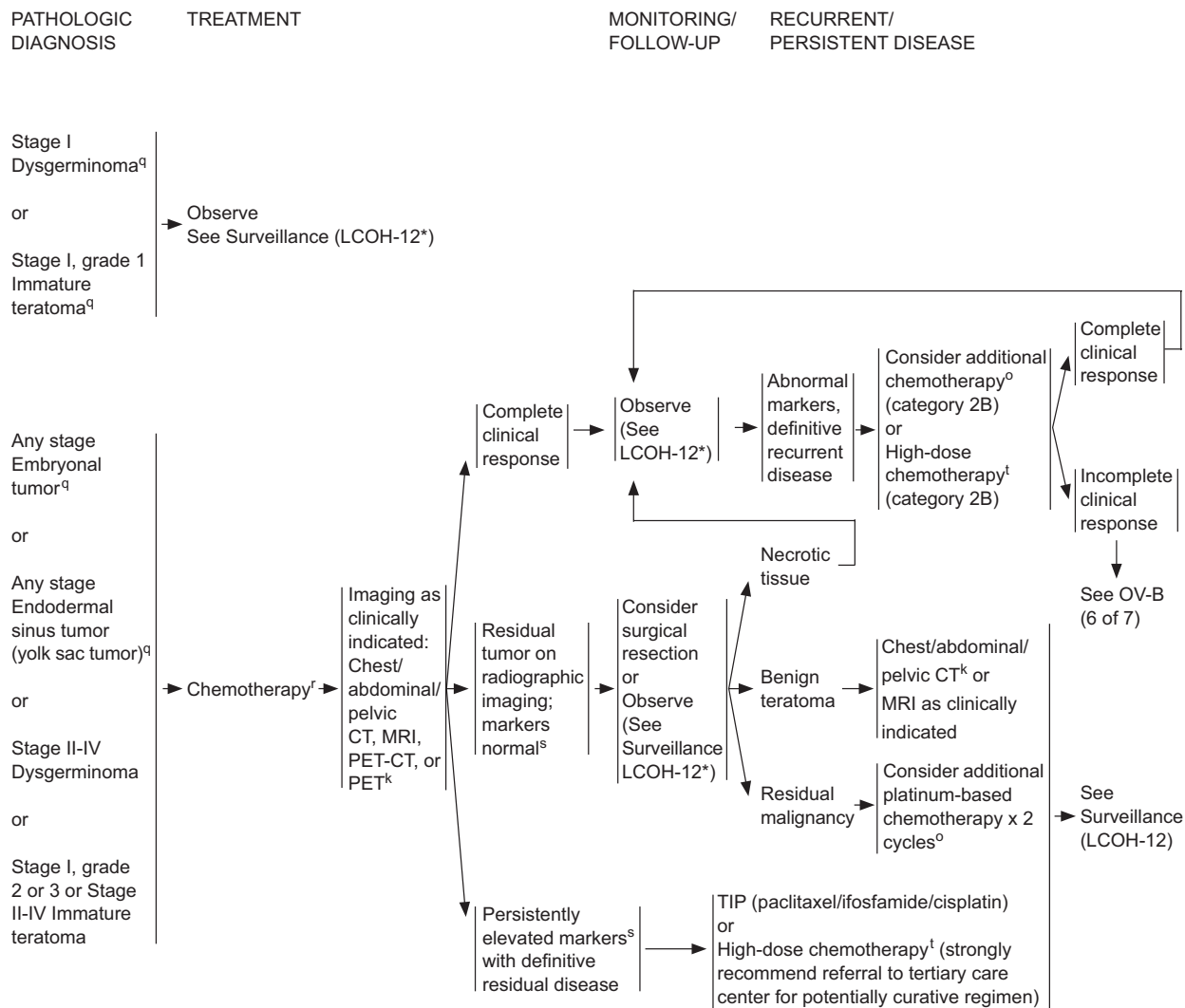
LCOH-9



*Available online, in these guidelines, at NCCN.org.

⁹Standard recommendation includes a patient evaluation by a gynecologic oncologist.
^pSurgical principles for pediatric/young adult patients may differ from those for adult patients. See Principles of Surgery (OV-A*).

LCOH-10



*Available online, in these guidelines, at NCCN.org.

^kImaging performed with contrast unless contraindicated.

^oSee Acceptable Recurrence Therapies for Malignant Germ Cell/Sex Cord-Stromal Tumors (OV-B, 6 of 7).

^qPediatric/adolescent patients with the following clinical presentations may consider observation or chemotherapy as treatment options: stage IA, IB dysgerminoma; stage IA, grade 1 immature teratoma; stage IA embryonal tumors; or stage IA yolk sac tumors.

^fSee Primary Chemotherapy Regimens for Malignant Germ Cell Tumors (OV-B, 4 of 7).

^sSee LCOH-1 for markers.

^tHigh-dose chemotherapy regimens vary among institutions. Some patients are potentially curable with stem cell transplantation. Patients with potentially curable recurrent germ cell disease should be referred to a tertiary care institution for stem-cell transplant consultation and potentially curative therapy.

LCOH-11

*EPITHELIAL OVARIAN CANCER/FALLOPIAN TUBE CANCER/PRIMARY PERITONEAL CANCER & LESS COMMON HISTOPATHOLOGIES
PRINCIPLES OF SYSTEMIC THERAPY (3 of 7)

Primary Chemotherapy/Primary Adjuvant Therapy Regimens^a

Ovarian/Fallopian Tube/Primary Peritoneal/Carcinosarcoma/Clear Cell/Mucinous/Borderline Epithelial/Grade 1 (Low-Grade) Serous/Endometrioid

Stage II-IV

- IP/IV Regimen
 - ▶ Paclitaxel 135 mg/m² IV continuous infusion over 3 or 24 h^c Day 1; cisplatin 75–100 mg/m² IP, Day 2 after IV paclitaxel; paclitaxel 60 mg/m² IP Day 8. Repeat every 3 weeks x 6 cycles. (category 1)
- IV Regimens^b
 - ▶ Paclitaxel 175 mg/m² IV over 3 hours followed by carboplatin^d AUC 5–6 IV over 1 hour Day 1. Repeat every 3 weeks x 6 cycles. (category 1)
 - ▶ Dose-dense paclitaxel 80 mg/m² IV over 1 hour Days 1, 8, and 15 followed by carboplatin^d AUC 5–6 IV over 1 hour Day 1. Repeat every 3 weeks x 6 cycles. (category 1)
 - ▶ Paclitaxel 60 mg/m² IV over 1 hour followed by carboplatin AUC 2 IV over 30 minutes. Weekly for 18 weeks.^e (category 1)
 - ▶ Docetaxel 60–75 mg/m² IV over 1 hour followed by carboplatin^d AUC 5–6 IV over 1 hour Day 1. Repeat every 3 weeks x 6 cycles. (category 1)
 - ▶ Bevacizumab-containing regimens per ICON-7 and GOG-218:
Paclitaxel 175 mg/m² IV over 3 hours followed by carboplatin^d AUC 5–6 IV over 1 hour, and bevacizumab 7.5 mg/kg IV over 30–90 minutes Day 1. Repeat every 3 weeks x 5–6 cycles. Continue bevacizumab for up to 12 additional cycles. (category 2B)
 - or
Paclitaxel 175 mg/m² IV over 3 hours followed by carboplatin^d AUC 6 IV over 1 hour Day 1. Repeat every 3 weeks x 6 cycles. Starting Day 1 of cycle 2, give bevacizumab 15 mg/kg IV over 30–90 minutes every 3 weeks for up to 22 cycles. (category 2B)

Additional options for the following less common histopathologies:

- Carcinosarcoma (MMMT)
 - ▶ Carboplatin/ifosfamide
 - ▶ Cisplatin/ifosfamide
 - ▶ Paclitaxel/ifosfamide (category 2B)
- Mucinous tumors
 - ▶ 5-FU/leucovorin/oxaliplatin
 - ▶ Capecitabine/oxaliplatin
- Grade 1 (low-grade) serous/endometrioid and borderline epithelial carcinoma
 - ▶ Hormone therapy (Aromatase inhibitors [ie, anastrozole, letrozole], leuprolide acetate, tamoxifen) (category 2B)

PRINCIPLES OF SYSTEMIC THERAPY (4 of 7)

Primary Chemotherapy/Primary Adjuvant Therapy Regimens^a

Malignant Germ Cell/Sex Cord-Stromal Tumors

Malignant Germ Cell Tumors^a

- BEP (bleomycin, etoposide, cisplatin)^f
 - ▶ Bleomycin 30 units per week
 - ▶ Etoposide 100 mg/m² daily for days 1–5, cisplatin 20 mg/m² daily for days 1–5
 - ▶ Repeat every 21 days for 3 cycles for good risk (category 2B), or 4 cycles for poor risk.
- Etoposide/carboplatin^a
 - ▶ For select patients with stage IB-III resected dysgerminoma for whom minimizing toxicity is critical, 3 cycles of etoposide/carboplatin can be used.
 - ▶ Carboplatin 400 mg/m² on day 1 plus etoposide 120 mg/m² on days 1, 2, and 3 every 4 weeks for 3 cycles.

Malignant Sex Cord-Stromal Tumors

- BEP (category 2B)^f
- Paclitaxel/carboplatin (category 2B)

Continued on OV-B 5 of 7
(available online, in these guidelines, at NCCN.org)

^aSee Discussion for references.

^bIV regimens may be considered for neoadjuvant therapy for epithelial ovarian cancer.

^cThe published randomized trial regimen used IV continuous infusion paclitaxel over 24 h.

^dDue to changes in creatinine methodology, changes regarding carboplatin dosing can be considered. See FDA carboplatin dosing statement.

^eThis regimen may be considered for elderly patients or those with poor performance status.

^fRecommend pulmonary function test if considering bleomycin.

Ovarian Cancer, Version 1.2016

EOC/FTC/PPC & LCH*

*EPITHELIAL OVARIAN CANCER/FALLOPIAN TUBE CANCER/PRIMARY PERITONEAL CANCER & LESS COMMON HISTOPATHOLOGIES

PRINCIPLES OF SYSTEMIC THERAPY (6 of 7)

Acceptable Recurrence Therapies For Malignant Germ Cell/Sex Cord-Stromal Tumors

	Cytotoxic Therapy (In alphabetical order)	Hormonal Therapy	Targeted Therapy	Radiation Therapy
Malignant Germ Cell Tumors [†]	<p><u>Potentially Curative Therapy:</u> High-dose chemotherapy[†] TIP (paclitaxel, ifosfamide, cisplatin)</p> <p><u>Palliative Therapy Only:</u> Cisplatin/etoposide Docetaxel Docetaxel/carboplatin Paclitaxel Paclitaxel/ifosfamide Paclitaxel/carboplatin Paclitaxel/gemcitabine VIP (etoposide, ifosfamide, cisplatin) VeIP (vinblastine, ifosfamide, cisplatin) VAC (vincristine, dactinomycin, cyclophosphamide) TIP Supportive care only (See NCCN Supportive Care Guidelines, available at NCCN.org)</p>			Palliative localized radiation therapy
Malignant Sex Cord-Stromal Tumors [‡]	<p>Docetaxel Paclitaxel Paclitaxel/ifosfamide Paclitaxel/carboplatin VAC Supportive care only (See NCCN Supportive Care Guidelines, available at NCCN.org)</p>	<p>Aromatase inhibitors (ie, anastrozole, letrozole) Leuprolide acetate (for granulosa cell tumors) Tamoxifen</p>	Bevacizumab (single agent)	Palliative localized radiation therapy

*Available online, in these guidelines, at NCCN.org.

[†]High-dose chemotherapy regimens vary among institutions. Some patients are potentially curable with stem cell transplantation. Patients with potentially curable recurrent germ cell disease should be referred to a tertiary care institution for stem-cell transplant consultation and potentially curative therapy.

[‡]See WHO Histologic Classification (OV-D*).

OV-B
6 of 7

Text cont. from page 1135.

ments. Exceptions to the rule were discussed among the panel members while developing these NCCN Guidelines.

Epidemiology

Epithelial ovarian cancer is the leading cause of death from gynecologic cancer in the United States and is the country's fifth most common cause of cancer mortality in women.⁶ However, LCOHs are rare cancers that present at an earlier age than epithelial ovarian cancer. The risk for borderline epithelial tumors may be increased after ovarian stimulation for in vitro fertilization.^{7,8}

Family history (primarily patients having ≥ 2 first-degree relatives with ovarian cancer)—including linkage with *BRCA1* and *BRCA2* genotypes (hereditary breast and ovarian cancer syndrome) or families affected by Lynch syndrome (hereditary nonpolyposis colorectal cancer syndrome)—is associated with early-onset disease.^{9–21} Lynch syndrome is associated with risk for endometrioid carcinomas, clear cell carcinomas, and papillary serous carcinomas.^{9–11} In women at high risk (with either *BRCA1* or *BRCA2* mutations), prophylactic bilateral salpingo-oophorectomy (BSO) is associated with a reduced risk for breast, ovarian, fallopian tube, and primary peritoneal cancers.^{22–27}

Occult ovarian cancer is sometimes found after prophylactic salpingo-oophorectomy, thus emphasizing the need for careful pathologic review of the ovaries and tubes (see “Risk-Reducing Salpingo-Oophorectomy [RRSO] Protocol” in the complete version of these guidelines, available at NCCN.org [OV-A]).^{28–31} The risks of surgery include injury to the bowel, bladder, ureter, and vessels.³²

Screening

Because of the location of the ovaries and the biology of most epithelial cancers, it has been difficult to diagnose ovarian cancer at an earlier, more curable stage. However, evaluations of patients with newly diagnosed ovarian cancer have resulted in consensus guidelines for ovarian cancer symptoms, which may enable earlier identification of patients possibly at an increased risk of having early-stage ovarian cancer.^{33,34} Symptoms suggestive of ovarian cancer include bloating, pelvic or abdominal pain, difficulty eating or feeling full quickly, and urinary symptoms (urgency or frequency), especially if these symptoms are new and frequent (>12 d/mo).³³ Physicians evaluating women

with this constellation of symptoms must be cognizant of the possibility that ovarian pathology may be causing these symptoms.³⁵ However, some evidence suggests that the screening test using these symptoms is not as sensitive or specific as necessary, especially in those with early-stage disease.^{32,36–38}

Randomized data do not yet support routine screening for ovarian cancer in the general population, and routine screening is not currently recommended by any professional society.^{32,35,39–46} Some physicians follow-up women with high-risk factors (eg, *BRCA* mutations, family history) using cancer antigen 125 (CA 125) monitoring and endovaginal ultrasound³⁹; however, prospective validation of these tests remains elusive.

Staging

The NCCN Guidelines for Ovarian Cancer reflect the importance of stage and grade of disease on prognosis and treatment recommendations. Ovarian cancer is classified primarily as stages I to IV using the FIGO (International Federation of Gynecology and Obstetrics) and AJCC staging systems (see Table 1 and other staging tables in the complete version of these guidelines, available at NCCN.org [ST-1–5]).⁴⁷ Serous ovarian cancer is now often referred to as either low grade (most grade 1 serous tumors) or high grade (most grade 2 or 3 serous tumors).^{48–53} Pathologists may use histologic grades 1, 2, or 3 for endometrioid carcinomas, mucinous carcinomas, and stage IC tumors.⁴⁸ Staging for the LCOHs is performed using the ovarian cancer staging system.⁴⁷

FIGO recently updated the staging for ovarian, fallopian tube, and peritoneal cancer; their new staging system has been approved by the AJCC (see “Staging” in the complete version of these guidelines [ST-1–5]).^{49,50} In the new staging guidelines, old stages IC, IIIA, and IV are now subdivided, and the old stage IIC has been eliminated. These changes will be included in the next edition of the AJCC Cancer Staging Manual (8th edition), which will be published in 2016 and will be effective for all cancer cases recorded on or after January 1, 2017. The 2016 protocol from the College of American Pathologists (CAP) for ovarian cancer includes the LCOHs.^{48,54}

Recommended Workup

The LCOH algorithms begin after surgery and histologic diagnosis of a suspicious pelvic mass (see LCOH-1;

page 1139). The recommended workup for the LCOHs is similar to the workup for epithelial ovarian cancer (see OV-1; page 1136). The NCCN Guidelines for Epithelial Ovarian Cancer begin with the management of an undiagnosed pelvic mass or a prior diagnosis of a malignant epithelial ovarian tumor. Many patients with this diagnosis come to NCCN Member Institutions after having had previous surgery. The NCCN Guidelines recommend symptom management and best supportive care for all patients; patients should be referred for palliative care assessment if appropriate (see the NCCN Guidelines for Palliative Care, available at NCCN.org).

Undiagnosed Pelvic Mass: The primary workup should include an ultrasound and/or abdominal/pelvic CT/MRI scan (after an abdominal/pelvic examination) and appropriate laboratory studies for a patient with a suspicious pelvic mass (detected on abdominal/pelvic examination) and/or ascites, abdominal distention, and/or symptoms (ie, bloating, pelvic or abdominal pain, difficulty eating or feeling full quickly, urinary symptoms) without other obvious sources of malignancy (see LCOH-1; page 1139).^{33,55–62} Tumor markers (including CA 125, inhibin, alpha fetoprotein [AFP], and beta-human chorionic gonadotropin [beta-hCG]) can be measured if clinically indicated to assess for LCOH and pregnancy (see “Less Common Ovarian Histopathologies,” page 1150, and LCOH-1, page 1139).^{63–65} For example, AFP levels should be considered to assess for germ cell tumors in women younger than 35 years with a pelvic mass.^{63–65} Ultrasound is typically used for initial evaluation; however, CT is useful to assess for metastases.⁵⁷ MRI may be useful for determining malignant potential if ultrasound is not reliable.^{61,62} CT/MRI imaging should be performed with contrast unless contraindicated. FDG-PET/CT scan may be useful for indeterminate lesions.^{66–68}

Most ovarian cancers, including the LCOHs, are diagnosed after pathologic analysis of a biopsy or surgical specimen, which may occur preoperatively, intraoperatively, or postoperatively. If possible, fine-needle aspiration (FNA) should be avoided for diagnosing ovarian cancer in patients with presumed early-stage disease to prevent rupturing the cyst and spilling malignant cells into the peritoneal cavity; however, FNA may be necessary in patients with bulky disease who are not surgical candidates.^{69,70} Other cancers that should be ruled out include

bowel, uterine, and pancreatic cancers and lymphoma.^{71,72} Benign ovarian and nonovarian conditions also need to be ruled out (eg, serous cystadenoma),⁷³ as do metastases to the ovaries (see “Mucinous Carcinomas,” page 1152).

It has been suggested that specific biomarkers (serum HE4 and CA 125) along with an algorithm (Risk of Ovarian Malignancy Algorithm [ROMA]) may be useful for determining whether a pelvic mass is malignant or benign.^{74,75} The FDA has approved the use of HE4 and CA 125 for estimating the risk for ovarian cancer in women with a pelvic mass, however, the NCCN Panel does not currently recommend the use of these biomarkers for determining the status of an undiagnosed pelvic mass.^{76–79} Although no direct evidence exists that chest radiography or CT is necessary, panel members felt that it should be part of the overall evaluation of a patient before surgical staging if clinically indicated. Gastrointestinal tract evaluation should be done for mucinous histology to determine if patients have metastases to the ovary or primary mucinous carcinoma of the ovary (see “Mucinous Carcinomas,” page 1152).⁸⁰

Prior Diagnosis of Malignancy: Patients are often referred to NCCN Member Institutions after a previous diagnosis of ovarian cancer through surgery or tissue biopsy (cytopathology). Often these patients have undergone cytoreductive surgery and comprehensive staging procedures. However, referral may occur after incomplete surgery and/or staging; for example, the uterus and/or adnexa may still be intact (see OV-2; page 1137). The components of surgical staging are listed in the algorithm (see “Principles of Surgery” in the complete version of these guidelines, available at NCCN.org [OV-A]). Identical workup procedures are recommended for patients with undiagnosed or diagnosed pelvic masses at the time of referral. Tissue diagnosis of metastatic sites can be considered.

Histologic Subtypes

Epithelial ovarian cancer has 4 main histologic subtypes: serous, endometrioid, mucinous, and clear cell; however, most patients (about 70%) have serous histology.^{3,47,51,81,82} For the 2016 update, primary treatment recommendations for the LCOH subtypes—mucinous, clear cell, and grade 1 (low-grade) serous/endometrioid—may be different from the treatment recommendations for the high-grade serous/endometrioid subtypes (see OV-3 and LCOH-1;

pages 1138 and 1139, respectively).⁵¹ Recent molecular characterization of clear cell, mucinous, or grade 1 (low-grade) tumors suggests that mutations in these histologies are different from those in higher-grade tumors.^{83–85} Ovarian cancer can be divided into types 1 and 2 based on these molecular alterations. Data suggest that serous tumors can be categorized as either low grade (most grade 1 serous tumors) or high grade (most grade 2 or 3 serous tumors).^{49–53,86,87} High-grade endometrioid tumors are difficult to distinguish from high-grade serous tumors.⁵¹ Grade 1 (low-grade) serous tumors are relatively resistant to standard chemotherapy regimens.^{51,88} Pathology review at NCCN Member Institutions is recommended for all patients. The CAP protocol is a useful tool for pathology reports; it was recently revised for 2016.^{48,54} For the 2016 update, the complete histologic classification from the WHO was added to the NCCN Guidelines (see “WHO Histologic Classification” in the complete version of these guidelines, available at NCCN.org [OV-D]).¹ The WHO pathology manual is also a useful resource.^{1,89}

Primary Treatment

Primary treatment for presumed ovarian cancer consists of appropriate surgical staging and cytoreduction, followed in most (but not all) patients by systemic therapy.^{90–93} *Neoadjuvant therapy* refers to drugs, radiation, or other treatment that is given to reduce the tumor burden before cancer surgery. The therapeutic benefit of neoadjuvant chemotherapy followed by interval cytoreduction remains controversial for epithelial ovarian cancer.^{94–101} Neoadjuvant chemotherapy may be considered (category 1) for patients with bulky stage III to IV disease who are not surgical candidates; however, a gynecologic oncologist should make this assessment before neoadjuvant chemotherapy is administered.^{102–108} Because many patients with LCOH are diagnosed after surgery and/or present with early-stage disease, neoadjuvant chemotherapy does not apply for the LCOHs.

Initial surgery should be a comprehensive staging laparotomy, including a total abdominal hysterectomy and BSO (see LCOH-1 and “Principles of Surgery” in the complete version of these guidelines [OV-A]).^{109–111} Based on published improved outcomes, it is recommended (category 1) that a gynecologic oncologist perform the primary surgery.^{112–114} For a young patient who wishes to maintain fertility,

a unilateral salpingo-oophorectomy (USO; preserving the uterus and contralateral ovary) may be adequate for select unilateral stage I tumors (stage 1A and 1C, but not stage 1B) and/or low-risk ovarian tumors (ie, early-stage, grade 1 tumors; borderline tumors; see LCOH-6, LCOH-9, LCOH-10; pages 1141, 1143, and 1144, respectively).^{115–120} Comprehensive staging may not be necessary for select patients, such as those with borderline epithelial tumors (see LCOH-6, page 1141).

Most patients have a hysterectomy with BSO, omentectomy, and lymphadenectomy of suspicious/enlarged nodes. Cytoreductive surgery is the initial treatment recommendation for patients with clinical stage II, III, or IV disease (see OV-1, page 1136, and “Principles of Surgery” in the complete version of these guidelines, available at NCCN.org [OV-A]).^{92,93,114,117,121–124} These procedures also apply to many of the LCOHs. Surgical cytoreduction is optimal if the residual tumor nodules are less than 1 cm in maximum diameter or thickness^{97,111,117,125,126}; extensive resection of upper abdominal ovarian metastases is recommended for patients who can tolerate this surgery.^{123,127} In select patients, minimally invasive procedures may be used to assess whether cytoreductive surgery is feasible and to achieve cytoreduction.^{110,128–131} For young patients who will abruptly enter menopause after surgery, various supportive care measures may be used to help decrease hot flashes and other symptoms.^{132–134} Procedures that may be considered for optimal surgical cytoreduction (in all stages) include radical pelvic dissection, bowel resection and/or appendectomy, diaphragm or other peritoneal surface stripping, splenectomy, partial hepatectomy, partial gastrectomy, or partial cystectomy and/or ureteroneocystostomy, cholecystectomy, and/or distal pancreatectomy.^{123,127,135} For patients with incomplete previous surgery and/or staging, treatment recommendations are outlined in the algorithm (see OV-2 and LCOH-7; pages 1137 and 1142, respectively).

Less Common Ovarian Histopathologies

For the 2016 update, the NCCN Panel extensively revised the section on LCOHs. As previously mentioned, new algorithms for clear cell carcinoma, mucinous carcinoma, and grade 1 (low-grade) serous/endometrioid epithelial carcinoma were added to

the NCCN Guidelines (see LCOH-1; page 1139). Previously, these rare histologies had been included in the algorithm for epithelial ovarian cancer. Panel members believe there is value in identifying potential pathways for these rare histologies because of emerging therapeutics for specific histologies. However, there are limited data for these rare histologies because of their infrequency, and it will be difficult to acquire prospective data. Therefore, individualized treatment may be the best treatment for patients with these rare histologies.

The complete histologic classification for ovarian cancer from the WHO was added to the NCCN Guidelines for 2016, which includes the different types of LCOH (see “WHO Histologic Classification” in the complete version of these guidelines, available at NCCN.org [OV-D]).¹ Other LCOHs include carcinosarcomas (MMMTs), borderline epithelial tumors, malignant sex cord-stromal tumors, and malignant germ cell tumors; all of these rare histologies had previously been included in the LCOH guidelines and were also revised for 2016.

Recommended Workup

Patients may obtain consultation at an NCCN Member Institution for recommendations and treatment of an undiagnosed pelvic mass, or for management of a previously biopsied malignant ovarian tumor. Many such patients come to NCCN Member Institutions after having had previous surgery at other institutions. Patients having a histologically undiagnosed pelvic mass should undergo evaluation and staging as described in the algorithm for epithelial ovarian cancer (see OV-1; page 1136). The diagnosis of LCOH is often not made until after surgery for a suspicious pelvic mass (see OV-3; page 1138). Therefore, the workup for LCOH is the same as for other types of ovarian cancer except that tumor markers are measured and other testing is done to determine the specific histopathology (see OV-1; page 1136). Tumor markers may include CA 125, inhibin, beta-hCG, AFP, and carcinoembryonic antigen (CEA). Women younger than 35 years with a pelvic mass should have AFP levels measured to assess for germ cell tumors and to rule out pregnancy.^{63–65} A gastrointestinal tract evaluation is recommended for mucinous histology to determine whether an occult gastrointestinal primary has metastasized to the ovaries.⁸⁰ An intraoperative frozen section evaluation is recom-

mended for women who would like to maintain their fertility (see “Surgery,” subsequent section).

Surgery

In contrast to high-grade serous epithelial ovarian cancer or MMMTs, many patients with other LCOHs present at an early stage. Some of the tumors may be confined to one ovary. Thus, some of the younger patients are candidates for fertility-sparing surgery, which may be performed laparoscopically (see “Principles of Surgery” in the complete version of these guidelines, available at NCCN.org [OV-A]).^{116,117,120,136–140} Fertility-sparing surgery may be performed (if technically feasible) if the intraoperative frozen section results are positive for malignant germ cell tumors, borderline epithelial tumors, unilateral stage I epithelial ovarian tumors, or unilateral stage I sex cord-stromal tumors.^{116,117,120,137–140} Patients who do not desire fertility preservation; those who have a clinical stage IB, II, III, or IV epithelial ovarian cancer; those with clinical stage IB, II, III, or IV sex cord-stromal tumor; or those with MMMT should undergo comprehensive surgical staging as per these guidelines (see “Principles of Surgery” in the complete version of these guidelines [OV-A]).

Patients may have been referred to an NCCN Member Institution after receiving a diagnosis of an LCOH tumor. The recommended initial surgical option depends on the specific histologic diagnosis. Often, patients have been comprehensively staged and have undergone cytoreductive surgery. However, in some instances, they are referred after having had incomplete staging (ie, uterus and/or adnexa intact, omentum not removed, surgical stage not documented) (see OV-2; page 1137).

Clear Cell Carcinoma

For the 2016 update, the NCCN Ovarian Cancer Panel added a new algorithm for patients with clear cell carcinoma of the ovary (see LCOH-3; page 1140).¹ Clear cell carcinomas are considered high-grade tumors; they are more common than the other LCOHs.¹⁴¹ Most clear cell carcinomas are negative for WT1 and estrogen receptors.¹⁴¹ Because patients are typically diagnosed with clear cell carcinoma after pathologic analysis of a surgical specimen, the workup for suspicious or palpable pelvic masses is performed before surgery, as described in the algorithm (see OV-1; page 1136).

Primary treatment for these patients includes completion surgery with comprehensive staging

followed by postoperative therapy (see LCOH-3; page 1140).¹⁴² Lymphadenectomy has been shown to improve survival.¹⁴³ The staging system for ovarian and primary peritoneal cancer is also used for clear cell carcinomas (see Table 1 in the complete version of these guidelines, available at NCCN.org [ST-1]). Lynch syndrome is associated with risk for clear cell carcinomas, endometrioid carcinomas, and papillary serous carcinomas.⁹⁻¹¹ For patients with stage IA to IC disease, recommended postoperative treatment is either intravenous paclitaxel/carboplatin or docetaxel/carboplatin.¹⁴³ Fertility-sparing surgery and/or observation/monitoring are options for patients with unilateral clear cell borderline tumors (see LCOH-6; page 1141). For patients with stage II to IV clear cell carcinoma, postoperative treatment is similar to that recommended for epithelial ovarian cancer. Patients with advanced clear cell carcinoma have a poor prognosis.^{142,143}

Mucinous Carcinomas

For the 2016 update, the NCCN Panel added a new algorithm for mucinous carcinoma of the ovary (see LCOH-4; page 1140).¹ Patients with mucinous carcinoma of the ovary are often diagnosed with early-stage disease and have a good prognosis; the 5-year disease-free survival is approximately 80% to 90%.^{80,144} Mucinous tumors are unusual because they may be very large cystic masses that may fill the entire abdominal pelvic cavity; this presentation often suggests mucinous histology. Patients with mucinous tumors typically present at a younger age (20–40 years) than women with high-grade serous ovarian cancer.

Patients are typically diagnosed with mucinous carcinoma after surgery for a suspicious pelvic mass (see OV-3; page 1138). Therefore, the initial workup is the same as for other types of ovarian cancer (see OV-1; page 1136). Primary treatment for these patients includes completion surgery with comprehensive staging followed by postoperative therapy or observation (see LCOH-4; page 1140).⁸⁰ An appendectomy is also recommended at primary surgery in patients with suspected or confirmed mucinous ovarian tumors. The staging system for ovarian and primary peritoneal cancer is also used for mucinous carcinomas (see Table 1 in the complete version of these guidelines [ST-1]).

The additional workup includes a gastrointestinal tract evaluation and CEA level for patients with

mucinous histology to determine whether patients have either an occult gastrointestinal primary that has metastasized to the ovaries or primary mucinous carcinoma of the ovaries (see OV-1; page 1136).⁸⁰ Metastases to the ovaries are more common, and primary mucinous tumors of the ovaries are uncommon; it is difficult to distinguish between metastatic adenocarcinomas to the ovaries and primary mucinous carcinomas.¹⁴⁵⁻¹⁴⁷ PAX8 immunostaining may be useful.¹⁴⁵

Postoperative observation and monitoring are recommended for patients with stage IA or IB mucinous tumors, because most of these tumors are benign or borderline.^{80,141} Fertility-sparing surgery is an option for patients with a unilateral mucinous borderline tumor (see LCOH-6; page 1141). For patients with stage IC mucinous carcinomas, postoperative options include (1) observation; (2) intravenous carboplatin with either paclitaxel or docetaxel; (3) 5-FU/leucovorin/oxaliplatin (gastrointestinal regimen); or (4) capecitabine/oxaliplatin (gastrointestinal regimen).⁸⁰ Some clinicians feel the gastrointestinal regimens are appropriate, because mucinous carcinomas of the ovary are similar to gastrointestinal tumors.¹⁴⁸ For patients with stages II to IV mucinous carcinomas, postoperative options include (1) chemotherapy using the regimens for epithelial ovarian cancer; (2) 5-FU/leucovorin/oxaliplatin (gastrointestinal regimen); or (3) capecitabine/oxaliplatin (gastrointestinal regimen).

Grade 1 (Low-Grade) Serous/Endometrioid Epithelial Carcinomas

For the 2016 update, the NCCN Panel added a new algorithm for grade 1 (low-grade) endometrioid serous/endometrioid epithelial carcinomas (see LCOH-5; page 1141).¹ Endometrioid carcinomas may be associated with endometriosis.^{149,150} Endometrioid adenocarcinomas are usually positive for cytokeratin 7 (CK7), PAX8, CA 125, and estrogen receptors; metastatic colorectal adenocarcinomas are usually positive for CK20, CEA, and CDX2.¹⁴¹ Endometrioid tumors are also very similar in appearance to sex cord-stromal tumors.¹⁴¹ Lynch syndrome is associated with risk for endometrioid carcinomas, clear cell carcinomas, and serous carcinomas.⁹⁻¹¹

Patients with grade 1 (low-grade) serous carcinomas may present with more advanced disease, but they often have more indolent disease and present at a younger age than those with high-grade serous carci-

nomas.^{88,151} Serous carcinomas are usually positive for WT1 and estrogen receptors.¹⁴¹ Primary treatment for these patients includes completion surgery with comprehensive staging followed by postoperative therapy or observation; patients are typically diagnosed after surgery (see OV-3; page 1138).⁸⁸ Fertility-sparing surgery is an option for patients with serous and endometrioid borderline tumors (see LCOH-6; page 1141).¹ Some clinicians feel that neoadjuvant therapy should not be recommended for patients with grade 1 (low-grade) serous carcinomas, because they often respond poorly to chemotherapy.⁸⁸

Postoperative observation and monitoring are recommended for patients with stage IA or IB disease. For patients with stage IC to II disease, postoperative options include (1) intravenous carboplatin with either paclitaxel or docetaxel; (2) observation (category 2B); or (3) hormone therapy including anastrozole, letrozole, leuprolide, or tamoxifen (category 2B for all hormone therapy). Postoperative options for patients with stage III to IV disease include (1) first-line chemotherapy regimens used for epithelial ovarian cancer; or (2) hormone therapy (category 2B) as previously described (see OV-B, 3 of 7; page 1146).^{88,152–154}

Malignant Germ Cell Tumors

These malignant tumors include dysgerminomas, immature teratomas, embryonal tumors, and endodermal sinus (yolk sac) tumors (see LCOH-10; page 1144).¹ They mainly occur in girls, adolescents, and younger women who are often diagnosed with stage I disease; the median age at diagnosis is 16 to 20 years.^{155,156} Germ cell tumors are the predominant ovarian tumor in this age group.¹⁵⁷ The recommended workup may include pulmonary function studies if bleomycin is being considered (see OV-B, 4 of 7; page 1146).^{63,158} In young women (<35 years of age) with a pelvic mass, AFP levels can indicate the presence of germ cell tumors.^{63–65} Gonadal dysgenesis is a risk factor for germ cell tumors.¹⁵⁷ Women with malignant germ cell tumors have an excellent prognosis. After appropriate treatment, the 5-year survival rate is more than 85%.^{155,159,160}

Treatment: Completion surgery with comprehensive staging is recommended as initial surgery for patients who do not desire fertility preservation (see LCOH-10; page 1144).¹⁵⁷ The staging system for ovarian and primary peritoneal cancer is also used for malignant

germ cell tumors (see Table 1 in the complete version of these guidelines, available at NCCN.org [ST-1]). After comprehensive surgical staging, observation with monitoring is recommended for patients with stage I dysgerminoma or stage I, grade 1 immature teratoma.¹⁶¹ Surgery for children or adolescents may differ from that for adult women (see “Principles of Surgery” in the complete version of these guidelines [OV-A]). In children or adolescents with early-stage germ cell tumors, comprehensive staging may be omitted.^{162,163} If these patients have had incomplete surgical staging, recommended options depend on the type of tumor, the results of imaging and tumor marker testing (eg, AFP, beta-hCG), the age of the patient, and whether the patient desires fertility preservation (see LCOH-10; page 1144). Fertility-sparing surgery should be considered for those desiring fertility preservation, regardless of stage (see LCOH-10; page 1144).^{120,156,160,164–166} Patients who chose fertility-sparing surgery should be monitored by ultrasound examinations if necessary; completion surgery (category 2B) should be considered after childbearing is finished.

After surgery, observation with surveillance is the recommended option for patients with stage I dysgerminoma or stage I, grade 1 immature teratoma based on European and pediatric reports.^{167–170} Observation or chemotherapy may be considered for children or adolescents with select stage IA or IB tumors (see LCOH-11; page 1145).^{156,167,169,171–173} For patients with stage II to IV malignant dysgerminomas or immature teratomas, postoperative chemotherapy is recommended (see OV-B, 4 of 7; page 1146).

Postoperative chemotherapy for 3 to 4 cycles with bleomycin/etoposide/cisplatin (BEP) (category 2B for 3 vs 4 cycles) is recommended for (1) any stage embryonal tumors or endodermal sinus tumors; (2) stages II to V dysgerminoma; or (3) stage I, grade 2 to 3, or stage II to IV immature teratoma (see OV-B, 4 of 7; page 1146).^{158,174–176} If considering the use of bleomycin, pulmonary function tests are recommended.^{158,159} The 4-cycle BEP regimen is recommended (category 2A) as the standard regimen. Although most clinicians avoid a 3-week BEP regimen, some feel that a 3-week BEP regimen (3 cycles) may be useful in patients with low-risk or stage 1 disease, although this is a category 2B recommendation; the Memorial Sloan Kettering Cancer Center criteria can be used to identify tumors that

are low risk.^{167,177–184} In select patients with stage IB to III dysgerminoma for whom minimizing toxicity is critical, 3 courses of etoposide/carboplatin can be used (carboplatin, 400 mg/m² [area under the curve, ≈5–6] on day 1 plus etoposide, 120 mg/m² on days 1–3 every 4 weeks for 3 courses).¹⁸⁵ Dose reductions or delays are not recommended even in the setting of neutropenia.

Surveillance recommendations for germ cell tumors are described in the algorithm (see “Surveillance for Malignant Germ Cell and Sex Cord-Stromal Tumors” in the complete version of these guidelines, available at NCCN.org [LCOH-12]).¹⁸⁶ Patients experiencing a complete clinical response after chemotherapy should be observed clinically every 2 to 4 months with AFP and beta-hCG levels (if initially elevated) for 2 years. For those with abnormal markers and definitive recurrent disease, options (category 2B) include (1) high-dose chemotherapy¹⁸⁷ or (2) consider additional chemotherapy (see OV-B, 6 of 7; page 1147). Referral of these patients to a tertiary care center for stem cell transplant consultation and potentially curative therapy is strongly recommended. Several case reports suggest that patients who have received chemotherapy for germ cell tumors may later present with growing teratoma syndrome.^{188–191}

Residual or Recurrent Disease: For patients having radiographic evidence of residual tumor (after surgery and chemotherapy) but with normal AFP and beta-hCG, consider surgical resection of the tumor; observation with monitoring is also an option. Clinical judgment should be used regarding the frequency of imaging.¹⁹² Further options depend on which findings are present: residual malignancy, benign teratoma, or necrotic tissue (see LCOH-11; page 1145). For patients with definitive residual disease and with persistently elevated AFP and/or beta-hCG after first-line chemotherapy, recommendations include paclitaxel/ifosfamide/cisplatin (TIP)¹⁹³ or high-dose chemotherapy. Referral to a tertiary care center for potentially curative treatment is strongly recommended.¹⁹⁴ There are small series but no major trials in adult patients.

Patients with recurrent or residual malignancy after multiple chemotherapeutic regimens may be treated with a recurrence modality, including TIP, vincristine/dactinomycin/cyclophosphamide (VAC), vinblastine/ifosfamide/cisplatin (VeIP),

etoposide/ifosfamide/cisplatin (VIP), cisplatin/etoposide, docetaxel/carboplatin, paclitaxel/carboplatin, paclitaxel/gemcitabine, paclitaxel/ifosfamide, docetaxel, paclitaxel, high-dose chemotherapy, radiotherapy, or supportive care only (see OV-B, 6 of 7 page 1147).^{180,194–198} Most of the combination chemotherapy regimens are recommended as palliative options for patients with recurrent or residual disease who have no curative options. These recurrence regimens (see OV-B, 6 of 7 page 1147) are not generalizable for all of the uncommon histology tumors; therefore, patients should be referred to tertiary care institutions for treatment.

Malignant Sex Cord-Stromal Tumors

Malignant sex cord-stromal tumors are rare and include granulosa cell tumors (most common) and SertoliLeydig cell tumors; they are typically associated with a good prognosis.^{199,200} Most patients with granulosa tumors present with early-stage disease; the disease is typically indolent.²⁰¹ For the 2016 update, the complete histologic classification for ovarian cancer from the WHO was added to the NCCN Guidelines, which includes the different types of sex cord-stromal tumors and whether they are benign or malignant (see “WHO Histologic Classification” in the complete version of these guidelines [OV-D]).¹ The staging system for ovarian and primary peritoneal cancer is also used for sex cord-stromal tumors (see Table 1 in the complete version of these guidelines [ST-1]).

Patients with stage IA or IC sex cord-stromal tumors desiring to preserve their fertility should be treated with fertility-sparing surgery (see LCOH-9; page 1143).^{201–204} Although complete staging is recommended for all other patients, lymphadenectomy may be omitted for patients with stage IA or IC tumors.²⁰⁵ For patients who choose fertility-sparing surgery, completion surgery (category 2B) should be considered after childbearing is finished. Postoperative options in the NCCN Guidelines have category 2B recommendations (see LCOH-9; page 1143).²⁰² For patients with high-risk stage I tumors (tumor rupture, stage 1C, poorly differentiated tumor, and tumor size >10–15 cm²⁰⁶), postoperative recommendations (all are category 2B) include observation or consideration of platinum-based chemotherapy (see LCOH-9 and OV-B, 4 of 7; pages 1143 and 1146, respectively).²⁰⁷ Those with surgical findings of low-risk stage I tumor (ie, without high-risk features)

should be observed (see “Surveillance for Malignant Germ Cell and Sex Cord-Stromal Tumors” in the complete version of these guidelines, available at NCCN.org [LCOH-12]). For patients with granulosa cell tumors who are undergoing observation, inhibin levels can be followed if they were initially elevated (category 2B). For patients with stage II to IV tumors, recommended options (all are category 2B) include RT for limited disease or platinum-based chemotherapy (BEP or paclitaxel/carboplatin regimens are preferred) (see LCOH-9 and OV-B, 4 of 7; pages 1143 and 1146, respectively).^{208–211}

Surveillance recommendations for malignant sex cord-stromal tumors are provided in the algorithm, which are based on the Society of Gynecologic Oncology recommendations (see “Surveillance for Malignant Germ Cell and Sex Cord-Stromal Tumors” in the complete version of these guidelines [LCOH-12]).¹⁸⁶ Prolonged surveillance is recommended for granulosa cell tumors, because they can recur years later (eg, 30 years).^{165,199,200,212} For patients with stage II to IV tumors who subsequently experience a clinical relapse, options include a clinical trial or recurrence therapy (see LCOH-9 and OV-B, 6 of 7; pages 1143 and 1147, respectively).^{200,212–215} Cytotoxic recurrence therapy includes docetaxel, paclitaxel, paclitaxel/ifosfamide, paclitaxel/carboplatin, and VAC. Hormone recurrence therapy includes aromatase inhibitors, leuprolide, and tamoxifen. Note that single-agent bevacizumab or leuprolide is an option for patients with recurrent granulosa cell tumors.^{215,216} Secondary cytoreductive surgery may also be considered. Palliative localized RT may also be useful.

Carcinosarcomas (MMMTs)

MMMTs are rare tumors with a poor prognosis; they are the most aggressive tumors in the algorithm (see LCOH-2; page 1139).^{217–220} Most pathologists now consider MMMTs to be a variant of poor-risk, poorly differentiated epithelial ovarian cancer (metaplastic carcinoma).²²¹ Patients with MMMTs are not candidates for fertility-sparing surgery regardless of age. The staging system for ovarian and primary peritoneal cancer is also used for MMMTs (see Table 1 in the complete version of these guidelines [ST-1]).²¹⁹

Optimal surgical debulking is recommended for patients with MMMTs (see “Principles of Surgery” in the complete version of these guidelines [OV-

A]).^{219,222–224} After complete surgical staging, several postoperative chemotherapy regimens are recommended for patients with stage I to IV MMMT. Patients with stage I to IV MMMT may be treated as per epithelial ovarian cancer (see OV-3; page 1138).^{221,225–230} The intraperitoneal chemotherapy regimen described for ovarian cancer can be used for select patients with MMMT. For the 2016 update, the NCCN Panel also added 3 new postoperative chemotherapy options for patients with stage I to IV MMMT: cisplatin/ifosfamide (category 2A), carboplatin/ifosfamide (category 2A), and paclitaxel/ifosfamide (category 2B).^{217,221,225,231} After treatment, the surveillance and follow-up recommendations for epithelial ovarian cancer are also used for MMMTs.

Borderline Epithelial Tumors (Low Malignant Potential Tumors)

Diagnosis: The terms for borderline epithelial tumors (also known as *low malignant potential tumors* or *atypical proliferative tumors*) have changed over the years.¹⁴¹ The 2016 CAP cancer protocol for ovarian cancer uses “borderline” and does not use “low malignant potential.”⁴⁸ Borderline epithelial tumors are typically serous or mucinous; other histologic subtypes can also occur (see “WHO Histologic Classification” in the complete version of these guidelines [OV-D]).^{1,136} A borderline tumor is a primary epithelial lesion with cytologic characteristics suggesting malignancy but without frank invasion and with a clinically indolent course and good prognosis.^{232,233} The 5-year survival rate exceeds 80%.²³⁴ In contrast to patients with frankly invasive ovarian carcinoma, women with borderline epithelial tumors tend to be younger, are often diagnosed with stage I disease, and are candidates for fertility-sparing surgery.^{235,236}

Borderline epithelial tumors are rare tumors and are managed differently from high-grade carcinomas (see LCOH-6; page 1141).^{136,237} The characteristic pathologic hallmark of typical epithelial ovarian cancer is the identification of peritoneal implants, which microscopically and/or macroscopically invade the peritoneum. A borderline epithelial tumor has the visual appearance of peritoneal carcinomatosis. However, microscopic evaluation fails to reveal evidence of frank invasion by the tumor nodules, although rarely invasive implants (which continue to be consistent with the diagnosis of borderline epithelial lesions) can be identified microscopically by

the pathologist.

Treatment: Surgery is the primary treatment for borderline epithelial tumors, including standard ovarian cancer debulking surgery or fertility-sparing surgery, depending on the surgical evaluation and other factors as discussed in the subsequent paragraphs (see “Principles of Surgery” in the complete version of these guidelines, available at NCCN.org [OV-A]).²³⁸ Treatment guidelines for borderline epithelial tumors depend on the histologic and clinical characteristics, the age of the patient,²³⁶ and whether invasive implants are present. Patients should be evaluated by a gynecologic oncologist. At NCCN Member Institutions, patients may be initially evaluated with an undiagnosed pelvic mass or with an established diagnosis of borderline epithelial tumor. NCCN panel members are less likely to recommend aggressive treatment after surgery; observation is one of several possible approaches (see LCOH-6; page 1141).^{136,239} Although the staging system for epithelial ovarian cancer is used for borderline epithelial tumors, the NCCN Guidelines use the presence or absence of invasive implants to determine the need for postoperative therapy (see LCOH-6; page 1141).

Patients with a borderline epithelial tumor who desire to maintain their fertility may undergo surgery limited to a USO (preserving the uterus, contralateral ovary, and contralateral fallopian tube) with resection of residual disease.^{116,117,240} If the patient does not desire fertility-sparing surgery, standard ovarian cancer debulking surgery and resection of residual disease are recommended. Data do not show increased survival with lymphadenectomy and omentectomy for borderline epithelial tumor, although upstaging does occur.^{241,242} For the 2016 update, the NCCN Panel deleted the recommendation for comprehensive surgical staging (category 2B); lymph node evaluation may be considered on a case-by-case basis.

For patients with a known borderline epithelial tumor who had incomplete previous surgery and/or were incompletely staged at the time of their initial laparotomy, recommendations depend on whether invasive implants are present and whether fertility preservation is desired (see LCOH-7; page 1142). Patients who want to preserve their fertility should undergo fertility-sparing surgery and resection of residual disease. Some clinicians feel that the appearance of invasive implants on the peritoneal surfaces in patients with borderline epithelial tumors portends

a less favorable prognosis; therefore, postoperative chemotherapy with the same regimens used for grade 1 (low-grade) serous epithelial ovarian cancer can be considered for these patients (see LCOH-5 and LCOH-7; pages 1141 and 1142, respectively).^{235,236,243} For the 2016 update, the NCCN Panel revised this recommendation for postoperative chemotherapy to category 2A (from category 2B); intravenous carboplatin with either docetaxel or paclitaxel is recommended. However, the benefit of chemotherapy, either intraperitoneal or intravenous, is controversial in patients with borderline epithelial tumors. The significance of invasive implants remains under investigation.^{136,244} The benefit of postoperative chemotherapy has not been demonstrated for patients who have no microscopically demonstrable invasive implants.²⁴⁵ Although observation is an option for all patients, it is a category 3 recommendation for patients with invasive implants and a category 2B recommendation for those without invasive implants; these recommendations were revised for the 2016 update (see LCOH-7; page 1142).

Follow-up: Treatment recommendations after surgery depend on the presence or absence of invasive implants. The initial therapeutic approach for patients having invasive implants may include treatment with the same chemotherapeutic regimens used for grade 1 (low-grade) serous epithelial ovarian cancer, or observation (category 3) (see LCOH-6; page 1141).²⁴⁴ Patients with no invasive implants may be observed (category 2B) and monitored (see LCOH-8; page 1142).^{235,246} Patients who chose fertility-sparing surgery should be monitored by ultrasound examinations if necessary. After childbearing is completed, completion surgery should be considered (category 2B).¹³⁶

Relapse: At the time of clinical relapse, surgical evaluation and debulking are recommended if appropriate. For the 2016 update, the NCCN Panel revised the algorithm by clarifying the recommendations for low-grade and high-grade disease. Patients who have low-grade invasive carcinoma or invasive implants from borderline epithelial tumors may be treated as per patients with grade 1 (low-grade) serous epithelial ovarian cancer; those with high-grade invasive carcinoma may be treated as per patients with epithelial ovarian cancer (see LCOH-5 and LCOH-8; pages 1141 and 1142, respectively). Observation is recommended for those with noninvasive disease.

References

- Kurman RJ, Carcangiu ML, Harrington CS, et al. WHO Classification of Tumours of Female Reproductive Organs, 4th ed. WHO/IARC Classification of Tumours. Vol. 6. Lyon: IARC Publications; 2014.
- Chan JK, Cheung MK, Husain A, et al. Patterns and progress in ovarian cancer over 14 years. *Obstet Gynecol* 2006;108:521–528.
- Prat J. New insights into ovarian cancer pathology. *Ann Oncol* 2012;23(Suppl 10):x111–117.
- Jelovac D, Armstrong DK. Recent progress in the diagnosis and treatment of ovarian cancer. *CA Cancer J Clin* 2011;61:183–203.
- Morgan RJ Jr, Copeland L, Gershenson D, et al. NCCN Ovarian Cancer Practice Guidelines. The National Comprehensive Cancer Network. Oncology (Williston Park) 1996;10:293–310.
- Siegel RL, Miller KD, Jemal A. Cancer statistics, 2016. *CA Cancer J Clin* 2016;66:7–30.
- van Leeuwen FE, Klip H, Mooij TM, et al. Risk of borderline and invasive ovarian tumours after ovarian stimulation for in vitro fertilization in a large Dutch cohort. *Hum Reprod* 2011;26:3456–3465.
- Pearce CL, Templeman C, Rossing MA, et al. Association between endometriosis and risk of histological subtypes of ovarian cancer: a pooled analysis of case-control studies. *Lancet Oncol* 2012;13:385–394.
- Nakonechny QB, Gilks CB. Ovarian cancer in hereditary cancer susceptibility syndromes. *Surg Pathol Clin* 2016;9:189–199.
- Chui MH, Ryan P, Radigan J, et al. The histomorphology of Lynch syndrome-associated ovarian carcinomas: toward a subtype-specific screening strategy. *Am J Surg Pathol* 2014;38:1173–1181.
- Lu KH, Daniels M. Endometrial and ovarian cancer in women with Lynch syndrome: update in screening and prevention. *Fam Cancer* 2013;12:273–277.
- Lancaster JM, Powell CB, Chen LM, et al. Society of Gynecologic Oncology statement on risk assessment for inherited gynecologic cancer predispositions. *Gynecol Oncol* 2015;136:3–7.
- Rebbeck TR, Mitra N, Wan F, et al. Association of type and location of BRCA1 and BRCA2 mutations with risk of breast and ovarian cancer. *JAMA* 2015;313:1347–1361.
- Daly MB, Axilbund JE, Buys S, et al. Genetic/familial high-risk assessment: breast and ovarian. *J Natl Compr Canc Netw* 2010;8:562–594.
- Walsh CS, Blum A, Walts A, et al. Lynch syndrome among gynecologic oncology patients meeting Bethesda guidelines for screening. *Gynecol Oncol* 2010;116:516–521.
- Lancaster JM, Powell CB, Kauff ND, et al. Society of Gynecologic Oncologists Education Committee statement on risk assessment for inherited gynecologic cancer predispositions. *Gynecol Oncol* 2007;107:159–162.
- Shulman LP. Hereditary breast and ovarian cancer (HBOC): clinical features and counseling for BRCA1 and BRCA2, Lynch syndrome, Cowden syndrome, and Li-Fraumeni syndrome. *Obstet Gynecol Clin North Am* 2010;37:109–133.
- Bulletins ACOG Committee on Practice Bulletins. Hereditary breast and ovarian cancer syndrome. *Gynecol Oncol* 2009;113:6–11.
- American College of Obstetricians and Gynecologists, ACOG Committee on Practice Bulletins—Gynecology, ACOG Committee on Genetics, et al. ACOG Practice Bulletin No. 103: Hereditary breast and ovarian cancer syndrome. *Obstet Gynecol* 2009;113:957–966.
- Zhang S, Royer R, Li S, et al. Frequencies of BRCA1 and BRCA2 mutations among 1,342 unselected patients with invasive ovarian cancer. *Gynecol Oncol* 2011;121:353–357.
- Liu G, Yang D, Sun Y, et al. Differing clinical impact of BRCA1 and BRCA2 mutations in serous ovarian cancer. *Pharmacogenomics* 2012;13:1523–1535.
- Marchetti C, De Felice F, Palaia I, et al. Risk-reducing salpingo-oophorectomy: a meta-analysis on impact on ovarian cancer risk and all cause mortality in BRCA 1 and BRCA 2 mutation carriers. *BMC Womens Health* 2014;14:150.
- Reitsma W, de Bock GH, Oosterwijk JC, et al. Support of the ‘fallopian tube hypothesis’ in a prospective series of risk-reducing salpingo-oophorectomy specimens. *Eur J Cancer* 2013;49:132–141.
- Domchek SM, Friebel TM, Singer CF, et al. Association of risk-reducing surgery in BRCA1 or BRCA2 mutation carriers with cancer risk and mortality. *JAMA* 2010;304:967–975.
- Finch A, Beiner M, Lubinski J, et al. Salpingo-oophorectomy and the risk of ovarian, fallopian tube, and peritoneal cancers in women with a BRCA1 or BRCA2 mutation. *JAMA* 2006;296:185–192.
- Rebbeck TR, Kauff ND, Domchek SM. Meta-analysis of risk reduction estimates associated with risk-reducing salpingo-oophorectomy in BRCA1 or BRCA2 mutation carriers. *J Natl Cancer Inst* 2009;101:80–87.
- Powell CB, Chen LM, McLennan J, et al. Risk-reducing salpingo-oophorectomy (RRSO) in BRCA mutation carriers: experience with a consecutive series of 111 patients using a standardized surgical-pathological protocol. *Int J Gynecol Cancer* 2011;21:846–851.
- Mingels MJ, van Ham MA, de Kievit IM, et al. Mullerian precursor lesions in serous ovarian cancer patients: using the SEE-Fim and SEE-End protocol. *Mod Pathol* 2014;27:1002–1013.
- Callahan MJ, Crum CP, Medeiros F, et al. Primary fallopian tube malignancies in BRCA-positive women undergoing surgery for ovarian cancer risk reduction. *J Clin Oncol* 2007;25:3985–3990.
- Sherman ME, Piedmonte M, Mai PL, et al. Pathologic findings at risk-reducing salpingo-oophorectomy: primary results from Gynecologic Oncology Group Trial GOG-0199. *J Clin Oncol* 2014;32:3275–3283.
- Domchek SM, Friebel TM, Garber JE, et al. Occult ovarian cancers identified at risk-reducing salpingo-oophorectomy in a prospective cohort of BRCA1/2 mutation carriers. *Breast Cancer Res Treat* 2010;124:195–203.
- Clarke-Pearson DL. Clinical practice. Screening for ovarian cancer. *N Engl J Med* 2009;361:170–177.
- Goff BA, Mandel LS, Drescher CW, et al. Development of an ovarian cancer symptom index: possibilities for earlier detection. *Cancer* 2007;109:221–227.
- Andersen MR, Goff BA, Lowe KA, et al. Combining a symptoms index with CA 125 to improve detection of ovarian cancer. *Cancer* 2008;113:484–489.
- American College of Obstetricians and Gynecologists Committee on Gynecologic Practice. Committee Opinion No. 477: the role of the obstetrician-gynecologist in the early detection of epithelial ovarian cancer. *Obstet Gynecol* 2011;117:742–746.
- Lim AW, Mesher D, Gentry-Maharaj A, et al. Predictive value of symptoms for ovarian cancer: comparison of symptoms reported by questionnaire, interview, and general practitioner notes. *J Natl Cancer Inst* 2012;104:114–124.
- Rossing MA, Wicklund KG, Cushing-Haugen KL, Weiss NS. Predictive value of symptoms for early detection of ovarian cancer. *J Natl Cancer Inst* 2010;102:222–229.
- Gilbert L, Basso O, Sampalis J, et al. Assessment of symptomatic women for early diagnosis of ovarian cancer: results from the prospective DoVE pilot project. *Lancet Oncol* 2012;13:285–291.
- Smith RA, Manassaram-Baptiste D, Brooks D, et al. Cancer screening in the United States, 2015: a review of current American cancer society guidelines and current issues in cancer screening. *CA Cancer J Clin* 2015;65:30–54.
- Nolen BM, Lokshin AE. Protein biomarkers of ovarian cancer: the forest and the trees. *Future Oncol* 2012;8:55–71.
- Buyss SS, Partridge E, Black A, et al. Effect of screening on ovarian cancer mortality: the Prostate, Lung, Colorectal and Ovarian (PLCO) Cancer Screening Randomized Controlled Trial. *JAMA* 2011;305:2295–2303.
- Hartge P. Designing early detection programs for ovarian cancer. *J Natl Cancer Inst* 2010;102:3–4.
- Moyer VA, U.S. Preventive Services Task Force. Screening for ovarian cancer: U.S. Preventive Services Task Force reaffirmation recommendation statement. *Ann Intern Med* 2012;157:900–904.
- Gentry-Maharaj A, Menon U. Screening for ovarian cancer in the general population. *Best Pract Res Clin Obstet Gynaecol* 2012;26:243–256.
- Schorge JO, Modesitt SC, Coleman RL, et al. SGO White Paper on ovarian cancer: etiology, screening and surveillance. *Gynecol Oncol* 2010;119:7–17.
- Brown DL, Andreotti RF, Lee SI, et al. ACR appropriateness criteria(c) ovarian cancer screening. *Ultrasound Q* 2010;26:219–223.
- Edge SB, Byrd DR, Compton CC, et al. AJCC Cancer Staging Manual, 7th ed. New York: Springer; 2010.
- Gilks B, Movahedi-Lankarani S, Baker PM, et al. Protocol for the examination of specimens from patients with carcinoma of the ovary or fallopian tube. Available at: <http://www.cap.org/ShowProperty?nodePath=/UCMCon/Contribution%20Folders/WebContent/pdf/cp-ovary-fallopian-16protocol-1000.pdf>. Accessed August 22, 2016.
- Zeppernick F, Meinhold-Heerlein I. The new FIGO staging system for ovarian, fallopian tube, and primary peritoneal cancer. *Arch Gynecol Obstet* 2014;290:839–842.

Ovarian Cancer, Version 1.2016

50. Prat J, FIGO Committee on Gynecologic Oncology. Staging classification for cancer of the ovary, fallopian tube, and peritoneum. *Int J Gynaecol Obstet* 2014;124:1–5.
51. McCluggage WG. Morphological subtypes of ovarian carcinoma: a review with emphasis on new developments and pathogenesis. *Pathology* 2011;43:420–432.
52. Malpica A, Deavers MT, Tornos C, et al. Interobserver and intraobserver variability of a two-tier system for grading ovarian serous carcinoma. *Am J Surg Pathol* 2007;31:1168–1174.
53. Malpica A, Deavers MT, Lu K, et al. Grading ovarian serous carcinoma using a two-tier system. *Am J Surg Pathol* 2004;28:496–504.
54. Movahedi-Lankarani S, Baker PM, Gilks B, Soslow RA. Protocol for the examination of specimens from patients with carcinoma of the ovary. Available at: <http://www.cap.org/ShowProperty?nodePath=/UCMCon/Contribution%20Folders/WebContent/pdf/ovary-15protocol-3201.pdf>. Accessed August 22, 2016.
55. Mitchell DG, Javitt MC, Glanc P, et al. ACR appropriateness criteria staging and follow-up of ovarian cancer. *J Am Coll Radiol* 2013;10:822–827.
56. Im SS, Gordon AN, Buttin BM, et al. Validation of referral guidelines for women with pelvic masses. *Obstet Gynecol* 2005;105:35–41.
57. American College of Obstetricians and Gynecologists. ACOG Practice Bulletin. Management of adnexal masses. *Obstet Gynecol* 2007;110:201–214.
58. Dearing AC, Aletti GD, McGree ME, et al. How relevant are ACOG and SGO guidelines for referral of adnexal mass? *Obstet Gynecol* 2007;110:841–848.
59. Timmerman D, Testa AC, Bourne T, et al. Simple ultrasound-based rules for the diagnosis of ovarian cancer. *Ultrasound Obstet Gynecol* 2008;31:681–690.
60. Iyer VR, Lee SI. MRI, CT, and PET/CT for ovarian cancer detection and adnexal lesion characterization. *AJR Am J Roentgenol* 2010;194:311–321.
61. Harris RD, Javitt MC, Glanc P, et al. ACR Appropriateness Criteria(R) clinically suspected adnexal mass. *Ultrasound Q* 2013;29:79–86.
62. Dodge JE, Covens AL, Lacchetti C, et al. Management of a suspicious adnexal mass: a clinical practice guideline. *Curr Oncol* 2012;19:e244–257.
63. Gregory JJ Jr, Finlay JL. Alpha-fetoprotein and beta-human chorionic gonadotropin: their clinical significance as tumour markers. *Drugs* 1999;57:463–467.
64. Schneider DT, Calaminus G, Reinhard H, et al. Primary mediastinal germ cell tumors in children and adolescents: results of the German cooperative protocols MAKEI 83/86, 89, and 96. *J Clin Oncol* 2000;18:832–839.
65. Kawai M, Furuhashi Y, Kano T, et al. Alpha-fetoprotein in malignant germ cell tumors of the ovary. *Gynecol Oncol* 1990;39:160–166.
66. Yamamoto Y, Oguri H, Yamada R, et al. Preoperative evaluation of pelvic masses with combined 18F-fluorodeoxyglucose positron emission tomography and computed tomography. *Int J Gynaecol Obstet* 2008;102:124–127.
67. Castellucci P, Perrone AM, Picchio M, et al. Diagnostic accuracy of 18F-FDG PET/CT in characterizing ovarian lesions and staging ovarian cancer: correlation with transvaginal ultrasonography, computed tomography, and histology. *Nucl Med Commun* 2007;28:589–595.
68. Risum S, Hogdall C, Loft A, et al. The diagnostic value of PET/CT for primary ovarian cancer—a prospective study. *Gynecol Oncol* 2007;105:145–149.
69. Cannistra SA, Gershenson DM, Recht A. Ovarian cancer, fallopian tube carcinoma, and peritoneal carcinoma. In: DeVita VT Jr, Lawrence TS, Rosenberg SA, eds. *DeVita, Hellman, and Rosenberg's Cancer: Principles & Practice of Oncology*, 10th ed. Philadelphia, PA: Lippincott Williams & Wilkins; 2014:1075–1099.
70. Vergote I, De Brabanter J, Fyles A, et al. Prognostic importance of degree of differentiation and cyst rupture in stage I invasive epithelial ovarian carcinoma. *Lancet* 2001;357:176–182.
71. Young RH. From Krukenberg to today: the ever present problems posed by metastatic tumors in the ovary. Part II. *Adv Anat Pathol* 2007;14:149–177.
72. Lee KR, Young RH. The distinction between primary and metastatic mucinous carcinomas of the ovary: gross and histologic findings in 50 cases. *Am J Surg Pathol* 2003;27:281–292.
73. Kim KA, Park CM, Lee JH, et al. Benign ovarian tumors with solid and cystic components that mimic malignancy. *AJR Am J Roentgenol* 2004;182:1259–1265.
74. Romagnolo C, Leon AE, Fabricio AS, et al. HE4, CA125 and risk of ovarian malignancy algorithm (ROMA) as diagnostic tools for ovarian cancer in patients with a pelvic mass: an Italian multicenter study. *Gynecol Oncol* 2016;141:303–311.
75. Moore RG, Miller MC, Disilvestro P, et al. Evaluation of the diagnostic accuracy of the risk of ovarian malignancy algorithm in women with a pelvic mass. *Obstet Gynecol* 2011;118:280–288.
76. Yoshida A, Derchain SF, Pitta DR, et al. Comparing the Copenhagen Index (CPH-I) and Risk of Ovarian Malignancy Algorithm (ROMA): two equivalent ways to differentiate malignant from benign ovarian tumors before surgery? *Gynecol Oncol* 2016;140:481–485.
77. Jacob F, Meier M, Caduff R, et al. No benefit from combining HE4 and CA125 as ovarian tumor markers in a clinical setting. *Gynecol Oncol* 2011;121:487–491.
78. Molina R, Escudero JM, Auge JM, et al. HE4 a novel tumour marker for ovarian cancer: comparison with CA 125 and ROMA algorithm in patients with gynaecological diseases. *Tumour Biol* 2011;32:1087–1095.
79. Van Gorp T, Cadron I, Despierre E, et al. HE4 and CA125 as a diagnostic test in ovarian cancer: prospective validation of the Risk of Ovarian Malignancy Algorithm. *Br J Cancer* 2011;104:863–870.
80. Ledermann JA, Luvero D, Shafer A, et al. Gynecologic Cancer InterGroup (GCIg) consensus review for mucinous ovarian carcinoma. *Int J Gynecol Cancer* 2014;24:S14–19.
81. Kobel M, Kalloger SE, Huntsman DG, et al. Differences in tumor type in low-stage versus high-stage ovarian carcinomas. *Int J Gynecol Pathol* 2010;29:203–211.
82. Seidman JD, Horkayne-Szakaly I, Haiba M, et al. The histologic type and stage distribution of ovarian carcinomas of surface epithelial origin. *Int J Gynecol Pathol* 2004;23:41–44.
83. Rechsteiner M, Zimmermann AK, Wild PJ, et al. TP53 mutations are common in all subtypes of epithelial ovarian cancer and occur concomitantly with KRAS mutations in the mucinous type. *Exp Mol Pathol* 2013;95:235–241.
84. Vereczkey I, Serester O, Dobos J, et al. Molecular characterization of 103 ovarian serous and mucinous tumors. *Pathol Oncol Res* 2011;17:551–559.
85. Reade CJ, McVey RM, Tone AA, et al. The fallopian tube as the origin of high grade serous ovarian cancer: review of a paradigm shift. *J Obstet Gynaecol Can* 2014;36:133–140.
86. Vang R, Shih Ie M, Kurman RJ. Ovarian low-grade and high-grade serous carcinoma: pathogenesis, clinicopathologic and molecular biologic features, and diagnostic problems. *Adv Anat Pathol* 2009;16:267–282.
87. Meinhold-Heerlein I, Bauerschlag D, Hilpert F, et al. Molecular and prognostic distinction between serous ovarian carcinomas of varying grade and malignant potential. *Oncogene* 2005;24:1053–1065.
88. Gourley C, Farley J, Provencher DM, et al. Gynecologic Cancer InterGroup (GCIg) consensus review for ovarian and primary peritoneal low-grade serous carcinomas. *Int J Gynecol Cancer* 2014;24:S9–13.
89. Meinhold-Heerlein I, Fotopoulou C, Harter P, et al. The new WHO classification of ovarian, fallopian tube, and primary peritoneal cancer and its clinical implications. *Arch Gynecol Obstet* 2016;293:695–700.
90. Erickson BK, Martin JY, Shah MM, et al. Reasons for failure to deliver National Comprehensive Cancer Network (NCCN) adherent care in the treatment of epithelial ovarian cancer at an NCCN cancer center. *Gynecol Oncol* 2014;133:142–146.
91. Bristow RE, Chang J, Ziogas A, et al. Impact of National Cancer Institute Comprehensive Cancer Centers on ovarian cancer treatment and survival. *J Am Coll Surg* 2015;220:940–950.
92. Ledermann JA, Raja FA, Fotopoulou C, et al. Newly diagnosed and relapsed epithelial ovarian carcinoma: ESMO Clinical Practice Guidelines for diagnosis, treatment and follow-up. *Ann Oncol* 2013;24(Suppl 6):vi24–32.
93. Bristow RE, Chang J, Ziogas A, Anton-Culver H. Adherence to treatment guidelines for ovarian cancer as a measure of quality care. *Obstet Gynecol* 2013;121:1226–1234.
94. Leary A, Cowan R, Chi D, et al. Primary surgery or neoadjuvant chemotherapy in advanced ovarian cancer: the debate continues. *Am Soc Clin Oncol Educ Book* 2016;35:153–162.
95. Chi DS, Bristow RE, Armstrong DK, Karlan BY. Is the easier way ever the better way? *J Clin Oncol* 2011;29:4073–4075.
96. Vergote I, Trope CG, Amant F, et al. Neoadjuvant chemotherapy is the better treatment option in some patients with stage IIIc to IV ovarian cancer. *J Clin Oncol* 2011;29:4076–4078.
97. Schorge JO, Garrett LA, Goodman A. Cytoreductive surgery for advanced ovarian cancer: quo vadis? *Oncology (Williston Park)* 2011;25:928–934.
98. Rose PG, Nerenstone S, Brady MF, et al. Secondary surgical cytoreduction for advanced ovarian carcinoma. *N Engl J Med* 2004;351:2489–2497.

Ovarian Cancer, Version 1.2016

99. van der Burg ME, van Lent M, Buyse M, et al. The effect of debulking surgery after induction chemotherapy on the prognosis in advanced epithelial ovarian cancer. Gynecological Cancer Cooperative Group of the European Organization for Research and Treatment of Cancer. *N Engl J Med* 1995;332:629–634.
100. Colombo PE, Mourregot A, Fabbro M, et al. Aggressive surgical strategies in advanced ovarian cancer: a monocentric study of 203 stage IIIC and IV patients. *Eur J Surg Oncol* 2009;35:135–143.
101. Rauh-Hain JA, Rodriguez N, Growdon WB, et al. Primary debulking surgery versus neoadjuvant chemotherapy in stage IV ovarian cancer. *Ann Surg Oncol* 2012;19:959–965.
102. Morrison J, Haldar K, Kehoe S, Lawrie TA. Chemotherapy versus surgery for initial treatment in advanced ovarian epithelial cancer. *Cochrane Database Syst Rev* 2012;8:CD005343.
103. Vergote I, Trope CG, Amant F, et al. Neoadjuvant chemotherapy or primary surgery in stage IIIC or IV ovarian cancer. *N Engl J Med* 2010;363:943–953.
104. Steed H, Oza AM, Murphy J, et al. A retrospective analysis of neoadjuvant platinum-based chemotherapy versus up-front surgery in advanced ovarian cancer. *Int J Gynecol Cancer* 2006;16(Suppl 1):47–53.
105. Tangjitgamol S, Manusirivithaya S, Laopaiboon M, Lumbiganon P. Interval debulking surgery for advanced epithelial ovarian cancer. *Cochrane Database Syst Rev* 2009;CD006014.
106. Tiersten AD, Liu PY, Smith HO, et al. Phase II evaluation of neoadjuvant chemotherapy and debulking followed by intraperitoneal chemotherapy in women with stage III and IV epithelial ovarian, fallopian tube or primary peritoneal cancer: Southwest Oncology Group Study S0009. *Gynecol Oncol* 2009;112:444–449.
107. Vandenput I, Van Calster B, Capoen A, et al. Neoadjuvant chemotherapy followed by interval debulking surgery in patients with serous endometrial cancer with transperitoneal spread (stage IV): a new preferred treatment? *Br J Cancer* 2009;101:244–249.
108. Chi DS, Musa F, Dao F, et al. An analysis of patients with bulky advanced stage ovarian, tubal, and peritoneal carcinoma treated with primary debulking surgery (PDS) during an identical time period as the randomized EORTC-NCIC trial of PDS vs neoadjuvant chemotherapy (NACT). *Gynecol Oncol* 2012;124:10–14.
109. Fleming GF, Seidman J, Lengyel E. Epithelial ovarian cancer. In: Barakat RR, Markman M, Randall ME, eds. *Principles and Practice of Gynecologic Oncology*, 6th ed. Philadelphia: Lippincott Williams & Wilkins; 2013:757–847.
110. Schorge JO, Eisenhauer EE, Chi DS. Current surgical management of ovarian cancer. *Hematol Oncol Clin North Am* 2012;26:93–109.
111. Whitney CW, Spiratos N. *Gynecologic Oncology Group Surgical Procedures Manual*. Philadelphia: Gynecologic Oncology Group; 2009.
112. Giede KC, Kieser K, Dodge J, Rosen B. Who should operate on patients with ovarian cancer? An evidence-based review. *Gynecol Oncol* 2005;99:447–461.
113. Earle CC, Schrag D, Neville BA, et al. Effect of surgeon specialty on processes of care and outcomes for ovarian cancer patients. *J Natl Cancer Inst* 2006;98:172–180.
114. du Bois A, Quinn M, Thigpen T, et al. 2004 consensus statements on the management of ovarian cancer: final document of the 3rd International Gynecologic Cancer InterGroup Ovarian Cancer Consensus Conference (GCI G OCCC 2004). *Ann Oncol* 2005;16(Suppl 8):viii7–viii12.
115. Schlaerth AC, Chi DS, Poyner EA, et al. Long-term survival after fertility-sparing surgery for epithelial ovarian cancer. *Int J Gynecol Cancer* 2009;19:1199–1204.
116. Schilder JM, Thompson AM, DePriest PD, et al. Outcome of reproductive age women with stage IA or IC invasive epithelial ovarian cancer treated with fertility-sparing therapy. *Gynecol Oncol* 2002;87:1–7.
117. Fader AN, Rose PG. Role of surgery in ovarian carcinoma. *J Clin Oncol* 2007;25:2873–2883.
118. Wright JD, Shah M, Mathew L, et al. Fertility preservation in young women with epithelial ovarian cancer. *Cancer* 2009;115:4118–4126.
119. Satoh T, Hatae M, Watanabe Y, et al. Outcomes of fertility-sparing surgery for stage I epithelial ovarian cancer: a proposal for patient selection. *J Clin Oncol* 2010;28:1727–1732.
120. Gershenson DM. Treatment of ovarian cancer in young women. *Clin Obstet Gynecol* 2012;55:65–74.
121. Bristow RE, Tomacruz RS, Armstrong DK, et al. Survival effect of maximal cytoreductive surgery for advanced ovarian carcinoma during the platinum era: a meta-analysis. *J Clin Oncol* 2002;20:1248–1259.
122. Stier EA, Barakat RR, Curtin JP, et al. Laparotomy to complete staging of presumed early ovarian cancer. *Obstet Gynecol* 1996;87:737–740.
123. Eisenhauer EL, Abu-Rustum NR, Sonoda Y, et al. The addition of extensive upper abdominal surgery to achieve optimal cytoreduction improves survival in patients with stages IIIC-IV epithelial ovarian cancer. *Gynecol Oncol* 2006;103:1083–1090.
124. du Bois A, Reuss A, Pujade-Lauraine E, et al. Role of surgical outcome as prognostic factor in advanced epithelial ovarian cancer: a combined exploratory analysis of 3 prospectively randomized phase 3 multicenter trials: by the Arbeitsgemeinschaft Gynaekologische Onkologie Studiengruppe Ovarialkarzinom (AGO-OVAR) and the Groupe d'Investigateurs Nationaux Pour les Etudes des Cancers de l'Ovaire (GINECO). *Cancer* 2009;115:1234–1244.
125. Chang SJ, Bristow RE. Evolution of surgical treatment paradigms for advanced-stage ovarian cancer: redefining 'optimal' residual disease. *Gynecol Oncol* 2012;125:483–492.
126. Elattar A, Bryant A, Winter-Roach BA, et al. Optimal primary surgical treatment for advanced epithelial ovarian cancer. *Cochrane Database Syst Rev* 2011;CD007565.
127. Chi DS, Eisenhauer EL, Zivanovic O, et al. Improved progression-free and overall survival in advanced ovarian cancer as a result of a change in surgical paradigm. *Gynecol Oncol* 2009;114:26–31.
128. Liu CS, Nagarsheth NP, Nezhat FR. Laparoscopy and ovarian cancer: a paradigm change in the management of ovarian cancer? *J Minim Invasive Gynecol* 2009;16:250–262.
129. Fagotti A, Vizzielli G, De Iaco P, et al. A multicentric trial (Olympia-MITO 13) on the accuracy of laparoscopy to assess peritoneal spread in ovarian cancer. *Am J Obstet Gynecol* 2013;209:462.e1–462.e11.
130. Magrina JF, Zanagnolo V, Noble BN, et al. Robotic approach for ovarian cancer: perioperative and survival results and comparison with laparoscopy and laparotomy. *Gynecol Oncol* 2011;121:100–105.
131. Mori KM, Neubauer NL. Minimally invasive surgery in gynecologic oncology. *ISRN Obstet Gynecol* 2013;2013:312982.
132. Committee on Practice Bulletins—Gynecology. ACOG Practice Bulletin No. 126: Management of gynecologic issues in women with breast cancer. *Obstet Gynecol* 2012;119:666–682.
133. Barton DL, Loprinzi C, Gostout B. Current management of menopausal symptoms in cancer patients. *Oncology (Williston Park)* 2002;16:67–72, 74; discussion 75–66, 79–80.
134. Jenkins MR, Sikin AL. Update on nonhormonal approaches to menopausal management. *Cleve Clin J Med* 2008;75(Suppl 4):S17–24.
135. Wimberger P, Lehmann N, Kimmig R, et al. Prognostic factors for complete debulking in advanced ovarian cancer and its impact on survival. An exploratory analysis of a prospectively randomized phase III study of the Arbeitsgemeinschaft Gynaekologische Onkologie Ovarian Cancer Study Group (AGO-OVAR). *Gynecol Oncol* 2007;106:69–74.
136. Fischerova D, Zikan M, Dunder P, Cibula D. Diagnosis, treatment, and follow-up of borderline ovarian tumors. *Oncologist* 2012;17:1515–1533.
137. Ayhan A, Celik H, Taskiran C, et al. Oncologic and reproductive outcome after fertility-saving surgery in ovarian cancer. *Eur J Gynaecol Oncol* 2003;24:223–232.
138. Zanetta G, Bonazzi C, Cantu M, et al. Survival and reproductive function after treatment of malignant germ cell ovarian tumors. *J Clin Oncol* 2001;19:1015–1020.
139. Lee SJ, Schover LR, Partridge AH, et al. American Society of Clinical Oncology recommendations on fertility preservation in cancer patients. *J Clin Oncol* 2006;24:2917–2931.
140. Lai CH, Chang TC, Hsueh S, et al. Outcome and prognostic factors in ovarian germ cell malignancies. *Gynecol Oncol* 2005;96:784–791.
141. McCluggage WG, Judge MJ, Clarke BA, et al. Data set for reporting of ovary, fallopian tube and primary peritoneal carcinoma: recommendations from the International Collaboration on Cancer Reporting (ICCR). *Mod Pathol* 2015;28:1101–1122.
142. Okamoto A, Glasspool RM, Mabuchi S, et al. Gynecologic Cancer InterGroup (GCI G) consensus review for clear cell carcinoma of the ovary. *Int J Gynecol Cancer* 2014;24:S20–25.
143. Magazzino F, Katsaros D, Ottaiano A, et al. Surgical and medical treatment of clear cell ovarian cancer: results from the multicenter Italian Trials in Ovarian Cancer (MITO) 9 retrospective study. *Int J Gynecol Cancer* 2011;21:1063–1070.
144. Massad LS, Gao F, Hagemann I, Powell M. Clinical outcomes among women with mucinous adenocarcinoma of the ovary. *Gynecol Obstet Invest* 2015.

Ovarian Cancer, Version 1.2016

145. Bruls J, Simons M, Overbeek LI, et al. A national population-based study provides insight in the origin of malignancies metastatic to the ovary. *Virchows Arch* 2015;467:79–86.
146. McCluggage WG, Wilkinson N. Metastatic neoplasms involving the ovary: a review with an emphasis on morphological and immunohistochemical features. *Histopathology* 2005;47:231–247.
147. de Waal YR, Thomas CM, Oei AL, et al. Secondary ovarian malignancies: frequency, origin, and characteristics. *Int J Gynecol Cancer* 2009;19:1160–1165.
148. Sato S, Itamochi H, Kigawa J, et al. Combination chemotherapy of oxaliplatin and 5-fluorouracil may be an effective regimen for mucinous adenocarcinoma of the ovary: a potential treatment strategy. *Cancer Sci* 2009;100:546–551.
149. Madore J, Ren F, Filali-Mouhim A, et al. Characterization of the molecular differences between ovarian endometrioid carcinoma and ovarian serous carcinoma. *J Pathol* 2010;220:392–400.
150. Mackay HJ, Brady MF, Oza AM, et al. Prognostic relevance of uncommon ovarian histology in women with stage III/IV epithelial ovarian cancer. *Int J Gynecol Cancer* 2010;20:945–952.
151. Bodurka DC, Deavers MT, Tian C, et al. Reclassification of serous ovarian carcinoma by a 2-tier system: a Gynecologic Oncology Group Study. *Cancer* 2012;118:3087–3094.
152. Gershenson DM, Sun CC, Iyer RB, et al. Hormonal therapy for recurrent low-grade serous carcinoma of the ovary or peritoneum. *Gynecol Oncol* 2012;125:661–666.
153. Gershenson DM, Bodurka DC, Coleman RL, et al. Hormonal maintenance therapy for women with low grade serous carcinoma of the ovary or peritoneum [abstract]. *J Clin Oncol* 2016;34:Abstract 5502.
154. Piccart MJ, Bertelsen K, James K, et al. Randomized intergroup trial of cisplatin-paclitaxel versus cisplatin-cyclophosphamide in women with advanced epithelial ovarian cancer: three-year results. *J Natl Cancer Inst* 2000;92:699–708.
155. Mangili G, Sigismondi C, Gadducci A, et al. Outcome and risk factors for recurrence in malignant ovarian germ cell tumors: a MITO-9 retrospective study. *Int J Gynecol Cancer* 2011;21:1414–1421.
156. Gershenson DM. Management of ovarian germ cell tumors. *J Clin Oncol* 2007;25:2938–2943.
157. Brown J, Friedlander M, Backes FJ, et al. Gynecologic Cancer Intergroup (GCI) consensus review for ovarian germ cell tumors. *Int J Gynecol Cancer* 2014;24:S48–54.
158. Gershenson DM, Morris M, Cangir A, et al. Treatment of malignant germ cell tumors of the ovary with bleomycin, etoposide, and cisplatin. *J Clin Oncol* 1990;8:715–720.
159. Zanagnolo V, Sartori E, Galleri G, et al. Clinical review of 55 cases of malignant ovarian germ cell tumors. *Eur J Gynaecol Oncol* 2004;25:315–320.
160. Low JJ, Perrin LC, Crandon AJ, Hacker NF. Conservative surgery to preserve ovarian function in patients with malignant ovarian germ cell tumors. A review of 74 cases. *Cancer* 2000;89:391–398.
161. Mangili G, Scarfone G, Gadducci A, et al. Is adjuvant chemotherapy indicated in stage I pure immature ovarian teratoma (IT)? A multicenter Italian trial in ovarian cancer (MITO-9). *Gynecol Oncol* 2010;119:48–52.
162. Billmire D, Vinocur C, Rescorla F, et al. Outcome and staging evaluation in malignant germ cell tumors of the ovary in children and adolescents: an intergroup study. *J Pediatr Surg* 2004;39:424–429; discussion 424–429.
163. Mahdi H, Swensen RE, Hanna R, et al. Prognostic impact of lymphadenectomy in clinically early stage malignant germ cell tumour of the ovary. *Br J Cancer* 2011;105:493–497.
164. Vazquez I, Rustin GJ. Current controversies in the management of germ cell ovarian tumours. *Curr Opin Oncol* 2013;25:539–545.
165. Pectasides D, Pectasides E, Kassanos D. Germ cell tumors of the ovary. *Cancer Treat Rev* 2008;34:427–441.
166. Tangir J, Zelterman D, Ma W, Schwartz PE. Reproductive function after conservative surgery and chemotherapy for malignant germ cell tumors of the ovary. *Obstet Gynecol* 2003;101:251–257.
167. Billmire DF, Cullen JW, Rescorla FJ, et al. Surveillance after initial surgery for pediatric and adolescent girls with stage I ovarian germ cell tumors: report from the Children's Oncology Group. *J Clin Oncol* 2014;32:465–470.
168. Cushing B, Giller R, Ablin A, et al. Surgical resection alone is effective treatment for ovarian immature teratoma in children and adolescents: a report of the pediatric oncology group and the children's cancer group. *Am J Obstet Gynecol* 1999;181:353–358.
169. Patterson DM, Murugaesu N, Holden L, et al. A review of the close surveillance policy for stage I female germ cell tumors of the ovary and other sites. *Int J Gynecol Cancer* 2008;18:43–50.
170. Marina NM, Cushing B, Giller R, et al. Complete surgical excision is effective treatment for children with immature teratomas with or without malignant elements: a Pediatric Oncology Group/Children's Cancer Group Intergroup study. *J Clin Oncol* 1999;17:2137–2143.
171. Billmire DF, Krailo M, Rodriguez-Galindo C, Frazier AL. Reply to G. Mangili et al and C. Lhomme et al. *J Clin Oncol* 2014;32:2816–2817.
172. Lhomme C, Leary A, Uzan C, et al. Adjuvant chemotherapy in stage I ovarian germ cell tumors: should indications and treatment modalities be different in young girls and adults? *J Clin Oncol* 2014;32:2815–2816.
173. Mangili G, Sigismondi C, Lorusso D, Pignata S. Surveillance policy for stage IA malignant ovarian germ cell tumors in children and young adults. *J Clin Oncol* 2014;32:2814–2815.
174. Brown J, Shvartsman HS, Deavers MT, et al. The activity of taxanes compared with bleomycin, etoposide, and cisplatin in the treatment of sex cord-stromal ovarian tumors. *Gynecol Oncol* 2005;97:489–496.
175. Williams S, Blessing JA, Liao SY, et al. Adjuvant therapy of ovarian germ cell tumors with cisplatin, etoposide, and bleomycin: a trial of the Gynecologic Oncology Group. *J Clin Oncol* 1994;12:701–706.
176. Kang H, Kim TJ, Kim WY, et al. Outcome and reproductive function after cumulative high-dose combination chemotherapy with bleomycin, etoposide and cisplatin (BEP) for patients with ovarian endodermal sinus tumor. *Gynecol Oncol* 2008;111:106–110.
177. Saxman SB, Finch D, Gonin R, Einhorn LH. Long-term follow-up of a phase III study of three versus four cycles of bleomycin, etoposide, and cisplatin in favorable-prognosis germ-cell tumors: the Indian University experience. *J Clin Oncol* 1998;16:702–706.
178. Xiao H, Mazumdar M, Bajorin DF, et al. Long-term follow-up of patients with good-risk germ cell tumors treated with etoposide and cisplatin. *J Clin Oncol* 1997;15:2553–2558.
179. Nichols CR, Catalano PJ, Crawford ED, et al. Randomized comparison of cisplatin and etoposide and either bleomycin or ifosfamide in treatment of advanced disseminated germ cell tumors: an Eastern Cooperative Oncology Group, Southwest Oncology Group, and Cancer and Leukemia Group B study. *J Clin Oncol* 1998;16:1287–1293.
180. Hinton S, Catalano PJ, Einhorn LH, et al. Cisplatin, etoposide and either bleomycin or ifosfamide in the treatment of disseminated germ cell tumors: final analysis of an intergroup trial. *Cancer* 2003;97:1869–1875.
181. Horwich A, Sleijfer DT, Fossa SD, et al. Randomized trial of bleomycin, etoposide, and cisplatin compared with bleomycin, etoposide, and carboplatin in good-prognosis metastatic nonseminomatous germ cell cancer: a Multiinstitutional Medical Research Council/European Organization for Research and Treatment of Cancer Trial. *J Clin Oncol* 1997;15:1844–1852.
182. Toner GC, Stockler MR, Boyer MJ, et al. Comparison of two standard chemotherapy regimens for good-prognosis germ-cell tumours: a randomised trial. Australian and New Zealand Germ Cell Trial Group. *Lancet* 2001;357:739–745.
183. Bamias A, Aravantinos G, Kastriotis I, et al. Report of the long-term efficacy of two cycles of adjuvant bleomycin/etoposide/cisplatin in patients with stage I testicular nonseminomatous germ-cell tumors (NSGCT): a risk adapted protocol of the Hellenic Cooperative Oncology Group. *Urol Oncol* 2011;29:189–193.
184. Dimopoulos MA, Papadimitriou C, Hamilos G, et al. Treatment of ovarian germ cell tumors with a 3-day bleomycin, etoposide, and cisplatin regimen: a prospective multicenter study. *Gynecol Oncol* 2004;95:695–700.
185. Williams SD, Kauderer J, Burnett AF, et al. Adjuvant therapy of completely resected dysgerminoma with carboplatin and etoposide: a trial of the Gynecologic Oncology Group. *Gynecol Oncol* 2004;95:496–499.
186. Salani R, Backes FJ, Fung MF, et al. Posttreatment surveillance and diagnosis of recurrence in women with gynecologic malignancies: Society of Gynecologic Oncologists recommendations. *Am J Obstet Gynecol* 2011;204:466–478.
187. Reddy Ammakkanavar N, Matei D, Abonour R, Einhorn LH. High-dose chemotherapy for recurrent ovarian germ cell tumors. *J Clin Oncol* 2015;33:226–227.
188. Shibata K, Kajiyama H, Kikkawa F. Growing teratoma syndrome of the ovary showing three patterns of metastasis: a case report. *Case Rep Oncol* 2013;6:544–549.
189. Matsushita H, Arai K, Fukase M, et al. Growing teratoma syndrome of the ovary after fertility-sparing surgery and successful pregnancy. *Gynecol Obstet Invest* 2010;69:221–223.

Ovarian Cancer, Version 1.2016

190. Amsalem H, Nadjari M, Prus D, et al. Growing teratoma syndrome vs chemotherapeutic retroconversion: case report and review of the literature. *Gynecol Oncol* 2004;92:357–360.
191. Djordjevic B, Euscher ED, Malpica A. Growing teratoma syndrome of the ovary: review of literature and first report of a carcinoid tumor arising in a growing teratoma of the ovary. *Am J Surg Pathol* 2007;31:1913–1918.
192. Brenner DJ, Hall EJ. Computed tomography: an increasing source of radiation exposure. *N Engl J Med* 2007;357:2277–2284.
193. Kondagunta GV, Bacik J, Donadio A, et al. Combination of paclitaxel, ifosfamide, and cisplatin is an effective second-line therapy for patients with relapsed testicular germ cell tumors. *J Clin Oncol* 2005;23:6549–6555.
194. Einhorn LH, Williams SD, Chamness A, et al. High-dose chemotherapy and stem-cell rescue for metastatic germ-cell tumors. *N Engl J Med* 2007;357:340–348.
195. Loehrer PJ, Sr., Gonin R, Nichols CR, et al. Vinblastine plus ifosfamide plus cisplatin as initial salvage therapy in recurrent germ cell tumor. *J Clin Oncol* 1998;16:2500–2504.
196. Hinton S, Catalano P, Einhorn LH, et al. Phase II study of paclitaxel plus gemcitabine in refractory germ cell tumors (E9897): a trial of the Eastern Cooperative Oncology Group. *J Clin Oncol* 2002;20:1859–1863.
197. Nichols CR, Roth BJ, Loehrer PJ, et al. Salvage chemotherapy for recurrent germ cell cancer. *Semin Oncol* 1994;21:102–108.
198. Slayton RE, Park RC, Silverberg SG, et al. Vincristine, dactinomycin, and cyclophosphamide in the treatment of malignant germ cell tumors of the ovary. A Gynecologic Oncology Group Study (a final report). *Cancer* 1985;56:243–248.
199. Mangili G, Ottolina J, Gadducci A, et al. Long-term follow-up is crucial after treatment for granulosa cell tumours of the ovary. *Br J Cancer* 2013;109:29–34.
200. Colombo N, Parma G, Zanagnolo V, Insinga A. Management of ovarian stromal cell tumors. *J Clin Oncol* 2007;25:2944–2951.
201. Lee IH, Choi CH, Hong DG, et al. Clinicopathologic characteristics of granulosa cell tumors of the ovary: a multicenter retrospective study. *J Gynecol Oncol* 2011;22:188–195.
202. Ray-Coquard I, Brown J, Harter P, et al. Gynecologic Cancer InterGroup (GCIG) consensus review for ovarian sex cord stromal tumors. *Int J Gynecol Cancer* 2014;24:S42–47.
203. Zhang M, Cheung MK, Shin JY, et al. Prognostic factors responsible for survival in sex cord stromal tumors of the ovary: an analysis of 376 women. *Gynecol Oncol* 2007;104:396–400.
204. Wolf J, Brown J. Management of stromal tumors of the ovary: ASCO; 2008.
205. Brown J, Sood AK, Deavers MT, et al. Patterns of metastasis in sex cord-stromal tumors of the ovary: can routine staging lymphadenectomy be omitted? *Gynecol Oncol* 2009;113:86–90.
206. Schumer ST, Cannistra SA. Granulosa cell tumor of the ovary. *J Clin Oncol* 2003;21:1180–1189.
207. Schneider DT, Calaminus G, Wessalowski R, et al. Ovarian sex cord-stromal tumors in children and adolescents. *J Clin Oncol* 2003;21:2357–2363.
208. Park JY, Jin KL, Kim DY, et al. Surgical staging and adjuvant chemotherapy in the management of patients with adult granulosa cell tumors of the ovary. *Gynecol Oncol* 2012;125:80–86.
209. Gurumurthy M, Bryant A, Shanbhag S. Effectiveness of different treatment modalities for the management of adult-onset granulosa cell tumours of the ovary (primary and recurrent). *Cochrane Database Syst Rev* 2014;4:CD006912.
210. Homesley HD, Bundy BN, Hurteau JA, Roth LM. Bleomycin, etoposide, and cisplatin combination therapy of ovarian granulosa cell tumors and other stromal malignancies: a Gynecologic Oncology Group study. *Gynecol Oncol* 1999;72:131–137.
211. Pautier P, Gutierrez-Bonnaire M, Rey A, et al. Combination of bleomycin, etoposide, and cisplatin for the treatment of advanced ovarian granulosa cell tumors. *Int J Gynecol Cancer* 2008;18:446–452.
212. Teoh D, Freedman R, Soliman PT. Nearly 30 years of treatment for recurrent granulosa cell tumor of the ovary: a case report and review of the literature. *Case Rep Oncol* 2010;3:14–18.
213. Alhill MM, Long HJ, Podratz KC, Bakkum-Gamez JN. Aromatase inhibitors in the treatment of recurrent ovarian granulosa cell tumors: brief report and review of the literature. *J Obstet Gynaecol Res* 2012;38:340–344.
214. Korach J, Perri T, Beiner M, et al. Promising effect of aromatase inhibitors on recurrent granulosa cell tumors. *Int J Gynecol Cancer* 2009;19:830–833.
215. Fishman A, Kudelka AP, Tresukosol D, et al. Leuprolide acetate for treating refractory or persistent ovarian granulosa cell tumor. *J Reprod Med* 1996;41:393–396.
216. Tao X, Sood AK, Deavers MT, et al. Anti-angiogenesis therapy with bevacizumab for patients with ovarian granulosa cell tumors. *Gynecol Oncol* 2009;114:431–436.
217. Pacaut C, Bourmaud A, Rivoirard R, et al. Uterine and ovary carcinosarcomas: outcome, prognosis factors, and adjuvant therapy. *Am J Clin Oncol* 2015;38:272–277.
218. George EM, Herzog TJ, Neugut AI, et al. Carcinosarcoma of the ovary: natural history, patterns of treatment, and outcome. *Gynecol Oncol* 2013;131:42–45.
219. del Carmen MG, Birrer M, Schorge JO. Carcinosarcoma of the ovary: a review of the literature. *Gynecol Oncol* 2012;125:271–277.
220. Mano MS, Rosa DD, Azambuja E, et al. Current management of ovarian carcinosarcoma. *Int J Gynecol Cancer* 2007;17:316–324.
221. Berton-Rigaud D, Devouassoux-Shisheboran M, Ledermann JA, et al. Gynecologic Cancer InterGroup (GCIG) consensus review for uterine and ovarian carcinosarcoma. *Int J Gynecol Cancer* 2014;24:S55–60.
222. Jernigan AM, Fader AN, Nutter B, et al. Ovarian carcinosarcoma: effects of cytoreductive status and platinum-based chemotherapy on survival. *Obstet Gynecol Int* 2013;2013:490508.
223. Chun KC, Kim JJ, Kim DY, et al. Optimal debulking surgery followed by paclitaxel/platinum chemotherapy is very effective in treating ovarian carcinosarcomas: a single center experience. *Gynecol Obstet Invest* 2011;72:208–214.
224. Brown E, Stewart M, Rye T, et al. Carcinosarcoma of the ovary: 19 years of prospective data from a single center. *Cancer* 2004;100:2148–2153.
225. Silasi DA, Illuzzi JL, Kelly MG, et al. Carcinosarcoma of the ovary. *Int J Gynecol Cancer* 2008;18:22–29.
226. Duska LR, Garrett A, Eltabbakh GH, et al. Paclitaxel and platinum chemotherapy for malignant mixed müllerian tumors of the ovary. *Gynecol Oncol* 2002;85:459–463.
227. Inthasorn P, Beale P, Dalrymple C, Carter J. Malignant mixed müllerian tumour of the ovary: prognostic factor and response of adjuvant platinum-based chemotherapy. *Aust N Z J Obstet Gynaecol* 2003;43:61–64.
228. Rauh-Hain JA, Growdon WB, Rodriguez N, et al. Carcinosarcoma of the ovary: a case-control study. *Gynecol Oncol* 2011;121:477–481.
229. Leiser AL, Chi DS, Ishill NM, Tew WP. Carcinosarcoma of the ovary treated with platinum and taxane: the memorial Sloan-Kettering Cancer Center experience. *Gynecol Oncol* 2007;105:657–661.
230. Loizzi V, Cormio G, Camporeale A, et al. Carcinosarcoma of the ovary: analysis of 13 cases and review of the literature. *Oncology* 2011;80:102–106.
231. Rutledge TL, Gold MA, McMeekin DS, et al. Carcinosarcoma of the ovary: a case series. *Gynecol Oncol* 2006;100:128–132.
232. Prat J, De Nictolis M. Serous borderline tumors of the ovary: a long-term follow-up study of 137 cases, including 18 with a micropapillary pattern and 20 with microinvasion. *Am J Surg Pathol* 2002;26:1111–1128.
233. Cadron I, Leunen K, Van Gorp T, et al. Management of borderline ovarian neoplasms. *J Clin Oncol* 2007;25:2928–2937.
234. Barakat RR, Benjamin I, Lewis JL, Jr., et al. Platinum-based chemotherapy for advanced-stage serous ovarian carcinoma of low malignant potential. *Gynecol Oncol* 1995;59:390–393.
235. Leake JF, Currie JL, Rosenshein NB, Woodruff JD. Long-term follow-up of serous ovarian tumors of low malignant potential. *Gynecol Oncol* 1992;47:150–158.
236. Barnhill DR, Kurman RJ, Brady MF, et al. Preliminary analysis of the behavior of stage I ovarian serous tumors of low malignant potential: a Gynecologic Oncology Group study. *J Clin Oncol* 1995;13:2752–2756.
237. Prat J. Ovarian carcinomas: five distinct diseases with different origins, genetic alterations, and clinicopathological features. *Virchows Arch* 2012;460:237–249.
238. Harter P, Gershenson D, Lhomme C, et al. Gynecologic Cancer InterGroup (GCIG) consensus review for ovarian tumors of low malignant potential (borderline ovarian tumors). *Int J Gynecol Cancer* 2014;24:S5–8.
239. Burger CW, Prinszen HM, Baak JP, et al. The management of borderline epithelial tumors of the ovary. *Int J Gynecol Cancer* 2000;10:181–197.
240. Morice P, Denschlag D, Rodolakis A, et al. Recommendations of the Fertility Task Force of the European Society of Gynecologic Oncology about the conservative management of ovarian malignant tumors. *Int J Gynecol Cancer* 2011;21:951–963.

Ovarian Cancer, Version 1.2016

-
- 241.** Wingo SN, Knowles LM, Carrick KS, et al. Retrospective cohort study of surgical staging for ovarian low malignant potential tumors. *Am J Obstet Gynecol* 2006;194:e20–22.
- 242.** Winter WE, 3rd, Kucera PR, Rodgers W, et al. Surgical staging in patients with ovarian tumors of low malignant potential. *Obstet Gynecol* 2002;100:671–676.
- 243.** Gershenson DM, Silva EG. Serous ovarian tumors of low malignant potential with peritoneal implants. *Cancer* 1990;65:578–585.
- 244.** Shih KK, Zhou QC, Aghajanian C, et al. Patterns of recurrence and role of adjuvant chemotherapy in stage II-IV serous ovarian borderline tumors. *Gynecol Oncol* 2010;119:270–273.
- 245.** Sutton GP, Bundy BN, Omura GA, et al. Stage III ovarian tumors of low malignant potential treated with cisplatin combination therapy (a Gynecologic Oncology Group study). *Gynecol Oncol* 1991;41:230–233.
- 246.** Kennedy AW, Hart WR. Ovarian papillary serous tumors of low malignant potential (serous borderline tumors). A long-term follow-up study, including patients with microinvasion, lymph node metastasis, and transformation to invasive serous carcinoma. *Cancer* 1996;78:278–286.

Ovarian Cancer, Version 1.2016

Individual Disclosures of the Ovarian Cancer Panel				
Panel Member	Clinical Research Support/Data Safety Monitoring Board	Scientific Advisory Boards, Consultant, or Expert Witness	Promotional Advisory Boards, Consultant, or Speakers Bureau	Date Completed
Deborah K. Armstrong, MD	Astellas LLC; AstraZeneca Pharmaceuticals LP; and Clovis Oncology	None	None	10/27/15
Ronald D. Alvarez, MD				
Jamie N. Bakkum-Gamez, MD	None	None	None	7/13/16
Kian Behbakht, MD	None	None	None	4/13/16
Lee-may Chen, MD	None	Genentech, Inc.	Genentech, Inc.	7/18/15
Larry Copeland, MD	GOG Foundation; NRG Oncology; and TESARO, Inc.	Advaxis, Inc.; Bayer HealthCare ; Cerulean Pharma Inc.; Endocyte, Inc.; Helomics, Inc.; and Johnson & Johnson	None	9/30/15
Marta Ann Crispens, MD	AstraZeneca Pharmaceuticals LP; and Janssen Pharmaceutica Products, LP	None	None	5/8/16
Marie DeRosa, RN	None	None	None	3/18/16
Oliver Dorigo, MD, PhD	None	None	None	5/4/16
David M. Gershenson, MD ^a	NCI	None	None	8/7/15
Heidi J. Gray, MD	None	None	None	4/21/16
Ardeshir Hakam, MD	None	None	None	2/29/16
Laura J. Havrilesky, MD	None	None	None	10/2/15
Carolyn Johnston, MD	None	None	Michigan Cancer Consortium; and MPRO	3/29/16
Shashikant Lele, MD	None	None	None	10/13/15
Lainie Martin, MD	Novartis Pharmaceuticals Corporation; and Synta Pharmaceuticals Corp.	None	None	9/29/15
Ursula A. Matulonis, MD	None	AstraZeneca Pharmaceuticals LP; Genentech, Inc.; ImmunoGen, Inc.; Merck & Co., Inc.; and Pfizer Inc.	None	5/11/16
Robert J. Morgan Jr, MD	None	None	None	3/14/16
David M. O'Malley, MD	None	AstraZeneca Pharmaceuticals LP; Clovis Oncology; and Janssen Pharmaceutica Products, LP	None	4/18/16
Richard T. Penson, MD, MRCP	Amgen Inc.; AstraZeneca Pharmaceuticals LP; Endocyte, Inc.; Genentech, Inc.; and Vascular Biogenics Ltd	AstraZeneca Pharmaceuticals LP; Genentech, Inc.; and Vascular Biogenics, Ltd	None	3/9/16
Sanja Percac-Lima, MD, PhD	None	None	None	7/31/16
Mario Pineda, MD, PhD	None	None	None	1/7/16
Steven C. Plaxe, MD ^a	Amgen Inc.; AstraZeneca Pharmaceuticals LP; Azaya Therapeutics, Inc.; BIND Therapeutics, Inc.; Endocyte, Inc.; Janssen Pharmaceutica Products, LP; Millennium Pharmaceuticals, Inc.; Navidea Biopharmaceuticals; Novartis Pharmaceuticals Corporation; Pfizer Inc.; PharmaMar; and TESARO, Inc.	Ambrx, Inc.; and Insys Therapeutics, Inc.	Insys Therapeutics, Inc.	11/6/15
Matthew A. Powell, MD	Bristol-Myers Squibb Company; and Eisai Inc.	AnorMED Inc.; and Genentech, Inc.	Genentech, Inc.	7/13/15
Elena Ratner, MD	None	None	None	11/11/15
Steven W. Remmenga, MD	None	None	None	5/10/16
Peter G. Rose, MD	None	Pfizer Inc.	None	5/19/16
Paul Sabbatini, MD	Bristol-Myers Squibb Company	None	None	10/5/15
Joseph T. Santoso, MD	None	None	None	9/19/15
Theresa L. Werner, MD	None	None	None	10/1/15

^aThe following individuals have disclosed that they have an employment/governing board, patent, equity, or royalty conflict: David M. Gershenson, MD: Biogen Idec, Celgene Corporation, Elsevier, Johnson & Johnson, NCI, Proctor and Gamble, UpToDate Steven C. Plaxe, MD: Abbott Laboratories, Abb Vie Inc., Bristol-Myers Squibb Company, Pfizer Inc.

The NCCN Guidelines Staff have no conflicts to disclose.