

Focus on Fertility Preservation

Ovarian cryopreservation for fertility preservation: indications and outcomes

R A Anderson, W H B Wallace and D T Baird

The Queen's Medical Research Institute, Centre for Reproductive Biology, University of Edinburgh, 47 Little France Crescent, Edinburgh EH16 4TJ, UK

Correspondence should be addressed to R A Anderson; Email: richard.anderson@ed.ac.uk

Abstract

Female fertility preservation provides significantly different challenges to that for the male, with the only established method being cryopreservation of embryos thus necessitating the involvement of a male. Other, experimental, options include oocyte or ovarian tissue cryopreservation. The latter has been regarded as a potential method for more than a decade, but has resulted in the birth of only five babies. It is not possible to be certain how many women have had ovarian tissue cryopreserved. Oocyte cryopreservation also remains experimental, but ~100-fold more babies have been born through this technique over the last two decades. Ovarian tissue cryopreservation has the potential advantages of preservation of a large number of oocytes within primordial follicles, it does not require hormonal stimulation when time is short and indeed may be appropriate for the pre-pubertal. Disadvantages include the need for an invasive procedure, and the uncertain risk of ovarian contamination in haematological and other malignancies. We here review this approach in the context of our own experience of 36 women, highlighting issues of patient selection especially in the young, and uncertainties over the effects of cancer treatments on subsequent fertility. Of these 36 women, 11 have died but 5 have had spontaneous pregnancies. So far, none have requested reimplantation of their stored ovarian tissue. Ovarian cryopreservation appears to be a potentially valuable method for fertility preservation, but the indications and approaches best used remain unclear.

Reproduction (2008) **136** 681–689

Introduction

The adverse effects of the treatment of malignant disease on reproductive function have long been recognised (Himelstein-Braw *et al.* 1978, Chapman *et al.* 1979). In women, both chemotherapy and radiotherapy result in loss of ovarian function due to follicular depletion, and radiotherapy to a field that includes the pelvis can have an adverse effect on the uterus (Howell & Shalet 1998, Meiorow & Nugent 2001, Critchley & Wallace 2005). The increase in survival rates from cancer has highlighted the long-term consequences of both treatment and disease and has led to a growing interest in ameliorating these effects. The effects on the ovary occur both pre-pubertally as well as in adulthood. Established options for women include embryo and oocyte cryopreservation, which both have demonstrated success rates, albeit widely different (Sonmezer & Oktay 2004). Both treatments require ovarian stimulation that may not be possible or appropriate in some instances, most clearly for younger and pre-pubertal patients (Wallace *et al.* 2005) or when delay must be avoided. In these circumstances, the option of cryopreservation of ovarian tissue has been proposed, allowing

long-term storage of potentially large numbers of primordial follicles and there are comprehensive reviews of this approach (Sonmezer & Oktay 2004, Wallace *et al.* 2005, Donnez *et al.* 2006b). The stored ovarian tissue can at least theoretically then later be reimplanted orthotopically or heterotopically, or even xenografted or matured entirely *in vitro*.

Ovarian cryopreservation and reimplantation has been widely advocated since its successful demonstration, including spontaneous conception and live birth, in sheep (Gosden *et al.* 1994). Case reports in humans initially indicated the possibility of some restoration of follicular activity (Oktay & Karlikaya 2000, Radford *et al.* 2001) but subsequently live birth after orthotopic reimplantation (Donnez *et al.* 2004, Meiorow *et al.* 2005, Demeestere *et al.* 2007, Andersen *et al.* 2008) and embryo development after heterotopic implantation and IVF (Oktay *et al.* 2004) have been demonstrated. At July 2008, only five babies have been born following this technique (Table 1): it is unknown how many women have had ovarian tissue cryopreserved or reimplanted. Guidelines for the introduction of this very experimental technique have been proposed by several professional

Table 1 Pregnancies following ovarian tissue cryopreservation and transplantation.

Diagnosis	Age	Surgical method	Reimplantation	Pregnancy	Reference
Hodgkin's lymphoma	25	Unilateral ovarian biopsy	Orthotopic	Spontaneous, live birth	Donnez <i>et al.</i> (2004)
Non-Hodgkin's lymphoma	28	Unilateral ovarian biopsy (after first course chemo)	Orthotopic, to both ovaries	IVF, live birth	Meirow <i>et al.</i> (2005, 2007)
Hodgkin's lymphoma	29	Unilateral oophorectomy (after one cycle ABVD)	Ortho and heterotopic	Spontaneous, miscarriage	Demeestere <i>et al.</i> (2007)
Hodgkin's lymphoma	28	Unilateral oophorectomy	Ortho and heterotopic	Oocyte aspiration from heterotopic site/ICSI/biochemical pregnancy	Rosendahl (2006)
Hodgkin's lymphoma	31	Unilateral ovarian biopsy (after first course chemo)	Ortho and heterotopic	Spontaneous, miscarriage then livebirth	Demeestere <i>et al.</i> (2007)
Hodgkin's lymphoma	25	Unilateral oophorectomy	Ortho and heterotopic	IVF, miscarriage	Andersen <i>et al.</i> (2008)
Hodgkin's lymphoma	26	Unilateral oophorectomy	Orthotopic	IVF, live birth	Andersen <i>et al.</i> (2008)
Ewing sarcoma	27	Unilateral oophorectomy	Orthotopic	IVF, live birth	Andersen <i>et al.</i> (2008)

bodies (Royal College of Obstetricians and Gynaecologists 2000, British Fertility Society 2003, The Practice Committee of the American Society for Reproductive Medicine 2004, FIGO Committee for the Ethical Aspects of Human Reproduction and Women's Health 2006, Lee *et al.* 2006) emphasising its experimental nature and uncertain outcome. All aspects of this approach remain unclear: appropriate indications, the methods to be used surgically and in the laboratory both at the time of cryopreservation and later usage, and the potential risks that may in the case of reimplantation include reintroduction of the original disease. In view of this uncertainty, much of the development has been opportunistic without a clear strategy as to which girls/women would most benefit from the procedure and in particular who is likely to request use of their stored tissue. In this review, we discuss this technique in the context of its development over ~15 years in one centre.

Patients and experimental approach

The experimental basis for the development of ovarian cryopreservation for women was established in an animal model in the early 1990s. The surgical approach, methods for tissue cryopreservation and reimplantation and ovarian and endocrine consequences have been described in detail in sheep (Gosden *et al.* 1994, Baird *et al.* 1999). In response to the widespread publicity following reports of the first successful pregnancies in sheep in 1993, we received many requests to apply this technique for clinical use. From the outset, it was clear that it would be preferable to develop local guidelines for the referral and counselling of potential patients. In this way, we hoped that there would be consistency among the wide range of health professionals potentially involved in advising patients as to the suitability of this experimental technique. We realised that the guidelines would initially rely on clinical experience and limited data rather than be evidence based. A consensus was

reached by a group that included the disciplines of gynaecology, paediatric and adult oncology, and tissue banking. The guidelines have remained in place for the last 13 years with minor revision in the light of our own subsequent and published experience (Table 2). This procedure has the approval of the local Research Ethics Committee, and all women (or their parents, in the case of minors) gave informed consent in writing. In collaboration with a parent, we have developed age-specific patient information sheets.

The first subject was referred for discussion of ovarian cryopreservation in 1993. She had been diagnosed with non-Hodgkin's lymphoma (age 19.6 years), had received cyclophosphamide/vincristine/adriamycin and was to be treated with melphalan as conditioning chemotherapy before bone marrow transplantation (BMT), which would make premature ovarian failure very likely. Subsequently, a total of 36 women have consented to this procedure, although ovarian biopsy was unsuccessful in one due to equipment failure.

Details of the women's diagnoses and ages at the time of cryopreservation are given in Table 3. After discussion and providing written consent, virological screening is performed both at the time of discussion and on the day of biopsy, in line with current UK and EC tissue storage regulations. Our technique of surgical collection and storage of ovarian biopsies duplicated that used when developing the technique in sheep. The density of primordial follicles, which are the sole class to survive cryopreservation and the ischaemia associated with transplantation, is highest in the cortex. In most cases,

Table 2 Provisional criteria for offering ovarian cryopreservation.

Not more than 30 years old
No existing children
Reasonable chance of surviving 5 years
> 50% chance of having ovarian function destroyed by the therapy
If age > 15: no previous chemo/radiotherapy
If age < 15: eligible if previous 'mild' chemotherapy

Table 3 Details of surviving patients who have undergone ovarian cryopreservation and current reproductive function.

Risk	No	Diagnosis	Treatment	Age at diagnosis	Pregnancy	Assessment interval	Age now/at last assessment	LH (IU/l)	FSH (IU/l)	Oestradiol (pmol/l)
High	1	Non-Hodgkin's Lymphoma	CHOP×six cycles + etoposide and melphalan/BMT	19.6		13.0	32.6	7.3	9.3	160
	2	Ewing's sarcoma pubis	Ifosfamide-based chemo, pelvic radiotherapy 55 Gy	15.0	Yes	7.2	22.2	9.1	20	90
	5	Squamous ca cervix	Wertheim hysterectomy – no chemo/radiotherapy	27.5		7.8	35.3	12.2	6.8	412
	6	Sacral ependymoma	Radiotherapy to sacrum 55 Gy	11.3	Yes	10.7	22.0			
	21	Chronic granulocytic leukaemia	Total body irradiation and BMT	9.9		7.2	17.1			
	27	Cervical embryonal rhabdomyosarcoma	VIA – nine cycles	19.2		1.9	21.1	2.8	7.5	112
	28	Pelvic rhabdomyosarcoma	VAC – six cycles. Radiotherapy to pelvis – 42.85 Gy	5.4		3.1	8.5			
	33	Ewing's sarcoma	VIDE× six cycles; VIA + high dose myeloablative chemo + radiotherapy to skull and pelvis (55 Gy)	9.9		1.6	11.5			
	35	Pelvic alveolar \rhabdomyosarcoma	Ifosfamide-based chemotherapy plus pelvic and inguinal radiotherapy 45 Gy	16.0		0.6	16.6			
Medium	7	Müllerian adenocarcinoma	One cycle VIA	16.5		0.1	16.6			
	8	Hodgkin's lymphoma	ChLVVP×6	15.0		7.9	22.9	3	6.6	226
	13	Hodgkin's lymphoma	ChLVPP×6	13.8	Yes	7.8	21.6	5.1	7	88
	14	Hodgkin's lymphoma	ChLVPP×6	11.1		7.0	18.1	3.7	7.6	144
	13	Lymphoma	VAPEC B	23.2	Yes	6.8	30.0	3.4	16.1	<60
	15	Bechet's syndrome	Cyclophosphamide 10.5 g	20.4	Yes	6.2	26.6	7.8	6.5	208
	17	Non-Hodgkin's lymphoma	CHOP×three cycles	30.5	Yes	5.5	36.1	1.9	3.9	440
	18	Breast ca	Epirubicin/CMF×four cycles	35.6		4.8	40.5	11.4	18	1489 ^a
	22	SLE	Cyclophosphamide 21.3 g	14.6	Yes	7.1	21.7			
	24	SLE	Cyclophosphamide 6 g	17.2		6.1	23.3			
	27	SLE	Cyclophosphamide 8.3 g	19.1		2.3	21.4	4.4	6.7	232
	29	SLE	Cyclophosphamide 4.1 g	23.5		1.1	24.6	2.3	3.9	121
	31	Wilms' tumour	Vincristine/actinomycin D; carboplatin and etoposide/cyclophosphamide and adriamycin	22.8		2.6	25.4			
	32	Tibial osteosarcoma	Displatin/adriamycin×6 cycles	23.2		1.6	24.8	3.4	3.7	338
	34	Breast ca	Fluorouracil/epirubicin/cyclophosphamide×6 cycles	28.5		1.5	30.0			
Low	26	Hodgkin's lymphoma	ABVD×6	27.6		2.7	30.4	0.5	1.1	<60

ABVD, adriamycin, bleomycin, vinblastine and dacarbazine; BMT, bone marrow transplant; ChLVPP, chlorambucil, vinblastine, procarbazine and prednisolone; CHOP, cyclophosphamide, doxorubicin, vincristine and prednisolone; CMF, cyclophosphamide, methotrexate, 5-fluorouracil; SLE, systemic lupus erythematosus; VAC, vincristine, actinomycin D and cyclophosphamide; VAPEC B, vincristine, adriamycin, etoposide and bleomycin with prednisolone; VIA, vincristine, ifosfamide and actinomycin D; VIDE, vincristine, ifosfamide, doxorubicin (adriamycin) and etoposide.

^aTaking tamoxifen at time of assessment.

~12 small biopsies (3×3×1 mm) or in later cases strips of ovarian cortex are collected from one ovary, usually at laparoscopy. The size of the biopsy was dictated by the largest fragment that could survive the period of ischaemia following transplantation before neovascularisation occurs, after about 3–4 days (Baird *et al.* 1999). In one patient, the youngest laparoscopic unilateral oophorectomy was performed at the time of therapeutic surgery. In other patients, laparoscopy was performed at the time of insertion of a central venous line in one, at the time of Wertheim's hysterectomy in a second and at the time of Caesarean section at 34 weeks gestation in a third in whom sarcoma had been diagnosed during pregnancy. In all others, surgery for cryopreservation has been undertaken as a separate procedure. In addition to samples for storage, one further ovarian biopsy is taken for histological examination, and a small biopsy of s.c. fat taken for bacteriological control purposes after handling and transport to the laboratory in medium with the ovarian biopsies. No postoperative complications have occurred.

After the first two patients, ovarian biopsies have been processed and stored by the Tissue Services division of the Scottish National Blood Transfusion Service, based in Edinburgh. This organisation has the required accreditation for handling all human tissues and organs and provides tissue banking services for the whole of Scotland. Ovarian biopsies are collected into Leibovitz medium and cryopreserved in DMSO with patient serum as previously described (Gosden *et al.* 1994). Biopsies are stored in the vapour phase of liquid nitrogen at -176°C .

The referring medical team is contacted annually by Tissue Services to confirm the patient's health. In the case of death, the instructions specified on the consent form are followed. This allows only for destruction of the tissue or donation to properly approved laboratory-based research. Follow-up of patients has been variable, reflecting their disease, treatment course and geographical constraints thus recent reproductive endocrine status is not available for all (Table 3).

Patient outcomes

Of the 36 women requesting and consenting to this procedure, the most common diagnoses have been haematological malignancies (lymphoma and leukaemia, $n=11$). Sarcoma ($n=10$) was the commonest solid malignancy. Twenty percentage of the women had inflammatory rather than malignant diagnoses, generally systemic lupus erythematosus, and were to be treated with cyclophosphamide-based regimens.

Initial local guidelines for acceptance of patients for this treatment excluded any previous chemotherapy, although the first patient had received cyclophosphamide/vincristine/adriamycin before ovarian cryopreservation. This was subsequently changed to allow young girls previously treated for acute leukaemia with regimens with 'low' gonadal toxicity, but requiring total body

irradiation and BMT for treatment of relapse. Although this relaxation in the guidelines was made in 2000, no patients in those circumstances have in fact undergone this procedure.

The guidelines also suggested an upper but not a lower age cut-off. The median age at cryopreservation was 19.2 years (range 5–35, Fig. 1A). At the time of surgery, 15 patients (42%) were aged 16 years of less. At December

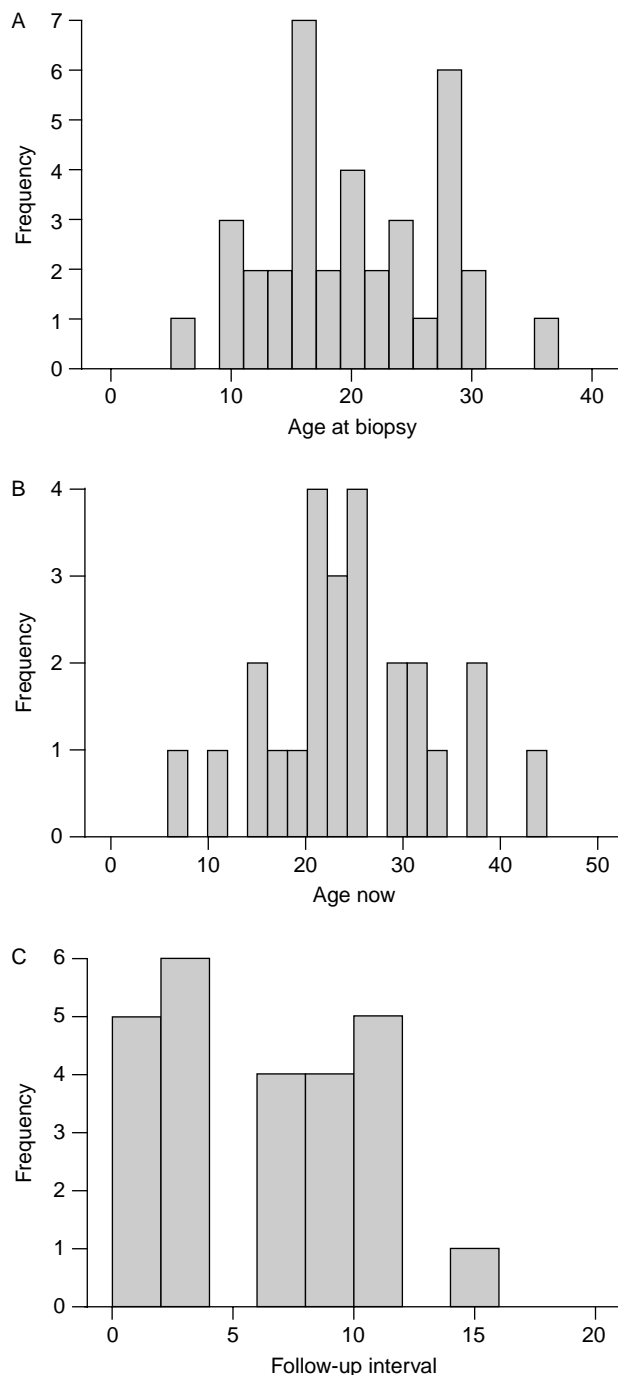


Figure 1 Age distribution of women undergoing ovarian cryopreservation (A) at time of surgery, (B) currently or at most recent follow-up and (C) interval since cryopreservation. In (A), $n=36$; in (B) and (C), $n=25$.

2007, the median age of those surviving was 24.4 years (range 8.5–43.6, Fig. 1B) and median duration since cryopreservation was 7.1 years (Fig. 1C).

We are unable to give an accurate denominator for the number, diagnoses or ages of women with whom the possibility of ovarian cryopreservation has been discussed as many have not wished to proceed following initial consultations with their physician. However, we are aware that the procedure has been discussed at length with the parents of a girl as young as 18 months of age (diagnosis vaginal rhabdomyosarcoma) who subsequently decided not to proceed.

Current reproductive function is detailed in Table 3. Of 20 surviving women currently over 18 years old, 7 (35%) have had spontaneous pregnancies. Five have resulted in term live birth, with one induced and one spontaneous abortion. One of these women received substantial chemotherapy and pelvic radiotherapy and became menopausal: details have been presented previously (Bath *et al.* 2004). Of the remainder, none are menopausal. Two women have moderately elevated early follicular follicle-stimulating hormone (FSH) concentrations, one of whom is now aged over 40 and received chemotherapy for breast cancer at age 35. The other was treated for lymphoma aged 23, but has subsequently had a successful pregnancy aged 29, with the hormone analysis performed less than a year after delivery. The first patient treated, who underwent high-dose chemotherapy and BMT aged 19, retains a regular menstrual cycle with early follicular phase FSH concentration <10 IU/l 13 years later.

Table 3 groups patients according to whether the chemotherapy they were scheduled to receive would be considered to put them at high (>80%), medium (20–80%) or low (<20%) risk of premature ovarian failure. This classification was performed by an oncologist with particular interest in reproductive function (WHBW) blinded to subsequent reproductive outcome. Although the inclusion criteria specified that they should be at medium or high risk of ovarian failure, one was retrospectively regarded as being at low risk. Of the five adult patients assessed at high risk, two have had spontaneous pregnancies. In the eight women in the medium risk group with known reproductive status >2 years post diagnosis, four have had spontaneous pregnancies as has one other with otherwise unknown current reproductive function.

A total of 11 (31%) of the girls and women have died (Table 4). Their diagnoses span the range, including those with inflammatory conditions. Most died within a year of diagnosis and all within 5 years.

Who are the right patients and how to treat them?

The successful development of ovarian cryopreservation, reimplantation with spontaneous conception and delivery of healthy offspring in sheep led to widespread

Table 4 Deceased patients.

Study no	Diagnosis	Age at cryopreservation
3	Sarcoma of thigh	28.9
5	Cervical ca	26.0
10	Acute myeloid leukaemia	28.5
11	Chronic myeloid leukaemia	17.8
12	Cervical ca	28.2
16	Shwachman–Diamond syndrome	16.8
19	Sarcoma of humerus	15.1
20	Breast ca	29.1
23	Cerebral SLE	24.0
30	Chronic myeloid leukaemia	15.7

interest in this technique around the world. Initial human experience with reimplantation of ovarian tissue demonstrated some hormonal function but without ovulation (Oktay & Karlikaya 2000, Radford *et al.* 2001) and, more recently, successful conception has been reported after orthotopic reimplantation in women with Hodgkin's and non-Hodgkin's lymphoma and Ewing's sarcoma (Donnez *et al.* 2004, Meirrow *et al.* 2005, Demeestere *et al.* 2007, Andersen *et al.* 2008). There are currently published reports of five babies delivered following reimplantation of cryopreserved ovarian tissue (Table 1). It is unknown how many patients have had ovarian tissue reimplanted, but undoubtedly more pregnancies will follow. Of all pregnancies that have derived from orthotopic transplantation, four of the successful conceptions were spontaneous with the fifth following IVF. Concerns as to whether the first patient (Donnez *et al.* 2004) was fully menopausal and thus conception may have derived from residual follicular activity remain unresolved (Oktay & Tilly 2004). There is clearer evidence that the pregnancies arose from transplanted ovarian tissue in the other reported live births. It is well recognised, however, that spontaneous ovarian activity and pregnancy may occur even some years after ovarian failure is clearly documented (Bath *et al.* 2004). Heterotopic follicular development with oocyte aspiration, maturation and development of good quality embryos has been reported (Oktay *et al.* 2004) but unfortunately pregnancy did not follow embryo transfer. Monitoring and oocyte aspiration of heterotopic follicles indicate that oocytes need to be aspirated from relatively small (~10 mm) follicles, and may need further maturation *in vitro* to allow fertilisation (Oktay *et al.* 2004). Nevertheless, these pregnancies provide substantial encouragement that ovarian cryopreservation and orthotopic reimplantation can restore fertility. Ovarian transplantation has also been used with success in the treatment of identical twins where one had a premature menopause (Silber *et al.* 2008). This serves to reinforce that this approach can be successful, and applied to a range of clinical situations in addition to malignancy. We are not aware of any examples that ovarian cryopreservation has been applied for 'social'

indications, to preserve fertility against the physiological decline in ovarian function, as has been proposed as a possible use of oocyte cryopreservation.

There remains controversy about who should be offered ovarian cryopreservation. Criteria were developed locally following multidisciplinary discussion and have been subsequently revised. Similar criteria have recently been published (Demeestere *et al.* 2007) and are broadly in keeping with reports by the Royal College of Obstetricians and Gynaecologists, the British Fertility Society and the American Society of Clinical Oncology (Royal College of Obstetricians and Gynaecologists 2000, British Fertility Society 2003, Lee *et al.* 2006). An upper age limit was felt necessary and has been the most debated criterion. Any age limit is bound to be arbitrary in the absence of evidence, but what might appear a relatively low limit of 30 years was adopted as it was felt that this very experimental technique should only be offered to those in whom it was most likely to be successful. While one patient reported here underwent the procedure aged 35 years, we have otherwise maintained this age limit. Others 'prefer' to offer this procedure to women <35 years of age, and do not offer it to those over 40 (Oktay & Karlikaya 2000, Sonmezer & Oktay 2004). Most primordial follicles and all growing follicles are lost during cryopreservation and subsequent revascularisation following reimplantation (Baird *et al.* 1999, Demirci *et al.* 2001). Age, as a proxy for follicle number, is therefore critical although in our own analysis of follicle number in 14 biopsies a clear relationship was not evident (Bertolino *et al.* 2003). An overall primordial follicle density of $\sim 50/\text{mm}^2$ was found, although this varied enormously both between biopsies from the same woman and between women. With development of this technique, it is likely that the current age limit will be revised upwards. The successful pregnancies reported so far have been in women aged 25–31 years (Table 1). The established option of embryo cryopreservation is more likely to be an option for women as they get older, although ovarian tissue cryopreservation does have the advantage of not requiring the involvement of a male partner whose consent is required for the use of stored embryos and may later be withdrawn.

The cryopreservation and subsequent use of prepubertal ovarian tissue presents a number of practical and ethical problems that must be addressed before embarking on any clinical programme (Wallace & Walker 2001). These include issues of safety relating to the harvesting of the tissue, subsequent use and possible implications for the progeny. Valid consent is necessary for clinical research, rendering potentially harmful interventions both ethical and legal. To be valid, consent must be informed, voluntarily obtained and given by a competent person. In practice, it may be difficult to satisfy these criteria, especially in children with cancer. The information necessary for parents and children to

make an informed choice about fertility preservation is inevitably complex and its comprehension cannot be guaranteed. Legal competence to consent requires that the individual giving it is able to understand the information given, believes that it applies to them, retains it and uses it to make an informed choice. Parental anxieties about their child's illness may reduce their competence. It may involve consideration of a future which neither they nor the child can envisage or have discussed. Therapeutic imperatives may limit the time available for discussion, which in turn imposes constraints on the voluntariness of the consent. The concept of informed consent is also difficult to reconcile when issues of safety are uncertain and the future use of any tissue is entirely experimental. Some of these practical difficulties may be alleviated if obtaining consent is considered as a continuum, which can be divided into two stages, with part one involving harvesting and cryopreservation of the tissue and part two involving subsequent use of the tissue. Clearly, subsequent use of the tissue would require separate consent. Issues relating to the use of the tissue in the event of the death of the patient should also be discussed.

Due to the invasive nature of ovarian biopsy (generally at laparoscopy undertaken only for cryopreservation), it was felt that only patients thought to be at high risk of loss of ovarian function should be included. Different chemotherapeutic agents are recognised to have varying toxicity to the ovary, but there is a paucity of clearly derived prospective data accurately quantifying this (Meirow & Schiff 2005). It is striking that four out of five reported successful pregnancies were in patients with lymphomas, and data on cryopreservation in an extensive series of such patients have recently been published (Meirow *et al.* 2007). Treatment regimens for lymphoma may be less gonadotoxic in women than previously (Clark *et al.* 1995, Hodgson *et al.* 2007), whereas the increasing use of taxanes in, for example, breast cancer may be associated with increased gonadotoxicity (Anderson *et al.* 2006).

Our attempt at systemisation of this risk led to a requirement that the risk of permanent immediate sterility should be judged >50%. Follow-up has indicated that this risk may be overestimated by oncologists and others caring for these patients. Only one woman has become overtly menopausal, and strikingly she had a spontaneous conception with successful delivery 4 years after completing treatment. Overall, of 20 women currently well and aged 18 years or more, 7 (35%) have had spontaneous pregnancies. Of the remainder, one has moderately elevated FSH concentrations (following breast cancer treatment). Two women did not undergo anticipated chemotherapy or radiotherapy: in one, this had been planned based on assessment of a cervical biopsy demonstrating invasive cervical cancer, but pathological assessment following hysterectomy resulted in revision of this decision and

she remains well 9 years later. While her ovarian function is normal, surrogacy will be required for fertility. In a second, aged 16, initial pathological assessment of a cervical lesion indicated rhabdomyosarcoma, requiring chemotherapy. However, further pathological evaluation after ovarian cryopreservation and one cycle of chemotherapy resulted in a revised diagnosis of Müllerian adenosarcoma or pseudosarcoma, and further treatment involved fertility-sparing cervical biopsy without chemotherapy and radiotherapy unless there is recurrence of disease. These two cases illustrate the difficulties that can arise with either only preliminary histology or very rare conditions. These follow-up data are in general agreement with a previous report of reproductive function after ovarian cryopreservation (Schmidt *et al.* 2005). In that study, 10 out of 22 women who had one ovary removed for cryopreservation had apparently normal ovarian function of the remaining ovary, although the interval since treatment was short, generally being about 2 years. Three post-treatment pregnancies were reported in that relatively short post-cancer diagnosis interval, and it is likely that more will later occur as oncologists often advise women to wait at least 2–3 years to reduce the likelihood of early recurrence during pregnancy and minimise the risk of foetal exposure to chemotherapy agents.

The third main criterion was that there should be a relatively good prognosis, with anticipated chance of survival at 5 years of over 50%. It would therefore be expected that rather more than half of the patients will be alive at 5 years, and experience has been in keeping with this with 54% alive at least 5 years after diagnosis, and all deaths occurring within 5 years. Again, this criterion is merely a starting point and the decision to proceed with cryopreservation or not will take into account a range of individual factors.

Other criteria included that the patient should not have had any previous chemotherapy that would have reduced the number of follicles present, although this was subsequently revised to allow patients age 15 or less who had had chemotherapy thought to be of low risk to the ovary. This was to allow inclusion of children treated for acute leukaemia, who would not meet the criterion of a >50% risk of sterility after initial chemotherapy, but if they subsequently relapsed would again not be eligible having had some chemotherapy. In this series, two patients had chemotherapy prior to cryopreservation, the first, and one of the women with systemic lupus erythematosus (SLE) who had previously received some cyclophosphamide. Others have argued that cryopreservation after chemotherapy may be appropriate (Poirot *et al.* 2002, Meirow *et al.* 2007), although the health of oocytes/follicles cryopreserved under those conditions is uncertain and may increase the risk to a subsequent pregnancy due to the DNA-damaging mechanism of action of some chemotherapeutic agents. A recent study has demonstrated increased oocyte vacuolisation and

granulosa cell nuclear abnormalities after chemotherapy (Abir *et al.* 2008), supporting the practice of confining cryopreservation to before treatment.

The surgical technique most appropriate for obtaining ovarian tissue has been debated. Many have proposed unilateral oophorectomy, and this has been the method used in some reports (Radford *et al.* 2001, Poirot *et al.* 2002, Schmidt *et al.* 2005, Andersen *et al.* 2008). We have generally avoided this, other than in the case of our youngest patient who was to receive chemotherapy and pelvic radiotherapy. Instead, we and others (Donnez *et al.* 2006b) have taken the approach of removing what we consider to be a minimum amount of ovarian tissue, on the basis of causing the least possible compromise to future spontaneous fertility. Partial oophorectomy has been used by others (Meirow *et al.* 2007). Cryopreservation unavoidably involves the loss of the majority of follicles removed from the patient, mostly during revascularisation at the time of reingraftment (Baird *et al.* 1999). The follow-up data presented here highlights the risk of overestimation of damage to the ovary from the anti-cancer treatment and substantiates this approach.

None of the criteria make any specifications regarding diagnosis. As in a previous report (Poirot *et al.* 2002), we have included women with non-malignant conditions requiring cytotoxic chemotherapy, i.e. cyclophosphamide for SLE and other rheumatological conditions. While overall fertility is preserved in the majority of women with SLE (Park *et al.* 2004), they require variable treatment dosages over a more prolonged period than malignancies, adding to the difficulties of patient selection. Other appropriate conditions may include sickle cell disease where treatment with total body irradiation (TBI) is proposed (Donnez *et al.* 2006a). The present data highlight the mortality associated with these non-malignant conditions. Despite these uncertainties, we feel these are an important group of women for whom this procedure may be of value.

Reimplantation has not been requested by any patients in our series. This may reflect the high prevalence of continuing ovarian function and indeed pregnancy in these women. Others are yet young. Reimplantation may carry a risk of reintroduction of disease particularly in haematologic malignancies, which has been demonstrated in an animal model (Shaw *et al.* 1996), although analysis of clinical samples has been more reassuring (Kim *et al.* 2001, Seshadri *et al.* 2006). A recent report illustrates the use of highly sensitive techniques to detect malignant contamination in ovarian tissue, which was used to avoid reimplantation in a woman with chronic myeloid leukaemia (CML) (Meirow *et al.* 2008). The interpretation of the results of these sensitive assays for minimal residual disease remains controversial. The alternative to reimplantation is *in vitro* maturation but this has not so far progressed sufficiently to be a therapeutic possibility (Gosden *et al.* 2002) although recent developments are encouraging (Telfer *et al.* 2008):

this topic is further discussed in the accompanying review by Picton *et al.* (2008). Xenografting has been used to demonstrate the viability of cryopreserved ovarian tissue (Newton *et al.* 1996, Gook *et al.* 2005) but is not currently considered appropriate for therapy. It is widely recognised that only few men who have cryopreserved sperm prior to chemotherapy return to request use of the stored samples (Audrins *et al.* 1999, Blackhall *et al.* 2002) and it remains to be seen whether this may also be true in women.

While a full discussion of oocyte cryopreservation is beyond the scope of this article, it clearly offers an alternative means of gamete storage that may also be occasionally appropriate in young women. Progress in oocyte cryopreservation and vitrification has been recently reviewed (Oktay *et al.* 2006, Porcu & Venturoli 2006, Gook & Edgar 2007), illustrating many difficulties and limited progress in defining optimal techniques, resulting in generally low post-thaw fertilisation rates although these may be improving. Immature oocytes may be obtained from young women without gonadotrophin stimulation, and matured *in vitro* before vitrification: this approach has recently been reported in combination with ovarian tissue cryopreservation in a 16-year-old girl with mosaic Turner syndrome (Huang *et al.* 2008), although the normality of the chromosome complement of oocytes obtained from such patients is a concern.

In conclusion, these data illustrate the possibilities and uncertainties surrounding the development of criteria for selection of women and girls for ovarian cryopreservation. Substantially, improved data regarding the effects on fertility of current treatment regimens and other non-malignant conditions are required to allow a better informed decision to be made by patients and their doctors. There remain further uncertainties regarding the most appropriate surgical technique, and how many women will subsequently return to use their stored tissue. This may be after three decades in younger prepubertal patients, who may be those for whom this technique is most valuable.

Declaration of interest

None of the authors have any conflict of interest to declare.

Funding

This work was supported by the National Health Service and the Tissue Services Division of the Scottish National Blood Transfusion Service.

References

Abir R, Ben-Haroush A, Felz C, Okon E, Raanani H, Orvieto R, Nitke S & Fisch B 2008 Selection of patients before and after anticancer treatment for ovarian cryopreservation. *Human Reproduction* **23** 869–877.

- Andersen CY, Rosendahl M, Byskov AG, Loft A, Ottosen C, Dueholm M, Schmidt KL, Nyboe Andersen A & Ernst E 2008 Two successful pregnancies following autotransplantation of frozen/thawed ovarian tissue. *Human Reproduction* [in press].
- Anderson RA, Themmen APN, Al Qahtani A, Groome NP & Cameron DA 2006 The effects of chemotherapy and long-term gonadotrophin suppression on the ovarian reserve in premenopausal women with breast cancer. *Human Reproduction* **21** 2583–2592.
- Audrins P, Holden CA, McLachlan RI & Kovacs GT 1999 Semen storage for special purposes at Monash IVF from 1977 to 1997. *Fertility and Sterility* **72** 179–181.
- Baird DT, Webb R, Campbell BK, Harkness LM & Gosden RG 1999 Long-term ovarian function in sheep after ovariectomy and transplantation of autografts stored at -196°C . *Endocrinology* **140** 462–471.
- Bath LE, Tydeman G, Critchley HOD, Anderson RA, Baird DT & Wallace WHB 2004 Spontaneous conception in a young woman who had ovarian cortical tissue cryopreserved before chemotherapy and radiotherapy for a Ewing's sarcoma of the pelvis: case report. *Human Reproduction* **19** 2569–2572.
- Bertolino V, Anderson R, Wallace H & Baird D 2003 Follicle density in cryopreserved ovarian biopsies collected from young women prior to treatment for cancer. *International Journal of Gynecology & Obstetrics* **83** (Supplement 3) 83–84.
- Blackhall FH, Atkinson AD, Maaya MB, Ryder WD, Horne G, Brison DR, Lieberman BA & Radford JA 2002 Semen cryopreservation, utilisation and reproductive outcome in men treated for Hodgkin's disease. *British Journal of Cancer* **87** 381–384.
- British Fertility Society 2003 A strategy for fertility services for survivors of childhood cancer. *Human Fertility* **6** A1–A40.
- Chapman RM, Sutcliffe SB & Malpas JS 1979 Cytotoxic-induced ovarian failure in women with Hodgkin's disease. I. Hormone function. *Journal of the American Medical Association* **242** 1877–1881.
- Clark ST, Radford JA, Crowther D, Swindell R & Shalet SM 1995 Gonadal function following chemotherapy for Hodgkin's disease: a comparative study of MVPP and a seven-drug hybrid regimen. *Journal of Clinical Oncology* **13** 134–139.
- Critchley HO & Wallace WH 2005 Impact of cancer treatment on uterine function. *Journal of the National Cancer Institute* **34** 64–68.
- Demeestere I, Simon P, Emiliani S, Delbaere A & Englert Y 2007 Fertility preservation: successful transplantation of cryopreserved ovarian tissue in a young patient previously treated for Hodgkin's Disease. *Oncologist* **12** 1437–1442.
- Demirci B, Lornage J, Salle B, Frappart L, Franck M & Guerin JF 2001 Follicular viability and morphology of sheep ovaries after exposure to cryoprotectant and cryopreservation with different freezing protocols. *Fertility and Sterility* **75** 754–762.
- Donnez J, Dolmans MM, Demylle D, Jadoul P, Pirard C, Squifflet J, Martinez-Madrid B & Van Langendonck A 2004 Livebirth after orthotopic transplantation of cryopreserved ovarian tissue. *Lancet* **364** 1405–1410.
- Donnez J, Dolmans MM, Demylle D, Jadoul P, Pirard C, Squifflet J, Martinez-Madrid B & Van Langendonck A 2006a Restoration of ovarian function after orthotopic (intraovarian and periovarian) transplantation of cryopreserved ovarian tissue in a woman treated by bone marrow transplantation for sickle cell anaemia: case report. *Human Reproduction* **21** 183–188.
- Donnez J, Martinez-Madrid B, Jadoul P, Van Langendonck A, Demylle D & Dolmans MM 2006b Ovarian tissue cryopreservation and transplantation: a review. *Human Reproduction Update* **12** 519–535.
- FIGO Committee for the Ethical Aspects of Human Reproduction and Women's Health 2006 Ethical considerations and recommendations on oocyte and ovarian cryopreservation. *International Journal of Gynaecology and Obstetrics* **92** 335–336.
- Gook DA & Edgar DH 2007 Human oocyte cryopreservation. *Human Reproduction Update* **13** 591–605.
- Gook DA, Edgar DH, Borg J, Archer J & McBain JC 2005 Diagnostic assessment of the developmental potential of human cryopreserved ovarian tissue from multiple patients using xenografting. *Human Reproduction* **20** 72–78.
- Gosden RG, Baird DT, Wade JC & Webb R 1994 Restoration of fertility to oophorectomized sheep by ovarian autografts stored at -196°C . *Human Reproduction* **9** 597–603.

- Gosden RG, Mullan J, Picton HM, Yin H & Tan SL 2002 Current perspective on primordial follicle cryopreservation and culture for reproductive medicine. *Human Reproduction Update* **8** 105–110.
- Himmelstein-Braw R, Peters H & Faber M 1978 Morphological study of the ovaries of leukaemic children. *British Journal of Cancer* **38** 82–87.
- Hodgson DC, Pintilie M, Gitterman L, Dewitt B, Buckley CA, Ahmed S, Smith K, Schwartz A, Tsang RW, Crump M *et al.* 2007 Fertility among female hodgkin lymphoma survivors attempting pregnancy following ABVD chemotherapy. *Hematological Oncology* **25** 11–15.
- Howell S & Shalet S 1998 Gonadal damage from chemotherapy and radiotherapy. *Endocrinology and Metabolism Clinics of North America* **27** 927–943.
- Huang JY, Tulandi T, Holzer H, Lau NM, Macdonald S, Tan SL & Chian RC 2008 Cryopreservation of ovarian tissue and *in vitro* matured oocytes in a female with mosaic Turner syndrome: case report. *Human Reproduction* **23** 336–339.
- Kim SS, Radford J, Harris M, Varley J, Rutherford AJ, Lieberman B, Shalet S & Gosden R 2001 Ovarian tissue harvested from lymphoma patients to preserve fertility may be safe for autotransplantation. *Human Reproduction* **16** 2056–2060.
- Lee SJ, Schover LR, Partridge AH, Patrizio P, Wallace WH, Hagerly K, Beck LN, Brennan LV & Oktay K 2006 American Society of Clinical Oncology recommendations on fertility preservation in cancer patients. *Journal of Clinical Oncology* **24** 2917–2931.
- Meirow D & Nugent D 2001 The effects of radiotherapy and chemotherapy on female reproduction. *Human Reproduction Update* **7** 535–543.
- Meirow D & Schiff E 2005 Appraisal of chemotherapy effects on reproductive outcome according to animal studies and clinical data. *Journal of the National Cancer Institute* **34** 21–25.
- Meirow D, Levron J, Eldar-Geva T, Hardan I, Fridman E, Zalel Y, Schiff E & Dor J 2005 Pregnancy after transplantation of cryopreserved ovarian tissue in a patient with ovarian failure after chemotherapy. *New England Journal of Medicine* **353** 318–321.
- Meirow D, Baum M, Yaron R, Levron J, Hardan I, Schiff E, Nagler A, Yehuda DB, Raanani H, Hourvitz A *et al.* 2007 Ovarian tissue cryopreservation in hematologic malignancy: ten years' experience. *Leukemia & Lymphoma* **48** 1569–1576.
- Meirow D, Hardan I, Dor J, Fridman E, Elizur S, Ra'anani H, Slyusarevsky E, Amariglio N, Schiff E, Rechavi G *et al.* 2008 Searching for evidence of disease and malignant cell contamination in ovarian tissue stored from hematologic cancer patients. *Human Reproduction* **23** 1007–1013.
- Newton H, Aubard Y, Rutherford A, Sharma V & Gosden R 1996 Low temperature storage and grafting of human ovarian tissue. *Human Reproduction* **11** 1487–1491.
- Oktay K & Karlikaya G 2000 Ovarian function after transplantation of frozen, banked autologous ovarian tissue. *New England Journal of Medicine* **342** 1919.
- Oktay K & Tilly J 2004 Livebirth after cryopreserved ovarian tissue autotransplantation. *Lancet* **364** 2091–2092 (author reply 2092–2093).
- Oktay K, Buyuk E, Veeck L, Zaninovic N, Xu K, Takeuchi T, Opsahl M & Rosenwaks Z 2004 Embryo development after heterotopic transplantation of cryopreserved ovarian tissue. *Lancet* **363** 837–840.
- Oktay K, Cil AP & Bang H 2006 Efficiency of oocyte cryopreservation: a meta-analysis. *Fertility and Sterility* **86** 70–80.
- Park MC, Park YB, Jung SY, Chung IH, Choi KH & Lee SK 2004 Risk of ovarian failure and pregnancy outcome in patients with lupus nephritis treated with intravenous cyclophosphamide pulse therapy. *Lupus* **13** 569–574.
- Picton HM, Harris SE, Maruvi W & Chambers EL 2008 The *in vitro* growth and maturation of follicles. *Reproduction* **136** 703–715.
- Poirot C, Vacher-Lavenu MC, Helardot P, Guibert J, Brugieres L & Jouannet P 2002 Human ovarian tissue cryopreservation: indications and feasibility. *Human Reproduction* **17** 1447–1452.
- Porcu E & Venturoli S 2006 Progress with oocyte cryopreservation. *Current Opinion in Obstetrics and Gynecology* **18** 273–279.
- Radford JA, Lieberman BA, Brison DR, Smith AR, Critchlow JD, Russell SA, Watson AJ, Clayton JA, Harris M, Gosden RG *et al.* 2001 Orthotopic reimplantation of cryopreserved ovarian cortical strips after high-dose chemotherapy for Hodgkin's lymphoma. *Lancet* **357** 1172–1175.
- Rosendahl M, Loft A, Byskov AG, Ziebe S, Schmidt KT, Anderson AN, Ottosen C & Anderson CY 2006 Biochemical pregnancy after fertilization of an oocyte aspirated from a heterotopic autotransplant of cryopreserved ovarian tissue: case report. *Human Reproduction* **21** 2006–2009.
- Royal College of Obstetricians and Gynaecologists 2000 *Storage of Ovarian and Prepubertal Testicular Tissue. Report of a Working Party.* London: RCOG Press.
- Schmidt KL, Andersen CY, Loft A, Byskov AG, Ernst E & Andersen AN 2005 Follow-up of ovarian function post-chemotherapy following ovarian cryopreservation and transplantation. *Human Reproduction* **20** 3539–3546.
- Seshadri T, Gook D, Lade S, Spencer A, Grigg A, Tiedemann K, McKendrick J, Mitchell P, Stern C & Seymour JF 2006 Lack of evidence of disease contamination in ovarian tissue harvested for cryopreservation from patients with Hodgkin lymphoma and analysis of factors predictive of oocyte yield. *British Journal of Cancer* **94** 1007–1010.
- Shaw JM, Bowles J, Koopman P, Wood EC & Trounson AO 1996 Fresh and cryopreserved ovarian tissue samples from donors with lymphoma transmit the cancer to graft recipients. *Human Reproduction* **11** 1668–1673.
- Silber SJ, Derosa M, Pineda J, Lenahan K, Grenia D, Gorman K & Gosden RG 2008 A series of monozygotic twins discordant for ovarian failure: ovary transplantation (cortical versus microvascular) and cryopreservation. *Human Reproduction* **23** 1531–1537.
- Sonmezer M & Oktay K 2004 Fertility preservation in female patients. *Human Reproduction Update* **10** 251–266.
- Telfer EE, McLaughlin M, Ding C & Thong KJ 2008 A two step serum free culture system supports development of human oocytes from primordial follicles in the presence of activin. *Human Reproduction* **23** 1151–1158.
- The Practice Committee of the American Society for Reproductive Medicine 2004 Ovarian tissue and oocyte cryopreservation. *Fertility and Sterility* **82** 993–998.
- Wallace WH & Walker DA 2001 Conference consensus statement: ethical and research dilemmas for fertility preservation in children treated for cancer. *Human Fertility* **4** 69–76.
- Wallace WHB, Anderson RA & Irvine DS 2005 Fertility preservation for young patients with cancer: who is at risk and what can be offered? *Lancet Oncology* **6** 209–218.

Received 5 March 2008

First decision 8 May 2008

Revised manuscript received 28 July 2008

Accepted 5 August 2008