



Published in final edited form as:

Ann Neurol. 2014 March ; 75(3): 411–428. doi:10.1002/ana.24117.

Overlapping demyelinating syndromes and anti-NMDA receptor encephalitis

Maarten J. Titulaer, MD PhD^{1,2}, Romana Höftberger, MD^{1,3}, Takahiro Iizuka, MD⁴, Frank Leypoldt, MD^{1,5}, Lindsey McCracken, MPH⁶, Tania Cellucci, MD MScCH, FRCPC⁷, Leslie A. Benson, MD⁸, Huidy Shu, MD PhD⁹, Takashi Irioka, MD PhD¹⁰, Makito Hirano, MD PhD¹¹, Gagandeep Singh, MD DM¹², Alvaro Cobo Calvo, MD¹³, Kenichi Kaida, MD PhD¹⁴, Pamela S. Morales, MD¹⁵, Paul W. Wirtz, MD PhD¹⁶, Tomotaka Yamamoto, MD PhD¹⁷, Markus Reindl, PhD¹⁸, Myrna R. Rosenfeld, MD PhD¹, Francesc Graus, MD PhD¹, Albert Saiz, MD, PhD¹, and Josep Dalmau, MD PhD^{1,6,19}

¹Department of Neurology, Hospital Clínic, Universitat de Barcelona and Institut d'Investigació Biomèdica August Pi i Sunyer (IDIBAPS), Barcelona, Spain ²Department of Neurology, Erasmus Medical Center, Rotterdam, the Netherlands ³Institute of Neurology, Medical University of Vienna, Vienna, Austria ⁴Department of Neurology, Kitasato University School of Medicine, Kanagawa, Japan ⁵Department of Neurology, University Medical-Center Hamburg-Eppendorf, Hamburg, Germany ⁶Department Neurology and Neurosciences, Hospital of the University of Pennsylvania, Perelman School of Medicine, Philadelphia, USA ⁷Department of Pediatrics, McMaster Children's Hospital, McMaster University, Hamilton, Canada ⁸Partners Pediatric MS Center, Department of Child Neurology, Massachusetts General Hospital, Boston, and Pediatric MS and Related Disorders Clinic, Boston Children's Hospital, Boston, USA ⁹Department of Neurology, Pali Momi Medical Center, Aiea, USA ¹⁰Department of Neurology, Yokosuka Kyosai Hospital, Kanagawa, Japan ¹¹Department of Neurology, Sakai Hospital Kinki University Faculty of Medicine, Sakai, Japan ¹²Department of Neurology, Dayanand Medical College, Ludhiana, India and Department of Clinical and Experimental Epilepsy, University College London, Queens Square London, UK ¹³Department of Neurology, Hospital Universitario de Bellvitge, Barcelona, Spain ¹⁴Department of Neurology, National Defense Medical College, Japan ¹⁵Department of Pediatrics, Pontificia Universidad Católica de Chile, Santiago, Chile ¹⁶Department of Neurology, Haga Hospital, The Hague, The Netherlands ¹⁷Medical Safety Management Center, University of Tokyo Hospital, Tokyo, Japan ¹⁸Clinical department of Neurology, Innsbruck Medical University, Innsbruck, Austria ¹⁹Catalan Institution for Research and Advanced Studies (ICREA), Barcelona, Spain

Abstract

Objective—To report the clinical, radiological, and immunological association of demyelinating disorders with anti-N-methyl-D-aspartate receptor (NMDAR) encephalitis.

Methods—Clinical and radiological analysis of a cohort of 691 patients with anti-NMDAR encephalitis. Determination of antibodies to NMDAR, aquaporin-4 (AQP4) and myelin

Address correspondence to: Josep Dalmau, MD, PhD, Service of Neurology, IDIBAPSHospital Clínic, University of Barcelona, Casanova, 143; Floor 5, Lab 503, Department 2 Barcelona 08036 (Spain), [Josep.dalmau@uphs.upenn.edu] Phone: +34 932 271 738 Fax: +34 932271726.

oligodendrocyte glycoprotein (MOG) was performed using brain immunohistochemistry and cell-based assays.

Results—Twenty-three of 691 patients with anti-NMDAR encephalitis had prominent MRI and/or clinical features of demyelination. *Group 1* included 12 patients in whom anti-NMDAR encephalitis was preceded or followed by independent episodes of NMO-spectrum disorder (5 cases, 4 anti-AQP4-positive), or brainstem or multifocal demyelinating syndromes (7 cases, all anti-MOG-positive). *Group 2* included 11 patients in whom anti-NMDAR encephalitis occurred simultaneously with MRI and symptoms compatible with demyelination (5 AQP4-positive, 2 MOG-positive). *Group 3* (136 controls) included 50 randomly selected patients with typical anti-NMDAR encephalitis, 56 with NMO, and 30 with multiple sclerosis: NMDAR-antibodies were detected only in the 50 anti-NMDAR patients, MOG-antibodies in 3/50 anti-NMDAR and 1/56 NMO patients, and AQP4-antibodies in 48/56 NMO and 1/50 anti-NMDAR patients ($p < 0.0001$ for all comparisons with Groups 1 and 2). Most patients improved with immunotherapy, but compared with anti-NMDAR encephalitis the demyelinating episodes required more intensive therapy and resulted in more residual deficits. Only 1/23 NMDAR patients with signs of demyelination had ovarian teratoma compared with 18/50 anti-NMDAR controls ($p = 0.011$).

Interpretation—Patients with anti-NMDAR encephalitis may develop concurrent or separate episodes of demyelinating disorders, and conversely patients with NMO or demyelinating disorders with atypical symptoms (e.g., dyskinesias, psychosis) may have anti-NMDAR encephalitis.

Introduction

Anti-N-methyl-D-aspartate receptor (NMDAR) encephalitis is a severe autoimmune disorder that occurs in association with IgG antibodies against the GluN1 subunit of the NMDAR.¹ The pathogenic effects of the antibodies have been demonstrated at the cellular and synaptic levels using in vitro and in vivo models.^{2,3} Despite the severity of symptoms, only 35% of the patients have abnormal brain MRI at disease onset,⁴ increasing to 50% when the entire course of the disease is considered.¹ The abnormalities identified on routine MRI studies are often mild, transient and non-specific, preferentially seen in FLAIR sequences, usually involving cortical and subcortical regions of the brain and hippocampus, but sometimes affecting the basal ganglia. Over the last five years we have identified patients with anti-NMDAR encephalitis with additional symptoms or episodes suggesting a demyelinating disorder. This finding is in line with a few case reports of anti-NMDAR encephalitis associated with acute demyelinating encephalomyelitis (ADEM), myelitis, or neuromyelitis optica (NMO) without aquaporin-4 (AQP4) antibodies.⁵⁻⁷ It is well established that AQP4 antibodies are useful to differentiate NMO and NMO-spectrum disorder (NMOSD) with spatially limited phenotypes such as optic neuritis (ON) or longitudinally extensive transverse myelitis (LETM) from other autoimmune disorders of the CNS.⁸⁻¹⁰ Some patients with NMO without AQP4 antibodies have serum antibodies to myelin oligodendrocyte glycoprotein (MOG),^{11,12} and these antibodies have been reported in children with ADEM.¹²⁻¹⁶ The recognition that anti-NMDAR encephalitis and a demyelinating disorder may occur in the same patient is important because treatment and outcome vary for each disorder, and we suspect that these patients may be misdiagnosed.

We report here 23 patients with these overlapping syndromes, focusing on the clinical, MRI and serological (NMDAR, AQP4, MOG) findings, as well as the frequency of these associations, the responses to treatment, and the long-term outcome.

Methods

Patients

Patients were identified from a cohort of 691 cases with anti-NMDAR encephalitis, whose serum and CSF samples were sent to the hospitals of the University of Pennsylvania and University of Barcelona. The diagnosis of anti-NMDAR encephalitis was based on the presence of symptoms of encephalopathy and antibodies in serum and/or CSF against the NMDAR confirmed with both rat brain immunohistochemistry and a cell-based assay of cells expressing GluN1, as reported.¹⁷ Criteria for the selection of patients with demyelinating features included, (1) anti-NMDAR encephalitis, (2) clinical and/or MRI findings compatible with demyelinating disorders, such as optic neuritis, myelitis, prominent brainstem dysfunction, and/or (3) T2/FLAIR multifocal, infratentorial or extensive abnormalities suggesting involvement of the white matter. In all patients the episodes of demyelination were scored as compatible with NMO or NMOSD as per the revised Wingerchuk⁹ and Sellner criteria.⁸ The presentation of these symptoms and/or MRI features of demyelination in relation to the time of development of anti-NMDAR encephalitis led us to consider two groups of patients, 1) those in whom the clinical and/or MRI features of demyelination occurred as episodes separate from anti-NMDAR encephalitis, and 2) those in whom the clinical and/or MRI features of demyelination occurred simultaneously with typical anti-NMDAR encephalitis.

Clinical and MRI data were obtained by the authors or treating physicians at symptom onset and at different time points during the course of the disease, as reported.⁴ In addition to the two indicated groups of patients, which are the focus of the manuscript, three additional groups were used as controls for antibody studies: 50 patients with anti-NMDAR encephalitis randomly selected among the indicated 691 cases by use of a random integer generator (<http://www.random.org/integers/>), 56 patients with definite NMO (48 with AQP4 antibodies), and 30 patients with multiple sclerosis (MS).

Informed consent was obtained from patients or patients' representatives. Studies were approved by the institutional review boards of the University of Pennsylvania and the University of Barcelona.

Antibody studies

Determination of antibodies against NMDAR was performed using both immunohistochemistry with rat brain and a cell-based assay.^{1,17} Analysis of antibodies to AQP4 was performed with both immunohistochemistry with rat brain and a cell based assay,¹⁸ and antibodies to MOG with a cell based assay (see below).¹²

Immunohistochemistry with rat brain—Non-perfused rat brains were fixed in 4% paraformaldehyde (PFA) for 1h, cryoprotected with 40% sucrose for 24h, and snap frozen in chilled isopentane. Seven micron thick sections were then incubated with 0.3% hydrogen

peroxide for 20 minutes, with 10% goat serum in PBS for 1h, and then labeled with patient's or control sample (serum: 1:200; CSF: 1:2) at 4°C overnight. The next day, sections were labeled with the appropriate secondary antibody (1:2000) for 2h at room temperature and visualized with an avidin-biotin-peroxidase method (Vector lab).

Cell-based assays: The CBA for AQP4 was performed with HEK293 cells transfected with the M23 isoform of AQP4 (the clone was a gift from Dr. R. Marignier).¹⁹ Twenty-four hours after transfection, live cells were incubated at room temperature with centrifuged patient's or control samples (serum: 1:20, CSF: 1:2; diluted in DMEM with 1% BSA) for 30 minutes, fixed with 1% PFA for 10 minutes and permeabilized with 0.3% Triton X-100. HEK cells were then immunolabeled with a rabbit polyclonal anti-AQP4 antibody (1:500; Sigma-Aldrich) for 1h at room temperature, followed by the corresponding Alexa Fluor 488 and 594 secondary antibodies against human and rabbit IgGs (1:1000).

The CBA for MOG was performed with HEK293 cells transfected with the full-length MOG C-terminally fused to EGFP (the clone was a gift from Dr. M. Reindl).¹² Twenty-four hours after transfection, live cells were incubated at 37°C with patient's or control samples for 30 minutes, fixed with 4% PFA for 10 minutes and permeabilized with 0.3% Triton X-100. HEK cells were then immunolabeled with an Alexa Fluor 594 secondary antibody against human IgG (1:1000). We used a high-titer cut-off (1:160) for serum to consider a patient as MOG-antibody positive as described before,^{12,20} while we used a minimum dilution of 1:2 for CSF.

Statistical analysis

Frequencies of characteristics within the different patient groups were compared by the Fisher-Freeman-Halton extension of the Fisher Exact test for dichotomous outcomes or by the Kruskal-Wallis test for continuous variables.

Results

Twenty-three patients (3.3%) with anti-NMDAR encephalitis and clinical and/or MRI features of demyelination were identified. The distribution of cases by clinical, MRI, and serological findings, and the temporal relationship between anti-NMDAR encephalitis and the clinical/MRI features of demyelination (Demyelination Syndrome Episode, or DSE) are summarized in Figure 1.

Group 1 ("NMDAR-DSE", Figure 1, Table 1) includes 12 patients who developed anti-NMDAR encephalitis preceded or followed by one or more DSE; in all patients the diagnosis was made by the time they developed the symptoms. Four of these patients had AQP4 antibodies (Figure 2 A, C) fulfilling criteria for NMOSD or definite NMO, and one had definite NMO without AQP4 antibodies.^{8,9} All patients with AQP4 antibodies had the episode of NMOSD before experiencing anti-NMDAR encephalitis (11–80 months), while the patient with NMO without AQP4 antibodies developed the first episode of NMO one month after full recovery from anti-NMDAR encephalitis. The other seven patients, including three with a brainstem syndrome and four with a multifocal demyelinating episode, all had MOG antibodies (Figure 2 B, C). In four of these seven patients anti-

NMDAR encephalitis occurred 3–36 months before the DSE and in the other three 22–96 months after. The episodes of anti-NMDAR encephalitis of these patients were similar to those of patients with typical anti-NMDAR encephalitis without overlapping demyelinating features (Figure 3A). An example of the course of symptoms in a patient with NMDAR and MOG antibodies is shown in Figure 3B. All 12 patients had abnormal MRI findings (examples provided in Figure 4); eight had infratentorial or spinal cord abnormalities ($p < 0.0001$, compared to NMDAR-controls, Table 2). None of these patients had a tumor ($p = 0.011$), and their clinical picture was milder than that of patients in the anti-NMDAR control group ($p = 0.001$). A 37 year-old woman (case 3) developed acetylcholine receptor antibody-positive myasthenia gravis for which she underwent elective thymectomy; seven years later she developed NMOSD, and 30 months thereafter presented with anti-NMDAR encephalitis.

In 10 patients the symptoms related to anti-NMDAR encephalitis responded to first-line immunotherapies (steroids, IVIg, plasma exchange); one patient was recently started on rituximab and has shown progressive improvement, and one patient died (Table 1). As far as the symptoms related to DSE are concerned, 11/12 patients showed partial improvement, requiring more intensive treatment than that used for anti-NMDAR encephalitis (Table 1). Seven out of 12 patients needed second-line immunotherapy. Eventually, 9 of 12 patients had good outcome (mRS 0–2) although only two had complete recovery. The other three patients had poor outcome, and in general the residual deficits of the demyelinating event predominated over the mild deficits of anti-NMDAR encephalitis.

Group 2 (“NMDAR + clinical/MRI features of demyelination”, Figure 1, Table 3) includes 11 patients with anti-NMDAR encephalitis occurring simultaneously with extensive FLAIR-T2 abnormalities which in five cases involved the infratentorial region or spinal cord (examples provided in Figure 5). None of these 11 patients developed separate episodes of DSE. Two patients had relapses of anti-NMDAR encephalitis that were typical and identical to (but milder than) the initial episode of anti-NMDAR encephalitis. Five patients had AQP4 antibodies (Table 3); three of them had atypical symptoms during the episode of encephalitis consisting of bilateral facial and bulbar palsy in one, ataxia and hemiparesis in another, and ataxic gait in the third. The other two patients with AQP4 antibodies had no symptoms that would suggest NMOSD. Of the six AQP4 antibody-negative patients, two had MOG antibodies and four did not (Table 3). The two patients with MOG antibodies had infratentorial MRI abnormalities and unusual symptoms in addition to a syndrome highly suggestive of anti-NMDAR encephalitis. Among the four patients without MOG antibodies, three had some unusual clinical features shown in Table 3.

Overall, compared with patients of group 1, in whom the episodes of anti-NMDAR were separated in time from the DSE, and with patients of the control group with anti-NMDAR encephalitis (without history of demyelinating episodes), those of group 2 were more likely to have prominent infratentorial or spinal cord symptoms ($p = 0.002$, Figure 3A). Five of 10 patients (1 is lost to follow-up) required second-line immunotherapy after initial immunotherapy. Overall, seven of 10 had good outcome. Two of the three patients with poor outcome had AQP4 antibodies in addition to NMDAR antibodies.

Control groups (Figure 1). Among the 50 random patients with typical anti-NMDAR encephalitis, only one (2%) had AQP4 antibodies. Therefore, the frequency of AQP4 antibodies in this group of patients was significantly lower than that found in Groups 1 and 2 ($p < 0.0001$, Table 2). The patient with AQP4 antibodies was a 46-year old woman who presented with dysarthria but otherwise had a clinical picture typical of anti-NMDAR encephalitis, including behavioral problems, confusion, memory deficits, akinetic mutism, orofacial dyskinesias, hyperthermia and central hypoventilation. The brain MRI was normal (spinal cord not examined), and she did not develop symptoms of demyelinating events in the 37 month follow-up. The clinical features of the other 49 patients were typical of anti-NMDAR encephalitis and comparable to those published.⁴ Three of these 49 patients had low-titer MOG antibodies, demonstrating that the frequency of these antibodies in this group of patients was also significantly lower than that found in Groups 1 and 2 ($p < 0.0001$, clinical details in Table 4).

Among the 56 control patients with NMO (48 with AQP4 antibodies), only one had MOG antibodies (without AQP4 antibodies), and none had NMDAR antibodies (clinical details in Table 4). None of the 30 patients with multiple sclerosis had NMDAR, AQP4, or MOG antibodies.

Discussion

This study provides several novel findings that are important for the recognition, treatment, and prognosis of a subgroup of patients with anti-NMDAR encephalitis occurring simultaneously or sequentially with clinical and/or MRI features of demyelinating disorders. In these patients, immunological studies often show independent but co-existing immune mechanisms underlying each of these disorders, such as AQP4 or MOG antibodies in association with NMDAR antibodies. Moreover, the data on outcome demonstrate that the demyelinating episodes are more difficult to treat than anti-NMDAR encephalitis and often result in more residual deficits, emphasizing the importance of prompt diagnosis and treatment.

The frequency of sequential or coexisting anti-NMDAR encephalitis and demyelinating disorders is unknown. Most patients with anti-NMDAR encephalitis have normal, mild, or transient MRI abnormalities. In contrast, the patients included here had extensive or multifocal T2-FLAIR abnormalities, representing 3.3% of cases in a cohort of 691 patients with anti-NMDAR encephalitis. Half of these atypical cases developed at least one demyelinating episode separated in time from the episode of anti-NMDAR encephalitis, making each disorder potentially recognizable on clinical grounds. However, the other half of the patients developed concurrent symptoms and MRI findings of both disorders confounding the diagnosis. These mixed phenotypes suggested the co-existence of two simultaneously active immune mechanisms which was supported by the identification of NMDAR and AQP4 or MOG antibodies in 7 of 11 cases.

The current data and a recent report indicating that patients with anti-NMDAR encephalitis often have white matter changes visible with diffusion tensor imaging and resting functional MRI, suggest that myelin disruption is more common than suspected on clinical grounds or

by conventional MRI.²¹ The exact contribution of NMDAR antibodies and other immune responses (AQP4, MOG, or yet unknown antibodies) to myelin dysfunction is unknown, but it should be noted that oligodendrocytes contain NMDAR,²² and future studies will determine whether they are affected by patients' antibodies. The role of MOG antibodies in demyelinating disorders is unclear; these have been detected in pediatric patients with monophasic or recurrent demyelination, but only rarely in classical MS. It has been suggested that MOG antibodies could reflect an underlying pathogenic mechanism, a secondary immune reaction, a bystander phenomenon, or even a beneficial effect.²⁰

Only one of 23 patients with anti-NMDAR-encephalitis and atypical clinical and/or MRI features had an ovarian teratoma, suggesting that patients with the nonparaneoplastic form of the disorder are prone to autoimmunity. An example would be patient #3 who sequentially developed three antibody-mediated disorders, including myasthenia gravis, anti-AQP4 NMOSD, and anti-NMDAR encephalitis. Moreover, at least 4 of 691 patients with NMDAR encephalitis had NMOSD with AQP4 antibodies, which is more than 200 times the expected frequency in the general population using an estimated prevalence of anti-AQP4 NMO of 2.7/100,000 ($p < 0.0005$).²³ Despite this, clinical experience and previous reports suggest that the association of anti-NMDAR encephalitis with other autoimmune disorders occurs less frequently than in NMO/NMOSD where the association with other autoimmune disorders has been reported in 30–75% of the patients.²⁴

The clinical diagnosis of the patients reported here posed substantial difficulties. These patients were often suspected to have ADEM, NMO or MS, but eventually the presence of prominent psychiatric symptoms, orofacial dyskinesias, and/or autonomic dysfunction suggested the diagnosis of anti-NMDAR encephalitis. We suspect that in similar cases the diagnosis of anti-NMDAR encephalitis may not be considered, and these patients are probably diagnosed and treated as having a demyelinating disorder.

In the current study, the episodes of anti-NMDAR encephalitis of most patients responded to first-line therapies and resulted in mild residual deficits, but the episodes of demyelination often required more intense immunotherapies and resulted in more deficits. This was emphasized by the fact that during the demyelinating episodes the maximum symptom severity was less compared with that of the episodes of anti-NMDAR encephalitis. Moreover, the time lapsing between symptom onset and initiation of immunotherapy was similar for the episodes of demyelination and the episodes of anti-NMDAR encephalitis. We therefore postulate that different immune-mechanisms such as reversible antibody-mediated effects on NMDAR,^{2,25} versus AQP4 complement-mediated toxicity²⁶ or additional cytotoxic T-cell effects on myelin, account for the different responses to treatment and outcomes. Therefore, although the initial treatment approach with steroids is similar for anti-NMDAR encephalitis and demyelinating disorders, subsequent treatments and prognosis are different. An example is case 5 who developed mixed symptoms of anti-NMDAR encephalitis along with more than 10 relapses of LETM and ON refractory to treatment.⁵ This patient was initially suspected to have seronegative NMO and treated as such, but became asymptomatic after NMDAR antibodies were identified and treatment with rituximab and cyclophosphamide was used. Moreover, the treatment plan for these disorders is also different; for example, anti-NMDAR encephalitis often requires intensive care and

rehabilitation addressed to the prominent psychiatric symptoms, executive dysfunction, and challenging social interactions.^{27–29}

This study has limitations related to the clinical history of some patients, which antedates the availability of antibody-testing, and its retrospective nature. For example, patients with anti-NMDAR encephalitis and previous DSE episodes without AQP4 were not examined during the earlier DSE episodes for NMDAR antibodies. Therefore, the possibility that some of these DSE episodes could represent atypical presentations of anti-NMDAR encephalitis cannot be completely ruled out. We believe this is unlikely, because all these patients had MOG antibodies which showed a significant correlation with DSE compared with the control groups. On the other hand, the six patients with anti-NMDAR encephalitis and AQP4-antibodies without DSE episodes (but with abnormal brain MRI in 5), have not developed NMO as of the last follow-up (median 37 months, range 20–48 months); we cannot exclude that these patients may develop NMO in the future.

The current findings indicate that patients with anti-NMDAR encephalitis may develop demyelinating features as concurrent or independent episodes, and that patients with NMO and other demyelinating disorders with unusual symptoms (e.g. prominent psychiatric manifestations, orofacial dyskinesias, or autonomic instability among others) may have anti-NMDAR encephalitis. Testing for AQP4 and MOG antibodies often help to recognize these associations, but in rare instances no antibodies other than NMDAR are detected. Future studies including prospective clinical assessment coupled with comprehensive antibody testing will establish the actual frequency of these associations.

Acknowledgments

Clinical Investigators Group: Tanuja Chitnis, MD (Partners Pediatric MS Center, Department of Child Neurology, Massachusetts General Hospital, Boston, USA); Guy D'Anjou, MD PhD (Department of Pediatric Neurology, Université de Montréal, CHU Ste-Justine, Montreal, Canada); Fabiola Fajardo Fregosa, MD (Department of Pediatric Neurology, Hospital Civil de Guadalajara “Fray Antonio Alcalde”, Guadalajara, Mexico); Norito Kokubun, MD (Department of Neurology, Dokkyo Medical University, Japan); Michael C Krueger, MD (Department of Pediatrics, Sanford Children's Health Research Center, Sioux Falls, SD 57103 USA); Yusaku Nakamura, MD PhD (Department of Neurology, Sakai Hospital Kinki University Faculty of Medicine, Japan); Birinder Singh Paul, MD DM (Department of Neurology, Dayanand Medical College & Hospital Ludhiana, India); Luis Querol MD PhD (CIBERNED researcher, Neuromuscular Disorders Unit, Neurology Department, Hospital de la Santa Creu i Sant Pau, Barcelona, Spain); Denise Z Skuster, MD (Department of Neurology, LDS Hospital, Salt Lake City, USA).

We thank other physicians and family members of patients who provided clinical information. The authors thank Mercè Alba, Eva Caballero, and Esther Aguilar for excellent technical support and Romain Marignier (Lyon, France) for providing the M23-AQP expression plasmid.

Funding source: This study was supported in part by a Dutch Cancer Society fellowship (MT), an ErasmusMC fellowship (MT), the Fonds zur Förderung der wissenschaftlichen Forschung, Austria, Project J3230 (RH), the Forschungsförderungsfonds Hamburg Eppendorf Exzellenzjahr (FL), the National Institutes of Health RO1NS077851 (JD), a McKnight Neuroscience of Brain Disorders award (JD), Fundació la Marató TV3 (101530, JD, and 101610, AS), and Fondo de Investigaciones Sanitarias (FIS, PI11/01780 to JD).

The funding sources had no role in the design, collection, analysis, or interpretation of the study, nor in the writing of the publication or decision to submit.

Financial disclosures Dr. Frank Leypoldt has received speaker honoraria from Grifols and scientific funding from Euroimmun, Lübeck, Germany. Dr. Leslie Benson received a National MS Society Clinical Care Fellowship. Dr. Makito Hirano received research support from Grants-in-Aids for Scientific Research from the Ministry of Education, Culture, Sports, Science and Technology of Japan (25461297), and from a University Research Grant

from Kinki University. Dr. Markus Reindl received research support from the Fonds zur Förderung der wissenschaftlichen Forschung, Austria, Projects W1206 and I916. Josep Dalmau has received a research grant from Euroimmun. Josep Dalmau and Myrna Rosenfeld receive royalties from patents for the use of Ma2 and NMDAR as autoantibody tests.

References

1. Dalmau J, Gleichman AJ, Hughes EG, et al. Anti-NMDA-receptor encephalitis: case series and analysis of the effects of antibodies. *Lancet Neurol.* 2008; 7:1091–1098. [PubMed: 18851928]
2. Hughes EG, Peng X, Gleichman AJ, et al. Cellular and synaptic mechanisms of anti-NMDA receptor encephalitis. *J Neurosci.* 2010; 30:5866–5875. [PubMed: 20427647]
3. Mikasova L, De RP, Bouchet D, et al. Disrupted surface cross-talk between NMDA and Ephrin-B2 receptors in anti-NMDA encephalitis. *Brain.* 2012; 135:1606–1621. [PubMed: 22544902]
4. Titulaer MJ, McCracken L, Gabilondo I, et al. Treatment and prognostic factors for long-term outcome in patients with anti-NMDA receptor encephalitis: an observational cohort study. *Lancet Neurol.* 2013; 12:157–165. [PubMed: 23290630]
5. Kruer MC, Koch TK, Bourdette DN, et al. NMDA receptor encephalitis mimicking seronegative neuromyelitis optica. *Neurology.* 2010; 74:1473–1475. [PubMed: 20439851]
6. Lekoubou A, Viaccoz A, Didelot A, et al. Anti-N-methyl-D-aspartate receptor encephalitis with acute disseminated encephalomyelitis-like MRI features. *Eur J Neurol.* 2012; 19:e16–e17. [PubMed: 22182357]
7. Pennington C, Livingstone S, Santosh C, et al. N-methyl D-aspartate receptor antibody encephalitis associated with myelitis. *J Neurol Sci.* 2012; 317:151–153. [PubMed: 22459355]
8. Sellner J, Boggild M, Clanet M, et al. EFNS guidelines on diagnosis and management of neuromyelitis optica. *Eur J Neurol.* 2010; 17:1019–1032. [PubMed: 20528913]
9. Wingerchuk DM, Lennon VA, Pittock SJ, et al. Revised diagnostic criteria for neuromyelitis optica. *Neurology.* 2006; 66:1485–1489. [PubMed: 16717206]
10. Wingerchuk DM, Lennon VA, Lucchinetti CF, et al. The spectrum of neuromyelitis optica. *Lancet Neurol.* 2007; 6:805–815. [PubMed: 17706564]
11. Kitley J, Woodhall M, Waters P, et al. Myelin-oligodendrocyte glycoprotein antibodies in adults with a neuromyelitis optica phenotype. *Neurology.* 2012; 79:1273–1277. [PubMed: 22914827]
12. Mader S, Gredler V, Schanda K, et al. Complement activating antibodies to myelin oligodendrocyte glycoprotein in neuromyelitis optica and related disorders. *J Neuroinflammation.* 2011; 8:184. [PubMed: 22204662]
13. Brilot F, Dale RC, Selter RC, et al. Antibodies to native myelin oligodendrocyte glycoprotein in children with inflammatory demyelinating central nervous system disease. *Ann Neurol.* 2009; 66:833–842. [PubMed: 20033986]
14. McLaughlin KA, Chitnis T, Newcombe J, et al. Age-dependent B cell autoimmunity to a myelin surface antigen in pediatric multiple sclerosis. *J Immunol.* 2009; 183:4067–4076. [PubMed: 19687098]
15. O'Connor KC, McLaughlin KA, De Jager PL, et al. Self-antigen tetramers discriminate between myelin autoantibodies to native or denatured protein. *Nat Med.* 2007; 13:211–217. [PubMed: 17237795]
16. Probstel AK, Dornmair K, Bittner R, et al. Antibodies to MOG are transient in childhood acute disseminated encephalomyelitis. *Neurology.* 2011; 77:580–588. [PubMed: 21795651]
17. Gresa-Arribas N, Titulaer MJ, Torrents A, et al. Antibody titres at diagnosis and during follow-up of anti-NMDA receptor encephalitis: a retrospective study. *Lancet Neurol.* 2013
18. Hoftberger R, Sabater L, Marignier R, et al. An optimized immunohistochemistry technique improves NMO-IgG detection: study comparison with cell-based assays. *PLoS One.* 2013; 8
19. Marignier R, Bernard-Valnet R, Giraudon P, et al. Aquaporin-4 antibody-negative neuromyelitis optica: distinct assay sensitivity-dependent entity. *Neurology.* 2013; 80:2194–2200. [PubMed: 23658379]
20. Reindl M, Di PF, Rostasy K, et al. The spectrum of MOG autoantibody-associated demyelinating diseases. *Nat Rev Neurol.* 2013; 9:455–461. [PubMed: 23797245]

21. Finke C, Kopp UA, Scheel M, et al. Functional and structural brain changes in anti-N-methyl-D-aspartate receptor encephalitis. *Ann Neurol*. 2013
22. Lipton SA. NMDA receptors, glial cells, and clinical medicine. *Neuron*. 2006; 50:9–11. [PubMed: 16600850]
23. Asgari N, Lillevang ST, Skejoe HP, et al. A population-based study of neuromyelitis optica in Caucasians. *Neurology*. 2011; 76:1589–1595. [PubMed: 21536639]
24. Jarius S, Paul F, Franciotta D, et al. Neuromyelitis optica spectrum disorders in patients with myasthenia gravis: ten new aquaporin-4 antibody positive cases and a review of the literature. *Mult Scler*. 2012; 18:1135–1143. [PubMed: 22183934]
25. Martinez-Hernandez E, Horvath J, Shiloh-Malawsky Y, et al. Analysis of complement and plasma cells in the brain of patients with anti-NMDAR encephalitis. *Neurology*. 2011; 77:589–593. [PubMed: 21795662]
26. Haruki H, Sano Y, Shimizu F, et al. NMO sera down-regulate AQP4 in human astrocyte and induce cytotoxicity independent of complement. *J Neurol Sci*. 2013; 331:136–144. [PubMed: 23809190]
27. Dalmau J, Lancaster E, Martinez-Hernandez E, et al. Clinical experience and laboratory investigations in patients with anti-NMDAR encephalitis. *Lancet Neurol*. 2011; 10:63–74. [PubMed: 21163445]
28. Finke C, Kopp UA, Pruss H, et al. Cognitive deficits following anti-NMDA receptor encephalitis. *J Neurol Neurosurg Psychiatry*. 2012; 83:195–198. [PubMed: 21933952]
29. Kayser MS, Titulaer MJ, Gresa-Arribas N, et al. Frequency and characteristics of isolated psychiatric episodes in anti-NMDA receptor encephalitis. *JAMA Neurology*. 2013
30. Yamamoto M, Kokubun N, Watanabe Y, et al. [NMDA receptor encephalitis in the course of recurrent CNS demyelinating disorders: a case report]. *Rinsho Shinkeigaku*. 2013; 53:345–350. [PubMed: 23719981]
31. Sakamoto H, Hirano M, Samukawa M, et al. Details of treatment-related difficulties in men with anti-N-methyl-D-aspartate receptor encephalitis. *Eur Neurol*. 2013; 69:21–26. [PubMed: 23128856]
32. Takeda A, Shimada H, Tamura A, et al. A case of anti-N-methyl-D-aspartate receptor encephalitis with multiple sclerosis-like demyelinated lesions. *Mult Scler Rel Disord*. in press.

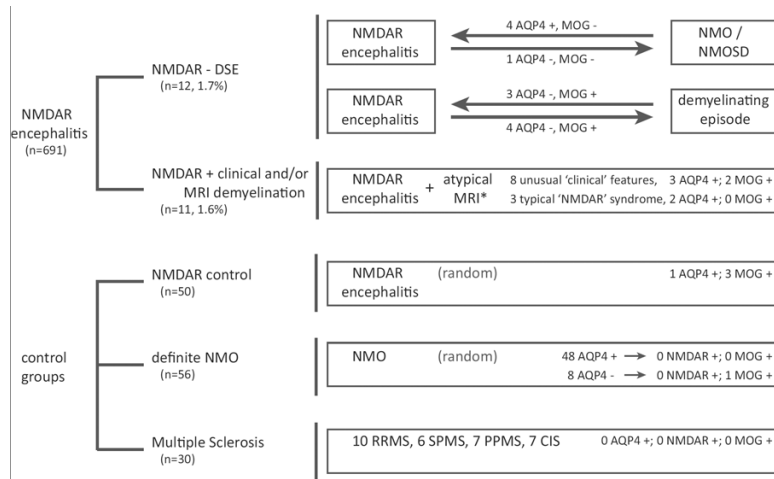


Figure 1.

Flow chart summarizing the patients included in the study

“NMDAR-DSE” or group 1 includes 5 patients with sequential episodes of anti-NMDAR encephalitis and NMO or NMO spectrum disorder (NMOSD), and 7 patients with sequential episodes of anti-NMDAR encephalitis and unusual symptoms and MRI findings suggesting demyelination, but without criteria for NMO or NMOSD. The arrows indicate which of the episodes occurred first, and the profile of antibodies associated with demyelination (AQP4, MOG).

“NMDAR + clinical/MRI demyelination” or group 2, includes 11 patients in whom anti-NMDAR encephalitis developed simultaneously with MRI and/or clinical features of demyelination (8 of them with unusual symptoms for anti-NMDAR encephalitis). Controls include three groups of patients with classical features of anti-NMDAR encephalitis, NMO, or multiple sclerosis (relapsing-remitting [RRMS], secondary progressive [SPMS], primary progressive [PPMS], clinically isolated syndrome [CIS]). All 136 patients were tested for NMDAR, NMO, and AQP4 antibodies and results are shown in the chart.

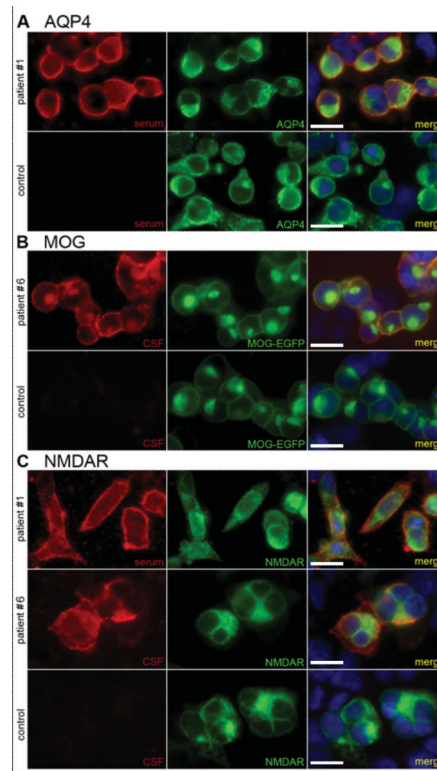
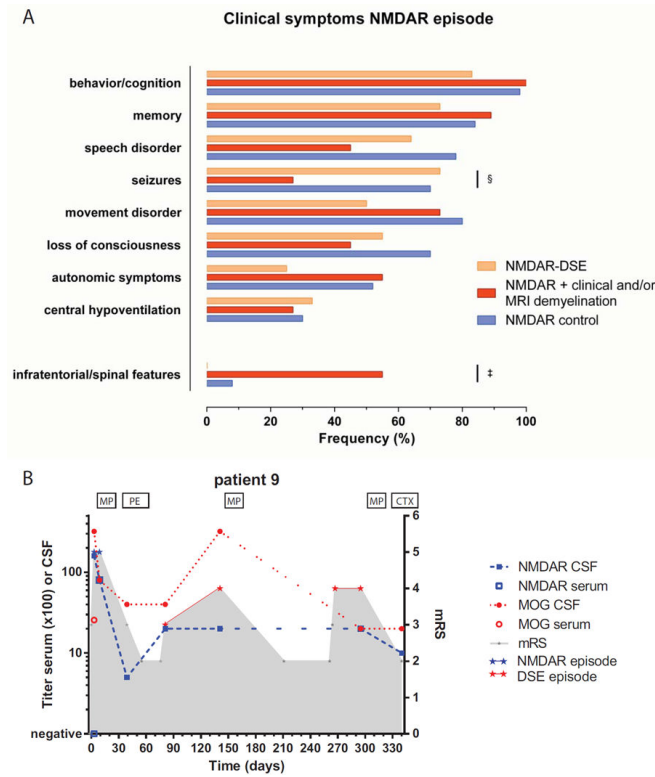


Figure 2.

Demonstration of co-occurrence of NMDAR antibodies with aquaporin 4 (AQP4), or myelin oligodendrocyte glycoprotein (MOG)

HEK293 cells transfected with the AQP4-M23 isoform (A), EGFP-N1-hMOG (B), and GluN1/GluN2B subunits of the NMDAR (C); (A) serum from patient #1 (red) shows reactivity with AQP4-M23 transfected HEK293 cells (green, commercial antibody against AQP4; blue: DAPI; yellow: merged reactivities), in contrast, a control serum is negative. (B) CSF from patient #6 (red) shows reactivity with MOG-EGFP transfected HEK293 cells (green), in contrast, a control CSF is negative. (C) serum from patient #1 and CSF from patient #6, also show reactivity with NR1/NR2B-transfected HEK293 cells (green, commercial antibody against NR1 subunit), in contrast, a control CSF is negative. A–C: magnification $\times 400$, all bars = 10 micrometer.

**Figure 3.**

Clinical symptoms of the anti-NMDAR encephalitis episodes for the three groups of patients.

(A) Comparison of the indicated groups of patients. § $p = 0.031$; ‡ $p = 0.002$. The p -values are uncorrected values.

(B) Clinical course and follow-up of antibodies in a patient with anti-NMDAR encephalitis and DSE with MOG-antibodies.

MP methylprednisolone; PE plasma exchange; CTX cyclophosphamide

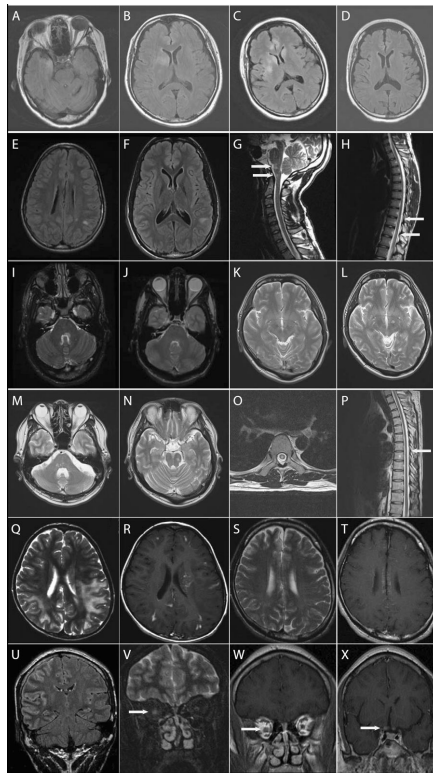


Figure 4.

Brain and spinal cord MRI of patients with anti-NMDAR encephalitis separated in time from demyelinating episodes

(**A–D**) Patient 3 of table 1: Increased T2/FLAIR signal abnormalities involving the right temporal lobe (**A**), caudate nucleus and frontal lobes (**B**), deterioration over time (**C**), and near-resolution after treatment (**D**).

(**E–J**) patient 7: T2/FLAIR increased signal in the left parietal region during Sydenham's chorea (**E**), subtle increase of the area of abnormal signal two weeks into the anti-NMDAR encephalitis (**F**); new T2 lesions in the brainstem and Th9 and Th11–12 during the first demyelinating episode (**G–H**); new T2/FLAIR abnormalities in the left facial collicular region and cerebellum during the second demyelinating episode (**I**), and near-resolution after treatment (**J**).

(**K–P**) patient 9: T2/FLAIR sequences showing no lesions during anti-NMDAR encephalitis (**K**); several new lesions during the first demyelinating episode (**L–M**) and second demyelinating episode (**N**). In the first demyelinating episode there was also involvement of the spinal cord at Th6 (**O–P**).

(**Q–T**) patient 10: increased T2 signal (**Q**) and areas of contrast enhancement (**R**) during an episode of demyelination. Different abnormalities, including increased T2 signal in cortical frontal regions (**S**) without contrast enhancement (**T**) occurred during an episode of anti-NMDAR encephalitis.

(**U–X**) patient 11: increased FLAIR signal in the cortex of the right hemisphere during anti-NMDAR encephalitis (**U**); during a demyelinating episode with symptoms of optic neuritis,

the right optic nerve shows increased T2 signal (**V**) with contrast enhancement (**W**), along with enhancement in pre-chiasmal right and left optic nerves (**X**).

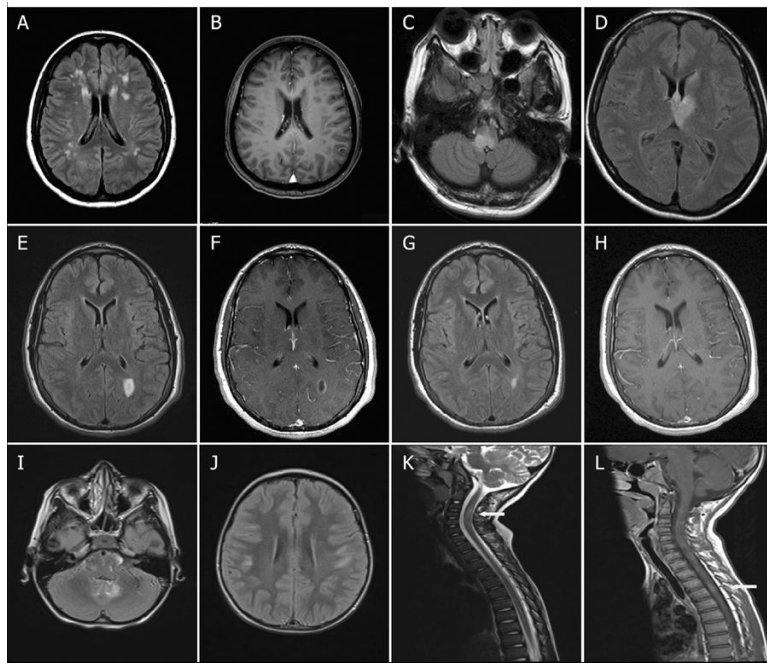


Figure 5.

Brain and spinal cord MRI of patients with anti-NMDAR encephalitis occurring simultaneously with extensive, atypical FLAIR-T2 MRI-abnormalities
(A–B) Patient 17 of table 3, increased T2/FLAIR signal abnormalities involving the periventricular, subcortical white matter **(A)**, with hypointense T1 signals **(B)**.
(C–D) Patient 13, increased FLAIR signal abnormalities in the pons, periventricular region of the fourth ventricle **(C)**, and the third ventricle **(D)**.
(E–H) Patient 22, increased FLAIR signal abnormality in the left parietal region **(E)**, with ring-enhancement with Gadolinium at T1 **(F)**; the abnormality improved after immunotherapy **(G)**, showing resolution of the gadolinium enhancement **(H)**.
(I–L) Patient 19, increased FLAIR signal abnormalities, involving the brainstem **(I)**, subcortical white matter **(J)**, and increased T2 signal in the spinal cord C3–C6 and Th3–Th4 **(K)**, with gadolinium enhancement **(L)**.

Table 1

Clinical features of the episodes of NMDAR encephalitis (A) and the demyelinating syndrome episode (B) in 12 patients in whom these disorders occurred separated in time. None of the patients had a tumor.

No	Age, sex (Ethnicity)	NMDAR-DSE interval (months)	Clinical features of anti-NMDAR encephalitis	mRS max	IS for NMDAR	Best mRS after NMDAR	MRI brain	CSF: WBC per µl/OCB	NMDAR ab (CSF/serum)
(A) Episode of anti-NMDAR encephalitis (NMDAR)									
1	8, F (H)	-84	fluctuating level of consciousness, seizures; later: paranoia, dystonia and orofacial dyskinesias, coma, autonomic symptoms, spasticity	5	st, IVIG, PLEX, CTX, RTX	6 [†]	Multifocal increased T2/FLAIR signal in putamen, internal capsule, subcortical insula, hippocampi and temporal regions; also bilateral optical atrophy and cervical atrophy	11 / +	+ / +
2	13, F (I)	-11	seizures; later: altered behavior, memory and speech dysfunction	5	st	2 (due to NMO)	Transient mild FLAIR increased signal	60 / n.d.	+ / n.d.
3 [*]	37, F (Fi)	-30	depression; behavioral, memory and sleep dysfunction, autonomic symptoms	5	st, PLEX, IVIG, RTX	2	Several areas of increased T2/FLAIR signal in right caudate, right temporal lobe, and frontal lobes	1 / +	+ / -
4	55, F (C)	DSE before & after NMDAR	seizures, blurry vision, encephalopathy; behavioral, memory, speech and sleep disorder, lower level of consciousness	5	st, IVIG	3 (due to NMO)	Unchanged	20 / n.d.	+ / n.d.
5 [§]	15, F (H)	2	seizures, encephalopathy, behavioral and memory dysfunction, dyskinesias, hypoventilation	5	none initially	0	periventricular increased T2/FLAIR signal with Gd-enhancement	420 / +	+ / -

(A) Episode of anti-NMDAR encephalitis (NMDAR)

No	Age, sex (Ethnicity)	NMDAR-DSE interval (months)	Clinical features of anti-NMDAR encephalitis	mRS max	IS for NMDAR	Best mRS after NMDAR	MRI brain	CSF: WBC per μ l/OCB	NMDAR ab (CSF/serum)
6	48, F (NA)	18	behavioral dysfunction, seizures; later: memory deficit and mutism, bradycardia	4	st	2	Few scattered small increased T2/FLAIR signals	150 / +	+ / +
7 [†]	17, M (AA)	3	behavioral dysfunction, insomnia, mutism, catatonia, dyskinesias	5	ECT, st	2	new T2/FLAIR increased signal in right frontal/temporal lobes and left parietal/temporal region (in addition to several increased T2/FLAIR signals in parietal lobes, from 'Sydenham's chorea episode 5 years earlier')	3 / -	+ / n.d.
8 [§]	27, F (I)	-48	confusion, behavioral dysfunction, stupor, orofacial dyskinesias (between DSE 3 and 4)	5	st	0	Increased FLAIR signal in cortical area of right frontal lobe	66 / +	+ / n.d.
9 [§]	34, M (J)	3	behavioral and speech dysfunction, orofacial dyskinesias, intubated	5	st, PLEX	2	Increased T2/FLAIR signal right cerebral peduncle	164 / -	+ / - ^γ
10	10, M (J)	-96	seizures, fever (multiple episodes)	4	st	0	Increased T2/FLAIR signal in the grey matter of frontal lobes	9 / -	+ / -
11	29, M (H)	36	seizures, dysarthria, hemiparesis	3	st	0	Frontotemporal increased T2/FLAIR signal with Gd-enhancement	0 / -	+ / n.d.
12	38, M (J)	-22	1. character change, psychosis, RSD; 2. mild memory change, severe psychosis; 3. cognitive changes, mild psychosis	3	1st st; 2nd st; 3rd st	1 (due to DSE)	1. new T2/FLAIR lesion right temporal subcortical	2 / -	+ / -

Toulaer et al.

(A) Episode of anti-NMDAR encephalitis (NMDAR)

No	Age, sex (Ethnicity)	NMDAR-DSE interval (months)	Clinical features of anti-NMDAR encephalitis	mRS max	IS for NMDAR	Best mRS after NMDAR	MRI brain	CSF: WBC per µl / OCB	NMDAR ab (CSF/serum)	Laer et al
							white matter; 2, unchanged; 3, new increased FLAIR/T2 signals in ri			
							white matter; 2, unchanged; 3, new increased FLAIR/T2 signals in ri			
							white matter; 2, unchanged; 3, new increased FLAIR/T2 signals in ri			
							white matter; 2, unchanged; 3, new increased FLAIR/T2 signals in ri			
							white matter; 2, unchanged; 3, new increased FLAIR/T2 signals in ri			
							white matter; 2, unchanged; 3, new increased FLAIR/T2 signals in ri			

(B) Demyelinating syndrome episode (DSE)

No	Clinical presentation DSE	AQP4 ab titer (CSF / serum)	MOG ab titer ; (CSF / serum)	mRS max	IS for DSE	Best mRS after DSE	MRI brain / spinal cord	FU NMDAR-DSE	Last mRS	Sequela e due to
NMO/NMOSD										
1	1st DSE: bilat ON; 2nd DSE: LETM [‡]	160 / 10240	n.d. / -	5	Untreated	5	n.d. / n.d.	88 mo	6 [‡]	Both
2	recurrent LETM [‡]	160 / n.d.	- / n.d.	4	st, CTX	2	Normal / T2/FLAIR increased signal from medulla to C5	30 mo	2	NMOSD
3	recurrent ON [‡]	320 / 10240	- / -	3	st, IFN	1	Unknown / n.d.	38 mo	5	NMDAR
4	no details available [‡]	- / 20	- / -	5	st, IVIG	3	White matter lesions in brain and spinal cord	36 mo	5	NMOSD
5	10 DSE: several episodes of LETM and ON [‡]	- / n.d.	- / n.d.	5	st, IVIG, PLEX, CTX, RTX, IFN, MMF	0	Periventricular and chiasmatic T2/FLAIR abnormalities with Gd-enhancement; increased T2/FLAIR signal cervical spine	60 mo	1	n.a

Brainstem syndrome

1st DSE: diplopia, abducens paresis; 2nd DSE: vertigo, diplopia

1st DSE: New increase of T2/FLAIR signal in pontomedullary junction with abnormal DWI signal; 2nd DSE: expansion pontomedullary lesion with Gd-enhancement, additional T2/FLAIR abnormalities in brachium pontis, putamen and subcortical white matter with Gd-enhancement / n.d.

(B) Demyelinating syndrome episode (DSE)

No	Clinical presentation DSE	AQP4 ab titer (CSF / serum)	MOG ab titer ; (CSF / serum)	mRMS max	IS for DSE	Best mRS after DSE	MRI brain / spinal cord	FU NMDAR-DSE	Last mRS	Sequelae due to
7	1st DSE: facial palsy, ataxia; 2nd DSE: ataxia, ophthalmoplegia	- / n.d.	16 / n.d.	4	1st DSE: IVIG, MMF; 2nd DSE: IVIG, RTX	2	1st DSE: increased T2/FLAIR signals in internal capsule, pons (facial colliculus), and chiasm; 2nd DSE: additional brainstem and cerebellar abnormalities / increased T2/FLAIR in Th3 and Th9-10	9 mo	2	Both
8	1st DSE: hemihypesthesia; 2nd DSE: diplopia; 3rd DSE: hemiparesis, dysphagia; 4th DSE: numbness, involuntary movements; 5th DSE: aphasia and dysphagia	n.d. / -	2 / 320	5	1st DSE: st; 2nd DSE: st; IFN; 3rd DSE: -; 4th DSE: st; 5th DSE: st, AZA, PLEX	0	1st DSE: Multiple areas of increased T2/FLAIR signal in midbrain and pons; 2nd DSE: new lesion in midbrain; 4th DSE: new lesions in left parietal lobe and medulla / n.d.	108 mo	0	n.a.
Multifocal syndrome										
9	1st DSE: diplopia, thoracic myelitis; 2nd DSE: diplopia, disorientation, fever	n.d. / -	320 / 2560	4	1st DSE: st; 2nd DSE: st, CTX	3	1st DSE: Several areas of increased T2/FLAIR signal: cerebellum, pons, periventricular; 2nd DSE: multiple areas of increased T2/FLAIR signal in cerebellum, pons and cerebral white matter, with Gd-enhancement / 1st DSE: increased T2/FLAIR signal in Th6	22 mo	3	Both
10	hemiparesis, bilateral visual impairment	n.d. / -	160 / 2560	4	st	0	Multiple areas of increased T2/FLAIR signal in white matter of parietal, temporal, occipital lobes, focal Gd-enhancement / n.d.	144 mo	0	n.a.
11	hemiparesis/hypesthesia; later: ON, abnormal behavior, speech and memory	- / n.d.	320 / 320	4	st, IVIG	2	Bilateral increased STIR signal and Gd-enhancement of the optic nerve / n.d.	41 mo [#]	2	DSE
12	DSE 1: hemidysesthesia, ptosis, diplopia, convergence deficit, absent light reflex; DSE 2: diplopia	n.d. / -	40 / 320	2	1st DSE: st, TMZ; 2nd DSE: st	1	DSE 1. T2/FLAIR abnormalities in thalamus, hypothalamus and mesencephalon; DSE 2. new T2/FLAIR abnormalities in thalamus, hypothalamus and mesencephalon, slight Gd-enhancement	60 mo	1	DSE

F female; M male; I Indian; H Hispanic; Fi Filipino; C Caucasian; NA native American; AA Afro-American; J Japanese; RSD REM (rapid-eye movements)-sleep behavioral disorder; AQP4 aquaporin-4; MOG myelin oligodendrocyte glycoprotein; ab antibodies; LETM longitudinal extensive transverse myelitis; ON optic neuritis; NMO neuromyelitis optica; NMOSD neuromyelitis optica spectrum disorder; FLAIR fluid attenuation inversion recovery; DWI diffusion weighted imaging; STIR: Short T1 inversion recovery; Gd gadolinium; Th thoracic; CSF cerebrospinal fluid; WBC white blood cells;

OCB oligoclonal bands; mRS modified Rankin Scale; max maximum; st steroids; IVIG intravenous immunoglobulins; PLEX plasma exchange; RTX rituximab; MMF mycophenolate mofetil; AZA azathioprine; CTX cyclophosphamide; IFN- β interferon- β ; ECT electroconvulsive therapy; TMZ temozolomide; AQP4 aquaporin-4; FU follow-up; n.d. not done; n.a. not applicable.

Titers for AQP4 and MOG are based on the cell-based assay and provided as the reciprocal number of the highest sample dilution where reactivity was visible.

[‡] Patient 1 and 5 fulfill criteria for 'Definite NMO' according to the revised Wingerchuk criteria⁹ and Sellner criteria,⁸ Patient 2–4 are considered 'NMOSD', fulfilling the criteria for definite longitudinal extensive transverse myelitis or recurrent optic neuritis according to the Sellner criteria.⁸

[‡] died 4 months after onset of her anti-NMDAR encephalitis.

^{*} developed myasthenia gravis ten years before neuromyelitis optica (NMO); had thymectomy seven years before onset of NMO.

[†] diagnosed with Sydenham's chorea five years before NMDAR, and post-chorea with Asperger's syndrome and attention deficit hyperactivity disorder (ADHA). These symptoms all vanished after immunotherapy.

[§] patient 5 was published in Krueer et al.,⁵ patient 8 was published in Yamamoto et al.(Japanese),²⁹ patient 9 was published as patient 4 in Sakamoto et al.;³⁰

[‡] titers are shown in Figure 3B.

[#] only three months follow-up after DSE.

Table 2

Main clinical features among the three groups of anti-NMDAR encephalitis patients

	Group 1 NMDAR-DSE	Group 2 NMDAR + clinical and/or MRI-demyelination	Group 3 NMDAR control	p-value *
AQP4 antibodies	4/12	5/11	1/50 (2%)	< 0.0001
MOG antibodies	7/12	2/11	3/50 (6%)	< 0.0001
Male	5/12	2/11	8/50 (16%)	0.18
Median age NMDAR IQR, range	30 (16.3–39.8; 14–55)	19 (13–37; 4–62)	20 (15.8–27.3; 1–46)	0.31
Median age DSE IQR, range	29.5 (13.5–37.8; 9–49)	n.a. n.a.	n.a. n.a.	
Tumor	0/12	1/11	18/50 (36%)	0.011
mRS max (NMDAR)				
5	8/12	7/11	48/50 (96%)	0.001
4	2/12	4/11	2/50 (4%)	
3	2/12	0/11	0/50 (0%)	
Abnormal MRI	12/12	11/11	16/47 (34%)	< 0.0001
Infratentorial or spinal cord abnormalities	8/12	5/11	1/47 (2%)	< 0.0001
Abnormal EEG	8/9	8/10	41/47 (87%)	0.85
Abnormal CSF	9/12	10/11	40/46 (87%)	0.58
OCB	5/10	6/9	15/20 (75%)	0.40

DSE demyelinating syndrome episode; IQR interquartile range; mRS modified Rankin Scale; MRI magnetic resonance imaging; EEG electroencephalography; CSF cerebrospinal fluid; OCB oligoclonal bands; n.a. not applicable

* Median age was compared between groups using the Kruskal-Wallis test; for all other analyses we tested with the Fisher-Freeman-Halton extension of the Fisher-Exact test.

Table 3

Clinical characteristics of the patients with anti-NMDAR encephalitis occurring simultaneously with multifocal or extensive FLAIR-T2 abnormalities

No	Age, sex (Ethnicity)	Clinical features	Atypical features	mRS max	Immunotherapy	NMDAR ab (CSF / serum)	AQP4 ab (CSF / serum)	MOG ab (CSF / serum)	MRI brain / spinal cord	CSF: WBC per μ l / OCB	FU	Last mRS
13 [#]	37, F (I)	fluctuating level of consciousness, change of behavior	bilateral facial & bulbar palsy	5	st, PLEX, IVIG, su	+ / -	>2 / 80	- / -	periventricular (3rd and 4th ventricle) increased FLAIR abnormalities	76 / -	30	3
14	32, F (C)	psychiatric symptoms, depression, irritability, apathy, behavioral changes, attention and language deficit, dysphasia and mild distal myoclonus	gait disturbance	4	Unknown	+ / n.d.	- / 20	- / -	multiple increased T2 signals in cerebellar peduncles, pons, mid brain, pyramidal tracts, thalamus, internal capsules, and lenticular nuclei, with 2 small periventricular areas of Gd-enhancement / increased T2 signals	< 5 / +	20	n.d.
15	16, F (C)	headache, diplopia, anisocoria, vertigo, ataxia, intention tremor, memory deficit, anxiety, depression, insomnia; later hemihyesthesia, dyskinesias, and dysarthria; afterwards hemiballismus, hemiparesis, vomiting and flushing	diplopia, anisocoria, ataxia, vertigo, vomitus; later hemihyesthesia, hemiparesis, ballismus	4	st, IVIG	+ / -	- / 20	- / -	Multiple increased T2/FLAIR signals in the right mesotemporal lobe, cerebellum and thalamus / normal	5 / -	4	4
16*	32, F (C)	memory and behavioral dysfunction, depression	-	4	1. st, IVIG; 2. st, CTX	+ / +	- / 40	- / -	Increased FLAIR signal in hippocampi and caudate nuclei	< 5 / +	48	0
17	47, F (I)	speech disturbance, behavioral change, orofacial dyskinesias, decreased level of	-	5	st, PLEX, IVIG, CTX, RTX	+ / +	n.d. / 20	- / -	Multifocal periventricular, subcortical white matter	25 / n.d.	22	1

No	Age, sex (Ethnicity)	Clinical features	Atypical features	mRS max	Immunotherapy	NMDAR ab (CSF / serum)	AQP4 ab (CSF / serum)	MOG ab (CSF / serum)	MRI brain / spinal cord	CSF: WBC per µl / OCB	FU	Last mRS
18	4, F(H)	consciousness, seizures, tachycardia and hyperventilation seizures, hemiparesis; later: mutism, chorea, orofacial dyskinesias	Hemiparesis	5	st, IVIG	+ / n.d.	n.d. / -	2 / 1280	T2/FLAIR increased signal Multifocal areas of T2/FLAIR increased signal: periventricular, basal ganglia, cerebellum, and pons	< 5 / +	7	2
19	6, M (H)	irritability, personality change, hypersomnia	ataxia, hyperreflexia, Babinski reflexes	5	IVIG	+ / -	n.d. / -	> 5 / 2560	Multifocal areas of increased FLAIR signal: cortex, subcortex, thalamus, basal ganglia, cerebellum, brainstem, cervical, thoracic cord, with small areas of Gd-enhancement	43 / +	2.5	1
20	13, F(H)	confusion, behavioral dysfunction, stupor, orofacial dyskinesias (between DSE 3 and 4)	Leg cramps	5	st, IVIG, RTX	+ / +	n.d. / -	- / -	Multiple subcortical and periventricular T2/FLAIR increased signal abnormalities	18 / -	16	0
21 [†]	18, F (C)	behavioral and speech dysfunction, orofacial dyskinesias, intubated	9 months before encephalitis: hypesthesia in the legs	5	st, IVIG; RTX, CTX, MMF	+ / +	n.d. / -	n.d. / -	Single area of demyelination in the right frontal region (discovered 2 months before onset encephalitis)	40 / +	34	0
22	19, M (C)	seizures, fever (multiple episodes)	Oculogyric crises	5	st, AZA	+ / n.a.	- / n.a.	- / n.a.	Recurrent left parietal T2/FLAIR abnormality with Gd-enhancement	36 / +	36	0

Titulaer et al.

Page 24

Titulaer et al.

No	Age, sex (Ethnicity)	Clinical features	Atypical features	mRS max	Immunotherapy	NMDAR ab (CSF / serum)	AQP4 ab (CSF / serum)	MOG ab (CSF / serum)	MRI brain / spinal cord	CSF: WBC per µl / OCB	FU	Last mRS
23 [‡]	62, F (C)	seizures, dysarthria, hemiparesis	-	4	1. st. IVIG, PLEX; CTX; 2. st. CTX, RTX	+ / n.a.	- / n.a.	- / n.a.	Extensive areas of increased T2/FLAIR signal in temporal and frontal lobes	88 / n.d.	24	3

mRS modified Rankin Scale; max maximum; AQP4 aquaporin-4; ab antibodies; CSF cerebrospinal fluid; WBC white blood cells; OCB oligoclonal bands; FU follow-up; mo months; F female; M male; J Japanese; C Caucasian; H Hispanic; st steroids; PLEX plasma exchange; IVIG intravenous immunoglobulins; su surgery; CTX cyclophosphamide; RTX rituximab; MMF mycophenolate mofetil; AZA azathioprine; FLAIR fluid attenuation inversion recovery; Gd gadolinium; n.d. not determined.

Titers for AQP4 and MOG are based on the cell-based assay and provided as the reciprocal number of the highest sample dilution where reactivity was visible.

[#] had an ovarian teratoma.

^{*} also suffered from discoid lupus; developed an identical relapse 15 months later.

[†] has two sisters with relapsing remitting multiple sclerosis.

[‡] had a purely psychiatric relapse 10 months later.

Table 4

Clinical characteristics of the patients from the control groups with AQP4 or MOG antibodies

No	Age, sex (Ethnicity)	Diagnosis	Clinical features	Atypical features	mRS max	Immunotherapy	NMDAR ab (CSF/ serum)	AQP4 ab (CSF/ serum)	MOG ab (CSF/ serum)	MRI brain/ spinal cord	CSF: WBC per μl/ OCB	FU	Last mRS	Other ab
C1	46, F (J)	NMDAR	Dysarthria, later confusion, delirium, orofacial dyskinesias, hypoventilation, hyperthermia	-	5	st, IVIG	+/+	>2/40	-/-	normal/n.d.	>5/ n.d.	37	2	-
C2	6, M (C)	NMDAR	Seizures, later encephalopathy with cognitive dysfunction, speech disorder and choreiform movements	-	5	St, IVIG, CTX	+/+	n.d./-	n.a./160	subtle increase in T2 signal in subcortical and periventricular parietal cortex / n.d.	42/+	43	1	TPO +
C3	18, F (C)	NMDAR	Respiratory tract infection, followed by confusion with apraxia and behavioral and memory dysfunction; later seizures requiring mechanical ventilation, and orofacial dyskinesias	-	5	st, IVIG, PLEX, CTX, RTX	+/+	n.d./-	2/160	normal/n.d.	100/+	24	1	TPO +, VGCC +
C4	45, F (J)	NMDAR	Psychiatric symptoms, followed by lowered level of consciousness, fever and hypoventilation. Later orofacial dyskinesias, chorea, and hypersalivation	-	5	st	+/+	n.d./-	2/160	normal/n.d.	<5/ n.d.	54	0	-
C5	43, M (C)	SN-NMO	Bilateral ON and 7 days later	-	5	1. st; 2/3 st, AZA; 4. st, MIMF	-/-	n.d./-	16/2560	normal/ increased T2- signal C2-C5	30/-	110	1	TPO +, ANA +

No	Age, sex (Ethnicity)	Diagnosis	Clinical features	Atypical features	mRS max	Immunotherapy	NMDAR ab (CSF / serum)	AQP4 ab (CSF / serum)	MOG ab (CSF / serum)	MRI brain / spinal cord	CSF; WBC per μ l / OCB	FU	Last mRS	Other ab
			LETM; 3 relapses with ON LETM; 3 relapses with ON											Titulae et al.

mRS modified Rankin Scale; max maximum; IS immunosuppressive therapy; NMDAR N-methyl-D-aspartate Receptor; AQP4 aquaporin-4; MOG myelin oligodendrocyte glycoprotein; ab antibodies; CSF cerebrospinal fluid; WBC white blood cells; OCB oligoclonal bands; FU follow-up; mo months; F female; M male; J Japanese; C Caucasian; LETM longitudinal extensive transverse myelitis; ON optic neuritis; st steroids; PLEX plasma exchange; IVIG intravenous immunoglobulins; CTX cyclophosphamide; RTX rituximab; MMF mycophenolate mofetil; AZA azathioprine; FLAIR fluid attenuation inversion recovery; Gd gadolinium; n.d. not done; TPO thyroid peroxidase; ANA anti-nuclear antibodies.

Titers for AQP4 and MOG are based on the cell-based assay and provided as the reciprocal number of the highest sample dilution where reactivity was visible.