

Overlaying Ultrasonographic Images on Direct Vision

George D. Stetten, MD, PhD, Vikram S. Chib

The objective of this technical advance is to permit in situ visualization of ultrasonographic images so that direct hand-eye coordination can be used during invasive procedures. A method is presented that merges the visual outer surface of a patient with a simultaneous ultrasonographic scan of the patient's interior. The method combines a flat-panel monitor with a half-silvered mirror such that the image on the monitor is reflected precisely at the proper location within the patient. The ultrasonographic image is superimposed in real time on the patient, merging with the operator's hands and any invasive tools in the field of view. Instead of looking away from the patient at an ultrasonographic monitor, the operator sees through skin and underlying tissue as if it were translucent. Two working prototypes have been constructed, demonstrating independence of viewer location and requiring no special apparatus to be worn by the operator. This method could enable needles and scalpels to be manipulated with direct hand-eye coordination under ultrasonographic guidance. Invasive tools would be visible up to where they enter the skin, permitting natural visual extrapolation into the ultrasonographic slice. Biopsy needles would no longer be restricted to lie in the plane of the ultrasonographic scan but could instead intersect it. These advances could lead to increased safety, ease, and reliability in certain invasive procedures. **Key words:** tomographic reflection; ultrasonographically guided biopsy; image overlay; augmented reality; visualization; percutaneous.

Abbreviations

CT, computed tomographic; HMD, head-mounted display; 3D, three-dimensional

Received September 11, 2000, from the Department of Bioengineering, University of Pittsburgh, and Carnegie Mellon Robotics Institute, Pittsburgh, Pennsylvania. Revised manuscript accepted for publication November 28, 2000.

Valuable assistance and advice were received from Robert Tamburo, Costa Nikou, Richard LaBarca, Robert Kucler, Reed McManigle, Mark Peterson, Joseph Maroon, and the Medical Robotics and Computer-Assisted Surgery Laboratory at the Carnegie Mellon Robotics Institute. This research was supported by a seed fund grant from Carnegie Mellon University and a grant from the Whitaker Foundation to the Department of Bioengineering at the University of Pittsburgh.

Address correspondence and reprint requests to George D. Stetten, MD, PhD, Department of Bioengineering, University of Pittsburgh, 749 Benedum Hall, Pittsburgh, PA 15261.

Percutaneous ultrasonographically guided intervention encompasses a wide range of procedures in clinical medicine,¹⁻³ including biopsy of the liver,⁴ breast,⁵ lymph nodes,⁶⁻⁸ and thyroid,⁹ as well as central venous access¹⁰ and various musculoskeletal interventions.¹¹ In such procedures, a needle is typically constrained by a guide attached to the transducer so that the entire length of the needle remains visible within the plane of the ultrasonographic scan. The operator must look away from the patient at the ultrasonographic display and use a displaced version of hand-eye coordination. These constraints have motivated research into developing techniques to visually merge ultrasonography with real-world views in a more natural and unconstrained manner.

Fuchs and colleagues have experimented with a head-mounted display (HMD) by following 2 distinct approaches in what they call *augmented reality*. In the first approach, they optically combined a direct view of the patient with ultrasonographic images by using small,

half-silvered mirrors mounted in the HMD.¹² More recently, they have replaced direct vision with miniature video cameras in the HMD, displaying merged video and ultrasonographic images on miniature monitors in the HMD. This second approach permits greater control of the display, although it introduces a significant reduction in visual resolution.^{13–15} In both cases, the HMD and the ultrasonic transducer must be tracked so that an appropriate perspective can be computed for the ultrasonographic images. Head-mounted displays, in general, restrict the operator's peripheral vision and freedom of motion.

In related work, DiGioia et al^{16,17} have merged real-world images with computed tomographic (CT) data while achieving a reduction in the apparatus that the operator must wear. In their system, called *image overlay*, a large, half-silvered mirror is mounted just above the patient with a display monitor fixed above the mirror. Images of CT data on the monitor are reflected by the mirror and superimposed on the view of the patient through the mirror. The operator need only wear a small head-tracking optical transmitter so that a correct perspective of the three-dimensional (3D) CT data can be rendered. Special glasses are needed only if stereoscopic visualization is desired. A tracking device must be attached to the patient to achieve proper registration between the rendered CT data and the patient.

We have modified the approach of DiGioia et al and applied it to ultrasonography with significant simplification. By restricting ourselves to a single tomographic slice in real time (i.e., ultrasonography) and strategically positioning the transducer, the mirror, and the display, we have eliminated the need for tracking either the observer or the patient. This is possible because we are actually merging the virtual image in three dimensions with the interior of the patient.

Ultrasonography produces a tomographic slice within the patient representing a set of 3D locations that lie in a plane. The image of that tomographic slice, displayed at its correct size on a flat-panel display, can be reflected to occupy the same physical space as the actual slice within the patient. If a half-silvered mirror is used, the patient can be viewed through the mirror with the reflected image of the slice superimposed, independent of viewer location. The reflected image is truly occupying its correct location within the patient and does not require a particular

perspective to be rendered. Therefore, we have adopted the term *tomographic reflection* rather than image overlay.

Tomographic reflection has previously been demonstrated on CT data by Masamune et al.¹⁸ A slice through a CT data set is displayed on a flat-panel monitor, with a half-silvered mirror reflecting the virtual image to within the patient. Because the data have already been acquired by a separate CT scanner, the visualization system requires independent registration of the patient's location. Furthermore, the static data do not permit monitoring of changes during a procedure. These restrictions are eliminated by implementing tomographic reflection with a real-time imaging modality such as ultrasonography.

Materials and Methods

We have implemented 2 versions of real-time tomographic reflection using ultrasonography. The first implementation uses an immobilized transducer held by a large frame in a rigid geometric relationship with a half-silvered mirror and a flat-panel monitor (Fig. 1). The second implementation has the same components, but the mirror and display are mounted directly on the transducer to yield a less-clumsy handheld device (Fig. 2). The mobility of the system and other factors are discussed below.

Both versions use the same basic concept. To accomplish tomographic reflection, certain geometric relationships must exist between the slice being scanned, the monitor displaying the slice, and the mirror. As shown in Fig. 3, the mirror must bisect the angle between the slice and the monitor. On the monitor, the image must be correctly translated and rotated so that each point in the image is paired with a corresponding point in the slice to define a line segment perpendicular to, and bisected by, the mirror. By fundamental laws of optics, the ultrasonographic image will thus appear at its physical location, independent of viewer position.

The above concept was implemented using an apparatus consisting of an ultrasonic transducer (3.5 MHz, curvilinear), a flat-panel video monitor (150 MP; Samsung, Seoul, Korea), and a half-silvered mirror (32 × 18 in). The relative positioning of these components is shown in Figure 1A. The ultrasonic transducer and the flat-panel monitor were mounted on opposite sides of the mirror, with each fixed at an angle of 60° relative

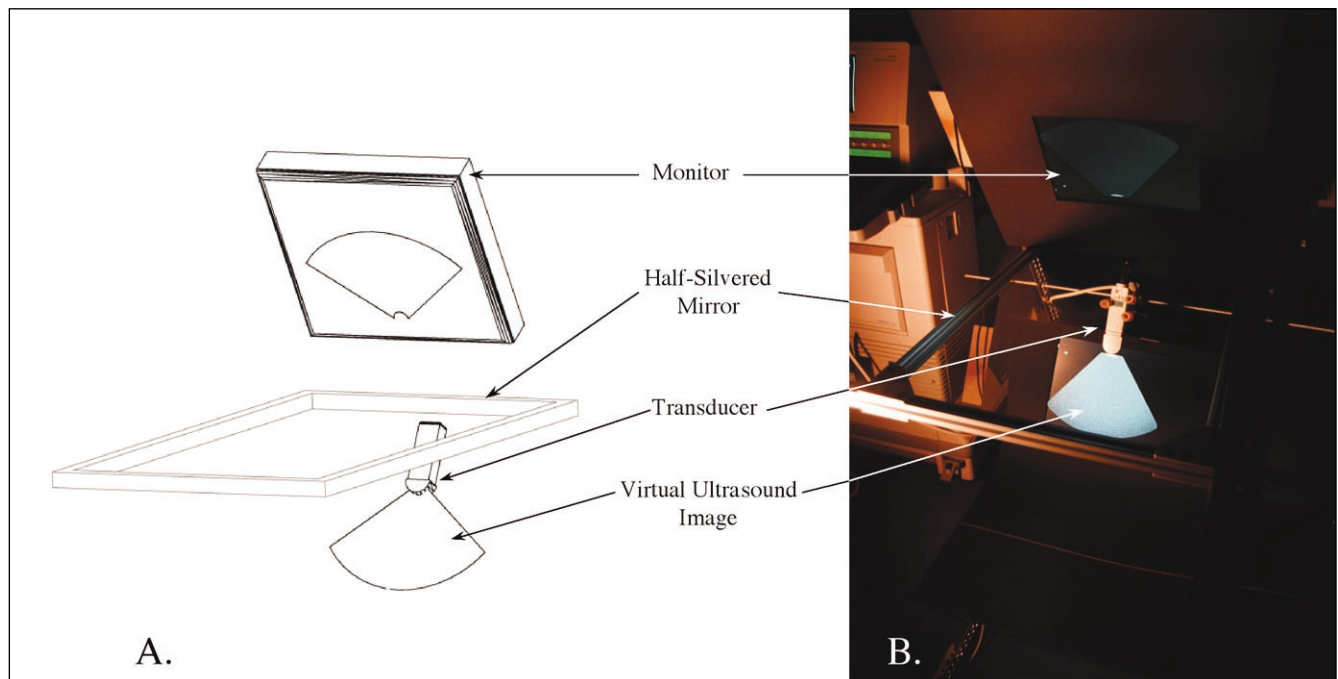


Figure 1. A. Schematic representation of the apparatus. A flat-panel monitor and an ultrasonic transducer are placed on opposite sides of a half-silvered mirror such that the mirror bisects the angle between them. **B.** Photograph of the apparatus with the transducer in the open air generating an empty slice.


to the mirror. The video image produced by the ultrasonographic scanner (5200B; Acoustic Imaging, Phoenix, AZ) was fed through a graphics computer (O₂; SGI, Mountain View, CA) and displayed on the flat-panel monitor. The purpose of the graphics computer was to scale, rotate, and translate the image so that its reflection merged properly with the physical slice. The computer accomplished this video processing continually at a frame rate of approximately 5 frames per second and a latency of approximately 0.2 seconds.

Calibration of the apparatus was accomplished by visual inspection. First, with the transducer pointing into open air and with the gain increased to display an “empty slice,” the transducer was positioned to make the reflected image of the slice appear to emanate correctly from the head of the transducer (see Fig. 1B). A strong sense of the location and orientation of the reflected image relative to the transducer permitted this to be accomplished with confidence. Various targets were then scanned, and adjustments were made to the scale, orientation, and translation on the graphics computer to accomplish visual alignment between the target

and its reflected ultrasonographic image. The calibration, once established, remained effective for subsequent targets.

The apparatus was tested on a number of in vitro and in vivo targets, with the goal of establishing a proof of concept for the overall technique. Several examples are described in the following section. Photographs were taken from

Figure 2. Portable version of the apparatus, with a plastic, half-silvered mirror and miniature flat-panel display mounted directly on the transducer.



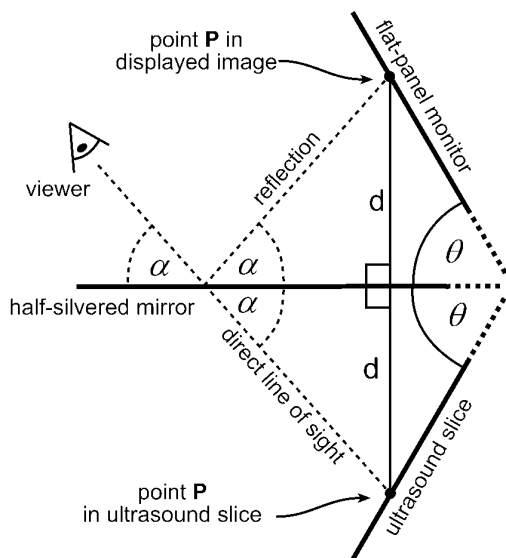


Figure 3. The half-silvered mirror bisects the angle 2θ between the ultrasonographic slice (within the target) and the flat-panel monitor. Point P in the ultrasonographic slice and its corresponding location on the monitor are equidistant from the mirror along a line perpendicular to the mirror (distance = d). Because the angle of incidence equals the angle of reflectance (angle = α), the viewer (shown as an eye) sees each point in the reflection precisely at its corresponding physical 3D location.

Figure 4. Photograph, from the viewpoint of the operator, showing a scan of a hand using the apparatus in Figure 2. The reflected ultrasonographic image is merged with the direct visual image.



the point of view of the operator, i.e., looking through the mirror at the target with the ultrasonographic image reflected in the mirror.

A second apparatus was constructed on the basis of the same principles but with the idea of flexibility in transducer motion. In this apparatus, a small monitor (4-in back-lit video display; Sharp, Mahwah, NJ) and a light plastic, half-silvered mirror (12 × 9 in) were mounted directly on the transducer (see Fig. 2). This apparatus was calibrated in a manner similar to that used with the original apparatus.

Results

The following examples demonstrate the efficacy of the technique and illustrate potential clinical applications. In Figure 4, a human hand is seen with the transducer pressed against the soft tissue between the thumb and index finger. Although not a common target for clinical ultrasonography, the hand was chosen because it clearly demonstrates successful alignment. The external surfaces of the hand are consistent with structures within the ultrasonographic image. The photograph cannot convey the strong sense, derived from stereoscopic vision, that the reflected image is located within the hand. This sense is intensified with head motion because the image remains properly aligned from different viewpoints. To one experiencing the technique firsthand, ultrasonographic targets within the hand are clearly accessible for direct percutaneous injection, biopsy, or incision. The handheld version of the device was used in a similar manner to scan a finger, as shown in Fig. 5.

In Fig. 6, a water-filled balloon was scanned. A protrusion into the balloon, which was produced by the operator's finger, is visible in the ultrasonographic image. Inside the balloon, a short piece of rubber tubing was placed to simulate an artery or vein. The tube is seen in cross section with the end of the operator's finger pressing against it. This demonstrates a combination of tactile and visual feedback that the operator could use to introduce an intravascular catheter. Unlike conventional ultrasonographically guided intervention, in which the needle is restricted to lie within the slice, our system permits the tube to be targeted in cross section, thereby presenting its lumen as a convenient "bull's eye" for catheter insertion.



Figure 5. Scan of a finger using the portable version of the device, as seen through the half-silvered mirror.

Figure 6. Scan of a fluid-filled balloon containing a short piece of rubber tubing (tubing is seen in cross section). The operator's finger is seen pressing into the balloon against the tubing.



Discussion

We have demonstrated a new method for combining human vision with ultrasonographic images in a natural and simple manner. Tomographic reflection is achieved without requiring any special apparatus to be worn by the operator or any tracking of the patient. Furthermore, it is independent of viewer location and permits stereoscopic vision, in effect, to penetrate the skin with ultrasound.

The work to date is presented simply as a proof of concept. Rigorous calibration will be required to quantify and minimize error before clinical applications can be tested. Accurate calibration will be especially important if the method is used to guide interventional procedures. Conventional ultrasonographically guided biopsies, in which the needle is constrained to the slice, are self-calibrating in the sense that refraction and speed-of-sound errors affect the target and the needle equally. This is not true for tomographic reflection, in which such artifacts may lead to inaccuracies during interventional procedures. Other factors such as grating lobes, reverb, speckle, and signal dropout will affect accuracy and efficacy as well.

In our first implementation, the ultrasonic transducer is immobilized. This clearly presents difficulties for the operator accustomed to freely moving the transducer during an examination. We have begun to address this problem in the portable version by mounting the mirror and display directly on the transducer. Further reductions in mass should be possible as lighter displays become available. We plan to pursue an alternate solution to this problem by keeping the mirror immobilized and allowing the transducer to be handheld while tracking its location. A combination of robotic manipulation of the monitor and graphical manipulation of the image would cause the reflected image to remain properly aligned, at least within a limited range of motion. This latter approach, however, would probably not be able to accommodate full rotation of the transducer around its axis.

Superimposing ultrasonographic images on human vision using real-time tomographic reflection may improve an operator's ability to find targets while avoiding damage to neighboring structures, generally facilitating inter-

pretation of ultrasonographic images by relating them spatially to external anatomy. As such, it holds promise for increasing accuracy, ease, and safety during percutaneous biopsy of suspected tumors, amniocentesis, fetal surgery, brain surgery, insertion of catheters, and many other interventional procedures.

References

1. Dodd G, Esola C, Memel D, et al. Sonography: the undiscovered jewel of interventional radiology. *Radiographics* 1996; 16:1271–1288.
2. Sheafor D, Paulson E, Simmons C, et al. Abdominal percutaneous interventional procedures: comparison of CT and US guidance. *Radiology* 1998; 207:705–710.
3. Holm H, Skjoldbye B. Interventional ultrasound. *Ultrasound Med Biol* 1996; 22:773–789.
4. Shah S, Mayberry J, Wicks A, et al. Liver biopsy under ultrasound control: implications for training. *Gut* 2000; 45:628–629.
5. Liu J, Fornage B, Edeiken-Monro B, et al. The reliability of ultrasound-guided core needle biopsy (US-CNB) in the evaluation of non-palpable solid breast lesions [abstract]. *Lab Invest* 1999; 79:26A.
6. Gupta S, Rajak C, Sood B, et al. Sonographically guided fine needle biopsy of abdominal lymph nodes: experience in 102 patients. *J Ultrasound Med* 1999; 18:135–139.
7. Memel D, Dodd G, Esola C. Efficacy of sonography as a guidance technique for biopsy of abdominal, pelvic, and retroperitoneal lymph nodes. *AJR Am J Roentgenol* 1996; 167:957–962.
8. Fisher A, Paulson E, Sheafor D, et al. Small lymph nodes of the abdomen, pelvis, and retroperitoneum: usefulness of sonographically guided biopsy. *Radiology* 1997; 205:185–190.
9. Boland G, Lee M, Mueller P, et al. Efficacy of sonographically guided biopsy of thyroid masses and cervical lymph nodes. *AJR Am J Roentgenol* 1993; 161:1053–1056.
10. Fry W, Clagett G, O'Rourke P. Ultrasound-guided central venous access. *Arch Surg* 1999; 134:738–741.
11. Cardinal E, Chhem R, Beauregard C. Ultrasound-guided interventional procedures in the musculoskeletal system. *Radiol Clin North Am* 1998; 36: 597–604.
12. Azuma R. A survey of augmented reality. *Presence Teleoperators Virtual Environments* 1997; 6: 355–385.
13. State A, Livingston M, Garret W, et al. Technologies for augmented reality systems: realizing ultrasound-guided needle biopsies. *Proceedings of SIGGRAPH 96*; August 4–9, 1996; New Orleans, LA. In: *Computer Graphics Proceedings, Annual Conference Series*. New York, NY: Association for Computing Machinery; 1996:439–446.
14. Fuchs H, State A, Pisano E, et al. Towards performing ultrasound-guided needle biopsies from within a head-mounted display. In: *Proceedings of Visualization in Biomedical Computing*; September 22–25, 1996; Hamburg, Germany; 591–600.
15. Fuchs H, Livingston M, Raskar R, et al. Augmented reality visualization for laparoscopic surgery. *Medical Image Computing and Computer-Assisted Intervention*. In: Wells WM, Colchester A, Delp SL (eds). *Lecture Notes in Computer Science*. Vol 1496. Berlin, Germany: Springer; 1998:934–943.
16. DiGioia A, Colgan B, Koerbel N. Computer-aided surgery. In: Satava R (ed). *Cybersurgery*. New York, NY: Wiley; 1998:121–139.
17. Blackwell M, Morgan F, DiGioia A. Augmented reality and its future in orthopaedics. *Clin Orthop* 1998; 345:111–122.
18. Masamune K, Masutani Y, Nakajima S. Three-dimensional slice image overlay system with accurate depth perception for surgery. *Medical Image Computing and Computer-Assisted Intervention*. In: Delp SL, DiGioia AM, Jaramaz B (eds). *Lecture Notes in Computer Science*. Vol 1935. Berlin, Germany: Springer; 2000:395–402.