

Overview of the mucopolysaccharidoses

Joseph Muenzer¹

Abstract

The mucopolysaccharidoses (MPSs) are a group of rare, inherited lysosomal storage disorders that are clinically characterized by abnormalities in multiple organ systems and reduced life expectancy. The MPSs are heterogeneous, progressive disorders. Patients typically appear normal at birth, but during early childhood they experience the onset of clinical disease, including skeletal, joint, airway and cardiac involvement, hearing and vision impairment, and mental retardation in the severe forms of MPS I, MPS II and MPS VII and all subtypes of MPS III. There are two treatment options for patients with MPS that are directed at the underlying pathophysiology: haematopoietic stem cell transplantation, which is useful for selected patients, and recombinant i.v. enzyme replacement therapy, which is available for MPS I, II and VI. Early diagnosis and treatment can improve patient outcomes and may reduce the disease burden on patients and caregivers. As skeletal and joint abnormalities are characteristic of many patients with MPS, rheumatologists are positioned to recognize the features of the disease and to facilitate early diagnosis and referral. In this overview, the clinical features of the MPS disorders and a brief review of treatment options will be presented in order to aid the rheumatologist in recognizing the features of these rare genetic disorders.

Key words: Mucopolysaccharidoses, Genetic disorder, Glycosaminoglycan, Enzyme replacement therapy, Haematopoietic stem cell transplantation.

Introduction

The mucopolysaccharidoses (MPSs) are a group of rare genetic disorders of glycosaminoglycan (GAG) catabolism [1] (Table 1). Each MPS disorder is caused by a deficiency in the activity of a single, specific lysosomal enzyme required for GAG degradation. These diseases are biochemically characterized by an accumulation of partially degraded GAG within lysosomes and the elevation of GAG fragments in urine, blood [2, 3] and cerebral spinal fluid [4, 5]. The GAG accumulation results in progressive cellular damage, which can affect multiple organ systems and lead to organ failure, cognitive impairment and reduced life expectancy. Of interest to the rheumatologist, skeletal and joint abnormalities are a prominent feature of many of the MPS disorders; patients often present with skeletal dysplasia, decreased joint mobility, short stature and CTS [1].

With the exception of MPS II, the MPS disorders are inherited in an autosomal recessive pattern and affect both

males and females equally. MPS II is an X-linked recessive disorder that generally affects only males, although rare female patients with MPS II have been described [6–8]. This can be caused by an X-autosome translocation and non-random X-chromosome inactivation in a carrier female.

Early diagnosis and treatment can improve outcomes in MPS [9, 11], particularly in those disorders that can be treated with haematopoietic stem cell transplantation (HSCT) and those for which enzyme replacement therapy (ERT) is available (MPS I, II and VI). Yet, because the MPS disorders produce a wide variety of clinical presentations, diagnosis is often delayed, particularly in those patients without cognitive impairment [12]. Even those with severe cognitive and somatic disease may not be diagnosed until 12–18 months after the onset of symptoms, during which time irreversible organ damage can occur. Given the clinical heterogeneity and rarity of MPS, newborn screening may be the key to identifying individuals before the onset of irreversible clinical disease. Newborn screening methods for the MPS disorders and other lysosomal storage disorders are in development. Chamoles *et al.* [13] demonstrated that an MPS I enzyme activity assay based on a fluorescence method can be conducted using 3-mm circles punched from dried blood spots on filter paper. More recently, a direct multiplex assay of

¹Division of Genetics and Metabolism, Department of Pediatrics, University of North Carolina at Chapel Hill, Chapel Hill, NC, USA. Submitted 1 July 2011; revised version accepted 6 October 2011.

Correspondence to: Joseph Muenzer, Division of Genetics and Metabolism, Department of Pediatrics, University of North Carolina at Chapel Hill, Chapel Hill, NC 27599, USA.
E-mail: muenzer@med.unc.edu

TABLE 1 The mucopolysaccharidoses

Disorder	GAG storage material	Deficient enzyme	Gene locus	Genetic inheritance	Incidence per 100 000 live births [16–24]
MPS I (Hurler, Hurler–Scheie, Scheie syndromes)	Dermatan sulphate, heparan sulphate	α -L-iduronidase	4p16.3	Autosomal recessive	0.69–1.66
MPS II (Hunter syndrome)	Dermatan sulphate, heparan sulphate	Iduronate-2-sulphatase	Xq28	X-linked recessive	0.30–0.71
MPS III A–D (Sanfilippo syndrome)	Heparan sulphate	A: heparan N-sulphatase B: α -N-acetylglucosaminidase C: acetyl-CoA: α -glucosaminide acetyltransferase D: N-acetylglucosamine 6-sulphatase	A: 17q25.3 B: 17q21 C: 8p11.1 D: 12q14	Autosomal recessive	A: 0.29–1.89 B: 0.42–0.72 C: 0.07–0.21 D: 0.1
MPS IV A, B (Morquio syndrome)	A: keratan sulphate, chondroitin sulphate B: keratan sulphate	A: galactose 6-sulphatase B: β -galactosidase	A: 16q24.3 B: 3p21.33	Autosomal recessive	A: 0.22–1.3 B: 0.02–0.14
MPS V	Formerly Scheie syndrome, later discovered to be α -L-iduronidase deficiency and allelic to Hurler syndrome				
MPS VI (Maroteaux–Lamy syndrome)	Dermatan sulphate, chondroitin sulphate	Arylsulphatase B	5q11–q13	Autosomal recessive	0.36–1.30
MPS VII (Sly syndrome)	Dermatan sulphate, heparan sulphate, chondroitin sulphate	β -Glucuronidase	7q21.11	Autosomal recessive	0.05–0.29
MPS VIII	A deficiency of glucosamine-6-sulphate was reported in one patient with clinical features of Morquio and Sanfilippo syndromes and assigned as MPS VIII, but this report was subsequently retracted. The MPS VIII term is no longer used.				
MPS IX	Hyaluronan	Hyaluronidase	3p21.3-p21.2	Autosomal recessive	Four cases reported

lysosomal enzymes in dried blood spots by tandem mass spectrometry has been developed [14]. Meikle *et al.* [15] have taken a different approach, developing a multiplexed immune-quantification assay of lysosomal proteins from dried blood spots on filter paper. Some of these methods are under pilot study in the USA, Europe and Australia. In the interim, greater physician awareness of the MPS disorders will enable early, accurate diagnosis and treatment and improve patient outcomes. To this end, this review will describe the pathogenesis, diagnosis and management of the MPS disorders, with an emphasis on those for which ERT has been approved.

Pathophysiology of the MPS disorders

The MPSs are chronic and progressive syndromes that produce a spectrum of signs and symptoms in multiple organ systems. A good example of this is seen in individuals with MPS I. MPS I was also known as Hurler syndrome after being described by Dr Gertrud Hurler in 1919. In 1962, Dr Harold Scheie described a syndrome in adults that resembled a mild version of Hurler syndrome. Scheie syndrome was thought to have a distinct aetiology from MPS I and was designated MPS V. In 1972, Hurler and Scheie syndromes were both determined to be due to a deficiency of α -L-iduronidase [25]. In light of this, it was thought that a mutation of the α -L-iduronidase gene would produce Hurler syndrome, while a different mutation was responsible for Scheie syndrome. An intermediate MPS I phenotype, which was termed Hurler–Scheie syndrome, was speculated to occur when an individual was heterozygous for both a Hurler and a Scheie mutation. Thus MPS I has historically been delineated into three separate diseases on the basis of clinical presentation; that is, Hurler syndrome (severe), Hurler–Scheie syndrome (intermediate) and Scheie syndrome (mild). It is now recognized that there are more than 100 different alleles of the α -L-iduronidase gene that can cause MPS I, and that MPS I—as well as all of the MPS disorders—represents a disease continuum from severe to attenuated. Patients with severe disease have signs and symptoms occurring early in childhood in several different organ systems simultaneously, and these patients will very often have significant cognitive impairment in those MPS disorders for which it is a characteristic [1]. Patients with attenuated disease, on the other hand, have fewer signs and symptoms that occur later, and they typically do not display cognitive impairment. Such patients may remain undiagnosed for years [12].

In the overall presentation, MPS I, II and VII have many similar clinical features [1, 26, 27], although hydrops fetalis resulting in stillbirth or neonatal death may be the most common presentation of MPS VII. This presentation is not generally seen with MPS I or II. Among patients who present after the neonatal period, those with the severe form of MPS I, II and VII have both somatic and cognitive involvement. The skeletal abnormalities seen in these patients are collectively referred to as dysostosis multiplex [28] (Fig. 1). These skeletal changes result in profound loss of joint range of motion, restricted mobility, growth

slowing or arrest in childhood and short stature. Hand and wrist involvement are also common and include decreased wrist range of motion, stiffening of the IP joint and curved finger. These abnormalities cause the hands to take on a claw-like appearance and can result in loss of hand function. Other signs and symptoms include coarse facial features, vision loss [29], hearing loss [30], decreased pulmonary function and obstructive sleep apnoea [31], frequent and recurrent respiratory infections, cardiac disease [32, 33], hepatomegaly and splenomegaly, umbilical and inguinal hernias, chronic diarrhoea, CTS [34], communicating hydrocephalus and spinal cord compression. Unique among the MPS disorders, MPS II patients may have a distinctive skin lesion (pebbling), which is described as ivory-white papules that are 2–10 mm in diameter, often coalescing to form ridges [35] (Fig. 2). In addition to the somatic manifestations, children with severe MPS I, II or VII have extensive cognitive impairment, characterized early in the disease course by globally delayed developmental milestones and a plateau in development, followed by progressive and inexorable regression. Life expectancy is reduced in untreated patients with the severe form of MPS I, II or VII; death generally occurs before 10 years of age in the severe form of MPS I and in the teenage years in the severe form of MPS II. The attenuated form of these disorders, in contrast, can present with mild symptoms in many organ systems or severe symptoms in one or two organ systems coupled with mild symptoms in other organ systems. For example, decreased joint range of motion may be the initial presenting symptom in patients with attenuated disease, but on exam, such patients typically have mild multisystemic disease, which can be easily missed. Patients with attenuated disease have little to no cognitive impairment, and often live into adulthood, although premature death secondary to progressive airway and cardiac disease can occur [36].

As opposed to the extensive somatic involvement seen in MPS I, II and VII, all forms of MPS III present with cognitive and neurological impairment with little or no somatic involvement. This disorder may be recognized in childhood by developmental delays, behavioural difficulties, sleep disturbances and dementia. The mental retardation can be profound in patients with severe disease, with a lack of development of social or communicative skills in early childhood. Such patients eventually enter a vegetative state and generally only live into their second or third decade [1, 37]. Some individual patients with MPS III show only mild-to-moderate developmental delays and behavioural problems [38]. It is quite likely that many mildly affected MPS III patients are not recognized in clinical practice.

Both forms of MPS IV are characterized by a skeletal dysplasia, ligamentous laxity/joint hypermobility, odontoid hypoplasia and short stature, without cognitive impairment. Of interest to the rheumatologist, the skeletal dysplasia is distinct from the dysostosis multiplex seen in MPS I, II and VII. The ligamentous laxity/joint hypermobility associated with MPS IV is also unique among the

Fig. 1 X-ray images of dysostosis multiplex. **(A)** Hips and pelvis of an 8-year-old patient with MPS I. Courtesy of Bianca Link. **(B)** Spine of a 9-year-old patient with MPS I. Courtesy of Bianca Link. **(C)** Hands and **(D)** elbow/forearm of an 18-year-old patient with MPS II. Courtesy of J.M. Fig.1A and B published with permission from Genzyme.

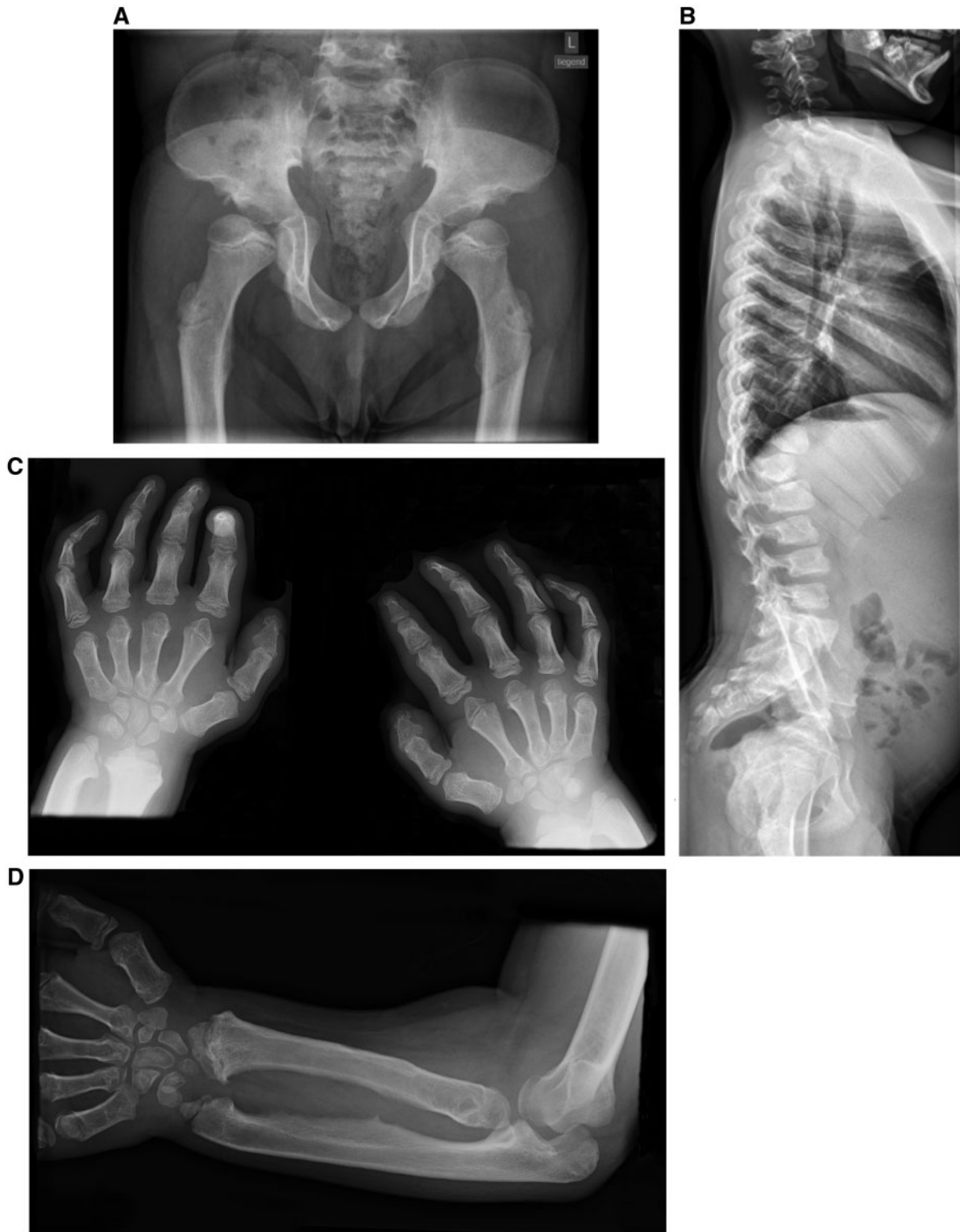
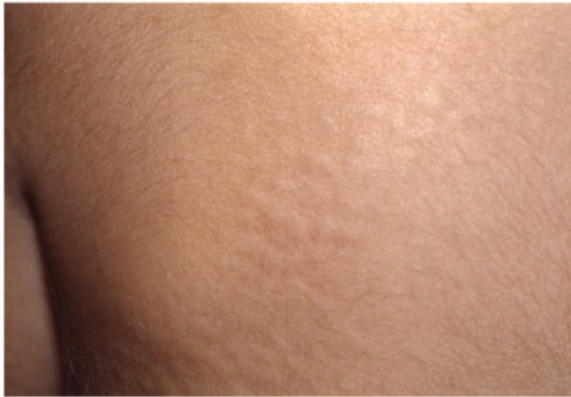

Fig. 2 Skin lesions (pebbling) in a patient with MPS II. This figure is reproduced from Morelli JG. Diseases of the dermis. In: Kliegman RM, Behrman RE, Jenson HB *et al.*, eds. *Nelson Textbook of Pediatrics*, 18th edn. Philadelphia, PA: Saunders Elsevier, 2007, chapter 658, with permission from Elsevier.



MPS disorders, since the other disorders with joint involvement present with stiffness and decreased mobility. Neurological involvement, such as cervical spine instability and communicating hydrocephalus, is common in MPS IV and can be life threatening. Patients with severe MPS IV may live into their second or third decade, and those with attenuated disease may live much longer [39].

Like MPS IV, MPS VI manifests as a purely somatic disease with no primary cognitive involvement; however, the somatic manifestations are similar to those seen with MPS I, II and VII, as described above. As with those disorders, MPS VI patients present with a spectrum of clinical severity. Patients with severe disease show onset before 2 or 3 years of age and impaired mobility by 10 years of age; these patients generally live into their second or third decade [40]. Patients with attenuated or slowly progressing disease typically have later onset of symptoms that often are not recognized until the teenage years or early adulthood, when they may develop skeletal complications and a decrease in their overall functional status. Most patients with attenuated MPS VI will develop some severe manifestations of the disease at some point, such as joint degeneration, cardiac valve disease, sleep apnoea, a decrease in pulmonary function and reduced endurance [40].

Only four cases of MPS IX have been described in the literature [23, 24]. The first case was a 14-year-old female with short stature, who had multiple periarticular soft-tissue masses with occasional swelling and normal joint mobility, mild dysmorphic facial features and frequent episodes of otitis media [23]. The other three recently reported cases are siblings (11–21 years of age) from a single consanguineous family [24]. The patients exhibited only knee and/or hip pain associated with swelling, which began as young as 4 years of age in one sibling. Clinical evaluation demonstrated diffuse joint involvement with an

unusual proliferative synovitis on MRI. Synovial biopsies were notable for an infiltration of macrophages with abundant cytoplasm filled with faintly basophilic vacuoles. The patients were initially diagnosed with JIA, but none responded to standard treatment with NSAIDs. Genome-wide homozygosity mapping identified a 40.52 Mb homozygous stretch within the 3p13–3p22.3 chromosomal region that segregated with the arthropathy and included three hyaluronidase genes. DNA sequencing identified a homozygous deletion in *HYAL1* and enzymatic analysis confirmed a complete deficiency of hyaluronoglucosaminidase (*HYAL1*) activity. The diagnosis of MPS IX should be considered in patients with oligoarticular JIA who fail to respond to anti-inflammatory therapy, a family history of other similarly affected siblings and/or MRI findings of proliferative synovitis without erosions [24].

Predicting disease severity

Predicting disease severity for the MPS disorders remains difficult. Early on, it was hoped that urinary GAG levels might prove to be a useful tool to predict disease severity. It was found, however, that while a higher level is suggestive of more severe disease [41], the urinary GAG level cannot be utilized as a reliable indicator of severity [42]. Genotype–phenotype correlations have been limited by the rarity of the disorders and the large number of mutations, many of which occur only in a single affected family [43]. It is known that in MPS I, patients who are homozygous for a nonsense allele or have two different nonsense alleles have the severe form of MPS I [44]. In MPS II, large deletions or rearrangements always result in a severe disease phenotype [45]. The clinical severity associated with missense mutations and other types of mutations, however, has remained difficult to predict for all the MPS disorders [1, 46].

Diagnosis

As mentioned above, early and accurate diagnosis of the MPS disorders is imperative to optimize treatment outcomes, particularly for those disorders that are amenable to treatment with HSCT or ERT. The measurement of urinary GAG levels is a useful screening test for the MPS disorders. A positive result is very suggestive of an MPS, but false-negative results are very common [47]. False-negative results occur because of a lack of sufficient sensitivity in the various assays and because of samples that are too dilute. Thus a negative urinary GAG analysis does not rule out MPS.

Enzyme activity assays based on cultured fibroblasts, leucocytes, plasma or serum are definitive for a specific MPS disorder and are considered the gold standard for diagnosis. When a sulphatase deficiency is identified, it is recommended that the activity of another sulphatase be measured in order to rule out multiple sulphatase deficiencies [48]. Measurement of enzyme activity in cultivated chorionic villus [49] or amniocytes can be used for prenatal diagnosis, although it may not be uniformly available [50]. Gene sequencing can follow biochemical

diagnosis in order to identify the mutation(s) present. By identifying the gene mutation(s) in the MPS patient, at-risk family members can be offered genetic counselling and genetic carrier testing to allow for more informed family planning.

Treatment options

The management of patients with MPS requires regular assessments, supportive care and a multidisciplinary clinical team that can address a variety of systemic complications. The burden of surgery is often very high for MPS patients with severe somatic involvement [51, 52]. Due to the complexity and rarity of these disorders, patients are best monitored and treated at a facility that has experience treating patients with MPS. In this regard, it is important to note that MPS patients with airway involvement and/or atlanto-axial instability who have to undergo a procedure requiring anaesthesia have a particularly high risk of complications (including death) [53].

Historically, palliative care was the only option for patients with MPS. In 1980, HSCT was first successfully used to treat an MPS disorder when a 1-year-old boy with MPS I received an allogeneic HSCT [54]. Currently, HSCT with bone marrow or umbilical cord blood stem cells has been shown to prevent many of the clinical features of the severe phenotypes of MPS I, VI and VII [55–57]. If performed before developmental deterioration begins in MPS I, successful HSCT can significantly preserve intellectual development in most children who, on the basis of mutational analysis, would have been predicted to develop severe mental impairment [55]. Early, successful HSCT can produce improvements and/or stabilization in upper airway and respiratory function, hearing, vision, cardiac function, hepatosplenomegaly and joint mobility for patients with MPS I, VI or VII [55–59]. The facial features of such children generally also become less coarse. Yet, even when full engraftment does occur, there are certain abnormalities that remain resistant to HSCT treatment and will require intervention, particularly corneal clouding [55], cardiac valvular deformities [58] and skeletal abnormalities [59]. In addition, HSCT does not appear to reverse any cognitive or intellectual deterioration after it has already occurred [62]. Although it has been attempted, HSCT has not shown promise for the treatment of MPS II, III or IV [60–62].

HSCT carries significant risk of morbidity and death. In a large retrospective analysis of 146 patients with MPS I, the mortality rate after first transplant was 15% (22 of the 146 patients). Only 56% of the original cohort (82 of the 146 patients) both survived and had successful engraftment [63]. Historically, fewer patients with MPS VI have undergone HSCT. Early on, this was due to both the rarity of MPS VI and the difficulties in obtaining adequate or optimal HLA-matched donors [64]. More recently, the availability of ERT for MPS VI has reduced the number of patients and families willing to accept the risks of HSCT. Between 1982 and 2007, there were 45 MPS VI patients from around the world registered with the Center for

International Blood and Marrow Transplant Research who received allogeneic stem cell transplantation. The 1-year survival for these patients was 67% [40]. The clinical success of HSCT depends on the age of the child at transplantation, the degree of clinical involvement, the child's cardiopulmonary status and neurological development, the type of donor and the ability to achieve stable engraftment without the development of graft-vs-host disease [62].

Over the last 8 years, ERT with recombinant human enzyme for MPS I, II and VI has been approved in the USA, Europe and many other countries worldwide. As with HSCT, the earlier that ERT is initiated, the better the potential outcome because of the irreversible nature of some of the abnormalities associated with the MPS disorders [10, 11]. This highlights the importance of early and accurate diagnosis and the need for increased disease awareness in physicians who might encounter these patients in clinical practice. The benefits of ERT for certain of the MPS disorders may include improvements in joint mobility, walking ability, and pulmonary and respiratory function; reduction in liver and spleen volume; and significant reduction in urinary GAG excretion [65–70]. ERT administered intravenously does not cross the blood–brain barrier at the labelled doses and has not shown neurocognitive benefit.

The most common adverse events with ERT are infusion-related hypersensitivity reactions that can be characterized by flushing, headache, pyrexia or urticaria. Such reactions are generally managed by slowing the infusion rate and administering anti-histamines and/or steroids [71]. A significant number of patients with MPS who receive ERT are known to develop IgG anti-drug antibodies [65–70]. The significance of these antibodies is unclear; such patients may be at increased risk for infusion-related reactions [71]. In clinical trials, no patients developed IgE anti-drug antibodies [65–70]. Life-threatening anaphylactic reactions have occurred in patients receiving ERT. These can involve respiratory distress, tongue or laryngeal oedema and cardiac failure or arrhythmias [65–70]. Therefore ERT should be administered in a facility with appropriate medical support, and if a severe reaction occurs, the patient should be placed under extended observation [71].

Looking forward

The MPS disorders are progressive, life-threatening diseases with a tremendous impact upon quality of life for both patients and their caregivers. While neither HSCT nor ERT represents a cure, it is clear that the key to altering the natural history of the MPS disorders is early and accurate diagnosis and the development of successful therapeutic interventions aimed at preventing or halting cognitive and somatic deterioration. Many efforts are under way to achieve these goals. Based on the positive somatic data seen with currently available ERT, there has been a push to develop ERT for use in MPS IV and VII as well as to investigate the use of intrathecal ERT in order to

treat spinal cord compression and to prevent neurological decline.

One way that patients can take part in ongoing research efforts is through enrolment in disease-specific registries. Observations made in these international registries will provide insight into the natural history of the disease and the long-term effects of various types of therapy. Such data can be used to better identify the unmet needs of patients as well as to stimulate further research. Registries have been established for MPS I (www.mpsregistry.com), MPS II (www.elapraxe.com/patients_families/about_hunter/outcomes/) and MPS VI (<http://www.naglazyme.com/en/Clinical-resources/surveillance-program.aspx>). These observational databases involve no experimental intervention; patients and their caregivers should be encouraged to enrol even if they are not receiving ERT or HSCT treatment.

Rheumatology key messages

- MPSs are heterogeneous, progressive, multisystemic diseases for which diagnosis is often delayed.
- Rheumatologists may encounter patients with MPSs because of manifestations that mimic rheumatological disorders.
- Greater awareness of MPSs will enable early diagnosis and treatment, which may improve patient outcomes.

Acknowledgements

Writing assistance to J.M. was funded by Shire HGT and provided by Jillian Lokere, MS, of the Curry Rockefeller Group. The author received no payment for his work. This work was supported by Shire Human Genetic Therapies, Inc. The opinions and conclusions set forth herein are those of the authors and do not necessarily represent the views of Genzyme, BioMarin or Shire.

Supplement: This paper forms part of the supplement entitled 'Rheumatologic Aspects of the Mucopolysaccharidoses'. This supplement was supported by joint educational funding from Genzyme, BioMarin Pharmaceutical and Shire Human Genetic Therapies.

Disclosure statement: J.M. has received travel expense reimbursement and honoraria for speaking from BioMarin Pharmaceutical Inc., Shire Human Genetic Therapies, Inc. (HGT) and Genzyme Corporation. He has served on advisory boards and has been a principal investigator for MPS I and MPS II enzyme replacement clinical trials for BioMarin Pharmaceutical Inc., Shire HGT and Genzyme Corporation. He is currently the principal investigator for a Phase I/II intrathecal enzyme replacement clinical trial for the severe form of MPS II sponsored by Shire HGT.

References

- 1 Neufeld EU, Muenzer J. The mucopolysaccharidoses. In: Scriver CR, ed. *The Metabolic and Molecular Bases of Inherited Disease*. New York: McGraw-Hill, 2001:3421–52.
- 2 Tomatsu S, Okamura K, Maeda H *et al*. Keratan sulphate levels in mucopolysaccharidoses and mucopolipidoses. *J Inher Metab Dis* 2005;28:187–202.
- 3 Tomatsu S, Gutierrez MA, Ishimaru T *et al*. Heparan sulfate levels in mucopolysaccharidoses and mucopolipidoses. *J Inher Metab Dis* 2005;28:743–57.
- 4 Federico A, Capece G, Cecio A *et al*. Sanfilippo B syndrome (MPS III B): case report with analysis of CSF mucopolysaccharides and conjunctival biopsy. *J Neurol* 1981;225:77–83.
- 5 Munoz-Rojas MV, Vieira T, Costa R *et al*. Intrathecal enzyme replacement therapy in a patient with mucopolysaccharidosis type I and symptomatic spinal cord compression. *Am J Med Genet A* 2008;146A:2538–44.
- 6 Tuschl K, Gal A, Paschke E *et al*. Mucopolysaccharidosis type II in females: case report and review of literature. *Pediatr Neurol* 2005;32:270–2.
- 7 Sukegawa K, Matsuzaki T, Fukuda S *et al*. Brother/sister siblings affected with Hunter disease: evidence for skewed X chromosome inactivation. *Clin Genet* 1998;53:96–101.
- 8 Cudry S, Tigaud I, Froissart R *et al*. MPS II in females: molecular basis of two different cases. *J Med Genet* 2000;37:E29.
- 9 Peters C. Hematopoietic cell transplantation for storage diseases. In: Blume KG, Forman SJ, Appelbaum FR, eds. *Hematopoietic Stem Cell Transplantation*. Malden, MA: Blackwell Science, 2004:1455–70.
- 10 McGill JJ, Inwood AC, Coman DJ *et al*. Enzyme replacement therapy for mucopolysaccharidosis VI from 8 weeks of age—a sibling control study. *Clin Genet* 2010;77:492–8.
- 11 Schulze-Frenking G, Jones SA, Roberts J *et al*. Effects of enzyme replacement therapy on growth in patients with mucopolysaccharidosis type II. *J Inher Metab Dis* 2011;34:203–8.
- 12 Vijay S, Wraith JE. Clinical presentation and follow-up of patients with the attenuated phenotype of mucopolysaccharidosis type I. *Acta Paediatr* 2005;94:872–7.
- 13 Chamoles NA, Blanco M, Gaggioli D. Diagnosis of alpha-L-iduronidase deficiency in dried blood spots on filter paper: the possibility of newborn diagnosis. *Clin Chem* 2001;47:780–1.
- 14 Gelb MH, Turecek F, Scott CR *et al*. Direct multiplex assay of enzymes in dried blood spots by tandem mass spectrometry for the newborn screening of lysosomal storage disorders. *J Inher Metab Dis* 2006;29:397–404.
- 15 Meikle PJ, Grasby DJ, Dean CJ *et al*. Newborn screening for lysosomal storage disorders. *Mol Genet Metab* 2006;88:307–14.
- 16 Baehner F, Schmiedeskamp C, Krummenauer F *et al*. Cumulative incidence rates of the mucopolysaccharidoses in Germany. *J Inher Metab Dis* 2005;28:1011–7.
- 17 Poorthuis BJ, Wevers RA, Kleijer WJ *et al*. The frequency of lysosomal storage diseases in The Netherlands. *Hum Genet* 1999;105:151–6.

- 18 Meikle PJ, Hopwood JJ, Clague AE *et al.* Prevalence of lysosomal storage disorders. *JAMA* 1999;281:249–54.
- 19 Nelson J. Incidence of the mucopolysaccharidoses in Northern Ireland. *Hum Genet* 1997;101:355–8.
- 20 Nelson J, Crowhurst J, Carey B *et al.* Incidence of the mucopolysaccharidoses in Western Australia. *Am J Med Genet* 2003;123:310–3.
- 21 Lowry RB, Renwick DH. Relative frequency of the Hurler and Hunter syndromes. *N Engl J Med* 1971;284:221–2.
- 22 Applegarth DA, Toone JR, Lowry RB. Incidence of inborn errors of metabolism in British Columbia, 1969–1996. *Pediatrics* 2000;105:e10.
- 23 Triggs-Raine B, Salo TJ, Zhang H *et al.* Mutations in HYAL1, a member of a tandemly distributed multigene family encoding disparate hyaluronidase activities, cause a newly described lysosomal disorder, mucopolysaccharidosis IX. *Proc Natl Acad Sci USA* 1999;96:6296–630.
- 24 Imundo L, Leduc CA, Guha S *et al.* A complete deficiency of hyaluronoglucosaminidase 1 (HYAL1) presenting as familial juvenile idiopathic arthritis. *J Inherit Metab Dis* 2011;34:1013–22.
- 25 Bach G, Friedman R, Weissmann B *et al.* The defect in the Hurler and Scheie syndromes: deficiency of α -L-iduronidase. *Proc Natl Acad Sci USA* 1972;69:2048–51.
- 26 Muenzer J, Wraith JE, Clarke LA *et al.* Mucopolysaccharidosis I: management and treatment guidelines. *Pediatrics* 2009;123:19–29.
- 27 Martin R, Beck M, Eng C *et al.* Recognition and diagnosis of mucopolysaccharidosis II (Hunter syndrome). *Pediatrics* 2008;121:e377–86.
- 28 Taybi H, Lachman RS. *Radiology of Syndromes, Metabolic Disorders, and Skeletal Dysplasias*. Mosby. 4th edn. New York: Mosby-Year Book, 1996:670–81.
- 29 Ashworth JL, Biswas S, Wraith E *et al.* Mucopolysaccharidoses and the eye. *Surv Ophthalmol* 2006;51:1–17.
- 30 Bredenkamp JK, Smith ME, Dudley JP *et al.* Otolaryngologic manifestations of the mucopolysaccharidoses. *Ann Otol Rhinol Laryngol* 1992;101:472–8.
- 31 Muhlebach MS, Wooten W, Muenzer J. Respiratory manifestations in mucopolysaccharidoses. *Paediatr Respir Rev* 2010;12:133–38.
- 32 Farina V, Leva F, Caso P *et al.* Echo-Doppler abnormalities in mucopolysaccharide storage diseases. *Acta Paediatr* 1992;81:702–4.
- 33 Rigante D, Segni G. Cardiac structural involvement in mucopolysaccharidoses. *Cardiology* 2002;98:18–20.
- 34 Haddad FS, Jones DHA, Vellodi A *et al.* Carpal tunnel syndrome in the mucopolysaccharidoses. *J Bone Joint Surg* 1997;79-B:576–82.
- 35 Thappa DM, Singh A, Jaisankar TJ *et al.* Pebbling of the skin: a marker of Hunter's syndrome. *Pediatr Dermatol* 1998;15:370–3.
- 36 Wraith JE. The mucopolysaccharidoses: a clinical review and guide to management. *Arch Dis Child* 1995;72:263–7.
- 37 Barone R, Nigro F, Triulzi F *et al.* Clinical and neuroradiological follow-up in mucopolysaccharidosis type III (Sanfilippo syndrome). *Neuropediatrics* 1999;30:270–4.
- 38 Valstar MJ, Neijs S, Bruggenwirth HT *et al.* Mucopolysaccharidosis type IIIA: clinical spectrum and genotype-phenotype correlations. *Ann Neurol* 2010;68:876–87.
- 39 Northover H, Cowie RA, Wraith JE. Mucopolysaccharidosis type IVA (Morquio syndrome): a clinical review. *J Inherit Metab Dis* 1996;19:357–65.
- 40 Valayannopoulos V, Nicely H, Harmatz P *et al.* Mucopolysaccharidosis VI. *Orphanet J Rare Dis* 2010;5:5.
- 41 Swiedler SJ, Beck M, Bajbouj M *et al.* Threshold effect of urinary glycosaminoglycans and the walk test as indicators of disease progression in a survey of subjects with mucopolysaccharidosis VI (Maroteaux-Lamy syndrome). *Am J Med Genet* 2005;134A:144–50.
- 42 Hopwood JJ, Muller V. Biochemical discrimination of Hurler and Scheie syndromes. *Clin Sci* 1979;57:265–72.
- 43 Terlato NJ, Cox GF. Can mucopolysaccharidosis type I disease severity be predicted based on a patient's genotype? A comprehensive review of the literature. *Genet Med* 2003;5:286–94.
- 44 Scott H, Bunge S, Gal A *et al.* Molecular genetics of mucopolysaccharidosis type I: diagnostic, clinical, and biological implications. *Hum Mutat* 1995;6:288–302.
- 45 Froissart R, Moreira, da Silva I, Guffon N *et al.* Mucopolysaccharidosis type II: genotype/phenotype aspects. *Acta Paediatr Suppl* 2002;91:82–7.
- 46 Tomatsu S, Fukuda S, Sukegawa K *et al.* Mucopolysaccharidosis type VII: characterization of mutations and molecular heterogeneity. *Am J Hum Genet* 1991;48:89–96.
- 47 Mahalingam K, Janani S, Priya S *et al.* Diagnosis of mucopolysaccharidoses: how to avoid false positives and false negatives. *Indian J Pediatr* 2004;71:29–32.
- 48 Hall CW, Liebaers I, Di Natale P *et al.* Enzymatic diagnosis of the genetic mucopolysaccharide storage disorders. *Methods Enzymol* 1978;50:439–56.
- 49 Young EP. Prenatal diagnosis of Hurler disease by analysis of alpha-iduronidase in chorionic villi. *J Inherit Metab Dis* 1992;15:224–30.
- 50 Filocamo M, Morrone A. Lysosomal storage disorders: molecular basis and laboratory testing. *Hum Genomics* 2011;5:156–69.
- 51 Arn P, Wraith JE, Underhill L. Characterization of surgical procedures in patients with mucopolysaccharidosis type I: findings from the MPS I Registry. *J Pediatr* 2009;154:859–64.
- 52 Mendelsohn NJ, Harmatz P, Bodamer O *et al.* Importance of surgical history in diagnosing mucopolysaccharidosis type II (Hunter syndrome): data from the Hunter Outcome Survey. *Genet Med* 2010;12:816–22.
- 53 Muhlebach MS, Wooten W, Muenzer J. Respiratory manifestations in mucopolysaccharidoses. *Paediatr Respir Rev* 2010;12:133–8.
- 54 Hobbs JR, Hugh-Jones K, Barrett AJ *et al.* Reversal of clinical features of Hurler's disease and biochemical

- improvement after treatment by bone-marrow transplantation. *Lancet* 1981;2:709-12.
- 55 Souillet G, Guffon N, Maire I *et al.* Outcome of 27 patients with Hurler's syndrome transplanted from either related or unrelated haematopoietic stem cell sources. *Bone Marrow Transplant* 2003;31:1105-17.
- 56 Herskhovitz E, Young E, Rainer J *et al.* Bone marrow transplantation for Maroteaux-Lamy syndrome (MPS VI): long-term follow-up. *J Inher Metab Dis* 1999;22:50-62.
- 57 Yamada Y, Kato K, Sukegawa K. Treatment of MPS VII (Sly disease) by allogeneic BMT in a female with homozygous A619V mutation. *Bone Marrow Transplant* 1998; 21:629-34.
- 58 Braunlin EA, Stauffer NR, Peters CH *et al.* Usefulness of bone marrow transplantation in the Hurler syndrome. *Am J Cardiol* 2003;92:882-6.
- 59 Weisstein JS, Delgado E, Steinbach LS *et al.* Musculoskeletal manifestations of Hurler syndrome: long-term follow-up after bone marrow transplantation. *J Pediatr Orthop* 2004;24: 97-101.
- 60 Peters C, Krivit W. Hematopoietic cell transplantation for mucopolysaccharidosis IIB (Hunter syndrome). *Bone Marrow Transplant* 2000;25:1097-9.
- 61 Sivakumur P, Wraith JE. Bone marrow transplantation in mucopolysaccharidosis type IIIA: a comparison of an early treated patient with his untreated sibling. *J Inher Metab Dis* 1999;22:849-50.
- 62 Prasad VK, Kurtzberg J. Transplant outcomes in mucopolysaccharidoses. *Semin Hematol* 2010;47:59-69.
- 63 Boelens JJ, Wynn RF, O'Meara A *et al.* Outcomes of hematopoietic stem cell transplantation for Hurler's syndrome in Europe: a risk factor analysis for graft failure. *Bone Marrow Transplant* 2007;40:225-33.
- 64 Rovelli AM. The controversial and changing role of haematopoietic cell transplantation for lysosomal storage disorders: an update. *Bone Marrow Transplant* 2008;41: S87-9.
- 65 Wraith JE, Beck M, Lane R *et al.* Enzyme replacement therapy in patients who have mucopolysaccharidosis I and are younger than 5 years: results of a multinational study of recombinant human alpha-L-iduronidase (laronidase). *Pediatrics* 2007;120:e37-46.
- 66 Clarke LA, Wraith JE, Beck M *et al.* Long-term efficacy and safety of laronidase in the treatment of mucopolysaccharidosis I. *Pediatrics* 2009;123:229-40.
- 67 Muenzer J, Wraith JE, Beck M *et al.* A phase II/III clinical study of enzyme replacement therapy with idursulfase in mucopolysaccharidosis II (Hunter syndrome) [published correction appears in *Genet Med* 2006;8:599]. *Genet Med* 2006;8:465-73.
- 68 Harmatz P, Giugliani R, Schwartz I *et al.* Enzyme replacement therapy for mucopolysaccharidosis VI: a phase 3, randomized, double-blind, placebo-controlled, multinational study of recombinant human N-acetylgalactosamine 4-sulfatase (recombinant human arylsulfatase B or rhASB) and follow-on, open-label extension study. *J Pediatr* 2006;148:533-9.
- 69 Muenzer J, Beck M, Eng CM *et al.* Long-term, open-labeled extension study of idursulfase in the treatment of Hunter syndrome. *Genet Med* 2011;13:95-101.
- 70 Muenzer J, Beck M, Giugliani R *et al.* Idursulfase treatment of Hunter syndrome in children younger than 6 years: results from the Hunter Outcome Survey. *Genet Med* 2011; 13:102-109.
- 71 Burton BK, Whiteman DA. On behalf of the HOS Investigators. Incidence and timing of infusion-related reactions in patients with mucopolysaccharidosis type II (Hunter syndrome) on idursulfase therapy in the real-world setting: a perspective from the Hunter Outcome Survey (HOS). *Mol Genet Metab* 2011;103: 113-20.