



Painful swelling of the index finger

John D. Fitzpatrick¹ · Nikhil Patel¹ · Madhvi Patel¹

Received: 14 November 2021 / Revised: 2 March 2022 / Accepted: 2 March 2022 / Published online: 9 March 2022
© ISS 2022

History:

84 year old female with history of previous pulmonary tuberculosis and ongoing chronic cavitary pulmonary aspergillosis on oral antifungal treatment presents with painful

swelling of the left index finger of weeks/months duration. The alkaline phosphatase (ALP) was noted to be elevated at 615 u/l (reference range of 30 to 160 u/l). A radiograph was performed of the left hand (Figure 1). In addition, a recent CT Thorax was noted (Figures 2 and 3).

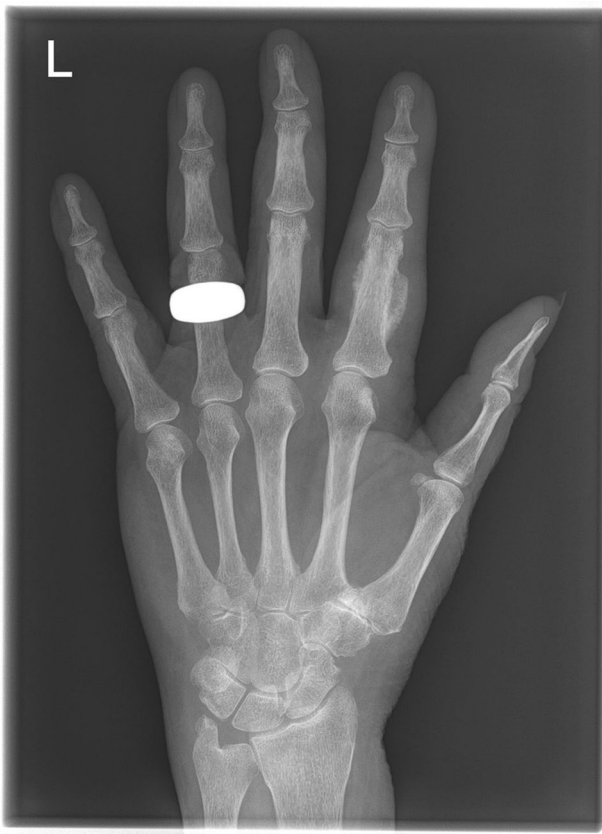

Fig. 1 Radiograph of left hand

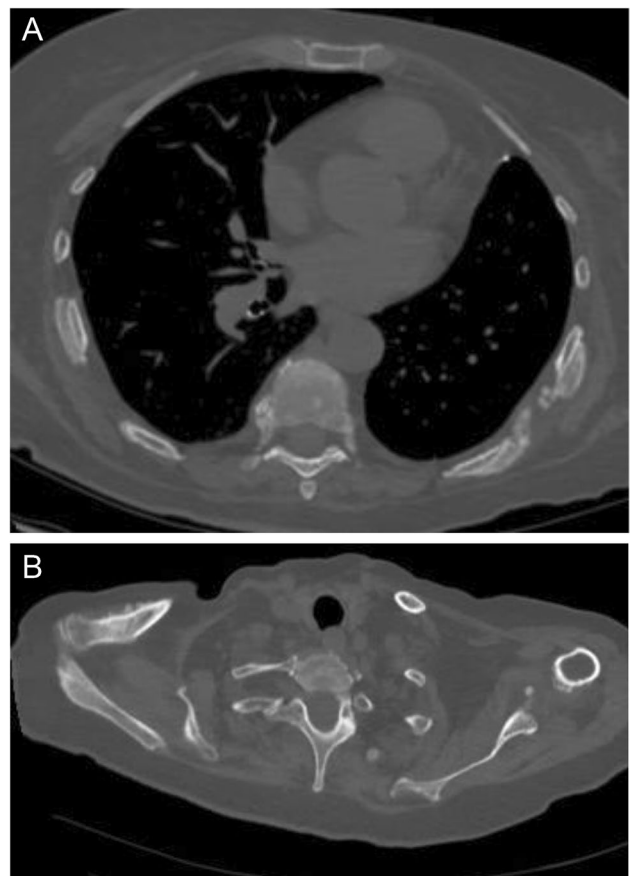


Fig. 2 a+b: CT Thorax

The diagnosis can be found at <https://doi.org/10.1007/s00256-022-04027-3>

✉ John D. Fitzpatrick
john.fitzpatrick2@nhs.net

¹ Radiology Department, St George's Hospital, St George's University Hospitals NHS Foundation Trust, Blackshaw Rd, London SW17 0QT, UK

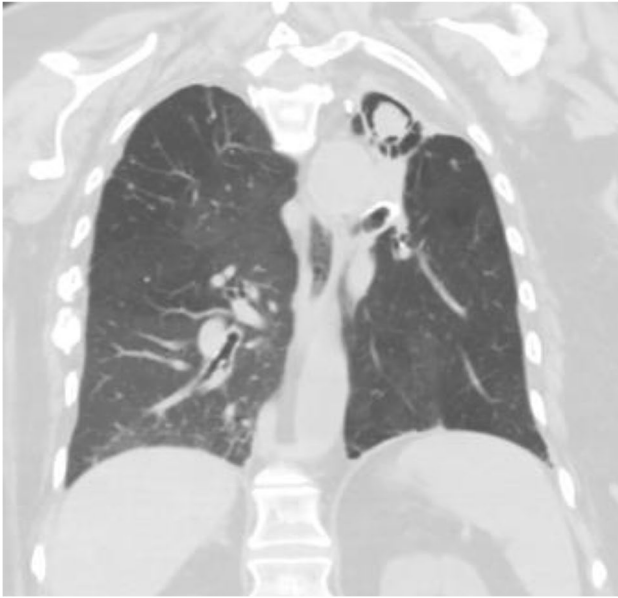


Fig. 3 CT Thorax

Declarations

Conflict of interest The authors declare that they have no conflict of interest.

Publisher's note Springer Nature remains neutral with regard to jurisdictional claims in published maps and institutional affiliations.