

## PARACOCCIDIOIDOMYCOSIS IN CHILDREN WITH DIFFERENT SKELETAL INVOLVEMENT

Nelson Augusto ROSARIO FILHO (1), Flávio Queiroz TELLES FILHO (2), Orival COSTA (1) and Leide P. MARINONI (1)

### SUMMARY

The rarity of paracoccidioidomycosis in childhood prompted us to report two cases with different clinical and radiological skeletal involvement. The number of osteolytic lesions, the presence of periosteal reaction and the finding of *Paracoccidioides brasiliensis* in biopsy specimens, were distinctive features in both cases.

### INTRODUCTION

Paracoccidioidomycosis (South American blastomycosis) is an infectious disease that occurs endemically in Brazil as well as in other Latin American countries. *Paracoccidioides brasiliensis*, its etiologic agent, causes so much illness and mortality among people of both sexes and of all ages that the disease constitutes a major public health problem.

The disease is rare in childhood. In one study of 1,899 patients, 70 (3.68%) were less than 14 years and only 5 (0.26%) were below 7 years of age<sup>2</sup>. In our Institution, Universidade Federal do Paraná, 614 cases of paracoccidioidomycosis have been diagnosed. Among them there were 23 children (4.07%) aged less than 14 years. It is an essentially lymphatic disease in children, with additional gastrointestinal and skeletal involvement. Unlike adults, children seldom develop the pulmonary form of the disease.

The rarity of this disease in children prompted us to report the following two cases with distinctive clinical features.

**CASE 1** — A 3 year-old indian boy was seen with complaints of intermittent low-grade fever of two months duration and presented with multiple abscesses on the posterior iliac

spine, scapula and forehead. This last site produced spontaneous drainage of caseous material. As the disease progressed, several other abscesses developed which were painful but showed no other signs of inflammation. Eventually the patient was unable to walk due to pain.

The child had lost weight and was pale. The liver was palpable 2 cm below the right costal margin, but neither the spleen nor cervical lymph-nodes could be palpated.

A Tine test was weakly positive (7 mm induration). Serum immunoglobulins, EKG, CPK, LDH were normal as were serum glucose, BUN and electrolytes. Bacteriological examination of the drainage material failed to reveal any pathogenic bacteria or mycobacteria. Blood counts showed leukocytes ranging from 13.0 to 27.4 X 10<sup>3</sup> / μl with 10 to 26% bands. Erythrocyte sedimentation rate, C-reactive protein and mucoprotein were persistently abnormal. Radiographic examination of the involved areas showed multiple lytic lesions of a permeative pattern and lamellar periosteal reaction in the diaphysis and metaphysis of several bones. Representative radiographs of lower extremity and chest are shown in Fig. 1. There

(1) Professor Adjunto, Departamento de Pediatria da Universidade Federal do Paraná, Curitiba, PR — Brasil  
(2) Setor de Micologia Médica, Hospital de Clínicas da Universidade Federal do Paraná, Curitiba, PR. — Brasil

were lytic lesions in both the left scapula and the left clavicle, and also a pathologic fracture with callus formation in the later. The lungs were normal. Those findings suggested the diagnosis of paracoccidioidomycosis to the radiologist. However, a thorough search for fungi in culture media and in biopsy specimens of bone and skin was negative. The histopa-

thological findings were of chronic granulomatous ulcer (skin lesion of forehead) and chronic osteomyelitis. An immunologic evaluation disclosed serum precipitating antibodies and delayed hypersensitivity skin reaction to a polysaccharide antigen of *Paracoccidioides brasiliensis*.

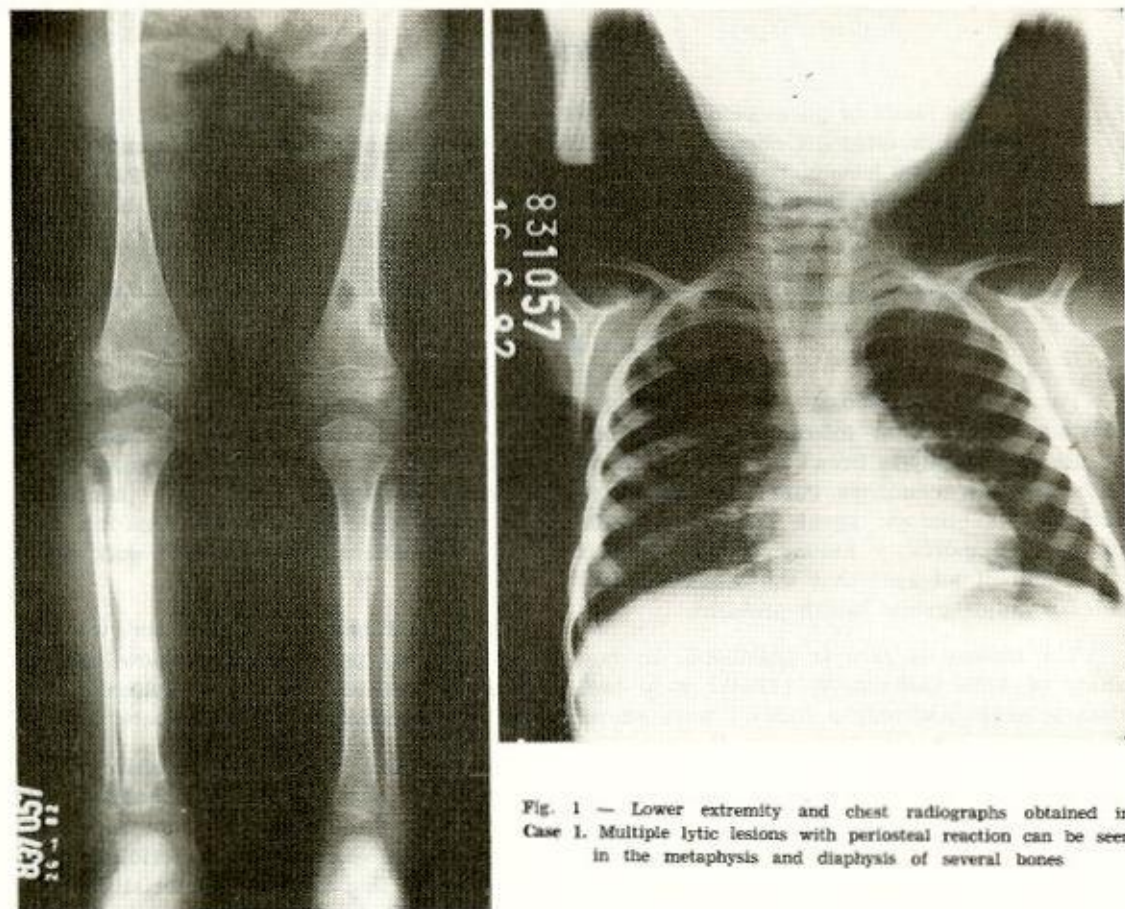


Fig. 1 — Lower extremity and chest radiographs obtained in Case 1. Multiple lytic lesions with periosteal reaction can be seen in the metaphysis and diaphysis of several bones

**CASE 2** — A 5 year-old white boy living in a farm was hit on his left leg by a hog's kick. Two weeks later he developed gradual and painful enlargement of the upper leg with inflammation signs. The radiographs obtained showed an osteolytic lesion in tibia with no marginal sclerosis and little periosteal reaction (Fig. 2). Chest and skeletal examination appeared radiologically normal. Leukocyte counts, erythrocyte sedimentation rate and mucoprotein were elevated. Serum precipitating antibodies were demonstrated. A needle biopsy

of the lesion revealed a granulomatous reaction containing *Paracoccidioides brasiliensis*.

#### COMMENTS

The typical radiological finding in paracoccidioidomycosis is a well delineated osteolytic lesion with little surrounding reaction. It can be observed in any bone, but more frequently it presents in the clavicles, ribs and scapulae<sup>1,7</sup>. In fact, the diagnosis of paracoccidioidomycosis

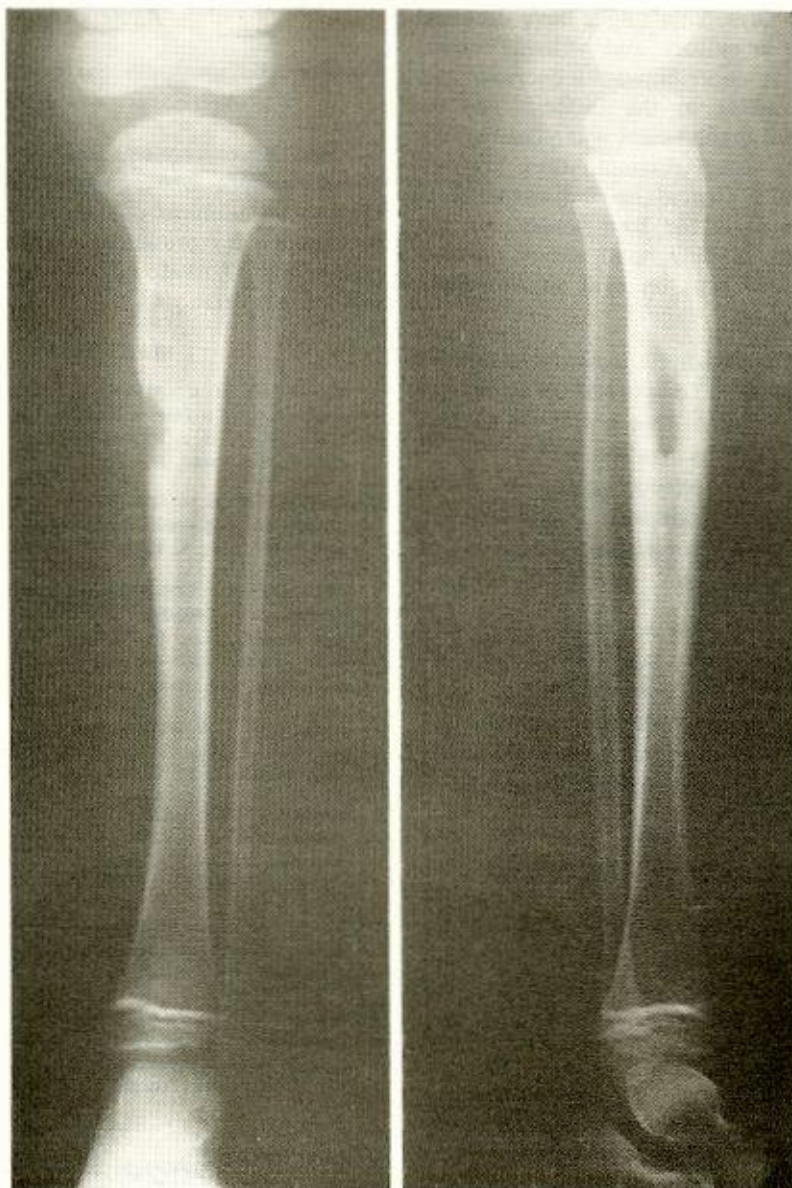


Fig. 2 — Frontal and lateral views of left leg in Case 2. A well delineated lytic lesion was observed in tibia with no marginal sclerosis and little periosteal reaction

can be suggested, as was on both cases, by an experienced radiologist.

The infection can be either localized or its granulomata can be found in any organ. In the event of preserved cell-mediated immunity, the host responds normally with the production of granulomas. Very few parasites, if any, can be observed in these lesions. On the other hand, a compromised cell-mediated immunity is

followed by a systemic disease where the lesions are necrotizing and have plenty of parasites<sup>4,5</sup>.

In Case 1, a positive Tine test and a delayed reaction to the fungus antigen suggested the presence of normal T-cell function. The histopathological findings were taken for chronic granulomatous disease of infancy and the patient was treated with sulfamethoxazol-trime-

thoprim for 30 days. This might have deterred fungus growth in culture and with a normal host response, it contributed to decrease the number of parasites in the lesions. The remarkable skeletal involvement was possibly due to hematogenous fungi dissemination. The patient was initially treated on a hospital-basis with amphotericin B for four weeks. As the lesions subsided quickly and almost healed completely he was kept on oral sulfonamides for two years.

In Case 2, the osteolytic lesion was limited to the site of trauma. The current pathogenetic concept is that trauma does not inoculate the parasite but favours its fixation at that site<sup>3,6</sup>. Admitting that the infectious agent was in the bloodstream, trauma generated a phenomenon known as *locus minoris resistentiae* that could have localized the agent.

Unlike Case 1, there was a single lesion with little periosteal reaction, and *Paracoccidioides brasiliensis* could be demonstrated in bone biopsy. He received ketoconazole daily for 6 months. When cure was achieved it was substitute for sulfonamides, for further 6 months.

The patients described presented with skeletal involvement but minimal systemic manifestation. The number of lytic lesions, the radiographic pattern, and the finding of *Paracoccidioides brasiliensis* made both cases dissimilar. To our knowledge these are the youngest patients ever reported with such presentation.

In spite of its rarity in children, awareness of this possibility should aid in early diagnosis of paracoccidioidomycosis.

## RESUMO

### Paracoccidioidomycose em crianças, com comprometimento ósseo distinto

São apresentados dois casos de paracoccidioidomycose óssea, cujas diferenças eram em relação ao número das lesões, ao aspecto radiológico e à presença do fungo em biópsia das lesões. O relato se deve à raridade desta doença em crianças.

## REFERENCES

1. BARANSKI, M. C.; SILVA, A. F. & RODRIGUES, D. — Lesões ósseas e osteo-articulares. In: DEL NEGRO, G.; LACAZ, C. da S. & FIORILLO, A. M. — *Paracoccidioidomycose*. São Paulo, Sarvier — EDUSP, 1982, pp. 211-219.
2. CASTRO, R. M. & DEL NEGRO, G. — Particularidades clínicas da paracoccidioidomycose na criança. *Rev. Hosp. Clin. Fac. Med. S. Paulo* 31: 194-198, 1976.
3. GIRALDO, R.; RESTREPO, A.; GUTIERREZ, F.; ROBLEDO, M.; LONDONO, F.; HERNANDEZ, H.; SIERRA, F. & CALLE, G. — Pathogenesis of paracoccidioidomycosis: a model based on the study of 46 patients. *Mycopathologia (Den Haag)* 58: 63-70, 1976.
4. MOK, P. W. Y. & GREER, D. L. — Cell-mediated immune responses in patients with paracoccidioidomycosis. *Clin. Exp. Immunol.* 28: 89-98, 1977.
5. MUSATTI, C. C.; REZKALLAH, M. T.; MENDES, E. & MENDES, N. F. — *In vivo* and *in vitro* evaluation of cell-mediated immunity in patients with paracoccidioidomycosis. *Cell. Immunol.* 34: 365-378, 1976.
6. NEGRONI, P. & NEGRONI, R. — Nuestra experiencia de la blastomycosis sudamericana en la Argentina. *Mycopathologia (Den Haag)* 26: 264-272, 1965.
7. SILVA, A. F. — *Contribuição ao estudo da paracoccidioidomycose no Paraná e das lesões ósseas e articulares paracoccidioidicas*. [Tese Livre Docência]. Curitiba, Universidade Federal do Paraná, 1976, 273 p.

Recebido para publicação em 29/10/1984.