

Paragonimus and Paragonimiasis in Korea

Dong Wik Choi

Department of Parasitology, Kyungpook National University
 School of Medicine, Taegu 700-422, Korea

Abstract: The lung fluke, *Paragonimus*, and lung fluke disease, were reviewed, especially on the works performed in Korea. Among 43 species of *Paragonimus* recorded in the world literature, *P. westermani*, *P. pulmonalis*, and *P. iloktsuenensis* are known to distribute in Korea. Biological studies on *P. westermani* have revealed that its snail intermediate host is *Semisulcospira* spp. and major second intermediate hosts are crabs such as *Eriocheir japonicus* and *E. sinensis* or crayfish such as *Cambaroides similis* and *C. dauricus*. The final hosts other than man are dogs, cats, pigs, and wild animals. Paragonimiasis has been known to distribute widely over the south Korea, however, the prevalence among people and intermediate hosts is gradually decreasing in recent years. In Korean people, the lung fluke have caused pulmonary infections in a great many of cases but as well extrapulmonary ones including cerebral, spinal, subcutaneous, hepatic, splenic, abdominal, urinary, gynecologic, and other types. The definite diagnosis of paragonimiasis can be executed by the recovery of eggs from sputum or feces of patients, however, immunological methods such as intradermal test, complement-fixation test, precipitin reactions, immunofluorescent techniques, enzyme-linked immunosorbent assay (ELISA) are greatly helpful for egg-negative or extrapulmonary cases. Various drugs have been introduced for the treatment of paragonimiasis, and among them, bithionol, niclofolan and praziquantel have shown high therapeutic efficacy. The most recommendable one is considered praziquantel. For control of this disease, mass chemotherapy of patients seems to be the most efficient and feasible measure.

Key words: *Paragonimus westermani*, *P. iloktsuenensis*, morphology, biology, distribution, pathology, symptoms, diagnosis, chemotherapy, review

INTRODUCTION

The lung fluke disease in man, paragonimiasis, with accompanying persistent cough, hemoptysis, and chest pain, has been traditionally known as "tojil" or literally "earth-borne disease" by native doctors in Korea. Although a considerable number of papers on the *Paragonimus* and paragonimiasis has been published in Korea, the present review deals mainly with the references reported after the World War II.

Since the case report of abdominal paragonimiasis was published by Choi (1948), almost all of the reports concerning *Paragonimus* in the 1950's were confined to cases of extrapulmonary paragonimiasis or epidemiological studies. Parasitological researches gradually became refined after the establishment of the Korean Society for Parasitology in 1959. Recently, with continuous epidemiological surveys to determine the endemicity of localities, marked advance in research of paragonimiasis have been shown, especially in the immunodiagnostic and chemo-

therapeutic fields.

SPECIES AND MORPHOLOGY

1. Species of *Paragonimus*

From the discovery of *P. rudis* in the lung of an otter by Diesing in 1885 to the report of *P. macacae* by Sandosham in 1953, only 11 additional species have been listed for about a 100-year period. However, 32 new species have been listed during a period of 20 years from *P. skrjabini* in 1959 to *P. westermanni filipinus* in 1979.

Recently, 43 species of *Paragonimus* including *P. westermanni* have been reported in several countries, but some of these are considered as synonyms (Table 1).

According to Miyazaki (1982), 8 species known to develop and cause disease in man are *P. westermanni*, *P. skrjabini*, *P. miyazakii*, *P. heterotremus*, *P. africanus*, *P. uterobilateralis*, *P. mexicanus*, and *P. pulmonalis*. For a few of them, however, the question of synonym remains uncertain. Among these, *P. miyazakii* found in Japan and *P. skrjabini* in China and Thailand do not reach the lung, but the flukes usually develop in ectopic locations, especially in the subcutaneous nodules.

Paragonimus westermanni (Kerbert, 1878) had been believed to be the only species of the genus *Paragonimus* existing in Korea, until Yokogawa *et al.* (1971) reported the species, *P. iloktsuenensis* from the crabs in the delta area of the Naktong River. After the discovery of *P. pulmonalis* (Baelz, 1880) by Miyazaki (1978), the total number of species found to be distributed in Korea was brought to three (Figs. 1, 2 & 3).

It has been known that there are 2 distinct forms, a small and other larger ones, of the lung fluke which have been called *P. westermanni* for a century (Chyu, 1966; Kim *et al.*, 1971; Miyazaki, 1978). Miyazaki (1978) reported that *P. westermanni* has diploid chromosomes ($2n=22$) and bisexual reproduction, while *P. pulmonalis* has triploid chromosomes ($3n=33$) and reproduces

Table 1. Reported species of *Paragonimus* in the world

<i>P. rudis</i> (Diesing, 1850)
<i>P. compactus</i> (Cobbold, 1859)
<i>P. westermanni</i> (Kerbert, 1878)
<i>P. ringeri</i> (Cobbold, 1880)
<i>P. pulmonis</i> (Nakahama, 1883)
<i>P. pulmonalis</i> (Baelz, 1883)
<i>P. kellicotti</i> (Ward, 1908)
<i>P. edwardsi</i> (Gulati, 1926)
<i>P. ohirai</i> (Miyazaki, 1939)
<i>P. iloktsuenensis</i> (Chen, 1940)
<i>P. macacae</i> (Sandosham, 1953)
<i>P. skrjabini</i> (Chen, 1959)
<i>P. yunnanensis</i> (Ho <i>et al.</i> , 1959)
<i>P. miyazakii</i> (Kamo <i>et al.</i> , 1961)
<i>P. szechuanensis</i> (Chung & Ts'ao, 1962)
<i>P. westermanni</i> szechuan variety (Chung & Ts'ao, 1962)
<i>P. macrorchis</i> (Chen, 1962)
<i>P. cenocopiosus</i> (Chen, 1962)
<i>P. fukiensis</i> (Tang & Tang, 1962)
<i>P. cheni</i> (Hu, 1963)
<i>P. heterotremus</i> (Chen & Hsia 1964)
<i>P. tuanshanensis</i> (Chung <i>et al.</i> , 1964)
<i>P. proliferus</i> (Hsia & Chen, 1964)
<i>P. menglaensis</i> (Chung <i>et al.</i> , 1964)
<i>P. hokuoensis</i> (Ho <i>et al.</i> , 1964)
<i>P. siamensis</i> (Miyazaki & Wykoff, 1965)
<i>P. africanus</i> (Voelker & Vogel, 1965)
<i>P. uterobilateralis</i> (Voelker & Vogel, 1965)
<i>P. paishuihoensis</i> (Ts'ao <i>et al.</i> , 1965)
<i>P. bankokensis</i> (Miyazaki & Vajrasthira, 1967)
<i>P. harinasutai</i> (Miyazaki & Vajrasthira, 1968)
<i>P. sadonensis</i> (Miyazaki <i>et al.</i> , 1968)
<i>P. caliensis</i> (Little, 1968)
<i>P. mexicanus</i> (Miyazaki & Ishii, 1968)
<i>P. peruvianus</i> (Miyazaki <i>et al.</i> , 1969)
<i>P. amazonicus</i> (Miyazaki <i>et al.</i> , 1973)
<i>P. hueilungensis</i> (Chung <i>et al.</i> , 1975)
<i>P. inca</i> (Miyazaki <i>et al.</i> , 1975)
<i>P. westermanni ich'unensis</i> (Chung <i>et al.</i> , 1977)
<i>P. filifinus</i> (Miyazaki, 1978)
<i>P. philippinensis</i> (Ito <i>et al.</i> , 1978)
<i>P. ecuadoriensis</i> (Volker & Arzube, 1979)
<i>P. westermanni filipinus</i> (Miyazaki & Habe, 1979)

parthenogenetically (Table 2). They are also separated by the contents of the seminal recep-

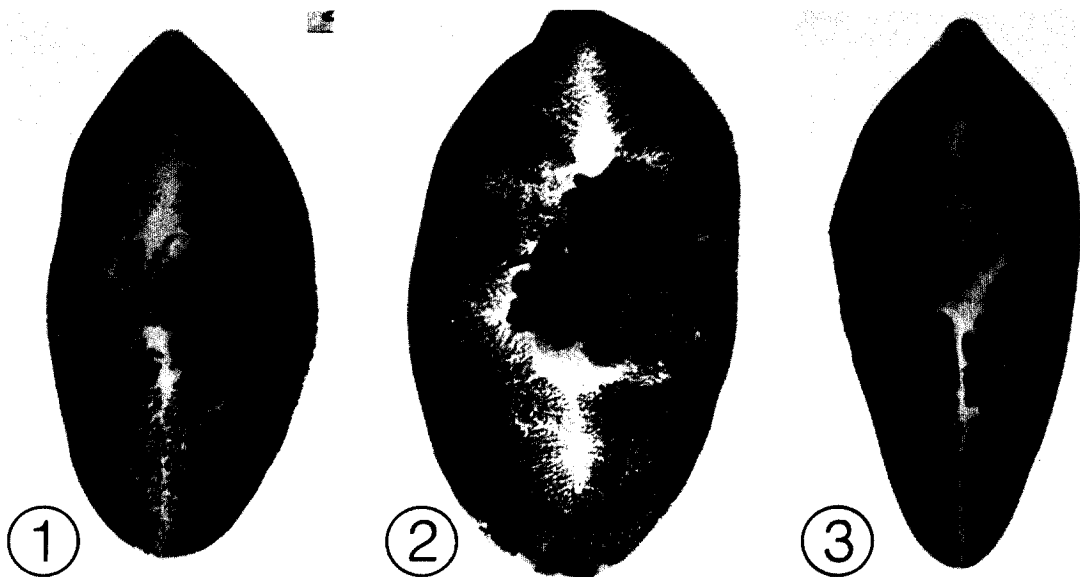


Fig. 1. *P. westermani*.

Fig. 2. *P. pulmonalis*.

Fig. 3. *P. iloktsuenensis*.

(from Professor Ishii, Y., Kyushu University, Japan)

tacle; it is filled with sperms in bisexual form, while in the parthenogenetic form, it is occupied by eggs and vitelline cells instead of sperms. He also noticed that in *P. westermani*, the eggs, larvae, and adults are smaller and were found mainly in tropical Asia, whereas *P. pulmonalis* is distributed mainly in Japan, Korea, and Taiwan.

However, Yokogawa(1982) proposed that *P. pulmonalis* might be a synonym of *P. westermani*. At present, it has been clarified by Miyazaki (1978) that there are two forms of *P. westermani* in Korea. Miyazaki(1978 & 1979) stressed in recent years that the validity of *P. pulmonalis* has been recognized by population genetics and cytological studies. Ihm and Ahn(1979) reported, supporting Miyazaki's opinion, that the majority in Korea is of the parthenogenetic type.

2. Ultrastructure

In this review, only ultrastructural studies of

the *Paragonimus* species found in Korea will be dealt with, although there have been several papers on the morphology of *Paragonimus* species at various stages through light microscopy.

Lee *et al.* (1981) observed the teguments of a 3-week-old juvenile and a 3-month-old adult *P. westermani* through scanning and transmission electron microscopes. The ultrastructural differences of tegument by worm growth and development outlined were as follows. The scale-like spines observed irregularly around the oral sucker of the juvenile, remained in the adult. The surface of the juvenile was seen wrinkled irregularly, whereas that of the adult looked flat and smooth. As the juvenile grew and developed to an adult, the valleys disappeared, the tips of the protoplasmic knobs became wide, and the spines were well-protruded. The findings of the transmission electron microscope corresponded well with those of the scanning electron micro-

Table 2. Two types of *Paragonimus westermani*(Kerbert, 1878) reported by Miyazaki in 1978

Type	Worm size	Chromosome	Reproduction	Spermatogenesis
<i>P. pulmonalis</i>	large group	triploid 3n=33	parthenogenetic	none or few
<i>P. westermani</i>	small group	diploid 2n=22	bisexual	abundant

scope. Choi and Yoo(1985) reported findings similar to those of Lee *et al.*(1981).

Kim *et al.* (1987) undertook ultrastructural studies on the surface of excysted *P. westermanni* metacercaria and identified 3 types of sensory papillae; large (3~5 μm) domed papillae distributed on the oral (12~13 in number) and the ventral (6 in number) suckers only, small (2~3 μm) domed papillae distributed symmetrically on the ventral (30~32 pairs) and dorsal (40~42 pairs) surfaces, and ciliated papillae (0.8~1.5 μm) found around the oral sucker (5~6 in number) and on the ventral and dorsal surfaces of the body (3~5 pairs on each surface). Single pointed spines were found to cover the entire surface of the excysted metacercaria except around the excretory pore. The spines were longer and more populous in their distribution on the anterior part of the body than those on the posterior part. The spines were found to originate from near the basement membrane of the tegument.

Lee *et al.* (1989a) observed the tegumental ultrastructures of *P. iloktsuenensis* according to its developmental stages. The excysted metacercariae were typically gourd-shaped, with their whole body surface beset with numerous spade-shaped spines. The large, type II sensory papillae (non-ciliated round swellings) were seen arranged along the rim of the oral and ventral suckers, 11~12 and 6~8 in number respectively. Two-week old juveniles, slender in shape and with more populous tegumental spines than in the newly-excysted metacercaria, were found to be beset with numerous ciliated knob-like type I papillae on both sides of the oral sucker, along with 6 large, type II papillae along the rim of the ventral sucker. On 4-week old worms, with grouped spine on the ventral surface, the type I and type II papillae were distributed chiefly around the rim of the 2 suckers. On the dorsal surface of an eight-week old adult, covered densely with bear-foot-like spines, cobblestone-like cytoplasmic processes were well-developed.

BIOLOGY AND LIFE CYCLE

The adult *Paragonimus* is usually harbored encapsulated in pockets of the lungs and less frequently in the other organs. The eggs deposited by the adult escape from the pulmonary pockets through the bronchioles, are voided in the sputum, or are swallowed and passed in the feces. The discharged eggs require at least 2 weeks for complete embryonation and hatching, and the miracidia escape to become free-swimming.

After entering the appropriate snail host, a sporocyst and 2 redia generations are produced, followed by the development of microcercous cercariae, about 20 of which may be seen at one time within the redia during a period of several weeks (Choi *et al.*, 1982). When the crustacean host ingests the snail, host infested with the cercariae, the cercariae encyst to become metacercariae, usually in the vessels of the gills, liver, and muscles of the cephalothorax of the crustacean host. Sometimes the cercariae, after leaving the snail, penetrate the crustacean host.

It was reported that the genus *Semisulcospira* snail plays a role as the first intermediate host, while the crabs, *Eriocheir japonicus* and *E. sinensis*, the crayfish, *Cambaroides similis* and *C. dauricus* (found in North Korea), and the shrimp, *Macrobrachium nipponensis*, play roles as the second intermediate hosts of *Paragonimus westermanni* in Korea (Soh, 1962; Soh *et al.*, 1964b & 1966; Chyu, 1966; Chyu and Lee, 1966; Kim, 1984; Chung, 1983). Seo and Kwak (1972) indicated that the second intermediate host of *P. iloktsuenensis* is *Helice tridens* and *Sesarma dehaani* in Korea.

When the definitive host ingests the raw flesh of the second intermediate host infested with the metacercariae, the metacercariae excyst in the small intestine, especially in the duodenum, migrate through the intestinal wall, and reach the abdominal cavity in 3~6 hours. They enter and remain in the abdominal wall for several days before migration through or around the

diaphragm to the pleural cavity and lungs, finally arriving at the vicinity of the bronchioles where they develop to adult worms. Lee(1966) suggested that the excysted metacercariae in the abdominal muscle seemed not to return to the peritoneal cavity but migrate upward along muscle fibers, while the worms inoculated into various parts of the body showed a tendency to migrate toward the thoracic cavity without regard to the suitability of the animals as experimental hosts.

The natural definitive hosts of *Paragonimus westermani* other than man include such felines as tigers, lions, domestic cats, wildcats, leopards, and some domestic animals like dogs and pigs (Min, 1981), whereas the host of *P. iloktsuenensis* is the rat (Seo and Koo, 1971). Mice, guinea pigs, cats and dogs are known to be experimental definitive hosts of *P. iloktsuenensis* (Seo and Kwak, 1972; Seo and Lee, 1973; Lee *et al.*, 1989b).

As for the distribution of adult *P. westermani* in dogs, Soh *et al.* (1962) revealed that the flukes were found in the thoracic cavity and viscera including the lungs 84.0%, from the abdominal cavity and viscera 15.0% and in arachnoidal tissue 0.2%. Lee *et al.* (1976) reported that only 15.8% of the immature worms reached the pleural cavity or lungs of unfavorable hosts, such as mice, gerbills, hamsters, rats and rabbits.

As for the biological studies on *P. iloktsuenensis*, Seo and Kwak(1972) reported that the recovery and infection rates for *P. iloktsuenensis* in mice were relatively high, although the worms recovered were immature. Seo and Lee(1973) reported that the recovery rate for *P. iloktsuenensis* from rats was between 6.7% and 25.0%. Lee *et al.* (1989b) found that the recovery rates in cats and dogs were 12.7% and 21.0%, respectively. Kang *et al.* (1975) reported that the density pattern of the metacercariae in *Sesarma dehaani* was well fitted to the negative binomial distribution.

Several biochemistry studies have been carried out to determine the metabolism of *Paragonimus*. Kang *et al.* (1963) suggested that there seemed to be a tissue specificity in the distribution of

glycogen, nucleic acids, fat, and polyphenol oxidase in its body. Chun(1966) demonstrated the activity of polyphenol oxidase from the vitelline gland and eggs of the fluke by histochemical method. Kang *et al.* (1965a) found that adult *P. westermani* ingested Cr⁵¹-tagged RBC in cats and dogs. Park(1971) found that muscular organs such as the suckers and pharynx showed considerable density of exogenous C¹⁴-glucose compared with other organs. Ahn and Seo(1972) detected several kinds of amino acids and organic acids from the homogenate of the fluke incubated in a medium containing 1 μ Ci/ml of D-C¹⁴-glucose by paper chromatography.

Lee(1963) revealed 13 amino acids from the cyst content and body constituents of *P. ohirai*. Lee *et al.* (1964) detected alanine, methionine, valine, leucine, lysine, arginine, tyrosine, proline, and histidine from the hydrolysate of *P. westermani*. Min and Seo(1966) found that the activity of the transaminases, GOT and GPT in *P. westermani* was higher than that of such lumen-dwelling trematodes as *Clonorchis sinensis* and *Eurytrema pancreaticum*. Lee(1967) revealed that the lactic dehydrogenase activity in *P. westermani* increased as the incubation temperature or substrate concentration increased. Lee and Seo(1967) also determined the activity of malic dehydrogenase and reported results similar to those of Lee(1967). Chu *et al.* (1972) revealed that carbonic anhydrase in *P. westermani* was distributed in the mucous membrane, vitelline gland cells, and the eggs. Huer *et al.* (1985) reported that the protein composition of *P. westermani* showed profound changes at 8 and 12 weeks after infection.

GEOGRAPHICAL DISTRIBUTION

The geographic distribution of *P. westermani* in Korea is shown in Figs. 4 & 5.

A number of surveys to determine the infestation status of the first and the second intermediate hosts, fresh-water snails, and crayfish (sometimes crabs and shrimps) with the larvae of *Paragonimus* have been carried out. Fig. 4

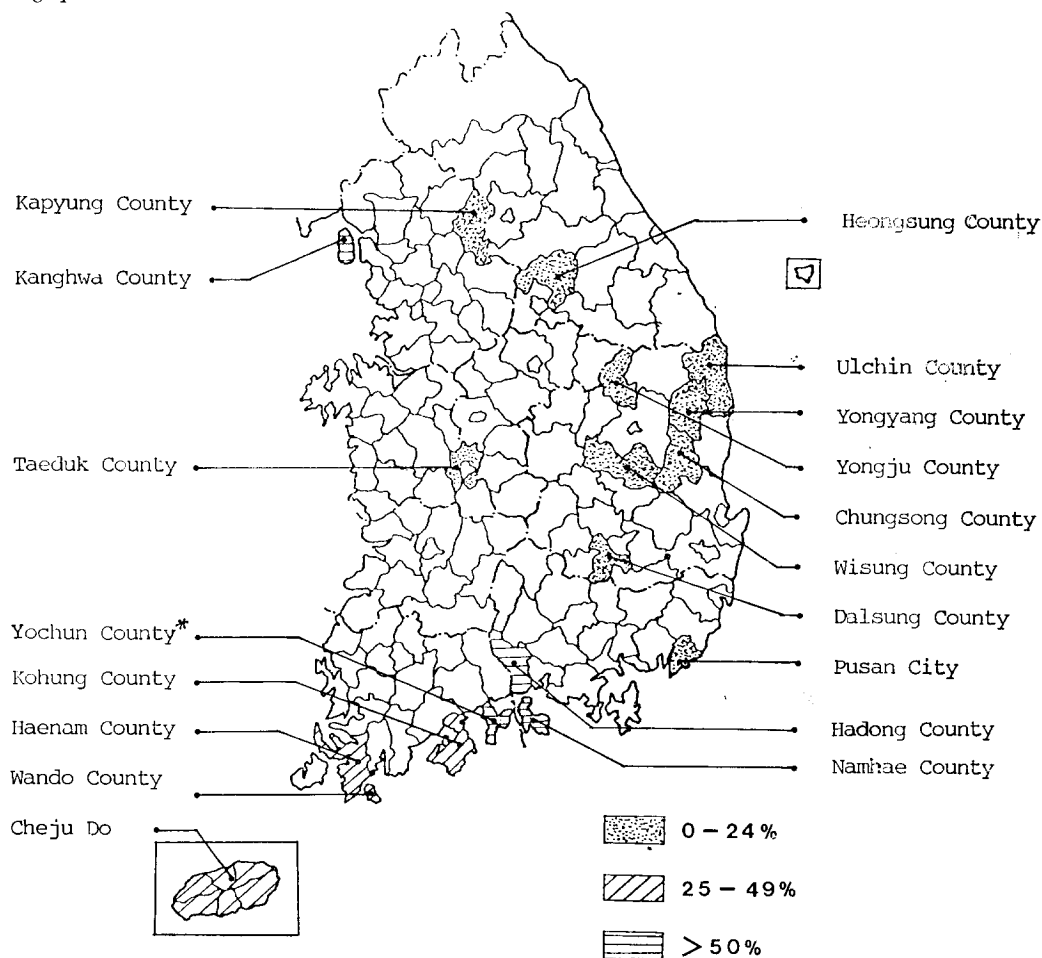


Fig. 4. Endemic areas of paragonimiasis in Korea. Endemicity determined by demonstration rates for *P. westermani* metacercariae from crayfish and crabs* (see text for years of survey in each area)

presents infestations of the intermediate host with the larvae in the reported endemic foci. Also, Fig. 5 shows the prevalence or positive rate by intradermal test using *Paragonimus* antigen before 1985 by localities.

1. Kyonggi-do (Kyonggi Province): Yun (1965) reported that the prevalence of paragonimiasis among the school children in 174 primary schools from 169 Myons in 18 Guns by intradermal test with *Paragonimus* antigen was 4.9% (937/19,345), and the rate was higher in the male (5.5%) than in the female (4.0%). The infestation rate of crayfish with the metacercaria in Kyonggi-do was 1.1% (271/25,640).

Similar investigations have been carried out by Rim *et al.* (1975), Lee *et al.* (1979 & 1980b),

and Min and Chun(1987). They reported that the percentage of positive dermal reactions to *Paragonimus* antigen among school children and residents in Kanghwa-gun(County) varied from 15% to 28%, and fresh-water crayfish were either scarce or absent. Afterwards, Min (1980) reported that the crayfish in the district of Seoul is no longer an infection source of human paragonimiasis.

2. Chungchongnam-do (Chungnam Province): Kim *et al.*(1967) found that the prevalence rate for paragonimiasis among residents in Huksok-ri(village), Kuksong-myon, Taedok-gun was 7.6%, and the infestation rate for *Paragonimus* metacercaria in crayfish was 4.2%. Min and Hong(1974) reported the higher positive

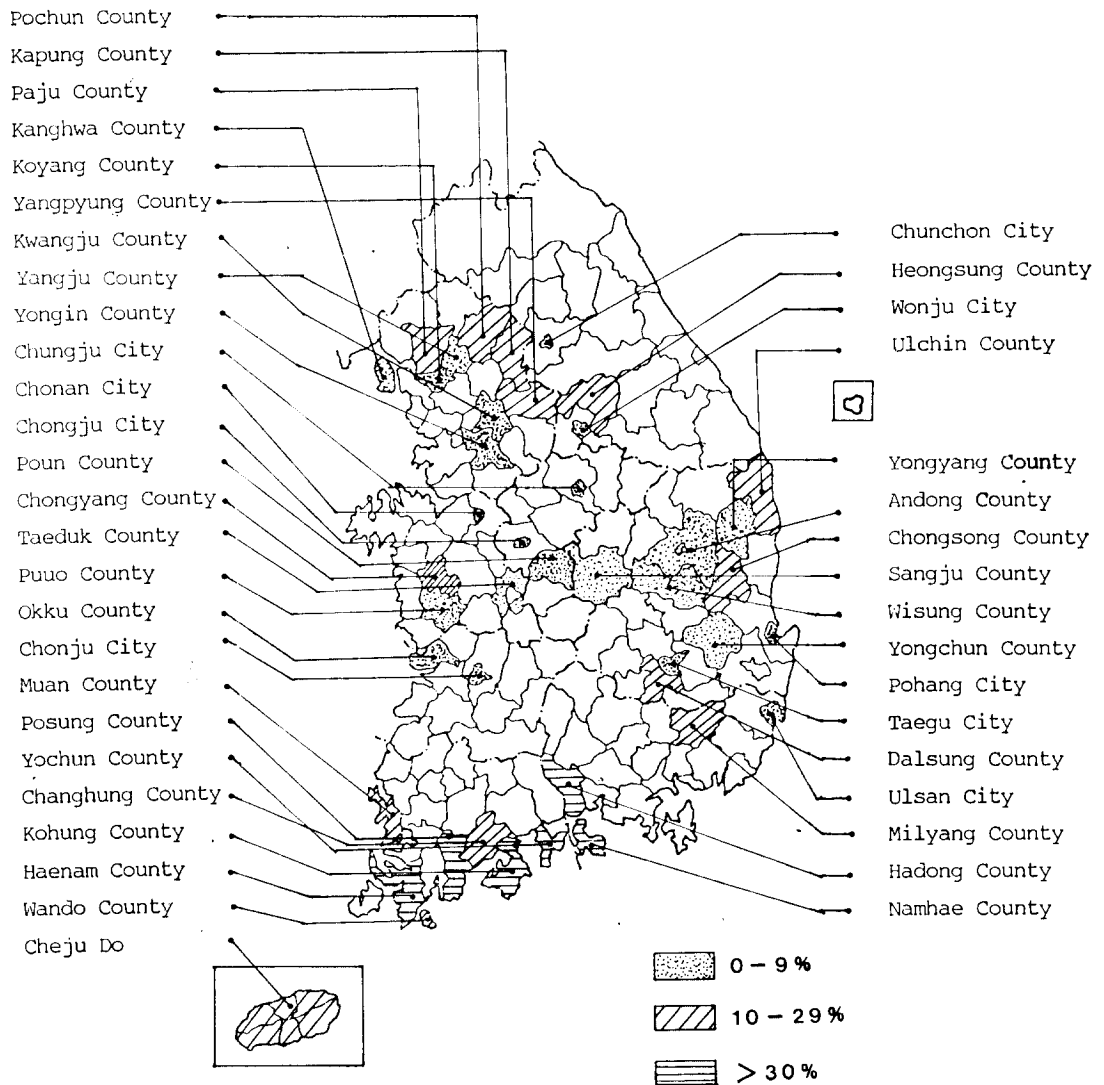


Fig. 5. Reported endemic areas of paragonimiasis. Prevalence was determined by intradermal test among residents (before 1985).

rate (12.7%) of dermal reactions in residents of Chongyang-gun, but no positive dermal reaction with *Paragonimus* antigen was found in children less than 9 years of age.

3. Kangwon-do (Kangwon Province): Lee *et al.* (1981) reported results in which the prevalence rate of the lung fluke among residents was 14.5 % and the metacercarial rate from crayfish, 20.9 %. The average number of metacercariae per positive crayfish was 0.56 in Hoengsong-gun.

4. Chollanam-do (Chonnam Province): Ko-

hung-gun is well-known for its high endemicity of paragonimiasis. After World War II, Chyu (1957) reported for the first time on the high prevalence (52.5%) of paragonimiasis among residents in Kohung-gun.

Kang *et al.* (1964d) surveyed the prevalence of paragonimiasis (20.1%) in residents and school children by intradermal test, and found the highest prevalence (46.7%) in the age group of 16-to-20 years. Ahn and Lee (1964) reported that cercarial rate of *Paragonimus* in *Semisulco-*

spira snails was 0.2% and the metacercarial rates in crabs and crayfish were 44.0% and 49.4%, respectively.

Rim *et al.* (1980) summarized survey findings in Podu-myon, where the positive dermal reaction with *Paragonimus* antigen among residents was 56.9%, and the metacercarial rate of crabs collected from markets was 25% and the average number of metacercariae per positive crab was 0.6. Such results have been reported by Chun (1970) in Haenam-gun, Ahn *et al.* (1974) in Yochon-gun, Ahn *et al.* (1979) in Wando-gun, Lee *et al.* (1980 a) in Bosong-gun, and Lee *et al.* (1980 c) in Changhung-gun.

It was found that the percentage of positive dermal reactions among residents and school children varied from 7% to 61% and the metacercarial rate varied from 4.2% to 49.4% from crayfish and from 5.5% to 66.7% from crabs.

Kim *et al.* (1985) reported that the prevalence of paragonimiasis in the islanders of Bogildo (islet) was 10.2%, the cercarial rate in the snail was 24.2%, and the metacercarial rate in the crayfish was 65.4%; and the average number of metacercariae per positive crayfish was 6.5.

5. Kyongsangnam-do (Kyongnam Province): Lee (1958) studied infestation with the metacercaria in the crab host and the prevalence of paragonimiasis in Taedong-myon, Changwon-gun. Sadun *et al.* (1959) surveyed the epidemiology in Sangdong and Sannae myons, Milyang-gun. Ahn *et al.* (1966) reviewed the high prevalence of *Paragonimus* in snail and human hosts in Namhae-gun. The results of the studies were as follows: the percentage of positive dermal reactions among residents was high (43.7 to 60.4%) and the metacercarial infestation rate in crabs was also high (59.0 to 94.6%). In Hadong-gun, Kim *et al.* (1979) found that the positive dermal reaction with *Paragonimus* antigen among residents was relatively high, 31.5%. The rate was 35.2% in male and 24.5% in female. Because of the low density of crayfish in the mountain streams and a significant reduction in the incidence of *Paragonimus* larvae from the crayfish, the incidence of paragonimiasis among residents

would decrease in the near future.

6. Kyongsangpuk-do (Kyungpook Province): Park (1961) conducted clinical observations on 179 cases of paragonimiasis. Park and Choi (1974) reported that crayfish were found in 65 small mountainous streams close to the temples, but no crayfish were found in the rivers. The crayfish from four out of 65 streams harbored *Paragonimus* metacercariae, which were abundant in the cephalothorax and a few on the pericardiac wall, and the number of metacercariae per positive crayfish ranged from 2.1 to 5.7.

Kim *et al.* (1974) conducted a survey of paragonimiasis and found that the prevalence of paragonimiasis among residents based on the positive dermal reaction with *Paragonimus* antigen was 4.3% (693/16,106). The positive rate for *Paragonimus* was higher for male than for female, and the rate 1.4% (46/1,883) in Taegu.

From 1977 to 1988, a resurvey of *Paragonimus* in 5 endemic foci of Kyungpook Province had been conducted by Choi and his associates.

Chilgok-gun: Kasan-myon has been known as an endemic focus of *Paragonimus*. Sohn and Choi (1977) carried out a survey of the endemic distribution of *Semisulcospira* snails and *Cambaroides* crayfish in the streams and the prevalence of the lung fluke among residents. They found an abundance of snails and crayfish in the streams and a high infection rate of *Paragonimus* in residents, 23.4% by intradermal test.

Kim and Choi (1977) found that the infection rate for the fluke in residents by intradermal test was 5.4%, and a difference in the age and sex specific rates was noted. Lee and Choi (1979) reported that the positive dermal reaction with *Paragonimus* antigen in 496 school-children was 9.9%.

Because of the low density of snails and crayfish in the streams and failure to demonstrate *Paragonimus* larvae from the hosts, the 4 localities in Chilgok-gun, where they studied, were no longer the endemic foci of paragonimiasis.

Uisung-gun: The prevalence of paragonimiasis among residents in the 3 communities

varied from 1.4% to 7.9%, with an average rate of 4.0% (Choi and Hwang, 1980). The average rate in school children was 3.6% (Choi *et al.*, 1981). There was no significant difference in the rate of infection between residents and school-children. They indicated that paragonimiasis is no longer an important endemic disease in Uisong-gun.

Talsung-gun: Choi *et al.* (1982 & 1983) reported that the population density of crayfish in the endemic areas and the infection of crayfish with the metacercaria of *Paragonimus* had decreased drastically over the 8-year period from 1974 to 1982.

Andong-gun: Park *et al.* (1984) conducted a survey on snail and crayfish hosts of *Paragonimus* and found that the density of snails in the stream was low, and no *Paragonimus* cercaria was found in the snails. It was almost impossible to find crayfish in the streams, but the metacercaria of *Paragonimus* was still found from the crayfish.

Youngpung-gun: The density of snails and crayfish in the stream of Roja village was somewhat higher than that in Daechon village. No *Paragonimus* cercaria was found in either stream but *Paragonimus* metacercaria was found from the crayfish collected in Roja stream (Lee and Choi, 1984).

Chungsong-gun: Choi *et al.* (1987) conducted an intermediate host survey of *Paragonimus* and reported that the density of snails was relatively high in all of the streams, but no *Paragonimus* cercaria was found. The density of crayfish was very low, and metacercariae were found from the crayfish collected in the streams of Songjae and Kalchon villages.

Ulchin-gun: The prevalence of paragonimiasis among residents was 25.8% by the *Paragonimus* intradermal test (Joo *et al.*, 1985). The population density of the crayfish ranged from 1 to 13, with an average of 4, and 15% of the crayfish harbored the metacercaria of *Paragonimus* (Hong *et al.*, 1986). A recent survey (Suh and Joo, 1990) indicated that paragonimiasis still remained prevalent among residents of Ulchin

county.

7. Cheju-do (Quelpart Island) : Thirty-two percent of the primary, middle and high school boys and girls showed positive dermal reactions with *Paragonimus* antigen. The sexual differences in the rate of positivity were 25.2% in males and 18.8% in females (Kang *et al.*, 1964c & 1965c). The infestation rates for *Paragonimus* metacercariae in 2,377 crabs, *Eriocheir japonicus* varied from 0 to 100%, with an average of 43.5% (Kang *et al.*, 1964b). Kang *et al.* (1965b) surveyed the relationship between the complaints of paragonimiasis symptoms and eating of crabs among residents. Kim (1969c) reported that the infestation rate of snail host with *Paragonimus* cercaria was high in the area where human association was more frequent. The distribution of *Paragonimus* metacercariae in infected crabs varied by body sites, the most frequently found in the gills, and then in the legs, internal organs and thoracic muscle in decreasing order.

Joo (1979) reported that 2.3% of ROK army soldiers showed positive dermal reactions to *Paragonimus* antigen, and the highest prevalence was found among the soldiers from Cheju-do and the lowest from Seoul City.

The positive dermal reactions to *Paragonimus* antigen were 22.0% in Masan and 15.2% in Kongju sanatoria patients (Choi *et al.*, 1984).

PATHOLOGY AND SYMPTOMATOLOGY

1. Pathology

Although there are many conflicting theories as to the pathogenesis of the formation of the parasitic cyst in the lungs, two theories, in general, have had favorable acceptance. (1) The theory of softening of the lung tissue: The adult *Paragonimus westermani* parasitizes the lung parenchyma and exerts compression on the surrounding tissues including the alveoli, bronchioles and capillaries, with a resultant reactive inflammation followed by softening cystic space; this cystic space then surrounded by a fibrous wall, forming the parasitic cyst. (2) The bronchiectatic theory: Columnar epithelium lines the

inner wall of the cystic lesion, along with the smooth muscle bundles in the wall of the cyst.

Chung (1971) suggested, however, that the type of worm cyst seemed to be determined only by the relationship between its location and the presence of bronchi in the light of the fact that there are two kinds of cysts, one due to softening or collapse of the pulmonary tissue and the other due to bronchiectatic change. In human material, nevertheless, the parasitic cysts found on surgically removed specimens or autopsy material are usually of the bronchiectatic type.

In addition, allergic or toxic reactions seem to play roles in the pathogenesis of pulmonary paragonimiasis by the appearance of epithelioid tubercles due to paragonimus eggs, with plasma cells and eosinophils as well as the vascular lesions (Chyu, 1962a; Soh, 1975).

The degree of the pathologic changes varies mainly depending on the duration of infection, the number of parasites and the host tissue reaction.

Experimental paragonimiasis in dogs and cats (Chyu, 1962a; Yoo and Chyu, 1966; Lee, 1979; Choi *et al.*, 1979; Chi *et al.*, 1982) assists in understanding the pathologic changes in humans.

Sequential pathologic changes occur as follows: Pathologic findings in the thoracic cavity are first noticed 20 days after oral infection. This consists of fibrinous pleuritis with superficial hemorrhage. Only the juveniles are found in the pleural cavity together with turbid effusion at this period. Before this period, inflammatory cell infiltration is seen in the intestinal villi (the 8th day), liver and diaphragm (the 15th day). *Paragonimus* juveniles are first recognized inside the lung parenchyma by 30 days after infection. This is the period when the lungs show multiple areas of hemorrhage and probable active penetration by worms. Hemorrhagic bronchopneumonia is quite pronounced from this stage through the 45th day. On the 45th day of infection, early alveolar cell proliferation is seen around the worm. On the 60th day, the worm cyst is composed of fibrous scar and heavy inflammatory

cellular infiltration and the lining epithelial cells are first noticed, which are thought to be probably transformed alveolar lining cells rather than bronchial epithelial cells. The cyst wall becomes more stable and often shows squamous metaplasia. On the 120th day, hemorrhage is shown in the lumen of the bronchiole in the vicinity of the fluke, and the pleura shows fibrotic thickening. As the infection progresses, the pleura surrounding the lesion is diffusely thickened (Min *et al.*, 1958; Chyu, 1962a; Lee, 1979; Choi *et al.*, 1979; Chi *et al.*, 1982; Choi, 1984a).

Bae *et al.* (1976) reported that the nature and characteristics of the pulmonary lesion in albino rats produced by *P. iloktsuenensis* were just the same as those produced by *P. westermani*.

Laboratory findings frequently seen in paragonimiasis are hypergammaglobulinemia, slight-to-moderate eosinophilia, and an increased erythrocyte sedimentation rate (Yun, 1960; Chyu, 1962c; Lee, 1975).

Extrapulmonary paragonimiasis: Extrapulmonary parasitism with *Paragonimus westermani* has been reported in the brain (Kim, 1956; Kim, 1957; Graumann *et al.*, 1957; Lee *et al.*, 1958; Kim, 1959; Hong *et al.*, 1959; Oh, 1963), spinal cord (Choi *et al.*, 1956; Suh and Shim, 1959; Park, 1962; Oh and Laursen, 1964), thoracic muscle (Chi, 1957b), subcutaneous tissues (Lee, 1975), liver (Lee, 1975), spleen (Chi *et al.*, 1981), greater omentum (Chi, 1957a; Park *et al.*, 1963), peritoneum (Park *et al.*, 1963; Lee, 1975), pericardium (Lee, 1975), mediastinum (Lee, 1975), uterus (Hong *et al.*, 1982b), fallopian tubes (Chung and Kim, 1968), ovaries (Hong *et al.*, 1982b), and urinary tract (Weistein *et al.*, 1953; Lee *et al.*, 1959 & 1960) in Korea.

The most commonly involved organ other than the lungs and pleura is known to be the brain (Lee *et al.*, 1958; Lee, 1975). The incidence of cerebral paragonimiasis is higher among males than females. In cerebral paragonimiasis, early granulomatous lesion and, later, mass with calcification and liquefaction, surrounded by fibrous capsule, are the findings frequently encountered. Irregularly-shaped ova are observed

in the abscess cavity. Histopathologic findings of spinal paragonimiasis, usually situated epidurally in the thoracic level, are quite similar to those of cerebral paragonimiasis.

2. Symptomatology

Paragonimiasis is usually insidious in its onset and mildly chronic in its course, but there may be an initial episode of chills and fever. Fulminating cases with fatal termination were also recorded. The symptoms are characteristically referable to the chest, abdomen, lymph glands, or brain.

In pulmonary paragonimiasis, the most remarkable clinical feature is cough and blood-tinged sputum, and less frequently hemoptysis, distressing chest pain, and dyspnea (Lee, 1975; Choi, 1984a). The cough is dry at first and later productive with blood-stained, rusty-brown tenacious sputum most pronounced on rising in the morning.

Occasionally there is profuse hemoptysis following paroxysmal coughing. The manifestations are more severe after physical exertion. There are no characteristic auscultatory findings, but hyper-resonance is present.

X-ray films show patchy, cloudy infiltration of the lungs, nodular shadows, calcified spots, and pleural thickening, with interlobar pleuritis and pleural effusion (Han, 1956; Seol and Byun, 1958; Yun, 1960; Chyu, 1962d; Lee, 1975). Han (1965) reported that CT was more useful for the detection of the worm cysts than simple chest X-ray.

Signs on physical examination may be similar to those observed in bronchopneumonia or bronchiectasis with pleural effusion.

In the abdominal type, the worms produce less definite symptoms. Usually there is dull abdominal pain. Moderate rigidity and tenderness on deep palpation may be present. Lodged in the intestinal wall they provoke diarrhea, with eggs in the stools. Ectopic parasitism in the female genital organ could produce sterility (Hong *et al.*, 1982b).

In the brain the worms are responsible for epilepsy of Jacksonian type, such as occurs in

cerebral cysticercosis. In addition, headache (Lee *et al.*, 1958), motor and sensory disturbance, aphasia, hemiplegia, visual disturbance, blindness, and nausea are known to be relatively common in cerebral paragonimiasis. Kim (1959) also reported that seizure (95%) was the most commonly followed by hemiplegia, meningitic syndrome, and mental retardation from 47 cerebral paragonimiasis patients. In endemic foci, cerebral symptoms in children under 15 years of age have sometimes been attributed to infantile paralysis, cerebral hemorrhage, encephalitis, or meningitis, whereas the actual causative agent was this fluke. The most common finding in skull radiographs was intracranial calcification (Oh, 1968) in the posterior temporal and parietal, and the occipital areas. Sometimes the findings usually seen in cerebral tumor might be observed.

In spinal paragonimiasis, paravertebral pain, urinary difficulty, motor disturbance in the lower extremities, increased knee and Achilles jerk, increased muscle tonus in the lower extremities, and positive Babinski sign (Choi *et al.*, 1956) might be observed.

In urinary paragonimiasis, the chief complaints are frequency and difficulty (Lee *et al.*, 1959 & 1960).

DIAGNOSIS AND IMMUNOLOGY (SEROLOGY)

1. Clinical and laboratory diagnosis

Pulmonary symptoms, blood tinged sputum, and eosinophilia in patients in endemic regions are suggestive. At times radiographs aid in diagnosis, although it is difficult to differentiate paragonimiasis from tuberculosis which is common in areas where *Paragonimus* is endemic. A typical roentgenographic finding is a ring shadowed opacity, 5 to 10 cm, comprising several small contiguous cavities that give the appearance of a bunch of grapes.

Definite diagnosis is based on the finding of characteristic eggs in sputum, aspirated pleural effusion, feces, or from cutaneous lesions. The zinc sulfate flotation method was reported to be

more recommendable for concentration of *Paragonimus* eggs than the formaline-ether sedimentation method (Loh, 1964).

Clinically, the pulmonary paragonimiasis must be distinguished from tuberculosis, bronchopneumonia, bronchiectasis and pleural effusion.

Kim (1970) proposed that the definite diagnosis of paragonimiasis should be established by finding the eggs in the sputum or in the feces, and then recommended at least three repeated examinations.

2. Seroimmunology

In spite of Kim's (1970) proposal, however, since the recovery of the eggs is not easy in mild, latent, ectopic, or therapeutically-affected cases, several immunologic and serologic tests have been applied to determine the availability as diagnostic tools for paragonimiasis or to assess the efficacy of chemotherapeutic agents after treatment. Choi (1978 & 1984b) stressed the availability of serologic tests for the diagnosis of paragonimiasis.

The most commonly used test for screening paragonimiasis was doubtlessly the intradermal reaction to *Paragonimus* antigen (Sadun *et al.*, 1959; Kim and Park, 1974). In general, the skin test is thought to be highly sensitive, specific, and convenient for epidemiologic study. Since it remains positive for years after the death of the fluke, however, it is inadequate for clinical use. Several workers (Chyu, 1958 & 1959; Park, 1963; Chyu and Kim, 1965; Kim, 1969b; Lee, 1974; Choi *et al.*, 1986) have attempted to overcome this handicap of the skin test. Chyu (1958) reported that 60 out of 510 patients clinically diagnosed to be tuberculosis were found to reveal positive reactions for skin test using *Paragonimus* antigen and 13 patients were confirmed by demonstration of *Paragonimus* eggs. Walton and Chyu (1959) and Chyu (1959) introduced the methods of using the skin test antigen and interpreting the results. The test was also applied in the field of pediatrics. Chyu and Kim (1965) found that the peptide antigen was highly sensitive although the antigen titre was low. Kim (1969b) assessed the reliability of the VBS (Veronal buffered saline) antigen

based on the demonstration rate for *Paragonimus* eggs. Kim *et al.* (1969) reported that irregular intradermal reactions were observed in rabbits experimentally sensitized with the antigen. Lee (1974) reported that the skin test with PPF (purified protein fraction) was more sensitive than those with VBS antigens. Choi *et al.* (1986) fractionated adult *Paragonimus* antigens by means of biochemical methods and assessed the value as an antigen.

Complement-fixing antibodies are known to appear in 1 month after infection with some variations depending on the host species (Chyu, 1962b) and to disappear in humans 3 to 9 months after successful therapy. For this reason, the complement fixation test may be used to assess the results of the chemotherapy. This test, especially a modification by Kohlmer, and also used in the assessment of antigen titre (Chyu and Lee, 1961) showed earlier and more sensitive reactions than the double diffusion test (Han and Woo, 1969).

Precipitation reaction in gels (Ouchterlony method and immunoelectrophoresis) also tested its applicability in the serodiagnosis of paragonimiasis (Kim *et al.*, 1969; Yun and Choi, 1973; Choi *et al.*, 1976; Lee, 1977; Choi and Lee, 1976 & 1981; Lee and Choi, 1983; Lee, 1986) and in evaluation of the therapeutic efficacy of bithionol and niclofolan in experimental paragonimiasis (Choi *et al.*, 1976). According to Choi *et al.* (1976), the sera from the rats treated with bithionol or niclofolan showed precipitation bands delayed by 2 weeks over the untreated controls. Choi and Lee (1981) reported that the Ouchterlony method was highly sensitive and specific. However, irregular reactions in the immunoelectrophoresis and double diffusion technique was also reported (Lee, 1977).

Choi (1978) suggested the availability of the intradermal test and the serologic tests such as complement fixation (CF), Ouchterlony method (double diffusion in gel), and immunoelectrophoresis (IEP) in the diagnosis of the paragonimiasis. Kim *et al.* (1983) reported that secretory-excretory antigen from adult *P. westermani* was

more antigenic than crude extract.

Recently, the enzyme-linked immunoelectro-transfer blotting method (EITB) after sodium dodesyl sulfate-polyacrylamide gel electrophoresis (SDS-PAGE) has been employed for the assessment of antigenicity of antigen fractions (Kim *et al.*, 1988; Joo *et al.*, 1989a & b). Joo *et al.* (1989 a) compared the reactions of the serum depending on the course of infection to antigen fractions by EITB, and reported that saline extract of *Paragonimus* recovered from cats 12 weeks after infection was found to be of value for early diagnosis of paragonimiasis. Joo *et al.* (1989 b) reported that protein bands of 91, 60, 21, and 10 kDa from crude antigen showed strong positive reactions with patients sera by EITB. Kim *et al.* (1986) reported the immunofluorescence technique has been known to be a highly sensitive method for the serologic diagnosis of paragonimiasis (Choi *et al.*, 1975; Kim, 1975; Cho and Soh, 1976; Lee *et al.*, 1980). Choi *et al.* (1975) reported that the IF technique was found to be more sensitive and specific for serodiagnosis of paragonimiasis than the complement fixation technique. Kim (1975) carried out the IF technique using delipidized adult worm particles fixed on a microscopic slide as antigen, and reported that this modification was found to be available for diagnosis of paragonimiasis. Lee *et al.* (1980) also reported similar results using cryocut adult worm antigen.

Enzyme-linked immunosorbent assay (ELISA) has been widely applied for serologic diagnosis of paragonimiasis (Cho *et al.*, 1981, 1983 & 1989; Jin *et al.*, 1983). Cho *et al.* (1981) reported that the sensitivity of the assay was 86% and the specificity, 100%. Cho *et al.* (1983) stressed that the detection of *Paragonimus*-specific IgG antibody by micro-ELISA was helpful in detecting the active cases as well as in proper evaluation of the endemicity of human paragonimiasis. Kim *et al.* (1982), after testing crude and excretory-secretory antigens, suggested that the latter was found to be more useful in detecting anti-*Paragonimus* antibody. Kim *et al.* (1986) reported weak antigenicity of eggs

compared to adult worm extracts. Cho and Kim (1983) reported detection of the antibody from the pleural effusion. Jin *et al.* (1983) found that the antiserum from sensitized rabbits showed positive reactions by ELISA and the Ouchterlony method 2 weeks after the sensitization. Lee and Choi (1983) proposed that the ELISA, using a small amount of purified *Paragonimus* antigens, was also highly sensitive with good correspondence with the agar-gel diffusion and counter immunoelectrophoresis techniques. Choi *et al.* (1984) and Soh *et al.* (1985) reported the high sensitivity, specificity, and reproducibility of the ELISA technique. Lee *et al.* (1986) and Park *et al.* (1987) detected the antibody from the urine of patients. Choi *et al.* (1986) observed the changing patterns of the antibody titre from cats depending on the intensity of the infection course, and treatment. Lee and Chang (1986) determined the reactivity of crude antigen and purified antigen with the antiserum of cats. Yong *et al.* (1987) reported that the antigens produced by the fluke were detected from the serum of the infected rats 1 week after infection and disappeared in 3 weeks.

In addition to the serodiagnosis of paragonimiasis, several studies on the acquired immunity against *Paragonimus* have been performed. Chyu (1962 b) reported that the recovery rate of adults *P. westermani* from immunized dogs was significantly lower than that from the unsensitized control. According to Jung *et al.* (1985), plaque forming cells from the spleens of ICR mice sensitized by injection of metabolites or somatic constituents of *P. westermani* were detected for the first time 5 days after sensitization. The number of plaque-forming cells was found to be highest on the 10th day, and decreased step by step from the 15th day of sensitization. Moon and Shin (1986) also demonstrated the plaque-forming cells from the spleen of BALB/c mouse sensitized by oral administration of *P. westermani* metacercariae. Park and Shin (1986), however, reported that protective immunity against *P. westermani* was acquired by intraperitoneal injections of the metacercariae, but failed by

oral administration of the larvae. Min *et al.* (1989) assumed that antibody and complement act directly as effectors on functional and morphological impediment of tegument of *P. westermani* metacercaria.

CHEMOTHERAPY

Ten kinds of drugs have been tried in experimental chemotherapy of paragonimiasis in Korea: (1) nilodin (Weinstein *et al.*, 1953); a combined regimen of (2) emetine hydrochloride and (3) sulfonamides (Weinstein *et al.*, 1953; Graumann *et al.*, 1957); (4) chloroquine phosphate (Graumann *et al.*, 1957; Choi, 1959); (5) bithionol (Kang, 1962a & b; Kang *et al.*, 1963 & 1964a; Chyu *et al.*, 1964; Kim *et al.*, 1964; Soh *et al.*, 1964a; Kim, 1966; Oh, 1967; Kim, 1969a; Kim and Bang, 1974); (6) dehydroemetine hydrochlorides (Lim *et al.*, 1964); (7) niclofolan (Rim *et al.*, 1976; Choi *et al.*, 1976); (8) flubendazole (Soh *et al.*, 1977), and (9) praziquantel (Rim and Chang, 1980; Rim *et al.*, 1981; Soh *et al.*, 1981; Chiu *et al.*, 1982; Kim *et al.*, 1982; Rim, 1983 & 1984; Yoo *et al.*, 1984; Lee, 1984; Lee *et al.*, 1987). Among these drugs, bithionol, niclofolan and praziquantel are known to be effective for the treatment of paragonimiasis. Since medical treatment of paragonimiasis had not been successful before 1960, Kim (1957), suggesting indications of surgical measure, treated 6 cases of pulmonary paragonimiasis by partial lobectomy.

Since 1962, bithionol (Thistoming®) seemed to be the most effective chemotherapeutic drug against *Paragonimus* (Kang, 1962a & b). The inhibition of or prevention from infection of *Paragonimus* in both man and dogs may be possible, if sufficient doses of bithionol could be administered continuously for proper period prior to the infection or disease (Kang *et al.*, 1963). Chyu *et al.* (1964) reported that Thistoming® (bithionol preparation) given in daily doses of 40 mg/kg every other day, decreased the eggs in the sputum markedly from 4 to 7 days after medication and caused them to disappear com-

pletely from 5 to 17 days. Bloody sputum stopped from 2 to 10 days.

Bithionol-S-oxide 100 mg per kg body weight every other day or daily of varying periods is highly effective to cats, dogs and monkeys with paragonimiasis. Efficacy of the agent against paragonimiasis varied depending on the host species and on the intensity of the infection (Kim *et al.*, 1964). When bithionol in doses of 0.6 ~ 2.5 gm every other day was given to 19 with paragonimiasis, the cough and bloody patients sputum disappeared or reduced to below clinical level, converting to egg negative (Soh *et al.*, 1964).

Kim (1966) stressed that Thistoming® was most effective against paragonimiasis, more than emetine hydrochloride with chloroquine diphosphate and chloroquine phosphate only. Bithionol is effective in the acute phases of cerebral paragonimiasis, especially meningitis, whereas it is of no benefit in chronic stabilized cases (Oh, 1967). Kim (1969a) and Kim and Bang (1974) made a follow-up study to evaluate the efficacy of mass chemotherapy for the control of paragonimiasis, and reported that continuous and intense chemotherapy may be able to bring paragonimiasis under control.

Rim *et al.* (1976) reported that niclofolan was a very promising drug and highly effective for human paragonimiasis with a daily dose of 2.0 mg/kg body weight for 3 days, and it was also effective in experimentally infected dogs and cats with paragonimiasis in 2 doses of 2.0 mg/kg body weight on alternate days with no toxic manifestations. Choi *et al.* (1976) reported that the sera from rats infected with *Paragonimus*, and after treatment with bithionol or niclofolan preparations, began to show precipitin bands against *Paragonimus* antigen 8 weeks after the infection, and in the untreated control rats showed 2 weeks earlier.

Recently, it was found by *in vivo* and *in vitro* studies that praziquantel was more effective and safer than niclofolan. Therefore, praziquantel was a promising drug for the treatment of paragonimiasis (Rim and Chang, 1980). Ten

patients who had received 2×25 mg/kg body weight for 3 consecutive days were completely cured at 4-month follow-up examinations (Rim *et al.*, 1981). At the same time, Soh *et al.* (1981) reported that 31 cases of paragonimiasis were treated with praziquantel in doses of 25 mg/kg body weight on 1 day and the same daily dose on 2 consecutive days. Clinical complaints improved within 1 or 2 months, and parasitological egg negative in sputum was achieved by the 2-day regimen, but not all in 1-day treatment. Moreover, abnormal radiologic findings of the chest disappeared 1 year after treatment with praziquantel (Rim, 1984).

Chiu *et al.* (1982) carried out electron microscopic studies for the effects of praziquantel on the morphological changes of *Paragonimus*. Experimentally infected dogs were given praziquantel 3×25 mg/kg for 3 days or 3×50 mg/kg for 3 days. Each dog was autopsied at 24 hours to 7 days after the last medication, and the lesions with *Paragonimus* worms were observed. As a result, no living worm was found in the lungs of the dogs. Scanning electron microscopic observations revealed that the bleb-like structures were formed at the papillae near two suckers and the host cells of the defense system attached to the tegumental vacuoles were caused by the bursting of the blebs. Yoon *et al.* (1984) and Lee (1984) also reported similar results to those of Chiu *et al.* (1982).

Lee *et al.* (1987) observed the *in vitro* effects of praziquantel on *P. westermani* and suggested that the effects, immobilization, vacuolation of worm tissue, and disintegration of the reproductive organs seemed more related with incubation time than with drug concentration.

In general, bithionol, thiobis-dichlorophenol, 30 to 50 mg orally, per kilogram of body weight every day for 10 to 15 days, is known to be curative with a cure rate of 90 percent. Praziquantel, at a dose of 20 mg per kilogram *t.i.d.* for 2 consecutive days, has been used. Owing to a narrow safety margin of niclofolan (Hong *et al.*, 1982a) and the necessity for bithionol to be administered over a long term, praziquantel,

well-tolerated by patients (Rim, 1984), has been preferred by clinicians to the others.

PREVENTION AND CONTROL

The control of paragonimiasis should include the following procedures: (1) reduction of the sources of infection in human beings by chemotherapy, (2) education in personal prophylaxis to abstain from eating raw, freshly salted, or inadequately-cooked crabs or crayfish, and from contaminating fingers or kitchen utensils with the metacercarial cysts while preparing infected crustaceans for cooking, (3) control of molluscan and crustacean intermediate hosts, and (4) sanitary control of human excreta (Chyu, 1966; Soh *et al.*, 1986). Among these, the mass treatment of patients with bithionol (Kim, 1969 b) or praziquantel and public education are more practical than the other methods, since the elimination of reservoir hosts and intermediate hosts is not feasible.

In Korea, the juice of crushed crayfish had been used as a remedy for measles, and thus served as a source of *Paragonimus* infection. According to Loh (1966 a), 15.4% of the housewives answered that their children had taken the crushed crayfish juice orally for the treatment of measles. About 50% of Koreans were in the habit of eating crayfish or crabs, raw or boiled.

Since immersion of the infected crustacean host in rice wine or strong brine for a short time will not kill the cysts, it is imperative that the infested crustaceans be boiled or fried in deep fat to insure against infection (Loh, 1966 b; Kim, 1967; Lee and Nam, 1977). It was suggested that eating raw meat of paratenic hosts such as wild boar would be a route of infection (Kim and Lee, 1970; Lee *et al.*, 1976). Human infection may also come from drinking water containing the metacercariae freed from the dead crayfish (Loh *et al.*, 1969).

Loh (1966b) reported that boiling the crayfish for 30 seconds, or soaking in Japanese soy sauce for about 1 week killed all of the metacercariae. Lee and Nam (1977) suggested that some metacer-

cariae in the crab, *Eriocheir japonicus*, remained alive even after 10 days in soy-bean sauce.

Kim(1967) also reported the effectiveness of the temperature over 50°C, and Korean or Japanese soy-bean sauce in killing the metacercariae.

Recent surveys revealed that there was a significant reduction in the prevalence of paragonimiasis among people, in the population density of the intermediate hosts, and in the incidence of larvae from intermediate hosts. Choi *et al.* (1983) indicated that broad spray of pesticides and construction of dams would affect the ecosystem to diminish the intermediate hosts.

REFERENCES

- Ahn, J.H. and Seo, B.S. (1972) Paper chromatographic analysis on the carbohydrate metabolism of the lung fluke, *Paragonimus westermani* and the pancreatic fluke, *Eurytrema pancreaticum*. *Seoul J. Med.*, 13(4):235-242.
- Ahn, Y.K., Lee, B.H. and Han, S.H. (1974) Epidemiological survey of paragonimiasis and intermediate hosts of *P. westermani* in Yochon-goon (Chunnam Province, Korea). *New Med. J.*, 17(6):47-52(in Korean).
- Ahn, Y.K. and Lee, Y.H. (1964) The survey of intermediate hosts in endemic area of paragonimiasis, Podu-Myun, Kohung-Kun, Korea. *Korean Med. J.*, 9(1):133-139(in Korean).
- Ahn, Y.K., Han, J.K. and Chung, J.H. (1979) Epidemiological survey on *Paragonimus* infection in Wando and Bogil islet, Wando-Gun(Chconnam Province, Korea). *New. Med. J.*, 22(11):1051-1056(in Korean).
- Ahn, Y.K., Suh, J.K. and Lee, Y.H. (1966) Survey of paragonimiasis and intermediate hosts of *Paragonimus westermani* in Namhai Island (Namhai Kun, Kyungnam province, Korea). *New Med. J.*, 9(11):1117-1121(in Korean).
- Bae, J.H., Seo, B.S. and Lee, S.H. (1976) Studies on the lung fluke, *Paragonimus iloktsuenensis*. V. Host tissue reactions in albino rats. *Korean J. Parasit.*, 14(1):1-9(in Korean).
- Chi, H.C. (1957a) A case of multiple *Paragonimus* cysts in greater omentum followed by paragonimiasis. *Korean Med. J.*, 2:77-82(in Korean).
- Chi, H.C. (1957b) A case of paragonimiasis accompanied by two abscesses in the right thoracic muscle. *Korean Med. J.*, 2:899-905(in Korean).
- Chi, J.G., Choi, W.Y., Lee, O.R. and Chung, C.S. (1982) Changes of liver and diaphragm in experimental paragonimiasis. *Korean J. Parasit.*, 20(2):160-168(in Korean).
- Chi, J.G. Lee, O.R. and Choi, Y.W. (1981) Splenic paragonimiasis: A case in a dog. *Korean J. Parasit.*, 19(1):81-85.
- Chiu, H.S., Kim, S.J. and Rim, H.J. (1982) Electron microscopic studies on the effect of praziquantel to *Paragonimus westermani*. *Korea Univ. Med. J.*, 19(3):617-630(in Korean).
- Cho, K.M. and Soh, C.T. (1976) Indirect fluorescent antibody test for the serodiagnosis of paragonimiasis and clonorchiasis. *Yonsei Rep. Trop. Med.*, 7(1):26-39.
- Cho, S.Y., Hong, S.T., Rho, Y.H., Choi, S.Y. and Han, Y.C. (1981) Application of micro-ELISA in serodiagnosis of human paragonimiasis. *Korean J. Parasit.*, 19(2):151-156.
- Cho, S.Y. and Kim, S.I. (1983) Detection of *Paragonimus*-specific IgG antibody in CSF and pleural effusion by micro-ELISA. *Korean J. Parasit.*, 21(2):286-288.
- Cho, S.Y., Kim, S.I., Kang, S.Y., Kong, Y., Han, S.K., Shim, Y.S. and Han, Y.C. (1989) Antibody changes in paragonimiasis patients after praziquantel treatment as observed by ELISA and immunoblot. *Korean J. Parasit.*, 27(1):15-21.
- Cho, S.Y., Lee, D.K., Kang, S.Y. and Kim, S.I. (1983) An epidemiological study of human paragonimiasis by means of micro-ELISA. *Korean J. Parasit.*, 21(2):246-256(in Korean).
- Choi, D.W., Ahn, D.H. and Kim, H.S. (1982) Larval trematodes from *Semisulcospira* snails in Kyungpook Province, Korea. *Korean J. Parasit.*, 20(2):147-159.
- Choi, D.W. and Hwang, J.T. (1980) Epidemiological study of *Paragonimus westermani* in Wiscong County, Kyungpook Province, Korea. *Korean J. Parasit.*, 18(2):229-234.
- Choi, D.W., Joo, C.Y. and Kim, J.H. (1981) Prevalence of *Paragonimus westermani* in some Wiscong school children. *Kyungpook Univ. Med. J.*, 22(1):185-189.
- Choi, D.W., Kim, J.I. and Chung, D.I. (1987) Intermediate host survey of *Paragonimus westermani* in Cheongsong County, Kyungpook Province. *Kyungpook Univ. Med. J.*, 28(1):23-27(in Korean).

- Choi, D.W., Kim, M.S. and Joo, C.Y. (1983) Comparative infestation of *Paragonimus westermani* metacercaria from crayfish in endemic area. *Kyungpook Univ. Med. J.*, 24(1):1-9.
- Choi, H.J. (1948) Paragonimiasis and peritonitis followed by lung fluke. *J. Korean Med. Ass.*, 1:29 (in Korean).
- Choi, H.J. (1959) Treatment of paragonimiasis with chloroquine. *Korean Med. J.*, 4(4):483-496 (in Korean).
- Choi, H.J., Yun, B.Y. and Suh, S.J. (1956) Two cases of spinal paragonimiasis. *Eui-Yak-Gye*, 1(3):184-188(in Korean).
- Choi, S.K., Lee, J.S. and Rim, H.J. (1984) The use of ELISA in the diagnosis of human paragonimiasis. *Korea Univ. Med. J.*, 21(1):33-40.
- Choi, W.Y. (1978) Immunoserological diagnosis for paragonimiasis. *Human Sci.*, 2(1):89-92(in Korean).
- Choi, W.Y. (1984a) *Paragonimus westermani*: Pathogenesis and clinical features of infection. *Arzneim.-Forsch./Drug Res.*, 34(2):1184-1185.
- Choi, W.Y. (1984b) Significance of immunodiagnostic methods for paragonimiasis. *J. Catholic Med. Coll.*, 37(1):1-6(in Korean).
- Choi, W.Y., Kimura, K. and Tsuji, M. (1976) Immunoelectrophoresis for anthelmithics evaluation against experimental paragonimiasis. *Korean J. Parasit.*, 14(2):94-102(in Korean).
- Choi, W.Y. and Lee, O.R. (1976) Precipitin reactions between host organ extracts and antisera for *Paragonimus* and *Clonorchis*. *Korean J. Parasit.*, 14(2):90-93(in Korean).
- Choi, W.Y. and Lee, O.R. (1981) Agar gel precipitin reactions in experimental paragonimiasis. *Korean J. Parasit.*, 19(2):101-108(in Korean).
- Choi, W.Y., Lee, O.R., Jin, Y.K. and Chi, J.G. (1979) Lung findings in experimental paragonimiasis. *Korean J. Parasit.*, 17(2):132-146(in Korean).
- Choi, W.Y., Lee, W.K. and Lee, O.R. (1975) Indirect fluorescent antibody test for diagnosis of paragonimiasis. *Korean J. Parasit.*, 13(2):152-158(in Korean).
- Choi, W.Y. and Yoo, J.E. (1985) Ultrastructure of the integument of adult *Paragonimus westermani*. *Korean J. Parasit.*, 23(1):111-122(in Korean).
- Choi, W.Y., Yoo, J.E., Kim, W.G., Yun, B.H., Kim, S.G. and Yoo, W.H. (1984) Prevalence of intestinal helminthic infections and skin tests for *Paragonimus* and *Clonorchis* in tuberculosis patients. *Korean J. Parasit.*, 22(2):209-214(in Korean).
- Choi, W.Y., Yoo, J.E., Nam, H.W. and Choi, H.R. (1986) Purification of antigenic proteins of *Paragonimus westermani* and their applicability to experimental cat paragonimiasis. *Korean J. Parasit.*, 24(2):177-186(in Korean).
- Chu, J.K., Ryang, Y.S. and Cho, Y.J. (1972) Histochemical study on trematodes: Distribution of carbonic anhydrase activity. *Korean J. Parasit.*, 10(1):27-33(in Korean).
- Chun, H.B. (1970) Epidemiological studies on *Paragonimus westermani* in Hae-nam District, Cholla-Nam-Do, Korea. *Yonsei J. Med. Sci.*, 3(1):174-186 (in Korean).
- Chun, M.H. (1966) Histochemical studies on parasitic helminths: The distribution of peroxidase and polyphenol oxydase. *J. Busan Med. Coll.*, 6(1):161-176(in Korean).
- Chung, C.H. (1971) Human paragonimiasis. Pathology of protozoal and helminthic diseases with clinical correlation. pp.504-535. Ed. by Marcial-Rojas, R.A., The Williams & Wilkins Company, Baltimore, USA.
- Chung, J.J. and Kim, Y.H. (1968) Sterility due to paragonimiasis involving female genital organs and greater omentum. *J. Korean Med. Ass.*, 11(9):765-768(in Korean).
- Chung, P.R. (1983) Review and problems on *Paragonimus* and paragonimiasis with special reference to its intermediate and natural final hosts. *Yonsei Rep. Trop. Med.*, 14(1):44-56.
- Chyu, I. (1957) Epidemiological study of paragonimiasis: Report of the field survey in Kohung area. *Korean Med. J.*, 2:1209-1215(in Korean).
- Chyu, I. (1959) Skin test for paragonimiasis and clonorchiasis. *Korean Med. J.*, 4(4):477-480(in Korean).
- Chyu, I. (1960) Paragonimiasis found among pulmonary tuberculosis patients. *Korean J. Int. Med.*, 3(1):71-74(in Korean).
- Chyu, I. (1962a) Studies on the experimental paragonimiasis I. Parasitological and histopathological study on dog paragonimiasis. *Korean J. Int. Med.*, 5(4):241-250(in Korean).
- Chyu, I. (1962b) Studies on the experimental paragonimiasis II. Immunological study on dog paragonimiasis. *Korean J. Int. Med.*, 5(4):251-259.
- Chyu, I. (1962c) Studies on the experimental paragonimiasis III. Clinical and laboratory findings on dog paragonimiasis. *J. Korean Med. Ass.*, 5(4):1778-1784(in Korean).

- Chyu, I. (1966) Present status of paragonimiasis in Korea. *Theses of Cath. Med. Coll.*, 11:301-308.
- Chyu, I. and Kim, J.S. (1962) Studies on the experimental paragonimiasis IV. Comparison between the roentgenological and pathological findings in dog paragonimiasis. *Korean J. Int. Med.*, 5(4):261-270(in Korean).
- Chyu, I. and Kim, K.S. (1965) Studies on the purification of fluke antigens Part 1. Purification of *Paragonimus* antigen. *Theses of Cath. Med. Coll.*, 9:153-158.
- Chyu, I. and Lee, C.S. (1966) Observation on the metacercariae of lung fluke in *Eriocheir japonicus* in Cheju Island. *Theses of Cath. Med. Coll.*, 10:289-301(in Korean).
- Chyu, I. and Lee, O.Y. (1961) The complement fixation test of paragonimiasis. *Rep. Nat. Inst. Prev. Inf. Dis.*, 4(1):1-6(in Korean).
- Chyu, I., Yoo, J.S. and Lim, Y.C. (1964) Studies on the treatment of paragonimiasis with Thistoming (Bithionol Preparation). *Korean Med. J.*, 9(4):447-454(in Korean).
- Graumann, T., Graumann, H.W. and Shin, S.W. (1957) Pulmonary and extrapulmonary paragonimiasis in 311 cases studies in Korea. *J. Korean Nat. Tubercul. Ass.*, 17:117-131.
- Han, K.J. (1956) Ectopic parasitism of *Paragonimus westermani*. *Eui-Yak-Ge*, 1:189-192(in Korean).
- Han, S.H. and Woo, C.K. (1969) Immuno-diffusion and complement-fixation test in paragonimiasis of cat. *Korean J. Parasit.*, 7(3):160-165(in Korean).
- Hong, S.S., Kim, S.C. and Kim, Y.S. (1959) A study of paragonimiasis: An analysis of 340 cases. *New Med. J.*, 2(3):99-102.
- Hong, S.T., Lee, S.H., Ahn, H.S. and Yun, C.K. (1982a) A case of niclofolan (Bilevon®) intoxication. *Korean J. Parasit.*, 20(1):49-52.
- Hong, S.T., Lee, S.H., Chi, J.G., Jin, Y.S., Kim, C.S. and Chang, Y.S. (1982b) A case of systemic paragonimiasis with ovarian involvement. *Korean J. Parasit.*, 20(1):53-59.
- Hong, Y.A., Joo, C.Y. and Pyun, Y.S. (1986) Infestation status of *Paragonimus westermani* metacercariae in the second intermediate host in Ulchin County, Kyungpook Province. *Korean J. Parasit.*, 24(2):194-200.
- Huer, B., Kim, S.I., Kang, S.Y. and Cho, S.Y. (1985) Electrophoretic patterns of proteins from *Paragonimus westermani* in early developmental stages. *Korean J. Parasit.*, 23(2):189-196.
- Ihm, G.S. and Ahn, Y.K. (1979) Comparative studies on type determination of *Paragonimus westermani* in Korea. *Yonsei Med. J.*, 12(1):38-47(in Korean).
- Jin, S.W., Lee, J.S. and Rim, H.J. (1983) Comparative studies of ELISA test and Ouchterlony test by use of the immune animal sera in clonorchiasis and paragonimiasis. *Korea Univ. Med. J.*, 20(1):191-199(in Korean).
- Joo, C.Y. (1979) Prevalence of *Paragonimus westermani* among ROK army soldiers. *Kyungpook Univ. Med. J.*, 20(1):105-108(in Korean).
- Joo, C.Y., Ahn, S.H. and Park, Y.C. (1985) Epidemiological survey of *Paragonimus westermani* in Ulchin County, Kyungpook Province, Korea. *Korean J. Parasit.*, 23(1):102-110.
- Joo, K.H., Ahn, H., Chung, M.S. and Rim, H.J. (1989a) Demonstration of species specific and cross reactive components of *Paragonimus westermani* crude worm antigen by EITB. *Korean J. Parasit.*, 27(1):9-14.
- Joo, K.H., Hong, S.C., Chung, M.S. and Rim, H.J. (1989b) Analysis of antigenic specificities of *Paragonimus westermani* developmental stages using immunoblot technique. *Korean J. Parasit.*, 27(1):1-7(in Korean).
- Jung, S.G., Whang, I.W., Choi, D.W. and Ock, M.S. (1985) Cell-mediated immunity to *Paragonimus westermani* in inbred mice(ICR strain). *Kyungpook Univ. Med. J.*, 26(3):270-278(in Korean).
- Kang, S.Y. (1962a) Chemotherapy of paragonimiasis with bithionol. *New Med. J.*, 5(5):401-407(in Korean).
- Kang, S.Y. (1962b) Studies on chemotherapy of pulmonary paragonimiasis I. Clinical observation on the treatment with bithionol. *Korean J. Int. Med.*, 5(8):531-547(in Korean).
- Kang, S.Y., Cho, S.Y. and Seo, B.S. (1975) Studies on the lung fluke, *Paragonimus iloktsuenensis* IV. A mathematical analysis on metacercarial density of *Paragonimus iloktsuenensis* in crab host, *Sesarma dehaani*. *Korean J. Parasit.*, 13(1):31-37.
- Kang, S.Y., Choo, J.K. and Loh, I.K. (1963) Histochemical studies on *Paragonimus westermani*: Especially on the distribution of glycogen, nucleic acids, fat substance and polyphenol oxidase. *Korean J. Int. Med.*, 6(11):1127-1134(in Korean).
- Kang, S.Y., Chun, Y.S. and Loh, I.K. (1965a) An experimental study on uptake of Cr⁵¹ tagged red blood cells to *Paragonimus westermani* in definitive host. *Korean J. Parasit.*, 3(3):127-131(in Korean).

- Kang, S.Y., Loh, I.K. and Cho, B.C. (1964a) Studies on the chemotherapy of pulmonary paragonimiasis (Report II). Experimental chemotherapy with bithionol on dogs infected with *Paragonimus westermani*. *J. Korean Med. Ass.*, 7(3):133-141(in Korean).
- Kang, S.Y., Loh, I.K., Ham, E.K. and Chyu, I. (1963) An experimental study on chemoprophylaxis in paragonimiasis(Report I). *J. Korean Med. Ass.*, 6(8):833-840(in Korean).
- Kang, S.Y., Loh, I.K., Park, Y.H., Kim, B.C. and Lim, T.B.(1964b) Studies on pulmonary paragonimiasis in Cheju Province(Quelpart Island)(Report III). The incidence of pulmonary *Paragonimus* metacercaria infection in the crabs collected at Cheju Province. *Korean J. Int. Med.*, 7(4):223-228(in Korean).
- Kang, S.Y., Loh, I.K., Park, Y.H., Kim, B.C. and Lim, T.B. (1965b) Survey on the eating habits of foods infested with parasites among inhabitants in Cheju Province, Korea. *Korean J. Int. Med.*, 8(4):197-209(in Korean).
- Kang, S.Y., Loh, I.K., Park, Y.H., Kim, B.C. and Lim, T.B. (1965c) Studies on paragonimiasis in Cheju Province(Quelpart Island)(Report II). An epidemiologic survey for human paragonimiasis by the use of intradermal screening test in students of primary, middle, high school. *Korean J. Int. Med.*, 8(5):251-258(in Korean).
- Kang, S.Y., Loh, I.K., Park, Y.H. and Lim, T.B. (1964c) Studies on pulmonary paragonimiasis in Cheju Province (Quelpart Island) I. An epidemiologic survey for human paragonimiasis by the use of intradermal test in primary school children. *Korean J. Int. Med.*, 7(7):385-390(in Korean).
- Kang, S.Y., Loh, I.K., Song, T.Y. and Lyu, T.S. (1964d) Studies on paragonimiasis in Ko-Hoong County, Korea(Report 1). An epidemiologic survey for human paragonimiasis by use of intradermal screening test. *Korean J. Parasit.*, 2(3):189-194 (in Korean).
- Kim, B.C. (1967) Studies on the effects of physico-chemical agents to the metacercariae of *Paragonimus westermani*. *Theses of Cath. Med. Coll.*, 13: 335-349(in Korean).
- Kim, C.H., Cheung, B.S. and Kim, O.C. (1967) Epidemiological survey of *Paragonimus* and *Clonorchis* in Houk-suk, Chung-nam-do, Korea. *Korean Med. J.*, 12(2):955-958(in Korean).
- Kim, D.C.(1984) *Paragonimus westermani*: Life cycle, intermediate hosts, transmission to man and geographical distribution in Korea. *Arzneim.-Forsch./Drug Res.*, 34(II):1180-1183.
- Kim, D.C., Chung, E.B., Lee, O.Y., Chang, J.S. and Son, G.T. (1979) Endemicity of paragonimiasis in Hadong-Gun, Gyeongsang Nam Do. *Rep. NIH Korea*, 16:339-344(in Korean).
- Kim, D.C. and Lee, O.Y. (1970) Experimental infection of *Paragonimus westermani* to final host passing through unfavorable host. *Korean J. Parasit.*, 8(3) Supp.:16(in Korean).
- Kim, D.C., Lee, O.Y. and Sung, W.K. (1969) Immunological studies of *Paragonimus westermani* I. Studies on the antibody production against immunization of *Paragonimus* antigens and the determination of sero-immunologic reaction. *Rep. NIH Korea*, 6:291-308(in Korean).
- Kim, D.C., Lee, O.Y., Lee, J.S. and Ahn, S.A. (1982) Studies on control of paragonimiasis II. Immunodiagnosis of human paragonimiasis by ELISA using secretory-excretory antigen. *Rep. NIH Korea*, 19:109-114(in Korean).
- Kim, D.C., Lee, O.Y., Lee, J.S., Ahn, J.S., Chang, Y.M., Son, S.C., Ahn, S.A. and Lee, D.W. (1982) Studies on control of paragonimiasis I. Experimental chemotherapy with praziquantel of *Paragonimus westermani*(parthenogenetic type). *Rep. NIH Korea*, 19:91-108(in Korean).
- Kim, D.C., Lee, O.Y., Miyazaki, I. and Hashiguchi, Y. (1971) Comparative studies on two forms of *Paragonimus* parasitic in *Eriocheir japonicus* on Cheju Island, Korea(Preliminary report). *Jpn. J. Parasitol.*, 20(1):58-61.
- Kim, D.C., Sun, S.C. and Bergner, J.F. (1964) Chemotherapy with bithionol-S-oxide in animals infected with *Paragonimus westermani*. *Rep. NIH Korea*, 1(1):153-166.
- Kim, D.K.(1966) Clinical study on paragonimiasis. *J. Busan Med. Coll.*, 6(1):205-211(in Korean).
- Kim, J.H. and Choi, D.W. (1977) *Paragonimus westermani* infection among residents from Northern Chilgok, Kyungpook Province, Korea. *Kyungpook Univ. Med. J.*, 18(2):166-171.
- Kim, J.J., Chang, J.K., Chung, P.R. and Soh, C.T. (1985) A study on the intermediate hosts of *Paragonimus westermani* in Bogil islet, Chonra-Nam-Do, Korea. *Korean J. Malacol.*, 1(1):19-23 (in Korean).
- Kim, J.S. (1957) Treatment of pulmonary paragonimiasis with partial lobectomy. *Korean Med. J.*,

- 2:693-697(in Korean).
- Kim, J.S. (1969a) Mass chemotherapy in the control of paragonimiasis. *Korean J. Parasit.*, 7(1):6-14.
- Kim, J.S. (1969b) An evaluation of intradermal test for the screening of paragonimiasis by comparing antigens variously processed. *Korean J. Parasit.*, 7(1):15-24.
- Kim, J.S. (1969c) A study on the infection status on intermediate hosts by *Paragonimus* on Cheju Island. *Korean J. Parasit.*, 7(3):171-177.
- Kim, J.S. (1970) A comparison of sensitivity on stool and sputum examination for diagnosis of paragonimiasis. *Korean J. Parasit.*, 8(1):22-24.
- Kim, J.S. and Bang, F.B. (1974) A follow-up study to evaluate the efficacy of mass chemotherapy for control of paragonimiasis. *Korean J. Parasit.*, 12(1):8-13(in Korean).
- Kim, J.S. and Park, S.S. (1974) Values of intradermal test and multiple sputum examinations for diagnosis of paragonimiasis. *Korean J. Parasit.*, 12(2):119-125.
- Kim, J.T. (1957) A case of cerebral paragonimiasis. *J. Korean Med. Ass.*, 2:329(in Korean).
- Kim, K.M., Ahn, M.H. and Min, D.Y. (1987) Ultrastructural studies on the surface of *Paragonimus westermani* metacercariae. *Korean J. Parasit.*, 25(2):129-140(in Korean).
- Kim, N.W. (1975) Studies on the indirect fluorescent antibody test for the serodiagnosis of paragonimiasis. *Yonsei J. Med. Sci.*, 8(1):27-46(in Korean).
- Kim, S.H., Kong, Y., Kang, S.Y. and Cho, S.Y. (1988) Immunoblot observation of antigenic protein fractions in *Paragonimus westermani* reacting with human patients sera. *Korean J. Parasit.*, 26(4):239-244.
- Kim, S.I., Kang, S.Y. and Cho, S.Y. (1983) On the applicability of partially purified antigenic preparations of *Paragonimus westermani*. *Korean J. Parasit.*, 21(2):257-264(in Korean).
- Kim, S.I., Ko, E.K., Kang, S.Y. and Cho, S.Y. (1986) Antigenicity of the soluble egg antigen of *Paragonimus westermani*. *Korean J. Parasit.*, 24(1):49-54(in Korean).
- Kim, S.K. (1956) Cerebral paragonimiasis and its surgical treatment. *J. Korean Med. Ass.*, 2:225(in Korean).
- Kim, S.K. (1959) Cerebral paragonimiasis: A report of forty-seven cases. *AMA Arch. Neurol.*, 1:30-37.
- Kim, Y.M., Choy, C.H. and Choi, D.W. (1974) Epidemiological surveys of *Paragonimus westermani* in Kyungpook Province, Korea. *Kyungpook Univ. Med. J.*, 15(1):165-174.
- Lee, B.H. (1958) Epidemiological survey of paragonimiasis among residents in Taedong Myun, Kyung Sang Nam Do, Korea by *Paragonimus* intradermal test. *J. Korean Med. Ass.*, 10:10(in Korean).
- Lee, C.K., Mok, D.S. and Kim, S.W. (1958) Surgical aspect of cerebral paragonimiasis in Korea. *Korean Med. J.*, 3:115-133(in Korean).
- Lee, C.Y. (1974) Antigenicity of *Paragonimus* intradermal antigens. *J. Busan Med. Coll.*, 14(2):441-448(in Korean).
- Lee, D.M. and Choi, D.W. (1979) Prevalence of *Paragonimus westermani* among school children in Kasan Myun, Chilgok county, Kyungpook Province, Korea. *New. Med. J.*, 22(12):1179-1182 (in Korean).
- Lee, E.H. and Seo, B.S. (1967) Studies on malic dehydrogenase activity in parasitic helminths. *Korean J. Parasit.*, 5:125-133(in Korean).
- Lee, G.J. (1984) Electron-microscopic observation on the effect of praziquantel on *Paragonimus westermani*. *J. Cath. Med. Coll.* 37(2):433-455(in Korean).
- Lee, J.H. (1975) Clinical study of paragonimiasis. *J. Busan Med. Coll.* 15:205-215(in Korean).
- Lee, J.S. (1977) Experimental studies on the immunodiagnosis of clonorchiasis and paragonimiasis. *Korea Univ. Med. J.*, 14(1):1-18.
- Lee, J.S., Bae, P.W., Rim, H.J. and Shin, H.S. (1980a) Epidemiological change on paragonimiasis in Ung Chi Myun, Bo Sung Gun. *Korean J. Rural Med.*, 1:40-45(in Korean).
- Lee, J.S., Chung, Y.W., Rim, H.J. and Park, Y.K. (1980b) Epidemiological change on paragonimiasis in Kwang-Tan Myun, Pa Joo Gun. *Korea Univ. Med. J.*, 17(3):627-632(in Korean).
- Lee, J.S., Kim, J.R., Kim, S.J., Rim, H.J., Song, O.D. and Kim, M.S. (1979) Epidemiological change on paragonimiasis 2nd intermediate host in Kang Hwa Gun. *Korean J. Rural Med.*, 4(1):71-80(in Korean).
- Lee, J.S., Lee, K.H., Rim, H.J., Kim, Y.K., Yoo, I.S. and Jon, S.S. (1980c) Positive rates on paragonimiasis in Chang Heung Gun. *Korean J. Rural Med.*, 5(1):34-39(in Korean).
- Lee, O.R. (1979) A histopathologic study of the lungs infected with *Paragonimus westermani* in the dog. *Korean J. Parasit.*, 17(1):19-44(in

- Korean).
- Lee, O.R. (1986) Serological immunoprecipitation of several *Paragonimus westermani* antigens, and electrophoretic patterns of antigenic proteins. *J. Soonchunhyang Univ.*, 9(2):239-246(in Korean).
- Lee, O.R. and Chang, J.K. (1986) ELISA of paragonimiasis in cat by crude and purified antigens of *Paragonimus westermani*. *Korean J. Parasit.*, 24(2):187-193(in Korean).
- Lee, O.R. and Choi, W.Y. (1983) Comparison of agar-gel diffusion tests, counterimmunoelectrophoresis and enzyme-linked immunosorbent assay in the sera of skin test positives for paragonimiasis. *Korean J. Parasit.*, 21(2):270-280(in Korean).
- Lee, O.Y., Kim, D.C., Han, E.J. and Kim, N.S. (1976) An experimental study on the mode of infection of *Paragonimus westermani* to final host through unfavorable hosts. *Rep. NIH Korea*, 13: 209-218(in Korean).
- Lee, O.Y., Kim, D.C. and Jeong, E.B. (1980) Immunodiagnosis of paragonimiasis by indirect fluorescent antibody technique with cryocut adult worm antigen. *Rep. NIH Korea*, 17:405-410.
- Lee, O.Y. and Nam, S.Y. (1977) Effect of NaCl on mortality of metacercariae of *Paragonimus westermani* with reference to the metacercariae in crabs soaked in soy-bean sauce, Gejang. *Rep. NIH Korea*, 14:203-218. (in Korean).
- Lee, S.H. (1963) Paper chromatographic study on the amino acids of trematodes. M.S. Thesis, Seoul National University.
- Lee, S.H. (1967) Studies on lactic dehydrogenase activity in parasitic helminths. *Korean J. Parasit.*, 5(1):5-16(in Korean).
- Lee, S.H., Kim, S.J., Chai, J.Y. and Sohn, W.M. (1989a) Tegumental ultrastructures of *Paragonimus iloktsuenensis* according to the developmental stages. *Korean J. Parasit.*, 27(1):57-66(in Korean).
- Lee, S.H., Koo, K.H., Chai, J.Y., Hong, S.T. and Sohn, W.M. (1989b) Experimental infection of *Paragonimus iloktsuenensis* to albino rats, dogs and cats. *Korean J. Parasit.*, 27(3):197-202(in Korean).
- Lee, S.H., Park, H.J., Hong, S.J., Chai, J.Y. and Hong, S.T. (1987) *In vitro* effect of praziquantel on *Paragonimus westermani* by light and scanning electron microscopic observation. *Korean J. Parasit.*, 25(1):24-36.
- Lee, S.H., Yoon, J.S. and Seo, B.S. (1964) Paper chromatographic study on the amino acids of some parasitic helminths. *Korean J. Parasit.*, 2:91-96.
- Lee, S.K., Choi, D.W. and Park B.H. (1959 & 1960) A clinical case of heteroparasitization of *Paragonimus* in urinary tract. *Jap. Mie Igaku*, 60:2486-2488(in Japanese).
- Lee, S.M., Hong, S.T., Lee, S.H. and Shim, T.S. (1981) Ultrastructural study on the teguments of juvenile and adult *Paragonimus westermani*. *Chung-Ang J. Med.*, 6(4):579-589(in Korean).
- Lee, W.S. and Choi, D.W. (1984) Intermediate host survey of *Paragonimus westermani* in endemic areas of Youngpung County, Kyungpook Province. *Kyungpook Univ. Med. J.*, 25(2):148-152(in Korean).
- Lee, Y.C., Lee, J.S. and Rim, H.J. (1986) Study on the immunodiagnosis of human paragonimiasis using a urine sample. *Korea Univ. Med. J.*, 23(3):35-42(in Korean).
- Lee, Y.H. (1966) Experimental studies on the route of larval migration of *Paragonimus westermani*. *Korean Central J. Med.*, 11(3):331-344(in Korean).
- Lee, Y.W., Bae, K.H. and Ahn, Y.K. (1981) Epidemiological study on *Paragonimus* infections in Hoengseong-gun, Gangweon-Do. *Korean J. Rural Med.*, 6(1):5-12(in Korean).
- Lim, Y.C., Yu, B.J., Kim, E.S., Kim, W.I., Lee, H., Park, B.J. and Soh, C.T. (1964) A trial with dehydroemetine hydrochloride(Ro 1-9334) in paragonimiasis in Korea. *Korean Central J. Med.*, 6(2):145-155(in Korean).
- Loh, I.K. (1964) Comparison of detection rate of some trematode eggs by combined technique of formalin-ether sedimentation and zinc sulfate floatation. *Korean J. Parasit.*, 2(1):52-54(in Korean).
- Loh, I.K. (1966a) Studies on the sources of infection of distomiasis: Part I. An investigation on the eating habits of Korean to the second intermediate hosts. *Korean J. Publ. Hlth.*, 3(1):1-7(in Korean).
- Loh, I.K. (1966b) Studies on the sources of infection of distomiasis: Part 3. An experimental study on *Paragonimus westermani* infectiousness of infected fresh-water crayfishes and crabs treated with various cooking methods. *Korean J. Publ. Hlth.*, 3(1):15-21(in Korean).
- Loh, I.K., Kim, J.J., Hyun, J.K. and Namgoong, T. (1969) Experimental observations on water contamination by second intermediate host infected with *Paragonimus westermani*. *Korean J. Parasit.*, 7(1):1-5(in Korean).
- Min, D.S., Kim, D.C., Min, H.K. and Chae, Y.K. (1958) Spontaneous pneumothorax and pleurisy

- accompanied by lung fluke. *Korean Med. J.* 3: 77-82(in Korean).
- Min, D.Y., Kim, K.M. and Woo, N.S. (1989) Morphological changes of *Paragonimus westermani* metacercariae by antibody and complement. *J. Hanyang Med. Coll.*, 9(1):367-377(in Korean).
- Min, H.K. (1980) A note on intermediate hosts of *Paragonimus* in district of Seoul. *Korean J. Parasit.*, 18(1):105-108(in Korean).
- Min, H.K. (1981) An epidemiological study on zoonoses in Korea. *Korean J. Parasit.*, 19(1):60-75(in Korean).
- Min, H.K. and Chun, K.S. (1987) Changes of some epidemiologic aspects in a hyperendemic area of paragonimiasis in Kanghwa-gun, Kyonggido, Korea. *Ewha Med. J.*, 10(4):195-201(in Korean).
- Min, H.K. and Hong, C.E. (1974) Investigation on general status of the helminthic infections in a remote area in Chungchongnamdo, Korea(I). Onamri, Sayangmyun, Chongyanggun. *New Med. J.*, 174(4):51-57(in Korean).
- Min, Y.O. and Seo, B.S. (1966) Studies on transaminase reactions in some parasitic helminths. *Korean J. Parasit.*, 4(2):7-13.
- Miyazaki I.(1978) Two types of lung fluke which has been called *Paragonimus westermani*(Kerbert, 1878). *Med. Bull. Fukuoka Univ.*, 5(4):251-263.
- Miyazaki, I. (1979) On the newly proposed lung fluke, *Paragonimus pulmonalis* (Baelz, 1880). *Med. Bull. Fukuoka Univ.*, 6(3):267-276(in Japanese).
- Miyazaki, I.(1982) Paragonimiasis. *CRC Handbook Series in Zoonoses*. Section C. Parasitic Zoonoses Vol. III:143-164.
- Moon, H.K. and Shin, J.W. (1986) Immune response to *Paragonimus westermani* in mice immunized by metabolites of adult worms and excysted metacercariae. *J. Pusan Med. Coll.* 26(1):69-76(in Korean).
- Oh, S.J. (1963) Clinical observation on cerebral paragonimiasis. *Korean J. Int. Med.*, 6(11):649-650(in Korean).
- Oh, S.J. (1967) Bithionol treatment in cerebral paragonimiasis. *Am. J. Trop. Med. Hyg.*, 16:585-590.
- Oh, S.J. (1968) Roentgen findings in cerebral paragonimiasis. *Radiology*, 90:292-299.
- Oh, S.J. and Laursen, L. (1964) Spinal paragonimiasis: Report of a case and literature review. *J. Korean Med. Ass.*, 7(6):580-593.
- Park, C.M. (1961) An epidemiological and clinical study on paragonimiasis in Korean children. *J. Korean Ped. Ass.*, 4(1):50-60(in Korean).
- Park, C.M. (1963) Symptoms, diagnosis and treatment of paragonimiasis. *J. Korean Med. Ass.*, 6(5): 482-486(in Korean).
- Park G.H., Ock, M.S. and Choi, D.W. (1984) A survey on intermediate hosts of *Paragonimus westermani* in endemic area in Andong County, Kyungpook Province. *Kyungpook Univ. Med. J.*, 25(2):158-162(in Korean).
- Park, H.Y., Lee, J.S. and Rim, H.J. (1987) Changes of serum and urine IgG levels before and after treatment in human paragonimiasis. *Korea Univ. Med. J.*, 27(3):35-43(in Korean).
- Park, J.S. (1962) Extradural cyst associated with spinal paragonimiasis. *Korean Central J. Med.*, 2: 489-492(in Korean).
- Park, J.S., Lee, U.T., Kim, J.S., Lee, H.K. and Lee, Y.L. (1963) 2 cases of ectopic paragonimiasis found in parietal peritoneum and greater omentum. *Korean Med. J.*, 8:1107-1111(in Korean).
- Park, K.H. and Shin, J.W. (1986) Acquired immunity in cats to *Paragonimus westermani*. (Personal communication).
- Park, S.D. and Choi, D.W. (1974) Distribution of the metacercariae in the second intermediate host of lung fluke, *Paragonimus westermani*. *Kyungpook Univ. Med. J.*, 15(1):117-127.
- Park, Y.O. (1971) Autoradiographic studies on the uptake and distribution of ¹⁴C-glucose by *Paragonimus westermani*. *Korean J. Parasit.* 9(1):9-15.
- Rim, H.J. (1983) Chemotherapy of clonorchiasis and paragonimiasis. *J. Korean Soc. Chemoth.*, 1(1):3-17(in Korean).
- Rim, H.J. (1984) Paragonimiasis: Experimental and clinical experience with praziquantel in Korea. *Arzneim-Forsch./Drug Res.* 34(II):1197-1203.
- Rim, H.J. and Chang, Y.S. (1980) Chemotherapeutic effect of niclofolan and praziquantel in the treatment of paragonimiasis. *Korea Univ. Med. J.*, 17(1):113-128(in Korean).
- Rim, H.J., Chang, Y.S., Lee, J.S., Joo, K.H. and Suh, W.H. (1981) Clinical evaluation of praziquantel(Embay 8440; Biltricide) in the treatment of *Paragonimus westermani*. *Korean J. Parasit.*, 19(1):27-37.
- Rim, H.J., Kim, M.S., Ha, J.H. and Chang, D.S. (1976) Experimental chemotherapeutic effects of niclofolan(Bayer 9015, Bilevon) on the animals infected with *Paragonimus westermani* or *P.*

- iloktsuenensis*. *Korean J. Parasit.*, 14(2):140-146.
- Rim, H.J., Lee, J.S., Chung, H.S., Hyun, I. and Jung, K.H. (1975) Epidemiological survey on paragonimiasis in Kang Hwa Gun. *Korean J. Parasit.*, 13(2):139-151(in Korean).
- Rim, H.J., Lee, J.S., Kim, D.U. and Chung, S.S. (1980) Epidemiological change on paragonimiasis in Po du Myun, Ko Heung Gun. *Korea Univ. Med. J.*, 17(1):345-350(in Korean).
- Sadun, E.H., Buck, A.A., Lee, B.K., Moon, C.H. and Burke, J.C. (1959) Epidemiologic studies for paragonimiasis and clonorchiasis by the use of intradermal tests. *Am. J. Hyg.*, 69:68-77.
- Seo, B.S. and Koo, B.Y. (1971) Studies on the lung fluke *Paragonimus iloktsuenensis* Chen, 1940. I. On the occurrence of *P. iloktsuenensis* in natural final hosts at the Nakdong and Sumjin river deltas in Korea. *Seoul J. Med.*, 12(1):31-43.
- Seo, B.S. and Kwak, J.W. (1972) Studies on the lung fluke, *Paragonimus iloktsuenensis* II. On the metacercaria, the second intermediate hosts and development in mice. *Seoul J. Med.*, 13(4):221-233.
- Seo, B.S. and Lee, W.J. (1973) Studies on the lung fluke, *Paragonimus iloktsuenensis* III. Migration, development and egg-production in albino rats. *Seoul J. Med.*, 14(2):131-141.
- Seol, K.D. and Byun, H.W. (1958) Roentgenographic findings in pulmonary paragonimiasis patients. *Korean Med. J.*, 3:181-183(in Korean).
- Soh, C.T. (1962) Paragonimiasis in Korea:Biological aspect. *Yonsei. Med. J.*, 3:79-84.
- Soh, C.T. (1975) Biology and pathogenesis of *Paragonimus westermani*. *Tubercul. Resp. Dis.*, 22(1):17-20(in Korean).
- Soh, C.T., Ahn, Y.K., Bae, K.H. and Park, C.Y. (1981) Praziquantel in the treatment of paragonimiasis. *Yonsei Rep. Trop. Med.*, 12(1):22-32.
- Soh, C.T., Kim, C.H., Kim, K.H. and Kim, Y.R. (1964a) Clinical observations on the treatment of paragonimiasis with bithionol. *Korean Med. J.*, 9(2):109-116(in Korean).
- Soh, C.T., Kim, D.C., Min, H.K., Min, D.Y. and Kang, H.C. (1977) Experimental study on anthelmintic activity of flubendazole against trematodes. *Yonsei Rep. Trop. Med.*, 8(1):79-84.
- Soh, C.T., Kim, J.H. and Ahn, Y.K. (1962) Distribution of lung fluke in dogs. *Med. Digest*, 4(4):1919-1922(in Korean).
- Soh, C.T., Lee, K.T., Ahn, Y.K. and Lee, Y.H. (1964b) A new second intermediate host of genus *Paragonimus*. *Korean J. Parasit.*, 2(1):35-40.
- Soh, C.T., Lee, K.T., Ahn, Y.K. and Lee, Y.H. (1966) Shrimp as intermediate host of *Paragonimus westermani* in Korea. *J. Parasitol.*, 52(5):1034-1035.
- Soh, C.T., Lee, K.T., Min, D.Y., Min, H.K., Ahn, Y.K., Chung, P.R., Yong, T.S., Kim, T.U., Lee, J.H., Chang, D.H. and Kang, J.S. (1986) Field operational research on the control of paragonimiasis in Korea. *Yonsei Rep. Trop. Med.*, 17(1):30-41.
- Soh, C.T., Min, D.Y., Ryu, J.S. and Yong, T.S. (1985) Study on the reproducibility of ELISA technique for the diagnosis of clonorchiasis and paragonimiasis. *Yonsi Rep. Trop. Med.*, 16(1):1-10.
- Sohn, Y.W. and Choi, D.W. (1977) Endemic foci of *Paragonimus westermani* in Chilgok, Kyungpook Province, Korea. *Korean J. Parasit.*, 15(2):133-138.
- Suh, S.K. and Joo, C.Y. (1990) Epidemiological survey of *Paragonimus westermani* among residents in Ulchin county, Kyungpook Province, Korea(in press).
- Suh, Y.H. and Shim, B.S. (1959) A case of spinal paragonimiasis. *Abstr. Korean Soc. Parasit.*, 1:19 (in Korean).
- Walton, B.C. and Chyu, I. (1959) Distribution of *Paragonimus westermani* and *Clonorchis sinensis* in Korea. *Korean Med. J.*, 4(9):103-109.
- Weinstein, P.P., Duman, L.J., Trelawny, G.S. and Patterson, J.C. (1953) Paragonimiasis: Failure of nilodin in therapy and report of one case with urinary tract involvement. *Am. J. Trop. Med. Hyg.*, 2:517-523.
- Yokogawa, M. (1982) Newly introduced questions-concerning *Paragonimus westermani*. *J. Formosan Med. Ass.*, 81(7):774-780.
- Yokogawa, M., Araki, K., Koyama, H., Seo, B.S., Lee, S.H. and Cho, S.Y. (1971) On the lung fluke, *Paragonimus iloktsuenensis* Chen, 1940 in Korea. *Jpn. J. Parasitol.*, 20(3):215-221.
- Yong, T.S., Kim, T.S., Lee, J.S., Lee, O.Y. and Kim, D.C. (1987) Detection of circulating antigens in rats experimentally infected with *Paragonimus westermani* by ELISA. *Korean J. Parasit.*, 25(4):141-148.
- Yoo, J.S. and Chyu, I. (1966) An experimental study on the ectopic infection of lung fluke. *Korean*

- Central J. Med.*, 10(3):351-365(in Korean).
- Yoon, J.S., Kim, S.J. and Rim, H.J. (1984) Electron-microscopic studies on the effect of praziquantel to the young adult worm of *Paragonimus westermani*. *Korea Univ. Med. J.*, 21(1):113-125(in Korean).
- Yun, B.H. and Choi, W.Y. (1973) Serological studies on paragonimiasis. *J. Cath. Med. Coll.* 25:163-176(in Korean).
- Yun, D.J. (1960) Paragonimiasis in children in Korea. *J. Pediatrics*, 56(6):736-751.
- Yun, D.J. (1965) Epidemiologic study of paragonimiasis in Kyunggi-Do. *J. Korean Med. Ass.*, 8(12):757-770(in Korean).