

Barbara Wildhaber · Felix Niggli · Eva Bergsträsser
Thomas Stallmach · Peter Sacher

Paraneoplastic syndromes in ganglioneuroblastoma: contrasting symptoms of constipation and diarrhoea

Received: 21 November 2002 / Accepted: 25 February 2003 / Published online: 9 May 2003
© Springer-Verlag 2003

Abstract A paraneoplastic syndrome is occasionally the first clinical symptom seen with tumours. We report on two children who initially presented with paraneoplastic syndromes due to ganglioneuroblastomas: the first with severe watery diarrhoea caused by a ganglioneuroma producing vasoactive intestinal peptide, the second with non-treatable constipation, caused by ganglioneuroma-produced anti-neuronal nuclear antibodies. **Conclusion:** Either severe diarrhoea or chronic constipation may represent rare paraneoplastic syndromes in ganglioneuroblastomas.

Keywords Anti-neuronal nuclear antibodies
Ganglioneuroblastoma · Paraneoplastic syndrome
Vasoactive intestinal peptide

Abbreviations ANNA anti-neuronal nuclear antibodies
VIP vasoactive intestinal peptide · WDHA watery
diarrhoea-hypokalaemia-achlorhydria

Introduction

Paraneoplastic syndromes in children are rare. However, mature neuroblastomas, i.e. ganglioneuroblastomas, are known to produce peptides that may cause paraneo-

plastic syndromes, which are mainly neurological, such as cerebellar encephalopathy [15], opsoclonus-myoclonus [11], and encephalomyelitis/sensory neuronopathy [17]. Gastrointestinal paraneoplastic syndromes of ganglioneuroblastomas have been rarely described.

Within the last 15 years, from 1987 until 2001, in our institution, 50 children with tumours arising from the neural crest were diagnosed. Five of them were classified primarily as ganglioneuroblastoma and four as ganglioneuroma. The remaining cases were a neuroblastoma. Two of the children with a ganglioneuroblastoma presented exclusively with severe gastrointestinal symptoms, which were recognised to be rare paraneoplastic syndromes.

Case reports

Case 1

A 19-month-old girl presented with a 4-month history of watery, non-bloody diarrhoea of large volume and high frequency (8–9 episodes per day), which showed no improvement with dietary management. Other substantial findings were weight loss, nocturnal cramp-like abdominal pain, and meteorism; but no fever. No other significant medical history, food allergy or unusual ingestion was reported. On admission, the girl appeared well hydrated and in relatively good condition, her abdomen was distended and meteoristic, no mass palpable, bowel movements were rare. Initial laboratory studies showed normal haematological parameters, CRP, serum sodium and chloride, whereas potassium was 2.1 mmol/l. Investigations for coeliac disease, cow's milk allergy, as well as for intestinal infections were negative. A colon contrast enema in search of a tumour was inconspicuous. However, a CT scan revealed a presacral mass. A percutaneous biopsy of the tumour showed histological features consistent with a ganglioneuroblastoma. Investigation of the *N-myc* gene amplification was negative. The working hypothesis thereafter was that the diarrhoea might be a sign of a paraneoplastic syndrome due to vasoactive intestinal polypeptide (VIP) produced by the tumour. Further laboratory investigations confirmed this hypothesis: The level of VIP was significantly elevated (960 pmol/l, normal < 25 pmol/l), as were those of vanillylmandelic acid, urinary homovanillic acid, chromogranin-B-sequence and neuron-specific enolase antigen, as well as the neuropeptides somatostatin, peptide histidine methionine, and gastrin. MIBG scintigraphy did not reveal metastases. Because of a primarily non-resectable unilateral tumour passing the midline,

B. Wildhaber (✉) · P. Sacher
Department of Surgery, University Children's Hospital,
Zurich, Switzerland
E-mail: bwildhab@med.umich.edu
Tel.: +1-734-6153303
Fax: +1-734-9369784

F. Niggli · E. Bergsträsser
Department of Oncology, University Children's Hospital,
Zurich, Switzerland

T. Stallmach
Department of Pathology, University Hospital of Zurich,
Zurich, Switzerland

Present address: B. Wildhaber
Section of Pediatric Surgery, University of Michigan Hospitals,
Mott F3970, 0245, MI 48109 Ann Arbor, USA

a preoperative chemotherapy according to the German NB-97 study protocol, standard risk, was initiated for this stage 3 tumour. But despite chemotherapy, the intense diarrhoea persisted and hypokalaemic episodes recurred. Therefore, laparotomy and resection of the tumour was performed 7 weeks after diagnosis (after two blocks of chemotherapy). The histological examination revealed a ganglioneuroblastoma with 70% neuroblastoma cells. VIP, but not somatostatin, tested positive immunohistochemically in the differentiated parts of the tumour. No additional chemotherapy was initiated. Peri-operatively, the patient showed high blood pressures (around 135/95 mmHg) requiring medical treatment. The early post-operative management was complicated by lung oedema and a thrombosis of the external iliac vein, which were treated conservatively with furosemide and agents for anticoagulation. Following a second operation for ileus due to a post-operative intussusception of the small bowel, the girl showed regular bowel movements with normal consistency, frequency, and volume. Potassium levels remained stable within normal limits. Six days post-operatively, values of VIP were within normal range (18 pmol/l). The patient has up to now remained free of disease (2 years post-surgery).

Case 2

A previously healthy 14-year-old girl presented with severe constipation as the sole clinical symptom lasting several weeks. Work-up, including an abdominal ultrasound and CT scan, revealed a right-sided 5×4×5 cm suprarenal mass. Vanillylmandelic acid values were normal. However, MIBG scintigraphy showed an abnormal uptake of radionuclides into the left suprarenal region. The tumour was completely resected by laparotomy. Histology confirmed a para-adrenal ganglioneuroblastoma. The blastoma (5% of the total mass of the tumour) was located in the centre of the tumour and therefore was considered to have been resected completely. Simultaneous biopsies of the rectal mucosa showed a normal histology. No further treatment was initiated. No constipation was evident for several weeks, after which complaints recurred. Eight months after the first operation, locally a recurrent tumour was found on a regular follow-up CT scan. A second laparotomy with resection of the local tumour relapse was performed. Histology again confirmed a ganglioneuroblastoma. Thereafter, the constipation was initially sufficiently controlled by enemas and laxatives. Due to exacerbation of the painful constipation with gross dilatation of the colon and failure of any conservative treatment, a third laparotomy became necessary and a caecostomy for antegrade bowel wash-outs was placed 8 months after the second laparotomy. Intra-operative direct observation showed a complete lack of propulsive motility within the large bowel. A full-thickness biopsy of the colon revealed chronic inflammation of the myenteric plexus with destruction of the ganglion cells, but with an intact submucous plexus (Fig. 1). Control of constipation was achieved by regular antegrade bowel washout enemas. Two weeks later, the girl presented with ileus; however, the immediate laparotomy did not reveal any mechanical cause. Therefore, an ileostomy as well as a jejunal feeding enterostomy were placed. At that time, the full thickness biopsy of the small bowel failed to show any ganglion cells within the myenteric plexus; inflammation had subsided. These combined findings suggested an immunogenic process initiating ganglionitis with subsequent destruction of ganglion cells. Assay of anti-neuronal nuclear antibodies (ANNA) revealed elevated levels with a titre of 1:1280 (normal < 1:40). A tentative therapy with glucocorticoids was ineffective, and the high titres of ANNA persisted. 1.5 years after the first laparotomy, a second relapse of the tumour was detected on a follow-up CT scan. Chemotherapy as well as radiotherapy were unsuccessful. A fifth laparotomy with resection of multiple tumour relapses was performed. Histology confirmed vital ganglioneuroblastoma, necrosis, and calcifications in the specimen. Simultaneously, a total colectomy anticipating an ileo-rectal pull-through later on was performed. Extensive investigation of the colon specimen failed to demonstrate one single ganglion cell

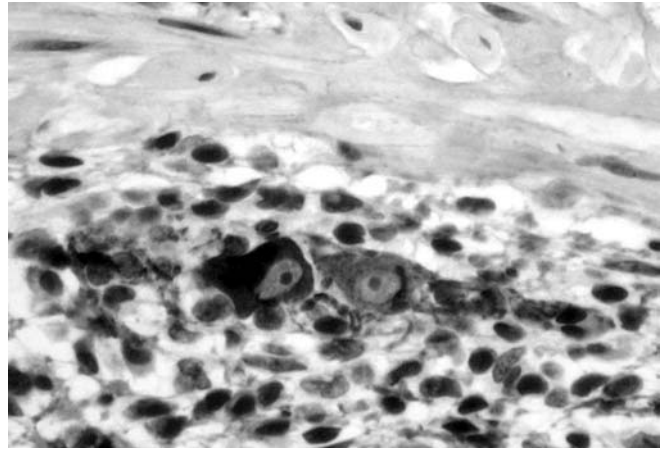


Fig. 1 Full thickness biopsy of the colon. Lymphocytes and plasma cells around altered ganglion cells within the myenteric plexus (synaptophysin x800)

within the myenteric plexus, whereas the submucous plexus appeared normal. The ileostomy was left in place. The patient died 18 months later due to tumour progression.

Discussion

Mature neuroblastomas, i.e. ganglioneuroblastomas, are known to produce substances that cause paraneoplastic syndromes [5]. A paraneoplastic syndrome may be defined as a dysfunction of organ systems caused by the remote humoral effects of a tumour and not by local effects or metastases.

Secretory diarrhoea and severe hypokalaemia are part of the watery diarrhoea, hypokalaemia and achlorhydria (WDHA) syndrome which was first described by Verner and Morrison in 1958 [18] in association with islet cell tumours of the pancreas in an adult. At that time, the aetiological agent was not known. Today, there is evidence that these symptoms are related to VIP production in tumour cells. Histologically, VIP-producing tumours can be divided into two groups: pancreatic endocrine tumours and neurogenic tumours, including ganglioneuroblastomas, ganglioneuromas, and pheochromocytomas. These tumours most frequently occur in the adrenal glands or retroperitoneum. VIP is the most useful laboratory finding enabling the detection of hormone-producing ganglioneuroblastomas. In addition, 50% of patients may show elevated levels of urinary catecholamines [12] and elevation of various neuropeptides [5]. VIP was first isolated in 1970 by Said and Mutt [13] from porcine gut, and they demonstrated that VIP stimulates intestinal secretions. It is known that VIP has effects on the cardiovascular, respiratory, and gastrointestinal systems. It resembles secretin in that it stimulates secretion of alkaline pancreatic juice. Similar to glucagon, it stimulates lipolysis and glycogenolysis. Furthermore, it relaxes smooth muscle leading to decreased intestinal movements, as clinically observed in our patient. VIP inhibits histamine

and pentagastrin-stimulated acid secretion in the stomach and is, in addition, a potent stimulator of the adenylate cyclase production by the intestinal mucosal cells, resulting in net secretion of water and electrolytes. Somatostatin may be used for medical treatment of the WDHA syndrome. Somatostatin inhibits gastrointestinal secretion and in some cases may prove helpful [3]. Other treatments include steroids, cholestyramine or loperamide. Recommended medical treatment of VIP-producing ganglioneuroblastomas requires surgical removal of the tumour. VIP levels are preferably used post-operatively to monitor tumour recurrence.

Severe constipation in an adolescent girl is not uncommon, and the differential diagnosis is extensive. Aetiologies can range from dietary and psychosocial disturbances, to metabolic diseases, gastrointestinal abnormalities, intrapelvic tumours and neuropathic rectum. Intestinal pseudo-obstruction as a paraneoplastic syndrome is rare and has mainly been reported in patients with small cell lung cancers [8, 9, 10], but only seldom in association with other malignant tumours [6, 7, 8], and not yet in connection with a ganglioneuroblastoma or neuroblastoma. Cancer patients with paraneoplastic disease show significantly higher titres of ANNA compared to those without the syndrome. In our second case, the intestinal pseudo-obstruction was due to a destruction of ganglion cells of the myenteric plexus caused by high levels of ANNA. The immunoglobulin G ANNA, or anti-Hu, is thought to be part of an immune response originally directed against tumour antigens. In our patient, there was strong evidence that the immunological process leading to auto-antibodies was initiated within the ganglioneuroblastoma. ANNA react with antigens shared by tumour cells and neurons, including the myenteric plexus [2]. Intestinal pseudo-obstruction due to acquired aganglionosis by auto-antibodies has been described in young adults without neoplasia or other neuronal involvement [16]. The typical paraneoplastic syndrome associated with elevated levels of ANNA is a sensoric neuropathy with paresthesia and stiffness, which was also observed in our patient, although it was not one of the leading symptoms. Intestinal pseudo-obstruction is a much less common presentation of the syndrome. It may be found isolated, or as a part of other autonomic dysfunctions [1]. Interestingly, ganglionitis with subsequent destruction of ganglion cells does not affect cells of the submucous plexus. Therefore, mucosal biopsies are not sufficient in detecting auto-immune ganglionitis. In our patient it remains unknown whether the destruction of the ganglion cells in the myenteric plexus was already present when rectal mucosal biopsies were performed during the initial operation (the histopathological findings have recently been discussed in detail by Schobinger-Clément et al. [14]). In cases of ganglioneuroblastoma with intestinal pseudo-obstruction, serum testing for auto-antibodies will reveal the cause of the paraneoplastic disease. Presently, the main therapeutic option for this auto-immune destruction of ganglion cells is surgical removal of the tumour. Steroids

and immunoglobulins have been used in cases with elevated ANNA levels and various neurological symptoms, but with inconsistent benefit [4]. ANNA levels can be used for monitoring and detection of tumour recurrence.

References

1. Altermatt HJ, Gerber HA, Scheithauer BW (1993) Neurologic paraneoplastic syndromes. Anti-Purkinje cell antibodies and anti-neuronal nuclear antibodies as serologic markers. *Dtsch med Wschr* 118: 1735–1741
2. Briellmann RS, Sturzenegger M, Gerber HA, Schaffner T, Hess CW (1996) Autoantibody-associated sensory neuropathy and intestinal pseudo-obstruction without detectable neoplasia. *Eur Neurol* 36: 369–373
3. Debas HT, Gittes G (1993) Somatostatin analog therapy in functioning neuroendocrine gut tumors. *Digestion* 54: 68–71
4. Dropcho EJ (1995) Autoimmune central nervous system paraneoplastic disorders: mechanisms, diagnosis, and therapeutic options. *Ann Neurol* 37: 203–213
5. Kimura N, Yamamoto H, Okamoto H, Wakasa H, Nagura H (1993) Multiple-hormone gene expression in ganglioneuroblastoma with watery diarrhea, hypokalemia, and achlorhydria syndrome. *Cancer* 71: 2841–2846
6. Kulling D, Reed CE, Verne GN, Cotton PB, Tarnasky PR (1997) Intestinal pseudo-obstruction as a paraneoplastic manifestation of malignant thymoma. *Am J Gastroenterol* 92: 1564–1566
7. Lautenbach E, Lichtenstein GR (1995) Retroperitoneal leiomyosarcoma and gastroparesis. A new association and review of tumor-associated intestinal pseudo-obstruction. *Am J Gastroenterol* 90: 1338–1341
8. Lee H, Lennon VA, Camilleri M, Prather, CM (2001) Paraneoplastic gastrointestinal motor dysfunction: clinical and laboratory characteristics. *Am J Gastroenterol* 96: 373–379
9. Lennon VA, Sas DF, Busk MF, Scheithauer B, Malagelada JR, Camilleri M, Miller LJ (1991) Enteric neuronal autoantibodies in pseudoobstruction with small-cell lung carcinoma. *Gastroenterol* 100: 137–142
10. Liang BC, Albers JW, Sima AF, Nostrand T (1994) Paraneoplastic pseudo-obstruction, mononeuropathy multiplex, and sensory neuropathy. *Muscle Nerve* 17: 91–96
11. Plantaz D, Michon J, Valteau-Couanet D, Coze C, Chastagner P, Bergeron C, Nelken B, Martelli H, Peyroulet MC, Carpentier AF, Armari-Alla C, Pagnier A, Rubie H (2000) Opsoclonus-myoclonus syndrome associated with non-metastatic neuroblastoma. Long-term survival. Study of the French society of Pediatric Oncologists. *Arch Pediatr* 7: 621–628
12. Quak SH, Prabhakaran K, Kwok R, O'Reilly AP (1988) Vasoactive intestinal peptide secreting tumours in children: a case report with literature review. *Aust Paediatr J* 24: 55–58
13. Said SI, Mutt V (1970) Polypeptide with broad biologic activity. Isolation from small intestine. *Science* 169: 1217–1218
14. Schobinger-Clément S, Gerber HA, Stallmach T (1999) Auto-aggressive inflammation of the myenteric plexus resulting in intestinal pseudoobstruction. *Am J Surg Pathol* 23: 602–606
15. Schuler D, Koos R, Peter A (1977) Paraneoplastic syndrome in children. *Acta Paediatr Acad Sci Hung* 18: 31–40
16. Smith VV, Gregson N, Foggensteiner L, Neale G, Milla PJ (1997) Acquired intestinal aganglionosis and circulating autoantibodies without neoplasia or other involvement. *Gastroenterology* 112: 1366–1371
17. Tora M, Graus F, de Bolos C, Real FX (1997) Cell surface expression of paraneoplastic encephalomyelitis/sensory neuropathy-associated Hu antigens in small-cell lung cancers and neuroblastomas. *Neurology* 48: 735–741
18. Verner JV, Morrison AB (1958) Islet cell tumor and a syndrome of refractory watery diarrhea and hypokalemia. *Am J Med* 25: 374–380