

PARASITIC EYE INFECTION BY ASCARIS LUMBRICOIDES — CASE REPORT

Janićijević-Petrović A. Mirjana,¹ Šarenac-Vulović Tatjana,¹ Vulović Dejan,²
Janićević Katarina,² Popović Andrijana²

¹Department of Ophthalmology, Clinical Centre of Kragujevac in Kragujevac, Serbia

²Faculty of Medical Sciences, University of Kragujevac, Serbia

Primljen/Received 15. 01. 2014. god.

Prihvaćen/Accepted 28. 03. 2014. god.

Abstract: The parasitic infection is an affection of the body as well as the eye with parasites, protozoa's, worms and ectoparasites, with world incidence of 30%. These diseases are chronic, systemic diseases because of weak innate immunity and ability of parasites to evade immune answer of the host or increasing the resistance to the adaptive immunity of the host. Parasites can evade immunity of the host by: antigens variations, forming cysts, changing the hosts and by synthesis of some cytokines, which decrease immunity of the host. *Ascaris lumbricoides* is the largest intestinal nematode parasitizing man. The worm is known to cause subconjunctival mass, granulomatous iridocyclitis, choroiditis, recurrent vitreous hemorrhage, chronic dacryocystitis and invasion into the subretinal space. **The goal of this case** was to analyze the affection of the eye, caused by the *Ascaris lumbricoides* as very rare ocular pathology.

Keywords: *Ascaris lumbricoides*, eye infections, diagnosis, therapy.

INTRODUCTION

The worm is known to cause subconjunctival mass, granulomatous iridocyclitis, choroiditis, recurrent vitreous hemorrhage, chronic dacryocystitis and invasion into the subretinal space. Parasites are undergoing a complex process of biological development, which takes place in humans. Humans are infected by-sharing living environments with carriers. Diseases have chronic course due to poor innate immunity and ability of the parasite to evade or resist elimination by the acquired immune mechanisms. Acquired antibody-dependent immunity mediated by eosinophils plays major role in defense against the helminthes. Interleukins stimulates proliferation of eosinophils, increases the secretion of mucus

and epithelial cells via inhibition of macrophages. Growth and multiplication of tissue forms granuloma with subsequent fibrosis in own response to the presence of a foreign body. The formations of parasitic deposits of immune complexes around the blood vessels are clinically presents as vasculitis. Parasites avoid human immune mechanisms by: antigenic variation, forming a layer, forming cysts, changing the host and with synthesis of immunosuppressive cytokines (1).

The first subset of the alimentary tract of nematodes is the group of Ascaridae — *Ascaris lumbricoides*, causing Ascariasis. Morphology: a parasite, whitish color, cylindrical shape, with a transverse line on cuticular surface (Figure 1).



Figure 1. The morphology of *Ascaris lumbricoides*

Parasites live in soil, small intestine, and infection occurs by entering the egg through food, water and soil (by “dirty hands”). Females are up to 46 cm long and wide 3–4 mm. Males are wide up to 2–3 mm and 30 cm long (Figure 2).

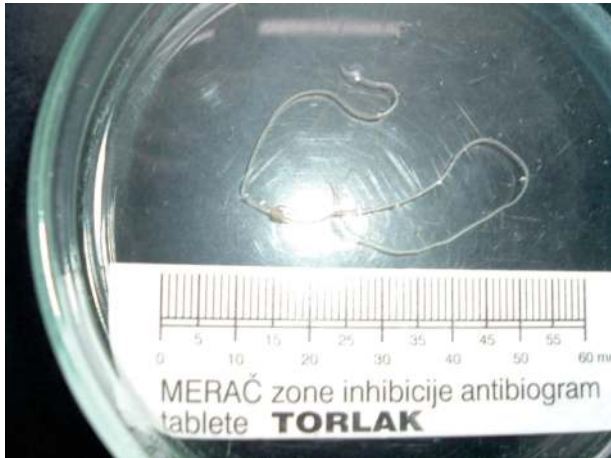

Figure 2. Dimensions of *Ascaris lumbricoides*

Eggs enter by contaminated food and water into the small intestine, and get through mucosa into bloodstream. Worm infections are followed by aberrant migrations of larva in different intraocular and periorbital tissues. Ocular manifestations are: swelling and redness of the eyelids, subconjunctival nodes, conjunctivitis, larva in tear ducts, uveitis, secondary glaucoma, lens luxation, vitreous hemorrhage, inflammation of the choroid and retina, optic nerve head swelling and pseudo tumor of the orbit. Clinical manifestations may be asymptomatic, depending on the stage of the infection, and the immunity of the host and can be manifested through the migratory phase, respiratory and digestive disorders, allergic reactions, eosinophilia, asthma and urticaria (2, 3).

Diagnoses are made by identifying the presence of fertile or infertile eggs in feces, Charcot-Leyden's crystals in the sputum, presence of adult parasites in feces, anus or mouth.

Management of ascariasis includes Albendazole tablets 400 mg once or Mebendazole tablets 500 mg once, or 100 mg twice a day for three days, surgical treatment, disease prevention and health education in endemic and other areas. Anti-parasitic agents are not optimal for the treatment, therefore social and global observation is necessary. Anti-parasitic drugs are involved in therapy after consultation with microbiologists. Due to the absence of signs of systemic disease, surgical removal of the parasite may be the main form of treatment of ectopic infection.

CASE REPORT

The 54-year-old woman presented to the Eye Clinic (Clinical Center of Kragujevac, Serbia) with a three days history of pain in the left eye, the left half of the head, swelling, redness of the eyelids, blepharospasm, photophobia and epiphora. She had an eye exam before she came to the Clinic. Ophthalmologist indica-

ted possible preseptal cellulites and prescribed local and systemic antibiotic and corticosteroid therapy.

After the first treatment, the symptoms were not fully withdrawn.

She denied any injury, surgery, allergy, family history of ocular disease and there was no history of recent trips.

Ophthalmological examination revealed a visual acuity of 6/6 in both eyes without correction. Intraocular pressure was 18 mm Hg. Anterior segment examination revealed mobile pseudo tumor (sub-tennial), whitish color with conjunctival hyperemia and hemorrhage of the left eye. Posterior segment findings were within normal.

Hematologic and biochemical results were within the reference values. The patient was surgically treated. By exploration of conjunctiva the parasite was extracted and placed in 10% formalin. Conjunctiva was closed with 8-0 suture and with no damage to surrounding tissue (Figure 3).

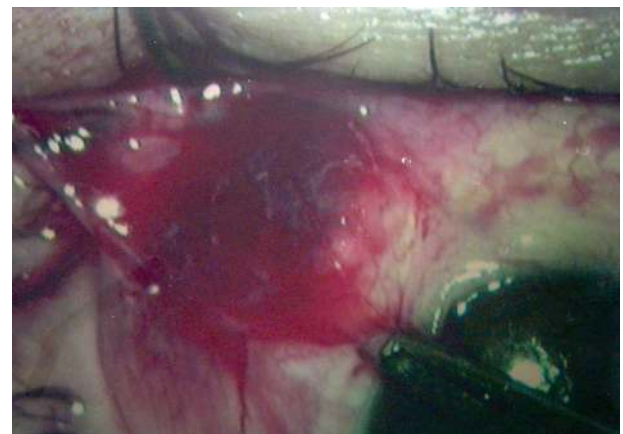


Figure 3. Surgical treatment — sub-tennial access and extraction of parasites

The parasite which was extracted has been sent for parasite identification at the Institute of Microbiology in Kragujevac. Stool examination was performed successively several times, forms of male adult parasites were detected identical to those recovered from the eye, and parasite eggs were not detected.

X-ray lung examination was without pathological changes. Ultrasound examination of abdomen showed orderly clinical findings. Computerized tomography of endocranium showed normal findings, laboratory results were within the reference values, except for increase in monocytes concentration (10 μ g/mL) and immunoglobulin E (0.05% of the Ig-concentration).

Treatment involved the surgical treatment with local antibiotics and corticosteroids, and after consultations with microbiologists the systemic use of Mebendazole tablets (100-mg in the morning of the two weeks). After the treatment, examination of feces showed no

adult parasites. The patient was controlled by ophthalmologists for the next six months.

DISCUSSION

Ascariasis is common in people of Southeast Asia. In Europe, ascariasis is rare, and eye infection caused by *Ascaris lumbricoides* is a true rarity in our country (3, 4).

Given the size of the parasites, associated clinical features and examination of feces, where were found identical parasites, it has been determined that in a female patient were found parasites of the genus *Ascaris* (intersections of parasites and the absence of eggs in the feces, speaks in favor of a male individual parasites) (5).

Given the rarity of *Ascaris lumbricoides* in the eye, our case report should indicate the ocular manifestation of ascariasis as well as on the long path of its detection. Identification of the parasite involves optimal parasitological examination of feces. On the basis of the morphology of the worms, found in the stool, microbiologists have diagnosed ascariasis. We believe that the infection occurred through the “dirty hands” way, which is mechanically transmitted to the digestive

tract, and from hematogenous to the respiratory tract and the eyes. Their growth is suppressed by surrounding structures and by causing inflammatory reaction with appropriate clinical symptoms. Clinical symptoms of *Ascaris lumbricoides* are similar to the symptoms of the disease of orbit; therefore it was hard in the beginning to set a diagnosis. Considering the diagnosis was set only after localizing worms in the tissue of the bulbar conjunctiva, we believe that the diagnosis could be set before, using other functional and diagnostic methods, ultrasound, computerized tomography of an orbit and others. Diagnostic errors in identification of the parasite (by microbiologists) are currently possible but antiparasitic therapy was adequate (6).

CONCLUSION

Authors have presented a case report of patient with parasitic infection of the eye.

In conclusion, it is necessary for ophthalmologists in their everyday practice to be able to make appropriate diagnose of the parasitic infection and to apply optimal therapeutic answer to a very rare infection of eye with *Ascaris lumbricoides*.

Sažetak

PARAZITARNA INFEKCIJA OKA IZAZVANA PARAZITOM ASCARIS LUMBRICOIDES — PRIKAZ SLUČAJA

Janićijević-Petrović A. Mirjana,¹ Šarenac-Vulović Tatjana,¹ Vulović Dejan,²
Janićević Katarina,² Popović Andrijana²

¹ Department of Ophthalmology, Clinical Centre of Kragujevac in Kragujevac, Serbia

² Faculty of Medical Sciences, University of Kragujevac, Serbia

Parazitarna infekcija je afekcija organizma i oka životinjskim parazitima, protozoama, helmintima, ektoparazitima sa 30% svetske incidence. Oboljenja su hroničnog toka, zbog slabog urođenog imuniteta i mogućnosti parazita da izbegnu, ili pruže otpor eliminaciji putem stečenih imunskih mehanizama. Paraziti izbegavaju imunske mehanizme čoveka: antigenskim varijacijama, formiranjem omotača, formiranjem cisti, menjanjem domaćina i sintezom imunosupresivnih citokina. *Ascaris lumbrico-*

ides je najveća crevna nematoda kod čoveka. Poznato je da crv može izazvati pojavu subkonjunktivalne tumorske mase, granulomatozni iridociklitis, horoiditis, rekurentna krvarenja u staklastom telu, hronični dakriocistitis i invaziju subretinanog prostora. **Cilj ovog rada** je da prikaže slučaj infekcije oka izazvane parazitom *Ascaris lumbricoides* što je veoma retka okularna patologija.

Ključne reči: *Ascaris lumbricoides*, infekcija oka, dijagnoza, terapija.

REFERENCES

1. Abbas KA, Lichtman HA. Cellular and molecular immunology. 5th ed. Philadelphia: Saunders Elsevier; 2005.
2. Faísca P, Morales-Hojas R, Alves M, et al. A case of canine ocular onchocercosis in Portugal. *Vet Ophthalmol.* 2010; 13(2): 117–21.
3. Seder RA, Gazzinelli RT. Cytokines are critical in linking the innate and adaptive immune response to bacterial, fungal and parasitic infection. *Adv Intern Med.* 1999; 44: 353–88.
4. Mattis A, Mowatt L, Lue A, Lindo J, Vaughan H. Ocular angiostrongyliasis — First case report from Jamaica. *West Indian Med. J* 2009; 58(4): 383–5.
5. Rathinam SR, Ashok KA. Ocular manifestation of systemic disease: ocular parasitosis. *Curr Opin Ophthalmol.* 2010; 21(6): 478–84.
6. Wesolowska M, Kisza K, Szalinski M et al. First case of heterochthonous subconjunctival dirofilariasis described in Poland. *Am J Trop Med Hyg.* 2010; 83(2): 210.

Correspondence to/Autor za korespondenciju

Mirjana A. Janićijević-Petrović,
Kneza Miloša 3/1-1
34000 Kragujevac, Serbia
E-mail: mira.andreja@yahoo.com
Tel.: +38134369828
Mob: +38166013691
Fax: +38134370073