

PATHOGENESIS OF *Trypanosoma evansi* INFECTION IN DOGS AND HORSES: HEMATOLOGICAL AND CLINICAL ASPECTS

PATOGÊNESE DA INFECÇÃO PELO *Trypanosoma evansi* EM CÃES E CAVALOS: ASPECTOS HEMATOLÓGICOS E CLÍNICOS

Roberto Aguilar Machado Santos Silva¹ Heitor Miraglia Herrera²
Luzimari Borges da Silveira Domingos³
Flora Auxiliadora Ximenes³ Alberto Martin Rivera Dávila⁴

SUMMARY

Trypanosoma evansi caused severe anemia in horses and pronounced leukopenia in dogs, both naturally infected. The horses presented microcytic normochromic anemia and the dogs showed microcytic hypochromic anemia. The clinical signs observed were fever, anemia, edema of the legs and lower parts, weakness and inappetence. Light microscopic studies demonstrated that *Trypanosoma evansi* produced several alterations in erythrocytes of dogs and horses. These pathologic changes included vacuolation, acanthocytes, dacrocytes, codocytes, microspherocytes and bizarre shapes. Mature erythrocyte were observed adhered to trypanosomes. Erythrophagocytosis was also demonstrated.

Key words: trypanosomosis, *Trypanosoma evansi*, pathogenesis, erythrocyte pathologic changes, dog, horse.

RESUMO

Trypanosoma evansi produziu severa anemia em cavalos e pronunciada leucopenia em cães, ambos naturalmente infectados. Os cavalos apresentaram anemia microcítica normocrômica e os cães desenvolveram uma anemia microcítica hipocrômica. Os sinais clínicos foram febre, anemia, edema das pernas e porções inferiores, fraqueza e inapetência. Estudos com microscopia ótica demonstraram que o *Trypanosoma evansi* produziu várias alterações nos eritrócitos dos cães e cavalos. Estas alterações patológicas incluíram vacuolação, acantócitos, dacrócitos, codócitos, microesferócitos e formas bizarras. Eritrócitos maduros foram observados aderidos a tripanosomas. Eritrofagocitose foi também observada.

Palavras-chave: tripanosomose, *Trypanosoma evansi*, patogênese, alterações dos eritrócitos, cão, cavalo.

¹Veterinarian, Pathologist, MS, Laboratory of Animal Health, Section Pathology, EMBRAPA/Centro de Pesquisa Agropecuária do Pantanal (CPAP), Rua 21 de setembro, 1880, 79320-900, Corumbá, MS, Brazil. Author for correspondence.

²Veterinarian, BS, Research Fellow, Laboratory of Animal Health, Section Pathology, EMBRAPA/CPAP.

³Biology Student, Fellowship Rhae/CNPq, Universidade Federal de Mato Grosso do Sul, Centro Universitário de Corumbá, Corumbá, MS, Brazil.

⁴Biology Student, Universidade Federal de Mato-Grosso do Sul, Centro Universitário de Corumbá.

INTRODUCTION

Trypanosomosis caused by *Trypanosoma evansi* receives several common names in different places of the world. In the Pantanal Matogrossense and other localities of South America the most widely used are "Mal de Caderas" or "Peste de Caderas". The clinical signs of "Mal de Caderas" is known by ranchers since past century.

The pathogenesis of diseases caused by *T. evansi* and other trypanosomes of the subgenus *trypanozoon* is characterized by rapid loss of weight and a variety degrees of anemia. Some of the lesions observed in the acute syndrome, e.g., the urticarial plaques and ophthalmitis are transitory and may be recurrent. In the chronic stages, the animals become weak, the mucous membranes are pale, sometimes icteric, and the superficial lymph nodes are enlarged. Additional symptoms which may be observed are keratitis and occasionally hemorrhages into anterior chamber of the eye (LOSOS, 1980). LEVINE (1973) reported that the signs of trypanosomosis due to *T. evansi* include intermittent fever, urticaria, anemia, edema of the legs and lower parts of the body, loss of hair, progressive weakness, loss of condition, and inappetence. Conjunctivitis may occur, and abortion is common in camels. MAHMOUD & GRAY (1980) described that the disease is often rapidly fatal for camels, dogs and horses.

Anemia, a common feature of trypanosome infections, is a complex process and remains unclear (ANOSA & KANEKO, 1983a,b). KATUNGUKA - RWAKISHAYA et al. (1992) reported that ovines infected with *Trypanosoma congolense* developed macrocytic normochromic anemia and leukocytosis which was mainly a lymphocytosis. According to LOSOS (1986), there is a considerable similarity between lesions and pathogenesis of diseases caused by *T. brucei*, *T. evansi* and *T. equiperdum* affecting animals, and *T. rhodesiense* and *T. gambiense* causing diseases to man. Varying degrees of anemia occur in all syndromes and are accompanied by either leukopenia or leukocytosis and thrombocytopenia. Hematological alterations are one of the most consistent findings in trypanosomosis. JENKINS & FACER (1985) reported that severe anemia in zebu cattle infected with *T. congolense* is the primary cause of death. Anemia and several other erythrocyte pathological changes were observed by ANOSA & KANEKO (1983b) in deer mice (*Peromyscus maniculatus*) infected with *T. brucei*.

The nature of the anemia is not completely elucidated and several mechanisms have been proposed (ANOSA & KANEKO, 1983a,b). JENKINS & FACER (1985) proposed several causes of anemia in acute and chronic African trypanosomosis such as: increased red cell destruction, extravascular and intravascular hemolysis by immune system (trypanosome antigen/antibody complex and

antierythrocyte antibodies), hemolysins, nonspecific reticulo endothelial system activation, direct traumatic effect of trypanosomes, microangiopathy associated with disseminated intravascular coagulation, splenic phagocytosis and splenic pooling, increased plasma volume, noncompensatory and/or decreased erythropoiesis and anemia of chronic disorders. According to JAIN (1986), the anemia is hemolytic in nature and results primarily from erythrophagocytosis in the spleen, liver, lungs, lymph nodes, bone marrow and even the circulation. Anemia in deer mice (*Peromyscus maniculatus*) experimentally infected with *Trypanosoma brucei* has been associated with erythrophagocytosis (ANOSA & KANEKO, 1983b). Mature erythrocytes and reticulocytes were observed to adhere to trypanosomes (ANOSA & KANEKO, 1983b; JENKINS & FACER, 1985). In these cases erythrophagocytosis was presumed to arise due to the damage caused by the adhesion phenomenon. ANOSA & KANEKO (1983b) demonstrated that *T. brucei* infection in deer mice produced several alterations in erythrocyte structure including microspherocytes, schistocytosis, vacuolation, doughnut-cell formation and keratocytosis. In the present study, light microscopy has been used to investigate aspects of erythrocyte pathologic changes in dogs and horses naturally infected by *T. evansi*.

MATERIAL AND METHODS

In February 1994, two outbreaks of equine trypanosomosis occurred in ranches located in the Pantanal region with forty-eight (51%) and ten (20%) horses deaths and abortion in a mare. In the same month, four dogs from two ranches, distant 150km from each other, presented trypanosomosis due to *T. evansi*. The fresh blood samples were submitted to EMBRAPA - Centro de Pesquisa Agropecuária do Pantanal, Section of Pathology. The diagnosis for trypanosomosis was done using hematocrit centrifuge technique, Giemsa-stained smears and mouse inoculation. The isolates were identified based on morphological and biometrical data. After this initial diagnosis, a study began on hematological changes in 10 horses and 4 sick dogs naturally infected. The horses and dogs were bled for determination of hematological data using a vacuum system (Vacuum II, Labnew, Campinas, Brazil) in tubes containing ethylene diaminetetraacetic acid as anticoagulant. The packed red cell volume (PCV) was measured using the standard microhematocrit method, and the red cell count (RBC) and total white cell count (WBC) were obtained using Neubauer chamber. The hemoglobin (Hb) concentration was determined colorimetrically (Micronal digital spectrophotometer, B 34212, São Paulo, SP, Brazil) after its conversion to cyanomethemoglobin. Thin blood films stained with May Grūwald-Giemsa were

examined by light microscopic (x 1,000) for morphologic abnormalities of erythrocytes.

RESULTS

Clinical findings

The signs observed in horses were fever (39° to 41°C), severe anemia, conjunctivitis, edema of the legs and lower parts of the body, progressive weakness, a gradual onset of paresis of hindquarters, resulting in staggering gait, loss of condition, inappetence and abortion (Figure 1). Urticaria and loss of hair were not observed, although these clinical signs have been reported by ranchers in other outbreaks.

The dogs presented fever (38° to 40°C), moderate to severe anemia, conjunctivitis, edema of the legs and lower parts of the body, progressive weakness, a gradual onset of paresis of hindquarters and inappetence .

Hematological findings

The main hematologic change produced in horses and dogs by *T. evansi* infections was a severe anemia. The horses presented microcytic normochromic anemia and dogs showed microcytic hypochromic anemia. The leukocyte alterations in the horses were mild leukopenia with relative lymphocytosis and monocytosis and decrease in the neutrophil count. The horses were not treated and died. The dogs survived after suramin treatment. Stained thin blood smears of 10 horses and 4 infected dogs were examined. Several erythrocyte abnormalities were observed in the blood of infected dogs and horses. These included the appearance of microspherocytes (Figure 2c), acanthocytes (Figure 2b), dacrocytes (Figure 2g), microcyte (Figure 2e, j), vacuolated (Figure 2f), sometimes bizarre shapes(Figure 2a, l). Polychromasia and poikilocytosis were present in both dogs and horses erythrocytes(Figure 2h, k). Adhesion of erythrocytes to trypanosomes in circulating blood was also observed. Erythrophagocytosis has been demonstrated in various trypanosome infections with light microscopy. Our studies confirmed that it occurs in bloodstream of infected animals (Figure 2d, i).

DISCUSSION

The clinical signs observed in sick dogs and horses are similar to those ones reported for diseases caused by trypanosomes of the subgenus *Trypanozoon* (LOSOS, 1986) and *Nannomonas* (KATUNGUKA-RWAKISHAYA

et al., 1992). Although the trypanosomosis can be confused with other common diseases in the Pantanal Mato-Grossense, such as helminthosis and equine infectious anemia in horses and helminthosis and leishmaniosis in dogs, these diseases have a chronic course. The trypanosomosis by *T. evansi* in dogs and horses is often rapidly fatal when not treated.

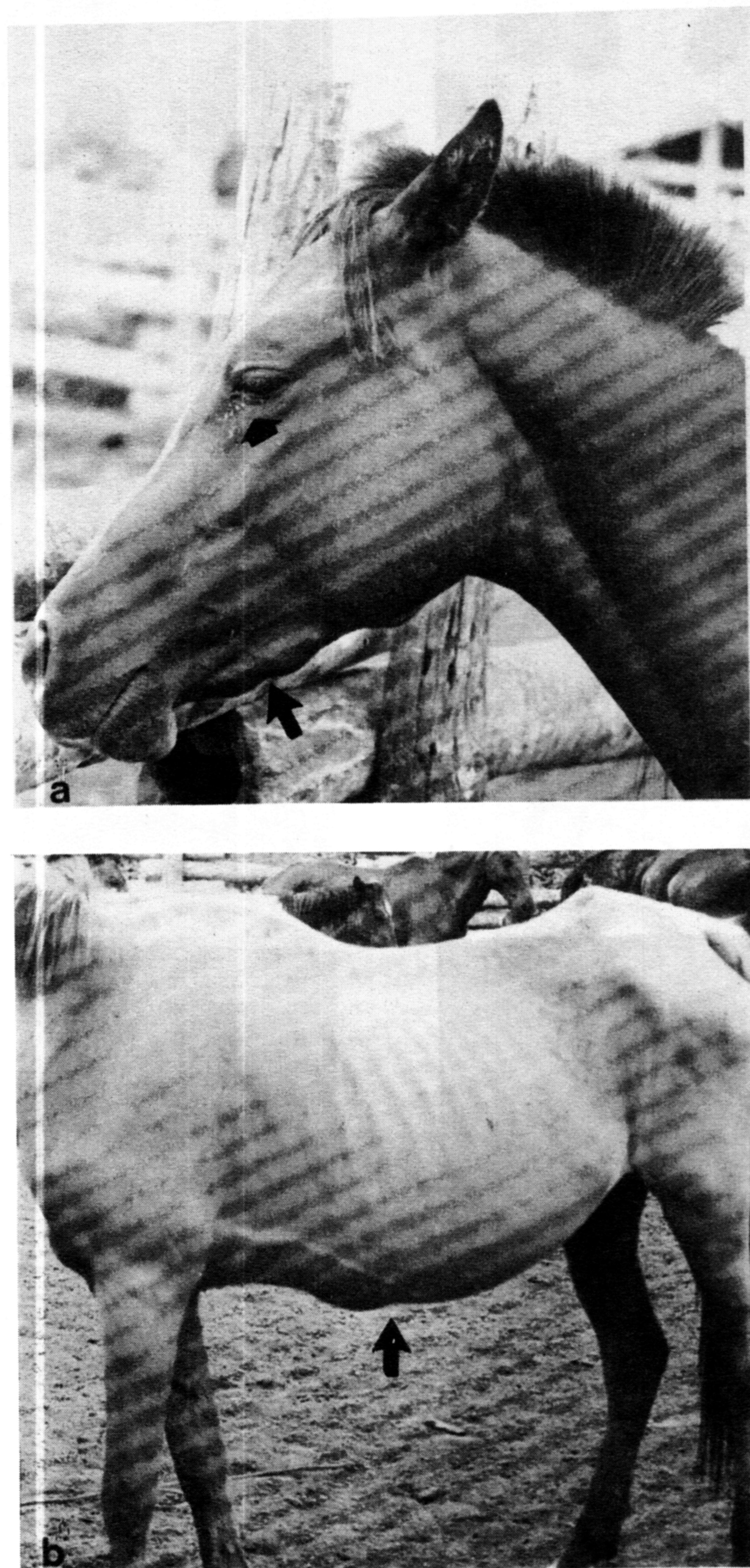


Figure 1. Clinical signs of *Trypanosoma evansi* in horses. a) Conjunctivitis and submandibular edema. b) Horses with edema of lower parts of the body.

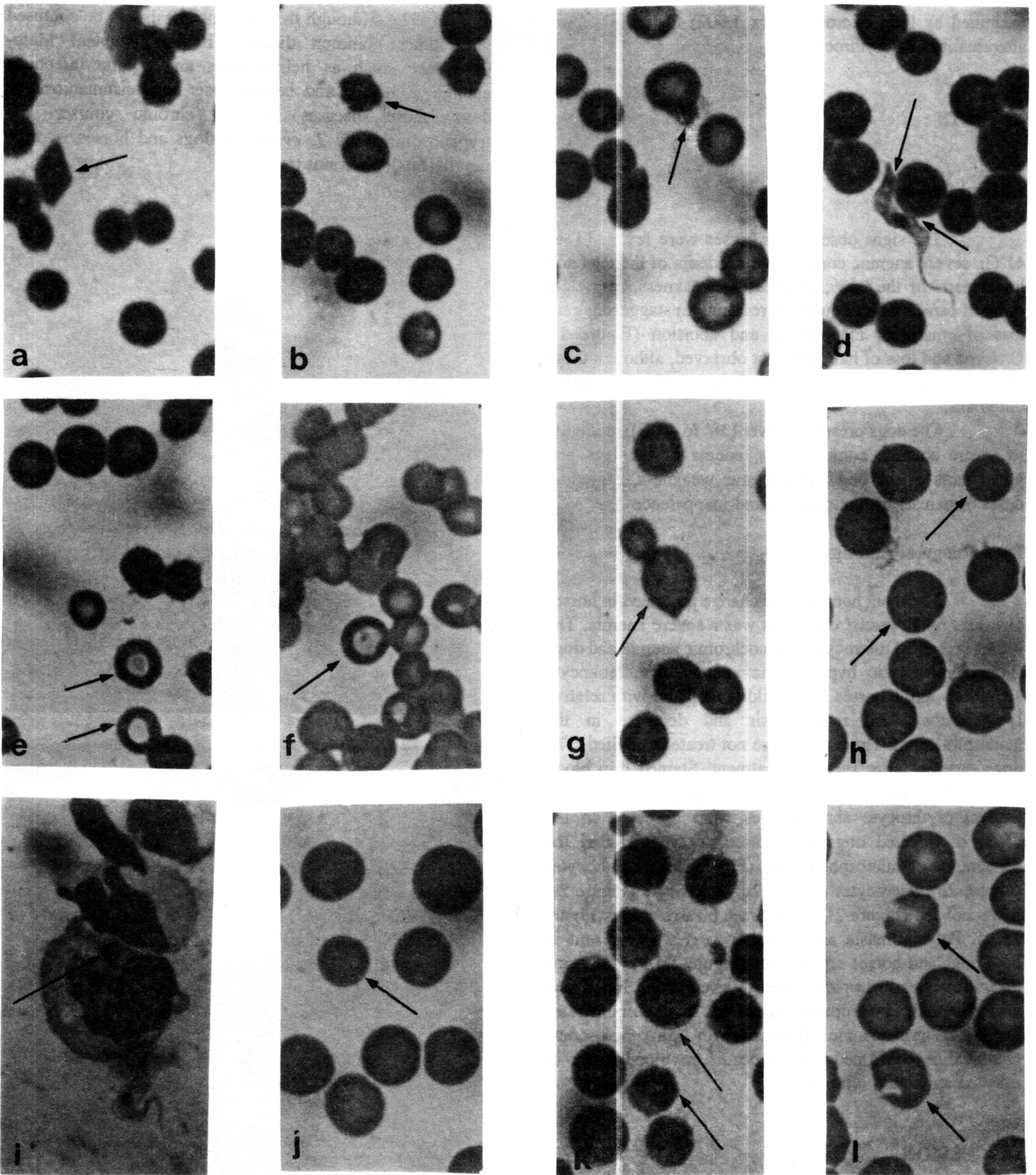


Figure 2. Erythrocyte pathologic changes in blood of horses and dogs with trypanosomosis due to *Trypanosoma evansi*. a) Horse erythrocyte with bizarre shape (arrow). b) Acanthocyte (arrow) in blood of infected horse. c) Microspherocyte (arrow) in blood of infected horse. d) Trypanosome adhered (arrow) to erythrocyte of infected horse. e) Microcyte exhibiting an achromic center (arrows) in blood of infected horse. f) Vacuolated erythrocyte (arrow) in blood of infected horse. g) Dacrocyte (arrow) in blood of infected horse. h) Anisocytosis (arrows) in blood of infected horse. i) Erythrophagocytosis (arrow) in blood of infected horse. j) Microcytes (arrows) in blood of infected dog. k) Anisocytosis (arrows) and poikilocytosis in blood of infected dog. l) Dog erythrocyte with bizarre shape (arrow).

Anemia is one of the most consistent findings in trypanosomosis. The nature of the anemia is not completely elucidated (ANOSA & KANEKO, 1983a). The significance of anemia on the overall morbidity of African trypanosomosis, both in man and in livestock, is often difficult to assess since many other causes of severe anemia (nutritional and parasitic) are concurrently present in endemic areas. However, a hematologic study on Nigerian cattle indicated that trypanosomosis produced the most severe anemia of all blood protozoan and gastrointestinal helminth infections encountered among the animals (JENKINS & FACER, 1985). According to these authors, the severe anemia observed in horses during our study can be considered an important cause of the high mortality. The anemia in dogs was also an important hematological finding. According to JAIN (1986), anemia, in two phases, is the most prominent finding in natural trypanosome infections. The severity of the first phase is proportional to the degree of parasitemia. The anemia is hemolytic in nature and results primarily from erythrophagocytosis. The second phase of anemia begins between 4 and 6 months after infection.

Parasitemia progressively disappears or becomes difficult to discern. Necropsy findings suggest impaired erythropoiesis and continuous red cell destruction through erythrophagocytosis. The high parasitemia and a severe anemia in horses agrees with JAIN's (1986) observation. The leukocyte changes in horses were characterized by relative lymphocytosis and monocytosis and decrease in the neutrophil counts (Table 1).

Table 1. Blood values of dogs (n = 4) and horses (n = 10) infected naturally by *T. evansi*.

	Horses	Dogs
Erythrocytic Series		
Erythrocytics (x 10 ⁶ /μl)	3,65	4,39
Hemoglobin (g/dl)	5,53	6,20
PCV* (%)	18,00	24,00
MCV** (μ ³)	49,31	54,66
MCH*** (μg)	15,15	14,30
MCHC**** (%)	30,72	25,25
Leukocytes (x 10³)		
Neutrophil	6,92	1,60
Lymphocyte	6,60	66,00
Monocyte	60,20	24,00
Eosinophil	29,00	6,00
Basophil	4,20	4,00
	0,00	0,00

* PCV = Packed Cell Volume;

** MCV = Mean Cell Volume;

*** MCH = Mean Cell Hemoglobin;

**** MCHC = Mean Cell Hemoglobin Concentration.

Leukopenia has been reported in trypanosomosis and is attributed to reduced myelopoiesis (JAIN, 1986). JENKINS & FACER (1985) reported an initial leukopenia over the first 3 weeks of *T. vivax* infection in cattle with values subsequently rising above the preinfection levels. Leukopenia as well as monocytosis and eosinopenia have been reported in *T. brucei* infection of mice and *T. vivax* of sheep (ANOSA & KANEKO, 1983a). In our study, the clinical signs were very close to those observed by other authors. The principal hematologic changes were a severe anemia in horses and a pronounced leukopenia in dogs. The causes of anemia in acute trypanosomosis are not completely elucidated and several mechanisms have been proposed. Leukopenia in dogs, as demonstrated in other animal species infected by trypanosomes, can be related to a critical "crisis" phase followed by a leukocytosis in the animals that survived (JENKINS & FACER, 1985). In this study was observed that *T. evansi* infection in dogs and horses was characterized by development of several erythrocyte abnormalities including vacuolation, acanthocytes, dacrocytes, codocytes microspherocytes, and bizarre shapes which resulted in anisocytosis and poikilocytosis. Polychromasia was present, too. ANOSA & KANEKO (1983b) reported that mechanical injury produced some of erythrocyte abnormalities observed in deer mice infected with *T. brucei*. The adhesion of *T. evansi* to erythrocytes observed in this study is not uncommon. This adhesion phenomenon has also been demonstrated in *T. gambiense*, *T. rhodesiense*, *T. brucei*, *T. congolense*, *T. lewisi* and *T. evansi* infections (DAVIS & BROWN, 1927; DUKE & WALLACE, 1930; BANKS, 1979; BANKS, 1980; BUNGENER & MULLER, 1976; ANOSA & KANEKO, 1983b). ANOSA & KANEKO (1983b) reported that the adhesion may damage the erythrocyte through alterations of membrane and predispose the affected red cell to destruction. Erythrophagocytosis demonstrated in this study with light microscopy has also been observed in various trypanosome infections (ANOSA & KANEKO, 1983b). The conclusion of this study is that erythrocyte abnormalities, trypanosome adhesion to red cells and erythrophagocytosis are important causes of anemia in trypanosomosis due to *T. evansi* in dogs and horses.

REFERENCES

- ANOSA, V.O., KANEKO, J.J. Pathogenesis of *Trypanosoma brucei* infection in deer mice (*Peromyscus maniculatus*): Hematologic, erythrocyte biochemical, and iron metabolic aspects. *Am J Vet Res*, v. 44, n. 4, p. 639-644, 1983a.
- ANOSA, V.O., KANEKO, J.J. Pathogenesis of *Trypanosoma brucei* infection in deer mice (*Peromyscus maniculatus*): Light and electron microscopic studies on erythrocyte pathologic changes and phagocytosis. *Am J Vet Res*, v. 44, n. 4, p. 645-651, 1983b.

- BANKS, K.L. *In vitro* binding of *Trypanosoma congolense* to erythrocytes. *J Protozool*, v. 26, p. 103-108, 1979.
- BANKS, K.L. Injury induced by *Trypanosoma congolense* adhesion to cell membranes. *J Parasitol*, v. 66, p. 34-37, 1980.
- BUNGENER, W., MULLER, G. Adhärenzphänomene bei *Trypanosoma congolense*. *Tropenmed Parasitol*, v. 27, p. 370-371, 1976.
- DAVIS, L.J., BROWN, H.C. The adhesionphenomenon, a special serological reaction occurring in trypanosomiasis. *Trans R Soc Trop Med Hyg*, v. 2, p. 113-114, 1927.
- DUKE, H.L., WALLACE, J.M. Red cell adhesion in trypanosomiasis of man and animals. *Parasitology*, v. 22, p. 414-456, 1930.
- JAIN, N.C. *Schalm's Veterinary Hematology*. 4th Ed. Philadelphia: Lea & Febiger, 1986. 1221 p.
- JENKINS, G.C., FACER, C.A. Hematology of African Trypanosomiasis, in: TIZARD, I. *Immunology and Pathogenesis of Trypanosomiasis*. Boca Raton, Florida: C.R.C. Press, p. 13-44, 1985.
- KATUNGUKA-RWAKISHAYA, E., MURRAY, M., HOLMES, P.H. The pathophysiology of ovine trypanosomosis: haematological and blood biochemical changes. *Vet Parasit*, v. 45, p. 17-32, 1992.
- LEVINE, N.D. *Protozoan Parasites of Domestic Animals and of Man*. 2nd Ed. Minneapolis, Minesota, Burgess Publishing Company, p. 48-49, 1973.
- LOSOS, G.J. Diseases caused by *Trypanosoma evansi*, a review. *Vet Res Com*, v. 4, p. 165-181, 1980.
- LOSOS, G.J. *Infectious Tropical Diseases of Domestic Animals*. Essex: Longman Scientific & Technical, 1986. 938 p.
- MAHMOUD, M.M., GRAY, A.R. Trypanosomiasis due to *Trypanosoma evansi* (Steel, 1885) Balbiani, 1888. A review of recent research. *Trop Anim Hlth Prod*, v. 12, p. 35-47, 1980.