

PATHOLOGICAL ALTERATIONS IN CARCASSES AND VISCERA OF JAPANESE QUAIL (*Coturnix japonica* - Temminck & Schlegel, 1849) OF COMMERCIAL BREEDING

[Alterações anatomopatológicas em carcaças e vísceras de codornas japonesas (*Coturnix japonica* - Temminck & Schlegel, 1849) de criação comercial]

Gersonval Leandro Silva Monte^{1*}, Daniel Grijó Cavalcante², Jefferson Bruno Soares Oliveira¹, Everton Ferreira Lima³

¹ Laboratório de Triatominae, Phlebotominae e fauna nidícola do Instituto Nacional de Pesquisas da Amazônia.

² Médico Veterinário da Secretaria Municipal de Meio Ambiente e Sustentabilidade – Semmas, Manaus.

³ Universidade Federal de Roraima, Centro de Ciências Agrárias, Campus Cauamé. Boa Vista, RR.

ABSTRACT – Identification of macroscopic injures in japanese quail carcasses during the slaughter process is essential to ensure the high quality of the final product, the meat, and decrease the risk of zoonotic diseases. This study aimed to describe the main pathological changes in japanese quail in slaughter process. For such, 31 individuals were sampled at two distinct farms situated in the rural zone of Manaus/AM. All analyses were performed in the Laboratory of Triatominae, Phlebotominae and Nidicola fauna of the National Institute for Amazonian Research, Manaus/AM. “*Ante mortem*” and “*post mortem*” inspection were performed in all carcasses. Externally there was only one specimen with cachexy. Lungs of 9,5% of the specimens had hyperemia and fibrin exudate in the apical lobes surface. Ulcerations in the proventriculus and ventriculus mucosal were reported in the 9,6% of birds. Pathological alterations have been registered in more than half of the Japanese quail. Three individuals showed mucus similar to coffee grounds in the jejunum, ileum and cecum. Cecum of these Japanese quail presented one or more parasites species. 87% of the livers showed a pale aspect, crumbly texture and multifocal areas yellowish or greenish gray colors. Ovarian follicles were atrophied and two oviducts presented fibrinous exudate in serous. The oviduct light it was partially obliterated by whitish exudate and caseous mass. Some pathological changes described are similar to those described for laying hens, however, we have also described macroscopic injuries to this species particular, which suggests further research on this kind has growing economic importance.

Keywords: macroscopic alteration; necropsy; *post mortem*; ornitopathology; coturniculture.

RESUMO – A identificação de lesões macroscópicas em carcaças de codornas japonesas durante o processo de abate é fundamental para manter a qualidade do produto final, a carne, e diminuir os riscos de zoonoses. Este trabalho visa descrever as principais alterações anatomopatológicas encontradas em codornas de postura. Foram examinadas 31 codornas com 12 meses de idade, destinadas ao abate, oriundas de duas granjas coturnicultoras da zona rural de Manaus/AM. A pesquisa foi desenvolvida no Laboratório de Triatominae, Phlebotominae e fauna nidícola do Instituto Nacional de Pesquisas da Amazônia, Manaus/AM. Esse consistiu em inspeções *ante mortem* e *post mortem* das carcaças. Externamente um exemplar estava com carcaça caquética. Os pulmões de 9,5% das amostras apresentavam hiperemia e exsudato fibrinoso na superfície dos lobos apicais. Verificaram-se ulcerações na mucosa do proventrículo e ventrículo, em 9,6% das codornas. Intestino delgado de 45,1% estavam alterados, bem como, 74,1 % dos cecos. Três codornas apresentaram conteúdo mucoso semelhante à borra de café nas porções do jejuno, íleo e cecos. Os cecos estavam parasitados por nematoda, cestoda e protozoários. Houve alteração em 87% dos fígados, verificou-se aspecto pálido, textura friável e áreas multifocais, uni ou bilobular, amareladas, acinzentadas ou esverdeadas. Alguns folículos ovarianos estavam atrofiados, sendo que, o oviduto de duas codornas apresentavam exudato fibrinoso na serosa, e massas caseosas na mucosa. Algumas lesões macroscópicas se mostraram particulares às codornas japonesas, o que sugere maiores pesquisas sobre esta espécie de crescente importância econômica.

Palavras-Chave: alteração macroscópica; necropsia; *post mortem*; ornitopatologia; coturnicultura.

* Autor para correspondência. E-mail: gersonval.monte@inpa.gov.br

INTRODUCTION

Recent problems for the expansion of coturniculture in the Brazilian market are in the standardization of the marketed carcasses quality. Currently, much of the Japanese quail intended for slaughter come from posture farms, consisting of birds at the end of production, and usually with carcasses traits out of livestock ideal for meats. The physiological and morphological similarities of Japanese quail with domestic chickens, have allowed the use of Japanese quail as an ideal experimental model for research centers, universities and in the poultry industry from various sectors. However, there are some differences in the macroscopic manifestations of affections, showing the importance of descriptive studies of specific anatomopathologic changes in Japanese quails (Berto et al., 2008; Shellenberger, 1968).

Foodborne diseases are extremely costly. Costing to countries like United States several billion dollars yearly in direct medical expenses and lost productivity. There are more than 250 known foodborne diseases. They can be caused by Nematodes, Cestoda, bacteria, viruses and other parasites or toxins. The risks of foodborne diseases as salmonellosis and aflotoxicoses are among the most common health problems of the current coturniculture, since there is little active supervision on hygiene, production, processing, packaging and preservation of meat and eggs sold in market-places (Balbani & Butugan, 2001; Smith, 2006). Just as in the inspection of beef, fish, chicken and derivatives, the post-mortem inspection of Japanese quail carcasses must provide a diagnosis of affections and other changes involving the partial or complete condemnation of carcasses and thus to promote the sanitation and zoonosis control (Lima et al., 2007).

Endoparasites also account for a significant portion of the problems of poultry production in general. Because when poorly controlled, protozoa and helminths can interfere in the commercial and productive performance of Japanese quail, causing reduced growth, weight gain and rejection of carcasses and internal organs, due to parasitic actions (Silva, 2005).

The Federal Inspection Service (FIS) when in activity on refrigerated slaughterhouses undertake nosological records with detailed description of the changes displayed on carcasses. These records will later be used for sanitary inspections, allowing the identification of subclinical characteristics of diseases and to quantify the severity of this, through visualization of anatomopathologic changes (Pointon et al., 1992; Morés et al., 2000), as an example, dehydration, ascites, hepatitis, cellulite,

serious bleeding process, neoplasia, fractures and bile and feces contamination (Luquetti, 2006). Therefore, this study aimed to describe the main anatomopathologic changes found in laying Japanese quails for slaughter.

MATERIAL AND METHODS

Were examined 31 Japanese quails (*Coturnix japonica* - Temminck & Schlegel, 1849) all of them with one year old, clinically healthy and intended for slaughter for consumption. The Japanese quails were donated by two coturnicultoras farms from rural area of Manaus, AM. All analyses were performed in the Laboratory of Triatominae, Phlebotominae and Nidicola fauna of the National Institute for Amazonian Research (INPA), Manaus/AM. The Japanese quails were examined individually, relating carcasses and their viscera. In the *ante-mortem* inspection was observed the appearance of feathers, bruises, nutritional status and the presence of ectoparasites. Already at *post-mortem*, there was a visual inspection and palpation, and then an incision along the pectoral muscles following all trough the sternum.

After the carcasses opening, the viscera were removed for further analysis. All organs were evaluated for color, consistency, aspect, shape, distribution and size of the lesions and the presence of liquid and smell. The lungs was visually inspected, palpated, been incised and examined. The abdominal and thoracic air sacs were visually inspected *in situ*.

The parenchymatous organs (liver, spleen and kidneys) were analyzed the outer surface cutting. As the intestines, these were opened for change research and the presence of parasites. The viscera were separated by systems and arranged in sterile Petri dish containing 10 ml of 0.9% saline solution in order to preserve the integrity of the tissues during the search.

RESULTS AND DISCUSSION

In the *ante-mortem* inspection was seen in only one quail, a clear sign of cachexia and apathy. In general, all the carcass were in good quality of meat and fat in breast. Lotfi et al. (2011) reported that the breast its a considerable part of the carcass in Japanese quail and due to the higher percentage of breast intramuscular fat, the quality of breast meat in Japanese quail is higher compared with that in broilers. Japanese quails are prone to almost all disease that are seen in chickens.

Macroscopically the lungs 9.5% of the Japanese quails were with deep red in color (hyperemic), due to congested, or opaque pink tending to gray,

slightly rounded, and the left lung most often compromised (Figure 1A). To palpation one exemplary presented cottony and crepitant consistency with emphysematous aspect.

Overall the changes had a fibrinoid aspect, apparently concentrating on the apical surface of lung lobes. In some cases as much as visceral the edge face of the left lobe were compromised by disease. Some authors believe that anatomical features of the respiratory tract of birds may facilitate the occurrence of diseases, especially diseases of bacterial origin (Fedde, 1998; Oliveira et al., 2009).

Also according to Dyce et al. (1990) the duct interconnecting the sinuses to the oral cavity is

extremely narrow and such morphology can facilitate the accumulation of secretions. Fedde (1998) adds that the normal accumulation of low quantities of gases in the abdominal air sacs also help in fixing bacteria and development of respiratory infections. Its possible that these mechanisms and anatomical peculiarities may explain the inflammatory processes described here for the respiratory system of Japanese quail. Moreover, recent experiments also demonstrated the relationship in the intrapulmonary inflammatory responses, as well as, pulmonary arterial hypertension with the anatomical traits of the pulmonary vasculature (degree of constriction) and cardiac vasculature (Wideman et al., 2013).

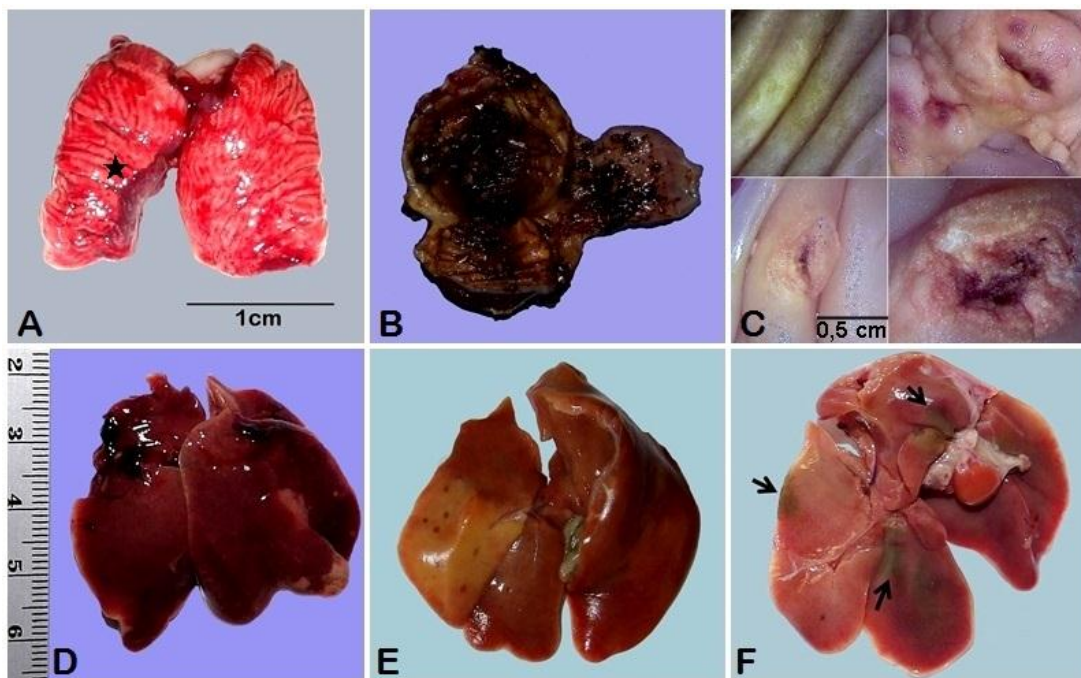


Figure 1. Major macroscopic changes found in the lungs, gizzard and liver of Japanese quail; A, left lung atrophied lobo, hyperemic, with great degeneration area deep red in color (star); Dorsoroventral view. B, proventriculus and ventriculus (gizzard) with blackish content similar to coffee grounds and several ulcerative lesion at the keratinoid coating (Coilin); Light organ. C, Micro ulcers in the proventriculus and ventriculus (gizzard). D, liver with curved edges (hepatomegaly) with diffuse haemorrhage and apical portion of right lobe to turn pale; Visceral view. E, Right lobo diffusely pale. With points of fibrosis similar to larvae migration; Visceral view. F, pale liver with diffuse greenish spots (arrows); Visceral view.

Examination of the proventriculus and ventriculus (gizzard) of 9.6% of quail revealed several ulcerative lesion at the keratinoid coating (coilin), the lesions ranged from 0.2 to 0.7 mm. Mostly perforating the coilin layer and were limited to the intermediate zone and mucus glands, two specimens its had blackish content similar to coffee grounds covering the entire ventricle, these after being washed with saline solution revealed diffuse multifocal and petechial hemorrhages (Figures 1B; 1C).

According to some authors (Santos, 1975; Marek et al., 2010; Lim et al., 2012) some vitamins and fowl adenovirus act as anti-erosion factors “*Anti Gizzard Erosion Factors*” proventriculus and ventricle they are vitamins K and B1, adenovirus serotype-1 (FAdV-1, K181 strain).

The adenovirus isolate alone can induce clinical disease in chicks infected experimentally, moreover, no clinical signs in experimental infection. However, macroscopically, focal gizzard lesions, such as a rough or cloudy koilin layer are

observed (Lim et al., 2012). In another situation, the deficiency of vitamins K, B1 would provide a weakening of the attachment of the epithelium membrane coilin proventriculus. Macroscopically the process begins with petechiae hemorrhages in the ventricular surface later the coilin takes on a rough exterior, and then arise points of proventricular and ventricular erosion.

Besides the *Anti Gizzard Erosion Factors* some toxins also provide the formation of erosion in coilin. According Sylos et al. (1996) approximately 36% of the strains of *Aspergillus flavus* produce Cyclopiazonic acid (CPA) a mycotoxin high erosive power coilin and the ventricular mucosa. All processes mentioned are potential trainers of injury: adenovirus, vitamin deficiencies or mycotoxins, and so far had not been mentioned in Japanese quails work, however, due to anatomical and physiological proximity between chickens and Japanese quails is possible that the lesions described in this study have the same etiology that described for chickens.

Of the 31 livers examined 27 (87%) had pale parenchyma and friable texture, macroscopically with yellowish, grayish or greenish focal areas ranging from 0.2 to 1.6 cm, which were distributed unilaterally or bilobar, with or without curved edges characteristics of hepatomegalias (Figures 1D, E, F).

According Butkeraitis et al. (2004) these changes are compatible with mycotoxicosis. The above described previously added to the latter in the liver increases the possibility of food poisoning. However, some authors claim that even under natural conditions laying hens tend to develop a physiological steatosis due to stress of the productive rhythm. Within the different species of fowl, the susceptibility to hepatic steatosis can be different according to species or breeds. (Randall & Reece, 1996; Saez et al., 2010). Livers pale (steatosis) and friable aspect in poultry production tends to be a routine to find, if we consider the intense feeding of the base feeds rich in proteins and oils, however this affirmative is controversial because it is not possible to affirmed whether these macroscopic characteristics are pathogenic or not changes.

On the 27 livers gross changes seven (25.92%) had punctate hemorrhage and easy detachment of the Glisson capsule. These hepatic alterations were observed in Japanese quails that also had ulcerative lesions in the ventriculus coilin, and, according to some authors (Müller et al., 1970; Bordini et al., 2013) these symptoms feature a suggestive diagnosis of poisoning by aflatoxins where sensitivity to aflatoxins varies considerably in the

following species; ducks, turkeys, geese, pheasants and chickens, which consequently generates a range of different pathophysiological changes.

In 25.9% of the 31 livers studied are perceived punctate cicatricial lesions well defined grayish color or black color circumscribed by a whitish halo similar to larval migration points. These lesions were more evident in the pale areas of the hepatic parenchyma. Some nematodes *Ascaridia galli* have larvae that eventually perform a liver and lung cycle before they reach the intestine. In these cases may also occur as bacterial infections associated with *Pasteurella multocida*, triggering a significant weight loss and low in the production of poultry (Dahl et al., 2002).

The gallbladder varied in length from 1.2 to 1.7 cm (AVG = 1.4 / SD = 0.16 / N = 21) as there is no in the literature a table of morphometric values for gallbladder Japanese quails, data morphometric could not be compared. Thus, could not determine whether the changes were or not some pathological change. The bile of the study also showed some chromatic variation; translucent yellowish, brown yellowish, yellow greenish, translucent brown, light green, dark green and blackish. In this case the lack of literature also does not allow a clear definition based only on descriptions of macroscopic findings and may or may not be due to the impairment of liver function.

At necropsy realized to macroscopic changes in the small intestine of 14 (45.1%) of the 31 sampled Japanese quails. Overall, the intestinal loops its had distended due to accumulation of gas, mucous membranes its had congested and covered with mucous content markedly yellowish mustard, possibly with blood streaks with the serous. According to the macroscopic characteristics of the lesion can suggest a catarrhal inflammation of the intestine (Figure 2A). Three Japanese quails were with lot of dark mucus similar to coffee grounds in the jejunum portions, ileum and cecum. In these cases also had adelgamento walls due to the accumulation of gas, which afforded strap ruptures during autopsy cases (Figure 2B).

According to Silva et al. (2005) production of poultry are subject to a variety of diseases such as salmonellosis, trichomoniasis, mycotoxicosis, avian monocytosis (*Disease cholera like*), all pathogenic and potentially causing gross lesions in the intestine. Dhillon et al. (2004) adds that infectious agents such as *Clostridium perfringens*, *C. colinum* and others are the most responsible for avian necrotic enteritis and ulcerative enteritis outbreaks respectively. These are present in the intestines of birds and in the environment which facilitates the spread poultry.

Dhillon et al. (2004) described an outbreak of avian necrotic enteritis as a result of ingestion of *C. perfringens* their flies or infected secretions, and because of this considered as a mechanical fly vector *C. perfringens*. However, in his work Dhillon et al. (2004) did not identify the species involved flies. Other insects such as mealworm beetle (*Alphitobius diaperinus*) have also been listed as potential vectors *C. perfringens* (Vittori et al., 2007).

In this research some parasites of classes Nematoda, Cestoda and protozoa were recorded in Japanese quails with catarrhal and hemorrhagic inflammation of the bowel, possibly being these parasites those responsible for enteritis. According to Silva et al. (2005) diagnosis enteritis with mucoid diarrhea when there is relatively common and cestodas parasitism by nematodes, especially in cases of high parasitic infestations. Among the protozoa that cause more damage to the commercial poultry industry are the *Eimeria*, however, in coturniculture some research shows that adult Japanese quails are relatively resistant to infection, not manifesting specific symptoms, however, the autopsy which can be checked hyperemia and congestion of intestinal mucous small and cecum (Gesek et al., 2014; Mohammad, 2012).

The cecum of 23 (74.1% / C = 31) of Japanese quails its had distended by gas accumulation as well, parasitized by one or more species of parasites. Three Japanese quails were with serous

both hyperemic cecum and dark colored excessive mucous content similar to coffee grounds. These Japanese quail are the same as presented above for "*hemorrhagic catarrhal enteritis*" described above. Teixeira et al. (2004) reported that diarrhea and cecal expansion by gas accumulation in quails are suggestive of parasitaemia by *Eimeria* sp. However, there are few eimeriosis research in Japanese quails, and besides, the clinical manifestations in Japanese quails tend to show themselves different infections in chickens due, perhaps, to the host specificity of *Eimeria*. In broilers and laying clinical signs are more intense (MacDougald & Reid, 1991).

Macroscopically, the ovarian follicles were mostly reduced in size or atrophied, and those that were developed were with flabby texture. Already in the oviducts, two Japanese quails had fibrinous material in serous, which was distributed throughout most of the peritoneum, possibly a fibrinous peritonitis.

At the opening of the oviduct it was found that the most affected areas stretched the isthmus area to the *magnum*. These had a adelgamento walls making it susceptible to breakage. In light of the oviduct was a thick layer of dense whitish exudates sharply, reaching in some cases to form caseous mass. Below that layer there was exudate multiple cysts measuring 0.5 to 1.5 mm, filled with slightly opaque liquid. Macroscopically, these descriptions are similar to those reported salpingitis for broilers and laying (Buim, 2007) (Figure 2C, 2D).

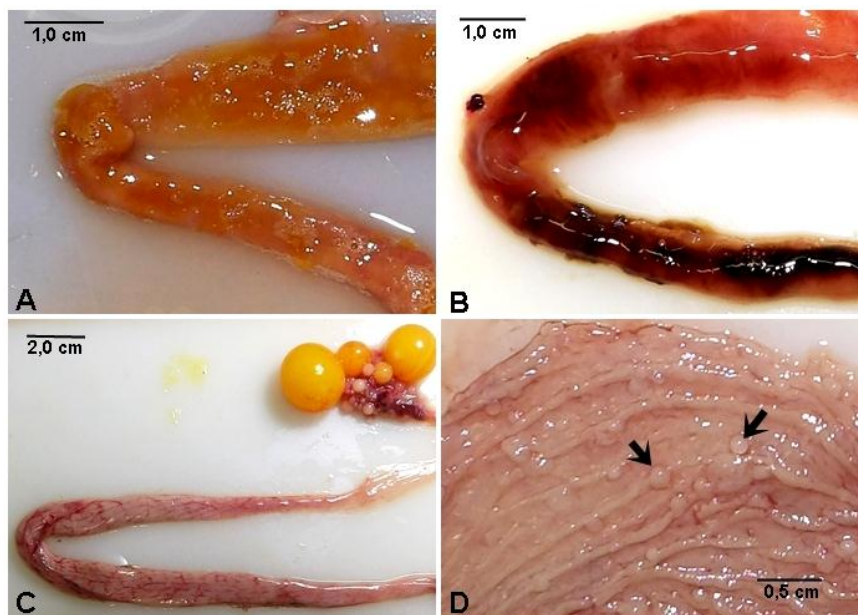


Figure 2. Macroscopic changes in the intestine and oviduct; A, Mucosa of the intestine congested and covered with lots of yellowish mustard mucous, suggestive of catarrhal inflammation of the intestine; Light organ. B, Mucosa of the intestine congested, and covered with red and black mucous, suggestive of hemorrhagic catarrhal inflammation of the intestine; Light organ. C, oviduct congested, with bulged appearance and thickening of the mucosa, possibly salpingitis. D, Formation of multiple cysts measuring 0.5 to 1.5 mm, filled with slightly opaque liquid (arrows).

Salpingitis consists of an inflammation of the oviduct, resulting from bacterial infections, whose main etiologic agent *Escherichia coli*. The process is usually chronic, often being more related to laying hens *Gallus gallus domesticus* (Knöbl et al., 2006).

CONCLUSION

Some pathological alterations described in this study for *C. japonica* are compatible with lesions known for laying hens, however, until they found themselves with no references in the literature. In this research we have also been described apparently private gross lesions to Japanese quails, however, more research is needed to make better know the pathological changes of this kind of growing economic importance.

ACKNOWLEDGEMENTS

To the academics of Veterinary Medicine; Luis Felipe and José Wallace Sampaio for his help in necropsy.

REFERENCES

- Balbani, A.P.S., Butugan, O. 2001. Contaminação biológica de alimentos. *Pediatria*, 23 (4):320-328.
- Berto, B.P., Cardozo, S.V., Teixeira-Filho, W.L., Ferreira, A.M.R., Lopes, C.W.G. 2008. Aflatoxin effect on the oocysts morphometry and contribution on the morphology of *Eimeria bateri* Bhatia, Pandey and Pande, 1965 of the Japanese quail *Coturnix japonica*, in Brazil. *Rev. Bras. Parasitol. Vet.*, 17:235-238.
- Bordini, J.G., Rossi, C.N., Hirooka, E.Y., Ono, E.Y.S. 2013. Impact of Fumonisin, Aflatoxins and Ochratoxin A on Poultry Industry. *Biochemistry and Biotechnology Reports*. Jan./Jun., v.2, n.1, p. 68-88.
- Buim, M.R. 2007. Micoplasmose aviária. *Arquivos do Instituto Biológico*, 73 (1): 23-26.
- Butkeraitis, P., Oliveira, C.A.F., Ledoux, D.R.; Ogido, R., Albuquerque, R., Rosmaninho, J. F., Rottinghaus, G.E. 2004. Effect of dietary fumonisin B1 on laying Japanese quail. *British Poultry Science*, v. 45, p. 798-801.
- Dahl, C., Permin A., Christensen, J.P., Bisgaard, M., Muhairwa A.P., Petersen K.M.D., Poulsen J.S.D., Jensen A.L. 2002. The effect of concurrent infections with *Pasteurella multocida* and *Ascaridia galli* on free range chickens. *Veterinary Microbiology*, 86: 313-324.
- Dhillon, A.S., Roy, P., Lauerman, L., Schaberg, D., Weber, S., Bandli, D., Wier, F. 2004. High Mortality in Egg Layers as a Result of Necrotic Enteritis. *Avian Diseases*, 48 (3): 675-680.
- Dyce, K.M., Sack, W.O., Wensing, C.J.G. 1990. Tratado de Anatomia Veterinária. Guanabara Koogan: Rio de Janeiro.
- Fedde, M.R. 1998. Relationship of Structure and Function of the Avian Respiratory System to Disease Susceptibility. *Poultry Science* 77:1130-1138.
- Gesek, M., Welenc, J., Tylicka, Z., Otrocka-Domagala, I., Paździor, K., Rotkiewicz, A. 2014. Pathomorphological changes in the alimentary system of Japanese quails naturally infected with *Eimeria tsunodai*. *Bull Vet Inst Pulawy* 58: 41-45.
- Knöbl, T., Gomes, T.A.T., Vieira, M.A.A., Bottino, J.A., Ferreira, A.J.P. 2006. Occurrence of adhesin-encoding operons in *Escherichia coli* isolated from breeders with salpingitis and chicks with omphalitis. *Brazilian Journal of Microbiology*, 37:140-143.
- Lim, T.H., Kim, B.Y., Kim, M.S., Jang, J.H., Lee, D.H., Kwon, Y.K., Lee, J.B., Park, S.Y., Choi, I.S., Song, C.S. 2012. Outbreak of gizzard erosion associated with fowl adenovirus infection in Korea. *Poultry Science* 91 :1113-1117.
- Lima, M.F.C., Suassuna, A.C.D., Ahid, S.M.M., Filgueira, K.D. 2007. Análise das alterações anatomopatológicas durante a inspeção *Post Mortem* em bovinos no abatedouro frigorífico industrial de Mossoró, Rio Grande do Norte. *Ciência Animal*, 17(2):113-116.
- Lotfi, E., Zerehdaran, S., Ahani Azari, M. 2011. Genetic evaluation of carcass composition and fat deposition in Japanese quail. *Poultry Science* 90:2202-2208.
- Luquetti, B.C., Oliveira, D.S., Cozza, R.A.Q. 2006. Síndrome Ascítica em Frangos de corte - Relato de Caso. *Ciências Agrárias em Saúde*, v.6.
- Marek, A., Schulz, E., Hess, C., Hess, M. 2010. Comparison of the fibers of fowl adenovirus A serotype 1 isolates from chickens with gizzard erosions in Europe and apathogenic reference strains. *J. Vet. Diagn. Invest.* 22:937-941.
- Mohammad, N.H. 2012. A study on the pathological and diagnosis of *Eimeria* species infection in Japanese quail. *Bas. J .Vet. Res.*11 (1).
- Morés, N., Sobestiansky, J., Lopes, A. 2000. Avaliação patológica de suínos no abate – Manual de identificação. Embrapa: Brasília. p 40.
- Müller, R.D., Carlson, C.W., Semeniuk, G., harshfield, G.S. 1970. The response of chicks, ducklings, goslings, pheasants and poult to graded levels of aflatoxins. *Poultry Science*, 49(5):1346-1350.
- Oliveira, A., Sereno, R., Nicolau, A., Azeredo, J. 2009. IMMUNOLOGY, HEALTH, AND DISEASE: The influence of the mode of administration in the dissemination of three coliphages in chickens. *Poultry Science* 88 :728-733.
- Pointon, A.M., Mercy A.R., Bacstrom, L. 1992. Disease surveillance at slaughter: In: Leman A.D., Straw W.L., Mengeling W.L. et al. (Eds). *Diseases of swine*. 7.ed. Iowa: Iowa University. pp.968-985.
- Randall, C.J., Reece, R.L. 1996. Colour atlas of avian histopathology. London, Mosby-Wolfe, p.232.
- Saez, G., Baéza, E., Bernadet, M.D., Davail, S. 2010. Is there a relationship between the kinetics of lipoprotein lipase activity after a meal and the susceptibility to hepatic steatosis development in ducks?. *Poultry Science* 89 :2453-2460.
- Silva, M.E.M., Júnior, D.G.M., Tortelly, R., Menezes, R.C. 2005. Lesões causadas por alguns helmintos em galinhas-d'angola (*Numida meleagris*, L.) procedentes do estado do Rio de Janeiro. *Revista Brasileira de Ciência Veterinária*, 12 (1/3): 118-123.
- Shellenberger, T.E. 1968. Biological studies utilizing Japanese quail. *Lab. An. Care*, 18: 244-249.

Sylos, C.M., Rodrigues-Amaya, D.B., Santurio, J.M., Baldissera, M.A. 1996. Occurrence of aflatoxins and cyclopiazonic acid in Brazilian peanut and corn. in: IX international IUPAC Symposium. Roma, Itália.

Teixeira, M., Teixeira-Filho, W. L., Lopes, C.W.G. 2004. Coccidiosis in Japanese quails (*coturnix japonica*) characterization of a naturally occurring infection in a commercial rearing farm. Rev Bras Cienc Avic. 6:129 -134.

Vittori, J., Schocken-Iturrino, R.P., Trovó, K.P., Ribeiro, C.A.M., Barbosa, G.G., Souza L.M., Pigatto, C.P. 2007. *Alphitobius diaperinus* como veiculador de *Clostridium perfringens* em granjas avícolas do interior paulista – Brasil. *Ciência Rural*, 37(3): 894-896.

Wideman, R.F., Rhoads, D.D., Erf, G.F., Anthony, N.B. 2013. Pulmonary arterial hypertension (ascites syndrome) in broilers: A review. *Poultry Science* 92 :64–83.