

We are IntechOpen, the world's leading publisher of Open Access books Built by scientists, for scientists

5,900

Open access books available

145,000

International authors and editors

180M

Downloads

Our authors are among the

154

Countries delivered to

TOP 1%

most cited scientists

12.2%

Contributors from top 500 universities



WEB OF SCIENCE™

Selection of our books indexed in the Book Citation Index
in Web of Science™ Core Collection (BKCI)

Interested in publishing with us?
Contact book.department@intechopen.com

Numbers displayed above are based on latest data collected.
For more information visit www.intechopen.com



Pathology Associated with Hormones of Adrenal Cortex

*Lovelesh K. Nigam, Aruna V. Vanikar, Rashmi D. Patel,
Kamal V. Kanodia and Kamlesh S. Suthar*

Abstract

Adrenal gland is an endocrine organ comprising of an outer cortex and inner medulla. These secrete various hormones that have a vital role in maintaining the normal homeostasis of the body. Lesions of adrenal cortex are quite common to encounter and most of these are related to the hormones secreted by three layers of adrenal cortex: the zona glomerulosa, the zona fasciculata, and the zona reticularis. Also it is very infrequent to encounter metastatic lesions in the adrenal glands too. So it is very important as a part of a clinician as well as a pathologist to know the pattern in which these hormones are secreted along with their physiological roles. Thus this chapter includes the disease that are related to excess as well as deficiencies of the hormones secreted by adrenal cortex. The chapter also includes various genetic syndromes that are associated with the disorders associated with hormones of adrenal cortex. The last part of the chapter includes a brief description of various benign as well as malignant lesions, the pathological as well as the etiological aspects and the hormonal abnormalities associated. This chapter thus mainly focuses on the pathology associated with the adrenal cortex and hormones secreted by the various layers of adrenal cortex.

Keywords: adrenal cortex, hormones, Cushing syndrome

1. Introduction

Adrenal gland consists of an outer cortex and inner medulla; the cortex is further subdivided into three distinct zones: the zona glomerulosa, the zona fasciculata, and the zona reticularis. Mineralocorticoids (aldosterone) secreted from the zona glomerulosa are essential for fluid and electrolyte balance and the renin-angiotensin-aldosterone system. The fasciculata secretes glucocorticoids (mainly cortisol). The zona reticularis produces steroid sex hormones called androgens. These hormones play an important role in maintaining the normal homeostasis of the body [1–3]. However, it is quite common to encounter disorders related to the hormones of these three layers. These disorders could be possibly due to adrenal cortical masses secondary to cortical hyperplasia. It is very infrequent to encounter metastatic lesions in the adrenal glands.

This chapter mainly focuses on the pathology related to adrenal cortex which includes various forms of adrenocortical hyperplasia and benign and malignant neoplasms of the adrenal gland which lead to various hormonal imbalances encountered in clinical practice. Hormonal deficiency is due to inherited glandular or enzymatic

disorder, destruction of pituitary gland by autoimmune disorders, infection, infarction, or others [4, 5]. The major disorders of the adrenal cortex are characterized by excessive or deficient secretion of each type of adrenocortical hormone.

2. Functional manifestations

The lesions of the adrenal cortex could be functional as well as nonfunctional, which means that patients with these lesions may exhibit clinical symptoms that are due to hypersecretion of hormones released. Usually cortical hyperplasia and adenomas are nonfunctioning. The functional syndromes associated with pathology of adrenal cortex are hypercortisolism (Cushing's syndrome), adrenal insufficiency (Addison's disease), hyperaldosteronism, and androgen excess (adrenogenital syndrome) [4–9].

3. Adrenal hyperplasia

Adrenal hyperplasia is characterized as a smooth, diffuse, bilateral enlargement of the adrenal glands, wherein the glands retain their adreniform shape. Hyperplasia can be either macronodular or micronodular. They are commonly unilateral; however bilateral cases are also observed [7, 8]. Broadly adrenal cortical hyperplasia can be grouped into three main categories: ACTH-dependent (adrenocorticotrophic hormone), ACTH-independent, and congenital adrenal hyperplasia (CAH). Cushing's syndrome is one of the common functional manifestations of adrenal gland hyperplasia and therefore is discussed first [8, 10, 11].

3.1 Cushing's syndrome

3.1.1 Definition

It is a syndrome which encompasses various clinical features due to chronic excess of glucocorticoids. The incidence is nearly 1–2 per 100,000 population per year. Harvey Cushing was the first to observe pituitary adenomas associated with hypercortisolism in 1932 [10–13]. Cushing's syndrome, caused by prolonged exposure of tissues to high levels of cortisol, presents as constellation of symptoms including central obesity, muscle fatigue/atrophy, hirsutism, infertility, osteoporosis, moon facies, dorsocervical and supraclavicular fat pads, and wide purple striae [8, 10, 12]. The syndrome may be ACTH-dependent or ACTH-independent. A fair number of cases attributed to iatrogenic causes are also identified. Most of the cases of Cushing's syndrome are due to ACTH hypersecretion from the anterior pituitary and are associated with pituitary cortical adenoma. Majority of the cases, about 80–90%, show diffuse hyperplasia of the adrenal cortex [9, 10]. Nearly 15% of cases do present with ectopic ACTH secretion associated with small cell lung carcinoma or bronchial carcinoid. Thymic carcinoids, pancreatic islet cell tumor, pheochromocytomas, and medullary carcinoma of thyroid form minor group of tumors associated with ectopic ACTH secretion [12]. In a study by Ejaz et al., lung tumors constituted 44.4% of all cases of neoplasm-related ectopic ACTH secretion causing Cushing's syndrome [14]. Clinically patients with Cushing's syndrome present with diastolic hypertension, hypokalemia, and edema. Hypogonadism and amenorrhea can also be seen in these patients which are attributed to suppression of gonadotropin secretion secondary to excess glucocorticoid secretion [10–14].

3.1.2 Cushing disease

Cushing disease, resulting from a pituitary corticotrophic adenoma, and rarely carcinoma, makes up to 80–85% of endogenous Cushing's syndrome cases [8, 10, 15].

3.1.3 Investigating a case of Cushing's syndrome

A two-stage test is usually recommended in a patient to rule out Cushing's syndrome [8, 10, 15–17]:

1. The first group of tests are to screen for the evidence of hypercortisolism. These comprise urine cortisol excretion and low-dose dexamethasone suppression test.
2. The second group of tests comprise of the diagnostic tests which help to determine the cause of excessive production of cortisol. These are:
 - a. Plasma ACTH measurement: Low plasma ACTH level suggests an adrenal cause of the disease; however normal/high [ACTH] level suggests ectopic ACTH secretion or hypersecretion of ACTH from pituitary (Cushing's disease).
 - b. High-dose dexamethasone suppression test: In this test the patient is administered with 2 mg of dexamethasone, 6 hourly for 48 h, following which plasma cortisol levels are measured. In the case of ectopic ACTH secretion or adrenal limited hypercortisolism, there is a failure of suppression of cortisol secretion. Also it is important to remember that cortisol is not suppressed with either low- or high-dose dexamethasone suppression in adrenal hyperplasia associated with ectopic ACTH production [18].

3.1.3.1 The 24-h urinary-free cortisol test

This investigation is used primarily for the diagnosis of hypercortisolism due to Cushing's syndrome, and reference ranges for this test with respect to age are 1.4–20 µg/24 h (3–8 years), 2.6–37 µg/24 h (9–12 years), 4–56 µg/24 h (13–17 years), and 3.5–45 µg/24 h in individuals ≥18 years of age. A 24-h urine sample with boric acid (10 g) as preservative is advisable for performing this analysis [10, 17–19].

3.1.4 ACTH-independent Cushing's syndrome

Nearly 15–20% of Cushing's syndrome are associated with ACTH-independent hypercortisolism and are secondary to a functioning adenoma or carcinoma. Diagnosis of ACTH-independent Cushing's syndrome includes clinical features of hypercortisolism, absence of serum cortisol diurnal rhythm, elevated late-night cortisol levels, and incomplete suppression of cortisol production with low-dose dexamethasone suppression test [10, 17–20].

3.1.5 Pathological findings

Adrenal glands from patients with Cushing's syndrome/hyperplasia appear variably enlarged in size and weigh approximately 6–12 g. The cortical width is widened as compared to the reticulosa. The zona fasciculata usually shows nodular hyperplasia. Nearly 10–20% of the patients reveal bilateral nodular hyperplasia, and up to 30% of patients may have normal adrenal morphology [2, 20, 21].

3.2 Primary pigmented nodular adrenocortical disease (PPNAD)

Primary pigmented nodular adrenocortical disease is a rare cause of childhood Cushing's disease having female preponderance, whereas Cushing's disease is common in prepubertal males [20–22]. It is the main endocrine manifestation of Carney complex (a multiple neoplasia syndrome caused by mutation in *PRKAR1A* gene) [23]. This is an autosomal dominant syndrome and is characterized by cutaneous lentigines, myxoma, schwannomas, and endocrinopathy [11, 23]. It was first described by Aidan Carney and co-workers in 1985. Almost 25–30% of patients with Carney complex have ACTH-independent Cushing's syndrome. Cutaneous pigmentation is the commonest manifestation of the disease [24]. Lentigines are seen in most patients, and this characteristic manifestation can be used to make the definitive diagnosis. The name is derived from the macroscopic appearance of the adrenals that show characteristic small pigmented micronodules in the adrenal cortex. The disease typically involves bilateral adrenal glands. Grossly the adrenal glands may have variable size. The most characteristic finding is the presence of multiple brown-black pigmented cortical nodules that measure 1 mm to 3 cm in diameter. The adjacent cortical tissue invariably shows atrophy. These pigmented nodules may extend into corticomedullary junction or peri-adrenal fat [9, 11, 24].

On microscopy these tumors appear as sharply circumscribed, unencapsulated tumors composed of large eosinophilic lipid-poor cells similar to the zona reticularis arranged predominantly in trabecular growth pattern. However the nucleus appears enlarged, with a variable degree of pleomorphism and prominent nucleoli. There is prominent lipofuscin deposit. Lipid-rich fasciculata-like cells are also seen invariably. The tumor may have focal areas of necrosis, mitotic activity, myelolipomatous change, and lymphocytic infiltrates [9, 11, 24].

3.3 ACTH-independent macronodular adrenal hyperplasia (AIMAH)

(Synonyms: ACTH-independent massive bilateral adrenal disease, massive macronodular hyperplasia, giant macronodular adrenal hyperplasia, macronodular adrenal hyperplasia, macronodular hyperplasia).

AIMAH is a disorder characterized by bilateral adrenocortical nodules, associated with ACTH-independent hypercortisolism, without any clinical features of pigmented nodular adrenocortical disease and histological features consistent with atrophic internodular cortex [25]. It is a rare cause of ACTH-independent Cushing's syndrome with slightly male preponderance. The patients present usually at later age (average: 48 years) [24–26]. In few patients with AIMAH, ectopic expression and/or increased sensitivity to gastric inhibitory peptide, vasopressin receptors, and beta-adrenergic receptors is also seen [25].

Grossly these lesions are characterized by nodules in the adrenal cortex, ranging from 1 to 4.2 cm. The adrenal gland weighs approximately 16.7–218 g. The adrenal gland may have a large mass of cortical tissue and multiple bilateral nodules measuring up to 5 cm. Combined adrenal gland weight of more than 300 g has also been noted (normal range: 8–12 g). Histology demonstrates large, yellow macronodules comprising of small cells with eosinophilic cytoplasm. Bilateral adrenalectomy and well-controlled glucocorticoid replacement is the most accepted treatment modality [2, 3, 9, 25, 26].

3.4 Congenital adrenal hyperplasia

CAH is an autosomal recessive disorder characterized by impaired steroidogenesis finally leading to mineralocorticoid and cortisol deficiency secondary to reduced activity of enzymes required for cortisol biosynthesis in the adrenal cortex.

These patients usually present during the perinatal period with ambiguous genitalia in females and salt wasting in males. The milder forms of disease may present later with virilization at puberty or even as irregular menses. Most of the cases (nearly 95%) are attributed to deficiency of the 21-hydroxylase enzyme [27, 28].

Abnormal growth and development, adverse effects on bone and the cardiovascular system, and infertility are few long-term effects seen in these patients. These patients are usually managed by reducing glucocorticoid exposure and improving excess hormone control [29, 30].

Congenital adrenal hyperplasia can be of four forms [8–10, 27–30]:

1. Congenital adrenal hyperplasia: classical 21-hydroxylase deficiency
2. Simple virilizing congenital adrenal hyperplasia
3. Non-classic or late onset form of congenital adrenal hyperplasia
4. Congenital adrenal hyperplasia with steroidogenic acute regulatory (StAR) mutation

3.4.1 Congenital adrenal hyperplasia: Classical 21-hydroxylase deficiency

This form is the most common form of CAH, occurring due to 21-hydroxylase (21-OH) deficiency, accounting for almost 90% of the cases. It occurs with the frequency of 1:12000 to 1:15000 births, and nearly 75% of patients with classic 21-OH

Multiple endocrine neoplasia (MEN) type 1	Adrenocortical lesions are seen in nearly 36–41% of individuals with MEN type I syndrome, the commonest being bilateral nonfunctioning adrenal cortical hyperplasia or adenoma; adrenocortical carcinoma is exceedingly rare. The pathogenesis of these lesions is proposed to be due to influence of locally secreted insulin and insulin-like growth factors and not due to menin gene mutations
Carney complex	This syndrome encompasses multiple endocrine hyperplasia, with tumors of two or more endocrine glands, including primary pigmented adrenocortical disease (PPNAD), GH- and prolactin-producing pituitary adenomas, testicular neoplasms, thyroid adenoma or carcinoma, and ovarian cysts. This autosomal dominant syndrome is mapped to two genetic loci, one present on chromosome 2p16 and another locus at chromosome 17q22–24 encoding the PRKARIA gene [82]
Beckwith-Wiedemann syndrome	This syndrome is characterized by gigantism, ear lobe pits and/or creases, macroglossia, and defects in the abdominal wall and is associated with chromosomal aberration of 11p15.5. These individuals are at higher risk of developing benign or malignant tumors of multiple organs, commonest being Wilms' tumor, rhabdomyosarcoma, hepatoblastoma, and adrenal carcinoma
Li-Fraumeni syndrome	Rare, autosomal, dominant familial syndrome with high incidence of multiple malignancies at an early age, including breast cancer, leukemias, soft tissue sarcomas, gliomas, laryngeal carcinoma, lung cancer, and adrenocortical carcinoma. The pathogenesis of this syndrome is attributed to germ-line point mutations in the p53 tumor suppressor gene (chromosome 17p13) in pediatric age group with adrenocortical carcinoma and deletion of short arm of chromosome 17 (17p)
Familial adenomatous polyposis	This disease is an autosomal dominant disorder, characterized by the presence of multiple adenomatous polyps of the colon and rectum. The gene [adenomatous polyposis coli gene] is located at 5q21. These patients are at high risk to develop adrenocortical adenomas and carcinomas, the incidence being 7.4% higher than 0.6–3.4% reported for normal population

Table 1.
Hereditary adrenocortical tumor syndromes.

deficiency also have defect in synthesizing aldosterone. These patients die in the neonatal period due to shock from salt wasting. CAH is associated with multiple tumors like testicular tumors arising from ectopic adrenal cortical rests, testicular and ovarian Leydig cell tumor, and ovarian tumor of the adrenogenital syndrome as ovarian and paraovarian brown masses. Grossly the adrenal gland is marked enlarged having a cerebriform appearance. On cut surface the gland appears tan-brown in color. Under the microscope the adrenal gland reveals diffuse cortical hyperplasia. The cells are compactly arranged like how they are in the zona reticularis [2, 27–30].

Table 1 illustrates various syndromes associated with adrenocortical lesions [31].

4. Primary hyperaldosteronism (Conn's syndrome)

This disease was defined first by Conn in 1955, with a prevalence of 5–13%. This syndrome is characterized by an inappropriate increase in production of aldosterone which is relatively independent from the renin-angiotensin mechanism and is non-suppressible by sodium loading. This is one of the leading causes of secondary hypertension in hypertensive adults [32]. Patients with primary aldosteronism may exhibit adrenal cortical hyperplasia or adenoma in 30% of sporadic cases, and nearly 1% of sporadic cases may have adrenocortical carcinoma [33]. Clinically these patients present most commonly as normokalemic hypertension, and severe cases do show hypokalemia (**Table 2**).

S. no.	Tests	Procedure	Interpretation
1.	Postural testing	<ul style="list-style-type: none"> Performed after overnight recumbency IV catheter inserted at 7 AM (measure baseline aldosterone, cortisol, and PRA values at 8 AM) Ambulate the patient for 2 h Measure baseline aldosterone, cortisol, and PRA 	<ul style="list-style-type: none"> 30–50% of APAs respond to upright posture, and 20% of bilateral adrenal hyperplasia are unresponsive Diagnostic accuracy of 85%
2.	18-Hydroxycorticosterone level		<ul style="list-style-type: none"> Elevated (>100 ng/dL) in patients with APAs and is significantly lower in patients with IHA Diagnostic accuracy of 82% Hybrid steroid levels (18-OHF and 18-oxoF) are high (3–30 times normal) in FH-I, normal to mildly elevated in FH-II (3–4 times normal, as in sporadic PA), and mildly to extremely high in FH-III (3–100 times normal)
3.	Dexamethasone suppression test: used for patients with glucocorticoid-remediable aldosteronism (GRA) as well as for those patients who do not have GRA	<ul style="list-style-type: none"> 4-day dexamethasone suppression test (using a dosage of 0.5 mg every 6 h) Measure aldosterone, renin, and cortisol levels—before suppression testing, after 2 days and then after 4 days of testing Plasma cortisol suppression (i.e., <5 mcg/dL) is used as an index of the dexamethasone effect 	<ul style="list-style-type: none"> Patients without GRA: aldosterone levels typically fall by approximately 50% and return to the reference range by the end of testing Patients with GRA: persistent suppression of aldosterone levels to less than 4 ng/dL Sensitivity of 92% and a specificity of 100% for the diagnosis of GRA

S. no.	Tests	Procedure	Interpretation
4.	18-Oxocortisol and 18-hydroxycortisol (>100 nmol/day)		<ul style="list-style-type: none"> Markedly elevated level of GRA
5.	Adrenal venous sampling	<ul style="list-style-type: none"> Test to differentiate unilateral disease from bilateral disease in patients with PA ACTH may be infused into a peripheral vein (at a dosage of 50 mcg/h, starting 30 min before sampling) Can be performed with cosyntropin stimulation 	<ul style="list-style-type: none"> Calculate lateralization index (LI): Plasma aldosterone (PAC) and plasma cortisol concentration (PCC) in both adrenal veins is determined The ratio of the higher (dominant) over the lower (non-dominant) PAC/PCC ratio is used for the assessment of lateralization of aldosterone hypersecretion Cutoff values of 4 during cosyntropin stimulation and of 2 for unstimulated AVS—criteria to document lateralization of aldosterone excess

Source: [9, 10, 33, 34].

Table 2.
Investigations.

The aldosterone-to-renin ratio (ARR), a gold standard method to differentiate primary from secondary causes of hyperaldosteronism, is defined as the ratio of plasma aldosterone (expressed in ng/dL) to plasma renin activity (PRA, expressed in ng/mL/h). The cutoff value of ARR is 30 ng/dL per/mL per hour (or 750 pmol/L per ng/mL per hour). The principle behind this test is that as aldosterone secretion rises, PRA in ex vivo testing falls due to sodium retention. This negative feedback response should occur when the aldosterone levels are supraphysiologic for that individual patient, and PRA may fall well before plasma aldosterone is clearly increased. Primary aldosteronism is suspected if the ARR is >30 ng/dL per mL per hour. This method is also helpful in differentiating aldosterone-producing adenoma from bilateral adrenal hyperplasia [34].

4.1 Familial primary aldosteronism

Familial primary aldosteronism is mainly of three types, all of which are inherited in an autosomal dominant manner [8, 10, 32, 33]:

1. Familial hyperaldosteronism type I (glucocorticoid-remediable aldosteronism): accounts for less than 1% of cases. This disorder is caused by a recombination between the CYP11B2 and CYP11B1 genes.
2. Familial hyperaldosteronism type II: nearly 3–5% cases of primary aldosteronism belong to this category and are attributed to 7p22. This disorder still lacks a specific gene.

4.1.1 Gross features

Grossly, the adrenal gland in cases of idiopathic hyperaldosteronism is rather unremarkable or may exhibit slight enlargement. The enlargement could be due to the presence of micronodules or macronodules. Usually, adenomas are unilateral and solitary. However few cases of bilateral disease have also been reported. These adenomas

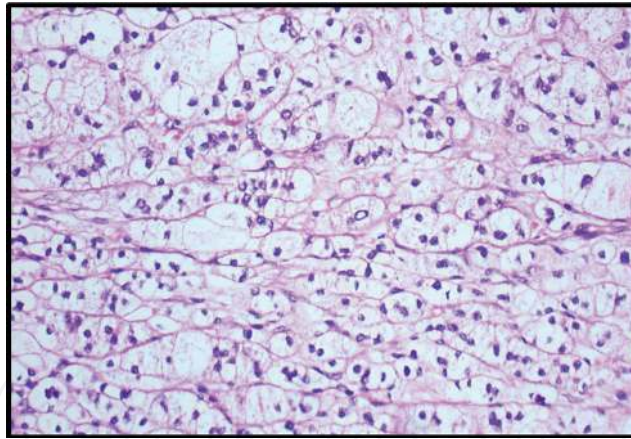


Figure 1. Section from a 22-year-old patient, presented with a 2 cm mass in the right adrenal gland. Histology reveals adenoma with clusters of cells with enlarged lipid-rich cytoplasm (hematoxylin and eosin stain, $\times 200$).

are mostly intra-adrenal and do not show a capsule. Few cases may reveal the presence of a true capsule or a pseudocapsule [2, 3, 35]. The cut surface of this tumor appears homogenous and golden yellow and is classically described as “canary yellow” [2]. Focal areas of hemorrhage or cystic changes can be present in few cases [35].

4.1.2 Microscopic features

Microscopically these adenomas appear encapsulated by compressed fibrous rim or fibrous “pseudocapsule.” The tumor cells are most commonly arranged in the form of nests or in alveolar pattern. Occasionally these cells may be arranged in short cords and trabeculae. Few cases may show mixed histological patterns. The tumor is composed of four different varieties of cells which may be present in varying proportions. More commonly seen are clear cells, having optically clear cytoplasm and centrally placed nuclei similar to those of the zona fasciculata cells; then there may be cells resembling to the zona glomerulosa or zona reticularis which appear small with compact eosinophilic cytoplasm. Then we have cells that are designated as “hybrid” cells. These hybrid cells have cytological features resembling both the zona fasciculata and glomerulosa (**Figure 1**). The uninvolved portion of adrenal cortex reveals atrophy. This atrophy is secondary to the negative feedback suppression effect of the hypothalamic–pituitary axis. Spironolactone bodies which appear as small, intracytoplasmic eosinophilic inclusions, round to oval, measuring 2–12 μm , are often encountered in adrenal cortical adenoma in patients on spironolactone treatment. These inclusions are delineated from the surrounding cytoplasm by a small, clear halo [2, 7, 9, 35].

5. Adrenal insufficiency

5.1. Introduction and definition

Adrenal insufficiency was first described by Thomas Addison in 1855 and was popularly known as Addison’s disease. This disorder can occur either due to failure of the adrenal gland or impairment of the hypothalamic–pituitary axis [36]. Clinically this syndrome is characterized by weakness, fatigue, anorexia, abdominal pain, weight loss, orthostatic hypotension, and salt craving. Characteristic hyperpigmentation is seen in patients with primary adrenal failure [37]. This disease has been reported in three forms [7, 9, 37]:

1. Primary disease also known as Addison's disease, a result of destruction of 90% or more of the adrenocortical gland or conditions that involve decreased production of adrenal steroids, resulting in subnormal synthesis of aldosterone, cortisol, and androgens.
2. Secondary and tertiary insufficiency occurs due to deficiency of secretion of corticotropin (ACTH) and corticotropin-releasing hormone (CRH), respectively.

Most of the cases (80–90%) of primary adrenal insufficiency are caused by autoimmune adrenalitis. Most of the cases fall under the autoimmune polyendocrinopathy syndrome (60%) [1, 2, 19, 32–34]. Cell-mediated immune mechanisms are implicated in pathogenesis. Various antibodies have been identified, antibodies against steroid 21-hydroxylase (85% cases) and autoantigens like steroid 17 α -hydroxylase and cholesterol side-chain cleavage enzyme. Other associations include cytotoxic T-lymphocyte antigen 4, protein tyrosine-phosphatase non-receptor type 22, and the MHC class II transactivator. Secondary adrenal insufficiency results from any process that involves the pituitary gland and interferes with corticotropin secretion. Tertiary adrenal insufficiency results from processes that involve the hypothalamus and interfere with secretion of corticotropin-releasing hormone, arginine vasopressin, or both. Suppression of the hypothalamic–pituitary–adrenal (HPA) axis by long-term administration of high doses of glucocorticoids is the most common cause [9, 36, 38].

5.2 Laboratory investigations

The patients of AI usually present with hyponatremia and hyperkalemia due to decreased aldosterone. Hypoglycemia also occurs due to cortisol. Decreased levels of this hormone also lead to an increase in lymphocytes and eosinophils, as a result of decreased immune-modulatory action of hydrocortisone. Measurement of baseline cortisol levels between 8:00 and 9:00 AM is the test used to diagnose AI. A serum cortisol level of value less than 5 $\mu\text{g/mL}$ favors diagnosis of AI. Stimulation test with cosyntropin which stimulates the cortex helps in differentiating primary and secondary AI. In this test 250 μg of cosyntropin is administered intramuscularly or intravenously, and serum cortisol is measured 30 min after infusion. Serum cortisol value of $\geq 18 \mu\text{g/dL}$ indicates a normal response. A cortisol peak $< 18 \mu\text{g/dL}$ confirms the diagnosis of AI. Serum cortisol level $\geq 100 \text{ pg/mL}$ confirms the diagnosis of Addison's syndrome. Serum cortisol value of $< 10 \text{ pg/mL}$ confirms diagnosis of secondary AI [35–39].

6. Adrenocortical carcinoma

6.1 Definition and introduction

ACC is a highly aggressive and a very rare malignancy. The incidence of this malignancy is approximately 0.72 per million cases per year according to the study by Surveillance, Epidemiology, and End Results (SEER) database [39]. The median age of diagnosis is usually fifth to sixth decade; however the German ACC Registry reports a median age at diagnosis of 46 years with a predilection for the female gender (female to male ratio: 1.5–2.5:1) [35, 38, 39].

Adrenocortical carcinomas (ACC) are rare tumors with an estimated annual incidence of 0.7–2 cases by year and a global prevalence of 4–12 cases per million with a 5-year survival rate inferior to 35% in most of the studies published.

6.2 Pathogenesis of adrenocortical carcinoma

Various mutations have been implicated in association with ACC. Most common are germ-line *TP53* mutations, associated with childhood ACCs. The adult population shows a prevalence of 3–7% of similar mutation. Childhood ACC can be found in association with Li-Fraumeni syndrome, Beckwith-Wiedemann syndrome, Lynch syndrome, and multiple endocrine neoplasia type 1. Of late an association with familial adenomatous polyposis (FAP), neurofibromatosis type 1, Werner syndrome, and Carney complex has also been postulated [39, 40].

6.2.1 Molecular mechanisms

In ACCs, chromosomal gains were frequently observed in regions 4q, 4p16, 5p15, 5q12–13, 5q32-qter, 9q34, 12q13, 12q24, and 19p, and chromosomal losses were observed at 1p, 2q, 11q 17p, 22p, and 22q. Microsatellite studies identified frequent allelic losses in regions 17p13, 11q15, and 2p16 (85%, 92%, and 90% of samples, respectively) [41–43].

Signaling pathways involved in adrenal malignant carcinogenesis [44–47]:

- p53 signaling pathway
- Wnt/beta-catenin signaling pathway
- Insulin growth factor II (IGF-II) locus

6.2.1.1 The *TP53* alterations

Protein p53, “guardian of genome,” is located at the 17p13 locus, and alterations in this gene have been noticed in various cancers including adrenocortical carcinoma, more so at the somatic level. p53 gene mediates cellular response to stress, and adult sporadic ACCs usually reveal loss of heterozygosity at this locus (nearly 85%) [48]. Stress leads to inhibition of degradation of p53 by E3 ubiquitin ligase MDM2, leading to inhibition of cell cycle arrest in response to DNA damage as well as apoptosis. These tumors tend to be larger and present at more advanced stage of tumor progression with shorter disease-free survival. Various genetic alterations have been reported in patients with adrenal cortex carcinoma like loss of *PTTG1* has been reported in nearly 84%, mutation in retinoblastoma protein (pRb) in nearly 27% cases and mutation in RB1 gene in 7% of the cases. Inactivating mutations or homozygous deletions of *CDKN2A* have also been reported in 11–16% cases. High-level amplifications of *CDK4* and *MDM2* were reported in 2–7% ACCs [49–51]. It is surprising to see that majority of the *TP53* mutations occur at the DNA-binding domain. Some tumors also have shown abnormalities in genes that encode for negative regulators of *TP53*, like *PTTG1* which encodes for securin, noted in 84% of ACC. It is considered as a marker of poor survival [44, 46, 49].

6.2.1.2 Wnt/beta-catenin signaling pathway

Wnt family consists of highly conserved growth factors having similar amino acid sequences and is responsible for various developmental and homeostatic processes [4, 44, 46–48, 51]. A prevalence of 39 and 84% has been reported by various authors on immunohistochemistry for β -catenin. The Wnt receptor is composed of members of the frizzled family and low-density lipoprotein receptor-related

protein. β -Catenin accumulates in the cytoplasm and gets translocated into the nucleus and then binds with Wnt receptor leading to inhibition of the axin-adenomatous polyposis coli—glycogen synthase kinase 3 β (GSK-3) complex. This blocks the phosphorylation of β -catenin, leading to increased accumulation of β -catenin in the cytoplasm which further translocates into the nucleus. Interaction between β -catenin with the T cell-specific transcription factor/lymphoid enhancer-binding factor-1 family of transcription factors occurs in the nucleus, thus regulating transcription of Wnt target genes. If Wnt stimulation of GSK-3 phosphorylating β -catenin does not occur, degradation by proteasomes occurs following ubiquitylation of this receptor. Wnt pathway has been implicated in patients with familial adenomatous polyposis and in the development of colorectal carcinomas as well as ACCs. Wnt/beta-catenin pathway can be activated in both benign and malignant tumors by *CTNNB1* mutations and by *ZNRF3* inactivation in adrenal cancer. *ZNRF3* is a recent gene that encodes a cell-surface transmembrane E3 ubiquitin ligase which acts as a negative feedback regulator of Wnt signaling. Recently, *ZNRF3* was found to be the most frequently altered gene in study cohorts of ACC investigated by integrated genomics, with a prevalence of 21 and 19% in studies by Assié et al. and Zheng et al., respectively [50, 51].

6.2.1.3 Insulin growth factor II (IGF-II)

Nearly 85–90% of the adult adrenocortical carcinomas are attributed to *IGF-II* overexpression. This molecular abnormality is associated with DNA demethylation at *IGF-II* locus in most of cases. Various transcriptome studies have confirmed that *IGF-II* is the most upregulated gene in ACC [52, 53].

6.2.2 Biochemistry

ACC are the tumors characterized by adrenocortical hormone production in nearly 45–70% of patients. Hypercortisolism is the most common presentation of patients presenting with hormone excess leading to a plethora of symptoms like diabetes mellitus, hypertension, hypokalemia, muscle weakness/atrophy, and osteoporosis [40–43]. Excess of androgens which comprise nearly 40–60% of hormone-secreting ACCs can cause rapid-onset male pattern baldness, hirsutism, virilization, and menstrual irregularities in women. Estrogen production occurs in 1–3% of male ACC patients, causing gynecomastia and testicular atrophy (through suppression of the gonadal axis). In the evaluation of adrenal tumors, regardless of size, androgen or estrogen production should always raise the suspicion of a malignant tumor [44].

6.2.3 Gross findings

ACCs are generally large tumors, measuring on average 10–13 cm. Only a minority of tumors are less than 6 cm (9–14%), with only 3% presenting as lesions less than 4 cm [2, 3, 6, 9, 35].

6.2.4 Microscopy findings

Microscopically these tumors have variable architectural patterns. The tumor cells are arranged in a trabecular, alveolar, or diffuse pattern. Occasionally mixed patterns are also noted. Some areas may also exhibit free-floating tumor cells forming balls [2, 3, 6, 9, 35] (**Figure 2A, B**).

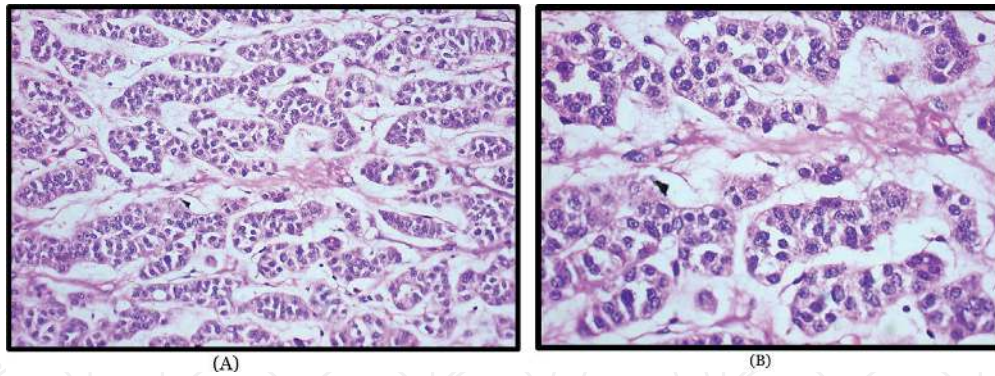


Figure 2.

(A) Section from a 45-year-old patient, presented with a 13 cm mass in the left adrenal gland. Histology reveals clusters of cells having anisocytosis and enlarged nuclei with prominent nucleoli. The fair number of darkly stained atypical mitosis is also evident (hematoxylin and eosin stain, $\times 200$). (B) Histology reveals clusters of cells having anisocytosis and enlarged nuclei with prominent nucleoli. The cells are separated by myxoid stroma. The fair number of darkly stained atypical mitosis is also evident (hematoxylin and eosin stain, $\times 400$).

Histologic criteria for malignancy in adrenal cortical tumors are assessed as follows [2, 3, 6, 9, 35, 43–45]:

1. High nuclear grade (grades III and IV according to the criteria of Fuhrman)
2. Mitotic rate > 5 per 50 HPF (10 HPF in each of the five areas that are most suspicious to be malignant)
3. Atypical mitotic figures (abnormal distribution of chromosomes or an excessive number of mitotic spindles)
4. Eosinophilic tumor cell cytoplasm ($>75\%$ of tumor cells or $<25\%$ clear vacuolated cells resembling the normal fasciculata)
5. Diffuse architecture ($>33\%$ of the tumor forming patternless sheets of cells)
6. Necrosis (occurring in confluent nests of cells)
7. Venous invasion (endothelial-lined vessel with smooth muscle as a component of the wall)
8. Sinusoidal invasion (endothelial-lined vessel in the adrenal with little supportive tissue)
9. Capsular invasion (nests or cords of tumor extended into or through the capsule with the corresponding stromal reaction)

Weiss et al. proposed a scoring system which was further modified and is widely accepted to report adrenal cortex carcinomas. These criteria include [35, 43–45, 54] (**Table 3**).

6.2.5 Interpretation

Adrenal cortical adenoma: total score < 3 .

Adrenal cortical carcinoma: total score ≥ 3 .

Thus if the modified Weiss score is ≥ 3 , then a diagnosis of adrenocortical carcinoma is given.

Criteria	Score	
	Absent	Present
Mitotic rate (≥ 6 mitotic figures/50 HPF)	0	1
Cytoplasm characteristics [clear vs. compact (compact >75% of cells)]	0	1
Abnormal mitoses	0	1
Tumor necrosis	0	1
Invasion of the capsule	0	1
<i>Overall score = 2 × mitotic rate + 2 × cytoplasm + abnormal mitoses + necrosis + capsular invasion.</i>		

Table 3.
 Weiss scoring for adrenocortical carcinoma.

Characteristics	Adrenocortical adenoma	Adrenocortical carcinoma
Macroscopy		
Weight	Usually less than 100 g	More than 100 g
Hemorrhage	+/-	+++
Necrosis	+/-	+++
Cystic degeneration	+/-	+++
IHC		
MIB-1	Negative	Positive
Vimentin	Negative	Positive
Inhibin	Positive	Positive
Melanin	Positive	Positive
Calretinin	Positive	Positive
BCL-2	Positive	Positive
C-kit	Negative	Positive
EMA	Negative	Negative
Cytokeratin	Negative	Negative
NSE	—	Positive
Synaptophysin	—	Positive
Chromogranin	—	Negative

Table 4.
 Differentiating features between adrenocortical adenoma and adrenocortical carcinoma.

However there are other features that may help in differentiating between adenomas and carcinoma. These are listed in **Table 4** [35, 43–45].

7. Conclusion

Adrenal glands have an essential role in maintaining the normal hemostasis. However the three layers of adrenal cortex, the zona glomerulosa, zona fasciculata, and zona reticularis, secrete essential hormones that are involved in fluid and electrolyte balance, regulating renin-angiotensin-aldosterone system, production of glucocorticoids, and synthesis of sex hormones. These hormones play an important

role in maintaining the normal homeostasis of the body. Various lesions in adrenal, benign as well as malignant, are known to cause disturbances in the internal milieu of our body. It is therefore essential to know the physiology as well as various types of disorders that can be encountered so as to define proper management of the patient. Also lesions of adrenal gland are attributed to various genetic abnormalities, knowledge of which can be implicated to study the pathogenesis and in applying this knowledge in prognosis as well as developing targeted therapy for these lesions.

IntechOpen

Author details

Lovelesh K. Nigam^{1*}, Aruna V. Vanikar^{1,2}, Rashmi D. Patel¹, Kamal V. Kanodia¹ and Kamlesh S. Suthar¹

1 Department of Pathology, Laboratory Medicine, Transfusion Services and Immunohematology, G.R. Doshi and K.M. Mehta Institute of Kidney Diseases and Research Centre and Dr. H.L. Trivedi Institute of Transplantation Sciences, Civil Hospital Campus, Asarwa, Ahmedabad, India

2 Department of Cell Therapy and Regenerative Medicine, Asarwa, Ahmedabad, India

*Address all correspondence to: drloveleshnigam@gmail.com

IntechOpen

© 2019 The Author(s). Licensee IntechOpen. This chapter is distributed under the terms of the Creative Commons Attribution License (<http://creativecommons.org/licenses/by/3.0>), which permits unrestricted use, distribution, and reproduction in any medium, provided the original work is properly cited. 

References

- [1] Tischler AS. Paraganglia. In: Mills SE, editor. *Histology for Pathologists*. 3rd ed. Philadelphia: Lippincott Williams & Wilkins; 2012. pp. 1277-1294
- [2] Zhang R, Lloyd RV. Chapter 2: The pathology of adrenal masses. In: Kebebew E, editor. *Management of Adrenal Masses in Children and Adults*. Cham: Springer; 2017. DOI: 10.1007/978-3-319-44136-8_2
- [3] Mangray S, De Lellis R. Adrenal glands. In: Mills SE, editor. *Sternberg's Diagnostic Surgical Pathology*. Philadelphia: Wolters Kluwer; 2015. pp. 585-646
- [4] Else T, Hammer GD, McPhee SJ. Chapter 21: Disorders of the adrenal cortex. In: *Pathophysiology of Disease: An Introduction to Clinical Medicine*. 7th ed. USA: McGraw Hill Education; 2014. pp. 593-624
- [5] Silverman ML, Lee AK. Anatomy and pathology of the adrenal glands. *The Urologic Clinics of North America*. 1989;**16**(3):417-432. PMID: 2665268
- [6] Hughes S, Lynn J. Chapter 37: Surgical anatomy and surgery of the adrenal glands. In: *Surgical Endocrinology*. Philadelphia: Elsevier Ltd; 1993. pp. 458-467. DOI: 10.1016/B978-0-7506-1390-.50042-8
- [7] Zynger DL. Chapter 10: Adrenal Primary Tumors and non-tumors. In: Epstein JI, editor. *Biopsy Interpretation of the Kidney and Adrenal Gland*. 1st ed. Philadelphia: Wolters Kluwer; 2016. pp. 173-186
- [8] Innes JA, Maxwell S. Chapter 10: Endocrine disease. In: *Davidson's Essentials of Medicine*. 23rd edition, Philadelphia: Elsevier; 2016. pp. 327-380
- [9] Rosai J. Chapter 16: Adrenal gland and other paraganglia. In: Rosai and Ackerman's *Surgical Pathology*. 10th ed. Vol. 2. Philadelphia: Elsevier; 2012. pp. 1057-1100
- [10] Arlt W. Disorders of the adrenal cortex. In: Kasper DL, Hauser SL, Jameson JL, Fauci AS, Longo DL, Loscalzo, editors. *Harrison's Principles of Internal Medicine*. 19th ed. Vol. 2. USA: McGraw Hill Education; 2015. pp. 2309-2330
- [11] Agrons MM, Jensen CT, Habra MA, Menias CO, Shaaban AM, Wagner-Bartak NA, et al. Adrenal cortical hyperplasia: Diagnostic workup, subtypes, imaging features and mimics. *The British Journal of Radiology*. 2017;**90**:20170330
- [12] MvNicol AM. Lesions of adrenal cortex. *Archives of Pathology & Laboratory Medicine*. 2008;**132**:1263-1269
- [13] Nieman L, Ilias I. Evaluation and treatment of Cushing's syndrome. *The American Journal of Medicine*. 2005;**118**:1340-1346.
- [14] Ejaz S, Vassilopoulou-Sellin R, Busaidy NL, Hu MI, Waguespack SG, Jimenez C, et al. Cushing syndrome secondary to ectopic adrenocorticotrophic hormone secretion. *Cancer*. 2011;**117**:4381-4389. DOI: 10.1002/cncr.26029
- [15] Chaudhary V, Bano S. Imaging of the pituitary: Recent advances. *Indian Journal of Endocrinology and Metabolism*. 2011;**15**(Suppl. 3):216-S223. DOI: 10.4103/2230-8210.84871
- [16] Lila AR, Sarathi V, Jagtap VS, Bandgar T, Menon P, Shah NS. Cushing's syndrome: Stepwise approach to diagnosis. *Indian Journal of Endocrinology and Metabolism*. 2011;**15**:317-321

- [17] Elamin MB, Murad MH, Mullan R, Erickson D, Harris K, Nadeem S. Accuracy of diagnostic tests for Cushing's syndrome a systematic review and meta-analyses. *The Journal of Clinical Endocrinology and Metabolism*. 2008;**93**:1553-1562
- [18] Al-Saadi N, Diederich S, Oelkers W. A very high dose dexamethasone suppression test for differential diagnosis of Cushing's syndrome. *Clinical Endocrinology*. 1998;**48**(1):45-51
- [19] Raff H, Sharma ST, Nieman LK. Physiological basis for the etiology, diagnosis, and treatment of adrenal disorders: Cushing's syndrome, adrenal insufficiency, and congenital adrenal hyperplasia. *Comprehensive Physiology*. 2014;**4**(2):739-769. DOI: 10.1002/cphy.c130035
- [20] Manipadam MT, Abraham R, Sen S, Simon A. Primary pigmented nodular adrenocortical disease. *Journal of Indian Association of Pediatric Surgeons*. 2011;**16**:160-162. DOI: 10.4103/0971-9261.86881
- [21] Pernick N. Cushing Syndrome. Available from: <http://www.pathologyoutlines.com/topic/adrenalcushings.html> [Accessed: 22 December 2018]
- [22] Katanić D, Kafka D, Živojinov M, Vlaški J, Budakov Z, Pogančev MK, et al. Primary pigmented nodular adrenocortical disease: Literature review and case report of a 6-year-old boy. *Journal of Pediatric Endocrinology & Metabolism*. 2017;**30**(5):603-609. DOI: 10.1515/jpem-2016-0249
- [23] Ngow HA, Khairin WM. Primary pigmented nodular adrenocortical disease. *Endokrynologia Polska (Polish Journal of Endocrinology)*. 2011;**62**(3):268-270
- [24] Bain J. Carney's complex. *Mayo Clinic Proceedings*. 1986;**61**:508. DOI: 10.1016/S0025-6196(12)61989-2
- [25] Swain JM, Grant CS, Schlinkert RT, Thompson GB, vanHeerden JA, Lloyd RV, et al. Corticotropin-independent macronodular adrenal hyperplasia. *Archives of Surgery*. 1998;**133**:541-546
- [26] New MI, Wilson RC. Steroid disorders in children: Congenital adrenal hyperplasia and apparent mineralocorticoid excess. *Proceedings of the National Academy of Sciences of the United States of America*. 1999;**96**:12790-12797. DOI: 10.1073/pnas.96.22.12790
- [27] Chung EM, Biko DM, Schroeder JW, Cube R, Conran RM. From the radiologic pathology archives: Precocious puberty: Radiologic-pathologic correlation. *RadioGraphics*. 2012;**32**:2071-2099. DOI: 10.1148/rg.327125146
- [28] Witchel SF. Congenital adrenal hyperplasia. *Journal of Pediatric and Adolescent Gynecology*. 2017;**30**(5):520-534
- [29] El Maouche D, Arlt W, Merke DP. Congenital adrenal hyperplasia. *The Lancet*. 2017;**390**(10108):2121-2241
- [30] Speiser PW, White PC. Congenital adrenal hyperplasia. *The New England Journal of Medicine*. 2003;**349**(8):776-788. PMID: 12930931
- [31] Åkerström G, Hellman P. Genetic syndromes associated with adrenal tumors. In: Linos D, van Heerden JA, editors. *Adrenal Glands*. Berlin, Heidelberg: Springer; 2005. DOI: 10.1007/3-540-26861-8_25
- [32] Mattson C, Young WF. Primary aldosteronism: Diagnostic and treatment strategies. *Nature Clinical Practice. Nephrology*. 2006;**2**(4):198-208

- [33] Ganguly A. Primary aldosteronism. *The New England Journal of Medicine*. 1998;**339**(25):1828-1834
- [34] Umakoshi H, Tsuiki M, Yokomoto Umakoshi M, Takeda Y, Kurihara I, et al. Correlation between lateralization index of adrenal venous sampling and standardized outcome in primary aldosteronism. *Journal of the Endocrine Society*. 2018;**2**(8):893-902. DOI: 10.1210/js.2018-00055
- [35] Lack EE, Wieneke J. Chapter 19: Tumors of the adrenal gland. In: Fletcher C, editor. *Diagnostic Histopathology of Tumors*. 4th ed. Vol. 2. Philadelphia: Elsevier Saunders; 2013. pp. 1294-1352
- [36] Fares AB, dos Santos RA. Conduct protocol in emergency: Acute adrenal insufficiency. *Revista da Associação Médica Brasileira*. 2016;**62**(8):728-734. DOI: 10.1590/1806-9282.62.08.728
- [37] Addison T. *On the Constitutional and Local Effects of Disease of the Supra-Renal Capsules*. London: Samuel Highley; 1855
- [38] Betterle C, Morlin L. Autoimmune Addison's disease. *Endocrine Development*. 2011;**20**:161-172
- [39] Reiff E, Duh QY, Clark OH, McMillan A. Extent of disease at presentation and outcome for adrenocortical carcinoma: Have we made progress? *World Journal of Surgery*. 2006;**30**:872-878
- [40] Lack EE. Tumors of the adrenal gland and extra-adrenal paraganglia. In: *Atlas of Tumor Pathology—3rd Series*. Washington, DC: Armed Forces Institute of Pathology; 1997. pp. 102-104
- [41] Aubert S, Wacrenier A, Leroy X, Devos P, Carnaille B, Proye C, et al. Weiss system revisited: A clinicopathologic and immunohistochemical study of 49 adrenocortical tumors. *The American Journal of Surgical Pathology*. 2002;**26**(12):1612-1619
- [42] Stojadinovic A, Brennan MF, Hoos A, Omeroglu A, Leung DNY, Dudas ME, et al. Adrenocortical adenoma and carcinoma: Histopathological and molecular comparative analysis. *Modern Pathology*. 2003;**16**(8):742-751. DOI: 10.1097/01.MP.0000081730.72305.81
- [43] Giordano TJ. Adrenocortical tumors: An integrated clinical, pathologic, and molecular approach at the University of Michigan. *Archives of Pathology & Laboratory Medicine*. 2010;**134**:1440-1443
- [44] Bonnet-Serrano F, Bertherat J. Genetics of tumors of the adrenal cortex. *Endocrine-Related Cancer*. 2018;**25**:131-152
- [45] Soon PSH, McDonald KL, Robinson BG, Sidhu SB. Molecular markers and the pathogenesis of adrenocortical cancer. *The Oncologist*. 2008;**13**:548-561
- [46] Lerario AM. Genetics and epigenetics of adrenocortical tumors. *Molecular and Cellular Endocrinology*. 2014;**386**:67-84. DOI: 10.1016/j.mce.2013.10.028
- [47] Else T, Kim AC, Sabolch A, Raymond VM, Kandathil A, Caoili EM, et al. Adrenocortical carcinoma. *Endocrine Reviews*. 2014;**35**(2):282-326
- [48] Gicquel C, Bertagna X, Gaston V, Coste J, Louvel A, Baudin E, et al. Molecular markers and long-term recurrences in a large cohort of patients with sporadic adrenocortical tumors. *Cancer Research*. 2001;**61**:6762-6767
- [49] Ragazzon B, Libé R, Assié G, Tissier F, Barreau O, Houdayer C, et al. Mass-array screening of frequent

mutations in cancers reveals RB1 alterations in aggressive adrenocortical carcinomas. *European Journal of Endocrinology*. 2014;**170**:385-391. DOI: 10.1530/EJE-13-0778

[50] Assié G, Letouzé E, Fassnacht M, Jouinot A, Luscap W, Barreau O, et al. Integrated genomic characterization of adrenocortical carcinoma. *Nature Genetics*. 2014;**46**:607-612. DOI: 10.1038/ng.2953

[51] Zheng S, Cherniack AD, Dewal N, Moffitt RA, Danilova L, Murray BA, et al. Comprehensive pan-genomic characterization of adrenocortical carcinoma. *Cancer Cell*. 2016;**29**:723-736. DOI: 10.1016/j.ccell.2016.04.002

[52] De Reyniès A, Assié G, Rickman DS, Tissier F, Groussin L, René-Corail F, et al. Gene expression profiling reveals a new classification of adrenocortical tumors and identifies molecular predictors of malignancy and survival. *Journal of Clinical Oncology*. 2009;**27**:1108-1115. DOI: 10.1200/JCO.2008.18.5678

[53] Else T. Association of adrenocortical carcinoma with familial cancer susceptibility syndromes. *Molecular and Cellular Endocrinology*. 2012;**351**(1):66-70. DOI: 10.1016/j.mce.2011.12.008

[54] Scarpellia M, Algabab F, Kirkalic Z, Poppeld HV. Handling and pathology reporting of adrenal gland specimens. *European Urology*. 2004;**45**:722-729