

# Journal of Veterinary Diagnostic Investigation

<http://vdi.sagepub.com/>

---

## Pathology of Experimentally Induced Chronic Selenosis (Alkali Disease) in Yearling Cattle

Donal O'Toole and Merl F. Raisbeck

*J VET Diagn Invest* 1995 7: 364

DOI: 10.1177/104063879500700312

The online version of this article can be found at:

<http://vdi.sagepub.com/content/7/3/364>

---

Published by:



<http://www.sagepublications.com>

On behalf of:



Official Publication of the American Association of Veterinary Laboratory Diagnosticians, Inc.

Additional services and information for *Journal of Veterinary Diagnostic Investigation* can be found at:

**Email Alerts:** <http://vdi.sagepub.com/cgi/alerts>

**Subscriptions:** <http://vdi.sagepub.com/subscriptions>

**Reprints:** <http://www.sagepub.com/journalsReprints.nav>

**Permissions:** <http://www.sagepub.com/journalsPermissions.nav>

**Citations:** <http://vdi.sagepub.com/content/7/3/364.refs.html>

>> [Version of Record](#) - Jul 1, 1995

[What is This?](#)

## Pathology of experimentally induced chronic selenosis (alkali disease) in yearling cattle

Donal O'Toole, Merl F. Raisbeck

**Abstract.** Prolonged oral exposure of cattle to elevated dietary selenium (Se) in forage and seleniferous plants in seleniferous areas of the western United States is associated historically with 2 clinical syndromes: alkali disease and "blind staggers." The potential for Se-induced disease in cattle and other species is considerable in areas with seleniferous shales, Se-accumulating plants, arid climates, and alkaline soils. These 2 Se-associated conditions were defined in the 1930s and 1940s, and the nosology of blind staggers is questionable. Seventeen yearling steers fed 0.15, 0.28, and 0.8 mg Se/kg body weight as selenomethionine or selenite for 120 days were euthanized and examined postmortem. Significant lesions were confined to 4 steers in the medium- and high-dose selenomethionine group and to 1 steer in the high-dose selenite group. Grossly, dystrophic hoof lesions developed in 2 steers, 1 of which had extensive separation of horn from lamellar and coronary epidermis and also lost hair from the tail switch. Histologically, tubules in the stratum medium of hooves from these 5 steers were replaced by islands of parakeratotic cellular debris, separated by more normal hoof matrix. Two of the 5 steers also had hyperplasia, acanthosis, parakeratosis, and disorganized germinal epithelium of varying severity in hoof epithelium, particularly at the tips of epidermal lamellae. These changes may distinguish the hoof lesions of chronic selenosis from those of chronic laminitis in cattle, in which dermal (chorial) changes predominate. In skin from the distal part of the tail of the animal that lost its switch, most follicles were atrophic and devoid of hairshafts and displayed dyskeratosis and mild superficial follicular keratosis. No significant lesions developed in tissues other than integument. Autometallographic staining for catalytic Se bonds in various tissues, including skin, liver, and kidney, revealed no positive staining of hair shafts; the correlation between stain intensity and dose group was poor. These findings indicate that dietary exposure for 4 months to 0.28 and 0.8 mg Se/kg in the form of selenomethionine and to 0.8 mg Se/kg in the form of sodium selenite reproduces in some cattle mild (subclinical) to severe (clinical) forms of alkali disease. No significant neurological, renal, or hepatic lesions developed, supporting the contention that blind staggers is caused by factors other than excessive dietary selenium.

Chronic poisoning by selenium was first described in range cattle in the 1930s and subsequent experimental studies in horses, cattle, and pigs confirmed that chronic selenosis resulted in characteristic changes in hooves and hair (alkali disease).<sup>3,11,33-35,39</sup> The National Academy of Sciences estimated the chronic, dietary no-effect level at 4 ppm.<sup>50</sup> Remarkably, although alkali disease ("the alkali," "bob tail disease") was recognized by homesteaders in arid parts of the American West at the turn of this century, there are no published histological descriptions of lesions in the integument. Other purported effects of selenium intoxication in cattle include neurological signs ("blind staggers"), possibly accompanied by nephrosis, hepatic fibrosis, and myocardial degeneration.<sup>3,4,11,44,45</sup> These latter effects, which are widely cited in contemporary texts of veterinary pathology,<sup>23</sup> toxicology,<sup>18,54,59</sup> and internal medicine,<sup>5,8</sup> were documented in two clini-

copathological studies published in 1935<sup>11</sup> and 1946.<sup>44</sup> Some recent reviews of selenium toxicosis question whether blind staggers is a distinct entity and challenge its association with selenosis.<sup>20,24,31,50,55,56</sup> Recent, widely circulated popular accounts of naturally induced selenosis describe heavy losses in livestock and native ruminants in the American West and draw heavily on these early clinicopathological studies.<sup>16</sup> At this laboratory, as in South Dakota (S. Zeman, personal communication), we do not currently identify selenosis as a significant problem in livestock or native ruminants or diagnose spontaneous cases of selenium-induced blind staggers in range cattle; alkali disease, chiefly affecting horses, continues to occur sporadically.<sup>42</sup> Acute selenosis due to oversupplementation occurs with some frequency in pigs (D. Zeman, personal communication). Much of the published experimental work on selenosis in herbivores is based on studies using inorganic forms of selenium, such as sodium selenate or sodium selenite,<sup>29,33,39</sup> whereas the predominant chemical form of selenium in forage is selenomethionine.<sup>59</sup> It was once proposed that the various clinicopathologic

From the Wyoming State Veterinary Laboratory, 1174 Snowy Range Road, Laramie, WY 82070.

Received for publication July 25, 1994.

syndromes of selenosis are determined by the predominant chemical form(s) of selenium in the diet: "alkali disease, produced by selenium in grains and grasses, and blind staggers, caused by selenium in indicator plants, are manifestations of the toxic effects of different selenocompounds present in plants" (p. 136).<sup>45</sup> This is one possible explanation for why blind staggers was not induced in earlier experimental studies.

We recently undertook an interdisciplinary study designed to establish whether prolonged exposure to selenomethionine induced a clinical syndrome and lesions distinct from those induced by selenite and to determine the sensitivity of yearling cattle to organic and inorganic forms of selenium. In this report, we describe the gross and histological lesions that developed in cattle from this study, following exposure to various levels of selenium in the diet for 4 months. Toxicological, clinicopathological, and immunological data from this study will be reported separately (M. F. Raisbeck et al., in preparation).

### Materials and methods

**Experimental animals and diets.** Nineteen Hereford steers and 1 Hereford-cross steer, all 9-11 mo old, were obtained locally. For 30 days before the start of the 120-day feeding study (June-September 1993), the steers were acclimated to finely chopped grass hay adequate in selenium. During the acclimation period, steers were vaccinated for common infectious diseases of yearling cattle,<sup>a,b</sup> fitted with insecticidal ear tags,<sup>c</sup> and treated with a broad-spectrum antiparasitic compound.<sup>d</sup> Animals were housed in groups of 4 in pens with concrete floors covered with wood chips and were assigned at random to either a control group or to 1 of 6 treatment groups of principals fed either sodium selenite<sup>e</sup> or selenomethionine<sup>f</sup> (Table 1). Individual doses (0.15, 0.28, and 0.8 mg Se/kg body weight [bw]) were prepared daily by absorbing aqueous Se of the appropriate form into 80 g ground corn cob, which was then thoroughly mixed by hand with the day's ration. Dosages were calculated to approximate exposure to 5, 10, and 25 ppm Se-containing forage under range conditions. Intake was monitored daily to ensure full consumption of the dose offered. A 1:1 mixture of Se-free sodium chloride and sodium polyphosphate was provided ad libitum. Steers were fed approximately 10 kg of grass hay (195-303 ppb Se) and 250 g of ground cotton seed meal daily. Each steer was fitted with a neck band and sensor key that controlled access to individual feed bunks with automatic gates.<sup>g</sup> Steers had access to water (< 5 ppb Se) from automatic waterers. One animal (no. 12) that was fed 0.8 mg Se/kg as selenomethionine refused feed after 11 days on the diet and for the remainder of the study (days 12-120) was dosed daily with selenomethionine by capsule. At day 96, animal no. 12 became lame and developed marked erythema of the periople, followed by dystrophic lesions of all hooves on day 106 and loss of the tailswitch on day 109. No lameness developed in the other 19 steers during the study.

**Pathology.** After 120 days on the feeding trial (May-Sep-

tember 1993), 19 steers were euthanized over a 4-day period using a combination of xylazine, electrocution, and axillary exsanguination. Animal no. 12 was euthanized 14 days after returning to the basal diet (i.e., after daily dosing with selenomethionine by capsule ceased). Gross lesions found at necropsy were noted. The weight of each whole carcass and, following trimming of excess fat and connective tissue, the weights of each of the following were recorded: liver, kidneys, spleen, thymus, pancreas, brain, adrenal glands, thyroids, pituitary, heart, left and right ventricular free walls, and septal myocardium. Samples from the following tissues were fixed in 10% neutral buffered formalin for light microscopic evaluation: salivary gland, tongue, esophagus, reticulum, rumen, omasum, abomasum, small bowel (3 levels), cecum, colon, liver, gallbladder, pancreas, lung (anterior, middle, and posterior lobes of the left lung), heart (right and left ventricles at the papillary muscles, and interventricular septum), thoracic aorta, kidneys, bladder, adrenal glands, thyroids, pituitary, thymus, spleen, lymph nodes (mesenteric and hepatic), bone marrow (femur), skin (3 sites: right lateral thorax, dorsal midline cervical area, proximal dorsal aspect of tail), hoof (medial digit of right forelimb), brain, spinal cord, 7 skeletal muscles (*Mm. biceps brachii, extensor carpi radialis, vastus lateralis, biceps femoris, tibialis cranialis, longissimus lumborum, psoas major*) and 4 peripheral nerves (*Nn. ulnaris, medianus, ischiadicus, fibularis*). Eyes were trimmed of extraocular tissue, fixed in Zenker's fixative-acetic acid, and cut in a vertical midsagittal plane through the optic papilla.

Following fixation in formalin, the following 11 levels of each brain and 7 transverse and longitudinal levels of spinal cord, including spinal nerve roots, were processed for histological examination: midsagittal level of cerebellum; septotemporal level of hippocampus; coronal levels of frontal, parietal, and occipital cortex; basal ganglia, thalamus, and midbrain; medulla oblongata at middle-posterior cerebellar peduncles, obex, and near the junction with C1; and spinal cord at C3, C6, T3, T7, T12, L1, and L4. Following fixation, hooves were cut initially on an electrical band saw, and 2 areas were sampled for histology using razor strips: through the junction of periople with coronary hoof at right angles to the periople (15- x 5- x 2-mm blocks) and through the junction of coronary with laminar hoof vertical to laminae<sup>12</sup> (5- x 5- x 2-mm blocks). Processed samples of hoof included dermis, epithelium, stratum lamellatum, stratum medium, and, in some, stratum tectorium;<sup>2</sup> no hoof ham softening agents were used. Additional samples taken from animal no. 12 included the sole of the hoof, axial and abaxial coronary hoof, axial and abaxial laminar hoof, and multiple blocks of skin from the distal 12 cm of the tail that were sectioned en face parallel to the surface (i.e., at right angles to the long axis of hair follicles). Estimates of the ratio of atrophic to nonatrophic follicles in skin from the tail of animal no. 12 were made by counting of  $\geq 300$  follicles in en face sections of skin sampled 3 cm (hairless) and 12 cm (haired) from the tail tip and sectioned at an approximately mid-follicular level in the dermis. Tissues were dehydrated, embedded in paraffin wax, sectioned at 5  $\mu$ m, and stained with hematoxylin and eosin (HE). Selected blocks were cut and stained by Gram's, periodic acid-Schiff, and von Kossa techniques.

**Table 1.** Lesions in tissues from cattle fed various levels of selenium.

Dose group (mg Se/kg bw)	Animal no.	Lesions*					
		Hoof		Cutaneous follicular atrophy, tail	Vacuolation, midbrain†	Wallerian degeneration, spinal cord‡	Perivascular peripheral endoneuritis‡
		Parakeratosis, stratum medium	Epithelial hyperplasia, laminae				
Control	1				1+	1+ (2/7)	
	2					1+ (1/7)	
	3					1+ (1/7)	1+ (2/4)
Selenomethionine (0.15)	4					1+ (1/7)	
	5						
	6					1+ (3/7)	
	7					1+ (2/7)	
	8						
Selenomethionine (0.28)	9	1+				1+ (2/7)	
	10					1+ (1/7)	
Selenomethionine (0.80)	11	1+					
	12§	3+	3+	3+			1+ (2/5)¶
	13	2+	2+				
Selenite (0.15)	14					1+ (1/7)	
	15				1+		
	16					1+ (2/7)	
Selenite (0.28)	17				1+	1+ (1/7)	
	18				1+		
Selenite (0.80)	19					1+ (1/7)	
	20	1+					

\* Lesion severity: 1+ = mild; 2+ = moderate; 3+ = severe.

† Vacuolation was either in neuropil of substantia nigra, associated with astroglial hypertrophy (nos. 15, 18), or intracytoplasmic in neurons of red nucleus (nos. 1, 17).

‡ Number in parenthesis is the number of sections with lesions/number of nerves or spinal levels examined.

§ Steer dosed orally by capsule on days 12-120.

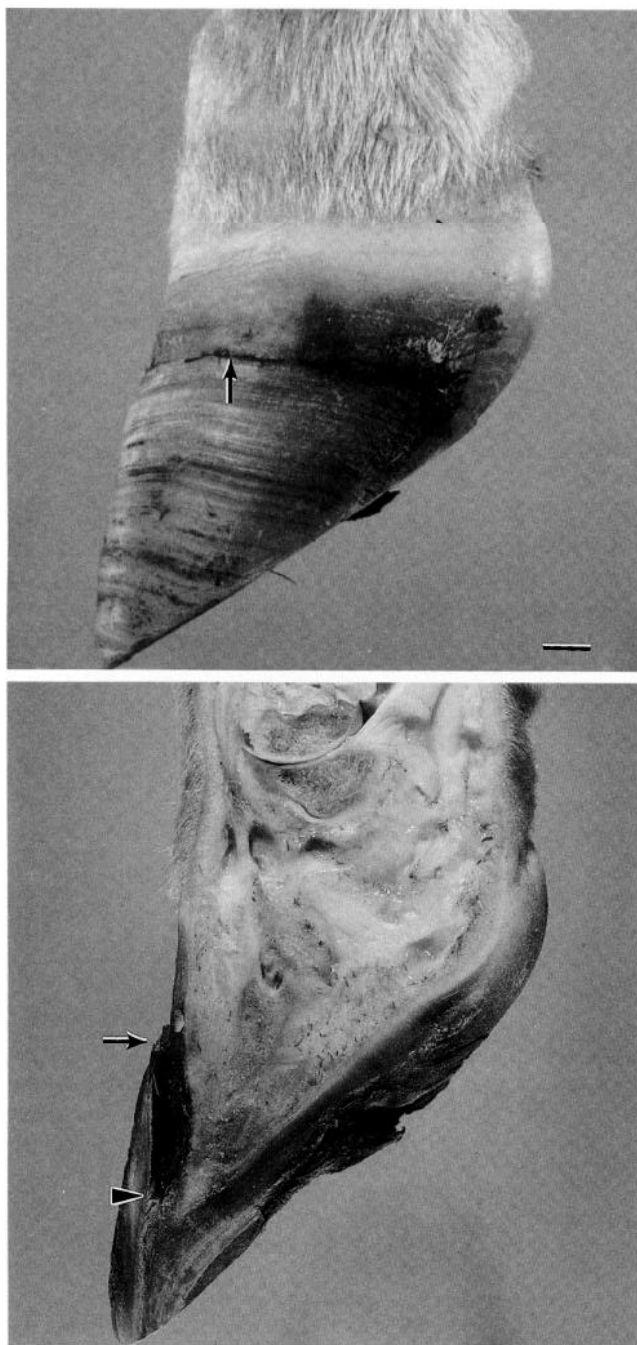
¶ Multiple small branches of autonomic nerves in ventricular myocardium also had histiocytic-lymphocytic endoneuritis.

Other mild incidental lesions found were interstitial pneumonia (no. 1), mineralization of tunica media of thoracic aorta (nos. 1, 2, 5, 12), multifocal encephalitis and/or myelitis (nos. 7, 10, 14, 17, 19), persisting hyaloid remnants (nos. 5, 9, 10, 14, 20), foreign body granulomas in soft palate (nos. 6, 17), oxalate aggregates in renal pelvic stroma (no. 4), parasitic abomasitis (no. 5), mineralization of germinal centers of lymph nodes (no. 6), fibropapilloma of right inferior eyelid (no. 8), focal pulmonary granuloma (no. 8), colonization of lingual stratum comeum by *Dermatophilus congolensis*-like organisms (no. 9), focal peripapillary retinal atrophy (no. 10), moderate cystic hyperplasia of gallbladder mucosal epithelium (no. 11), intraperitoneal fibrous adhesions (no. 13), focal granulomatous lymphadenitis (no. 14), bronchiolitis (no. 19), foreign body (hair shaft) abomasitis (no. 19), and moderate focal bursitis (no. 20). Most steers, including 1 or more controls, also had mild enteric coccidiosis (16/20 animals), mild superficial perivascular eosinophilic dermatitis (18/20), mild tonsillar cryptitis (12/20), and mild multifocal intraepithelial pustular rumenitis-omasitis-reticulitis (16/20).

To demonstrate catalytic selenium bonds,<sup>9</sup> fresh samples of myocardium (3 sites, as above), skin (3 sites, as above), liver, kidney, cervical and thoracic spinal cord intumescences (at C7 and L4), and frontal cortex were fixed in Camoy's solution, dehydrated in ascending concentrations of ethyl alcohol, embedded in paraffin wax, sectioned at 14 µm, stained in the dark with a physical developer composed of a mixture of silver lactate, hydroquinone, and gum arabic in a citrate buffer (Danscher's solution),<sup>9</sup> washed, and exposed to 5% thiosulfate. The intensity of the reaction was scored as follows: 0 = no staining; 1+ = weak; 2+ = moderate; 3+ = strong. Where multiple samples of a particular tissue were examined (heart, myocardium, spinal cord), the score for intensity was based on the sample of tissue that had the strongest reaction. Organ weights were normalized to brain weight prior to statistical analysis. Body and organ weights at necropsy were analyzed statistically by correlation and regression analysis<sup>h</sup> and considered significant at  $P \leq 0.05$ .

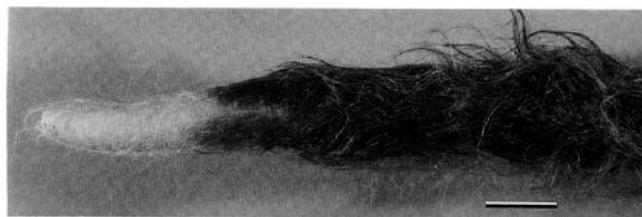## Results

Significant gross lesions were found in 2 animals, both in the high-dose selenomethionine group (nos. 12, 13). All hooves of steer no. 12 had a single deep semicircular crack in the dorsal axial and abaxial surface of the hoof wall 17 mm from the periople (Fig. 1a). In sagittal section, each crack extended obliquely close to the lamellar epidermis and resulted in extensive incomplete separation within the stratum medium (Fig. 1b). Similar, milder changes were present in hooves from steer no. 13 and comprised pronounced semicircular ridges and grooves parallel to the periople. The distal 6 cm of the tail from animal no. 12 were hairless (Fig. 2). No statistically significant differences between principal and control groups were found in the weights of organs.



**Figure 1.** Hoof from steer no. 12 fed 0.8 mg Se/kg bw as selenomethionine for 120 days. **a.** Note deep circumferential crack in horn of hoof wall (arrow). Bar = 1 cm. **b.** Sagittally sectioned digit showing oblique extension of crack to sensitive laminae (between arrow and arrowhead). The sole of the hoof is irregular and contains areas of splitting.

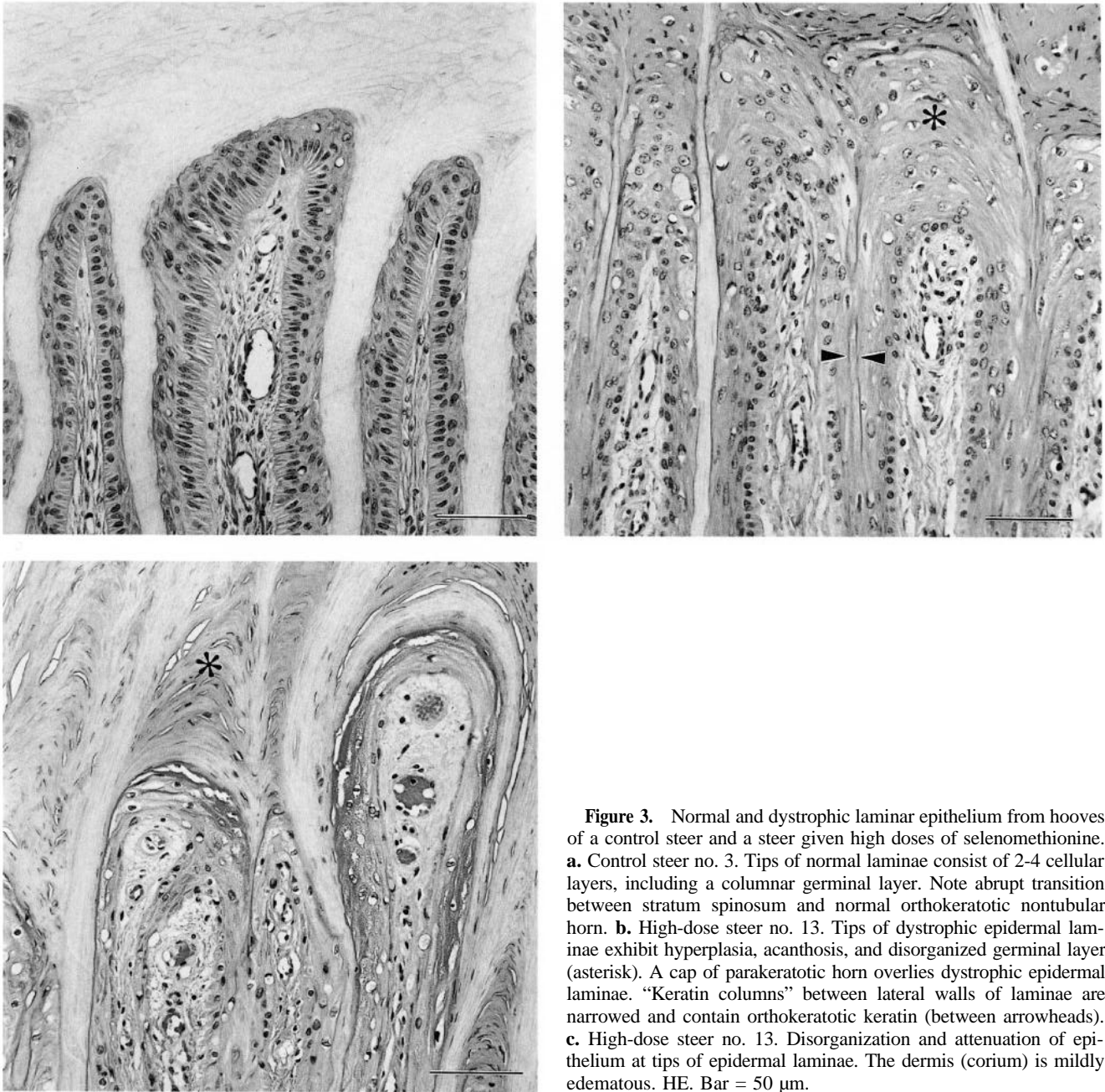
Histological lesions were present in the hooves of 5 steers (nos. 9, 11-13, 20) and in skin from 1 steer (no. 12) from 3 dose groups (Table 1). Lesions in hooves were most evident in laminar epithelium and were characterized by hyperplasia, acanthosis, and paraker-



**Figure 2.** Tail from steer no. 12 fed 0.8 mg Se/kg bw as selenomethionine for 120 days. The distal 6 cm of the tail is hairless. Bar = 2.5 cm.

atosis at the tips of laminae, with more diffuse change involving the lateral walls of laminae in animal no. 12. Where changes were marked, the germinal epithelium toward the laminar tips lost its normal columnar appearance and was disorganized and attenuated (Fig. 3). Similar, considerably milder multifocal lesions occurred in coronary epidermis covering the sides and tips of dermal papillae, resulting in displacement of dyskeratotic debris into the centers of recently formed, distended horn tubules (Fig. 4). Dermal stroma at tips of laminae was mildly edematous and contained a few unidentified pyknotic cells. Parakeratotic ridges of keratin were partly mineralized and were separated by relatively normal orthokeratotic keratin derived from the lateral walls of epidermal laminae (keratin columns)<sup>36</sup> (Fig. 3b). The stratum medium in 5 animals, which in control animals consisted of evenly spaced 15- $\mu$ m whorls of tubular horn separated by intertubular horn (Fig. 5a), contained oval to elliptical 75-250- $\mu$ m islands of cellular debris and parakeratotic keratinocytes (Fig. 5b). Some areas of coronary matrix of hoof from animal no. 12 contained bands of basophilic mineralized material near the junction of stratum lamellatum with stratum medium.

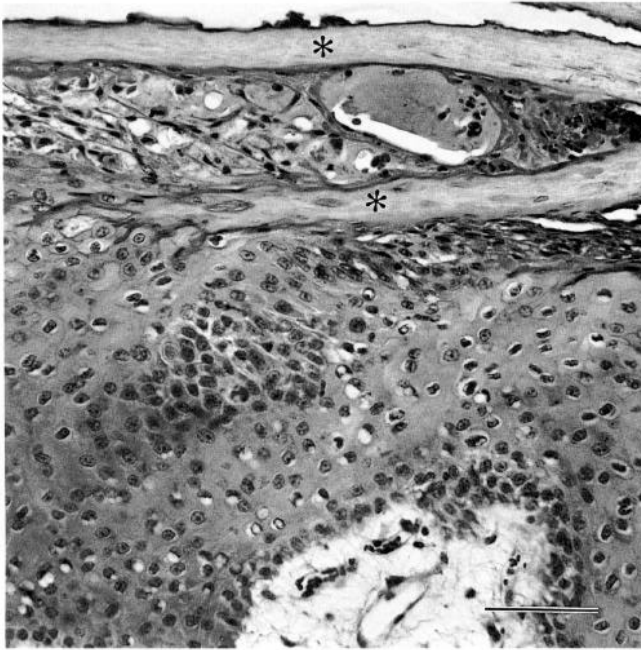
There was atrophy in a high proportion of primary (medullated, guard) hair follicles<sup>2</sup> in skin from the most distal 6 cm of the tail of animal no. 12. The ratio of atrophic to nonatrophic follicles (Fig. 6a) at this site was approximately 3:1, with transition to a ratio of  $\leq$  1:9 in more proximal, grossly haired sites (6-12 cm from the tip of the tail). Changes in follicles of secondary (nonmedullated, undercoat)<sup>2</sup> hairs were minimal in all sites examined. Most atrophic follicles were collapsed and lacked a hair shaft; the lumen was markedly reduced (Fig. 6b, 6c). Superficial follicular keratosis was common. The inner root sheath was poorly developed or absent, the outer root sheath contained poorly laminated and occasionally dyskeratotic keratinocytes, the glassy membrane was thickened and corrugated, and the perifollicular connective tissue sheath was expanded (Fig. 6b-d). Follicles that were less severely atrophic contained disproportionately small, ir-



**Figure 3.** Normal and dystrophic lamellar epithelium from hooves of a control steer and a steer given high doses of selenomethionine. **a.** Control steer no. 3. Tips of normal laminae consist of 2-4 cellular layers, including a columnar germinal layer. Note abrupt transition between stratum spinosum and normal orthokeratotic nontubular horn. **b.** High-dose steer no. 13. Tips of dystrophic epidermal laminae exhibit hyperplasia, acanthosis, and disorganized germinal layer (asterisk). A cap of parakeratotic horn overlies dystrophic epidermal laminae. "Keratin columns" between lateral walls of laminae are narrowed and contain orthokeratotic keratin (between arrowheads). **c.** High-dose steer no. 13. Disorganization and attenuation of epithelium at tips of epidermal laminae. The dermis (corium) is mildly edematous. HE. Bar = 50  $\mu$ m.

regular hair shafts. Some hair shafts had an abnormal internal structure. Mildly atrophic and remaining normal (nonatrophic) follicles were in the anagen stage of growth. The stage in the hair cycle was indeterminate in those follicles where atrophy was moderate or marked. Accessory follicular structures (arrector pili muscle, sebaceous and paratrighial glands), dermal components, and the superficial epidermis were unremarkable in all parts of skin from the tail of animal no. 12. Samples of skin from other sites on this animal and skin from all 3 sites including tail from the other 19 animals were unremarkable.

Other histological lesions in control and principal steers are summarized in Table 1. There was poor correlation between the intensity of autometallographic staining in particular tissues and dose groups. Eight of 17 principals and 0 of 3 controls had weak to strong staining of the internal root sheath and no staining of hair shafts. Autometallographic staining patterns in other tissues, which were essentially comparable for all groups including controls, comprised positive staining of some alpha motor neurons in spinal ventral horn and of periportal hepatocytes. Staining was absent in renal tissue and cerebral cortex.

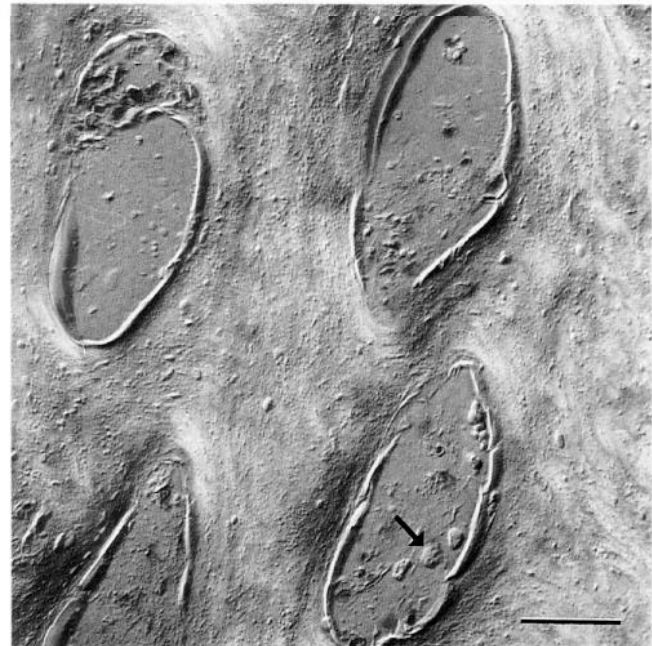


**Figure 4.** Dystrophic coronary epithelium from hoof of steer no. 12 given high doses of selenomethionine. Note formation of parakeratotic keratin overlying epithelium at tip of dermal papilla, flanked by orthokeratotic keratin (asterisks). HE. Bar = 50  $\mu$ m.

### Discussion

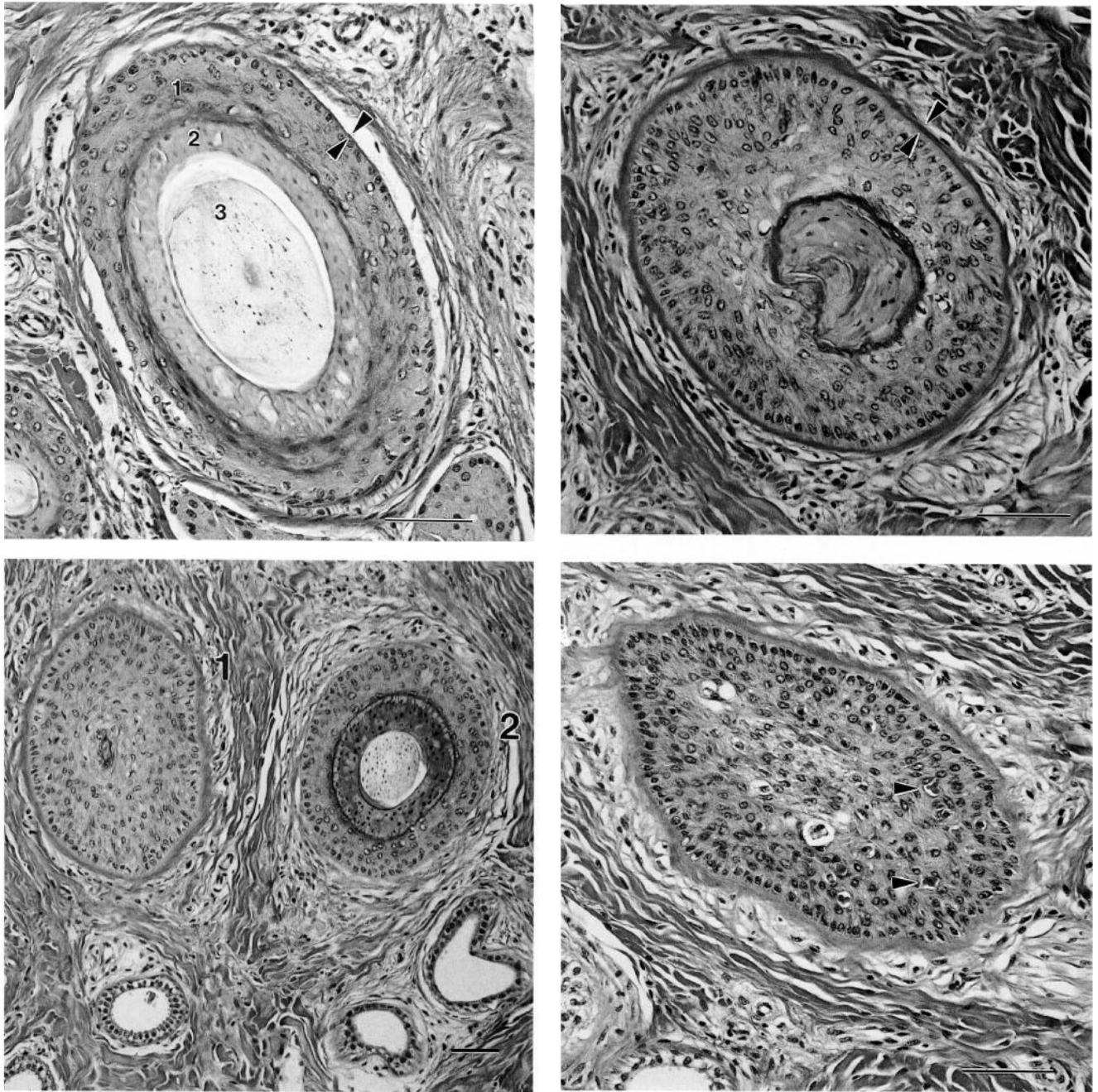
Significant lesions in the present study were confined to the integument, confirming earlier reports that characteristic changes in hooves and skin are the principal effect in cattle of prolonged exposure to abnormally elevated concentrations of dietary selenium ( $\geq 5$  ppm in diet).<sup>34,35,38,39,60</sup>

The distinctive histological changes that developed in hooves, particularly in stratum medium, may account for the dystrophic digital lesions in selenosis. These lesions were accompanied by mild to marked hyperplasia and parakeratosis in laminar epithelium and, to a lesser extent, in coronary epidermis and loss of the normal abrupt transition between stratum spinosum and stratum comeum. The predominance of epithelial changes in hooves may distinguish selenium-induced lesions from those of chronic laminitis in cattle, in which there are prominent dermal (corial) changes in addition to irregular hyperplasia of epidermal laminae.<sup>6,36,46,60</sup> Intradermal lesions that are typical of chronic bovine laminitis, such as granulation tissue, neovascularization, glomus-like vascular clusters, inflammation, thrombosis, and arteriosclerosis, were either minimal or absent. Weakening of the hoofs matrix in selenosis, resulting in dystrophic cracks and grooves, probably results from the formation of large, poorly keratinized spaces containing cellular debris in the stratum medium and consequential loss of regular



**Figure 5.** Normal and abnormal stratum medium from hooves of a control steer and a steer given high doses of selenomethionine. **a.** Control steer no. 3. Normal hoof. Regularly spaced concentric arrays of keratinocytes in tubular horn are separated by inter-tubular keratinocytes. **b.** High-dose steer no. 13. Dystrophic hoof. Islands of cellular debris, largely parakeratotic cells (arrowhead), are separated by essentially normal keratinocytes. Differential interference contrast optics/HE. Bar = 50  $\mu$ m.

arrays of tubular horn. Digital lesions were found in 5 steers, 4 of which were in the medium- or high-dose selenomethionine groups. Selenomethionine results in higher concentrations of selenium in most tissues than do sodium selenite and other inorganic forms of selenium;<sup>15,59</sup> the steer with the most severe digital lesions



**Figure 6.** Cross-sections of normal and atrophic primary hair follicles from distal part of tail of steer no. 12. **a.** Normal hair follicle. Note thin glassy membrane (between arrowheads), outer (1) and inner (2) root sheath, and medullated hair shaft (3). **b.** Atrophic hair follicle. The glassy membrane is thickened (between arrowheads). The lumen of the follicle is devoid of a hair shaft and is plugged by parakeratotic material. **c.** Atrophic hair follicle (1) adjacent to normal hair follicle that contains a hair shaft and inner root sheath, and thickened outer root sheath. **d.** Atrophic hair follicle. Note dyskeratotic cells (arrowheads). HE. Bar = 50  $\mu$ m.

also had higher concentrations of selenium<sup>17</sup> in hair, liver, and kidney than did the other 19 animals on the study (M. F. Raisbeck, in preparation). These results indicate that for a given dose of selenium, selenomethionine is more likely to cause alkali disease than is sodium selenite.

Histological lesions in hair follicles – follicular atrophy, loss of hair shafts, follicular keratosis, and col-

lapsed hair follicles- were found in 1 animal and were confined to the distal part of the tail. The reduced size of the inner root sheath suggests that, as in the hoof, chronic selenosis may induce defective terminal maturation of keratinocytes.

Epithelium from hair follicles and hooves is similar, particularly in the relative proportions of low-sulfur keratin polypeptides, high- and ultrahigh-sulfur pro-



teins, and high-glycine/tyrosine proteins.<sup>1,7,25,28,30,37,41</sup> High-sulfur proteins of hair, which are poorly characterized because of methodological difficulties, probably form the amorphous interfibrillar matrix that separates ordered filaments of keratin, including the 5 major 'hard' keratin polypeptides of human hair and nail.<sup>37</sup> Given the chemical similarities of selenium and sulfur, it seems reasonable that the epithelial lesions of alkali disease ultimately result from substitution of selenium for sulfur in the cysteine residues of high-sulfur proteins, with concomitant weakening of disulfide cross-linking.<sup>43,60</sup> Confirmation of this suggestion requires immunocytochemical, ultrastructural, and electrophoretic studies that compare normal with dystrophic hooves from herbivores with natural or experimentally induced chronic selenosis.

The Danscher technique for identifying catalytic selenium bonds was not helpful for comparing the cellular and subcellular distribution of selenium in the various dose groups. The autometallographic technique was used to localize selenium in various tissues from rats<sup>52,53</sup> and sheep<sup>47,48</sup> following acute intoxication. Recent studies indicate that the technique is specific for 1 chemical form of selenium (zinc selenide).<sup>10</sup> This specificity may account for the poor correlation between the intensity of staining and the dose group, particularly in kidney and hair shafts, which can accumulate high concentrations of selenium.<sup>59</sup> There was also a poor correlation between the intensity of Danscher staining and selenium concentration in various tissues (M. F. Raisbeck, in preparation). These results agree with those of an earlier study in rats<sup>40</sup> that autometallography is an unreliable index of the concentration of selenium in chronic and subchronic toxicity studies. Other techniques that permit reliable *in situ* identification of metalloids in tissue sections, such as energy dispersive X-ray analysis,<sup>49</sup> are required to define cellular and subcellular distribution of selenium in herbivores with chronic selenosis.

One objective the present study was to establish whether lesions other than the characteristic cutaneous and digital changes of alkali disease resulted from prolonged exposure to various levels of selenomethionine and sodium selenite, particularly in the heart, kidney, liver, and central nervous system. Acute intoxication with selenium results in myocardial necrosis in sheep,<sup>29</sup> and there are poorly documented, anecdotal reports of myocardial disease in cattle with chronic selenosis ("dishrag heart"). In a preliminary single-animal study, heart failure due to disseminated myocardial necrosis developed in a 16-month-old pregnant heifer fed 1 mg Se/kg bw as sodium selenite for 81 days; histological lesions were also present in digital lamellae and stratum medium of hooves (D. O'Toole and M. F. Raisbeck, unpublished observations). There was no evi-

dence of myocardial disease in steers in the present study. We are uncertain of the significance of multifocal neuritis in many branches of autonomic nerves in myocardial atria from the 1 steer that developed marked digital lesions.

Blind staggers was attributed to chronic selenosis in 2 early reports<sup>11,44</sup> that are widely and uncritically paraphrased in current reviews of selenosis.<sup>5,8,13,18,23,54,59</sup> None of the steers in this study developed any of the numerous lesions associated with selenosis in cattle, such as cirrhosis, ascites, myloid degeneration<sup>4</sup> and extensive edema<sup>29</sup> of "certain areas of the brain," atrophy of the pituitary, adrenal glands, and heart, splenic atrophy or enlargement, opaque tumorous masses of the cornea, scleral hemorrhages, renal congestion, degeneration of proximal convoluted tubules of the renal medulla, glomerulonephritis, hydronephrosis, fat deposition at the apex of the heart, hemorrhagic pancreatitis, desquamated epithelium in abomasum and small intestine, and enlarged edematous lymph nodes.<sup>3,11,44,45</sup> Various mild lesions were found in the central nervous system of many steers in this study and were interpreted as incidental findings. Intracytoplasmic neuronal vacuolation in the red nucleus is a common incidental finding in cattle.<sup>24,57,58</sup> Mild bilaterally symmetrical vacuolation in the neuropil of substantia nigra was reported recently from Great Britain in the brains of cattle that had clinical signs suggestive of bovine spongiform encephalopathy (BSE) but lacked the typical histological lesion profile of BSE;<sup>21</sup> the cause and significance of this lesion in the present study was not established. Widely scattered Wallerian degeneration was found in white matter of the spinal cord in both control and principal animals and was probably an age-related change. Various other mild lesions found in some control and principal animals in the study were considered to be incidental changes.<sup>19,26,27,32,51</sup>

Selenium-induced blind staggers remains to be reproduced experimentally. Original reports of this condition, which was recognized only by researchers at the University of Wyoming's Agriculture Experiment Station between 1934 and 1955, probably reflected a variety of diseases, including polioencephalomalacia,<sup>14,20,22</sup> pyrrolizidine and indolizidine alkaloid poisoning,<sup>20,55</sup> malignant catarrhal fever, and starvation, as well as histological misinterpretation of autolysis. Neither original published account of blind staggers described histological lesions in the brain, probably because the brains of affected cattle were not examined microscopically. It is difficult to directly disprove the original hypothesis that blind staggers was caused by ingestion of native seleniferous plants. Properly controlled intoxication studies using native seleniferous plants are impractical because of the large number of

candidate plant species, the variety of selenium compounds they contain at different stages of growth, their unpalatability, and the concurrent presence of other toxic constituents such as indolizidine alkaloids. Blind staggers does not appear to be a discrete nosological entity and has no proven association with selenosis.

### Acknowledgements

This study was funded by the Abandoned Coal Mine Land Research Program and the University of Wyoming's Agricultural Experiment Station. We thank Val Welch for technical help, Tami Browning for secretarial assistance, and Roger Siemion, Debbie Sanchez, Hank Edwards, Cody Molle, and Larry Castle for necropsy support. We are grateful to Dr. Lynn Woodard for advice and support.

### Sources and manufacturers

- a. Bar-Vac<sup>®</sup> 7/Somnus, Anchor Division, Boehringer Ingelheim Animal Health, St. Joseph, MO.
- b. Horizon<sup>®</sup> 4, Miles, Agricultural Division, Animal Health Products, Shawnee, KS.
- c. Guard Star Tags, V-Text, Cody, WY.
- d. Ivomec<sup>®</sup> 1% injection for cattle, Merck Agvet Division, Merck & Co., Rahway, NJ.
- e. Sigma Chemical Co., St. Louis, MO.
- f. Calbiochem Bulk Chemicals, La Jolla, CA.
- g. Calan Broadbent Feeding System, American Calan, Northwood, NH.
- h. Statistical Analysis Systems, SAS Institute, Cary, NC.

### References

1. Baden HP, Kubilus J: 1983, Fibrous proteins of bovine hoof. *J Invest Dermatol* 81:220-224.
2. Banks WJ: 1986, Applied veterinary histology, 2nd ed., pp. 365-371. Williams & Wilkins, Baltimore, MD.
3. Beath OA: 1982, The story of selenium in Wyoming. Bulletin no. 774. Agricultural Experiment Station, University of Wyoming, Laramie, WY.
4. Beath OA, Gilbert CS, Eppson HF, Rosenfeld I: 1953, Poisonous plants and livestock poisoning. Bulletin no. 324. Agricultural Experiment Station, University of Wyoming, Laramie, WY.
5. Blood DC, Radostits OM: 1989, Selenium poisoning. *In: Veterinary medicine. A textbook of the diseases of cattle, sheep, pigs and horses*, 7th ed., pp. 1254-125. Lea & Febiger, Philadelphia, PA.
6. Boosman R: 1990, The influence of calving and puerperium on clinical and histopathologic changes associated with laminitis and sole ulceration in a group of first-calving cows. *J Vet Med A* 37:513-519.
7. Chapman RE: 1984, Hoof, wool, quill, nail, claw, hoof, and horn. *In: Biology of the integument. 2. Vertebrates*, ed. Bereiter-Hahn J, Matoltsy AG, Richards KS, pp. 292-317. Springer-Verlag, Berlin, Germany.
8. Coyne CP, Oehme FW: 1990, Naturally occurring toxins. *In: Large animal internal medicine. Diseases of horses, cattle, sheep and goats*, ed. Smith BP, pp. 1653-1655, CV Mosby Co., St. Louis, MO.
9. Danscher G: 1982, Exogenous selenium in the brain. A histochemical technique for light and electron microscopical localization of catalytic selenium bonds. *Histochemistry* 76:281-293.
10. Danscher G, Montagnese C: 1994, Autometallographic localization of synaptic vesicular zinc and lysosomal gold, silver, and mercury. *J Histotechnol* 17:15-22.
11. Draize JH, Beath OA: 1935, Observations on the pathology of blind staggers and alkali disease. *J Am Vet Med Assoc* 39:753-763.
12. Dyce KM, Sack WO, Wensing CJG: 1987, Textbook of veterinary anatomy, pp. 707-710. WB Saunders Co., Philadelphia, PA.
13. Edmondson AJ, Norman BB, Suther D: 1993, Survey of state veterinarians and state veterinary diagnostic laboratories for selenium deficiency and toxicosis in animals. *J Am Vet Med Assoc* 202:865-872.
14. Gould DH, McAllister MM, Savage JC, Hamar DW: 1991, High sulfide concentrations in rumen fluid associated with nutritionally induced polioencephalomalacia in calves. *Am J Vet Res* 52:1164-1169.
15. Gronbaek H, Thorlacius-Ussing O: 1992, Selenium in the central nervous system of rats exposed to 75-Se L-selenomethionine and sodium selenite. *Biol Trace Elem Res* 35:119-127.
16. Harris T: 1991, Death in the marsh, pp. 125-147. Island Press, Washington, DC.
17. Helrich K: 1990, Selenium in food. Fluorometric method. *In: Official methods of analysis of the AOAC. Agricultural chemicals; contaminants; drugs*, 15th ed., vol. 1, pp. 269-270. Association of Official Analytical Chemists, Arlington, VA.
18. Humphreys DJ: 1988, Selenium. *In: Veterinary toxicology*, 3rd ed., pp. 69-71. Baillière Tindall, London, UK.
19. Imaizumi K, Nakamura T, Kiryu K, et al.: 1989, Morphological changes of the aorta and pulmonary artery in thoroughbred racehorses. *J Comp Pathol* 101:1-9.
20. James LF, Panter KE, Molyneux RI: 1992, Selenium poisoning in livestock. *In: Poisonous plants. Proceedings of the third international symposium*, ed. James LF, Keeler RF, Bailey EM, pp. 153-158. Iowa State University Press, Ames, IA.
21. Jeffrey M: 1992, A neuropathological survey of brains submitted under the Bovine Spongiform Encephalopathy Orders in Scotland. *Vet Rec* 131:332-337.
22. Jensen R, Griner LA, Adams OR: 1956, Polioencephalomalacia of cattle and sheep. *J Am Vet Med Assoc* 129:311-320.
23. Jones TC, Hunt RD: 1983, Diseases due to extraneous poisons. *In: Veterinary pathology*, pp. 952-955. Lea & Febiger, Philadelphia, PA.
24. Jubb KVF, Huxtable CR: 1993, The nervous system. *In: Pathology of domestic animals*, ed. Jubb KVF, Kennedy PC, Palmer N, 4th ed., vol. 1, pp. 296, 339, Academic Press, San Diego, CA.
25. Kitahara T, Ogawa H: 1993, Coexpression of keratins characteristic of skin and hair differentiation in nail cells. *J Invest Dermatol* 100:171-175.
26. Ladds PW: 1986, A color atlas of lymph node pathology in cattle, p. 33. PW Ladds, Townsville, Queensland, Australia.
27. Lie JT, Juergens JL: 1980, Degenerative arterial diseases other than atherosclerosis. *In: Peripheral vascular diseases*, ed. Juergens JL, Spittell JA, Fairbairn JF, 5th ed., pp. 238-240. WB Saunders Co., Philadelphia PA.
28. Lynch MH, O'Guin WM, Hardy C, et al.: 1986, Acidic and basic hair/nail ("hard") keratins: their colocalization in upper cortical and cuticle cells of the human hair follicle and their relationship to "soft" keratins. *J Cell Biol* 103:2593-2606.
29. Maag DD, Glenn MW: 1967, Toxicity of selenium: farm animals. *In: Selenium in biomedicine*, ed. Muth OH, pp. 127-140. AVI, Westport, CT.
30. Marshall RC, Frenkel MJ, Gillespie JM: 1977, High-sulphur proteins in mammalian keratins: a possible aid in classification. *Aust J Zool* 25:121-132.

31. Mayland HF, James LF, Panter KE, Sonderegger JL: 1989, Selenium in seleniferous environments. *In: Selenium in agriculture and the environment*, ed. Jacobs LW, pp. 15-50. Soil Science Society of America and American Society of Agronomy, Madison, WI.
32. Miller TR, Gelatt KN: 1991, Food animal ophthalmology. *In: Veterinary ophthalmology*, ed. Gelatt KN, 2nd ed., pp. 642-643. Lea & Febiger, Philadelphia, PA.
33. Miller WT, Williams KT: 1940, Effect of feeding repeated small doses of selenium as sodium selenite to equines. *J Agric Res* 61:353-369.
34. Moxon AL: 1937, Alkali disease or selenium poisoning. *SD Agric Exp Stn Bull* 311:1-91.
35. Moxon AL, Rhian MA, Anderson HD, Olson OE: 1944, Growth of steers on seleniferous range. *J Anim Sci* 3:299-309.
36. Nilsson SA: 1963, Clinical, morphological, and experimental studies of laminitis in cattle. *Acta Vet Scand* 4(suppl 1):1-304.
37. O'Guin WM, Dhouailly D, Manabe M, Sun TT: 1989, Specific keratins and their associated proteins as markers for hair follicle differentiation. *In: The biology of wool and hair*, ed. Rogers GE, Reis PJ, Ward KA, Marshall RC, pp. 37-50. Chapman and Hall, London, UK.
38. Olson OE: 1978, Selenium in plants as a cause of livestock poisoning. *In: Effects of poisonous plants on livestock*, ed. Keeler RF, Van Kampen KR, James LF, pp. 121-133. Academic Press, New York, NY.
39. Olson OE, Embry LB: 1973, Chronic selenite toxicity in cattle. *Proc SD Acad Sci* 52:50-58.
40. O'Toole D, Castle LE, Raisbeck MF: 1995, Comparison of histochemical autometallography (Danscher stain) to chemical analysis for detection of selenium in tissue. *J Vet Diagn Invest* 7:281-284.
41. Powell BC, Rogers GE: 1984, Hair keratin: composition, structure and biogenesis. *In: Biology of the integument. 2. Vertebrates*, ed. Bereiter-Hahn J, Matoltsy AG, Richards KS, pp. 695-721. Springer-Verlag, Berlin, Germany.
42. Raisbeck MF, Dahl ER, Sanchez DA, et al.: 1993, Naturally occurring selenosis in Wyoming. *J Vet Diagn Invest* 5:84-87.
43. Raisbeck MF, O'Toole DT, Belden EL, et al.: 1993, Selenium or sulfur? A comparison of toxic effects in mammals on western rangelands. *In: Planning, rehabilitation and treatment of disturbed lands*, 6th Billings Symposium, vol. 1, pp. 139-151. Reclamation Research Unit Publ. No. 9301, Billings, MT.
44. Rosenfeld I, Beath OA: 1946, Pathology of selenium poisoning. Bulletin no. 275. Agricultural Experiment Station, University of Wyoming, Laramie, WY.
45. Rosenfeld I, Beath OA: 1964, Selenium. *Geobotany, biochemistry, toxicity, and nutrition*, pp. 141-226. Academic Press, New York, NY.
46. Singh SS, Murray RD, Ward WR: 1992, Histopathological and morphometric studies on the hooves of dairy and beef cattle in relation to overgrown sole and laminitis. *J Comp Pathol* 107:319-328.
47. Smyth JBA, Wang JH, Barlow RM, et al.: 1990, Experimental acute selenium intoxication in lambs. *J Comp Pathol* 102:197-209.
48. Smyth JBA, Wang JH, Barlow RM, et al.: 1990, Effect of concurrent oral administration of monensin on the toxicity of increasing doses of selenium in lambs. *J Comp Pathol* 102:443-455.
49. Spycher MA, Vogt P, Wessicken R: 1991, In situ identification of toxic particles in human tissues. *Prog Histochem Cytochem* 23:372-382.
50. Subcommittee on Mineral Toxicity in Animals: 1980, Selenium. *In: Mineral tolerance of domestic animals*, pp. 392-420. National Academy Press, Washington, DC.
51. Tanimoto T, Ohtsuki Y, Nomura Y: 1994, Rumenoabomasal lesions in steers induced by naturally ingested hair. *Vet Pathol* 31:280-282.
52. Thorlacius-Ussing O, Danscher G: 1985, Selenium in the anterior pituitary of rats exposed to sodium selenite: light and electron microscopic localization. *Toxicol Appl Pharmacol* 81:67-74.
53. Thorlacius-Ussing O, Rasmussen BL: 1986, Light and electron microscopical visualization of selenium in adrenal glands from rats exposed to sodium selenite. *Exp Mol Pathol* 45:59-67.
54. Van Gelder GA: 1976, Selenium. *In: Clinical and diagnostic veterinary toxicology*, 2nd ed., pp. 345-354. Kendall-Hunt, Dubuque, IA.
55. Van Kampen CR, James LF: 1978, Manifestations of intoxication by selenium-accumulating plants. *In: Effects of poisonous plants on livestock*, ed. Keeler RF, Van Kampen KR, James LF, pp. 135-138. Academic Press, New York, NY.
56. Van Vleet JF, Ferrans VJ: 1992, Etiologic factors and pathologic alterations in selenium-vitamin E deficiency and excess in animals and humans. *Biol Trace Elem Res* 33:1-21.
57. Wells GAH, McGill IS: 1992, Recently described scrapie-like encephalopathies of animals: case definitions. *Res Vet Sci* 53:1-10.
58. Wells GAH, Scott AC, Johnson CT, et al.: 1987, A novel progressive spongiform encephalopathy in cattle. *Vet Rec* 121:419-420.
59. Whanger PD: 1989, Seleno compounds in plants and their effects on animals. *In: Toxicants of plant origin*, vol. 3. Proteins and amino acids, ed. Cheeke PR, pp. 141-167. CRC Press, Boca Raton, FL.
60. Yager, JA, Scott DW: 1993, The skin and appendages. *In: Pathology of domestic animals*, ed. Jubb KVF, Kennedy PC, Palmer N, 4th ed., vol. 1, pp. 587-589, 698-699. Academic Press, San Diego, CA.