

CRITICAL REVIEW

Pediatric Brain Development in Down Syndrome: A Field in Its Infancy



INS is approved by the American Psychological Association to sponsor Continuing Education for psychologists. INS maintains responsibility for this program and its content.

Taralee Hamner, Manisha D. Udhmani, Karol Z. Osipowicz, AND Nancy Raitano Lee

Department of Psychology, Drexel University, Philadelphia, Pennsylvania

(RECEIVED December 4, 2017; FINAL REVISION February 6, 2018; ACCEPTED March 3, 2018; FIRST PUBLISHED ONLINE May 23, 2018)

Abstract

Objectives: As surprisingly little is known about the developing brain studied *in vivo* in youth with Down syndrome (DS), the current review summarizes the small DS pediatric structural neuroimaging literature and begins to contextualize existing research within a developmental framework. **Methods:** A systematic review of the literature was completed, effect sizes from published studies were reviewed, and results are presented with respect to the DS cognitive behavioral phenotype and typical brain development. **Results:** The majority of DS structural neuroimaging studies describe gross differences in brain morphometry and do not use advanced neuroimaging methods to provide nuanced descriptions of the brain. There is evidence for smaller total brain volume (TBV), total gray matter (GM) and white matter, cortical lobar, hippocampal, and cerebellar volumes. When reductions in TBV are accounted for, specific reductions are noted in subregions of the frontal lobe, temporal lobe, cerebellum, and hippocampus. A review of cortical lobar effect sizes reveals mostly large effect sizes from early childhood through adolescence. However, deviance is smaller in adolescence. Despite these smaller effects, frontal GM continues to be largely deviant in adolescence. An examination of age-frontal GM relations using effect sizes from published studies and data from Lee et al. (2016) reveals that while there is a strong inverse relationship between age and frontal GM volume in controls across childhood and adolescence, this is not observed in DS. **Conclusions:** Further developmentally focused research, ideally using longitudinal neuroimaging, is needed to elucidate the nature of the DS neuroanatomic phenotype during childhood and adolescence. (*JINS*, 2018, 24, 966–976)

Keywords: Trisomy 21, Magnetic resonance imaging, Cerebral cortex, Hippocampus, Cerebellum, Frontal lobe

INTRODUCTION

Down syndrome (DS) is the most common genetic cause of intellectual disability (ID) occurring at a rate of $\sim 1/700$ live births (Parker et al., 2010). Although ID is the most widely recognized feature of the DS cognitive-behavioral phenotype (Gibson, 1978), research has identified a profile of relative strengths and weaknesses that distinguishes children with DS both from younger typically developing (TD) peers matched on developmental level and same age peers with other forms of ID (for a review, see Fidler, Most, & Philofsky, 2009). Specifically, those with DS demonstrate deficits in different aspects of language functioning that exceed overall cognitive impairments (Martin, Klusek, Estigarribia, & Roberts, 2009). Furthermore, challenges with explicit memory are prominent and are in excess of global impairments (Jarrold, Baddeley, &

Phillips, 2007). Motor difficulties are noted from early on and persist beyond the first years of life at more severe levels than within other ID syndromes (Spanò et al., 1999; Vicari, 2006; Volman, Visser, & Lensvelt-Mulders, 2007).

Despite advances in our understanding of the DS cognitive-behavioral phenotype in childhood, relatively little neuroimaging research exists for this critical period. Indeed, there are approximately twice as many neuroimaging investigations of adults with DS than children¹, likely due to a focus on Alzheimer's disease (AD) neuropathology in adults with DS and challenges inherent to scanning children. This dearth of knowledge on brain development in a syndrome that can be identified in utero is surprising. Whereas research focused on neuroanatomy of adult DS is crucial, it must be recognized that neuroanatomical abnormalities present in adulthood are the

*Correspondence and reprint requests to: Taralee Hamner, Department of Psychology, Drexel University, 3141 Chestnut Street, Stratton 119, Philadelphia, PA 19104. E-mail: taralee.hamner@gmail.com

¹ Determined from Web of Science review (described below). Estimates included magnetic resonance imaging, magnetic resonance spectroscopy, or positron emission tomography studies; 31 adult and 15 pediatric studies were identified.

result of a lifetime of development. A greater understanding of the brain in DS through a developmental perspective will not only illuminate important neurological principles in pediatric DS, but may elucidate underpinnings of adult phenotypes, particularly the heightened risk for precocious AD (Zigman & Lott, 2007). Thus, the current study sought to provide a review of the pediatric structural neuroimaging literature in DS within the context of typical brain development and the DS cognitive-behavioral phenotype. Before summarizing this literature, we describe the methods used in our review.

REVIEW METHODS

A comprehensive literature review was completed using the electronic database Web of Science. One author completed the initial search using search terms of topic: “Down syndrome” or “Trisomy 21” and topic: “brain”, “MRI”, “magnetic resonance imaging”, “neuroim*”, “neuroan*”, or “morpho*”, resulting in 2678 unique articles. Two additional authors reviewed all resulting abstracts and extracted relevant papers. Additionally, reference sections of identified articles were reviewed to locate additional articles and recently published manuscripts were identified *via* ResearchGate.

Structural neuroimaging studies were selected that (a) compared a DS group to a TD control group (although studies could include other comparison groups) and (b) had a DS group with a mean age of ≤ 30 years. This upper age limit was imposed in attempt to only include imaging studies completed before the development of AD neuropathology, as nearly all individuals with DS present with AD neuropathology by age 40 (Zigman & Lott, 2007). This conservative upper age limit illuminated a surprising dearth of literature in early adulthood, as no DS structural neuroimaging studies were identified with mean ages between 17 and 30 years.

Using these criteria, 14 studies published between 1990 and 2017 informed our review. These studies are summarized in Tables 1 and 2. To synthesize findings across studies, we identified a subset of these studies to gather effect size data to examine the magnitude of volumetric differences for the DS group relative to TD peers using the following criteria: (1) the study reported volumetric findings for one or more of the following: (a) total brain volume (TBV), (b) total, gray matter (GM), or white matter (WM) volumes, or (c) cortical lobar volumes; and (2) means and standard deviations were reported so that effect sizes could be calculated using Cohen’s *d* (Cohen, 1988). Using the established criteria, 6 of the 14 studies contributed data and 46 effect sizes were calculated. Contributing studies are noted in Table 1 and findings are summarized in Figures 1 and 2. More details about the figures are found in the Cerebral Cortex and DS Brain Imaging Findings in a Developmental Context sections. Also included in the latter section are published data from Lee et al. (2016) and data from the the NIH Study of Normal Brain Development. These data are presented in Figure 3 and were obtained with appropriate institutional review boards approvals from their respective institutions.

BRAIN DEVELOPMENT IN DS AND TYPICAL DEVELOPMENT

Over the past 30 years, knowledge about the developing brain studied *in vivo* has grown substantially thanks to the advent of non-invasive magnetic resonance imaging (MRI). Unlike older imaging methodologies (e.g., positron emission tomography) involving radiation exposure, MRI is a safe method to obtain detailed images of the brain in children (Bunge & Kahn, 2009). Whereas current imaging methods [e.g., voxel- and surface-based morphometry, diffusion tensor imaging (DTI)] allow the quantification of very localized regions of the brain at the level of the individual voxel or vertex using metrics such as volume, cortical thickness and surface area, gyrification, and fractional anisotropy (FA), the vast majority of DS neuroimaging studies provide gross descriptions of the brain. With the exception of a handful of recent studies, existing descriptions of the developing brain are limited to quantification of TBV [as well as total gray matter (GM) and white matter (WM)], lobar GM and WM, and measurements of targeted structures, such as the hippocampus, amygdala, basal ganglia, and cerebellum.

Given the state of DS pediatric neuroimaging research, we organized our review by first describing global deviations in TBV as well as GM and WM. We then focus on cortical anatomy and specific subcortical structures by embedding findings within the context of what is known about the DS cognitive-behavioral phenotype. In particular, we focus on structures relevant to four prominent features of the phenotype: intellectual functioning, language skills, explicit memory, and motor development. We close by discussing DS neuroimaging findings within the context of dynamic age-related changes known to occur in typical development and hypothesize about differing cortical developmental trajectories within pediatric DS.

TBV

Typical brain development begins in utero producing an incredibly plastic brain prime for development and specialization. TBV reaches 95% of adult size by approximately age 6. However, dynamic changes in TBV continue through early adulthood (Giedd et al., 2010). Although TBV is a gross measure of neuroanatomy, positive associations between TBV and intelligence have been repeatedly found in studies of children and adults (for a review, see McDaniel, 2005). Consistent with this research, cogent support exists for reduced TBV in pediatric DS, as all six investigations of TBV ($M_{ages: 5-15}$ years) identified reductions.

TBV is often controlled for when examining differences in structures. However, this is not a universal practice, as some account for other volumetric differences (e.g., cerebral GM volume) and others do not make any adjustments. In the sections that follow, we note whether findings are reported as unadjusted, raw values or adjusted for TBV.

GM and WM

Although TBV is an important measure linked to individual differences in intellectual ability in the typical population,

Table 1. Study descriptions and major volumetric findings organized by age period

Authors (year)	Group <i>N</i>	<i>M</i> age years (range or <i>SD</i>)	TBV	TGM	TWM	Frontal	Temporal	Parietal	Occipital	HC	Amygdala	CB	Other [#]	
Toddlerhood														
Gunbey et al. (2017)	DS <i>n</i> = 10 TD <i>n</i> = 8	DS = 2.6 (±0.69) TD = 2.5 (±0.71)		n.s.	n.s.					n.s.	n.s.	↓	✓	
Fujii et al. (2017)	DS <i>n</i> = 32 TD <i>n</i> = 32	DS = 3.7 (2 d-11 yr) TD = 3.7 (9 d-11 yr)											✓	
Early childhood														
Kates et al. (2002)	DS <i>n</i> = 12 TD <i>n</i> = 8	DS = 5.94 (2.94-8.0) TD = 5.79 (3.02-7.39)	↓			GM n.s.	WM n.s.	GM ↓	WM ↓	GM n.s.	WM ↓		✓	
Śmigielka-Kuzia et al. (2011)	DS <i>n</i> = 23 TD <i>n</i> = 26	DS = 6.7 (±3.7) TD = 8.3 (±2.4)	↓			↓ Left, right		↓ Left, right		↓	↓			
Kaufmann et al. (2003)	DS <i>n</i> = 11 TD <i>n</i> = 22*	DS = 7.2 (±2.1) TD = 8.3 (± 1.9)											✓	
Middle childhood														
Carter et al. (2008)	DS <i>n</i> = 15 TD <i>n</i> = 22*	DS = 9.1 (±6.0) TD = 10.3 (± 3.4)											✓	
Carducci et al. (2013)	DS <i>n</i> = 21 TD <i>n</i> = 27	DS = 10.5 (7-16) TD = 10.7 (7-16)											✓	
Pinter et al. (2001a)	DS <i>n</i> = 16 TD <i>n</i> = 15	DS = 11.3 (±5.2) TD = 11.9 (±4.7)	↓							↓ ^a	n.s. ^a			
Pinter et al. (2001b)				↓	↓	Total n.s. ^a	GM n.s. ^a	WM ↑ ^a	GM ↑ ^a	WM n.s. ^a	Total n.s. ^a	↓ ^a	✓	
Adolescence														
Jernigan et al. (1993)	DS <i>n</i> = 6 TD <i>n</i> = 21*	DS = 15.5 (±3.4) TD = 14.5 (±3.8)	↓ Cerebrum	↓ Cerebrum								↓	✓	
Lee et al. (2016)	DS <i>n</i> = 31 TD <i>n</i> = 45	DS = 15.2 (±5.64) TD = 15.7 (±5.87)	↓	↓ n.s. ^a	↓ n.s. ^a	GM ↓ n.s. ^a	WM ↓ ↓ ^a	GM ↓ ↑ ^a	WM ↓ ↑ ^a	GM n.s. ↑ ^a	WM ↓ ↑ ^a	GM ↓ ↑ ^a	WM ↓ n.s. ^a	✓
Menghini et al. (2011)	DS <i>n</i> = 12 TD <i>n</i> = 12	DS = 16 (12.7-19.6) TD = 15.9 (12.2-18.9)	↓	↓	↓								✓	
Jernigan & Bellugi (1990)	DS <i>n</i> = 3 TD <i>n</i> = 14*	DS = 16 (14-17) TD = 19 (8-32)	↓ Cerebrum									↓	✓	
Wang et al. (1992)	DS <i>n</i> = 7 TD <i>n</i> = 17*	Mean not reported. Range 10-20											✓	

Note. ↓ indicates significant reduction in DS; ↑ indicates significant increase in DS; n.s. indicates non-significant findings; a indicates finding once adjusted; *indicates additional comparison groups included; HC = hippocampus; CB = cerebellum; d = days. **Boldface** indicates studies represented in Figure 1. **Boldface italics** indicates studies included in Figure 1 and 2. # indicates other findings reported in Table 2.

Table 2. Other notable findings

Author	Year	Additional findings
Toddlerhood		
Gunbey et al.	2017	<p>↓ In brainstem, thalamus, basal ganglia, cerebellar cortex, right cerebellar WM, and corpus callosum</p> <p>↓ FA and ↑ MD in subsets of supratentorial WM tracts: fronto-temporo-occipital regions, corpus callosum, and anterior limb of internal capsule. ↑ MD in external capsule and thalamic tracks. ↑ FA in several regions. <i>See full text for details.</i></p>
Fujii et al.	2017	↓ Height, width, and area of the pons, width and area of the midbrain, and area of medulla oblongata
Early childhood		
Kates et al.	2002	<p>↓ Total parietal and temporal lobes</p> <p>n.s. Total frontal and occipital lobes</p>
Smigielska-Kuzia et al.	2011	<i>See Table 1 for primary findings</i>
Kaufmann et al.	2003	<p>↓ Posterosuperior and posteroinferior vermis (areas VI – X)</p> <p>n.s. Anterior vermis (areas I-V)</p>
Middle childhood		
Carter et al.	2008	Statistical significance not reported for DS-only <i>versus</i> TD controls; however, reductions were noted in DS for TBV, TGM, TWM, all lobes, and the cerebellum
Carducci et al.	2013	<p>VBM findings:</p> <p>Both regional ↓ and ↑ in the parietal lobe</p> <p>↑ In regions of temporal lobe</p> <p>↓ In regions of frontal lobe, insula, cerebellum, cingulate gyrus, pons, and hippocampus</p> <p><i>See full text for details</i></p>
Pinter et al.	2001	<i>See Table 1 for primary findings</i>
Pinter et al.	2001	<p>↑^a Subcortical GM</p> <p>n.s.^a Parietal and temporal total</p>
Adolescence		
Jernigan et al.	1993	n.s. Findings for the caudate
Lee et al.	2015	↓ In CSF
Menghini et al.	2011	<p>VBM findings:</p> <p>Both regional ↓ and ↑ were noted in the temporal lobe and fusiform gyrus</p> <p>↑ In regions of frontal lobe, insula, and basal ganglia</p> <p>↓ In hippocampus and post cerebellum</p> <p><i>See full text for details.</i></p>
Jernigan & Bellugi	1990	<p>↓ Anterior vermis (areas I-V)</p> <p>n.s. posterosuperior and posteroinferior vermis (areas VI – VII)</p>
Wang et al.	1992	Atypicalities in the corpus callosum, including callosal circularity (i.e., rounding) and ↓width in rostral fifth

Note. ↓ indicates reduction in DS; ↑ indicates increase in DS; **n.s.** indicates non-significant findings; VBM = voxel-based morphometry.

^aFindings once adjusted

mechanisms by which TBV changes over development are more nuanced. That is, TBV is a global measure further segmented into total GM and WM. GM, comprised of cell bodies and synaptic connections (Stiles & Jernigan, 2010), makes up the cerebral cortex and areas deep in the brain (e.g., hippocampus, amygdala, hypothalamus, thalamus, basal ganglia) and in the cerebellum. The development of GM over the first 2 decades of life follows an inverted U-shaped trajectory, in which it increases during childhood and decreases into adolescence (Giedd et al., 2010; Sowell et al., 2003). Much of this reduction is thought to be driven by synaptic pruning (Huttenlocher, 1979) which permits strengthening of relevant connections and elimination of redundant, non-essential ones (Webb, Monk, & Nelson, 2001).

WM is composed of myelinated axons and glial cells found beneath the cortical ribbon (Stiles & Jernigan, 2010). It forms vast webs which enhance fluency and communication between brain regions (Giedd, 2008). Unlike GM, WM largely increases over childhood and an age-related WM decline begins in middle adulthood (Gunning-Dixon, Brickman, Cheng, and Alexopoulos, 2009). As such, deviations in GM and WM across the course of development in a disorder like DS must be interpreted within the context of what is known about the developmental trajectories for these tissue types.

Within DS, GM and WM reductions are described in all studies of school age children and adolescents (Lee et al., 2016; Menghini, Costanzo, & Vicari, 2011; Pinter, Eliez,

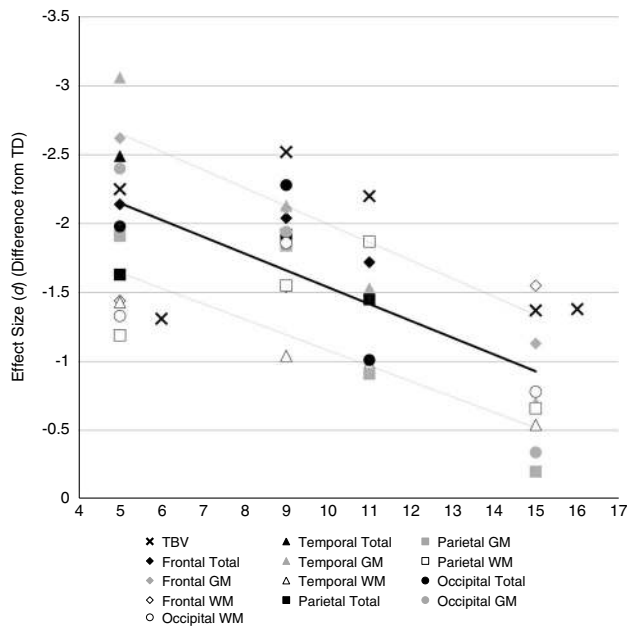


Fig. 1. Effect size estimates (Cohen’s *d*) of DS–control group differences for lobar volumes (total, GM, and WM) from published research studies reporting raw findings plotted as a function of age. N.B., negative effect size estimates indicate smaller volume in DS group. Line represents average volume effect size with upper and lower limits.

Schmitt, Capone, & Reiss, 2001). However, a recent study by Gunbey et al. (2017) in which toddlers ($M_{age} \sim 2.5$) were studied (the youngest group studied to date) reported that GM was non-significantly *larger* in children with DS relative to TD peers. They also reported a non-significant WM decrease in this group.

Thus, both GM and WM volumes are reported to be smaller by the time youth with DS are of school age. However, more nuanced descriptions in youth with typical development indicate that these tissue types do not mature uniformly across the brain (Gogtay et al., 2004; Krogsrud et al., 2016); rather, different regions reach maturation during different developmental periods. In a landmark study, Gogtay and colleagues (2004) found that cortical structures that are phylogenetically older and support sensory and motor functioning tend to mature first, whereas those that support higher-order cognition have a protracted developmental trajectory and mature the latest, well into adolescence.

The regional specificity of GM maturation suggests that a review of the developing brain in DS should provide descriptions of regionally specific findings. Further support for this comes from research indicating higher-level cognitive abilities are supported by specialized neural hubs embedded in distributed networks across the brain (van den Heuvel & Sporns, 2013). Thus, understanding deviations in specific brain structures (rather than deviations in TBV, GM, and WM) is crucial to understanding neural underpinnings of atypical cognitive development in DS.

In the sections that follow, we refine our focus to specific structures thought to be important neural hubs for different

aspects of the DS cognitive–behavioral phenotype. We first discuss the neuroanatomy of cortical structures relevant to two aspects of the DS cognitive–behavioral phenotype: intelligence and language. Next, subcortical structures central to explicit memory and motor functioning are discussed, the hippocampus and cerebellum, respectively. As our review focuses on structures relevant to the DS cognitive–behavioral phenotype, we do not summarize research on other structures that may be of interest to some readers in the text (e.g., amygdala, basal ganglia, brainstem, corpus callosum). However, we have summarized key findings of all studies in Tables 1 and 2 in an attempt to be comprehensive yet remain focused in the text.

Cerebral Cortex

The cerebral cortex comprises the outermost layer of GM and is divided into lobes. Research on the the neural correlates of both intellectual and language functioning suggests that subregions of each lobe contribute to higher-level cognitive processes. One prominent theory of the neural correlates of intellectual functioning, the Parieto-Frontal Integration Theory (P-FIT), identifies a distributed network of primarily cortical structures thought to underlie intellectual functioning (Jung & Haier, 2007), including the dorsolateral prefrontal cortex, anterior cingulate, superior parietal lobule, and the supramarginal and angular gyri. In addition, lateral and inferior portions of the temporal lobes as well as portions of the visual association cortices in the occipital lobes are implicated.

Analogous to studies of intelligence, neural correlates of language functioning are supported by complex networks containing key activity hubs (Friederici & Gierhan, 2013). Two such hubs are located in the temporal and inferior frontal lobes, in regions that include Wernicke’s and Broca’s areas, respectively. However, the neural correlates of language are

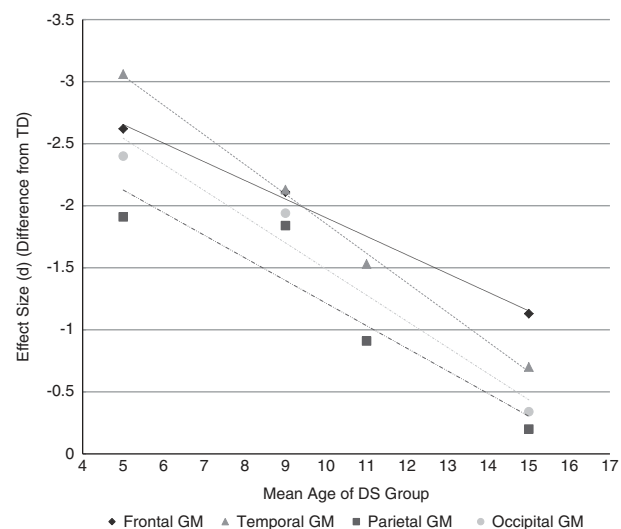


Fig. 2. GM volume for each lobe plotted by age and effect size. N.B., negative effect size denotes smaller volume in the DS group.

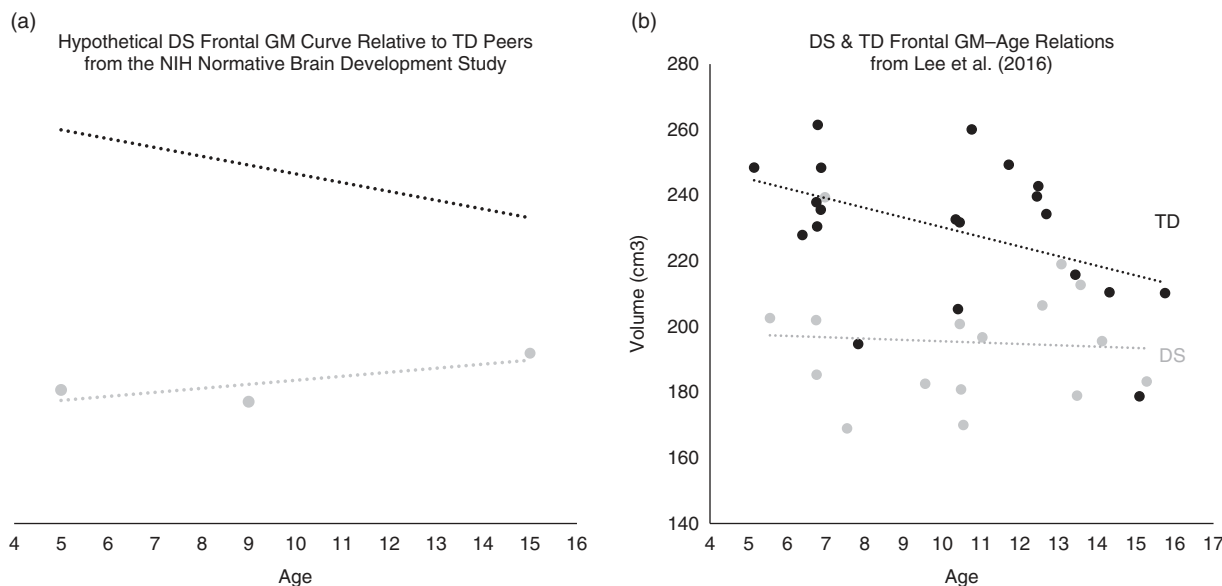


Fig. 3. Frontal GM–age relations in DS relative to TD controls. Panel A shows a hypothetical DS frontal GM curve (gray line) created from effect size estimates from three published studies of youth with DS with mean ages of 5, 9, and 15 (Carter, Capone, & Kaufmann, 2008; Kates, Folley, Lanham, Capone, & Kaufmann, 2002; Lee et al., 2016). These effect size estimates were used as a measure of degree of deviance from typical development by “working backwards” from Cohen’s d (e.g., for the study with mean age of 5: $DS_{\text{hypothetical volume age 5}} = M_{\text{Vol TD age 5}} - (\text{Cohen’s } d_{\text{DS age 5}} * SD_{\text{TD age 5}})$). To plot these relative to frontal GM volume across childhood for TD peers, frontal GM data from the NIH Normative Brain Development Study were used as a comparison group. Effect sizes from the three DS studies were used to approximate standard deviations of difference between youth with DS and TD youth of a similar age (based on the mean age of the DS group in the published study). These three points are plotted as a function of the mean age of the DS group in the respective study. In addition, data are plotted for frontal GM as a function of age for TD youth (black) ages 5 to 15 from the NIH sample. Panel B shows frontal GM–age relations examined cross-sectionally for DS and TD control groups from Lee et al. (2016). The data plotted here are from a subsample of the participants, ages 5–15, from the DS (gray) and TD (black) groups.

certainly more widespread than originally thought, and current theories also implicate structures at the temporo-parietal junction (e.g., angular and supramarginal gyri) and occipito-temporal structures (e.g., fusiform gyrus) (Friederici & Gierhan, 2013; Hickok & Poeppel, 2004). Given the distributed nature of intellectual and language functioning, we first review investigations of lobar volumes followed by voxel- and surface-based morphometric and DTI studies.

As the greatest number of studies examined the cortical lobes in DS and several studies include small samples which may have resulted in insufficient power to detect statistically significant findings, effect sizes for raw lobar volumes (as well as TBV) were calculated using Cohen’s d (Cohen, 1988) to synthesize findings across studies. These were plotted as a function of the mean age of the DS group and are presented in Figure 1. The figure includes effect sizes for four (Carter, Capone, & Kaufmann, 2008; Kates, Folley, Lanham, Capone, & Kaufmann, 2002; Lee et al., 2016; Pinter, Eliez, et al., 2001) of the five studies that described lobar volumes in DS.²

² One study (Smigielska-Kuzia et al., 2011) only reported left and right frontal and temporal lobes; thus, we could not calculate effect size estimates for this investigation. Another study (Carter et al., 2008) that focused on the comorbidity between DS and autism spectrum disorder, reported means/ SD s for their DS-only group but did not report the statistical significance of group findings. Thus, these results are presented in the figure but not described in the text.

Illustrated in Figure 1, raw frontal lobar volumes are substantially smaller in DS (all Cohen’s d values $m1$ or less; Carter et al., 2008; Kates et al., 2002; Lee et al., 2016; Pinter, Eliez, et al., 2001). However, the statistical significance varies across studies: some studies report statistically significant decreases in frontal volumes (Lee et al., 2016; Smigielska-Kuzia et al., 2011) and some do not (Kates et al., 2002; Pinter, Eliez, et al., 2001). When adjusting for TBV, statistically smaller frontal WM volumes are reported (Lee et al., 2016). In contrast, non-significant findings are noted for adjusted frontal GM (Lee et al., 2016) and total frontal volume (Pinter, Eliez, et al., 2001).

Medium to large effect sizes are observed in most studies of the parietal lobes (although the statistical significance varies). Specifically, raw parietal WM is noted as significantly smaller, whereas group differences are not found for parietal GM (Kates et al., 2002; Lee et al., 2016). However, unlike the frontal findings, when adjustments are made for TBV, parietal GM is significantly *larger* (Lee et al., 2016; Pinter, Eliez, et al., 2001). When adjusted parietal WM volumes are considered, findings are mixed. One study reported significantly *larger* volumes (Lee et al., 2016) and another did not (Pinter, Eliez, et al., 2001).

For the temporal lobes, fairly consistent findings are reported for unadjusted volumes (medium to large effect sizes across studies). Specifically, total temporal (Kates et al., 2002; Smigielska-Kuzia et al., 2011) and temporal GM and

WM volumes (Kates et al., 2002; Lee et al., 2016) are smaller in those with DS. However, this reduction does not survive TBV-correction. Once adjusted, one study reported no significant differences in total temporal and temporal GM (Pinter, Eliez, et al., 2001) and others reported significant *increases* in temporal GM (Lee et al., 2016) and WM (Lee et al., 2016; Pinter, Eliez, et al., 2001).

Within occipital lobes, reductions of medium to large effect are observed in most studies. Again, the statistical significance of these findings varies: one study reported statistically smaller occipital GM and WM volumes (Lee et al., 2016) and one study did not (Kates et al., 2002). When adjusted volumes were considered, total occipital (Pinter, Eliez, et al., 2001) and occipital WM have been reported not to differ from TD peers (Lee et al., 2016), whereas adjusted occipital GM is reportedly *larger* (Lee et al., 2016).

Complementing volumetric investigations, voxel-based morphometric investigations have reported reduced GM and WM (after adjusting for TBV) in multiple frontal regions, particularly medially (Carducci et al., 2013). Reduced GM has been reported in inferior and medial portions of the temporal lobes (Menghini et al., 2011). Reductions in WM have also been reported in regions of the insula and in frontal and parietal lobes (Carducci et al., 2013). In addition, relative increases in GM have been reported in regions of the insula, frontal (Menghini et al., 2011), temporal (Carducci et al., 2013; Menghini et al., 2011), and parietal (Carducci et al., 2013) lobes.

Surface-based morphometric approaches also note atypicalities in subregions of all lobes. Reduced surface area is reported in the frontal and temporal lobes, with the largest reductions (surviving TBV-correction) in the dorsal medial frontal cortex and superior temporal gyrus (Lee et al., 2016). In contrast, increased cortical thickness (which is thought to reflect less 'mature' cortex) is found throughout much of the frontal lobe, superior parietal lobe, and occipital lobe (Lee et al., 2016).

Lastly, findings from the only published DTI study completed with a pediatric sample (Gunbey et al., 2017) revealed reduced FA in the fronto-temporo-occipital tracts (particularly in frontal circuits) in toddlers with DS. Interestingly, these findings are consistent with the small DTI literature in adults with DS, which also reports frontal atypicalities in WM (Fenoll et al., 2017; Powell et al., 2014).

Hippocampus

The hippocampus is widely believed to be a central hub for explicit memory (Squire, 1992), with lesions resulting in catastrophic memory impairments across development (Isaacs et al., 2003; Savage, Buzzetti, & Ramirez, 2004). Like the structures reviewed thus far, the hippocampus undergoes massive changes across childhood, with peak volume between ages 9 and 11 (Uematsu et al., 2012) and subsequent decreases during adolescence. Investigations of youth with DS highlight significant impairments on hippocampally mediated memory tasks (Clark, Fernandez, Sakhon, Spano, & Edgin, 2017; Pennington, Moon, Edgin, Stedron, & Nadel, 2003).

Atrophy of the hippocampus is one of the most well-replicated neuroimaging biomarkers of AD pathology (Blanken et al., 2017). Thus, it is surprising that there are few investigations of this structure in youth with DS. The limited research available suggests no significant differences in hippocampal volume between those with DS and TD peers in toddler years (Gunbey et al., 2017), but as children age, those with DS are reported to have smaller hippocampal volumes when both unadjusted (Smigielska-Kuzia et al., 2011) and adjusted (Pinter, Brown, et al., 2001) for TBV. Additionally, reductions in hippocampal subregions are noted in voxel-based morphometric investigations (Carducci et al., 2013; Menghini et al., 2011).

Cerebellum

The cerebellum has long been recognized for its role in motor functioning and recent investigations implicate involvement in higher-order cognitive functioning as well (Buckner, 2013; Middleton & Strick, 2001; Ramnani, 2006). Thus, we review cerebellar findings to highlight possible contributions to motor impairments in DS, but recognize that cerebellar abnormalities likely contribute to multiple aspects of the DS cognitive-behavioral phenotype. In typical development, the cerebellum follows an inverted U-shaped trajectory with peak volume met in adolescence (Tiemeier et al., 2010). For those with DS, support for smaller cerebellar volume has been reported in childhood after TBV adjustment (Pinter, Eliez, et al., 2001) and in adolescence (Jernigan & Bellugi, 1990; Jernigan, Bellugi, Sowell, Doherty, & Hesselink, 1993). Specific reductions are noted in total cerebellar WM and GM in toddlerhood (Gunbey et al., 2017) continuing through childhood (Pinter, Eliez, et al., 2001). Similarly, voxel-based morphometric investigations noted relative reductions (Carducci et al., 2013; Menghini et al., 2011) and some relative increases (Menghini et al., 2011) in cerebellar subregions.

SUMMARY OF DS IMAGING FINDINGS

Our review of the DS pediatric neuroimaging literature revealed several key findings. First, TBV in DS is smaller overall. This finding is consistently replicated in the literature and is important to consider when interpreting other morphometric differences. Second, by childhood, GM and WM volumes are smaller relative to TD controls. Third, volumetric reductions are noted for all lobes, consistent with the distributed nature of intellectual and language functioning. However, only reductions in frontal WM lobar volumes survive adjustments for overall microcephaly. Findings from voxel- and surface-based morphometric investigations as well as the very limited DTI literature also note atypicalities in frontal anatomy in DS surviving correction for TBV. Lastly, consistent with the explicit memory and motor impairments associated with DS, volumetric reductions (in excess of TBV) in the hippocampus and cerebellum have been noted in several studies.

Our review also revealed several key gaps in knowledge that prevent the field from creating a developmentally informed model of brain development in DS. None of the 14 existing studies adopt a developmental neuroimaging approach. As the late Annette Karmiloff-Smith astutely stated, “development is not about studying children” (Karmiloff-Smith, 2012). Rather, to study the developing brain, one must be committed to examining relations between the brain and age. Ideally, this would involve longitudinal investigations consistent with the large corpus of studies on typical brain development (see Giedd et al., 2010 for a review). As outlined in a study by Thomas and colleagues (2009) on using developmental trajectories to understand developmental disorders, examining relations between age and a phenotype of interest in a cross-sectional analysis can begin to provide insights into the emergence of atypicalities associated with different developmental disorders. Thus, in an attempt to begin conceptualizing the brain in DS within a developmental context, we examine the existing neuroimaging findings with reference to the mean age of the participants studied in the section that follows.

DS BRAIN IMAGING FINDINGS IN A DEVELOPMENTAL CONTEXT

We know that bigger is not always better when it comes to the developing brain. Rather, understanding *how much* the brain in children with DS deviates from TD peers *at what point in development* may generate hypotheses about how brain trajectories differ for DS. Given the protracted developmental trajectory of the cerebral cortex, we extracted data from all studies in our review that reported on lobar volumetric findings (four studies; raw findings –i.e., uncorrected for TBV) and calculated effect size estimates for lobar GM differences in DS relative to TD controls using Cohen’s *d* (Cohen, 1988). This yielded 14 estimates. We then plotted these as a function of the mean age of the DS group in each study (Figure 2) to examine effect size–age relations for these structures. Importantly, many studies have a very wide age range requiring caution in interpretation as representing a developmental period. Also, it should be noted that while most studies use a similar method for acquiring lobar volume (i.e., Talairach-based), Lee et al. (2016) calculate lobar volume using regional segmented volumes in native space (see Collins, Holmes, Peters, & Evans, 1995 for details). Thus, some caution should be exercised when comparing findings across studies.

As illustrated in Figure 2, youth with DS deviate from their TD peers across all lobes and ages examined. Indeed, the vast majority of the 14 effect sizes are described as large using Cohen’s (1988) conventions (exceptions are four small-to-medium effects). Also evident is the fact that lobar GM is particularly deviant early in development and that less deviance is apparent over time. Of the lobes, frontal GM was most deviant in the oldest age group studied ($M_{\text{age}} = 15$ years) and was the only lobe to maintain a large effect size. Given established relationships between frontal anatomy and

intelligence (Jung & Haier, 2007), further exploration of the developmental trajectory for frontal GM within DS may help to elucidate the neurobiological underpinnings of ID in this and other groups.

To begin this investigation, we used the effect size estimates for frontal GM displayed in Figure 2 as measures of the degree of deviance observed in frontal GM relative to controls. We then plotted these relative to data from the the NIH Study of Normal Brain Development using the following methods. First, we used effect sizes from the 3 studies that reported on frontal GM to approximate standard deviations (*SD*) of difference between youth with DS and TD youth of a similar age from the Normative Brain Development Study (i.e., if the effect size from a given study is -1, then this indicates that the DS group mean is 1 *SD* below the mean of TD children from the Normative Brain Development Study of a particular age). Second, we estimated hypothetical DS volume by “working backwards” using Cohen’s *d*. Specifically, we subtracted the *SD*s of the difference from the normative mean for the age studied. For example, for youth in the study with the mean age of 5, the following equation was used to generate one point on the “curve”: $DS_{\text{hypothetical volume age 5}} = M_{\text{vol TD age 5}} - (\text{Cohen's } d_{\text{DS age 5}} * SD_{\text{TD age 5}})$. We then plotted these values for the studies of youth with DS with mean ages of 5, 9, and 15 alongside the normative data for TD youth, ages of 5–15 years, from the NIH normative sample in Figure 3a.

The hypothetical DS frontal GM ‘curve’ appears much flatter than the curve for TD peers. Because this line was created from three data points, we plotted GM volumes for youth with DS and TD controls, ages 5–15 years, as a function of age from the Lee et al. (2016) study in Figure 3b to present our “hypothetical curve” against existing, cross-sectional data. This cross-sectional sample also reveals an inverse relationship between frontal GM and age in the TD controls; however, similar to the hypothetical curve, this relationship is not evident in DS. Thus, this preliminary investigation of age–brain relations (through examination of effect sizes relative to longitudinal TD data *and* cross-sectional data from Lee et al., 2016) suggests that the developmental trajectory for frontal GM in DS differs from TD youth.

The potential difference in trajectory may inform why effect sizes for frontal (and other lobar) GM volumes are smaller in adolescence (see Figure 2). Specifically, the smaller effect sizes may result from the fact that frontal GM volumes for youth with DS do not appear to follow the downward trajectory observed in typically developing youth. Whereas TD peers enter adolescence with reduced GM volume (presumably due to the pruning of redundant synapses), this robust reduction is not evident in DS. Thus, the smaller effect sizes found at older ages are likely not due to youth with DS “catching up”. Rather, they may suggest a different developmental trajectory, consistent with research suggesting atypical neural trajectories in other neurodevelopmental disorders (Shaw, Gogtay, & Rapoport, 2010).

The data presented here from Lee et al. (2016) are cross-sectional and represent the findings of one study, requiring

caution with interpretation. However, by presenting these findings in conjunction with the hypothetical curves emerging from the literature review, it is our hope to begin to generate a conversation about atypical neurodevelopment within those with DS. With this, we provide a synopsis of the state of the current literature on the developing brain in DS and discuss future directions for research.

STATE OF THE LITERATURE: CONTRIBUTIONS, CHALLENGES, AND FUTURE DIRECTIONS

Research examining the brain *in vivo* in pediatric DS has provided important insights into the neural structures that likely underlie the DS cognitive-behavioral phenotype. However, this literature is still quite small and very few studies have adopted advanced neuroimaging methodologies to describe nuanced descriptions of the brain in youth with DS. This dearth of research is likely due to the many challenges inherent to successfully completing developmental neuroimaging, from methodological (e.g., child appropriate equipment and analyses) to more practical (e.g., participant anxiety, movement restrictions) limitations. However, it remains unclear why imaging within pediatric DS has not followed suit with other neurodevelopmental disorders associated with cognitive impairment (e.g., fragile X syndrome, Williams syndrome, 22q11.2 deletion syndrome), which have evolved to use modern techniques while addressing the shared challenges of imaging within these populations.

To move the field forward, a push for increased neuroimaging research, particularly focused on the first years of life and early childhood, using modern neuroimaging techniques and best practice guidelines for pediatric neuroimaging (for review, see: Raschle, Zuk, Ortiz-Mantilla, et al., 2012) is needed. Given the small samples that characterize the literature on neuroimaging in DS, it is worth noting that several studies in the current literature review were conducted at the same institutions. As a result, the existing literature on this topic is likely describing a small number of individuals with DS, as there may be overlap in study participants across studies given the low incidence of DS.

Consequently, the field could benefit from the implementation of multi-site investigations to garner larger samples needed for more advanced neuroimaging analyses. Analytic methods used in such studies might be modeled off successful multi-site investigations (e.g., Alzheimer's Disease Neuroimaging Initiative; Weiner et al., 2013). Moreover, data collected from published studies may be pooled and examined using data harmonization methodology, consistent with meta-analytic methods used by the Enhancing NeuroImaging Genetics through Meta-Analysis (ENIGMA) consortium (Thompson et al., 2014).

In conclusion, the results of this comprehensive review suggest that the field of DS pediatric neuroimaging is very much in its infancy. Our examination of existing research revealed consistencies and discrepancies within the literature and identified a key gap in research starting in late

adolescence and early adulthood. Although some findings are mixed, many findings reported as non-significant yield massive effect sizes, suggesting limitations in sample size and characterization of differences. Results from functional magnetic resonance imaging studies (a review outside the scope of this study) further support current findings that areas implicated in language and intellectual functioning are atypical in DS (Anderson et al., 2013; Jacola et al., 2011). Although our review focused on DS and TD peers, investigation of DS in relation to other developmental and genetic disorders can help to inform our understanding of neurological underpinnings of ID.

Lastly, and arguably most importantly, no longitudinal neuroimaging investigations of pediatric DS exist. Rather, much of what we know comes from cross-sectional studies including wide age ranges with little attention to developmental effects. This impedes our understanding of the developmental unfolding of the DS neuroanatomic and cognitive-behavioral phenotypes, limiting our ability to identify developmentally informed interventions to alter the developmental trajectory in pediatric DS and promote improved outcomes across the lifespan.

ACKNOWLEDGMENTS

Normative brain development data presented in Figure 3a were obtained from the Pediatric MRI Data Repository (version 4) created by the NIH MRI Study of Normal Brain Development. This is a multi-site, longitudinal study of TD children, from ages newborn through young adulthood, conducted by the Brain Development Cooperative Group and supported by the National Institute of Child Health and Human Development, the National Institute on Drug Abuse, the National Institute of Mental Health, and the National Institute of Neurological Disorders and Stroke (Contract #s N01-HD02-3343, N01-MH9-0002, and N01-NS-9-2314, -2315, -2316, -2317, -2319, and -2320). A listing of the participating sites and a complete listing of the study investigators can be found at http://www.bic.mni.mcgill.ca/nihpd/info/participating_centers.html. Data included in Figure 3b is from Lee et al. (2016); this work was supported by the Intramural Research Program of the National Institutes of Health, National Institute of Mental Health (NCT00001246; ProtocolID89-M-0006). We thank the children and families who made all of this research possible.

REFERENCES

- Anderson, J.S., Nielsen, J.A., Ferguson, M.A., Burbach, M.C., Cox, E.T., Dai, L., ... Korenberg, J.R. (2013). Abnormal brain synchrony in Down syndrome. *NeuroImage: Clinical*, 2, 703–715. doi: 10.1016/j.nicl.2013.05.006
- Blanken, A.E., Hurtz, S., Zarow, C., Biado, K., Honarpisheh, H., Somme, J., ... Lo, D. (2017). Associations between hippocampal morphometry and neuropathologic markers of Alzheimer's disease using 7T MRI. *NeuroImage: Clinical*, 15, 56–61.
- Buckner, R.L. (2013). The cerebellum and cognitive function: 25 years of insight from anatomy and neuroimaging. *Neuron*, 80(3), 807–815.

- Bunge, S.A., & Kahn, I. (2009). Cognition: An overview of neuroimaging techniques. *Encyclopedia of Neuroscience*, 2, 1063–1067.
- Carducci, F., Onorati, P., Condoluci, C., Di Gennaro, G., Quarato, P.P., Pierallini, A., ... Albertini, G. (2013). Whole-brain voxel-based morphometry study of children and adolescents with Down syndrome. *Functional Neurology*, 28(1), 19–28.
- Carter, J.C., Capone, G.T., & Kaufmann, W.E. (2008). Neuroanatomic correlates of autism and stereotypy in children with Down syndrome. *Neuroreport*, 19(6), 653–656.
- Clark, C.A.C., Fernandez, F., Sakhon, S., Spano, G., & Edgin, J.O. (2017). The medial temporal memory system in Down syndrome: Translating animal models of hippocampal compromise. *Hippocampus*, 27(6), 683–691. doi: 10.1002/hipo.22724
- Cohen, J. (1988). *Statistical power analysis for the behavioral sciences*. Hillsdale, NJ: Lawrence Erlbaum Associates.
- Collins, D.L., Holmes, C.J., Peters, T.M., & Evans, A.C. (1995). Automatic 3-D model-based neuroanatomical segmentation. *Human Brain Mapping*, 3(3), 190–208.
- Fenoll, R., Pujol, J., Esteba-Castillo, S., De Sola, S., Ribas-Vidal, N., García-Alba, J., ... Dierssen, M. (2017). Anomalous white matter structure and the effect of age in Down syndrome patients. *Journal of Alzheimer's Disease*, 57(1), 61–70.
- Fidler, D., Most, D., & Philofsky, A. (2009). The Down syndrome behavioural phenotype: Taking a developmental approach. Retrieved from https://www.researchgate.net/publication/253424551_The_Down_syndrome_behavioural_phenotype_Taking_a_developmental_approach.
- Friederici, A.D., & Gierhan, S.M. (2013). The language network. *Current Opinion in Neurobiology*, 23(2), 250–254. doi: 10.1016/j.conb.2012.10.002
- Gibson, D. (1978). *Down syndrome: The psychology of mongolism*. London: Cambridge University Press.
- Giedd, J.N. (2008). The teen brain: Insights from neuroimaging. *Journal of Adolescent Health*, 42(4), 335–343. doi: 10.1016/j.jadohealth.2008.01.007
- Giedd, J.N., Stockman, M., Weddle, C., Liverpool, M., Alexander-Bloch, A., Wallace, G.L., ... Lenroot, R.K. (2010). Anatomic magnetic resonance imaging of the developing child and adolescent brain and effects of genetic variation. *Neuropsychology Review*, 20(4), 349–361. doi: 10.1007/s11065-010-9151-9
- Gogtay, N., Giedd, J.N., Lusk, L., Hayashi, K.M., Greenstein, D., Vaituzis, A.C., ... Thompson, P.M. (2004). Dynamic mapping of human cortical development during childhood through early adulthood. *Proceeding of the National Academy of Sciences of the United States of America*, 101(21), 8174–8179. doi: 10.1073/pnas.0402680101
- Gunbey, H.P., Bilgici, M.C., Aslan, K., Has, A.C., Ogur, M.G., Alhan, A., ... Lutfi, I. (2017). Structural brain alterations of Down's syndrome in early childhood evaluation by DTI and volumetric analyses. *European Journal of Radiology*, 27(7), 3013–3021.
- Gunning-Dixon, F.M., Brickman, A.M., Cheng, J.C., & Alexopoulos, G.S. (2009). Aging of cerebral white matter: A review of MRI findings. *International Journal of Geriatric Psychiatry*, 24(2), 109–117.
- Hickok, G., & Poeppel, D. (2004). Dorsal and ventral streams: A framework for understanding aspects of the functional anatomy of language. *Cognition*, 92(1–2), 67–99. doi: 10.1016/j.cognition.2003.10.011
- Huttenlocher, P.R. (1979). Synaptic density in human frontal cortex—developmental changes and effects of aging. *Brain Research*, 163(2), 195–205.
- Isaacs, E., Vargha-Khadem, F., Watkins, K., Lucas, A., Mishkin, M., & Gadian, D. (2003). Developmental amnesia and its relationship to degree of hippocampal atrophy. *Proceedings of the National Academy of Sciences of the United States of America*, 100(22), 13060–13063.
- Jacola, L.M., Byars, A.W., Chalfonte-Evans, M., Schmithorst, V.J., Hickey, F., Patterson, B., ... Holland, S.K. (2011). Functional magnetic resonance imaging of cognitive processing in young adults with Down syndrome. *American Journal on Intellectual and Developmental Disabilities*, 116(5), 344–359.
- Jarrold, C., Baddeley, A.D., & Phillips, C. (2007). Long-term memory for verbal and visual information in Down syndrome and Williams syndrome: Performance on the Doors and People test. *Cortex*, 43(2), 233–247.
- Jernigan, T.L., & Bellugi, U. (1990). Anomalous brain morphology on magnetic resonance images in Williams syndrome and Down syndrome. *Archives of Neurology*, 47(5), 529–533.
- Jernigan, T.L., Bellugi, U., Sowell, E., Doherty, S., & Hesselink, J.R. (1993). Cerebral morphologic distinctions between Williams and Down syndromes. *Archives of Neurology*, 50(2), 186–191.
- Jung, R.E., & Haier, R.J. (2007). The Parieto-Frontal Integration Theory (P-FIT) of intelligence: Converging neuroimaging evidence. *Behavioral and Brain Sciences*, 30(2), 135–154. discussion 154–187.
- Karmiloff-Smith, A. (2012). Foreword: Development is not about studying children: The importance of longitudinal approaches. *American Journal on Intellectual and Developmental Disabilities*, 117(2), 87–89.
- Kates, W.R., Folley, B.S., Lanham, D.C., Capone, G.T., & Kaufmann, W.E. (2002). Cerebral growth in Fragile X syndrome: Review and comparison with Down syndrome. *Microscopy Research and Technique*, 57(3), 159–167.
- Kaufmann, W.E., Cooper, K.L., Mostofsky, S.H., Capone, G.T., Kates, W.R., Newschaffer, C.J., ... Lanham, D.C. (2003). Specificity of cerebellar vermian abnormalities in autism: A quantitative magnetic resonance imaging study. *Journal of Child Neurology*, 18(7), 463–470.
- Krogsrud, S.K., Fjell, A.M., Tamnes, C.K., Grydeland, H., Mork, L., Due-Tønnessen, P., ... Johansen-Berg, H. (2016). Changes in white matter microstructure in the developing brain—A longitudinal diffusion tensor imaging study of children from 4 to 11 years of age. *NeuroImage*, 124, 473–486.
- Lee, N.R., Adeyemi, E.I., Lin, A., Clasen, L.S., Lalonde, F.M., Condon, E., ... Giedd, J.N. (2016). Dissociations in cortical morphometry in youth with Down syndrome: Evidence for reduced surface area but increased thickness. *Cerebral Cortex*, 26(7), 2982–2990. doi: 10.1093/cercor/bhv107
- Martin, G.E., Klusek, J., Estigarribia, B., & Roberts, J.E. (2009). Language characteristics of individuals with Down syndrome. *Topics in Language Disorders*, 29(2), 112.
- McDaniel, M.A. (2005). Big-brained people are smarter: A meta-analysis of the relationship between in vivo brain volume and intelligence. *ScienceDirect*, 33(4), 337–346. doi: <https://doi.org/10.1016/j.intell.2004.11.005>
- Menghini, D., Costanzo, F., & Vicari, S. (2011). Relationship between brain and cognitive processes in Down syndrome. *Behavior Genetics*, 41(3), 381–393. doi: 10.1007/s10519-011-9448-3

- Middleton, F.A., & Strick, P.L. (2001). Cerebellar projections to the prefrontal cortex of the primate. *Journal of Neuroscience*, *21*(2), 700–712.
- Parker, S.E., Mai, C.T., Canfield, M.A., Rickard, R., Wang, Y., Meyer, R.E., ... Kirby, R.S. (2010). Updated national birth prevalence estimates for selected birth defects in the United States, 2004–2006. *Birth Defects Research Part A: Clinical and Molecular Teratology*, *88*(12), 1008–1016.
- Pennington, B.F., Moon, J., Edgin, J., Stedron, J., & Nadel, L. (2003). The neuropsychology of Down syndrome: Evidence for hippocampal dysfunction. *Child Development*, *74*(1), 75–93.
- Pinter, J.D., Brown, W.E., Eliez, S., Schmitt, J.E., Capone, G.T., & Reiss, A.L. (2001). Amygdala and hippocampal volumes in children with Down syndrome: A high-resolution MRI study. *Neurology*, *56*(7), 972–974.
- Pinter, J.D., Eliez, S., Schmitt, J.E., Capone, G.T., & Reiss, A.L. (2001). Neuroanatomy of Down's syndrome: A high-resolution MRI study. *American Journal of Psychiatry*, *158*(10), 1659–1665.
- Powell, D., Caban-Holt, A., Jicha, G., Robertson, W., Davis, R., Gold, B.T., ... Head, E. (2014). Frontal white matter integrity in adults with Down syndrome with and without dementia. *Neurobiology of Aging*, *35*(7), 1562–1569. doi: 10.1016/j.neurobiolaging.2014.01.137
- Ramrani, N. (2006). The primate cortico-cerebellar system: Anatomy and function. *Nature Reviews Neuroscience*, *7*(7), 511–522.
- Raschle, N., Zuk, J., Ortiz-Mantilla, S., Sliva, D.D., Franceschi, A., Grant, P.E., ... Gaab, N. (2012). Pediatric neuroimaging in early childhood and infancy: Challenges and practical guidelines. *Annals of the New York Academy of Sciences*, *1252*(1), 43–50.
- Savage, L.M., Buzzetti, R.A., & Ramirez, D.R. (2004). The effects of hippocampal lesions on learning, memory, and reward expectancies. *Neurobiology of Learning and Memory*, *82*(2), 109–119. doi: 10.1016/j.nlm.2004.05.002
- Shaw, P., Gogtay, N., & Rapoport, J. (2010). Childhood psychiatric disorders as anomalies in neurodevelopmental trajectories. *Human Brain Mapping*, *31*(6), 917–925. doi: 10.1002/hbm.21028
- Smigielska-Kuzia, J., Bockowski, L., Sobaniec, W., Sendrowski, K., Olchowik, B., Cholewa, M., ... Lebkowska, U. (2011). A volumetric magnetic resonance imaging study of brain structures in children with Down syndrome. *Polish Journal of Neurology and Neurosurgery*, *45*(4), 363–369.
- Sowell, E.R., Peterson, B.S., Thompson, P.M., Welcome, S.E., Henkenius, A.L., & Toga, A.W. (2003). Mapping cortical change across the human life span. *Nature Neuroscience*, *6*(3), 309–315.
- Spanò, M., Mercuri, E., Randò, T., Pantò, T., Gagliano, A., Henderson, S., & Guzzetta, F. (1999). Motor and perceptual-motor competence in children with Down syndrome: Variation in performance with age. *European Journal of Paediatric Neurology*, *3*(1), 7–14.
- Squire, L.R. (1992). Memory and the hippocampus: A synthesis from findings with rats, monkeys, and humans. *Psychology Review*, *99*(2), 195–231.
- Stiles, J., & Jernigan, T.L. (2010). The basics of brain development. *Neuropsychology Review*, *20*(4), 327–348. doi: 10.1007/s11065-010-9148-4
- Thomas, M.S., Annaz, D., Ansari, D., Scerif, G., Jarrold, C., & Karmiloff-Smith, A. (2009). Using developmental trajectories to understand developmental disorders. *Journal of Speech, Language, and Hearing Research*, *52*(2), 336–358.
- Thompson, P.M., Stein, J.L., Medland, S.E., Hibar, D.P., Vasquez, A.A., Renteria, M.E., ... Franke, B. (2014). The ENIGMA Consortium: Large-scale collaborative analyses of neuroimaging and genetic data. *Brain Imaging and Behavior*, *8*(2), 153–182.
- Tiemeier, H., Lenroot, R.K., Greenstein, D.K., Tran, L., Pierson, R., & Giedd, J.N. (2010). Cerebellum development during childhood and adolescence: A longitudinal morphometric MRI study. *NeuroImage*, *49*(1), 63–70. doi: 10.1016/j.neuroimage.2009.08.016
- Uematsu, A., Matsui, M., Tanaka, C., Takahashi, T., Noguchi, K., Suzuki, M., & Nishijo, H. (2012). Developmental trajectories of amygdala and hippocampus from infancy to early adulthood in healthy individuals. *PLoS One*, *7*(10), e46970.
- van den Heuvel, M.P., & Sporns, O. (2013). Network hubs in the human brain. *Trends in Cognitive Sciences*, *17*(12), 683–696.
- Vicari, S. (2006). Motor development and neuropsychological patterns in persons with Down syndrome. *Behavior Genetics*, *36*(3), 355–364.
- Volman, M.J., Visser, J.J., & Lensvelt-Mulders, G.J. (2007). Functional status in 5 to 7-year-old children with Down syndrome in relation to motor ability and performance mental ability. *Disability and Rehabilitation*, *29*(1), 25–31.
- Webb, S.J., Monk, C.S., & Nelson, C.A. (2001). Mechanisms of postnatal neurobiological development: Implications for human development. *Developmental Neuropsychology*, *19*(2), 147–171. doi: 10.1207/S15326942DN1902_2
- Weiner, M.W., Veitch, D.P., Aisen, P.S., Beckett, L.A., Cairns, N.J., Green, R.C., ... Liu, E. (2013). The Alzheimer's Disease Neuroimaging Initiative: A review of papers published since its inception. *Alzheimer's & Dementia*, *9*(5), e111–e194.
- Zigman, W.B., & Lott, I.T. (2007). Alzheimer's disease in Down syndrome: Neurobiology and risk. *Developmental Disabilities Research Reviews*, *13*(3), 237–246.