

Pediatric Flexible Flatfoot; Clinical Aspects and Algorithmic Approach

Farzin Halabchi^{1,2}, MD; Reza Mazaheri^{*1,2}, MD; Maryam Mirshahi², MD; Ladan Abbasian², MD

1. Sports Medicine Research Center, Tehran University of Medical Sciences, Tehran, Iran
2. Department of Sports & Exercise Medicine, Tehran University of Medical Sciences, Tehran, Iran

Received: Sep 04, 2012; Accepted: Jan 24, 2013; First Online Available: Feb 17, 2013

Abstract

Flatfoot constitutes the major cause of clinic visits for pediatric foot problems. The reported prevalence of flatfoot varies widely due to numerous factors. It can be divided into flexible and rigid flatfoot. Diagnosis and management of pediatric flatfoot has long been the matter of controversy. Common assessment tools include visual inspection, anthropometric values, footprint parameters and radiographic evaluation. Most flexible flatfeet are physiologic, asymptomatic, and require no treatment. Otherwise, the physician should treat symptomatic flexible flatfeet. Initial treatment options include activity modification, proper shoe and orthoses, exercises and medication. Furthermore, comorbidities such as obesity and ligamentous laxity should be identified and managed, if applicable. When all nonsurgical treatment options fail, surgery can be considered. Our purpose in this article is to present a clinical algorithmic approach to pediatric flatfoot.

Iranian Journal of Pediatrics, Volume 23 (Number 3), June 2013, Pages: 247-260

Key Words: Flatfoot; Pes planus; Hyperpronation; Orthosis; Exercise; Algorithm; Children

Introduction

Deformities of the lower extremities are very frequent in children and most of the time these conditions are physiological and do not need any treatment. Ninety percent of clinic visits for foot problems are due to flatfoot (FF)^[1]. Although flatfoot rarely leads to disability, it is still one of the major concerns of parents. Generally it is believed to lead to gait disorders later^[2-5]. The flatfoot has two components: sagging of the medial arch and heel valgus^[1]. Flattening of the medial arch is a universal finding in patients with flatfoot that is common in both pediatric and adult populations^[5-12].

In the neonates and toddlers, it is known that a fat pad is present underneath the medial longitudinal arch of the infant foot while the arch

develops; although this fat pad is thought to resolve between the ages of 2 and 5 years as the arch of the foot is formed^[13]. Children almost universally are "flat-footed" when they start walking. Intrinsic laxity and a lack of neuromuscular control result in flattening of the foot when weight-bearing^[14]. Pediatric flatfoot can be divided into flexible and rigid categories. Flexible flatfoot is characterized by a normal arch during non weight-bearing and a flattening of the arch on stance and may be asymptomatic or symptomatic. Rigid flatfoot is characterized by a stiff, flattened arch in both weight bearing and non-weight bearing positions. Most rigid flatfeet are associated with underlying pathology that requires special considerations^[10,15].

Flatfoot may be an isolated pathology or as part of a larger clinical entity. These entities

* **Corresponding Author;**

Address: Sports Medicine Research Center, Tehran University of Medical Sciences, No 7, Jalal ale Ahmad Highway, Tehran, P.O.Box: 14395-578, Iran
E-mail: Mazaheri_md@tums.ac.ir

© 2013 by Pediatrics Center of Excellence, Children's Medical Center, Tehran University of Medical Sciences, All rights reserved.

include generalized ligamentous laxity, neurologic and muscular abnormalities, genetic and collagen disorders^[10].

Pediatric flatfoot has long been a controversial issue that questions what is normal and what is pathologic, when to treat and when to observe, what is the best conservative treatment, and when to refer for surgical treatment. Infants are born with flexible flatfoot, and the normal foot arch develops in the first decade of life^[16].

It seems that the midfoot plantar fat pad starts resorption after the onset of independent walking. However, no study has investigated precisely when this fat pad is resolved in children^[17].

Decreasing in longitudinal arch is the primary manifestation of flatfoot, resulting in the bodyweight to medial side of the foot during standing and walking. Flatfoot has therefore been regarded not only as a problem of the static alignment of ankle and foot structures, but as a dynamic functional abnormality of the lower extremities^[7]. This overloading mechanism resulting from the flattened medial longitudinal arch (MLA) is transferred to proximal areas such as knees, hip and lower back^[8].

The reported prevalence of flatfoot varies and ranges from approximately 0.6-77.9%^[5-6,18-23]. This wide variety in prevalence of flatfoot in literature is related to numerous factors such as different age groups as well as different assessment methods. For example, the prevalence of flatfoot in different age groups of 2-6 and 8-13 years have been reported as 37-59.7% and 4-19.1%, respectively^[5,23]. Pediatric flatfoot appears during the first years of life, but persists in only 3% of adult population^[3,6,9,12,17,23-25].

We may consider some parameters as the predisposing factors of flatfoot, such as age, sex, body composition, ligamentous laxity, family history, types of footwear and age at which shoe wearing began^[24]. Males were twice more prone to have flatfoot as females^[21,23]. Obese and overweight children were more likely to have flatfoot than those with proper weight^[13,21,23]. Children with ligamentous laxity may also be prone to flatfoot due to impairment of arch development^[24,25]. Positive family history of flatfoot may be another important factor^[10]. Shoe wearing before the age of six may be another predisposing factor for flatfoot^[22,26,27].

Clinical Manifestation

The majority of flexible flatfeet are physiologic and longitudinal arch develops in the first 10 years of life^[9,28]. Flexible flatfeet rarely cause pain or disability in infancy and childhood. Children in this age group usually present for evaluation because of their parents' concern about the appearance of the feet or because of a family history of special shoe wearing during childhood^[1,11,29]. In some patients with general hyperlaxity, the flatfoot can be severe and deforms the shoe. Flatfeet can occasionally be painful, with more specific complaints after intense exercises or long walks. The pain is diffuse in the feet and lower legs^[1]. The researchers found that the adolescent patients who presented with a moderate to severe flatfoot demonstrated nearly double the rate of anterior knee pain and intermittent back pain^[9-10].

Etiology

Flatfoot (either flexible or rigid) may exist as an isolated pathology or as part of a larger clinical entity^[4]. These entities include generalized ligamentous laxity, neurologic and muscular abnormalities, genetic conditions and syndromes, and collagen disorders (Table 1)^[10].

Table 1: Etiology of pediatric flatfoot^[9-11]

Flexible	Rigid
Physiologic variant of normal	Traumatic
Limb rotation	Iatrogenic
Accessory navicular bone	Tarsal coalition
Obesity	Congenital vertical talus
Generalized ligamentous laxity	Peroneal spastic flat-foot
Neurologic disorders	
Cerebral palsy	
Hypotonia	
Muscular abnormalities	
Muscular dystrophy	
Genetic syndromes	
Osteogenesis imperfecta	
Marfan syndrome	
Down syndrome	
Collagen disorders	
Ehlers-Danlos	
Calcaneovalgus	
Other biomechanical causes	
Ankle equinus	
varus and valgus deformities	

Diagnosis

The first consideration, in the presentation, is the age of the patient. It is well understood that the longitudinal arch develops in the first 10 years of life and the prevalence of flatfeet correlates inversely with age. A second consideration is whether the foot is flexible or rigid. A flexible flatfoot deformity can be distinguished from a rigid one in that the flexible collapsed arch is present only when the patient bears weight, and then a normal medial longitudinal arch reappears in a toe stand or when the ankle is plantar flexed^[9]. The arch in rigid flat foot is fixed in a lowered position both with weight bearing and non-weight bearing^[1,9,14,29]. A rigid flatfoot is usually painful and caused by osseous or inflammatory disorders^[1].

It is clear that no general consensus exists on an ideal method for foot type classification. Existing methods of foot type classification based on foot morphology could be put into one of the 4 categories, including visual non-quantitative inspection, anthropometric values, footprint parameters and radiographic evaluation^[23,25].

To evaluate the height of the medial arch, indirect or direct methods can be used. Indirect approaches include footprint and direct methods include anthropometric and radiographic techniques^[30].

Visual assessment

The clinical assessment of a child with a flatfoot should consist of a general examination of the musculoskeletal system and walking pattern, in addition to the specific foot and ankle examination.

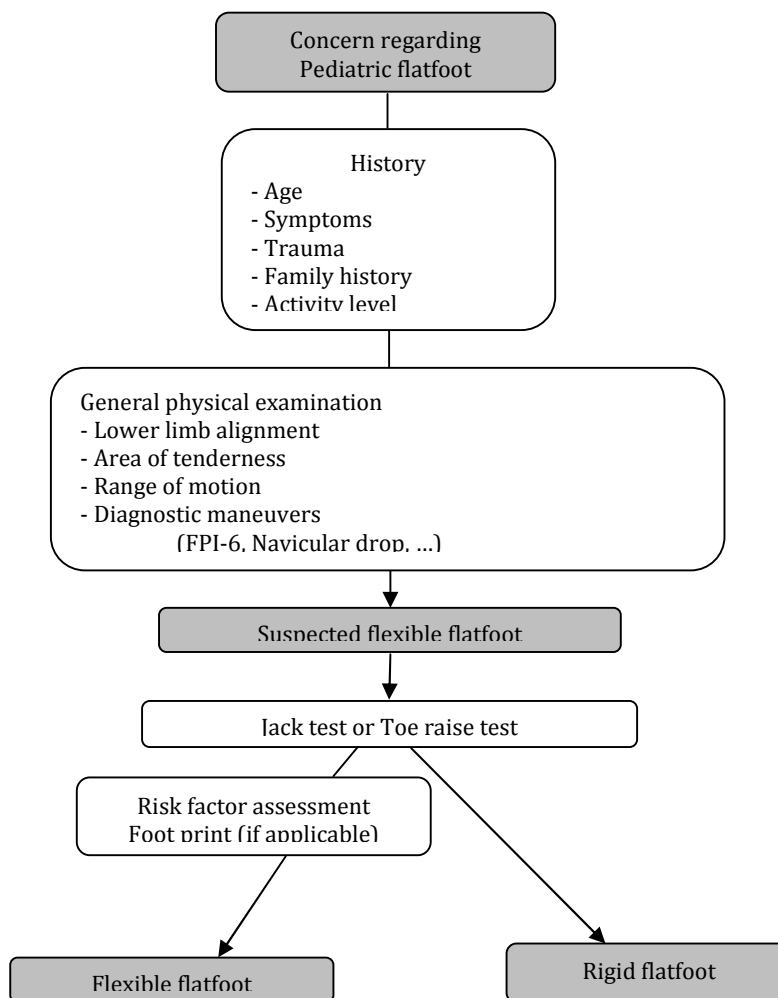


Fig. 3: Diagnostic algorithm for pediatric flatfoot

Assessment of the foot and ankle begins with evaluation of ankle dorsiflexion and plantarflexion (with knee extended and flexed) and rearfoot, midfoot, and forefoot ranges of motion. Assessment of Achilles tendon also is important and less than 10° of dorsiflexion indicates contracture of the Achilles tendon^[10-11]. The patient should be examined for evidence of generalized ligamentous laxity. Generalized joint laxity is easily evaluated using the Beighton scale^[23]. It is often rewarding to inquire about familial flatfeet and to examine the feet of other family members who are present in the examination room. Flexible flatfeet may cause rapid and uneven shoe attrition in older children and adolescents, so the shoes should be examined^[11]. As a part of the routine clinical examination of any foot problem, inspection can be made from front, sides and back of the foot in the non-weight-bearing and weight-bearing positions and during walking to observe presence or absence of foot curvatures. A podoscope provides more detailed evaluation by employing a mirror to show the contact area beneath the foot^[25].

Visual assessment is a simple method of evaluating the curvature and alignment of the foot, readily available to clinicians^[23,25]. A number of observational assessment scales have been developed to address the issue of the poor reliability of foot measures. Most recently the Foot Posture Index (FPI-6) has been developed for which normative values have now been collected^[20]. An evidence-based clinical tool for the evaluation of flatfoot sub-types is flatfoot clinical pathway or proforma (FFP). The FFP offers a structured checklist approach to significant clinical findings including arch shape, range of motion, tender areas, gait and diagnostic studies^[20]. The p-FFP is the shorter revised version that provides a practical standard by which pediatric flatfeet can be assessed and management broadly directed^[23].

Anthropometric assessment

Anthropometric approach to characterize the foot imply direct measurement of surface landmarks or bony prominences to depict the location and position of different structures within the foot, including the medial longitudinal arch (MLA).

Some well recognized anthropometric values in this approach include arch height, longitudinal arch angle, rearfoot angle, navicular drop and navicular drift^[23,25]. It seems that direct measurement of static arch height provides an objective approach to determine the differences in the foot structure. The prominent navicular bone generally represents the highest point of the MLA to the supporting surface^[9,25]. Navicular drop involves locating the navicular tuberosity on the non-weight-bearing foot and 50% weight bearing on the foot and then sagittal plane excursion of the navicular bone is measured by a ruler^[23,25]. Medial 'drift' of the navicular bone from neutral to resting stance position is measured by navicular drift in a way similar to navicular drop test and may provide a quantifiable indicator of the clinically observed 'medial bulging' associated with the pronated foot. Navicular drift reflects movements of the MLA in both the sagittal and frontal plane^[25].

Foot print

Although there are many methods currently being used to classify MLA structures, but the footprint is still the most popular approach to analyze and assess the MLA.

Three footprint measurements, the arch index, Chippaux-Smirak index, and Staheli arch index were most commonly used for clinical diagnosis^[31].

Arch index was calculated the ratio of the area of the middle third to the whole toeless footprint area. Staheli has characterized the width of the foot in the area of the arch and the heel, and the ratio between these widths was called the Staheli's arch index. Ratio of the maximum width of the metatarsals to the minimum width of the arch is known as the Chippaux-Smirak index (Fig. 1)^[13,31]. The above-mentioned measurements are regarded as reliable by many investigators and are recommended as screening tools for flatfoot.

Whilst clinical diagnoses based on the assessment of symptoms and signs tend to be subjective and require experienced clinicians, footprint analysis is a simple, quick, cost-effective, and readily available method for evaluation of flatfoot and has been recommended as a screening tool for flatfoot because of its convenience and efficiency^[31].

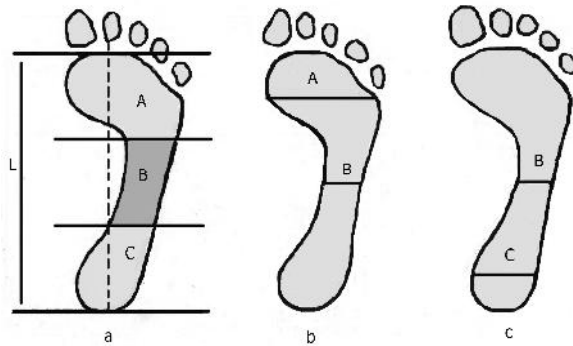


Fig. 1: Footprint analysis, a) Arch index, A-forefoot, B-midfoot, C-hindfoot, L- length of the foot. Arch index= $B/A+B+C$; b) Chippaux-Smirak index= $B/A \times 100\%$ c) Staheli arch index= $B/C \times 100\%$

Imaging studies

Imaging options may include radiographs (weight-bearing), computed tomography (CT) and magnetic resonance imaging (MRI)^[10].

Radiographs of the flexible flatfoot are not necessary for diagnosis, but they may be indicated to help with the assessment of uncharacteristic pain, decreased flexibility, and for surgical planning. Weight-bearing anteroposterior (AP) and lateral views of the foot are generally sufficient to evaluate the flexible flatfoot. The addition of the oblique and the axial views is necessary to evaluate the rigid and/or painful flatfoot such as tarsal coalition and accessory navicular bone^[9,11].

From the AP view, the talus-second metatarsal angle and the talo-navicular coverage angle were assessed^[32]. It is more difficult to interpret the AP radiograph than the lateral one^[11].

From the lateral view, the calcaneal inclination angle and the calcaneal first metatarsal angle were assessed. The calcaneal inclination angle is the angle between the inferior surface of the calcaneus and the supporting surface, the calcaneal-first metatarsal angle is the angle formed by the inferior surface of the calcaneus and a line parallel to the dorsum of the mid-shaft of the first metatarsal (Fig 2). Angles measured from the lateral view reflect sagittal plane alignment of the hindfoot and forefoot, with a lower calcaneal inclination angle and a greater calcaneal-first metatarsal angle indicating a flatter foot^[32].

MRI or CT scan is indicated if the joint range of motion in the subtalar or midfoot region is limited, and plain radiographs are negative for coalition because some coalitions are fibrous or

cartilaginous; therefore, they will not be visible on plain radiographs.

The CT scan is the gold standard used to diagnose a coalition, because it shows not only whether the coalition is osseous or non-osseous, but also the full extent of coalition and secondary degenerative joint disease.

MRI may be useful in surgical planning. MRI also can be used if the examiner suspects that the flatfoot is due to abnormalities in the posterior tibialis or peroneal tendons^[9].

There is controversy concerning the use of X-ray for measurement of the medial longitudinal arch of the foot. Staheli suggests that X-rays are only appropriate to determine the etiology of rigid flatfeet. Their low cost, excellent visual representation of osseous structure and relatively low radiation exposure may see their continued application for many years^[33]. Despite the presence of technical limitations, Benedetti et al believe that standard radiography of the foot may still be useful when surgical treatment is considered. Because radiographic measurements are not completely correlated to foot function, the presence of clinical and radiographic alterations should always be supported in addition by functional measures to distinguish feet that actually require treatment, particularly surgery^[34]. A summary of important diagnostic findings of flatfoot has been shown in Table 2.

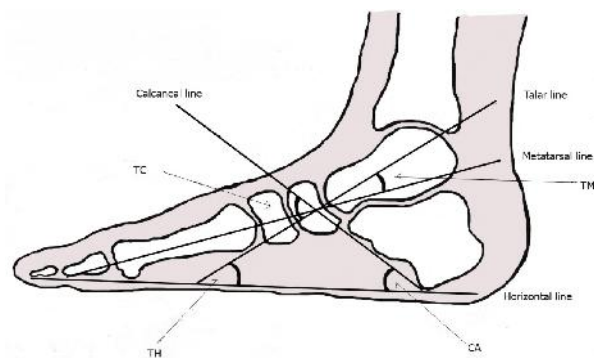


Fig. 2: Lateral radiograph of foot

TM, talo-first metatarsal angle; TH, talo-horizontal angle; TC, talocalcaneal angle; CA, calcaneal inclination angle

Management

Despite high prevalence of pediatric flatfoot, there is no universal agreement on proper treatment of

this disorder. Multiple controversies exist regarding appropriate management such as age to start treatment, due diagnostic procedures, the best intervention methods and effectiveness of each treatment measure^[11,23,35-38]. Based on current evidence in the literature for the management of flatfoot in children, it is of great importance to first categorize the patients in two groups of flexible or rigid flatfoot. As mentioned earlier, rigid flatfoot is usually related to the complicated bony deformities and mandates more detailed investigation. So, referral to orthopedic surgeons seems sensible. Flexible flatfoot can be further divided into asymptomatic and symptomatic.

Asymptomatic flexible flatfoot

Most flexible flatfeet are physiologic, asymptomatic, and require no treatment^[39-41]. Children with asymptomatic flexible flatfoot should be monitored clinically for onset of

symptoms and signs of progression. Continued progression requires reassessment to identify other underlying disease^[10]. As growth related changes of foot alignment and mobility will continue until approximately eight years of age^[42], it is anticipated that developmental problems resolve by this age^[14]. So, persistence of flatfoot in children older than 8 years necessitates further assessment, despite the lack of symptoms.

Symptomatic flexible flatfoot

In contrast to asymptomatic flexible flatfoot, symptomatic forms result in subjective complaints, deteriorate function, and produce substantial objective findings. Pain along the medial part of the foot; pain in the sinus tarsi, leg, and knee, diminished endurance, gait disorders, prominent medial talar head, everted heels, and heel cord tightness are among these findings^[10].

The physician should logically treat symptomatic flexible flatfeet with confidence as

Table 2: Summary of important findings

History
Age of onset
Symptoms
Family history
Trauma
Activity level
Physical examination
Inspection of arch (weight-bearing/non weight-bearing)
Ankle range of motion
Torsion deformity of lower extremity
-internal/external rotation of tibia
-genu varum/valgum
- femoral torsion
Ligamentous laxity
Tightness of Achilles tendon
Area of tenderness
Gait assessment
Diagnostic study
Imaging
-Radiography
-MRI
- CT scan
Foot print
Observational assessment scales
-FPI-6
-p-FFP
Anthropometric findings
-Arch height
-Longitudinal arch angle
-Rearfoot angle
-Navicular drop
-Navicular drift

this obviously requires intervention. The mode of treatment is less straight-forward, but can be fairly assessed against resolution of symptoms in most cases^[35].

Initial treatment options include activity modification, proper shoe and orthoses, stretching and strengthening exercises and nonsteroidal anti-inflammatory medications (in more severe cases). Furthermore, comorbidities such as obesity, ligamentous laxity, hypotonia, and proximal limb problems, must be identified and managed, if

possible^[10].

If there is a positive clinical response and symptoms are settled, follow-up observations are recommended. If clinical response is not acceptable, reassessment and additional work-ups are indicated. When all nonsurgical treatment options fail, surgery can be considered^[10,39,43-44]. A summary of algorithmic approach to pediatric flatfoot is shown in Fig. 4.

In the next section, we will address common treatment options in detail.

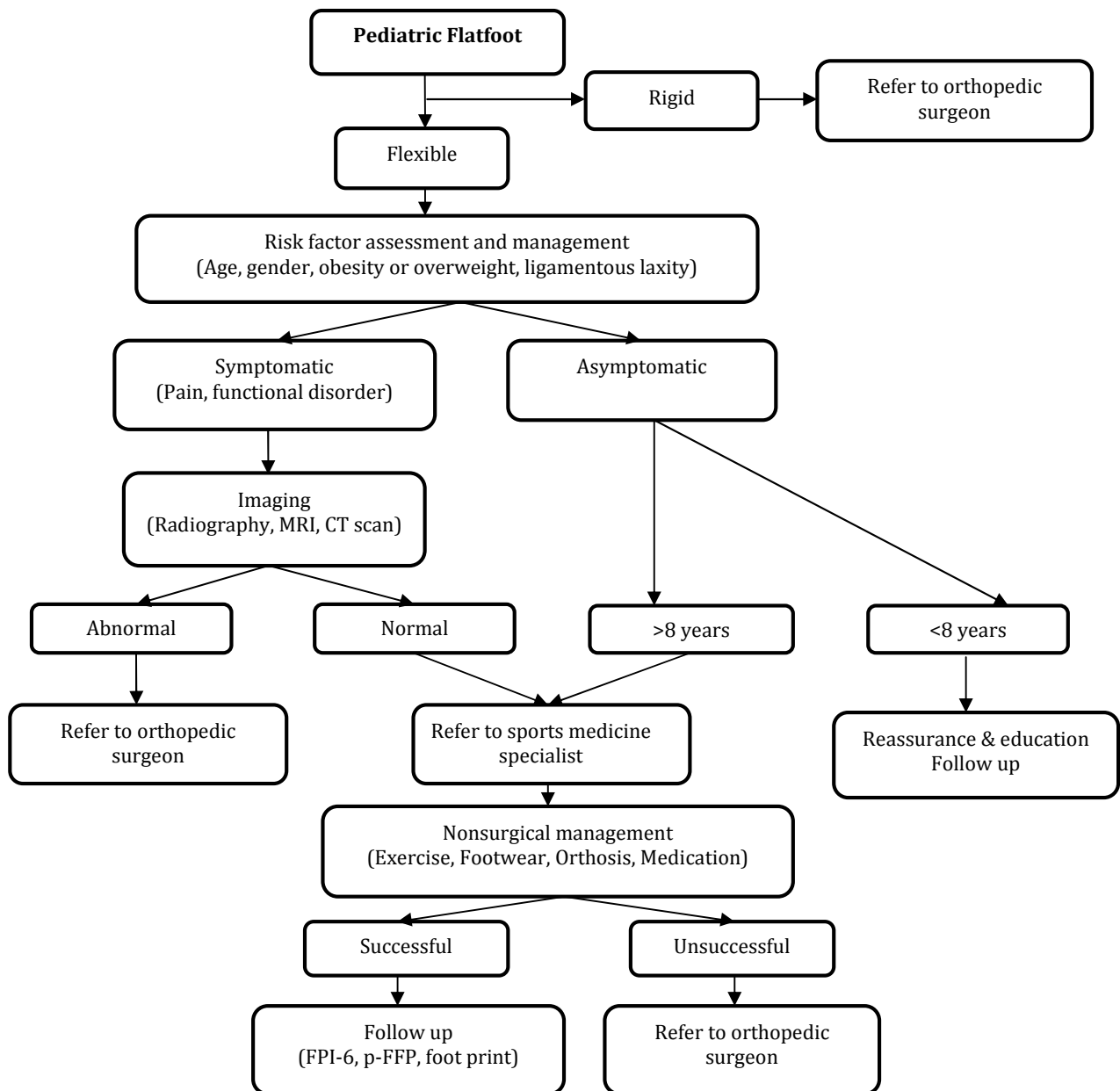


Fig. 4: Algorithmic approach to pediatric flatfoot

Nonsurgical interventions

The current evidence originating from randomized controlled trials is too scarce to result in definitive conclusions about the non-surgical interventions for pediatric flatfoot. Further high quality studies are needed in this field. Nowadays, a few studies have investigated the common interventions used in practice and there is much debate over the treatment of symptomatic and asymptomatic flatfoot. There are many types of non-surgical treatments for the pain and disability caused by flatfeet such as advice and education, footwear selection and modifications, foot orthoses (shoe inserts), exercise including stretching and strengthening, and medication for pain and inflammation^[36].

Unfortunately, critical evaluation of the evidence regarding the effect of non-surgical interventions on flexible pediatric flatfoot draws no definitive conclusions.

Advice and education

The conservative management of flexible flatfoot begins with education of the patient and the parents^[45]. Patients and their parents alike should be counseled regarding the facts that the flat foot deformity may resolve with maturation (depending on the age of the patient and any underlying conditions) and that there exists no evidence that this deformity will lead to a painful condition in adulthood^[46].

Education should consist of the biomechanical findings that support the diagnosis of flatfoot and the purpose of corrective devices if used. Different severities of deformity are present ranging from mild to the very severe symptomatic flatfoot^[45]. Most flexible flatfeet are physiologic, asymptomatic, and require no treatment^[39-40]. Concerned parents should be notified that physiologic flexible flatfoot follows a natural history of improvement over time. Periodic observation may be indicated to monitor for signs of progression^[41]. Normal development and strengthening of the foot may be all the treatment indicated^[45].

However, parents should be aware that non-physiologic flexible flatfoot is characterized by progression over time and the degree of deformity is more severe. Periodic observation is indicated in these cases^[10].

Footwear selection

Recommending proper supportive shoe is a valuable first-line intervention in the flexible flatfoot. Typically, an enclosed sneaker may provide structural support to the skeletally immature foot. The sneaker should comfortably support an orthotic device if that is to be the next intervention. The shoe should have a firm sole to prevent the orthosis from compressing the medial side of the shoe^[45,47].

High-top sneakers may be indicated if a large amount of instability is detected within the ankle and subtalar joints. Certain types of shoes such as sandals and moccasin styles should be avoided because they may fail to offer the structural support that the skeletally immature patient needs^[45].

It is noteworthy that, in the past, the nonsurgical treatment insisted on the use of orthopedic footwear and insoles. However, despite any therapeutic benefits they may have brought, orthopedic footwear unfortunately molds not only the feet but also the personality of the child wearing them. Nowadays, it is agreed worldwide that orthopedic footwear do not influence the natural development of the foot^[5,17,48-49].

Foot orthotics

One of the primary conservative interventions for pediatric flatfoot is in-shoe foot orthoses and arch supports^[5,23,50]. Many authors doubt the effectiveness of using orthotics and are of the opinion that childhood flatfoot resolves spontaneously with age without further treatment^[5].

In this section, we aim to answer common questions regarding foot orthosis.

A) How effective are orthoses?

There is no evidence of immediate effect of foot orthoses or orthopedic footwear on radiographic parameters of foot posture in children with flatfoot but there are some improvements over time^[23].

Studies have demonstrated that although orthotic supports may aid to correct soft tissue deformities, the underlying bony structure is unchanged. Many authors studied the effects of an over-the-counter insert and molded foot orthosis in children, and found no radiographic improvement in flat foot deformity compared with the bare foot^[11,46].

Some studies found an immediate improvement in the resting calcaneal stance position (RCSP) as a measure of static foot posture of the supported foot. Dynamic stabilizing insoles and customized foot orthoses which were adjusted to correct the RCSP to vertical position had significantly positive effects. Improvement of footprint measures and RCSP over time was also observed as an effect of foot orthoses^[23].

The strongest support against the routine use of orthotics came from Wenger et al, who performed a prospective study on 129 children with flatfoot and compared a control group, a corrective shoe group, a Helfet heel cup group, and a custom-made plastic insert (University of California Biomechanics Laboratory) group. After 3 years follow-up, radiographic and clinical examinations show improvement of all patients with no significant differences in the treated groups compared with the control group^[11,46,51].

In general, it is believed that asymptomatic flatfoot requires no foot orthosis and no evidence indicates that early use of them will prevent the development of symptomatic flatfoot^[11,22]. However, prescription of orthosis in symptomatic flexible flatfoot may be beneficial to resolve pain and keep away from surgical intervention^[45,52].

Wearing foot orthoses has a significant improvement in foot pain and function over time. Despite the absence of curative data, custom molded foot orthoses, the University of California at Berkeley Laboratory (UCBL) orthotic device and heel stabilizers which are designed to provide medial arch support and reduce hyperpronation, were effective in controlling pain in children who received them^[9,23,35,36].

There is general acceptance in the literature with respect to the clinical effectiveness of orthotic devices among runners. The use of foot orthotics has been positively associated with patient satisfaction and pain reduction^[50,52].

The effects of over the counter silicone insoles on gait pattern were evaluated by Kulcu et al^[53] and no beneficial effect was found in normalizing forces acting on the foot and the entire lower extremity.

B) What is their mechanism of action?

Application of dynamic foot orthoses in the pediatric flexible flatfoot helps restore structure and support to the medial and lateral column of

the foot. One of the main purposes of using functional orthoses is to control the amount of subtalar joint pronation, thereby restoring the support and alignment to the talocalcaneal joint. Either increasing the supination moment or decreasing the pronation moment will achieve the desired results^[8,45,47,50,54].

Tibialis posterior muscle is an essential stabilizer of the foot during standing and walking. Use of arch-supporting foot orthoses may augment selective activation of the muscle and have a positive impact on the foot function^[55-57].

C) Who will benefit and when?

Currently, orthotic prescription is suggested for patients with symptomatic flexible flatfoot in order to control the excessive motion of the lower extremity^[46,50]. Given the lack of evidence to support the prescription of customized foot orthoses in asymptomatic children, abandonment of this method is important^[35].

For the more severe flatfoot deformity or ligamentous laxity in patients with ankle instability or posterior tibial tendon symptoms, an ankle-foot orthoses (AFO) or a more proximal device can be more appropriate^[45,58]. If there is equinus deformity in which ankle joint range of motion is restricted, specific devices such as rocker bottom shoe soles, torque absorbing AFOs, and proximal weight-bearing AFOs can be used. These devices facilitate the transmission of deforming forces onto external materials and aid normal ground reactive forces through corrected functional anatomy and alignment^[45].

The orthotic device considered for pediatric patients must have the following characteristics: a) it should conform to the intrinsic and extrinsic structural deformities, b) prepare rigidity for control but accommodate the natural foot shape, c) generate postural alignment of the foot to the leg and d) improve the patient-orthoses interface. This device typically can be used in the first few years when the child starts to walk^[45,54,59].

D) What kinds are more suitable?

Well designed prefabricated devices aimed at reducing abnormal motion and stabilization of rear foot may have a role in managing mild cases particularly in younger patients. Inexpensive orthoses such as an off-the-shelf medial arch support are quite appropriate for early

management and can provide good positional support of the child's flatfoot and relief of symptoms^[35,46,58,60]. In more severe cases with biomechanical abnormalities and other comorbidities or those that fail the aforementioned modalities, a custom made orthosis gives somewhat promising improvement. Custom orthotics are often made from a casted or scanned model of the foot and aim to neutralize and reduce many of the structural influences that lead to compensation within the foot^[46,58,61].

The UCBL is an example of a device that can control the flexible flatfoot deformity representing hyperpronation and is used early in the child's life. The advantage of the UCBL orthotic device is its high medial and lateral borders which provide control of the rearfoot and midfoot complexes, especially when increased transverse plane deformity is seen^[45,54].

Compliance to these devices is an issue and requires explanation and education to the parents. An argument of how the orthotics function to provide realignment and support the foot is beneficial for parents to understand why such a treatment is essential. The use of visual aids, such as skeleton foot model can reveal the ability of the device to confine the foot and prevent arch collapse^[45].

Exercise

Exercise for flatfeet, in the form of barefoot walking and also prescribed activities have also been used^[23].

The main focus of exercise program is on stretching tight structures, strengthening the weak components and improving proprioception and postural balance.

Passive stretching of the Achilles tendon should be done if an equinus deformity is present, and the stretching is recommended as a part of the non-surgical approach to flexible flatfoot. Equinus may be a significant deforming force in the sagittal plane and also affect the frontal and transverse plane position. Statically and dynamically, an equinus contracture can lead to collapse of the midfoot, clinically seen as arch flattening and midfoot abduction^[45]. Multiple stretching exercises for Achilles tendon can be easily taught to the patient. Some authors believe that active strengthening exercises may not offer any benefit to an equinus disorder unless a muscle weakness is obvious^[45].

However, Riccio et al have shown that using proper rehabilitation exercises may enhance the effectiveness of treatment in pediatric flexible flatfoot (Table 3)^[48].

NSAIDs

Nonsteroidal anti-inflammatory drugs may be prescribed if any evidence of inflammation is present. Medial column collapse and strain may present as an inflammatory process and justify the use of anti-inflammatory drugs in conjunction with rest and ice to relieve the symptoms. Apophysitis is common in the skeletally immature children and requires same treatment^[45].

Table 3: Exercises and activities for flexible flatfoot

Aim	Exercises and activities
Flexibility	Passive ROM exercise of ankle and all foot joints Global movement (to approximate anterior and posterior foot columns) Stretching of gastrocnemius soleus complex and peroneus brevis muscles (to induce varus and adduction of the foot).
Strengthening	Anterior and posterior tibialis muscles and the flexor hallucis longus (to neutralize valgus) Intrinsic, interosseus plantaris muscles and the abductor hallucis (to prevent anterior arch flattening) Global activation/movement of the muscles involved in maintaining the medial longitudinal arch and the varus with and without load Single leg weight bearing Toe walking
Proprioception and balance	Toe and heel walking Single leg weight bearing (to make the foot cavus after dynamic pronation of the forefoot) Descending an inclined surface

Surgical Intervention

The consensus of opinion suggests that if conservative methods have failed, and the child does not have relief of symptoms, surgery is indicated^[23,44]. However, physician should not be swayed into operative treatment based on the requests of the parents to have a child with a straight foot^[46].

The goals of surgery are simple: pain reduction or resolution and realignment of the foot. Although achieving these goals may be difficult because there are such a wide variety of clinical presentations ranging from mild to severe flatfoot with a multitude of planal dominance contributions, surgical realignment may be challenging^[45].

Surgical management of the flexible flatfoot can be grouped into 3 types of reconstructive procedures, arthrodesis, and arthroereisis^[10,16,46].

A) Reconstructive procedures: These are further divided to soft tissue and bone techniques. Soft tissue procedures usually involve the Achilles tendon, posterior tibialis tendon, and peroneal tendons. The Achilles tendon can be lengthened for Achilles contractures. Depending on the area of contracture, a gastrocnemius recession or Achilles tendon lengthening may be considered. Several procedures have been described that aim to displace the insertion of the posterior tibialis tendon^[46]. However, it should be remembered that soft tissue reconstruction of the flexible flatfoot is rarely successful as an isolated procedure and a combination of soft tissue and bone procedures are often selected^[43,62].

Bony procedures include rearfoot, midfoot, and forefoot osteotomies. Depending on the plane of dominance of the deformity, lateral column lengthening and/or medial displacement osteotomy of the posterior calcaneus may be used^[63]. Although outstanding outcomes from surgical treatment of flatfoot have been described, questions remain regarding successful long-term correction^[41].

B) Arthrodesis: Arthrodesis of the rearfoot has also been described for treatment of symptomatic flexible flatfoot^[64-65]. Subtalar arthrodesis is typically performed as the primary procedure^[66]. Triple arthrodesis is reserved as a salvage technique for formerly failed surgical treatment. Although arthrodesis provides a stable foot and

long-lasting correction, eventual transfer of energy to the nonfused joints adjacent to the fusion is of concern.

C) Arthroereisis: This procedure involves insertion of a spacer into the sinus tarsi to restrict subtalar joint pronation^[67]. Proponents of this procedure believe that it is a minimally invasive technique that does not alter the normal anatomy of the foot^[68-70]. Others have expressed concern about placing a permanent foreign body into a mobile segment of a child's foot. The indication for this type of surgery remains controversial in the literature^[71].

If surgical intervention is successful in producing a functional painless result, the child should be further treated by periodic observation and appropriate orthoses. If surgery fails, salvage through appropriate intraarticular or extraarticular arthrodesis is suitable^[10].

Conclusion

Although flexible flatfoot is one of the main causes of visits for pediatric foot problems, there is no consensus on its diagnosis and management. Majority of flexible flatfeet are physiologic, asymptomatic and require no treatment. Otherwise, the clinician should manage symptomatic flexible flatfeet. Initial options include activity modification, appropriate shoe and orthoses, exercises and medications. When all nonsurgical treatment options fail, surgery may be considered.

Conflict of Interest: None

References

1. Fabry G. Clinical practice. Static, axial, and rotational deformities of the lower extremities in children. *Eur J Pediatr* 2010; 169(5):529-34.
2. Evans AM, Rome K, Peet L. The foot posture index, ankle lunge test, Beighton scale and the lower limb assessment score in healthy children: a reliability study. *J Foot Ankle Res* 2012; 5(1):1.
3. Krul M, van der Wouden JC, Schellevis FG, et al. Foot problems in children presented to the family physician: a comparison between 1987 and 2001. *Fam Pract* 2009; 26(3):174-9.

4. Lin CJ, Lai KA, Kuan TS, et al. Correlating factors and clinical significance of flexible flatfoot in preschool children. *J Pediatr Orthop* 2001; 21(3): 378-82.
5. Pfeiffer M, Kotz R, Ledl T, et al. Prevalence of flat foot in preschool-aged children. *Pediatrics* 2006; 118(2):634-9.
6. Shih YF, Chen CY, Chen WY, et al. Lower extremity kinematics in children with and without flexible flatfoot: a comparative study. *BMC Musculoskeletal Disord* 2012; 13:31.
7. Lee JH, Sung IY, Yoo JY. Clinical or radiologic measurements and 3-D gait analysis in children with pes planus. *Pediatr Int* 2009; 51(2):201-5.
8. Chen YC, Lou SZ, Huang CY, Su FC. Effects of foot orthoses on gait patterns of flat feet patients. *Clin Biomech (Bristol, Avon)* 2010; 25(3):265-70.
9. Yagerman SE, Cross MB, Positano R, Doyle SM. Evaluation and treatment of symptomatic pes planus. *Curr Opin Pediatr* 2011; 23(1):60-7.
10. Harris EJ, Vanore JV, Thomas JL, et al. Diagnosis and treatment of pediatric flatfoot. *J Foot Ankle Surg* 2004; 43(6):341-73.
11. Mosca VS. Flexible flatfoot in children and adolescents. *J Child Orthop* 2010; 4(2):107-21.
12. Moraleda L, Mubarak SJ. Flexible flatfoot: differences in the relative alignment of each segment of the foot between symptomatic and asymptomatic patients. *J Pediatr Orthop* 2011; 31(4): 421-8.
13. Mickle KJ, Steele JR, Munro BJ. The feet of overweight and obese young children: are they flat or fat? *Obesity (Silver Spring)* 2006; 14(11): 1949-53.
14. Nemeth B. The diagnosis and management of common childhood orthopedic disorders. *Curr Probl Pediatr Adolesc Health Care* 2011; 41(1):2-28.
15. Rodriguez N, Choung DJ, Dobbs MB. Rigid pediatric pes planovalgus: conservative and surgical treatment options. *Clin Podiatr Med Surg* 2010; 27(1):79-92.
16. Labovitz JM. The algorithmic approach to pediatric flexible pes planovalgus. *Clin Podiatr Med Surg* 2006; 23(1):57-76.
17. Mickle KJ, Steele JR, Munro BJ. Is the foot structure of preschool children moderated by gender? *J Pediatr Orthop* 2008; 28(5):593-6.
18. Vanstony M, Chambliss ML, Mackler L. How should you treat a child with flat feet? *J Fam Practice* 2010; 59(6):360c-e.
19. Chen CH, Huang MH, Chen TW, et al. The correlation between selected measurements from footprint and radiograph of flatfoot. *Arch Phys Med Rehabil* 2006; 87(2):235-40.
20. Evans AM, Nicholson H, Zakarias N. The paediatric flat foot proforma (p-FFP): improved and abridged following a reproducibility study. *J Foot Ankle Res* 2009; 2:25.
21. Chang JH, Wang SH, Kuo CL, et al. Prevalence of flexible flatfoot in Taiwanese school-aged children in relation to obesity, gender, and age. *Eur J Pediatr* 2010; 169(4):447-52.
22. Mortazavi SMJ, Espandar R, Baghdadi T. Flatfoot in children: How to approach? *Iran J Pediatr* 2007; 17(2):163-70.
23. Evans AM, Rome K. A Cochrane review of the evidence for non-surgical interventions for flexible pediatric flat feet. *Eur J Phys Rehab Med* 2011; 47(1):69-89.
24. Abolarin T, Aiyegbusi A, Tella A, et al. Predictive factors for flatfoot: The role of age and footwear in children in urban and rural communities in South West Nigeria. *Foot (Edinb)* 2011; 21(4):188-92.
25. Rzeghi M, Batt ME. Foot type classification: a critical review of current methods. *Gait Posture* 2002;15(3):282-91.
26. Sachithanandam V, Joseph B. The influence of footwear on the prevalence of flat foot. A survey of 1846 skeletally mature persons. *J Bone Joint Surg Br* 1995;77(2):254-7.
27. Rao UB, Joseph B. The influence of footwear on the prevalence of flat foot. A survey of 2300 children. *J Bone Joint Surg Br* 1992; 74(4):525-7.
28. Herrera-Soto JA. Pediatric foot and ankle disorders. *Curr Opin Orthop* 2004;15(6):417-22.
29. Houghton KM. Review for the generalist: evaluation of pediatric foot and ankle pain. *Pediatr Rheumatol Online J* 2008; 6:6.
30. Kanatli U, Yetkin H, Cila E. Footprint and radiographic analysis of the feet. *J Pediatr Orthop* 2001;21(2):225-8.
31. Chen K-C, Yeh C-J, Kuo J-F, et al. Footprint analysis of flatfoot in preschool-aged children. *Eur J Pediatr* 2011;170(5):611-7.
32. Murley GS, Menz HB, Landorf KB. A protocol for classifying normal- and flat-arched foot posture for research studies using clinical and radiographic measurements. *J Foot Ankle Res* 2009;2:22.
33. Metcalfe SA, Bowling FL, Baltzopoulos V, et al. The reliability of measurements taken from radiographs in the assessment of paediatric flat foot deformity. *Foot (Edinb)* 2012;22(3):156-62.
34. Benedetti MG, Berti L, Straudi S, et al. Clinicoradiographic assessment of flexible flatfoot in children. *J Am Podiatr Med Assoc* 2010;100(6):463-71.
35. Evans AM. The flat-footed child - To treat or not to treat - What is the clinician to do? *J Am Podiatr Med Assoc* 2008; 98(5):386-93.
36. Rome K, Ashford RL, Evans A. Non-surgical interventions for paediatric pes planus. *Cochrane Database Syst Rev* 2010; (7):CD006311.
37. Rodriguez N, Volpe RG. Clinical diagnosis and assessment of the pediatric pes planovalgus deformity. *Clin Podiatr Med Surg* 2010; 27(1):43-58.
38. Rose REC. Flat feet in children: When should they be treated. *Internet J Orthop Surg* 2007;6(1).
39. Cappello TMD, Song KMMD. Determining treatment of flatfeet in children. *Curr Opin Pediatr* 1998; 10(1):77-81.

40. Sullivan JA. Pediatric flatfoot: evaluation and management. *J Am Acad Orthop Surg* 1999;7(1):44-53.
41. Staheli L. Planovalgus foot deformity. Current status. *J Am Podiatr Med Assoc* 1999;89(2):94-9.
42. Evans AM. Pediatrics. The Pocket Podiatry Guide. 1st ed. New York, NY: Churchill Livingstone Elsevier. 2010.
43. Cohen-Sobel E, Giorgini R, Velez Z. Combined technique for surgical correction of pediatric severe flexible flatfoot. *J Foot Ankle Surg* 1995;34(2):183-94.
44. Roye DP Jr, Raimondo RA. Surgical treatment of the child's and adolescent's flexible flatfoot. *Clin Podiatr Med Surg* 2000; 17(3):515-30, vii-viii.
45. Blitz NM, Stabile RJ, Giorgini RJ, et al. Flexible pediatric and adolescent pes planovalgus: conservative and surgical treatment options. *Clin Podiatr Med Surg* 2010; 27(1):59-77.
46. Kwon JY, Myerson MS. Management of the flexible flat foot in the child: a focus on the use of osteotomies for correction. *Foot Ankle Clin* 2010; 15(2): 309-22.
47. Kirby KA. The medial heel skive technique. Improving pronation control in foot orthoses. *J Am Podiatr Med Assoc* 1992; 82(4):177-88.
48. Riccio I, Gimigliano F, Gimigliano R, et al. Rehabilitative treatment in flexible flatfoot: a perspective cohort study. *Chir Organi Mov* 2009; 93(3):101-7.
49. Staheli LT, Chew DE, Corbett M. The longitudinal arch. A survey of eight hundred and eighty-two feet in normal children and adults. *J Bone Joint Surg Am* 1987; 69(3):426-8.
50. Perry SD, Cunningham EA, Goodwin KM. Orthotics: Management of functional flat foot. *Lower Extremity Review* 2009;1:57-61.
51. Wenger DR, Mauldin D, Speck G, et al. Corrective shoes and inserts as treatment for flexible flatfoot in infants and children. *J Bone Joint Surg Am* 1989; 71(6):800-10.
52. Landorf KB, Keenan AM. Efficacy of foot orthoses. What does the literature tell us? *J Am Podiatr Med Assoc* 2000; 90(3):149-58.
53. Kulcu DG, Yavuzer G, Sarmer S, et al. Immediate effects of silicone insoles on gait pattern in patients with flexible flatfoot. *Foot Ankle Int* 2007; 28(10):1053-6.
54. Jay RM, Schoenhaus HD, Seymour C, et al. The Dynamic Stabilizing Innersole System (DSIS): the management of hyperpronation in children. *J Foot Ankle Surg* 1995;34(2):124-31.
55. Kulig K, Burnfield JM, Reischl S, et al. Effect of foot orthoses on tibialis posterior activation in persons with pes planus. *Med Sci Sports Exerc* 2005;37(1): 24-9.
56. Murley GS, Landorf KB, Menz HB. Do foot orthoses change lower limb muscle activity in flat-arched feet towards a pattern observed in normal-arched feet? *Clin Biomech (Bristol, Avon)* 2010;25(7):728-36.
57. Neville CG, Houck JR. Choosing among 3 ankle-foot orthoses for a patient with stage II posterior tibial tendon dysfunction. *J Orthop Sports Phys Ther* 2009; 39(11):816-24.
58. Blitz NM. Pediatric and adolescent flatfoot reconstruction in combination with middle facet talocalcaneal coalition resection. *Clin Podiatr Med Surg* 2010; 27(1):119-33.
59. Valmassy R. Torsional and frontal plane conditions of the lower extremity. In: Thomson P, Volpe R(eds). Introduction to Podopediatrics. 2nd ed. New York: Churchill Livingstone; 2001:231-55.
60. Hurd WJ, Kavros SJ, Kaufman KR. Comparative biomechanical effectiveness of over-the-counter devices for individuals with a flexible flatfoot secondary to forefoot varus. *Clin J Sport Med* 2010; 20(6):428-35.
61. Bordelon RL. Hypermobile flatfoot in children: Comprehension, evaluation, and treatment. *Clin Orthop Relat Res* 1983;181:7-14.
62. el-Tayeby HM. The severe flexible flatfoot: a combined reconstructive procedure with rerouting of the tibialis anterior tendon. *J Foot Ankle Surg* 1999;38(1):41-9.
63. Benthien RA, Parks BG, Guyton GP, et al. Lateral column calcaneal lengthening, flexor digitorum longus transfer, and opening wedge medial cuneiform osteotomy for flexible flatfoot: a biomechanical study. *Foot Ankle Int* 2007;28(1):70-7.
64. Turriago CA, Arbelaez MF, Becerra LC. Talonavicular joint arthrodesis for the treatment of pes planus valgus in older children and adolescents with cerebral palsy. *J Child Orthop* 2009;3(6):501-2.
65. Chou LB, Halligan BW. Treatment of severe, painful pes planovalgus deformity with hindfoot arthrodesis and wedge-shaped tricortical allograft. *Foot Ankle Int* 2007;28(5):569-74.
66. Kitaoka HB, Patzer GL. Subtalar arthrodesis for posterior tibial tendon dysfunction and pes planus. *Clin Orthop Relat Res* 1997;345:187-94.
67. Needleman RL. Current topic review: subtalar arthroereisis for the correction of flexible flatfoot. *Foot Ankle Int* 2005;26(4):336-46.
68. Viladot A. Surgical treatment of the child's flatfoot. *Clin Orthop Relat Res* 1992;283:34-8.
69. Nelson SC, Haycock DM, Little ER. Flexible flatfoot treatment with arthroereisis: radiographic improvement and child health survey analysis. *J Foot Ankle Surg* 2004;43(3):144-55.
70. Koning PM, Heesterbeek PJ, de Visser E. Subtalar arthroereisis for pediatric flexible pes planovalgus: fifteen years experience with the cone-shaped implant. *J Am Podiatr Med Assoc* 2009;99(5):447-53.
71. Metcalfe SA, Bowling FL, Reeves ND. Subtalar joint arthroereisis in the management of pediatric flexible flatfoot: a critical review of the literature. *Foot Ankle Int* 2011; 32(12):1127-39.

CME Questions

1. What is the most common form of flatfoot in children?
A) Symptomatic flexible flatfoot
B) Asymptomatic flexible flatfoot
C) Symptomatic rigid flatfoot
D) Asymptomatic rigid flatfoot

2. Which is the first step in the assessment of a child with flatfoot?
A) Physical examination
B) Radiography
C) Foot print
D) MRI

3. Which intervention is recommended for a 5- year child with asymptomatic flexible flatfoot?
A) Advice and reassurance
B) Prefabricated orthosis
C) Custom-made orthosis
D) Constant shoe wearing

4. Stretching exercises of all following muscles are highly recommended in flexible flatfoot, except:
A) Gastrocnemius
B) Soleus
C) Anterior tibialis
D) Proneus brevis

5. A ten year old boy with painful foot is referred to your office. The pain aggravates after physical activity and relieves with rest. What is your recommendation for treatment?
A) No treatment
B) Ankle-foot orthosis
C) Custom-made orthosis
D) Prefabricated foot orthosis

Answers:

1- B 2- A 3- A 4- C 5- D