

Pediatric Herpes Simplex Virus Encephalitis Complicated by *N*-Methyl-*D*-aspartate Receptor Antibody Encephalitis

Alasdair Bamford,^{1,3} Belinda H. A. Crowe,² Yael Hacoen,⁴ Jean-Pierre Lin,⁵ Antonia Clarke,⁶ Gareth Tudor-Williams,^{1,3} Vanessa Sancho-Shimizu,³ Angela Vincent,⁴ Ming Lim,^{4,5,†} and Sunil P. Pullaperuma^{2,†}

¹Department of Paediatric Infectious Diseases; ²Paediatric Neurodisability Service, St Mary's Hospital, Imperial College Healthcare NHS Trust, London, United Kingdom; ³Section of Paediatrics, Imperial College, London, United Kingdom; ⁴Nuffield Department of Clinical Neurosciences, John Radcliffe Hospital, University of Oxford, United Kingdom; ⁵Children's Neurosciences, Evelina London Children's Hospital, Guy's and St Thomas' NHS Foundation Trust, London, United Kingdom; and ⁶Department of Paediatric Neurology, St George's Hospital, St George's Hospital NHS Trust, London, United Kingdom

Corresponding Author: Ming Lim, PhD, Children's Neurosciences, Evelina London Children's Hospital, Guy's and St Thomas' NHS Foundation Trust, King's Health Partners Academic Health Science Centre, Lambeth Palace Road, London SE1 7EH, UK. E-mail: ming.lim@gstt.nhs.uk.

[†]M. L. and S. P. P. contributed equally to this work.

Received February 14, 2014; accepted May 2, 2014; electronically published June 12, 2014.

N-methyl-*D*-aspartate receptor antibodies (NMDAR-Abs) can contribute to neurological relapse after herpes simplex virus encephalitis (HSE). We describe a child with NMDAR-Ab encephalitis after HSE, which was recognized and treated early. We discuss the case in the context of existing reports, and we propose a modified immunotherapy strategy to minimize risk of viral reactivation.

Key words. encephalitis; HSV; NMDAR; pediatric; plasmapheresis.

BACKGROUND

Herpes simplex virus (HSV) is a common cause of infectious encephalitis in children [1, 2] with potentially devastating consequences including severe developmental impairment and neurodisability [3]. Intravenous (IV) aciclovir is a well established effective therapy [4]. The use of adjunctive steroids is controversial; however, evidence exists in support of potential benefit, suggesting a role of inflammation in addition to direct viral effects in disease pathogenesis [4].

Neurological relapse in the weeks or months after primary HSV encephalitis (HSE) is well described in children and adults (reviewed in [5]). In a subset of children presenting with biphasic illness, the second stage is characterized by predominant movement disorder but negative cerebrospinal fluid (CSF) HSV polymerase chain reaction (PCR) and stable brain magnetic resonance imaging (MRI) findings [6]. Clinical characteristics of these children during relapse resemble the acute stage of *N*-methyl-*D*-aspartate receptor antibody (NMDAR-Ab) encephalitis (dyskinesia, autonomic disturbance, seizures) [7, 8]. In recent studies, a

handful of predominantly pediatric cases of neurological relapse after HSE were reported to be associated with NMDAR-Abs [5, 9, 10].

In this study, we report a pediatric case in which post-HSE NMDAR-Ab-associated relapse, characterized by severe encephalopathy and movement disorder, was recognized early. Immunomodulatory treatment was initiated with the aim of limiting disease progression and optimizing potential for neurorehabilitation.

CASE REPORT

A previously well, developmentally normal, 16-month-old girl presented in Pakistan with lethargy and afebrile focal seizures. After treatment with ceftriaxone and diazepam, she was discharged on day 6 and given sodium valproate. On day 7, she developed fever and additional focal seizures involving the right arm. A computed tomography scan of the brain demonstrated extensive right-sided infarction. Intravenous aciclovir was commenced (at a suboptimal daily dose of 750 mg/m²). Seizures were controlled with phenytoin then phenobarbitone. She was intubated for

neuroprotection, remaining ventilated for 6 days. On day 16, lumbar puncture revealed CSF protein 76 mg/dL and 12 white blood cell/ μ L (mononuclear) with positive HSV-1 DNA PCR. An electroencephalogram (EEG) demonstrated no epileptiform activity.

On day 21, on transfer to the United Kingdom for further management, there was ongoing encephalopathy, left hemiparesis, and evolving right-sided movement disorder. An MRI scan of the brain demonstrated extensive right-sided encephalomalacia with complete destruction of the parietal and temporal lobes (Figure 1A–C). Aciclovir dose was optimized to 1500 mg/m² per day. Abnormal movements responded to trihexyphenidyl and clonidine, until deterioration on day 45, with florid orolingual and facial dyskinesia, dystonia, and right-sided ballismus. Fever, marked developmental regression and encephalopathy ensued. High titer NMDAR-Abs were detected in serum (1:1000) and CSF (1:50), whereas blood and CSF HSV PCRs were negative. Serum anti-aquaporin 4, antimyelin oligodendrocyte glycoprotein, and antidopamine D2 receptor antibodies were negative. On day 55, EEG tests still did not show seizure activity nor reported features of NMDAR-Ab encephalitis [11].

The patient completed 5 cycles of plasmapheresis between day 57 and day 61, with significant improvement in movement disorder severity and a reduction in serum NMDAR-Abs (1:200). An MRI scan on day 71 demonstrated minimal parenchymal progression but persistent leukoencephalopathy (Figure 1D–F). Dystonia and agitation increased and a second cycle of plasmapheresis was performed on days 86–90, with further clinical improvement and reduction in serum antibody titer to 1:20.

Five months after initial presentation, the patient is at home and undergoing intensive neurorehabilitation. She remains on suppressive oral aciclovir and a combination of medications that prevent seizures and manage her movement disorder. Right-sided dyskinesia and dystonia have reduced; however, left hemiparesis persists. There is severe global developmental impairment and she is fed through a gastrostomy feeding tube. The main benefit from treatment to date is improved awareness and social interaction, which has optimized neurorehabilitation potential in the setting of extensive acquired brain injury. Serum NMDAR-Abs persist (1:100), whereas CSF is negative. Her clinical course and relation with therapy and antibody levels is illustrated in Figure 1G.

The NMDAR-Abs were tested using a cell-based assay in routine clinical by the Clinical Neuroimmunology Service at Oxford Radcliffe Hospital Trust. We investigated for known single gene defects that predispose to HSE [12].

Functional UNC93B and Toll-like receptor 3 deficiencies have been excluded. Results of further genetic investigations (whole exome sequencing) are pending. Abdominal ultrasound excluded teratoma. Written consent was obtained from parents of the study participant.

DISCUSSION

Early identification of clinical signs characteristic of NMDAR-Ab encephalitis in this case allowed rapid targeted autoantibody testing. Immunotherapy was associated with amelioration of severe neurological symptoms, optimizing potential for neurorehabilitation. It also highlights a need for increased awareness of the co-occurrence of these 2 disorders and the importance of early recognition and accurate characterization of cases and their response to immunomodulatory therapy.

NMDAR-Ab encephalitis is a common cause of non-infectious encephalitis in adults and children [1, 2, 4]. The association between infection and brain autoimmunity such as in NMDAR-Ab encephalitis has been recognized [13]. NMDAR-Ab production was reported in 13 of 44 (30%) adults with HSE [14], suggesting a virus-specific and early induction of antibodies, although it was unclear whether any of these patients went on to develop neurological relapse. Subsequently, 2 studies reported that neurological relapse in children after HSE can be mediated by NMDAR-Ab encephalitis [5, 9]. Because NMDAR-Ab encephalitis was retrospectively diagnosed, stored samples (particularly CSF) at time-point of relapse from these cohorts, were often no longer available for testing. Early blood and CSF samples from our patient were also unavailable. In 5 prospectively diagnosed patients (4 children) with relapse post-HSE, NMDAR-Abs were identified. Antibody synthesis started 1–4 weeks post-HSE, preceding the neurological relapse [10]. Although predominantly reported in children, an additional adult case has been reported [15].

What is the mechanism by which HSV could result in an autoimmune response to NMDAR? A process of molecular mimicry has been proposed. However, as in the case described above, HSE is often associated with extensive neuronal destruction. It is considered more likely that loss of tolerance arises after HSV-mediated cellular damage, resulting in neuronal cell surface antigens being presented in such a way as to trigger an aberrant immune response [16]. This autoreactivity extends beyond NMDAR, to include dopamine-2 receptor [9] and a range of other detected (but unknown) neuronal surface targets [10]. It remains to be determined whether central nervous system autoimmunity is triggered in other infectious encephalitides.

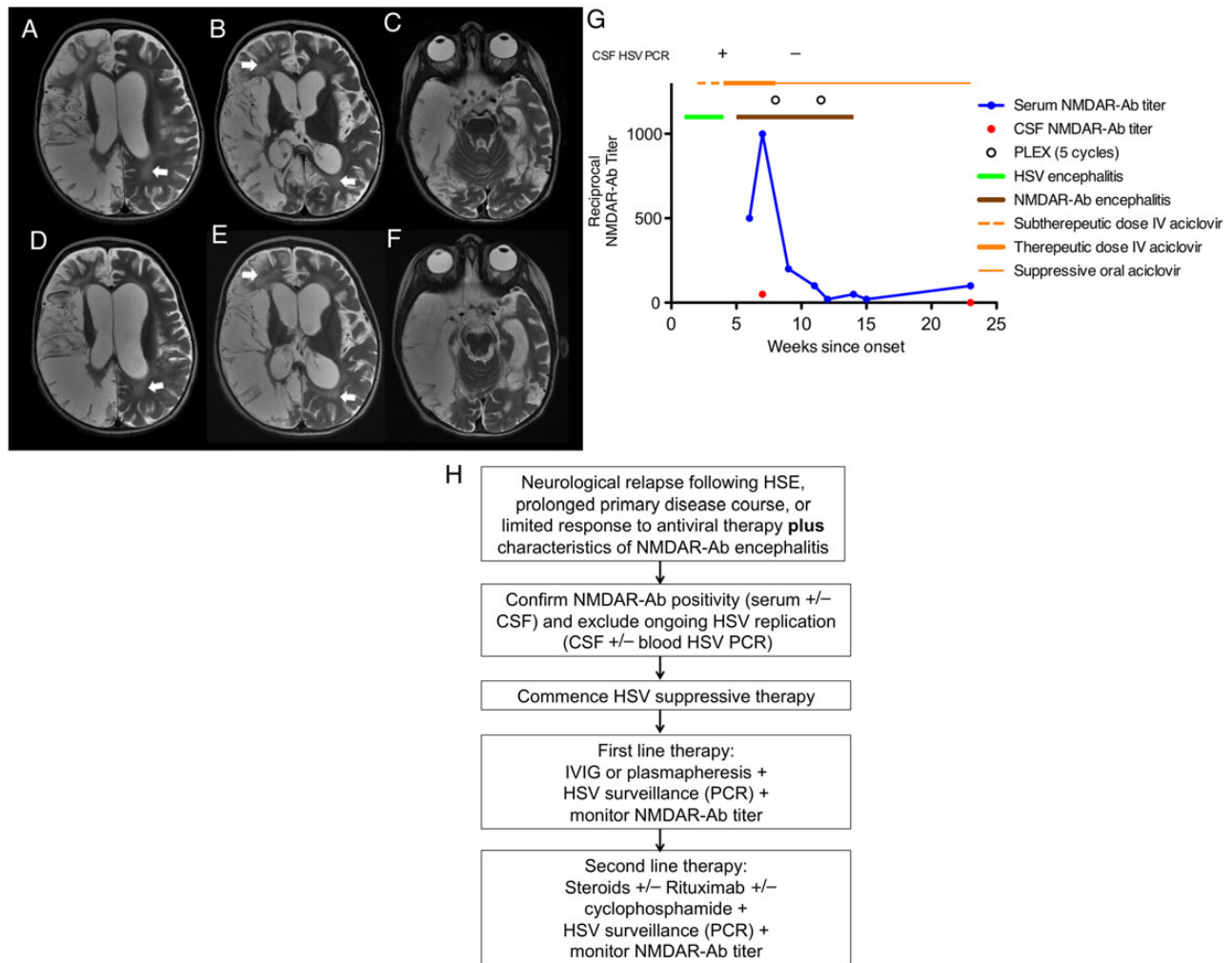


Figure 1. (A–F) Neuroimaging of patient with *N*-methyl-*D*-aspartate receptor antibody (NMDAR-Ab) encephalitis after herpes simplex virus encephalitis (HSE). Axial T2 images on day 24 (A–C) demonstrates hyperintensity in frontoparietal (A), occipital (B), and temporal lobes (C), with evidence of profound atrophic changes in corresponding regions, and widespread patchy white matter changes (arrows). Repeat neuroimaging on day 71 (E–F) reveals progressive atrophy in previously affected regions with no evidence of new regions of parenchymal hyperintensity. The persisting white matter changes prompted further courses of plasmapheresis. (G) Graph illustrating timeline correlating antibody levels, clinical syndromes, and therapy. (H) Proposed diagnostic and treatment algorithm for patients with neurological relapse after HSE. CSF, cerebrospinal fluid; HSV, herpes simplex virus; IV, intravenous; IVIG, IV immunoglobulin; PCR, polymerase chain reaction; PLEX, plasmapheresis; –, negative; +, positive.

The identification of this autoimmune response in HSE has significant therapeutic implications. Slow yet substantial recovery is observed in the majority of cases of isolated NMDAR-Ab encephalitis, 81% in a recently reported large case series [7]. Aggressive immunotherapy with second-line therapies such as cyclophosphamide and rituximab in patients who remain symptomatic after failure of first-line therapy (steroids, immunoglobulins, and plasmapheresis) incurs a higher chance of better recovery. However, when NMDAR-Ab encephalitis and HSE occur together, the precise contribution of each to the neurological sequelae may be difficult to distinguish. Nevertheless, the outcome of patients treated for longer and with more immunotherapy appears to be better [5]. In our case, when considering more aggressive

immunotherapy, the irreversible neuronal insult from HSV and the risk of viral reactivation needed to be balanced with the recognized benefits from treating isolated NMDAR-Ab encephalitis. Additional improvement observed in children undergoing second-line immunotherapy with isolated NMDAR-Ab encephalitis is modest. Data derived from Figure S4 from reference [7] reveal that an additional 15% treated with second-line immunotherapy had a modified Rankin Scale score of 3 and below. This result should be considered in the context of established severe neurodisability secondary to HSV primary insult, potential for HSV reactivation and other severe infectious, and immunological complications of second-line agents such as rituximab [17]. Immunotherapy regimens used in reported cases of NMDAR-Ab encephalitis complicating HSE are

variable. The majority of patients received steroids with 1 or more of IV immunoglobulin (IVIG), plasmapheresis, cyclophosphamide, cyclosporine, rituximab, or mycophenolate mofetil [5, 9, 10, 15]. We propose that when treating potential HSE-triggered brain autoimmunity such as NMDAR-Ab encephalitis, considerations should be given to modifying treatment recommended for NMDAR-Ab encephalitis previously proposed [13]. First, before initiation of immunosuppressive therapy, ongoing HSV replication should be excluded using CSF plus or minus blood HSV PCR. Second, therapies with an established risk of HSV reactivation (ie, high-dose steroids [18]) should be deferred until after treatment with IVIG or plasmapheresis. Third, empirical antiviral therapy (known to be effective in preventing HSV reactivation in patients following haematopoietic stem cell transplant [19]) should be administered conjunctly in patients undergoing immunotherapy. Finally, regular surveillance for HSV reactivation using blood/CSF PCR may be beneficial. The proposed diagnostic and therapeutic pathway for patients presenting with possible NMDAR-Ab encephalitis after HSE is summarized in Figure 1H. This therapeutic strategy differs from the algorithm recently proposed by Titulaer et al [20], with an emphasis on concurrent suppressive aciclovir therapy, monitoring HSV PCR and NMDAR-Ab, and postponement of steroids to second-line therapy.

In conclusion, we have described a rare, yet severe possible complication of HSE. Accumulating case reports support the hypothesis that NMDAR-Abs contribute to neurological relapse after HSE. In view of the infrequently documented incidence of HSE-associated NMDAR-Ab encephalitis, increased awareness, early recognition, and carefully described prospective cohorts will help delineate how best to optimize outcome using immunomodulatory therapy when these 2 potentially devastating diseases combine. Collaboration among pediatricians, neurologists, and infectious disease specialists at the national and international level will be required to unravel the complex interaction between infection and autoimmune neuroinflammation and in delineating the communal and disease-specific pathomechanisms.

Acknowledgments

We thank the patients and their families for their contribution and consent for the case to be published and the clinicians involved in their care: Drs. Hermione Lyall and Jennifer Stevens (St Mary's Hospital).

Potential conflicts of interest. M. L. receives research grants from Action Medical Research and MS Society and research support grants from the London Clinical Research Network and Evelina Appeal. M. L. also received consultation fees from CSL Behring, travel grants from Merck Serono, and was awarded educational grants to

organize meetings by Novartis, Biogen Idec. A. V. serves and has served on scientific advisory boards for the Patrick Berthoud Trust, the Brian Research Trust, and the Myasthenia Gravis Foundation of America. In addition, A. V. has received funding for travel and is a speaker honorarium from Baxter International Inc and Biogen Inc. Moreover, A. V. serves as an Associate Editor for *Brain*, receives royalties from the publication of *Clinical Neuroimmunology* (Blackwell Publishing, 2005) and *Inflammatory and Autoimmune Disorders of the Nervous System in Children* (Mac Keith Press, 2010), receives or has received research support from the European Union, NIHR Biomedical Research Centre Oxford, Euroimmun AG, and the Sir Halley Stewart Trust, and has received Musk antibody royalties and consulting fees from Athena Diagnostics Inc. A. V. and the University of Oxford hold patents and receive royalties and payments for antibody assays in neurologic diseases.

All authors have submitted the ICMJE Form for Disclosure of Potential Conflicts of Interest. Conflicts that the editors consider relevant to the content of the manuscript have been disclosed.

References

- Gable MS, Sheriff H, Dalmau J, et al. The frequency of autoimmune *N*-methyl-*D*-aspartate receptor encephalitis surpasses that of individual viral etiologies in young individuals enrolled in the California Encephalitis Project. *Clin Infect Dis* 2012; 54: 899–904.
- Granerod J, Ambrose HE, Davies NW, et al. Causes of encephalitis and differences in their clinical presentations in England: a multicentre, population-based prospective study. *Lancet Infect Dis* 2010; 10:835–44.
- Ward KN, Ohrling A, Bryant NJ, et al. Herpes simplex serious neurological disease in young children: incidence and long-term outcome. *Arch Dis Child* 2012; 97:162–5.
- Kneen R, Michael BD, Menson E, et al. Management of suspected viral encephalitis in children - Association of British Neurologists and British Paediatric Allergy, Immunology and Infection Group national guidelines. *J Infect* 2012; 64:449–77.
- Hacohen Y, Deiva K, Pettingill P, et al. *N*-methyl-*D*-aspartate receptor antibodies in post-herpes simplex virus encephalitis neurological relapse. *Mov Disord* 2014; 29:90–6.
- De Tieghe X, Rozenberg F, Des Portes V, et al. Herpes simplex encephalitis relapses in children: differentiation of two neurologic entities. *Neurology* 2003; 61:241–3.
- Titulaer MJ, McCracken L, Gabilondo I, et al. Treatment and prognostic factors for long-term outcome in patients with anti-NMDA receptor encephalitis: an observational cohort study. *Lancet Neurol* 2013; 12:157–65.
- Irani SR, Bera K, Waters P, et al. *N*-methyl-*D*-aspartate antibody encephalitis: temporal progression of clinical and paraclinical observations in a predominantly non-paraneoplastic disorder of both sexes. *Brain* 2010; 133(Pt 6):1655–67.
- Mohammad SS, Sinclair K, Pillai S, et al. Herpes simplex encephalitis relapse with chorea is associated with autoantibodies to *N*-methyl-*D*-aspartate receptor or dopamine-2 receptor. *Mov Disord* 2014; 29:117–22.
- Armangue T, Leypoldt F, Malaga I, et al. Herpes simplex virus encephalitis is a trigger of brain autoimmunity. *Ann Neurol* 2014; 75:317–23.
- Gitiaux C, Simonnet H, Eisermann M, et al. Early electro-clinical features may contribute to diagnosis of the anti-NMDA receptor encephalitis in children. *Clin Neurophysiol* 2013; 124:2354–61.
- Sancho-Shimizu V, Perez de Diego R, Jouanguy E, et al. Inborn errors of anti-viral interferon immunity in humans. *Curr Opin Virol* 2011; 1:487–96.

13. Dalmau J, Lancaster E, Martinez-Hernandez E, et al. Clinical experience and laboratory investigations in patients with anti-NMDAR encephalitis. *Lancet Neurol* 2011; 10:63–74.
14. Pruss H, Finke C, Holtje M, et al. *N*-methyl-*D*-aspartate receptor antibodies in herpes simplex encephalitis. *Ann Neurol* 2012; 72: 902–11.
15. Leypoldt F, Titulaer MJ, Aguilar E, et al. Herpes simplex virus-1 encephalitis can trigger anti-NMDA receptor encephalitis: case report. *Neurology* 2013; 81:1637–9.
16. Hoftberger R, Armangue T, Leypoldt F, et al. Clinical neuropathology practice guide 4-2013: post-herpes simplex encephalitis: *N*-methyl-*D*-aspartate receptor antibodies are part of the problem. *Clin Neuropathol* 2013; 32:251–4.
17. Kavcic M, Fisher BT, Seif AE, et al. Leveraging administrative data to monitor rituximab use in 2875 patients at 42 freestanding children's hospitals across the United States. *J Pediatr* 2013; 162: 1252–8.
18. Gutierrez K, Pinsky B, Arvin A. Herpes simplex viruses 1 and 2. In: Cherry J, Demmler-Harrison G, Kaplan S, Steinbach W, Hotez P, eds. *Feigin and Cherry's Textbook of Pediatric Infectious Diseases*. 7th ed, Vol. 2. Philadelphia: Saunders; 2014; pp 1933–91.
19. Tomblyn M, Chiller T, Einsele H, et al. Guidelines for preventing infectious complications among hematopoietic cell transplantation recipients: a global perspective. *Biol Blood Marrow Transplant* 2009; 15:1143–238.
20. Titulaer MJ, Leypoldt F, Dalmau J. Antibodies to *N*-methyl-*D*-aspartate and other synaptic receptors in choreoathetosis and relapsing symptoms post-herpes virus encephalitis. *Mov Disord* 2014; 29:3–6.