

## Pegylated Interferon- $\alpha$ for Treating Chronic Hepatitis E Virus Infection after Liver Transplantation

Nassim Kamar,<sup>1,4</sup> Lionel Rostaing,<sup>1,5</sup> Florence Abravanel,<sup>5,6</sup> Cyril Garrouste,<sup>1</sup> Laure Esposito,<sup>1</sup> Isabelle Cardeau-Desangles,<sup>1</sup> Jean Michel Mansuy,<sup>4</sup> Janick Selves,<sup>7</sup> Jean Marie Peron,<sup>8</sup> Philippe Otal,<sup>2</sup> Fabrice Muscari,<sup>3</sup> and Jacques Izopet<sup>5,6</sup>

Departments of <sup>1</sup>Nephrology, Dialysis and Organ Transplantation, <sup>2</sup>Radiology, and <sup>3</sup>Liver Transplantation and <sup>4</sup>Institut National de la Santé et de la Recherche Médicale (INSERM) U858, IFR –BMT, Centre Hospitalier Universitaire (CHU) Rangueil, and <sup>5</sup>INSERM U563, IFR–BMT, and Departments of <sup>6</sup>Virology, <sup>7</sup>Histopathology, and <sup>8</sup>Hepatology, CHU Purpan, Toulouse, France

**This study assessed the effect of a 3-month course of pegylated interferon- $\alpha$ -2a (Peg-IFN- $\alpha$ -2a) in 3 liver transplant patients with chronic active hepatitis E. A virological response was sustained for 6 and 5 months in 2 patients after Peg-IFN- $\alpha$ -2a therapy was completed. A relapse was observed in the third patient.**

It has been recently shown that hepatitis E virus (HEV) can lead to chronic hepatitis in solid-organ transplant recipients [1, 2] human immunodeficiency virus–infected persons [3], and hematology patients [4]. Furthermore, liver fibrosis progression can be very rapid, leading to liver cirrhosis within a few years after diagnosis [5–7]. Although a reduction of immunosuppressive drugs that target T cells can help eradicate HEV [8], this only occurs in some patients.

Herein, we report the effect of pegylated interferon- $\alpha$ -2a (Peg-IFN- $\alpha$ -2a) in 2 liver-transplant patients who had chronic, active HEV infection. The 3 patients received a 3-month course of Peg-IFN- $\alpha$ -2a at 135  $\mu$ g/week after they had provided informed consent. Anti-HEV status was determined by the EI-Agen HEV immunoglobulin (Ig) G kit (Adaltis and Ingen). The HEV RNA level was quantified using a real-time polymerase chain reaction protocol [9] and a plasmidic standard. The limit of quantification was 500 copies/mL.

Received 26 September 2009; accepted 28 October 2009; electronically published 29 January 2010.

Reprints or correspondence: Dr Nassim Kamar, Dept of Nephrology, Dialysis and Organ Transplantation, CHU Rangueil, TSA 50032, 31059 Toulouse Cedex 9, France (kamar.n@chu-toulouse.fr)

**Clinical Infectious Diseases** 2010;50:e30–e33

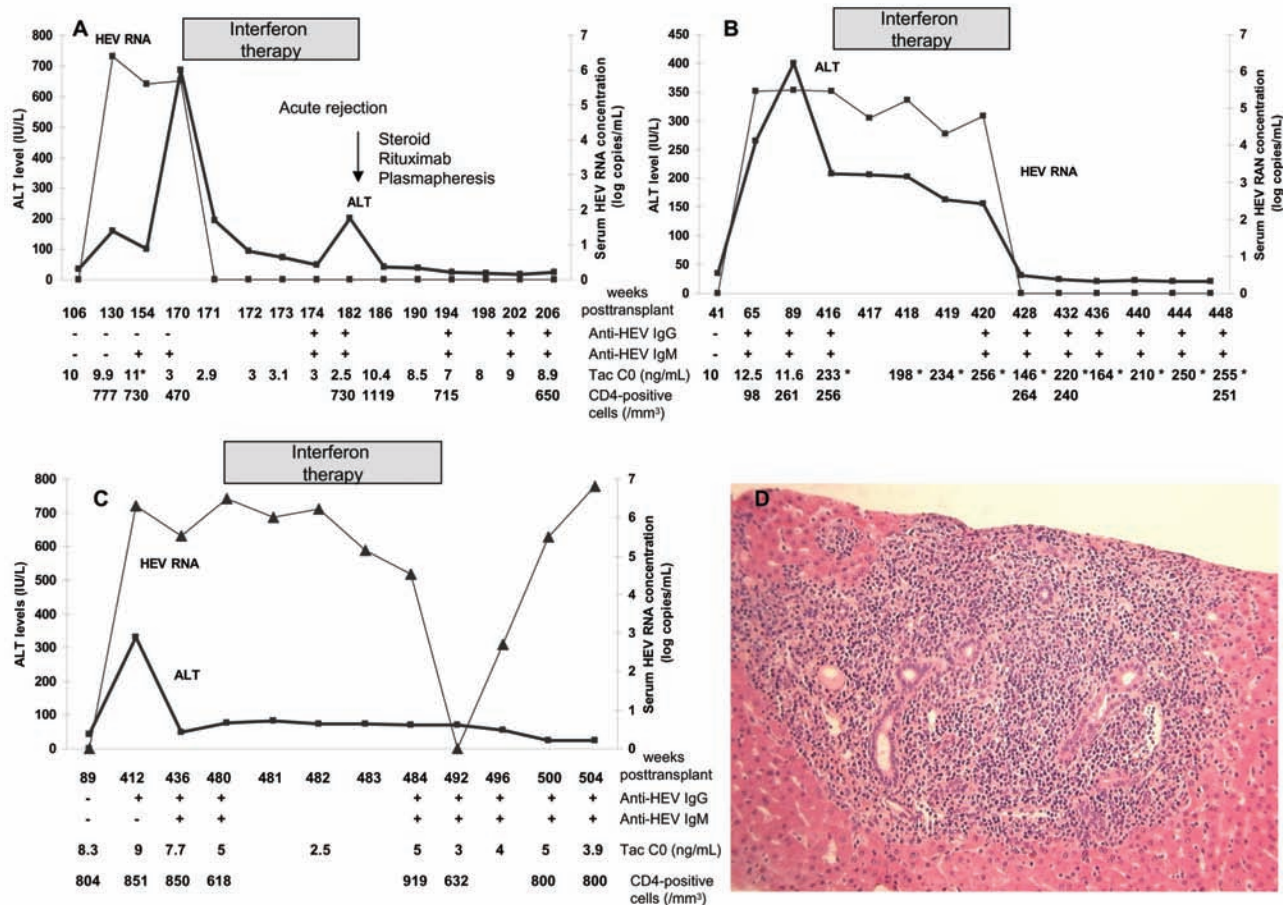
© 2010 by the Infectious Diseases Society of America. All rights reserved.  
1058-4838/2010/5005-00E2\$15.00  
DOI: 10.1096/650488

**Case reports.** Patient 1 was a 29-year-old man who had received a first cadaveric liver transplant for fulminant hepatitis B virus (HBV) infection. After receiving induction therapy with antithymocyte globulins, his initial immunosuppressive therapy included tacrolimus, mycophenolate mofetil, and steroids, with regular infusions of HBV-hyperimmune immunoglobulins and lamivudine prophylaxis. At week 130 after transplantation, although his serum HBV DNA result was still negative, he presented with acute hepatitis. HEV RNA test results were positive for both serum and stool specimens. Phylogenetic analysis revealed that the strain belonged to genotype 3c (GenBank accession number FJ665426). The patient's serum samples tested negative for anti-HEV IgG but positive for anti-HEV IgM. A liver biopsy revealed signs of acute viral hepatitis (Metavir score, A1F1) [10]. All other causes of hepatitis were excluded.

At the time of HEV infection diagnosis, the immunosuppressive therapy included tacrolimus–mycophenolate mofetil (1 g per day). Thirty weeks after diagnosis, because of persisting chronic active HEV infection, tacrolimus doses were significantly reduced to target trough levels of 2–4 ng/mL. Forty weeks after diagnosis, the patient's liver enzyme levels had increased, and serum HEV RNA test results was still positive (Figure 1A). A liver biopsy revealed signs of severe active hepatitis (Metavir score, A3F2), with no features of acute rejection (Figure 1D). Consequently, he commenced Peg-IFN- $\alpha$ -2a therapy. As soon as week 1 after administration of Peg-IFN- $\alpha$ -2a, his liver enzyme levels decreased significantly; HEV RNA levels became undetectable and remained undetectable until week 12. Immunosuppressive drug doses remained unchanged during antiviral therapy.

By week 12 of Peg-IFN- $\alpha$ -2a therapy, the patient developed acute hepatitis. Peg-IFN- $\alpha$ -2a was stopped, as previously scheduled. An additional search for HEV RNA in the serum and stool specimens yielded negative results, but liver biopsy revealed signs of acute humoral rejection. Anti-human leukocyte antigen antibodies directed against the donor were detected. The patient was treated with steroid pulses (10 mg/kg per day for 3 days), 6 plasmapheresis sessions, 2 rituximab infusions (375 mg/m<sup>2</sup> per week for 2 weeks), and increased tacrolimus doses. His liver enzyme levels progressively decreased and returned to within the normal range. At the last follow-up visit (24 weeks after the completion of Peg-IFN- $\alpha$ -2a therapy and after the acute rejection episode), HEV RNA test results were still negative for the serum and stool samples. Serum HBV DNA also remained undetectable at that follow-up visit.

Patient 2 was a 26-year-old man who had undergone a first



**Figure 1.** A, Outcome of biological parameters of patient 1. Tacrolimus target levels were decreased at month 7 after diagnosis. B, Outcome of biological parameters of patient 2. The patient's regimen was changed to cyclosporine A. Numbers correspond to cyclosporine A concentrations 2 h after intake. C, Outcome of biological parameters of patient 3. D, Liver biopsy at time of initiation of pegylated interferon- $\alpha$ -2a therapy in patient 1 (hematoxylin and eosin stain; original magnification,  $\times 20$ ). Important spotty or confluent necrosis of hepatocytes with polymorph inflammation in the lobule, consistent with intense viral hepatitis. In the portal tract, inflammation was marked with piecemeal necrosis. ALT, alanine aminotransferase; CO, trough level; HEV, hepatitis E virus; Ig, immunoglobulin; Tac, tacrolimus.

cadaveric liver transplantation for HBV-related cirrhosis. After an induction therapy using antithymocyte globulins, his initial immunosuppressive therapy included tacrolimus, steroids, HBV-hyperimmune immunoglobulins, and lamivudine prophylaxis. At week 65 after transplantation, although serum HBV DNA results remained negative, he presented with acute hepatitis with no apparent cause. At that time, tests for HEV RNA were not performed. A liver biopsy revealed signs of acute viral hepatitis (Metavir score, A1F0). Two other liver biopsies performed at 60 and 147 weeks after the acute phase showed significant progression of liver fibrosis (Metavir score, A2F2 and A3F4, respectively). At 91 weeks after the acute phase, because of suspected hepatotoxicity, tacrolimus was replaced with cyclosporine A.

Three years later, when assessed for the first time, HEV RNA was detected in a serum sample (Figure 1B). Retrospective analysis revealed that HEV RNA was detectable in all available

serum samples obtained since the first episode of posttransplantation acute hepatitis, suggesting that the patient developed HEV-related cirrhosis in <3 years. Phylogenetic analysis revealed that the strains were genotype 3f (GenBank accession number FJ665429). When HEV infection was diagnosed (216 weeks after the acute phase), immunosuppressive therapy included cyclosporine A (2-h concentration after intake, 430 ng/mL) and mycophenolate mofetil (2 g per day). After diagnosis, the dosage of mycophenolate mofetil was decreased from 2 to 1 g per day.

Because of persisting detectable HEV RNA in the serum and stool samples, and because of histological signs of virus-induced cirrhosis (Metavir score, A2F4), at 416 weeks after the onset of HEV infection, the patient began receiving Peg-IFN- $\alpha$ -2a therapy. Peg-IFN- $\alpha$ -2a was used to eradicate the virus before possible retransplantation was considered. The serum HEV RNA concentration decreased from 5.46 to 4.75 log copies/mL

by week 1, and HEV RNA test results became negative in the serum and stool samples by week 12 of Peg-IFN- $\alpha$ -2a therapy. Liver enzyme levels returned to within the normal range by week 12 of therapy. At the most recent follow-up visit (20 weeks after the completion of Peg-IFN- $\alpha$ -2a therapy), HEV RNA test results were still negative in the serum and stool samples, and liver enzyme levels remained within the normal range. Serum HBV DNA was also still undetectable at that follow-up visit.

Patient 3 was a 58-year-old man who had undergone a first cadaveric liver transplantation for sclerosing cholangitis. Induction therapy consisted of antithymocyte globulins, and his initial immunosuppressive therapy included tacrolimus and steroids. After transplantation, he initially experienced several biliary tract infections, followed by intrahepatic biliary tract stenosis. This required several percutaneous bile duct drainage procedures and was complicated by angiocholitis. After each infectious episode, his liver enzyme levels returned to within the normal range. At 412 weeks after transplantation, he presented with acute hepatitis. Biliary tract abnormalities were ruled out by magnetic resonance imaging. However, HEV RNA test results were found to be positive for both the serum and the stool samples. Phylogenetic analysis revealed that the strain belonged to genotype 3c (GenBank accession number FJ665422). Serum anti-HEV IgG results were positive, whereas serum anti-HEV IgM results were negative. A liver biopsy revealed signs of acute viral hepatitis (Metavir score, A2F1). All other causes of hepatitis were excluded.

At the time that HEV infection was diagnosed, the patient's immunosuppressive therapy consisted of tacrolimus monotherapy. Twenty-eight weeks after diagnosis, because of persisting chronic HEV infection, tacrolimus doses were reduced to target a trough level of 4–6 g/mL. Despite this decrease, the patient's liver enzyme levels remained elevated, and he remained infected with the virus (Figure 1C).

A liver biopsy was performed 68 weeks after diagnosis, revealing signs of cirrhosis (Metavir score, A2F4). Because of chronic active HEV infection and cirrhosis, the patient began receiving Peg-IFN- $\alpha$ -2a therapy to eradicate the virus before possible retransplantation was considered. The serum HEV RNA concentration decreased slowly, from 6.48 to 6.01 log copies/mL, by week 1, and HEV RNA results became negative for serum and stool samples after 3 months of Peg-IFN- $\alpha$ -2a therapy. Liver enzyme levels progressively returned to within the normal range. Unfortunately, at week 2 after completion of Peg-IFN- $\alpha$ -2a treatment, HEV RNA was redetected in serum and stool samples.

**Discussion.** It is well established that HEV infection can evolve to chronic hepatitis in immunosuppressed patients [1–3, 8]. Chronic HEV infection in solid-organ transplant recipients is characterized by rapidly progressing liver fibrosis, which leads to cirrhosis after <3 years of infection [5–8]. Two liver

transplant patients who developed HEV-related cirrhosis required retransplantation [6]. HEV infection persisted after the second liver transplantation in 1 patient, leading to recurring chronic hepatitis.

The presence of severe chronic active hepatitis in 1 patient and the occurrence of HEV-related cirrhosis, which may have necessitated retransplantation, in the other 2 patients prompted us to administer antiviral therapy after a reduction in the dosage of immunosuppressive therapy had failed to eradicate the virus.

To our knowledge, until now, no antiviral therapy has been shown to efficiently treat HEV infection. In a patient with non-Hodgkin lymphoma who was receiving rituximab and who developed chronic HEV infection, Ollier et al [4] reported that 3 months of IFN- $\alpha$  therapy improved the patient's clinical symptoms, although HEV RNA levels remained detectable. In this case, it is unknown whether the patient received pegylated or standard IFN- $\alpha$  and at what dosage.

We decided to evaluate the effect of a short regimen of Peg-IFN- $\alpha$ -2a monotherapy for treatment of chronic, active HEV infection. Ribavirin was not used, to avoid its related adverse effects. For the first time, to our knowledge, we have shown that a 3-month course of Peg-IFN- $\alpha$ -2a monotherapy has an antiviral effect on HEV. HEV clearance was sustained at 6 and 5 months after completion of Peg-IFN- $\alpha$ -2a treatment in 2 patients, although there was a relapse by day 15 after Peg-IFN- $\alpha$ -2a treatment for the third patient. We wonder whether a longer period duration of therapy would have resulted in a complete and sustained virological response.

Because immunosuppressant doses were reduced, because of the use of Peg-IFN- $\alpha$ -2a—an immunostimulating agent—patient 1 presented with an acute humoral rejection. Thus, in this setting, we suggest that immunosuppressant doses are increased after Peg-IFN- $\alpha$ -2a-induced HEV clearance occurs.

In conclusion, Peg-IFN- $\alpha$ -2a induced HEV RNA clearance after 3 months of therapy in liver transplant patients with chronic, active hepatitis. To avoid the risk of acute rejection induced by Peg-IFN- $\alpha$ -2a, we suggest that it is initiated in cases in which a reduction in the dose of immunosuppressive therapy has failed to eradicate the virus. The duration of Peg-IFN- $\alpha$ -2a therapy and its potential combination with ribavirin to obtain a sustained response still need to be determined. Additional studies of a larger number of patients and a longer follow-up period are required to confirm these data.

## Acknowledgments

**Potential conflicts of interest.** All authors: no conflicts.

## References

1. Kamar N, Selves J, Mansuy JM, et al. Hepatitis E virus and chronic hepatitis in organ-transplant recipients. *N Engl J Med* 2008; 358(8): 811–817.
2. Gerolami R, Moal V, Picard C, Colson P. Hepatitis E virus as an emerg-

- ing cause of chronic liver disease in organ transplant recipients. *J Hepatol* **2009**; 50(3):622–624.
3. Dalton HR, Bendall R, Keane F, Tedder R, Ijaz S. Persistent carriage of hepatitis E virus in patients with HIV infection. *N Engl J Med* **2009**; 361(10):1025–1027.
  4. Ollier L, Tieulie N, Sanderson F, et al. Chronic hepatitis after hepatitis E virus infection in a patient with non-Hodgkin lymphoma taking rituximab. *Ann Intern Med* **2009**; 150(6):430–431.
  5. Gerolami R, Moal V, Colson P. Chronic hepatitis E with cirrhosis in a kidney-transplant recipient. *N Engl J Med* **2008**; 358:859–860.
  6. Haagsma EB, van den Berg AP, Porte RJ, et al. Chronic hepatitis E virus infection in liver transplant recipients. *Liver Transpl* **2008**; 14(4): 547–553.
  7. Kamar N, Mansuy JM, Cointault O, et al. Hepatitis E virus-related cirrhosis in kidney- and kidney-pancreas-transplant recipients. *Am J Transplant* **2008**; 8(8):1744–1748.
  8. Kamar N, Abravanel F, Selves J, et al. Influence of immunosuppressive therapy on the natural history of genotype 3 hepatitis-E virus infection after organ transplantation. *Transplantation* (in press).
  9. Mansuy JM, Peron JM, Abravanel F, et al. Hepatitis E in the south west of France in individuals who have never visited an endemic area. *Journal of medical virology* **2004**; 74(3):419–424.
  10. Bedossa P, Poynard T. An algorithm for the grading of activity in chronic hepatitis C. The METAVIR Cooperative Study Group. *Hepatology* **1996**; 24(2):289–293.