

PDF hosted at the Radboud Repository of the Radboud University Nijmegen

The following full text is a publisher's version.

For additional information about this publication click this link.

<http://hdl.handle.net/2066/22689>

Please be advised that this information was generated on 2022-08-23 and may be subject to change.

Pelvic Adenopathy in Prostatic and Urinary Bladder Carcinoma: MR Imaging with a Three-Dimensional T1-Weighted Magnetization-Prepared-Rapid Gradient-Echo Sequence

Gerrit J. Jager¹
Jelle O. Barentsz¹
Gosse O. Oosterhof²
J. Alfred Witjes²
Sjef J. H. Ruijs¹

OBJECTIVE. The purpose of this study was to evaluate a magnetization-prepared-rapid gradient-echo (MP-RAGE) sequence as a three-dimensional (3D) T1-weighted MR imaging technique to reveal lymph node metastases from carcinoma of the bladder and the prostate.

SUBJECTS AND METHODS. Using a 3D T1-weighted MP-RAGE sequence, MR images of 134 consecutive patients with prostatic carcinoma ($n = 63$) or urinary bladder carcinoma ($n = 71$) who were scheduled for radical prostatectomy or radical cystectomy were correlated with histopathologic findings after fine-needle aspiration biopsy (FNAB) ($n = 6$), open or laparoscopic pelvic lymph node dissection ($n = 127$), or autopsy ($n = 1$). MR imaging was used 10 times to guide FNAB in nine patients.

RESULTS. The sensitivity, specificity, accuracy, and positive predictive value of the technique were 75%, 98%, 90%, and 94%, respectively. Thin-slice (1.2-mm) multiplanar reconstructed images correctly revealed diseased nodes in 33 patients. However, MR imaging failed to reveal microscopic metastatic deposits in normally sized nodes in 11 patients. Two other patients had enlarged nodes without metastasis. Furthermore, FNAB guided by MR imaging revealed metastases in six of nine patients.

CONCLUSION. MR imaging with a 3D MP-RAGE sequence was accurate in revealing nodal metastases from carcinoma of the prostate and bladder. This imaging technique can be used to select patients for biopsy or laparoscopic pelvic lymph node dissection.

MR imaging is considered superior to CT for local staging of prostatic carcinoma [1] and slightly better in local staging of urinary bladder carcinoma [2, 3]. Because we use MR imaging for local staging in patients with prostatic and urinary bladder cancer, we investigated whether MR imaging is appropriate in nodal staging. If it is, local and nodal staging could be done in one session.

However, CT provides the opportunity to do fine-needle aspiration biopsy (FNAB) more easily [4]. FNAB is a minimally invasive method of determining lymph node metastases histologically. The mean reported sensitivity of FNAB is 70% [5].

The purpose of this study was to evaluate the diagnostic accuracy of a three-dimensional (3D) magnetization-prepared-rapid gradient-echo (MP-RAGE) MR technique for staging regional lymph nodes in patients with prostatic or urinary bladder carcinoma.

Subjects and Methods

One hundred and thirty-four consecutive patients with biopsy-proven prostatic carcinoma ($n = 63$; mean age, 64 years old; range, 48–73 years old) or invasive urinary bladder carcinoma ($n = 71$; 55 men, 16 women; mean age, 59 years old; range, 38–75 years old) were considered suitable candidates for curative surgery on the basis of clinical staging, local and regional MR staging, and their general condition.

In patients with prostatic carcinoma, clinical stage was based on digital rectal examination, transrectal sonography, prostate specific antigen levels (mean, 8.2 ng/ml; range 2.4–40 ng/ml) and histologic tumor grade (nine tumors well differentiated, 42 moderately well differentiated, and 12 poorly differentiated). All patients with urinary bladder cancer had biopsy-proven muscle invasion. Nine patients had moderately differentiated tumors, and 64 patients had poorly differentiated tumors.

MR imaging was done using a 1.5-T magnet (Magnetom 63/48 SP/4000; Siemens, Erlangen, Germany) and a Helmholtz double surface coil (Siemens). To reduce bowel motion, patients

Received March 26, 1996; accepted after revision May 30, 1996.

¹Department of Radiology, University Hospital Nijmegen, Geert Grooteplein 10, P. O. Box 9101, 6500 HB, Nijmegen, the Netherlands. Address correspondence to G. J. Jager.

²Department of Urology, University Hospital Nijmegen, Nijmegen, the Netherlands.

AJR 1996;167:1503–1507

0361-803X/96/1676-1503

© American Roentgen Ray Society

received 0.5 mg of glucagon IV before the examination. To reduce respiratory motion, an adjustable belt was wrapped around the abdomen to induce slight compression. In the 3D MP-RAGE implementation, T1-weighting was obtained with a 180° inversion pulse for magnitude preparation. For each of the phase-encoding steps in the second dimension, the inversion preparation was applied and then the rapid gradient-echo data acquisition was obtained; the latter step extended into the phase encoding for the third dimension. The sequence parameters were 10/4 (TR/TE); inversion time, 500 msec; flip angle, 10°; matrix size, 192 × 256; field of view, 25 cm; two acquisitions; and voxel size, 1.0 × 1.3 × 1.6 mm. A total of 128 contiguous images were obtained in 9 min. From this image set, off-line multiplanar reconstruction of images in specific planes was performed depending on the preference of the investigator. A plane parallel to the external iliac vessels was always included. In

patients with urinary bladder carcinoma, the 3D MP-RAGE sequence was part of local staging [2]; in patients with prostatic carcinoma, the sequence preceded local staging with a transrectal surface coil. Image interpretation was done by two experienced investigators who were unaware of the clinical and surgical findings except that the patient was a candidate for prostatectomy or cystectomy. The image quality was assessed as good or poor according to previously reported criteria [2]. The investigators performed multiplanar reconstructions of the MP-RAGE data in what they considered to be the optimal plane. In the first 40 patients, all reconstructions were done independently by both investigators. As the study proceeded, the reconstructions were done by a single reader. When the reader was in doubt, independent double reading was performed. Consensus was achieved in all cases. In determining sizes of lymph nodes, maximal long-axis and minimal axial measurements were

obtained. The minimal axial size was measured in a plane perpendicular to the long axis through the thickest part of the node. From these measurements an index was calculated by dividing the shortest axial size by the long axis. Lymph nodes were considered pathologic when the minimal axial diameter was 10 mm or more (Fig. 1) or when the minimal axial diameter was between 8 mm and 10 mm and the index exceeded 0.8 (a round node) (Fig. 2). The signal intensity of lymph nodes was not considered diagnostic for metastases [3].

In nine patients, biopsies of suspected enlarged nodes were guided with MR imaging using an 18-gauge MR-imaging-compatible needle (Löfkin; Medicor, Türkenfeld, Germany). In one patient, the procedure was repeated after an inconclusive result. To determine the ideal percutaneous approach, multiple angulated images were reconstructed. The position of the needle tip was checked with transaxial and sagittal two-dimen-

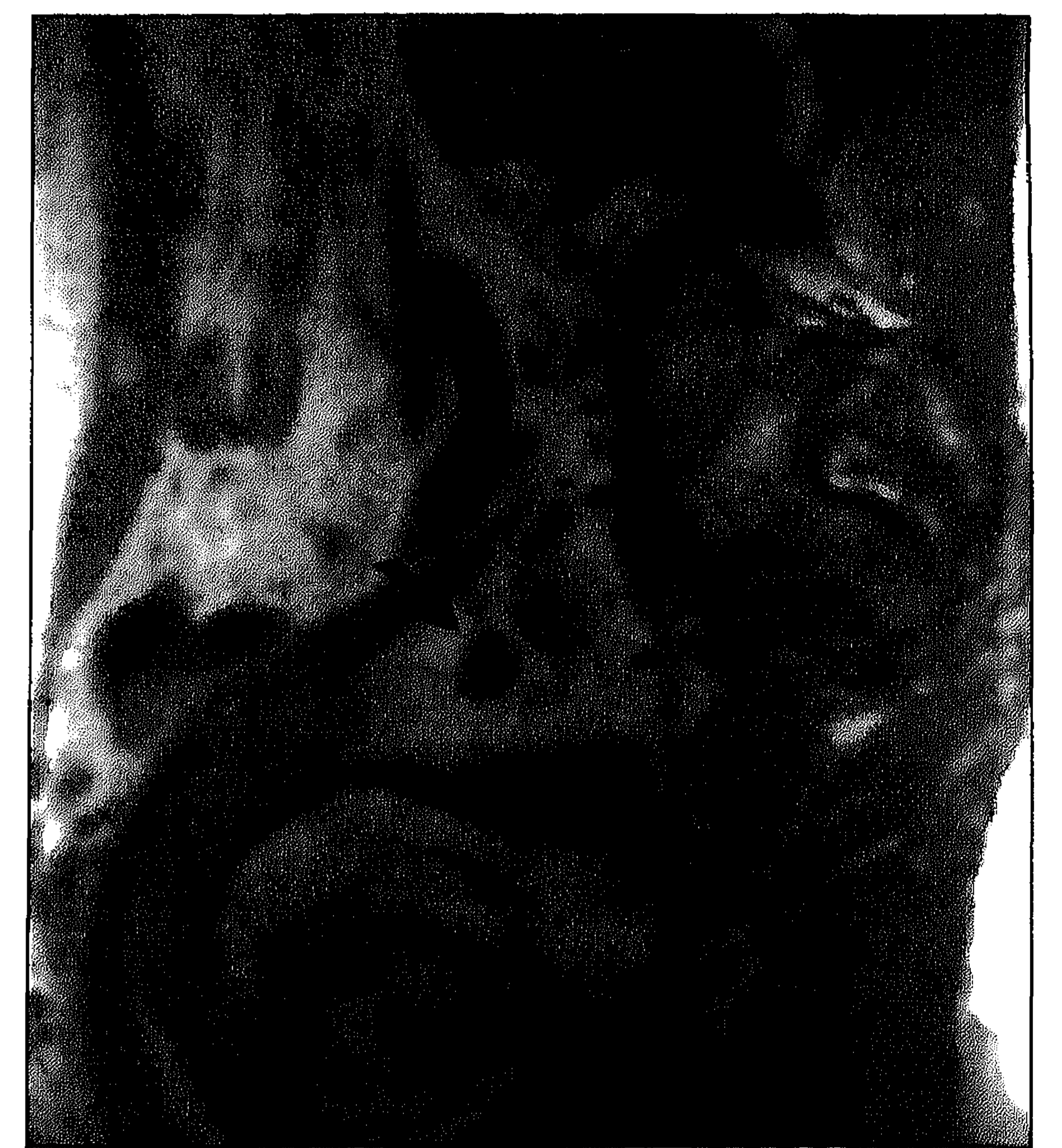
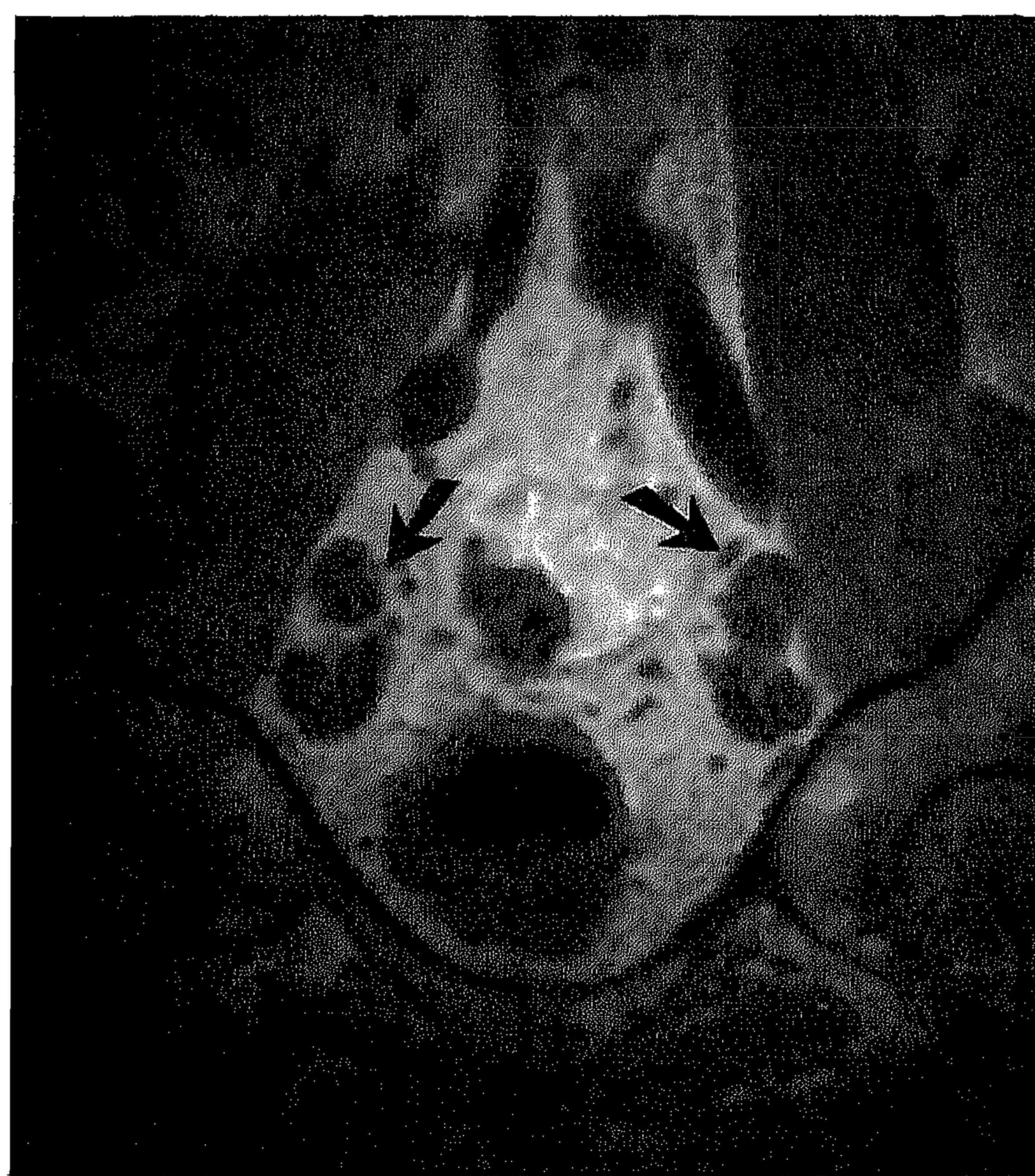
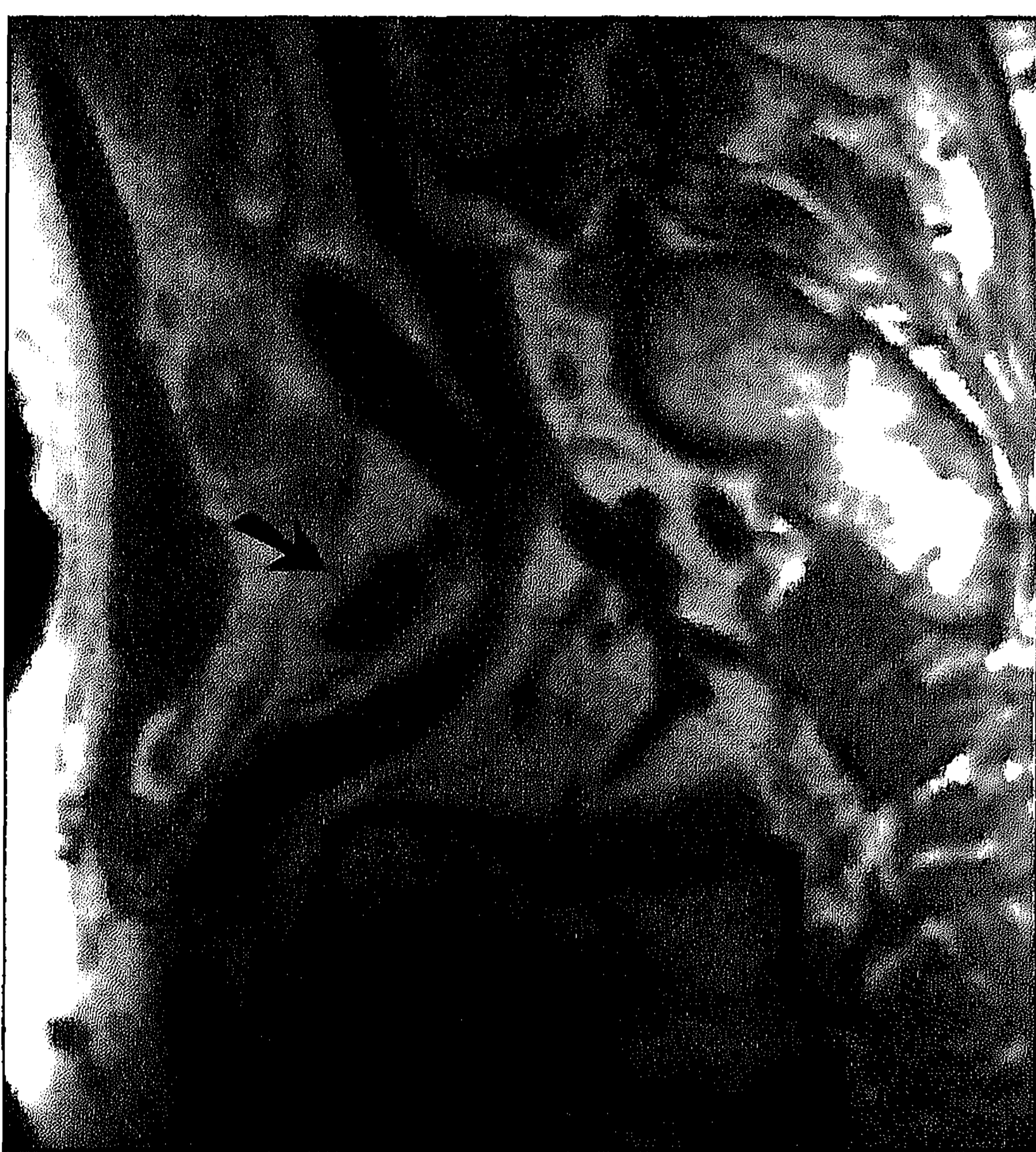Fig. 1.—Lymph node metastases in 54-year-old man with T3b urinary bladder carcinoma. **A**, Reconstructed three-dimensional magnetization-prepared-rapid gradient-echo (3D MP-RAGE) image in plane parallel to right external iliac vessel shows enlarged lymph node (*arrow*). **B**, Reconstructed 3D MP-RAGE image in slightly angulated coronal plane reveals enlarged lymph nodes (*arrows*) along course of iliac vessels (diameter, 12 mm). Histologic examination after fine-needle aspiration biopsy revealed metastatic deposits.

Fig. 2.—65-year-old man with localized prostatic cancer and iliac metastases. Reconstructed three-dimensional magnetization-prepared rapid gradient-echo image in plane parallel to right external iliac vessel reveals round obturator node with diameter of 9 mm (*arrow*). Histologic examination after laparoscopic lymph node dissection revealed metastatic deposits.

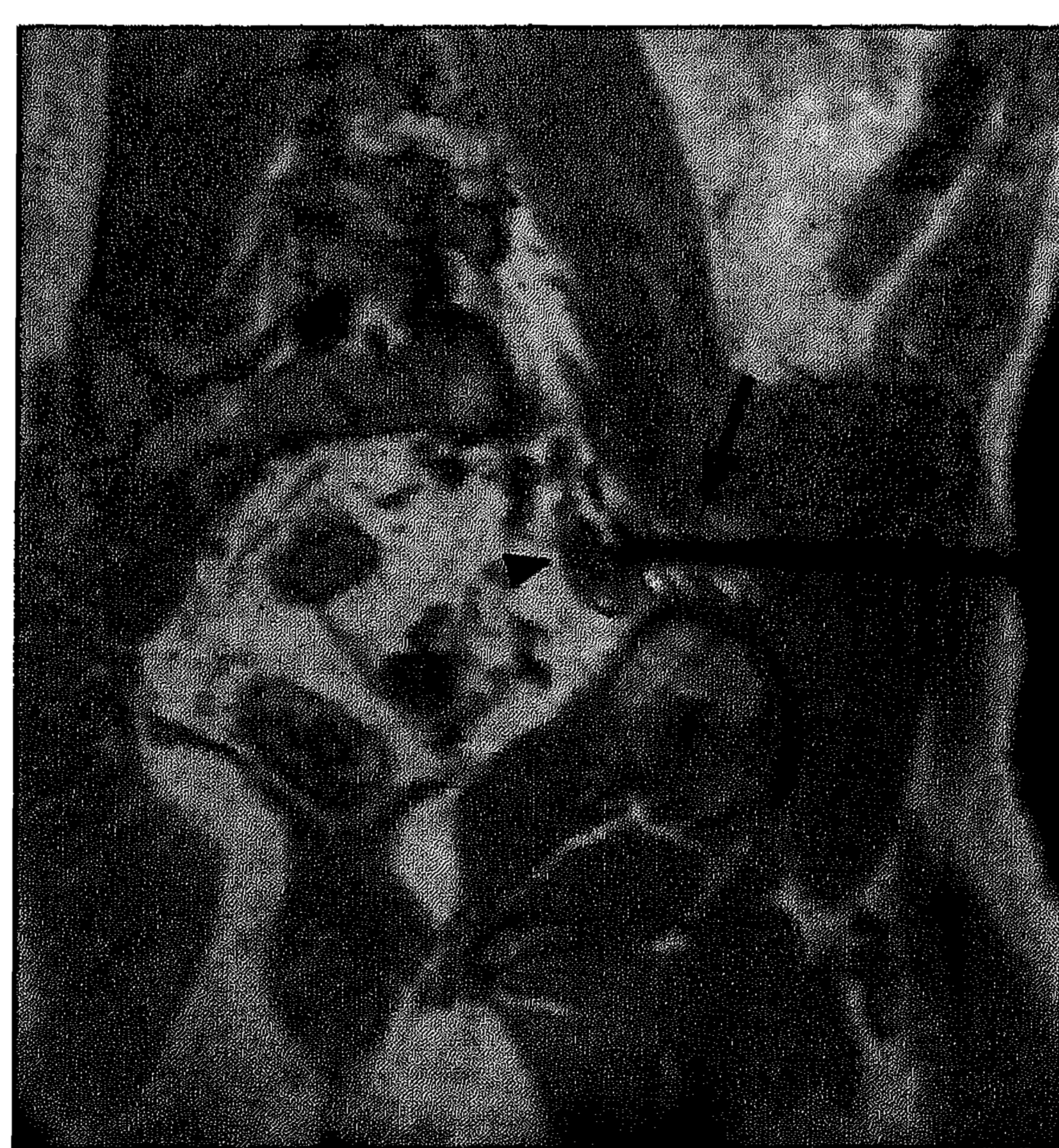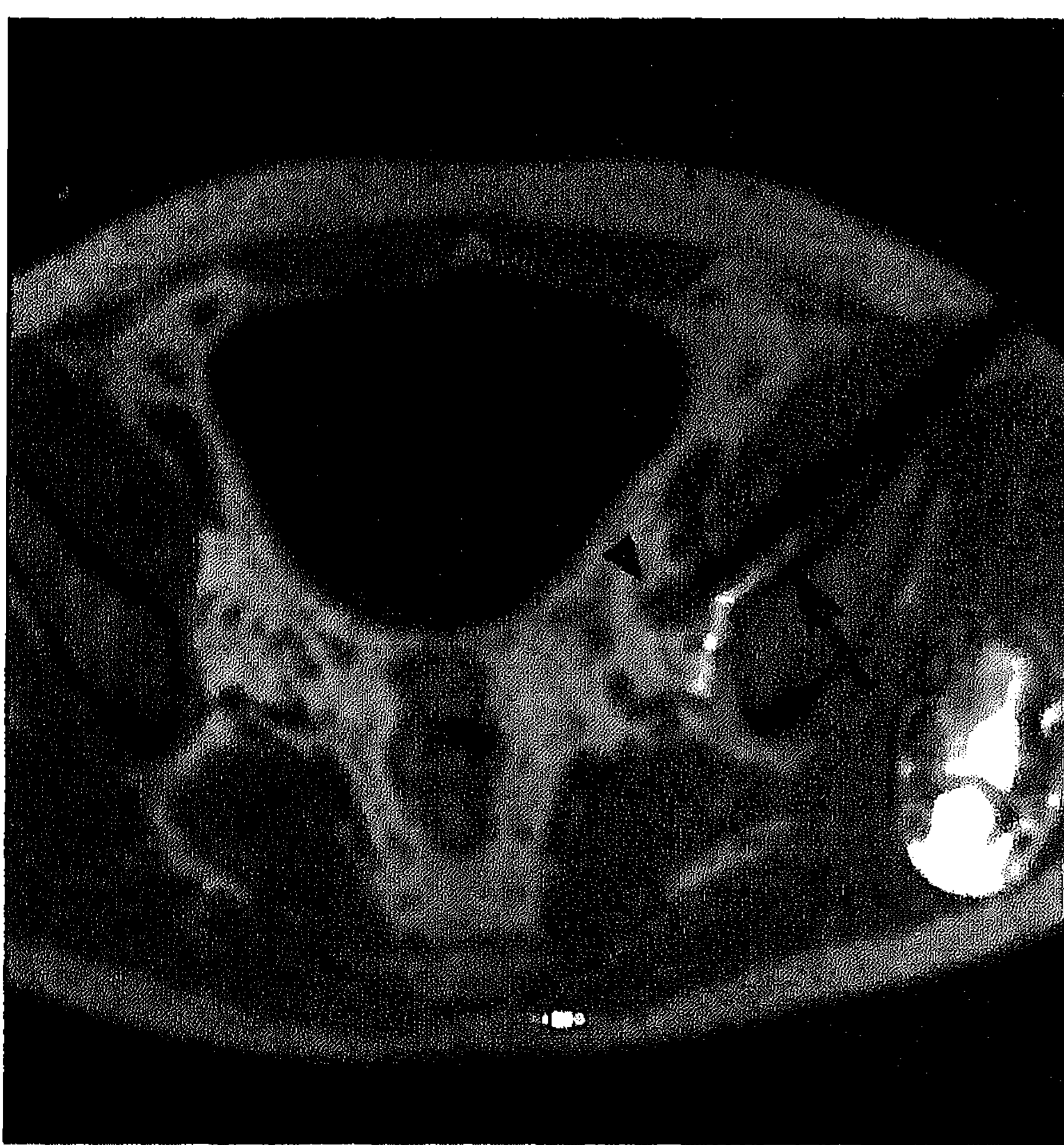


Fig. 3.—57-year-old man with urinary bladder carcinoma and lymph node metastases. Fast reconstructed three-dimensional magnetization-prepared-rapid gradient-echo image reconstructions in transverse (**A**) and multiple angulated (**B**) plane obtained during fine-needle aspiration biopsy show needle tip (*arrow*) and lymph node (*arrowhead*). Phase wrap of patient's wrist is visible within left gluteal muscle in **A**.

MR Imaging of Pelvic Adenopathy

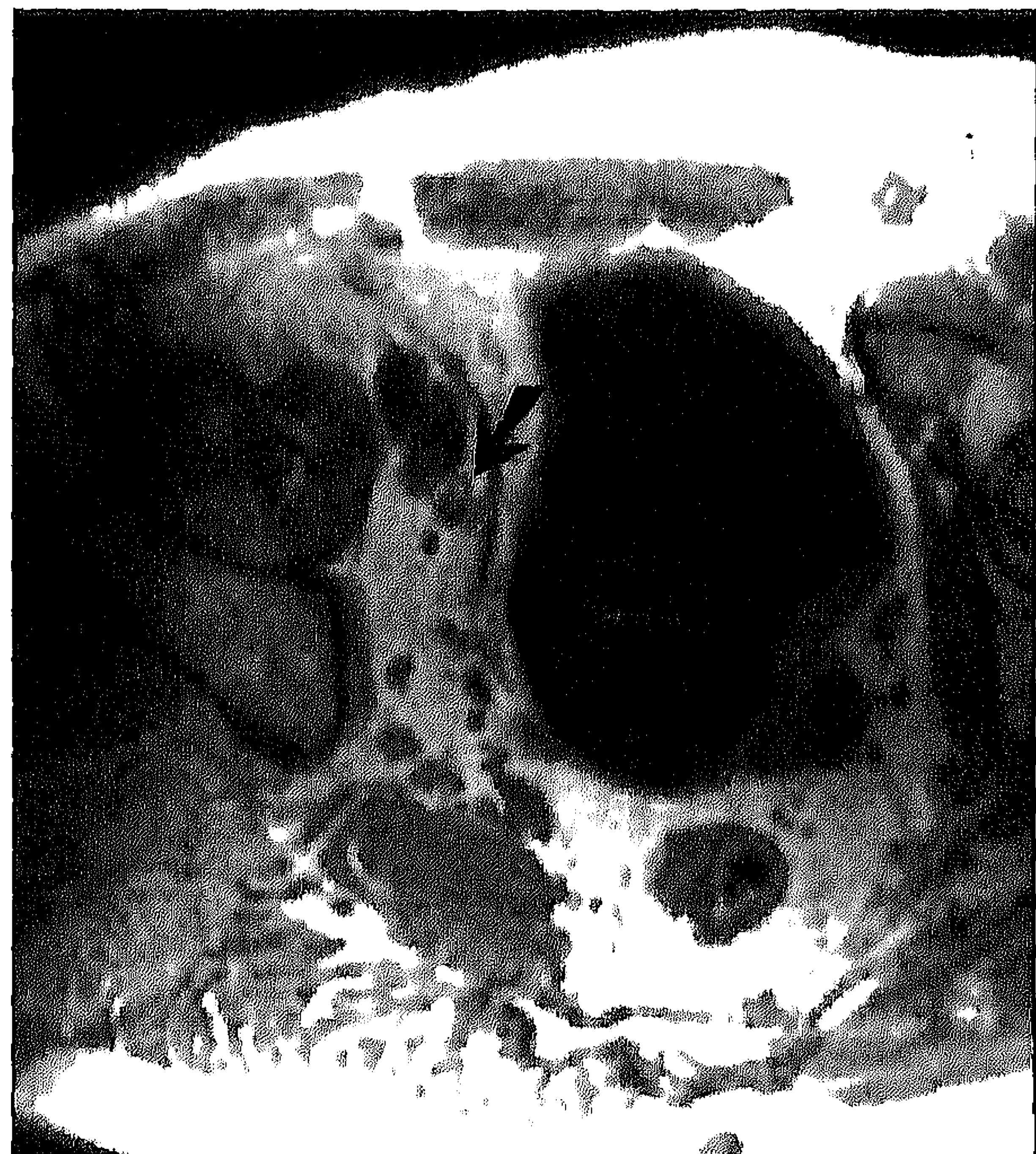sional spin-echo images with these parameters: 200/15; matrix size, 192 × 256; field of view, 25 cm; and contiguous slice thickness, 5 mm. We also used a fast 3D MP-RAGE sequence with these parameters: 10/4; inversion time, 500 msec; flip angle, 10°; field of view, 25 cm; and matrix size, 128 × 256 (Fig. 3). The procedure took 30–60 min and was done on outpatients.

The MR findings were compared with histopathologic findings after FNAB in six patients, open or laparoscopic pelvic lymph node dissection (PLND) in 127, and autopsy in one.

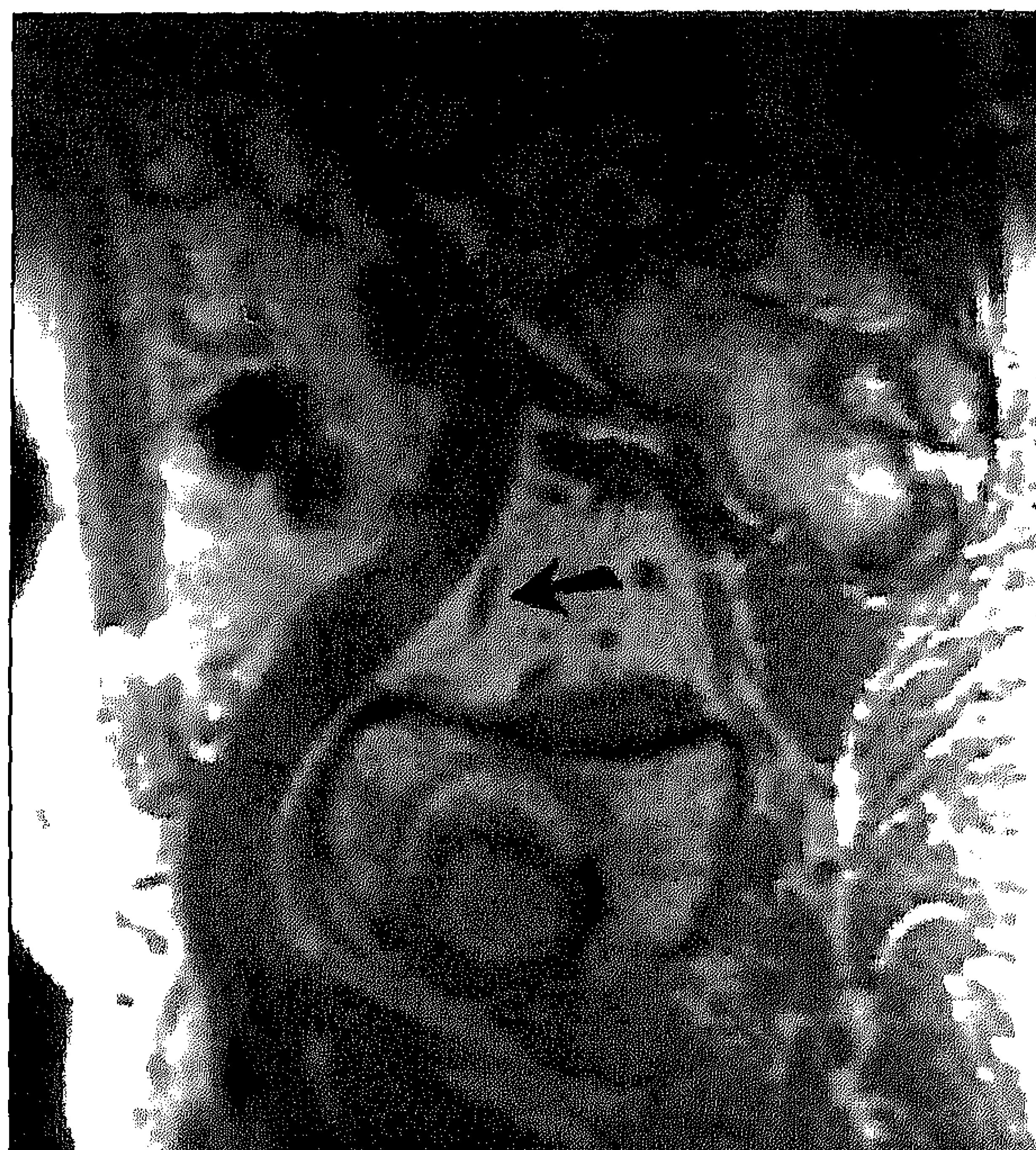Results

Overall

Lymph nodes with an axial diameter of 3 mm could be visualized (Fig. 4). Initially, multiplanar reconstructions were performed in 20 min; eventually, we could perform them in 10 min. Results of nodal staging are presented in Tables 1 and 2.



A



B

Fig. 4.—52-year-old man with prostatic cancer. Reconstructed three-dimensional magnetization prepared-rapid gradient echo images in coronal (A) and plane parallel to right external iliac vessel (B) show lymph nodes (arrow) with diameter of 3 mm along course of vessels. Histologic examination after open lymph node dissection revealed no metastatic deposits.

MR imaging revealed lymph node metastases in 33 of 44 patients. MR imaging failed to depict metastases in 11 patients with unenlarged nodes. No metastatic disease was found in two patients with enlarged nodes.

The MR technique proved to have a sensitivity of 77%, a specificity of 94%, an accuracy of 98%, and a positive predictive value of 95%.

Prostatic Carcinoma

The MR pelvic lymph node findings in 63 patients with prostatic carcinoma are correlated with the results of pathologic examination in Table 1. Metastases were revealed by MR imaging in nine patients. In these patients, 15 enlarged lymph nodes were shown with a mean diameter of 11 mm (range, 8–18 mm). In three of these patients, lymph node metastases were present in round nodes with a diameter of 8 or 9 mm. In six patients, lymph node metastases were

present in normally sized nodes. The diameter of the largest false-negative node was 6 mm (Fig. 5). In the one patient with a false-positive lymph node, we measured a diameter of 10 mm on reconstructed MR images.

Urinary Bladder Carcinoma

The MR pelvic lymph node findings in 71 patients with invasive urinary bladder carcinoma are correlated with pathologic examination in Table 2. Metastases were predicted correctly in 24 patients. In these 24 patients 39 enlarged lymph nodes were detected. The mean axial diameter was 12 mm (range, 9–18 mm). Metastases in five patients were predicted correctly because they were round. The diameter of the involved nodes was 9–10 mm. In one patient with false-positive nodes, the minimal axial diameter of the largest node was 15 mm. However, this node did not contain metastatic disease.

In nine patients with enlarged nodes, MR imaging was used to guide FNAB. All patients appeared to have metastases. In four patients, insufficient aspirated material precluded diagnosis. These cases were classified as false-negative. In one patient the procedure was repeated, and enough material was aspirated for diagnosis. In six patients tumor cells were seen after FNAB guided by MR imaging. All failures occurred in the first five procedures, suggesting a learning curve for this procedure.

Discussion

Accuracy of MR Imaging for Nodal Staging

Local and regional lymph nodes are routinely evaluated for metastases in candidates for radical prostatectomy or cystectomy. Surgical PLND is the most invasive and reliable method for establishing metastatic disease in pelvic lymph nodes. However, frozen sectioning has been reported to be false-negative in 33% of patients [6]. Laparoscopic PLND is less invasive and almost as accurate in sampling lymph nodes (90%). However, this method requires more skill and experience, and if no lymph node metastases are found a second operation is performed [7]. Therefore, a noninvasive, reliable method for detecting and staging nodal metastasis would reduce unnecessary surgery.

CT and MR imaging are reported to be the most accurate noninvasive techniques for nodal staging, but accuracy rates vary widely. For CT, the sensitivity varies from 0% to 100%, and the specificity varies from 44% to 100%

TABLE 1	Results of Pelvic Lymph Node Staging in Patients with Prostatic Carcinoma		
	Pathologic Examination		
MR Imaging	Metastases		
Metastases	No	Yes	Total
No	47	6	53
Yes	1	9	10
Total	48	15	63

Note.—The MR technique had a sensitivity of 60%, a specificity of 98%, an accuracy of 89%, a positive predictive value of 90%, and a negative predictive value of 89%.

TABLE 2	Results of Pelvic Lymph Node Staging in Patients with Bladder Carcinoma		
	Pathologic Examination		
MR Imaging	Metastases		
Metastases	No	Yes	Total
No	41	5	46
Yes	1	24	25
Total	42	29	71

Note.—The MR technique proved to have a sensitivity of 83%, a specificity of 98%, an accuracy of 92%, a positive predictive value of 96%, and a negative predictive value of 89%.

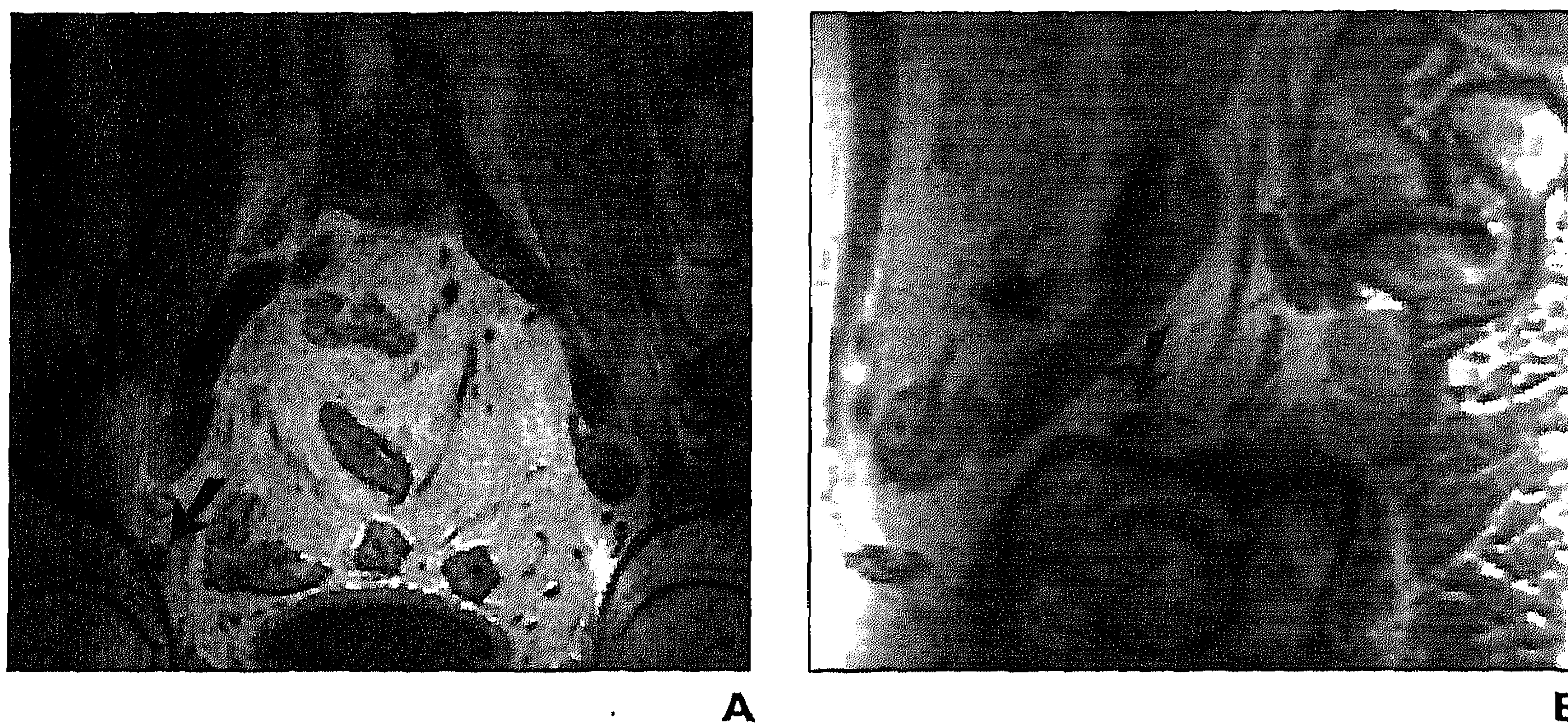


Fig. 5.—58-year-old man with prostatic cancer and false-negative node at MR examination. Reconstructed three-dimensional magnetization prepared-rapid gradient echo images in coronal (A) and plane parallel to right external iliac vessel (B) show lymph node with 6-mm diameter (arrow). This node contained metastatic deposits on pathologic examination.

[4, 5]. For MR imaging, the sensitivity varies from 0% to 100% and the specificity varies from 94% to 100% [8–10]. Compared with CT, MR imaging has better soft-tissue contrast and the potential of multiplanar imaging without IV contrast material. MR imaging may therefore be more accurate than CT scanning, but both imaging methods are considered similar in their ability to facilitate nodal staging [3, 5]. However, the most optimistic results were obtained with routine axial CT [4]. The reported CT technique had a sensitivity of 78%, a specificity of 97%, and an accuracy of 94%.

Because our MR technique obtained thin slices in multiple directions, the minimal axial diameter could be determined correctly. The multiplanar reconstruction allowed us to evaluate the nodal shape. By defining the maximal normal size for a round node as 8 mm instead of 1 cm, the number of true-positives increased from 25 to 33 with only one more false-positive. These findings concur with a study of Vinnicombe et al. [11], who suggested a lower limit for pelvic lymph nodes of 7 mm for internal iliac locations, 8 mm for obturator locations, 9 mm for common iliac locations and 10 mm for external iliac locations. Oyen et al. [4] also suggested lower limits of normal size for lymph nodes. They considered every asymmetric lymph node with a diameter of 6 mm or more to be abnormal. We used 8 mm as the upper limit of normal size pelvic lymph nodes. Had we chosen 6 mm, 18 patients with normal lymph nodes would have been judged to have disease (false-positives) and one patient with a true-positive node of 6.2 mm would have been correctly classified (Fig. 3). If a node is measured in a plane that is not perpendicular to its long axis, the size of the node can be overesti-

mated. We used reconstructions in every desired plane, which may explain the relatively low number of false-positive lymph nodes in our series.

Nodal Staging in Prostatic Carcinoma

Lymph node metastasis in patients with prostatic carcinoma is highly related to tumor grade and clinical stage. The chance that a patient with a well-differentiated T1a tumor has lymph node metastases is 0% [12, 13], whereas a patient with a poorly differentiated T3 tumor has a 68–93% probability of having nodal metastases [12, 14]. Lymph node metastases can also be assessed by prostate specific antigen levels [13, 15].

Because of an increasing trend to perform surgery on patients in the early stages of prostatic carcinoma, the incidence of lymph node metastases has decreased to 5–15% [16]. Therefore, routine use of PLND is no longer considered justified in all patients [13]. Also, the diagnostic yield of imaging for nodal staging is considered too low for routine use [13]. Cost-effective analysis performed by Wolf et al. [5] pointed out that imaging should be restricted to patients with a high probability of lymph node metastasis. They stated that when the probability of positive nodes based on prostate specific antigen level and clinical stage was 32%, the sensitivity of the imaging method must be 36% to be beneficial. When the sensitivity was 25%, as in their series, prior probability should be 45% if FNAB provided a sensitivity of 70%.

We achieved a high sensitivity in our series. Because metastases may occur in normally sized nodes, the sensitivity of imaging cannot be 100%. In a series of 39 lymph node

metastases [6], 14 were present in lymph nodes smaller than 1 mm. Of these, seven were not recognized on frozen sections.

In our study, subjects were restricted to those patients whose true disease status was verified by pathologic examination (verification bias). If clinicians' confidence in MR staging increases, the need for pathologic confirmation decreases. A patient with obvious T3c disease (seminal vesicle invasion) and enlarged lymph nodes will no longer undergo FNAB, and the number of true-positive nodes decreases. In addition, the real prevalence of disease affects the reported figures. In our hospital MR staging is no longer indicated in patients with low-grade tumors (prostate specific antigen concentration < 10 ng/ml), so we expect a lower number of true-negative results.

Nodal Staging in Urinary Bladder Carcinoma

In patients with urinary bladder carcinoma, lymph node metastases is related strongly to tumor stage. Lymph node metastases in patients with superficial tumors (less than T3) are rare, but if the deep muscle layer is involved (T3a) or if extravesical invasion is seen, the incidence of lymph node metastases rises to 20–30% and 50–60%, respectively [17]. Although some authors advocate radical cystectomy even when the patient has microscopic metastases [18], radical cystectomy is not justified if lymph node metastases are detected [19].

The sensitivity of nodal staging in patients with urinary bladder carcinoma was better than that in patients with prostatic carcinoma. The difference between these two groups of patients is also seen in previous reports. For prostatic cancer and urinary bladder cancer, the overall reported sensitivities for nodal staging with MR imaging are 32% [1, 4, 5, 10, 20–25] and 64% [10, 19, 26–32], respectively.

The 3D MP-RAGE sequence in our hospital plays an integral part in staging urinary bladder carcinoma. Therefore, nodal staging does not affect the costs of staging. In patients with urinary bladder carcinoma, laparoscopic PLND is no longer done because of the chances of tumor seeding. In patients with lymph node metastases shown by MR imaging we use FNAB guided by MR imaging.

FNAB

FNAB of pelvic lymph nodes has been performed under sonographic [33], CT [4], or lymphangiographic [34] guidance. The

reported sensitivity varies from 50% to 100% with a mean of 70% [5]. In our preliminary study of FNAB, we achieved a sensitivity of 60% in 10 procedures, obviating the need for radical cystectomy in six of nine patients. False-negative results were obtained in the first patient in whom we performed the procedure. Compared with CT, FNAB has no advantages; it is more time-consuming and expensive. With new MR-imaging-compatible puncture devices and open-configuration, superconducting MR imagers, which allow direct access to the patient during the procedure [35], we expect to overcome some of these problems.

Nodal staging using the 3D MP-RAGE technique is excellent compared with other MR studies and most CT studies. Therefore, local and nodal staging should be integrated into one MR examination. We advise MR staging in all patients with urinary bladder carcinoma with muscular invasion who are considered surgical candidates and in candidates for radical prostatectomy who have a Gleason score of seven or more (moderately and poorly differentiated tumors) and a prostate specific antigen level of 10 ng/ml or more. If a lymph node is considered to contain metastatic disease, an FNAB is advised.

Acknowledgment

We thank Janet Husband for reviewing the manuscript.

References

1. Hricak H, Dooms GC, Jeffrey RB, et al. Prostatic carcinoma: staging by clinical assessment, CT and MR imaging. *Radiology* 1987;162:331-336
2. Barentsz JO, Jager GJ, Mugler JP III, et al. Staging urinary bladder cancer: value of T1-weighted three-dimensional magnetization prepared-rapid gradient-echo and two-dimensional spin-echo sequences. *AJR* 1995;164:109-115
3. Husband JE. Review: staging bladder cancer. *Clin Radiol* 1992;46:153-159
4. Oyen RH, Van Poppel HP, Ameye FE, Van de Voorde WA, Baert AL, Baert LV. Lymph node staging of localized prostatic carcinoma with CT and CT-guided fine-needle aspiration biopsy: prospective study of 285 patients. *Radiology* 1994;190:315-322
5. Wolf JS, Cher M, dalla'Era M, Presti JC, Hricak H, Carroll PR. The use and accuracy of cross-sectional imaging and fine needle aspiration cytology

for detection of pelvic lymph node metastases before radical prostatectomy. *J Urol* 1995;153:993-999

6. Davis GL. Sensitivity of frozen section examination of pelvic lymph node for metastatic prostate carcinoma. *Cancer* 1995;76:661-668
7. Guazzoni G, Montorsi F, Bergamaschi F, et al. Open surgical revision of laparoscopic pelvic lymphadenectomy for staging of prostate cancer: the impact of laparoscopic learning curve. *J Urol* 1994;151:930-933
8. Kier R, Wain S, Troiano R. Fast spin-echo MR imaging of the pelvis obtained with a phased-array coil: value in localizing and staging prostatic carcinoma. *AJR* 1993;161:601-606
9. Biondetti PR, Lee JK, Ling D, Catalona WJ. Clinical stage B prostate carcinoma: staging with MR imaging. *Radiology* 1987;162:325-329
10. Narumi Y, Kadota T, Inoue E, et al. Bladder tumors: staging with gadolinium-enhanced oblique MR imaging. *Radiology* 1993;187:145-150
11. Vinnicombe SJ, Norman AR, Nicolson V, Husband JE. Normal pelvic lymph nodes: evaluation by CT scanning after bipedal lymphangiography. *Radiology* 1995;194:349-355
12. Smith JA, Seaman JP, Gleidman RG, Middleton RG. Pelvic lymph node metastases from prostate cancer: influence of tumor grade and stage in 452 consecutive patients. *J Urol* 1982;130:290-292
13. Narayan P, Fournier G, Gajendran V, et al. Utility of preoperative serum prostate-specific antigen concentration and biopsy gleason score in predicting risk of pelvic lymph node metastases in prostate cancer. *Urology* 1994;44:519-524
14. Donohue RE, Mani JH, Whitesel JA. Pelvic lymph node dissection: guide to patient management in clinically locally confined adenocarcinoma of prostate. *Urology* 1982;20:559-565
15. Bluestein DL, Bostwick DG, Bergstrahl EJ, Oesterling JE. Eliminating the need for bilateral pelvic lymphadenectomy in select patients with prostate cancer. *J Urol* 1994;151:1315-1320
16. Petros JA, Catalona WJ. Lower incidence of unsuspected lymph node metastases in 521 consecutive patients with clinically localized prostate cancer. *J Urol* 1992;147:1574-1575
17. van der Werf-Messing B, Schroeder RH, Bush H. Bladder. In: Halman KE, ed. *Textbook of cancer*. London: Chapman and Hall, 1982:457-474
18. Lerner SP, Skinner DG, Lieskovsky G, et al. The rationale for en bloc pelvic lymph node dissection for bladder cancer patients with nodal metastases: long-term results. *J Urol* 1993;149:758-765
19. Barentsz JO, Debryne FM, Ruijs SJJ. *Magnetic resonance of carcinoma of the urinary bladder*. Boston: Kluwer, 1990
20. Hricak H, White S, Vigneron DB, et al. Carcinoma of the prostate gland: MR imaging with pelvic phased-array coils versus integrated endorectal-pelvic phased-array coils. *Radiology* 1994;193:703-709
21. Bezzi M, Kressel HY, Allen KS, et al. Prostatic

carcinoma: staging with MR imaging at 1.5 T. *Radiology* 1988;169:339-346

22. Hammerer P, Huland H, Sparenberg A. Digital rectal examination, imaging, and systematic-sextant biopsy in identifying operable lymph node-negative prostatic carcinoma. *Eur Radiol* 1992;22:281-287
23. Mukamel E, Hannah J, Barbaric Z, de Kernion JB. The value of computed tomography scan and magnetic resonance imaging in staging prostatic carcinoma: comparison with clinical and histological staging. *J Urol* 1986;136:1231-1233
24. Rifkin MD, Zerhouni EA, Gatsonis CA, et al. Comparison of magnetic resonance imaging and ultrasonography in staging early prostate cancer: results of a multi-institutional cooperative trial. *N Engl J Med* 1990;323:621-626
25. McSherry SA, Levy F, Schiebler ML, Keefe B, Dent GA, Mohler JL. Preoperative prediction of pathological tumor volume and stage in clinically localized prostate cancer: comparison of digital rectal examination, transrectal ultrasonography and magnetic resonance imaging. *J Urol* 1991;146:85-89
26. Buy J-N, Moss AA, Guinet C, et al. MR staging of bladder carcinoma: correlation with pathologic findings. *Radiology* 1988;169:695-700
27. Rholi KS, Lee JKT, Heiken JP, Ling D, Glazer HS. Primary bladder carcinoma: evaluation with MR imaging. *Radiology* 1987;163:117-121
28. Amendola MA, Glazer GM, Grossman HB, Aisen AM, Francis IR. Staging of bladder carcinoma: MRI-CT-surgical correlation. *AJR* 1986;146:1179-1183
29. Bryan PJ, Butler HE, LiPuma JP, Resnick MI, Kursh ED. CT and MR imaging in staging bladder neoplasms. *J Comput Assist Tomogr* 1987;11:96-101
30. Tavares NJ, Demas BE, Hricak H. MR imaging of bladder neoplasms: correlation with pathologic staging. *Urol Radiol* 1990;12:27-33
31. Tanimoto A, Yuasa Y, Imai Y, et al. Bladder tumor staging: comparison of conventional and gadolinium-enhanced dynamic MR imaging and CT. *Radiology* 1992;185:741-747
32. Kim B, Semelka RC, Ascher SM, Chalpin DB, Carroll PR, Hricak H. Bladder tumor staging: comparison of contrast-enhanced CT, T1- and T2-weighted MR imaging, dynamic gadolinium-enhanced imaging, and late gadolinium-enhanced imaging. *Radiology* 1994;193:239-245
33. Nagano T, Nakai Y, Taniguchi F, et al. Diagnosis of paraaortic and pelvic lymph node metastasis of gynecologic malignant tumors by ultrasound-guided percutaneous fine-needle aspiration biopsy. *Cancer* 1991;68:2571-2574
34. Chagnon S, Cochand-Priollet B, Gzaoui M, et al. Pelvic cancers: staging of 139 cases with lymphography and fine-needle aspiration biopsy. *Radiology* 1989;173:103-106
35. Schenck JF, Jolesz FA, Roemer PB, et al. Superconducting open-configuration MR imaging system for image-guided therapy. *Radiology* 1995;195:805-814