

REVIEW ARTICLE

MECHANISMS OF DISEASE

Pemphigus, Bullous Impetigo, and the Staphylococcal Scalded-Skin Syndrome

John R. Stanley, M.D., and Masayuki Amagai, M.D., Ph.D.

From the Departments of Dermatology, University of Pennsylvania School of Medicine, Philadelphia (J.R.S.); and Keio University School of Medicine, Tokyo (M.A.). Address reprint requests to Dr. Stanley at the University of Pennsylvania, 211 CRB, 415 Curie Blvd., Philadelphia, PA 19104.

N Engl J Med 2006;355:1800-10.
Copyright © 2006 Massachusetts Medical Society.

PEMPHIGUS, WHICH IS CAUSED BY AUTOANTIBODIES, AND BULLOUS IMPETIGO (including its generalized form, the staphylococcal scalded-skin syndrome), which is caused by *Staphylococcus aureus*, are seemingly unrelated diseases. However, 200 years ago, astute clinicians realized that these diseases had enough clinical similarities to call bullous impetigo and the scalded-skin syndrome in infants “pemphigus neonatorum.”^{1,2} In this review we explain how a common mechanism accounts for the clinical overlap of these blistering diseases of the skin, and how the unraveling of the molecular pathophysiology of pemphigus provided the clues that were necessary to determine the mechanism of the formation of blisters in bullous impetigo and the staphylococcal scalded-skin syndrome. We also discuss how this new understanding of the pathophysiology of pemphigus could improve the diagnosis and treatment of this potentially life-threatening disease.

PEMPHIGUS

There are two major types of pemphigus, pemphigus vulgaris and pemphigus foliaceus.³ Patients with pemphigus vulgaris present with blisters and erosions of mucous membranes and skin. There are two subtypes of pemphigus vulgaris: the mucosal-dominant type, with mucosal lesions but minimal skin involvement, and the mucocutaneous type, with extensive skin blisters and erosions in addition to mucosal involvement (Fig. 1A). Patients with pemphigus foliaceus have scaly and crusted superficial erosions of the skin but not of mucous membranes (Fig. 1B).

The blisters of pemphigus vulgaris are characterized by a loss of cell adhesion in the deep epidermis, just above the basal layer (Fig. 1C), whereas in pemphigus foliaceus, the loss of cell adhesion is in the more superficial epidermis, just below the stratum corneum, which is the layer of dead keratinocytes that forms the barrier of the skin (Fig. 1D).

The blood of patients with pemphigus contains IgG antibodies that bind to the surface of normal keratinocytes; this binding is shown with the use of immunofluorescence (Fig. 1E and 1F). Immunofluorescence staining also shows IgG antibodies on the surface of the keratinocytes in biopsy specimens of the skin from patients with pemphigus.

These antibodies, which are autoantibodies because they react with the patient's own cells, are directly pathogenic — that is, they can cause loss of adhesion between keratinocytes, which results in blistering. When injected into neonatal mice, human IgG from patients with pemphigus vulgaris or pemphigus foliaceus binds to the surface of the epidermal keratinocytes (Fig. 1I) and causes blisters (Fig. 1G) with the typical histologic features of pemphigus vulgaris (Fig. 1H) or pemphigus foliaceus (Fig. 2D).^{4,5}

Therefore, pemphigus vulgaris and pemphigus foliaceus are related in that they

are blistering diseases caused by autoantibodies that interfere with adhesion between keratinocytes. They can be differentiated clinically by the presence or absence of involvement of the mucous membranes, and histologically by the epidermal level where the blistering occurs.

DESMOGLEINS

Because keratinocyte adhesion is defective in patients with pemphigus foliaceus and pemphigus vulgaris, it was logical to wonder whether the autoantibodies in patients with these disorders bind adhesion molecules in desmosomes. Desmosomes are cell adhesion structures that are especially prominent in the epidermis and mucous membranes.⁶ Transmembrane molecules that were discovered in desmosomes⁷ belong to two families of proteins — desmogleins and desmocollins (Fig. 3). Both families are related to cadherins, which are known to modulate cell–cell adhesion. For this reason, desmogleins and desmocollins are now called desmosomal cadherins, which presumably modulate adhesion within desmosomes.⁸ Serum from patients with pemphigus foliaceus contains antibodies that bind to desmoglein 1, a member of the desmoglein family.^{9,10} The antigen recognized by the autoantibodies in patients with pemphigus vulgaris was cloned by using immunostaining with the autoantibodies to identify clones from a phage library that expressed proteins from normal keratinocytes. This screening showed that the pemphigus vulgaris antigen was a previously unknown member of the desmoglein family. The antigen was subsequently called desmoglein 3.¹¹ Thus, pemphigus vulgaris and pemphigus foliaceus, which are related but distinct diseases, were found to have related but distinct autoantigens — desmoglein 3 and desmoglein 1, respectively.

PATHOGENICITY OF ANTIDESMOGLEIN ANTIBODIES

Antidesmoglein antibodies cause blisters. The injection of affinity-purified autoantibodies against desmoglein 1 or desmoglein 3 into mice causes blisters with the typical histologic features of pemphigus foliaceus or pemphigus vulgaris, respectively.^{12,13} Furthermore, the gross and microscopical lesions of pemphigus vulgaris can be induced in mice by intraperitoneal inoculation of hybrid-

oma cells that produce monoclonal anti–desmoglein 3 antibodies.¹⁴ In addition, desmoglein 1 or desmoglein 3 can adsorb the corresponding pathogenic antibodies from pemphigus serum.^{13,15} When monitored in individual patients, the titers of anti–desmoglein 1 and anti–desmoglein 3 IgG autoantibodies in serum, as measured by indirect immunofluorescence or enzyme-linked immunosorbent assay (ELISA), generally correlate with disease activity.^{16–18}

Pemphigus serum may bind antigens other than desmoglein 1 and desmoglein 3, but the clinical significance of these other antibodies is not well understood. For example, a subgroup of IgG anti–desmoglein 1 autoantibodies cross-reacts with desmoglein 4, but these antibodies have no pathogenic effect.¹⁹ Antibodies in pemphigus serum can bind to other antigens, such as acetylcholine receptors,^{20,21} but they have not been shown to directly mediate blister formation. Nevertheless, acetylcholine receptors may modulate disease activity in some patients who have pemphigus vulgaris.²²

DESMOGLEIN COMPENSATION

Clinically different subgroups of patients with pemphigus have characteristic profiles of antidesmoglein antibodies (Table 1).^{23,24} These autoantibody patterns, and the distribution of desmoglein isoforms in the epidermis and mucous membranes, suggest that desmoglein compensation can explain blister localization in patients with pemphigus vulgaris and pemphigus foliaceus (Fig. 4).^{25,26} The desmoglein compensation theory rests on the following two observations: anti–desmoglein 1 or anti–desmoglein 3 autoantibodies inactivate only the corresponding desmoglein, and functional desmoglein 1 or desmoglein 3 alone is usually sufficient for cell–cell adhesion.

Desmoglein compensation has been validated experimentally in the neonatal-mouse model of pemphigus. The injection of anti–desmoglein 1 autoantibodies into mice in which the desmoglein 3 (*Dsg3*) gene has been deleted causes blistering in areas that are protected from blistering by desmoglein 3 in normal mice.²⁶ Conversely, transgenic mice that have been engineered to express desmoglein 3 in areas that normally express only desmoglein 1 are protected from the blistering caused by anti–desmoglein 1 antibodies.²⁷ Finally, transgenic expression of desmoglein 1 in areas

that normally express only desmoglein 3 can at least partially correct defective cell–cell adhesion due to the genetic loss of desmoglein 3 in knockout mice.²⁸ Because the distribution of desmogleins in neonatal skin is similar to the distribution of desmogleins in mucous membranes, which do not blister in pemphigus foliaceus (Fig. 4A), desmoglein compensation explains why blisters usually do not develop in neonates whose mothers have pemphigus foliaceus, even though maternal autoantibodies cross the placenta and bind to the neonatal epidermis.²⁷

PEMPHIGUS AUTOANTIBODIES AND LOSS OF ADHESION OF KERATINOCYTES

INACTIVATION OF DESMOGLEIN

Some investigators proposed that pemphigus antibodies act by initiating a proteolytic cascade that nonspecifically cleaves cell-surface molecules.^{29,30} Subsequent studies, however, did not support this hypothesis.³¹

Other investigations have shown that anti-desmoglein 3 and anti-desmoglein 1 antibodies inactivate their targeted desmogleins with considerable specificity. The lesions caused by these antibodies are remarkably similar, if not identical, to the lesions caused by direct inactivation of desmoglein 3 or desmoglein 1. For example, the pathological features of the skin of knockout mice with an inactivated *Dsg3* gene are similar to those in patients with pemphigus vulgaris and to those in mice injected with anti-desmoglein 3 antibodies.³² And in both mice and humans, exfoliative toxin, which specifically cleaves desmoglein 1, causes blisters that are identical to the blisters caused by the anti-desmoglein 1 autoantibodies in cases of pemphigus foliaceus.³³ These findings, together with the desmoglein compensation theory, suggest that pemphigus antibodies inactivate only their targeted desmoglein and do not cause a generalized loss of function of cell-surface adhesion molecules.

DIRECT AND INDIRECT EFFECTS OF PEMPHIGUS ANTIBODIES

Whether pemphigus autoantibodies act directly or indirectly is controversial. There is evidence that pemphigus autoantibodies block adhesion by directly interfering with desmoglein transinterac-

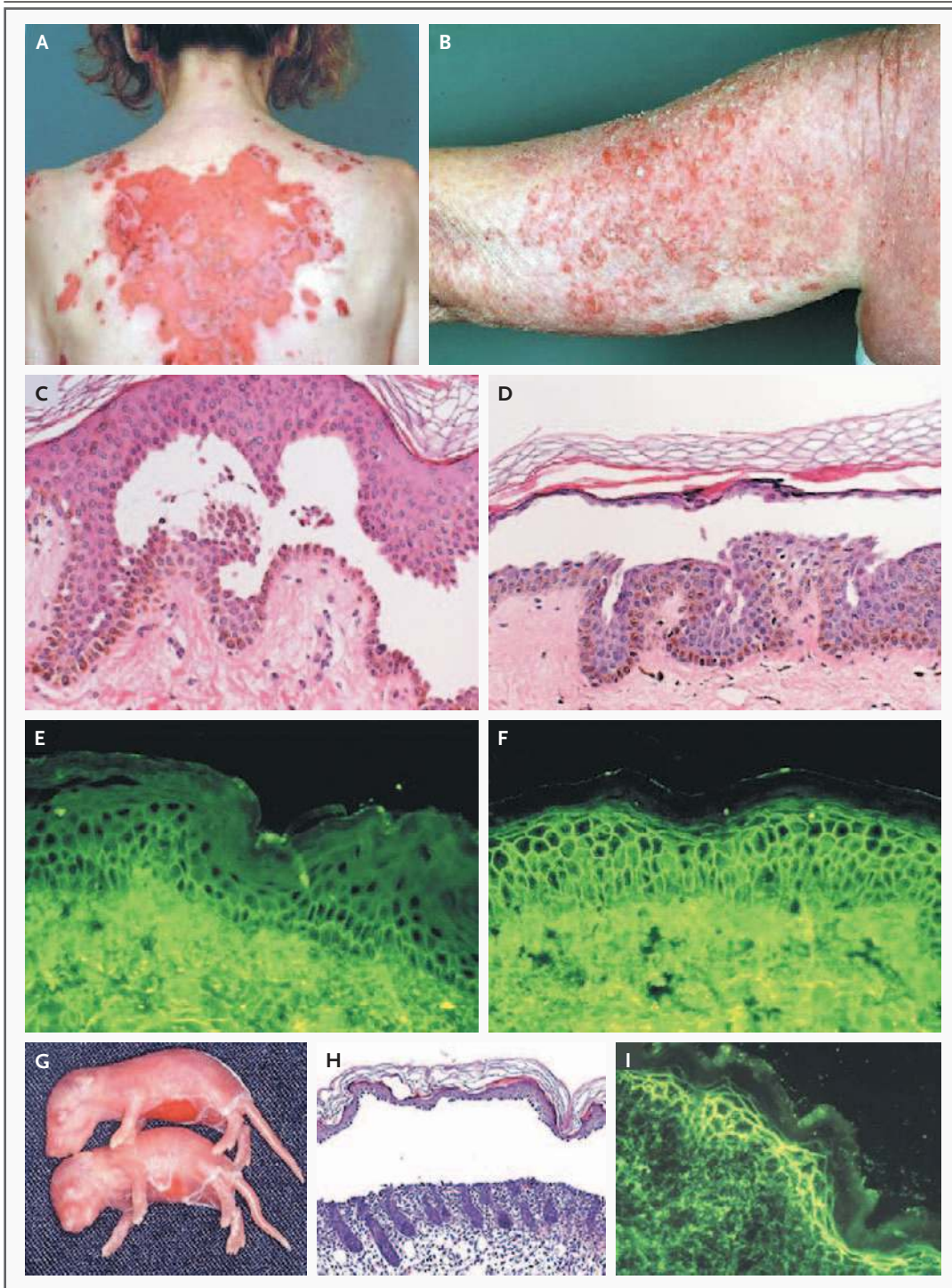
Figure 1 (facing page). Clinical, Histologic, and Immunopathological Features of Pemphigus.

The skin of a patient with mucocutaneous pemphigus vulgaris (Panel A) shows a large erosion surrounded by smaller erosions, resulting from unroofing and extension at the edges of expansive, deep epidermal blisters. In contrast, a patient with pemphigus foliaceus (Panel B) has scaly and crusted lesions resulting from the breaking of very superficial epidermal blisters. In pemphigus vulgaris the intraepidermal blister due to loss of adhesion between keratinocytes (acantholysis) occurs deep in the epidermis, just above the basal-cell layer (Panel C), whereas in pemphigus foliaceus it occurs in the superficial epidermis, just below the stratum corneum (Panel D). Indirect immunofluorescence on normal human skin with the use of serum (from a patient with mucosal-dominant pemphigus vulgaris) containing anti-desmoglein 3 IgG shows staining deep in the epidermis (Panel E). Serum from a patient with pemphigus foliaceus, containing anti-desmoglein 1 IgG autoantibodies, stains throughout the epidermis (Panel F). The dermal staining indicates IgG that is always in the dermis of normal skin. Neonatal mice injected with IgG from a patient with mucocutaneous pemphigus vulgaris have extensive skin blisters (Panel G) with the typical histologic features of pemphigus vulgaris (Panel H) and in vivo deposition of IgG on keratinocyte surfaces (Panel I).

tions (i.e., interactions of desmoglein on one cell with itself or with desmocollins on the adjacent cell). Studies have shown that fragments of pemphigus autoantibodies that contain only a single antigen-binding domain and lack the effector (Fc) region of antibodies can induce blisters in mice³⁴⁻³⁶ and, because they lack the ability to cross-link cell-surface molecules, probably interfere directly with adhesion. Furthermore, a mouse monoclonal anti-desmoglein 3 IgG antibody that binds to the N-terminal adhesive interface of desmoglein 3 induces pemphigus vulgaris lesions in mice, whereas other monoclonal antibodies that react with functionally less important parts of desmoglein 3 do not cause lesions in mice.¹⁴

Alternatively, the results of a recent study using single-molecule atomic-force measurements, a biomechanical method that measures the degree of protein–protein binding, suggest that anti-desmoglein 1 IgG antibodies in pemphigus foliaceus serum do not interfere directly with desmoglein 1 adhesive transinteractions.³⁷ In this extracellular system, the binding of desmoglein 1 to itself was not inhibited by pathogenic anti-desmoglein 1 antibodies.

Other studies suggest that direct functional



inactivation of desmoglein may not be sufficient to cause the blisters and that pemphigus autoantibodies may act through a more complex signaling mechanism. The addition of IgG from pemphigus vulgaris serum to cultured keratinocytes

induces a number of signals, including a transient increase in intracellular calcium and inositol 1,4,5-triphosphate, activation of protein kinase C, and phosphorylation of desmoglein 3, which in turn may lead to the internalization of desmoglein 3

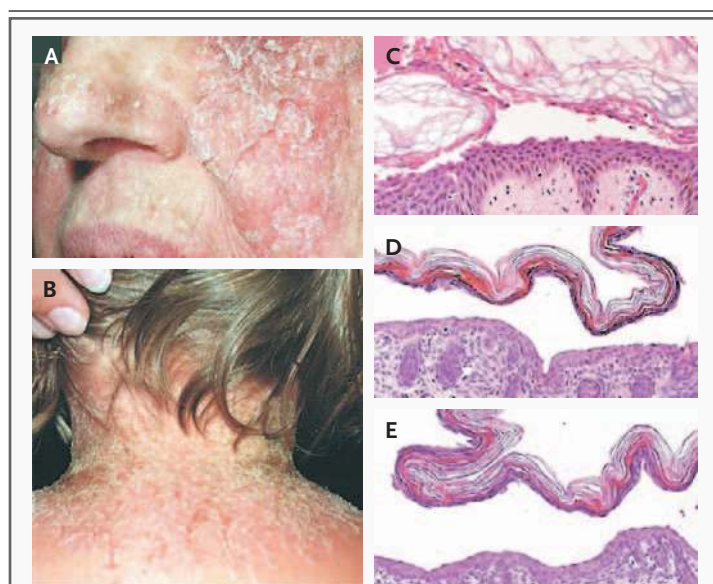

Figure 2. Clinical and Histologic Similarities between Pemphigus Foliaceus and the Staphylococcal Scalded-Skin Syndrome.

Patients with pemphigus foliaceus (Panel A) and those with the staphylococcal scalded-skin syndrome (Panel B) have scaly and crusted superficial erosions. Histologic features of the blisters in the staphylococcal scalded-skin syndrome (Panel C) include loss of cell adhesion in the superficial epidermis, just below the stratum corneum, which is indistinguishable from the loss of cell adhesion in pemphigus foliaceus (see Fig. 1D). Neonatal mice injected with anti-desmoglein 1 IgG autoantibodies from humans with pemphigus foliaceus (Panel D) or exfoliative toxin from *S. aureus* (Panel E) have superficial epidermal blisters with identical histologic features. (Panel B courtesy of Dr. Albert Yan, and Panel C courtesy of Dr. Phillip LeBoit.)

from cell surfaces, with resultant depletion of desmoglein 3 from desmosomes.³⁸⁻⁴³

Pemphigus vulgaris IgG is also reported to induce activation of other signaling pathways that may result in reorganization of the cytoskeleton,^{44,45} apoptosis of keratinocytes, or both.⁴⁶ Further studies are needed to clarify whether such signaling is involved in blister formation in vivo, because most of the studies on signal transduction were performed in vitro with the use of cultured keratinocytes.

BULLOUS IMPETIGO AND THE STAPHYLOCOCCAL SCALDED-SKIN SYNDROME

PEMPHIGUS NEONATORUM

A condition of infants that resembled pemphigus foliaceus was called pemphigus neonatorum by clinicians in the 18th and 19th centuries.^{1,2} Pemphigus neonatorum was actually bullous impetigo

or the staphylococcal scalded-skin syndrome. The observation of the similarities among pemphigus foliaceus, bullous impetigo, and the scalded-skin syndrome was the first suggestion that the pathophysiology of pemphigus might also apply to the other disorders.

PRODUCTION OF EXFOLIATIVE TOXIN BY STAPHYLOCOCCUS

Staphylococcal skin infections are among the most common skin diseases in children. Classic studies more than 30 years ago showed that the blisters in bullous impetigo and the scalded-skin syndrome are caused by exfoliative toxin released by staphylococcus.^{47,48} Subsequently, it was discovered that two major serotypes of this toxin, A and B, cause bullous impetigo and the scalded-skin syndrome.⁴⁹ In patients with bullous impetigo, the toxin produces blisters locally at the site of infection, whereas in cases of the scalded-skin syndrome, it circulates throughout the body, causing blisters at sites distant from the infection.⁴⁹ The risk of death from the scalded-skin syndrome is less than 5% among children, but among adults, the syndrome usually occurs in those who have renal disease or who are immunosuppressed, and the risk of death can be as high as 60%.^{49,50}

Exfoliative toxin injected into neonatal mice causes the blisters typical of bullous impetigo and the scalded-skin syndrome.⁴⁸ Exactly how exfoliative toxin causes these blisters was controversial for many years. However, when exfoliative toxin A and exfoliative toxin B were cloned, they were found to have amino acid sequences and crystal structures suggestive of serine proteases.⁵¹⁻⁵⁵ In some crystal solutions this structure was slightly irregular in that one peptide bond in the catalytic site was rotated 180 degrees in the wrong direction to form an active catalytic pocket. These findings indicated that exfoliative toxin might not be active as a protease unless it bound a specific substrate that was able to reform its catalytic pocket.

The specific substrate for exfoliative toxin remained elusive for several years. However, four important clues from studies of pemphigus foliaceus indicated that the substrate might be desmoglein 1. First, the clinical features of the scalded-skin syndrome (and its localized form, bullous impetigo) (Fig. 2B) resemble those of pemphigus foliaceus (Fig. 2A). Second, in cases of the scalded-skin syndrome, the blisters caused by exfoliative

toxin appear only on the skin, not on mucous membranes (the same distribution as the lesions caused in pemphigus foliaceus). Third, blisters in bullous impetigo and the scalded-skin syndrome (Fig. 2C) are histologically indistinguishable from those in pemphigus foliaceus (Fig. 1D). Finally, the injection of pemphigus foliaceus IgG antibodies or exfoliative toxin into neonatal mice causes blisters with identical gross and histologic features (Fig. 2D and 2E). These clues suggested that exfoliative toxin, like pemphigus foliaceus IgG, might target desmoglein 1. If desmoglein 1 was specifically cleaved by exfoliative toxin, then — just as in pemphigus foliaceus — desmoglein compensation would account for the localization of the blisters in bullous impetigo and the scalded-skin syndrome only in the superficial epidermis, not in mucous membranes (Fig. 4B).

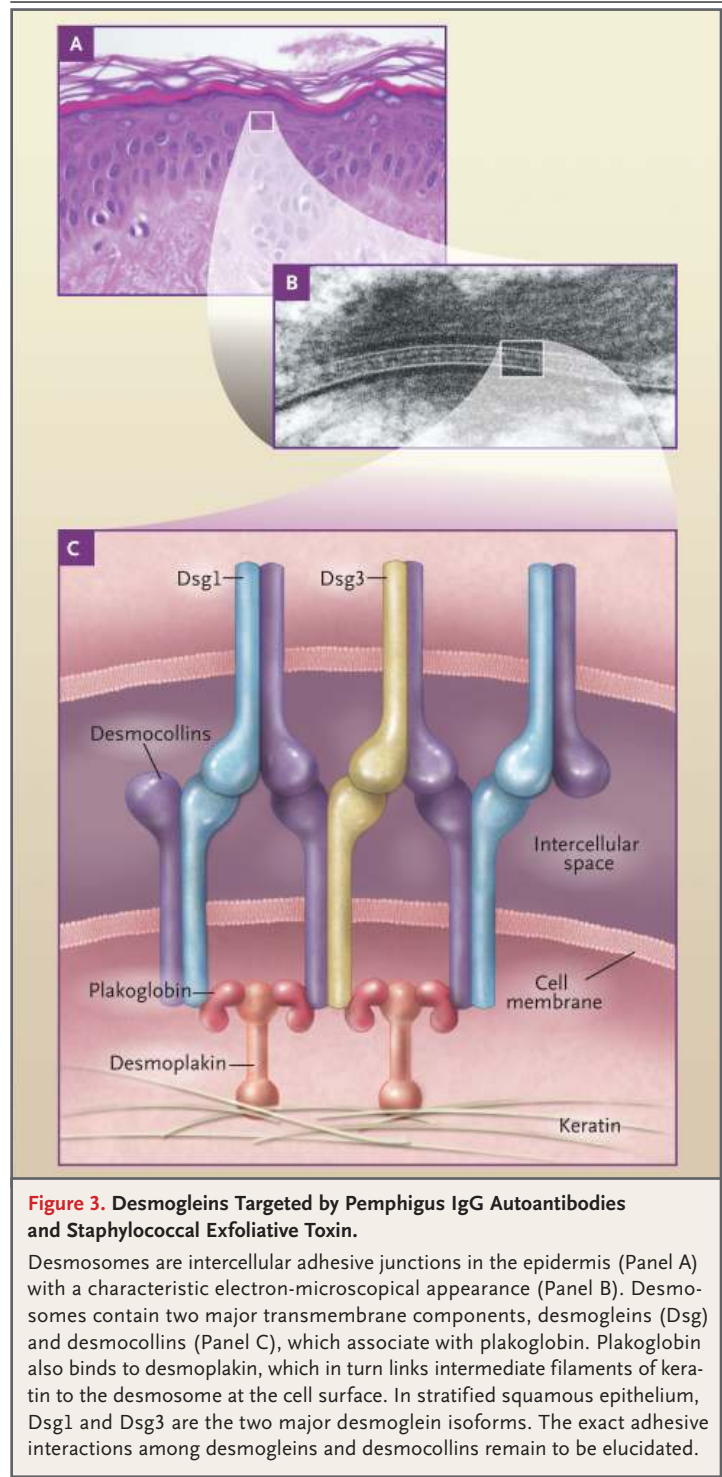
Indeed, studies show that exfoliative toxins do cleave desmoglein 1, but not the closely related desmoglein 3, on cultured human keratinocytes and keratinocytes in the skin of neonatal mice.^{33,56} Exfoliative toxin also cleaves recombinant desmoglein 1, but not desmoglein 3 or the intercellular adhesion molecule E-cadherin, in solution, showing a direct proteolytic effect of the toxin. Moreover, exfoliative toxin efficiently cleaves a particular peptide bond in desmoglein 1 at a calcium-binding site, and its ability to do so depends on the conformation of the site — that is, the toxin cannot cleave denatured desmoglein 1.⁵⁷⁻⁵⁹ The ability of the toxin to cleave desmoglein 1 also depends on amino acids about 100 residues upstream of the cleavage site.

These findings suggest that exfoliative toxin cleaves desmoglein 1 by the key-in-lock mechanism that is common to many proteolytic enzymes with limited substrate specificities. This remarkable mechanism efficiently targets one molecule — desmoglein 1 — that allows staphylococcus to grow below the epidermal barrier but superficially enough to be contagious by skin contact.

DIAGNOSIS AND THERAPY

BULLOUS IMPETIGO AND THE STAPHYLOCOCCAL SCALDED-SKIN SYNDROME

The staphylococcal scalded-skin syndrome can sometimes resemble another widespread blistering disease, toxic epidermal necrolysis, which is usually caused by a drug reaction. These two diseases can be differentiated quickly by examining



a frozen section of a biopsy specimen, which shows a superficial epidermal blister in cases of the scalded-skin syndrome and a subepidermal blister with necrotic keratinocytes in toxic epidermal necrolysis. Treatment of patients with bullous impetigo

Table 1. Antidesmoglein Antibody Profiles in Subtypes of Pemphigus.

Subtype	IgG Autoantibody	
	Anti-Desmoglein 1	Anti-Desmoglein 3
Pemphigus foliaceus	Yes	No
Pemphigus vulgaris		
Mucosal dominant	No	Yes
Mucocutaneous	Yes	Yes

or the scalded-skin syndrome usually consists of antibiotics, but one must keep in mind that cases caused by methicillin-resistant *S. aureus* have been reported.^{60,61}

PEMPHIGUS

The presence of IgG autoantibodies that bind to the keratinocyte surface or desmogleins is the gold standard for the diagnosis of pemphigus and its differentiation from other vesiculobullous or pustular diseases. Until recently, direct immunofluorescence (on the skin of patients) or indirect immunofluorescence (in serum from patients) was the standard method of detecting antibodies that bind to the surface of keratinocytes. However, ELISA with the use of recombinant desmoglein 1 and desmoglein 3 as antigens is much simpler and more quantifiable than immunofluorescence.^{17,18} ELISA to identify antibodies against desmoglein 1 and desmoglein 3 can be used not only for diagnosing the type of pemphigus but also for distinguishing subtypes of pemphigus vulgaris (Table 1).^{23,24} ELISA scores, which show parallel fluctuations with the activity of pemphigus vulgaris and pemphigus foliaceus, are useful for monitoring disease activity, planning schedules for tapering corticosteroid therapy, and predicting flares or relapses before they are clinically evident.^{17,62}

In general, pemphigus is treated by suppressing the immune system to blunt the autoimmune response. However, more targeted therapy may be possible. For example, recent case reports indicate that rituximab, an anti-CD20 monoclonal antibody that targets B cells (lymphocytes that mature to antibody-producing plasma cells), can be very effective in treating patients with pemphigus that is refractory to more standard immunosuppressive therapy.⁶³⁻⁶⁵

It might be possible to focus the development of new, more specific treatments for pemphigus on the autoantibodies themselves, especially if the

population of pathogenic autoantibodies in the disease is not diverse. The extent of their diversity has been studied by phage display, which allows the cloning of monoclonal antidesmoglein antibodies from patients with pemphigus. This method has been used in studies of one patient with pemphigus vulgaris³⁶ and one with pemphigus foliaceus (unpublished data); the results indicate that the populations of antidesmoglein antibodies in both cases were highly restricted, as judged by the lack of diversity of heavy chains in populations of monoclonal antibodies. This finding contrasts with the usual population of antibacterial antibodies, which are constructed from a large array of heavy chains and light chains. The possibility of a common structural pattern among pemphigus autoantibodies could have clinical implications for targeted therapy against a subpopulation of antibodies, as opposed to the suppression of the general production of antibodies.

Finally, understanding how T and B cells contribute to the antidesmoglein response could provide another basis for therapy. A mouse model of pemphigus vulgaris was developed by the transfer of T cells and B cells from *Dsg3*^{-/-} knockout mice, in which desmoglein 3 acts like a foreign antigen, into *Rag2*^{-/-} immunodeficient mice that express desmoglein 3.⁶⁶ The recipients of T cells and B cells from *Dsg3*^{-/-} mice produced anti-desmoglein 3 antibodies, and pemphigus vulgaris lesions developed. T and B cells were necessary for both antibody production and blister formation.⁶⁷ These results are consistent with increasing evidence of the role of autoreactive T cells in regulating the production of pathogenic IgG autoantibodies in humans.⁶⁸⁻⁷³ Furthermore, desmoglein 3-specific regulatory T cells were recently shown to be involved in the maintenance of peripheral tolerance to desmoglein 3 in healthy persons.⁷⁴ Thus, manipulation of regulatory T cells that are actively engaged in the control of a variety of physiologic and pathologic immune responses may provide a promising option for the treatment of pemphigus.^{75,76}

CONCLUSIONS

Further studies are needed to refine our understanding of the pathogenic mechanisms of pemphigus. This knowledge will provide the foundation for developing more targeted and better

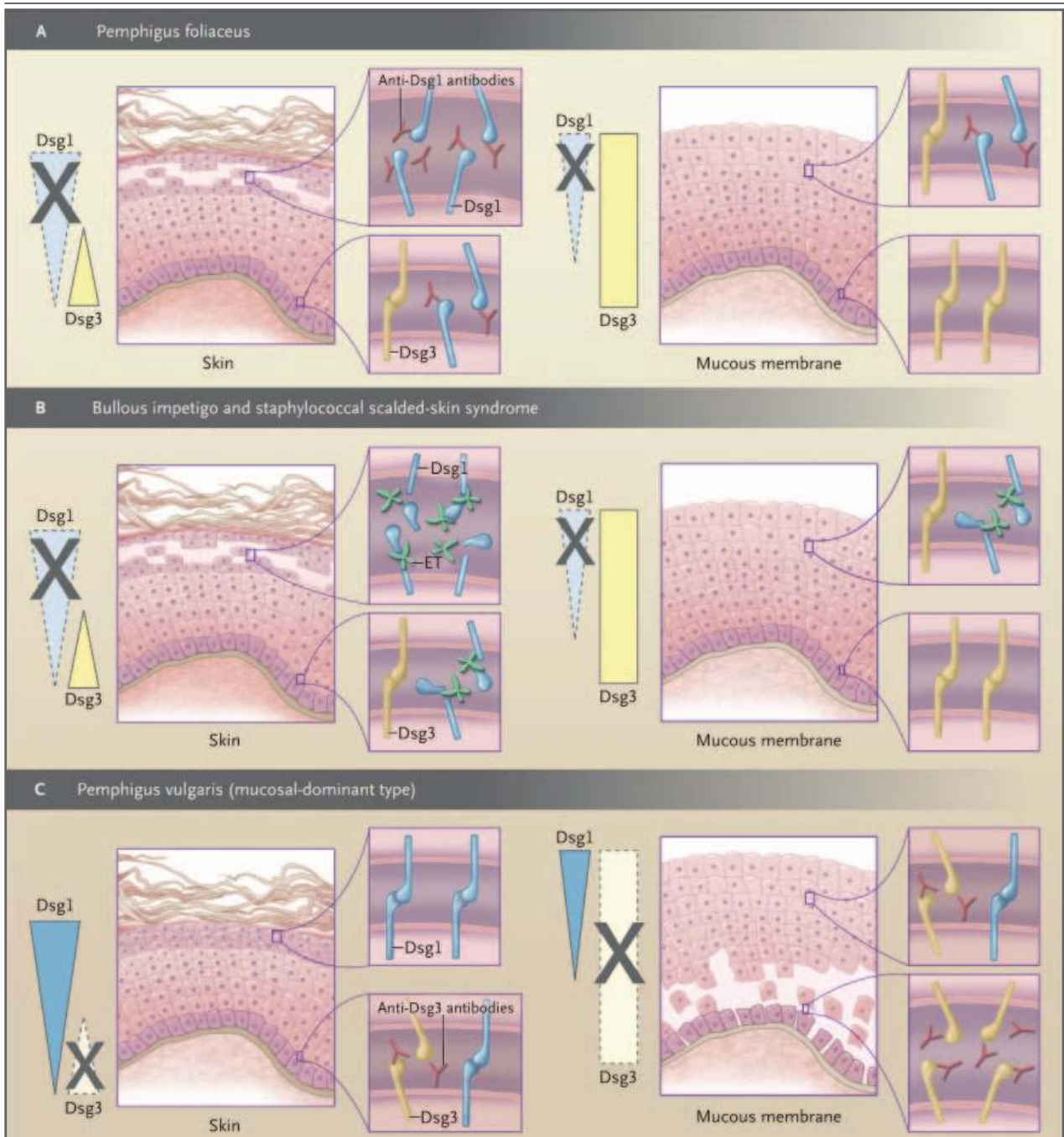


Figure 4. The Desmoglein Compensation Theory and the Sites of Blister Formation in Pemphigus, Bullous Impetigo, and the Staphylococcal Scalded-Skin Syndrome.

The colored triangles and rectangles represent the distribution of Dsg1 and Dsg3 in the skin and mucous membranes. Anti-Dsg1 IgG autoantibodies in serum from patients with pemphigus foliaceus cause superficial blisters in the skin; no blisters form in the lower epidermis or mucous membranes, because Dsg3 maintains cell–cell adhesion in those areas (Panel A). In bullous impetigo and the staphylococcal scalded-skin syndrome, exfoliative toxin (ET) produced by *S. aureus* acts like Dsg1-specific molecular scissors and exclusively cleaves Dsg1 but not Dsg3, resulting in only superficial epidermal blisters, because Dsg3 compensates in other areas (Panel B). Serum from patients with mucosal-dominant pemphigus vulgaris contains only anti-Dsg3 IgG, which causes mucosal blisters and erosions where there is no significant compensation by Dsg1 (Panel C).

tolerated therapies for these disfiguring and life-threatening diseases.

Supported by a grant (AR052672) from the National Institute of Arthritis and Musculoskeletal and Skin Diseases (to Dr. Stanley) and by Grants-in-Aid for Scientific Research from the Japa-

nese Ministry of Education, Culture, Sports, Science and Technology (to Dr. Amagai).

No potential conflict of interest relevant to this article was reported.

We are indebted to Karl Holubar for historical sources on pemphigus neonatorum.

REFERENCES

- Kaposi M. Pathologie und Therapie der Hautkrankheiten. Vienna: Urban & Schwarzenberg, 1887.
- Osiander FB. Denkwürdigkeiten für die Heilkunde und Geburtshülfe. Göttingen, Germany: Vandenhoeck-Ruprecht, 1794.
- Stanley JR. Pemphigus. In: Freedberg IM, Eisen AZ, Wolff K, Austen KF, Goldsmith LA, Katz SI, eds. Fitzpatrick's dermatology in general medicine. 6th ed. Vol. 1. New York: McGraw-Hill, 2003:558-67.
- Anhalt GJ, Labib RS, Voorhees JJ, Beals TF, Diaz LA. Induction of pemphigus in neonatal mice by passive transfer of IgG from patients with the disease. *N Engl J Med* 1982;306:1189-96.
- Roscoe JT, Diaz L, Sampaio SA, et al. Brazilian pemphigus foliaceus autoantibodies are pathogenic to BALB/c mice by passive transfer. *J Invest Dermatol* 1985; 85:538-41.
- Getsios S, Huen AC, Green KJ. Working out the strength and flexibility of desmosomes. *Nat Rev Mol Cell Biol* 2004;5: 271-81.
- Gorbsky G, Steinberg MS. Isolation of the intercellular glycoproteins of desmosomes. *J Cell Biol* 1981;90:243-8.
- Garrod DR, Merritt AJ, Nie Z. Desmosomal cadherins. *Curr Opin Cell Biol* 2002; 14:537-45.
- Koulu L, Kusumi A, Steinberg MS, Klaus Kovtun V, Stanley JR. Human autoantibodies against a desmosomal core protein in pemphigus foliaceus. *J Exp Med* 1984;160: 1509-18.
- Eyre RW, Stanley JR. Human autoantibodies against a desmosomal protein complex with a calcium-sensitive epitope are characteristic of pemphigus foliaceus patients. *J Exp Med* 1987;165:1719-24.
- Amagai M, Klaus-Kovtun V, Stanley JR. Autoantibodies against a novel epithelial cadherin in pemphigus vulgaris, a disease of cell adhesion. *Cell* 1991;67:869-77.
- Amagai M, Karpati S, Prussick R, Klaus-Kovtun V, Stanley JR. Autoantibodies against the amino-terminal cadherin-like binding domain of pemphigus vulgaris antigen are pathogenic. *J Clin Invest* 1992;90:919-26.
- Amagai M, Hashimoto T, Green KJ, Shimizu N, Nishikawa T. Antigen-specific immunoadsorption of pathogenic autoantibodies in pemphigus foliaceus. *J Invest Dermatol* 1995;104:895-901.
- Tsunoda K, Ota T, Aoki M, et al. Induction of pemphigus phenotype by a mouse monoclonal antibody against the amino-terminal adhesive interface of desmoglein 3. *J Immunol* 2003;170:2170-8.
- Amagai M, Hashimoto T, Shimizu N, Nishikawa T. Absorption of pathogenic autoantibodies by the extracellular domain of pemphigus vulgaris antigen (Dsg3) produced by baculovirus. *J Clin Invest* 1994; 94:59-67.
- Sams WM Jr, Jordon RE. Correlation of pemphigoid and pemphigus antibody titres with activity of disease. *Br J Dermatol* 1971;84:7-13.
- Ishii K, Amagai M, Hall RP, et al. Characterization of autoantibodies in pemphigus using antigen-specific enzyme-linked immunosorbent assays with baculovirus-expressed recombinant desmogleins. *J Immunol* 1997;159:2010-7.
- Amagai M, Komai A, Hashimoto T, et al. Usefulness of enzyme-linked immunosorbent assay using recombinant desmogleins 1 and 3 for serodiagnosis of pemphigus. *Br J Dermatol* 1999;140:351-7.
- Nagasaka T, Nishifuji K, Ota T, Whittock NV, Amagai M. Defining the pathogenic involvement of desmoglein 4 in pemphigus and staphylococcal scalded skin syndrome. *J Clin Invest* 2004;114:1484-92.
- Vu TN, Lee TX, Ndoye A, et al. The pathophysiological significance of non-desmoglein targets of pemphigus autoimmunity: development of antibodies against keratinocyte cholinergic receptors in patients with pemphigus vulgaris and pemphigus foliaceus. *Arch Dermatol* 1998; 134:971-80.
- Nguyen VT, Ndoye A, Grando SA. Pemphigus vulgaris antibody identifies pemphaxin: a novel keratinocyte annexin-like molecule binding acetylcholine. *J Biol Chem* 2000;275:29466-76.
- Nguyen VT, Arredondo J, Chernyavsky AI, Pittelkow MR, Kitajima Y, Grando SA. Pemphigus vulgaris acantholysis ameliorated by cholinergic agonists. *Arch Dermatol* 2004;140:327-34.
- Amagai M, Tsunoda K, Zillikens D, Nagai T, Nishikawa T. The clinical phenotype of pemphigus is defined by the anti-desmoglein autoantibody profile. *J Am Acad Dermatol* 1999;40:167-70.
- Ding X, Aoki V, Mascaro JM Jr, Lopez-Swiderski A, Diaz LA, Fairley JA. Mucosal and mucocutaneous (generalized) pemphigus vulgaris show distinct autoantibody profiles. *J Invest Dermatol* 1997;109: 592-6.
- Shirakata Y, Amagai M, Hanakawa Y, Nishikawa T, Hashimoto K. Lack of mucosal involvement in pemphigus foliaceus may be due to low expression of desmoglein 1. *J Invest Dermatol* 1998;110:76-8.
- Mahoney MG, Wang Z, Rothenberger K, Koch PJ, Amagai M, Stanley JR. Explanation for the clinical and microscopic localization of lesions in pemphigus foliaceus and vulgaris. *J Clin Invest* 1999;103: 461-8.
- Wu H, Wang ZH, Yan A, et al. Protection against pemphigus foliaceus by desmoglein 3 in neonates. *N Engl J Med* 2000; 343:31-5.
- Hanakawa Y, Matsuyoshi N, Stanley JR. Expression of desmoglein 1 compensates for genetic loss of desmoglein 3 in keratinocyte adhesion. *J Invest Dermatol* 2002; 119:27-31.
- Hashimoto K, Shafran KM, Webber PS, Lazarus GS, Singer KH. Anti-cell surface pemphigus autoantibody stimulates plasminogen activator activity of human epidermal cells: a mechanism for the loss of epidermal cohesion and blister formation. *J Exp Med* 1983;157:259-72.
- Morioka S, Lazarus GS, Jensen PJ. Involvement of urokinase-type plasminogen activator in acantholysis induced by pemphigus IgG. *J Invest Dermatol* 1987; 89:474-7.
- Mahoney MG, Wang ZH, Stanley JR. Pemphigus vulgaris and pemphigus foliaceus antibodies are pathogenic in plasminogen activator knockout mice. *J Invest Dermatol* 1999;113:22-5.
- Koch PJ, Mahoney MG, Ishikawa H, et al. Targeted disruption of the pemphigus vulgaris antigen (desmoglein 3) gene in mice causes loss of keratinocyte cell adhesion with a phenotype similar to pemphigus vulgaris. *J Cell Biol* 1997;137:1091-102.
- Amagai M, Matsuyoshi N, Wang ZH, Andl C, Stanley JR. Toxin in bullous impetigo and staphylococcal scalded-skin syndrome targets desmoglein 1. *Nat Med* 2000;6:1275-7.
- Mascaro JM Jr, Espana A, Liu Z, et al. Mechanisms of acantholysis in pemphigus vulgaris: role of IgG valence. *Clin Immunol Immunopathol* 1997;85:90-6.
- Rock B, Labib RS, Diaz LA. Monovalent Fab' immunoglobulin fragments from endemic pemphigus foliaceus autoantibodies reproduce the human disease in neonatal Balb/c mice. *J Clin Invest* 1990; 85:296-9.

36. Payne AS, Ishii K, Kacir S, et al. Genetic and functional characterization of human pemphigus vulgaris monoclonal autoantibodies isolated by phage display. *J Clin Invest* 2005;115:888-99.
37. Waschke J, Bruggeman P, Baumgartner W, Zillikens D, Drenckhahn D. Pemphigus foliaceus IgG causes dissociation of desmoglein 1-containing junctions without blocking desmoglein 1 transinteraction. *J Clin Invest* 2005;115:3157-65.
38. Aoyama Y, Kitajima Y. Pemphigus vulgaris-IgG causes a rapid depletion of desmoglein 3 (Dsg3) from the Triton X-100 soluble pools, leading to the formation of Dsg3-depleted desmosomes in a human squamous carcinoma cell line, DJM-1 cells. *J Invest Dermatol* 1999;112:67-71.
39. Kitajima Y, Aoyama Y, Seishima M. Transmembrane signaling for adhesive regulation of desmosomes and hemidesmosomes, and for cell-cell detachment induced by pemphigus IgG in cultured keratinocytes: involvement of protein kinase C. *J Invest Dermatol Symp Proc* 1999;4:137-44.
40. Aoyama Y, Owada MK, Kitajima Y. A pathogenic autoantibody, pemphigus vulgaris-IgG, induces phosphorylation of desmoglein 3, and its dissociation from plakoglobin in cultured keratinocytes. *Eur J Immunol* 1999;29:2233-40.
41. Sato M, Aoyama Y, Kitajima Y. Assembly pathway of desmoglein 3 to desmosomes and its perturbation by pemphigus vulgaris-IgG in cultured keratinocytes, as revealed by time-lapsed labeling immunoelectron microscopy. *Lab Invest* 2000;80:1583-92.
42. Shu E, Yamamoto Y, Sato-Nagai M, Aoyama Y, Kitajima Y. Pemphigus vulgaris-IgG reduces the desmoglein 3/desmocolin 3 ratio on the cell surface in cultured keratinocytes as revealed by double-staining immunoelectron microscopy. *J Dermatol Sci* 2005;40:209-11.
43. Calkins CC, Setzer SV, Jennings JM, et al. Desmoglein endocytosis and desmosome disassembly are coordinated responses to pemphigus autoantibodies. *J Biol Chem* 2006;281:7623-34.
44. Caldelari R, de Bruin A, Baumann D, et al. A central role for the armadillo protein plakoglobin in the autoimmune disease pemphigus vulgaris. *J Cell Biol* 2001;153:823-34.
45. Berkowitz P, Hu P, Liu Z, et al. Desmosome signaling: inhibition of p38MAPK prevents pemphigus vulgaris IgG-induced cytoskeleton reorganization. *J Biol Chem* 2005;280:23778-84.
46. Puviani M, Marconi A, Cozzani E, Pincelli C. Fas ligand in pemphigus sera induces keratinocyte apoptosis through the activation of caspase-8. *J Invest Dermatol* 2003;120:164-7.
47. Melish ME, Glasgow LA. The staphylococcal scalded-skin syndrome: development of an experimental model. *N Engl J Med* 1970;282:1114-9.
48. Melish ME, Glasgow LA, Turner MD. The staphylococcal scalded-skin syndrome: isolation and partial characterization of the exfoliative toxin. *J Infect Dis* 1972;125:129-40.
49. Ladhani S. Recent developments in staphylococcal scalded skin syndrome. *Clin Microbiol Infect* 2001;7:301-7.
50. Cribrier B, Piemont Y, Grosshans E. Staphylococcal scalded skin syndrome in adults: a clinical review illustrated with a new case. *J Am Acad Dermatol* 1994;30:319-24.
51. Lee CY, Schmidt JJ, Johnson-Winegar AD, Spero L, Iandolo JJ. Sequence determination and comparison of the exfoliative toxin A and toxin B genes from *Staphylococcus aureus*. *J Bacteriol* 1987;169:3904-9.
52. O'Toole PW, Foster TJ. Nucleotide sequence of the epidermolytic toxin A gene of *Staphylococcus aureus*. *J Bacteriol* 1987;169:3910-5.
53. Dancer SJ, Garratt R, Saldanha J, Jhoti H, Evans R. The epidermolytic toxins are serine proteases. *FEBS Lett* 1990;268:129-32.
54. Vath GM, Earhart CA, Rago JV, et al. The structure of the superantigen exfoliative toxin A suggests a novel regulation as a serine protease. *Biochemistry* 1997;36:1559-66.
55. Cavarelli J, Prevost G, Bourguet W, et al. The structure of *Staphylococcus aureus* epidermolytic toxin A, an atypical serine protease, at 1.7 Å resolution. *Structure* 1997;5:813-24.
56. Amagai M, Yamaguchi T, Hanakawa Y, Nishifuji K, Sugai M, Stanley JR. Staphylococcal exfoliative toxin B specifically cleaves desmoglein 1. *J Invest Dermatol* 2002;118:845-50.
57. Hanakawa Y, Schechter N, Lin C, et al. Molecular mechanisms of blister formation in bullous impetigo and staphylococcal scalded skin syndrome. *J Clin Invest* 2002;110:53-60.
58. Hanakawa Y, Selwood T, Woo D, Lin C, Schechter NM, Stanley JR. Calcium-dependent conformation of desmoglein 1 is required for its cleavage by exfoliative toxin. *J Invest Dermatol* 2003;121:383-9.
59. Hanakawa Y, Schechter NM, Lin C, Nishifuji K, Amagai M, Stanley JR. Enzymatic and molecular characteristics of the efficiency and specificity of exfoliative toxin cleavage of desmoglein 1. *J Biol Chem* 2004;279:5268-77.
60. Ito Y, Funabashi Yoh M, Toda K, Shimazaki M, Nakamura T, Morita E. Staphylococcal scalded-skin syndrome in an adult due to methicillin-resistant *Staphylococcus aureus*. *J Infect Chemother* 2002;8:256-61.
61. Yamaguchi T, Yokota Y, Terajima J, et al. Clonal association of *Staphylococcus aureus* causing bullous impetigo and the emergence of new methicillin-resistant clonal groups in Kansai district in Japan. *J Infect Dis* 2002;185:1511-6.
62. Cheng SW, Kobayashi M, Kinoshita-Kuroda K, Tanikawa A, Amagai M, Nishikawa T. Monitoring disease activity in pemphigus with enzyme-linked immunosorbent assay using recombinant desmogleins 1 and 3. *Br J Dermatol* 2002;147:261-5.
63. Arin MJ, Engert A, Krieg T, Hunzelmann N. Anti-CD20 monoclonal antibody (rituximab) in the treatment of pemphigus. *Br J Dermatol* 2005;153:620-5.
64. Schmidt E, Herzog S, Brocker EB, Zillikens D, Goebeler M. Long-standing remission of recalcitrant juvenile pemphigus vulgaris after adjuvant therapy with rituximab. *Br J Dermatol* 2005;153:449-51.
65. Ahmed AR, Spigelman Z, Cavacini LA, Posner MR. Treatment of pemphigus vulgaris with rituximab and intravenous immune globulin. *N Engl J Med* 2006;355:1772-9.
66. Amagai M, Tsunoda K, Suzuki H, Nishifuji K, Koyasu S, Nishikawa T. Use of autoantigen-knockout mice in developing an active autoimmune disease model for pemphigus. *J Clin Invest* 2000;105:625-31.
67. Tsunoda K, Ota T, Suzuki H, et al. Pathogenic autoantibody production requires loss of tolerance against desmoglein 3 in both T and B cells in experimental pemphigus vulgaris. *Eur J Immunol* 2002;32:627-33.
68. Wucherpfennig KW, Yu B, Bhol K, et al. Structural basis for major histocompatibility complex (MHC)-linked susceptibility to autoimmunity: charged residues of a single MHC binding pocket confer selective presentation of self-peptides in pemphigus vulgaris. *Proc Natl Acad Sci U S A* 1995;92:11935-9.
69. Wucherpfennig KW, Strominger JL. Selective binding of self peptides to disease-associated major histocompatibility complex (MHC) molecules: a mechanism for MHC-linked susceptibility to human autoimmune diseases. *J Exp Med* 1995;181:1597-601.
70. Lin MS, Swartz SJ, Lopez A, et al. Development and characterization of desmoglein-3 specific T cells from patients with pemphigus vulgaris. *J Clin Invest* 1997;99:31-40.
71. Hertl M, Karr RW, Amagai M, Katz SI. Heterogeneous MHC II restriction pattern of autoreactive desmoglein 3 specific T cell responses in pemphigus vulgaris patients and normals. *J Invest Dermatol* 1998;110:388-92.
72. Hertl M, Amagai M, Sundaram H, Stanley J, Ishii K, Katz SI. Recognition of

- desmoglein 3 by autoreactive T cells in pemphigus vulgaris patients and normals. *J Invest Dermatol* 1998;110:62-6.
- 73.** Veldman CM, Gebhard KL, Uter W, et al. T cell recognition of desmoglein 3 peptides in patients with pemphigus vulgaris and healthy individuals. *J Immunol* 2004;172:3883-92.
- 74.** Veldman C, Höhne A, Dieckmann D, Schuler G, Hertl M. Type I regulatory T cells specific for desmoglein 3 are more frequently detected in healthy individuals than in patients with pemphigus vulgaris. *J Immunol* 2004;172:6468-75.
- 75.** Aoki-Ota M, Kinoshita M, Ota T, et al. Tolerance induction by the blockade of CD40/CD154 interaction in pemphigus vulgaris mouse model. *J Invest Dermatol* 2006;126:105-13.
- 76.** Sakaguchi S. Naturally arising Foxp3-expressing CD25+CD4+ regulatory T cells in immunological tolerance to self and non-self. *Nat Immunol* 2005;6:345-52.

Copyright © 2006 Massachusetts Medical Society.