

Percutaneous posterior cervical fusion with the DTRAX Facet System for single-level radiculopathy: results in 60 patients

Clinical article

BRUCE M. McCORMACK, M.D.,¹ RAFAEL C. BUNDOC, M.D.,² MARIO R. VER, M.D.,³ JOSE MANUEL F. IGNACIO, M.D.,⁴ SIGURD H. BERVEN, M.D.,⁵ AND EDWARD F. EYSTER, M.D.¹

¹Clinical Faculty, Department of Neurosurgery, and ⁵Department of Orthopaedic Surgery, University of California San Francisco Medical Center, San Francisco, California; ²Department of Orthopedics, University of the Philippines Manila; ⁴Department of Orthopedics, Manila Doctors Hospital, Manila; and ³Department of Orthopedics, St. Luke's Medical Center, Quezon City, Philippines

Object. The authors present 1-year results in 60 patients with cervical radiculopathy due to spondylosis and stenosis that was treated with a bilateral percutaneous facet implant. The implant consists of a screw and washer that distracts and immobilizes the cervical facet for root decompression and fusion. Clinical and radiological results are analyzed.

Methods. Between 2009 and 2011, 60 patients were treated with the DTRAX Facet System in a multicenter prospective single-arm study. All patients had symptomatic clinical radiculopathy, and conservative management had failed. The majority of patients had multilevel radiographically confirmed disease. Only patients with single-level radiculopathy confirmed by history, physical examination, and in some cases confirmatory nerve blocks were included. Patients were assessed preoperatively with Neck Disability Index, visual analog scale, quality of life questionnaire (Short Form-12 version 2), CT scans, MRI, and dynamic radiographs. Surgery was percutaneous posterior bilateral facet implants consisting of a screw and expandable washer and iliac crest bone aspirate. Patients underwent postoperative assessments at 2 weeks, 6 weeks, 3 months, 6 months, and 1 year with validated outcome questionnaires. Alterations of segmental and overall cervical lordosis, foraminal dimensions, device retention and fusion criteria were assessed for up to 1 year with CT reconstructions and radiographs. Fusion criteria were defined as bridging trabecular bone between the facets, translational motion < 2 mm, and angular motion < 5°.

Results. All patients were followed to 1 year postoperatively. Ages in this cohort ranged from 40 to 75 years, with a mean of 53 years. Forty-two patients were treated at C5–6, 8 at C6–7, 7 at C4–5, and 3 at C3–4. Fifty-six had bilateral implants; 4 had unilateral implants due to intraoperative facet fracture (2 patients) and inability to access the facet (2 patients). The Neck Disability Index, Short Form-12 version 2, and visual analog scale scores were significantly improved at 2 weeks and remained significantly improved up to 1 year. At the treated level, 93% had intrafacet bridging trabecular bone on CT scans, translational motion was < 2 mm in 100% and angular movement was < 5° in 83% at the 1-year follow-up. There was no significant change in overall cervical lordosis. There was a 1.6° loss of segmental lordosis at the treated level at 1 year that was significant. Foraminal width, volume, and posterior disc height was significantly increased at 6 months and returned to baseline levels at 1 year. There was no significant decrease in foraminal width and height at adjacent levels. There were no reoperations or surgery- or device-related complications, including implant failure or retained hardware.

Conclusions. Results indicate that the DTRAX Facet System is safe and effective for treatment of cervical radiculopathy.

(<http://thejns.org/doi/abs/10.3171/2012.12.SPINE12477>)

KEY WORDS • minimally invasive surgery • DTRAX Facet System •
cervical spondylosis • cervical radiculopathy • posterior cervical fusion

ANTERIOR cervical discectomy and fusion is an effective and reliable treatment for cervical radiculopathy caused by degenerative disc disease and/

or spondylosis.^{8,14,23,24} Total disc replacement has been advocated to reduce the incidence of adjacent-segment disease, but with more than 10 years of follow-up has proven to have more limited clinical indications than originally considered.^{1,24} Both procedures remove disc

Abbreviations used in this paper: ACDF = anterior cervical discectomy and fusion; AP = anteroposterior; NDI = Neck Disability Index; SF-12v2 = Short Form-12 version 2; TDR = total disc replacement; VA = vertebral artery; VAS = visual analog scale.

This article contains some figures that are displayed in color online but in black-and-white in the print edition.

and bone to decompress the nerve root, followed by anterior spinal column reconstruction. The ACDF and TDR procedures are safe, but reported complications include implant failure and dislodgement, excessive or incomplete bone healing, spinal deformity, neurological complications, dysphagia, esophageal injury, and recurrent laryngeal nerve palsy.^{8,10,21,23}

Others argue that ACDF and TDR are too much surgery, and advocate posterior foraminotomy for root decompression when feasible.²² Adoption of foraminotomy is suppressed because the procedure can be technically difficult when performed through minimal access incisions.²² Axial neck pain and (less commonly) instability may ensue because the motion segment is not stabilized.^{2,7} Foraminotomy, particularly at C4–5, has been associated with motor palsies of the C-5 root.⁴

The DTRAX implant is a titanium screw and expandable washer designed to act as a shim placed percutaneously through minimal access incisions into the cervical facets. A shim takes advantage of the inclination of the cervical facet in the transverse plane to open the neural foramina. The facet is stabilized with instrumented distraction. A rasp and decorticator are used to promote definitive bone healing. The concept of percutaneously inserting a shim to adjust the space between 2 vertebrae is appealing because tissue is not removed from the patient and the procedure is less invasive than other surgical alternatives.

Our hypothesis was that indirect root decompression with an expandable shim (DTRAX) would provide clinical relief of radiculopathy in patients with spondylosis with straight or lordotic cervical spines who do not have symptomatic central canal stenosis necessitating an anterior approach.

We describe a prospective multicenter single-arm study to assess clinical and radiographic outcomes in patients with cervical radiculopathy treated with DTRAX at a single level over a period of 1 year. Secondary objectives were to document safety and describe appropriate patient selection criteria.

Methods

Patient Population

Prospective clinical and radiographic data on 60 patients with 1-year follow-up were compiled by an independent clinical research organization (Parexel International) and radiographic core lab (Perceptive Informatics). Procedures were performed between 2009 and 2011 in a multicenter trial in the Philippines. Institutional review board approval and informed consent were obtained prior to patient enrollment.

Data obtained in these patients comprised the initial human safety and efficacy information for the European CE application and US regulatory submissions. The investigators did not enroll a control arm for this initial pilot study. Safety and efficacy analysis of the data were completed using multiple peer-reviewed randomized controlled studies evaluating ACDF versus TDR.^{12,17,18} The consistent safety and efficacy data from those studies in a similar patient population to that in this pilot study provided a basis for initial analysis. The lack of a control arm is a limitation,

but was not included in the initial scope of the pilot study. A pivotal controlled study is planned for further evaluation of DTRAX against anterior fusion (ACDF).

All patients had a physical examination to evaluate single-level cervical radiculopathy. Objective findings were loss of reflex, motor weakness, and sensory deficit. Major motor deficit (2/5 strength) was a contraindication. Clinical evidence of radiculopathy had to correlate with foraminal stenosis identified on MRI studies, CT scans, and oblique cervical radiographs. Selective nerve root blocks and electromyograms were used to verify the findings in cases where the diagnosis was unclear. All patients had positive findings of foraminal stenosis at the symptomatic level on MRI, CT, and radiographs. Patients with severe multilevel foraminal stenosis in whom a single symptomatic nerve root could not be identified were not enrolled. Only patients with objective clinical symptoms from a single spinal level with compelling radiographically confirmed stenosis at the symptomatic level were offered surgery.

Inclusion criteria were radiographic evidence of cervical spondylosis in C3–7 with degenerated disc on MRI; loss of disc height on plain radiographs, CT scans, or MRI studies; and/or disc herniation on CT or MRI. Patients had radicular pain symptoms with either arm and shoulder pain, decreased reflexes, or strength and/or sensation. Sixty patients were enrolled; all were between 40 and 75 years old. Other inclusion criteria were positive Spurling sign, preoperative NDI score ≥ 30 , preoperative neck and arm pain score (VAS) ≥ 6 , symptoms refractory to at least 6 weeks of conservative management, and/or progression of neurological deficits with nonoperative management.

Exclusion criteria were cervical myelopathy, osteoporosis or osteopenia with a bone mineral density T score -2.5 or below, segmental instability with spondylolisthesis ≥ 3.5 mm, pregnancy, rheumatoid arthritis or other inflammatory or connective tissue disorder, prior fracture or fusion at the involved level, metabolic or systemic disease, metal allergies, chronic infection, and involvement in workers' compensation and/or litigation. Additional contraindications included cervical kyphosis and scoliosis.

Surgeries were performed by Drs. Bundoc, Ver, and Ignacio at Philippines General Hospital, St. Luke's Medical Center, and Manila Doctors Hospital, respectively. Surgeons had fellowship training in the US and Europe, and had done 2 cadaveric training sessions prior to the first surgery. All surgeons completed Good Clinical Practice certification led by Parexel International. More than 50% of the cases were performed in a cardiac catheterization lab at Manila Doctors Hospital.

Bias to outcome was avoided because patients' responses to standardized questionnaires were used as the primary outcome measure. Enrolled patients had pretreatment assessment, and then follow-up immediately after surgery and at 2 weeks, 6 weeks, and 3, 6, and 12 months after surgery. At each follow-up visit, patients were interviewed to determine if adverse events were experienced and to complete questionnaires. Neurological assessments were performed preoperatively and at all follow-up visits.

Clinical outcome data were determined using the

Posterior cervical fusion with the DTRAX Facet System

NDI, SF-12v2 Health Survey, and the VAS. Safety information included collecting the type, frequency, seriousness, and relatedness of adverse events and serious adverse events over 1 year.

Radiographic metrics were performed at an independent core lab (Perceptive Informatics) by using a 2-reader system, with disagreements adjudicated by a third reader. Radiographers were blinded to the hypothesis of the investigators.

All patients had preoperative AP/lateral/flexion/extension radiography, CT with reconstruction, and MRI. The radiographs were obtained the day after surgery (at discharge), and at 6 weeks, 3 months, 6 months, and 1 year. The CT scan with reconstruction was repeated at 6 months and 1 year.

The Cobb technique was used to measure overall (C2–T1) and segmental lordosis at the treated level on CT scans obtained at 6 and 12 months. These measurements were compared to preoperative CT values.

The neural foramina were measured on sagittal CT scans at the narrowest dimension of the treated level at 6 and 12 months and compared with the preoperative measurement by using Alice software (Perceptive Informatics). An orthogonal tool was used to measure foraminal height and width. Volume was measured by outlining the contours of the foramina and multiplying the area by the slice thickness. Only soft-tissue space was measured.

An additional retrospective review of adjacent neural foramina width and height on sagittal CT scans was performed. Measurements were made at the narrowest dimension of the neural foramina at adjacent levels from C-3 to C-7 preoperatively, at 6 months, and at 1 year. Anterior, middle, and posterior disc height measurements at the treated level were taken from CT scans and compared with preoperative CT values.

Fusion was assessed on radiographs and CT scans. Fusion criteria included the following: 1) evidence of bridging trabecular bone through the facets; 2) translational motion < 2 mm; and 3) angular range of motion < 5°. Any amount of device migration on CT scans and plain radiographs was recorded. All patients were instructed to wear a Miami J collar for 6 weeks. The t-test was used to determine statistical significance.

The DTRAX Facet System

Figure 1 depicts all components of the DTRAX Facet System.

The DTRAX implant consists of 2 titanium components: 1) a 13-mm titanium screw with tapered threaded shaft; and 2) an expandable washer consisting of 2 titanium base plates connected at the distal tip by an interlocking weld. The base plates have slots for exiting screw threads and posteriorly directed teeth on the lateral margins of the outer base plates. Both components are held preassembled by a delivery tool with the screw partially engaging the threads of the expandable washer. As the screw is advanced into the collapsed washer the base plates separate, causing the posteriorly directed teeth to grip subchondral bone (Figs. 2 and 3). Additional bone purchase occurs as the screw threads exit slots in the washer and engage bone. There is a half slot at the distal



Fig. 1. Photograph showing components of the DTRAX Facet System, which include a tongue chisel, chisel rasp, guide tube, tuning fork, implant delivery tool, decortication device, and bone graft delivery tool.

end of the washer and corresponding interruption in the distal screw thread to prevent screw backout (Fig. 4). The screw–base plate contact is dependent on counter pressure from 2 opposed surfaces (1–2 mm) such as the cervical facet joint. Advancing the screw within the expandable washer without counter pressure causes the washer to splay off the screw shaft.

Surgical Technique

After routine intubation, the patient was placed prone with his/her head in a neutral position on a foam donut. The patient's shoulders were pulled down with tape if necessary for radiographic visualization of the lower cervical spine. The posterior neck and upper thoracic spine and iliac crest were prepared. Iliac crest bone graft was obtained and mixed with demineralized bone matrix in most cases to create a more pastelike consistency to aid in percutaneous delivery.

Fluoroscopy was brought into the field in sterile fashion. A single fluoroscopy machine was used for AP and lateral views. Alternatively, 2 machines can be positioned for simultaneous AP and lateral imaging. On the lateral view, the facet closer to the cathode will appear larger than the contralateral facet. The patient's neck may be repositioned or the fluoroscopes may be adjusted by a technician to identify standard AP and lateral spinal radiographic landmarks.

A Steinman pin was placed externally and lateral to



Fig. 2. Photograph of the facet screw and washer. Teeth are a retention feature to resist screw pullout.

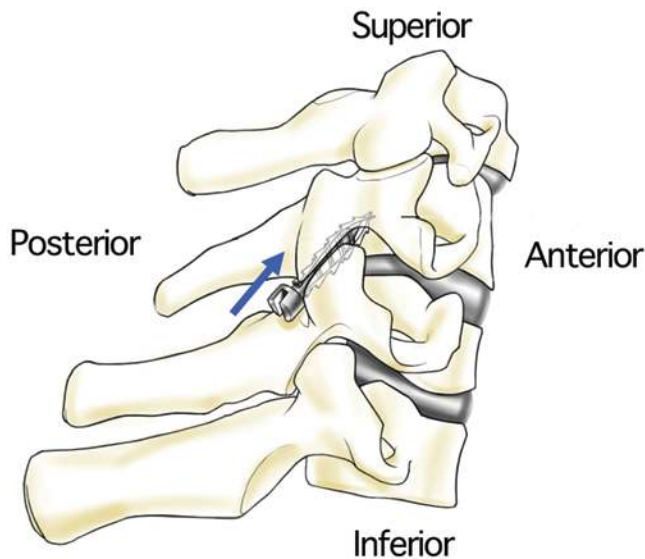


FIG. 3. Schematic showing the DTRAX device implanted in the cervical facet. Teeth engage subchondral bone.

the patient's neck and lined up with the intended facet by using lateral fluoroscopy to establish a cranial-caudal incision site. A 0.5-in incision was made, typically 2–3 spinal segments below the treated level, but varied depending on facet orientation. The incision was one and a half fingerbreadths off midline on both sides, to permit a slight medial-to-lateral trajectory up to the facet. The skin was marked and infiltrated with local anesthesia.

If the patient had unilateral radiculopathy, the symptomatic side was treated first. The incision was advanced through the fascia to avoid instrument snagging during exchanges. A forceps/hemostat was used to spread the fascia and muscle.

The tongue chisel was advanced to the spinolaminar line on the lateral fluoroscopic view. From this point, the tongue chisel was advanced to the lateral mass at the appropriate spinal level under the AP view to prevent penetration of the spinal canal.

The posterior facet capsule at the treated spinal level was scored with the tip of the chisel. Hand pressure was used to advance the chisel into the facet until it abutted the pedicle of the rostral vertebra, which is a firm end point (Fig. 5). The tongue chisel was 5.9 mm wide, so that it could not be inadvertently plunged past the pedicle to injure the nerve root or VA. This procedure was repeated on the other side.

A “rat tooth” decorticator (Fig. 6) was then advanced over the tongue chisel to the posterior aspect of the facet joint, and the superior and inferior lateral masses were decorticated. Rotational movements greater than 15° of the decorticator were discouraged to prevent lateral dislodgement of the tongue chisel from the facet. Small taps on the decorticator scored the adjacent lateral mass. The decorticator was then removed.

A guide tube was inserted over the tongue chisel and advanced into the facet. The guide tube has radiological features to ensure intrafacet implant positioning, including a radiolucent eye and raised bumps that should approximate the posterior facet margin on lateral fluoros-




FIG. 4. Top view of washer showing the half slot. This half slot engages a break in the screw thread to prevent screw backout.

copy with full implantation. A rasp was passed through the guide tube to decorticate the cartilaginous endplates.

The implant holder was inserted into the guide tube until the handles of the 2 instruments locked. To confirm proper implant placement, the anterior weld of the titanium base plate should abut the pedicle of the superior vertebral body (Fig. 7 left) and the radiographic marks on the guide tube should abut the posterior facet margin on lateral fluoroscopy (Fig. 7 right). Care was taken to maintain downward pressure on the guide tube to prevent guide tube backout during instrument exchange. If the guide tube was inadvertently retracted during instrument exchanges, it was readvanced with hand pressure or several light taps from a small mallet provided in the system (tuning fork).

The round handle of the implant delivery tool was rotated to advance the screw within the expandable washer. The surgeon felt resistance as the device engaged bone. Distraction of the facet was visualized on lateral fluoroscopy. Any splaying of the implant indicated that it was not entirely intrafacet and needed to be positioned more anteriorly. A facet fracture could also cause implant splaying. Splayed implants were removed in 2 cases. The screw was loosened from the base plate by using the tongue chisel. A needle driver was advanced to clasp and remove the washer, and a new implant was then inserted.

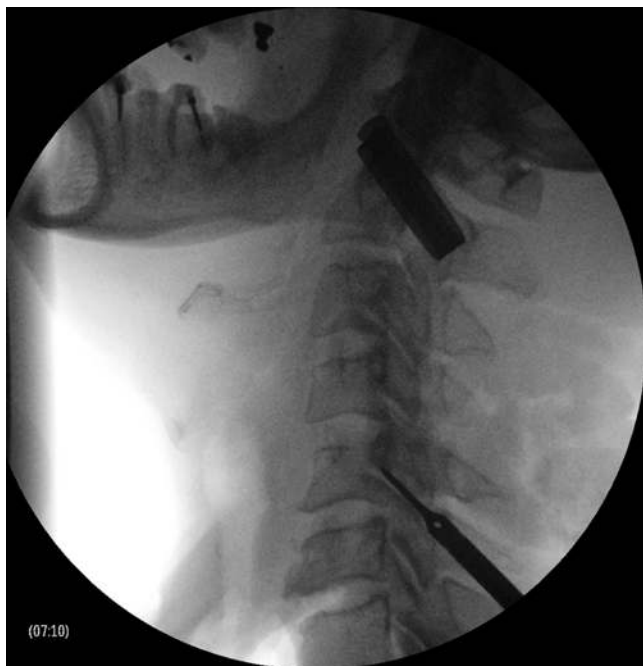

Fig. 5. Intraoperative radiograph showing chisel abutting the pedicle of the rostral vertebra.

After implant placement the DTRAX delivery tool was removed and 6–8 ml of bone allograft and iliac crest aspirate was inserted through the guide tubes into and over the facet. The procedure was repeated on the contralateral facet joint. Incisions were closed. The patient was put in a collar and extubated. Patients were discharged the following day per protocol.

Results

Demographic data are outlined in Table 1. There were no significant perioperative complications such as VA injuries, nerve root injuries, spinal cord injuries, or reoperations.

Of the first 10 patients there were unilateral facet fractures in 2; DTRAX was implanted on the symptomatic side. Both patients went on to attain radiographic fusion and did well clinically. Two other patients had hypertro-



Fig. 6. Photograph with a view of the teeth of the decorticator tool.

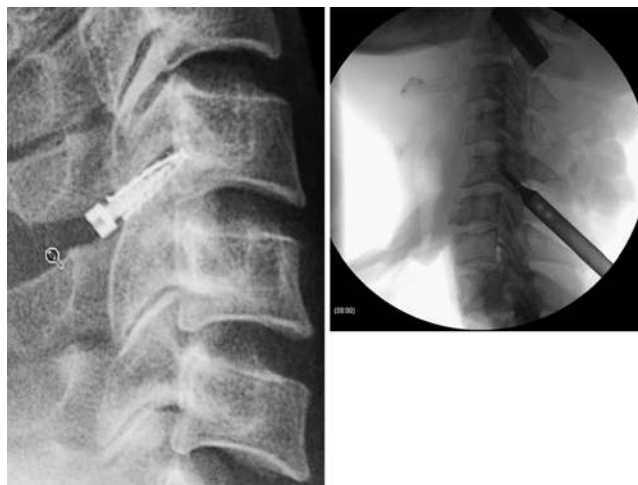

Fig. 7. Left: Intraoperative lateral fluoroscopy view of the DTRAX implant abutting the pedicle of the superior vertebral body. Right: Intraoperative lateral fluoroscopy view. Radiolucent hole on the guide tube abuts the posterior facet margin, indicating that the implant will be entirely intrafacet.

phic, partially ankylosed facets identified by preoperative CT but these were not considered to be a contraindication for the procedure. These patients also had unilateral DTRAX placement. The CT scans obtained in these 4 patients did not show coronal imbalance. With additional surgical experience, techniques were developed to access these arthritic facets safely.

The original facet access device had a leading edge 2.5 mm in height. After the 2 fractures, the tongue chisel tool was designed. The tongue chisel has a flat leading edge 1 mm in height so that it can be advanced into the facet with hand pressure only. After the implementation of the tongue chisel, there were no further fractures.

One patient was treated with DTRAX at C4–5 for radicular pain and weakness without numbness. Initial results appeared successful, but the patient developed progressive arm weakness in multiple myotomes over 1 year. Amyotrophic lateral sclerosis was diagnosed based on electrical studies performed 1 year after surgery. In retrospect, weakness was disproportionate to the foraminal stenosis visualized on preoperative imaging studies.

Another patient had a thoracolumbar fracture treated

TABLE 1: Demographic data in 60 patients with single-level cervical spondylotic radiculopathy

Parameter	Value
sex	
M	23
F	37
mean age	52.8 yrs
level treated	
C3–4	3
C4–5	7
C5–6	42
C6–7	8

with posterior fusion and hardware prior to enrollment. After DTRAX surgery, the patient developed a postoperative thoracolumbar infection. Treatment was additional surgery and intravenous antibiotics. Infection was not related to the DTRAX device and did not result in a cervical infection.

The mean NDI, SF-12v2, and VAS scores were significantly improved compared with baseline at 2 weeks and at all assessments up to 1 year (Figs. 8 and 9).

Radiographic results are summarized in Table 2. At 6 months there was a significant decrease in overall cervical lordosis of 1.7° ($p < 0.05$) but no significant changes at 1 year compared with baseline ($p > 0.05$). Segmental lordosis at the treated level decreased by 1.4° and 1.6° at 6 months and 1 year compared with baseline ($p < 0.05$). Anterior disc height decreased at 6 months and 1 year compared with baseline, but was only significantly changed at 1 year ($p < 0.05$). There were no significant changes in middle disc height. Posterior disc height was

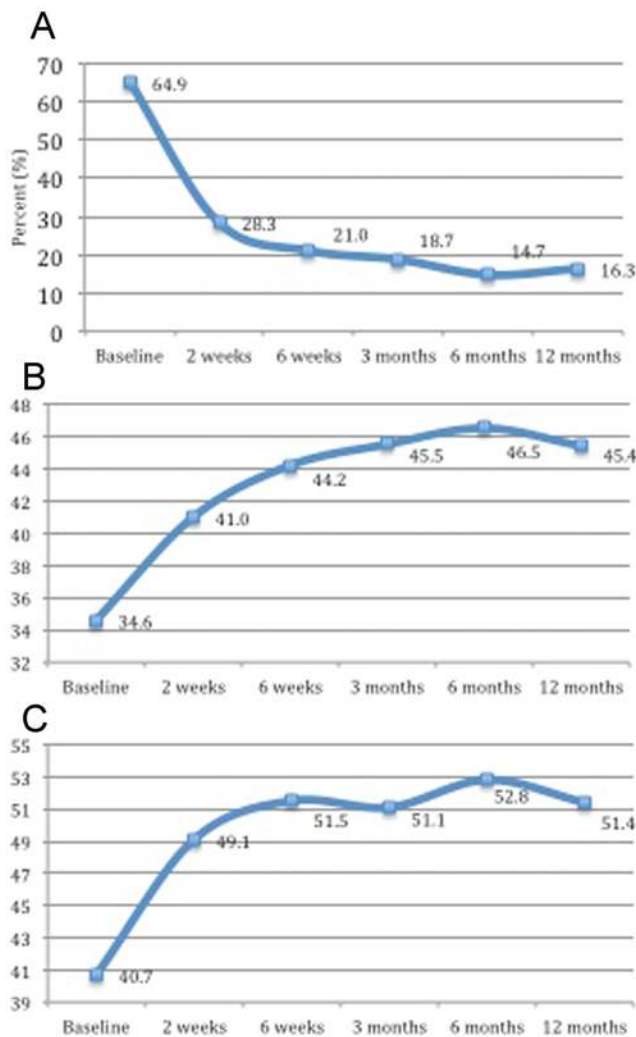


FIG. 8. A: Line graph showing NDI scores from baseline to 12 months. B: Line graph showing SF-12v2 physical component summary scores (y axis) from baseline to 12 months. C: Line graph showing SF-12v2 mental component summary scores (y axis) from baseline to 12 months.

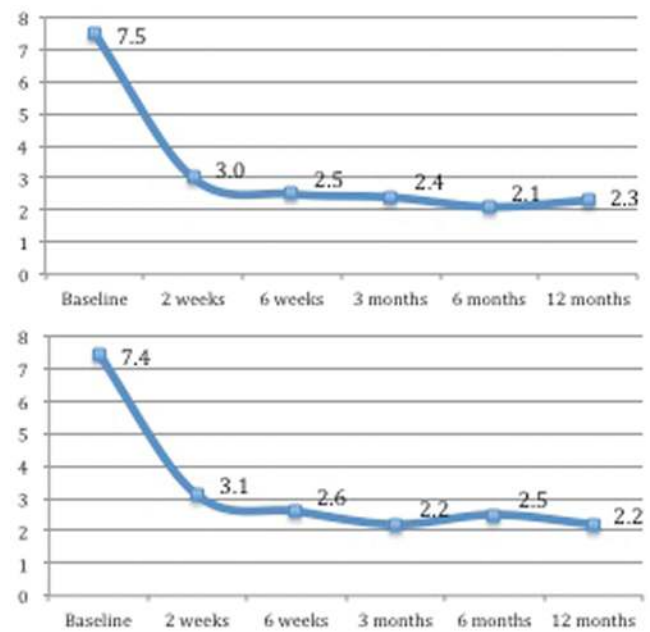


FIG. 9. Upper: Line graph showing VAS neck scores (y axis) from baseline to 12 months. Lower: Line graph showing VAS arm scores (y axis) from baseline to 12 months.

significantly increased at 6 months ($p < 0.05$) but returned to baseline at 1 year.

Foraminal width and volume were significantly increased at 6 months. Width returned to baseline and volume remained slightly elevated (just above baseline) at 1 year. Fifty-six patients (93%) had bridging trabecular bone in the treated facet on CT scans at 1 year. All patients had translational motion less than 2 mm at the treated level and in 47 patients (78%) translational motion was less than 1 mm at 1 year. Fifty (83%) of 60 patients had angulation less than 5°.

Of the 14 patients who did not meet all 3 radiographic specifications for fusion, 4 did not score well on validated outcome questionnaires. Two scored poorly on 2 of the 3 validated questionnaires, and 2 on 1 questionnaire.

There was no significant decrease in foraminal height and width at adjacent levels when comparing preoperative measurements to values at 6 months and 1 year. Measurements are depicted in Table 3.

There was no screw or base plate migration out of the facet. There was 1 partial screw backout (a quarter turn) from the base plate, but both base plate and screw remained intrafacet at 6 months. There was no further backout and the facet had bridging trabecular bone at 12 months. There was no halo or loosening of the base plate from the facet surface in any patient. There was no device breakage.

Discussion

The DTRAX implant is intended to treat patients with cervical radiculopathy without kyphosis and without symptomatic central canal stenosis. This population has historically been treated with anterior fusion and, less commonly, posterior foraminotomy. The common surgical dictum has been complete decompression of disc and

Posterior cervical fusion with the DTRAX Facet System

TABLE 2: Summary of radiographic data in 60 patients with single-level cervical spondylotic radiculopathy*

Measurement	Baseline	6 Mos	12 Mos	Net Change from Baseline at 12 Mos
overall cervical spine lordosis (°)	9.2 ± 6.9	7.5 ± 5.8†	8.9 ± 6.8	-0.4
Cobb angle at treated level (°)	6.5 ± 4.9	7.9 ± 4.8†	8.1 ± 5.1‡	+1.6‡
anterior disc height (mm)	3.2 ± 1.2	2.9 ± 1.0	2.7 ± 1.1‡	-0.5‡
middle disc height (mm)	4.2 ± 1.1	4.1 ± 1.0	4.0 ± 1.1	-0.3
posterior disc height (mm)	2.6 ± 0.9	3.0 ± 1.2‡	2.6 ± 0.9	0.0
foraminal height (mm)	11.0 ± 2.0	11.2 ± 1.8	11.1 ± 1.9	+0.1
foraminal width (mm)	6.4 ± 1.7	6.8 ± 1.9‡	6.4 ± 1.7	0.0
foraminal vol (ml)	56.7 ± 16.7	60.9 ± 17.4‡	58.6 ± 18.9	+2.0
evidence of bridging trabecular bone (%)		85.0	93.3	
translational motion <2 mm (%)		98.3	100.0	
angulation <5° (%)		73.3	83.3	

* Unless otherwise indicated, values are expressed as the mean ± SD throughout.

† p < 0.05.

‡ p < 0.01.

osteophyte via an anterior approach for patients with cervical radicular symptoms that fail to respond to conservative care.⁶ Complete decompression has been emphasized even more with prosthetic discs due to the potential for dynamic compression if there is residual disc or spur. The investigators recognize good results with anterior spinal reconstruction, but believe it may be more surgery than is necessary. Experience with closed traction suggests that lesser measures may suffice. Closed cervical traction is a known, accepted, and successful treatment for patients suffering from cervical radicular symptoms.^{5,15} Cervical traction is commonly performed by chiropractors and physical therapists, and home traction devices are popular, safe, and effective.¹² Recumbency can alleviate radicular symptoms by removing the weight of the head from the cervical spinal column.¹⁵

The DTRAX Facet System was conceived to provide surgical distraction to the symptomatic cervical spinal level by using a minimally invasive approach. It is an alternative to anterior fusion that is less invasive and could be performed earlier in the continuum of care. The concept of a shim to adjust the space between 2 vertebrae to alleviate root compression is appealing because tissue is not removed and it does not preclude further open surgical procedures. A shim placed into the facet opens the neural foramina due to the transverse orientation of the cervical facets. Cervical facet anatomy has been described by Pal et al.¹⁹ and Panjabi et al.²⁰ in their work they described the relationship of the superior articular facet to the sagittal and transverse plane. Pal et al. reported that the angle of the superior articular facet in the transverse plane varied from 46° at C-3 to 65° at C-7 in 30 adult male human vertebral columns. The less the angle from the transverse plane, the more facet distraction opens the neural foramina.

The DTRAX system is inserted intrafacet through the posterior facet capsule. This trajectory is technically easier than transfacet screw fixation, which can be difficult due to the patient's head position. A drill is also

required for transfacet fixation and there is risk of injury to nerve root, spinal cord, and VA, which are in proximity.¹³ Bone volume is small, so that only 1 attempt at transfacet screw placement is possible without irretrievably degrading bone integrity and compromising fixation. The DTRAX tongue chisel is inserted through the posterior facet and abuts the pedicle, which prevents plunging. Once the facet is accessed, instrument exchanges are straightforward, with a minimum of fluoroscopy, and a bone drill is not required.

In 2011, Goel and Shah⁹ validated the concept that facet distraction can lead to symptomatic relief of cord and root compression. These authors reported on 36 patients with cervical spondylotic disease enrolled over 4 years and treated with facet distraction by using metallic spacers. In this cohort, 18 patients had single-level and 18 had multilevel disease. Surgery was a standard open approach with interspinous process ligament resection, iliac crest grafting over the lamina and lateral mass, and facet decortications followed by impaction of spacers into the facet. The follow-up ranged from 6 to 37 months, with a mean follow-up duration of 17 months. Patients wore a 4-column hard collar for 3 months. All patients had varying degrees of relief from pain, radiculopathy, and myelopathy. Spacers resulted in an increase in the foraminal and canal dimensions.

Our present study of 60 patients with cervical radiculopathy treated with DTRAX provides further clinical evidence that facet distraction alleviates symptomatic root compression. The DTRAX and the Goel cervical spacer are both intrafacet implants. The DTRAX implant is inserted using a percutaneous approach, whereas Dr. Goel described an open surgery.⁹ DTRAX is inserted into the facet in a collapsed configuration and expands through screw advancement to provide incremental distraction. Goel's spacer is impacted into the facet by using an osteotome on the lateral edge of the joint to wedge it open.

Goel treated patients with myelopathy and radiculopathy at multiple spinal levels. He noted that facet dis-

TABLE 3: Summary of adjacent-level data in 60 patients with single-level spondylotic radiculopathy who underwent treatment with the DTRAX Facet System*

Treated Level	Adjacent Level	Baseline		6 Mos		12 Mos	
		Height (mm)	Width (mm)	Height (mm)	Width (mm)	Height (mm)	Width (mm)
lt side							
C3-4	C4-5	12.6 ± 3.5	10.1 ± 4.2	15.5 ± 3.5	12.1 ± 3.8	17.1 ± 0.7	12.5 ± 0.9
	C5-6	14.1 ± 3.0	9.3 ± 0.1	16.7 ± 2.0	11.0 ± 0.5	17.7 ± 2.5	12.1 ± 2.5
	C6-7	12.4 ± 2.0	13.0 ± 2.2	14.4 ± 1.5	12.9 ± 0.6	17.1 ± 4.6	14.3 ± 2.2
C4-5	C3-4	10.9 ± 1.8	8.7 ± 2.7	11.6 ± 0.5	9.4 ± 2.5	12.9 ± 3.0	10.4 ± 2.0
	C5-6	10.2 ± 2.2	9.0 ± 1.9	11.7 ± 2.4	10.4 ± 1.0	13.2 ± 4.3	10.3 ± 3.4
	C6-7	11.3 ± 3.5	8.9 ± 4.8	11.0 ± 2.4	8.4 ± 4.6	12.4 ± 5.5	9.6 ± 3.8
C5-6	C3-4	11.2 ± 2.3	9.1 ± 2.2	12.4 ± 3.0	10.9 ± 3.4	12.1 ± 2.6	10.3 ± 2.5
	C4-5	13.2 ± 3.2	9.2 ± 2.4	14.3 ± 3.1	10.7 ± 2.4	14.1 ± 3.2	10.4 ± 3.3
	C6-7	11.9 ± 2.4	9.8 ± 3.7	13.2 ± 2.9	11.2 ± 4.2	12.6 ± 2.4	10.1 ± 3.6
C6-7	C3-4	12.2 ± 2.2	9.8 ± 2.6	12.2 ± 2.7	9.8 ± 1.8	13.5 ± 1.4	10.4 ± 3.1
	C4-5	13.0 ± 4.0	9.1 ± 2.7	13.0 ± 4.6	9.5 ± 2.6	14.4 ± 1.6	11.7 ± 6.6
	C5-6	12.0 ± 0.6	9.1 ± 1.7	12.7 ± 2.3	10.1 ± 1.7	13.3 ± 2.7	10.5 ± 0.9
rt side							
C3-4	C4-5	12.3 ± 0.5	9.4 ± 0.7	12.6 ± 2.8	10.6 ± 0.6	14.8 ± 1.0	10.6 ± 3.5
	C5-6	14.5 ± 1.2	10.1 ± 0.1	15.9 ± 0.3	11.3 ± 0.1	18.4 ± 2.2	13.9 ± 1.6
	C6-7	10.9 ± 3.8	12.1 ± 1.6	14.0 ± 1.2	15.0 ± 3.5	17.1 ± 3.2	13.9 ± 0.8
C4-5	C3-4	10.6 ± 1.3	9.5 ± 2.6	12.2 ± 2.7	9.4 ± 2.0	12.8 ± 3.5	10.4 ± 4.2
	C5-6	11.0 ± 2.6	9.4 ± 4.3	12.5 ± 2.4	10.3 ± 3.0	13.9 ± 4.2	10.2 ± 2.9
	C6-7	10.4 ± 2.2	9.7 ± 2.9	11.4 ± 2.7	8.8 ± 4.2	12.2 ± 4.2	10.8 ± 4.4
C5-6	C3-4	11.6 ± 2.1	9.5 ± 2.0	12.5 ± 2.5	10.2 ± 2.5	11.7 ± 2.1	9.8 ± 3.0
	C4-5	13.6 ± 2.3	9.6 ± 1.9	14.3 ± 1.9	10.3 ± 2.5	13.8 ± 2.7	10.4 ± 2.5
	C6-7	11.9 ± 2.3	9.0 ± 3.6	12.6 ± 2.3	9.7 ± 3.8	12.8 ± 3.8	9.5 ± 3.7
C6-7	C3-4	12.5 ± 4.5	9.1 ± 1.3	12.6 ± 2.6	8.9 ± 0.7	12.3 ± 0.9	8.5 ± 1.3
	C4-5	14.4 ± 4.8	10.7 ± 1.3	14.5 ± 2.4	11.1 ± 1.9	14.7 ± 2.9	11.3 ± 1.0
	C5-6	13.6 ± 5.1	10.4 ± 1.6	13.2 ± 3.7	10.9 ± 3.1	14.6 ± 4.3	10.6 ± 2.1

* Values are expressed as the mean ± SD; none of the values were significant at either $p < 0.05$ or $p < 0.01$.

traction expanded canal dimensions by reducing buckling of the posterior longitudinal ligament and ligamentum flavum. This led to improvement in myelopathic symptoms.¹¹ We agree that facet distraction could improve myelopathy, but we limited our enrollment to patients with radiculopathy at a single spinal level to focus our analysis on a uniform clinical diagnosis.

In our current series, 60 patients were prospectively followed in the course of 1 year. Patients clinically improved, as assessed by NDI, SF-12v2, and VAS scores at 2 weeks, 6 weeks, 3 months, 6 months, and 1 year. Benefit is consistent with reported results of ACDF and TDR.^{3,11,16-18} This study was intended as a pilot evaluation of safety and efficacy. Additional controlled studies would be necessary to make valid comparisons to ACDF and TDR. Results at 1 year are favorable but preliminary; final results will be reported at 2 years of follow-up.

We believe that spinal root compression was alleviated

as documented in the validated clinical outcome questionnaires; in particular there was improvement in VAS arm scores. However, radiographic confirmation of root decompression was equivocal. Foraminal volume at the treated level was significantly increased at 6 months. At 1 year these increases were less significant. Posterior disc height also increased at 6 months and then returned to baseline at 1 year. These radiographic findings indicate that DTRAX provides temporary root decompression that approaches baseline at 1 year. Once fusion occurs, mechanical distraction may be less important than fusion immobilization of the motion segment in resolving radiculopathy (Fig. 10). The majority of patients (93%) demonstrated fusion through the facets at 12 months. Fusion of the symptomatic level results in long-term and permanent relief. This is consistent with clinical experience that even severe foraminal stenosis is asymptomatic if the motion segment is fused.

Comparison of measurements of foraminal height,

Posterior cervical fusion with the DTRAX Facet System

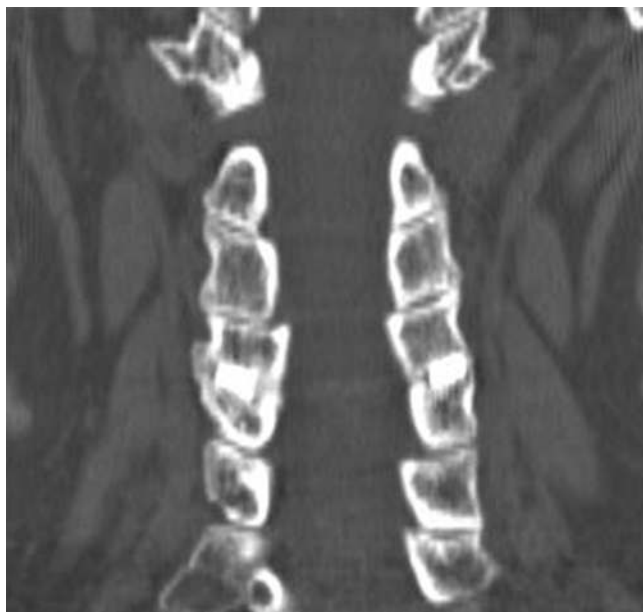

Fig. 10. Coronal CT scan of the DTRAX implant at C4–5 showing intrafacet bridging bone.

width, and volume across multiple time points with CT reconstructions was problematic. Independent radiologists at Perceptive Informatics attempted to obtain the same CT slice for valid measurement comparisons, but identical slice capture for all patients at all time points was not perfect. This unavoidable variability should be considered when interpreting the foramina changes. Other potential sources of error in reproducibly measuring the maximum site of foraminal narrowing were due to the small anatomical dimensions, oblique orientations, and irregular 3D funnel shape of the foramina. Current radiological techniques are limited when attempting to ascertain small increases in foramina dimensions that may unweight the nerve root. Goel and Shah⁹ noted foraminal expansion with the facet spacer but did not elaborate on methods for accessing foraminal dimensions.

The DTRAX implant did not result in any statistically significant changes in overall cervical lordosis, and loss of lordosis at the treated level was 1.6° at 1 year. Flexion deformity was small, but not nil. This small net loss of lordosis at the treated level was anticipated because distraction instrumentation posterior to the instantaneous axis of rotation will result in spinal flexion. The cervical facet joint is much closer to the instantaneous axis of rotation compared with an interspinous spacer. Hence, the applied moment arm from cervical facet distraction is less when compared with distraction applied in the interspinous space. A 15% loss of anterior disc height and a 5% loss of middle disc height were found at 1 year, and were anticipated due to posterior distraction instrumentation. Posterior disc height was unchanged at 1 year. Arthrodesis of the motion segment may also account for loss of disc height, but this is less likely because anterior, middle, and posterior disc height would be anticipated to decrease symmetrically.

Bone healing rates were 93% at 1 year on CT recon-

struction scans. However, dynamic films indicated residual angular movement in 17%. In the patients not meeting all 3 fusion criteria, 71% had good clinical results on the validated outcome questionnaires. Fusion is preferred for best results, but even when there was residual movement the majority of patients were clinically improved. This finding suggests that fusion is not critical for a good result when a shim is placed into the facet. However, it is our opinion that arthrodesis is desirable, and since the original study the decortication tools have been enhanced to further facilitate bone fusion. There was no instance of device migration, expulsion, or radiographic halo at the base plate.

There was no instance of spinal instability caused by facet distraction from DTRAX at the treated level. We believe this is because the implant was designed to exert tension on facet ligaments to stiffen the motion segment and not to overdistract the joint to overt ligament failure. The majority of patients in this series had cervical spondylosis with disc collapse. Concern that the implant could cause overt spinal instability in a patient with retained disc height is potentially valid and would require additional investigation.

The DTRAX implant was placed bilaterally whether the patient had unilateral or bilateral radicular symptoms. This was done because we had concerns that a unilateral implant might not heal, or might result in a contralateral radiculopathy due to the potential for narrowing of the foramina on the asymptomatic side. All 4 patients with unilateral implants did well and healed without deformity. A unilateral implant may suffice for patients with unilateral radicular symptoms, but further investigation will be needed to support this contention.

There were no changes in the adjacent neural foramina width and height from C-3 to C-7 measured at 1 year. Concern was raised that distraction of facet(s) at the treated level would result in compression of adjacent foramina or accelerated foraminal stenosis. These issues were not observed. There was no accelerated or atypical development of arthritic/degenerative cervical pathology identified at the 1-year follow-up.

One of the limitations of the study is that there was no control. However, we used validated outcome questionnaires, which can be compared with literature controls. Another limitation is that the follow-up is only 1 year. We used a clinical research organization to conduct the study and collect data to minimize potential investigator bias.

In this study we found that DTRAX provides a safe and successful treatment for select patients with radiculopathy at 1-year follow-up. Cervical facet distraction results in clinical relief of radiculopathy and satisfactory healing rates. We propose that this technique is safe and effective and may be a good alternative to conventional reconstructive surgery in select patients.

Conclusions

Our preliminary data at 1 year demonstrate that percutaneous distraction and fusion performed using the DTRAX Facet System is a safe and effective method of treating a subset of patients with cervical degenerative

disc disease and radiculopathy. Patients without kyphosis or symptomatic central canal stenosis were treated with success in this series. The procedure is reproducible at multiple sites and has a short learning curve. Patients healed without significant changes in overall cervical lordosis. This study does not address durability beyond 1 year, multilevel treatment, or use of DTRAX in conjunction with anterior stabilization. Additional studies will be needed to address these topics.

Disclosure

Providence Medical Technology, Inc. provided product, surgeon training, and financial resources to conduct the study. Two of the authors (Drs. Berven and McCormack) have a financial interest in the device (and Dr. Eyster has an ownership stake in the company), which can bias interpretation of results. The DTRAX Facet System has CE Marking, but is not yet commercially available in the US.

Author contributions to the study and manuscript preparation include the following. Drafting the article: McCormack. Critically revising the article: all authors. Reviewed submitted version of manuscript: all authors. Approved the final version of the manuscript on behalf of all authors: McCormack.

Acknowledgments

The authors thank Dr. Jerome A. Barakos, M.D., Director of Neuroimaging at California Pacific Medical Center, and Jennifer Ikeda for their help in preparing the manuscript.

References

- Bertagnoli R, Duggal N, Pickett GE, Wigfield CC, Gill SS, Karg A, et al: Cervical total disc replacement, part two: clinical results. *Orthop Clin North Am* **36**:355–362, 2005
- Chang JC, Park HK, Choi SK: Posterior cervical inclinatory foraminotomy for spondylotic radiculopathy preliminary. *J Korean Neurosurg Soc* **49**:308–313, 2011
- Cheng L, Nie L, Zhang L, Hou Y: Fusion versus Bryan Cervical Disc in two-level cervical disc disease: a prospective, randomised study. *Int Orthop* **33**:1347–1351, 2009
- Choi KC, Ahn Y, Kang BU, Ahn ST, Lee SH: Motor palsy after posterior cervical foraminotomy: anatomical consideration. *World Neurosurg* [epub ahead of print], 2011
- Constantoyannis C, Konstantinou D, Kourtopoulos H, Papadakis N: Intermittent cervical traction for cervical radiculopathy caused by large-volume herniated disks. *J Manipulative Physiol Ther* **25**:188–192, 2002
- Ellenberg MR, Honet JC, Treanor WJ: Cervical radiculopathy. *Arch Phys Med Rehabil* **75**:342–352, 1994
- Fehlings MG, Gray RJ: Editorial. Posterior cervical foraminotomy for the treatment of cervical radiculopathy. *J Neurosurg Spine* **10**:343–346, 2009
- Fountas KN, Kapsalaki EZ, Nikolakakos LG, Smisson HF, Johnston KW, Grigorian AA, et al: Anterior cervical discectomy and fusion associated complications. *Spine (Phila Pa 1976)* **32**:2310–2317, 2007
- Goel A, Shah A: Facetal distraction as treatment for single- and multilevel cervical spondylotic radiculopathy and myelopathy: a preliminary report. Technical note. *J Neurosurg Spine* **14**:689–696, 2011
- Heary RF, Benzel EC, Vaicys C: Single and multiple-single interbody fusion techniques, in Benzel EC (ed): *Spine Surgery: Techniques, Complication Avoidance, and Management*. Philadelphia: Elsevier, 2005, pp 351–362
- Heller JG, Sasso RC, Papadopoulos SM, Anderson PA, Fessler RG, Hacker RJ, et al: Comparison of BRYAN cervical disc arthroplasty with anterior cervical decompression and fusion: clinical and radiographic results of a randomized, controlled, clinical trial. *Spine (Phila Pa 1976)* **34**:101–107, 2009
- Laurin CA: Cervical traction in the home. *Can Med Assoc J* **94**:36–39, 1966
- McCullen GM, Garfin SR: Spine update: cervical spine internal fixation using screw and screw-plate constructs. *Spine (Phila Pa 1976)* **25**:643–652, 2000
- Mobbs RJ, Rao P, Chandran NK: Anterior cervical discectomy and fusion: analysis of surgical outcome with and without plating. *J Clin Neurosci* **14**:639–642, 2007
- Moeti P, Marchetti G: Clinical outcome from mechanical intermittent cervical traction for the treatment of cervical radiculopathy: a case series. *J Orthop Sports Phys Ther* **31**:207–213, 2001
- Mummaneni PV, Burkus JK, Haid RW, Traynelis VC, Zdeblick TA: Clinical and radiographic analysis of cervical disc arthroplasty compared with allograft fusion: a randomized controlled clinical trial. *J Neurosurg Spine* **6**:198–209, 2007
- Murrey D, Janssen M, Delamarter R, Goldstein J, Zigler J, Tay B, et al: Results of the prospective, randomized, controlled multicenter Food and Drug Administration investigational device exemption study of the ProDisc-C total disc replacement versus anterior discectomy and fusion for the treatment of 1-level symptomatic cervical disc disease. *Spine J* **9**:275–286, 2009
- Nabhan A, Ahlhelm F, Pitzen T, Steudel WI, Jung J, Shariat K, et al: Disc replacement using Pro-Disc C versus fusion: a prospective randomised and controlled radiographic and clinical study. *Eur Spine J* **16**:423–430, 2007
- Pal GP, Routal RV, Saggi SK: The orientation of the articular facets of the zygapophyseal joints at the cervical and upper thoracic region. *J Anat* **198**:431–441, 2001
- Panjabi MM, Oxland T, Takata K, Goel V, Duranceau J, Krag M: Articular facets of the human spine. Quantitative three-dimensional anatomy. *Spine (Phila Pa 1976)* **18**:1298–1310, 1993
- Riley LH III, Vaccaro AR, Dettori JR, Hashimoto R: Post-operative dysphagia in anterior cervical spine surgery. *Spine (Phila Pa 1976)* **35** (9 Suppl):S76–S85, 2010
- Ruetten S, Komp M, Merk H, Godolias G: Full-endoscopic cervical posterior foraminotomy for the operation of lateral disc herniations using 5.9-mm endoscopes: a prospective, randomized, controlled study. *Spine (Phila Pa 1976)* **33**:940–948, 2008
- Wenger M, Markwalder TM: Bryan total disc arthroplasty: a replacement disc for cervical disc disease. *Med Devices (Auckl)* **3**:11–24, 2010
- Zechmeister I, Winkler R, Mad P: Artificial total disc replacement versus fusion for the cervical spine: a systematic review. *Eur Spine J* **20**:177–184, 2011

Manuscript submitted May 14, 2012.

Accepted December 3, 2012.

Please include this information when citing this paper: published online January 18, 2013; DOI: 10.3171/2012.12.SPINE12477.

Address correspondence to: Bruce M. McCormack, M.D., 2320 Sutter Street, Suite 202, San Francisco, California 94115. email: bruce@neurospine.org.