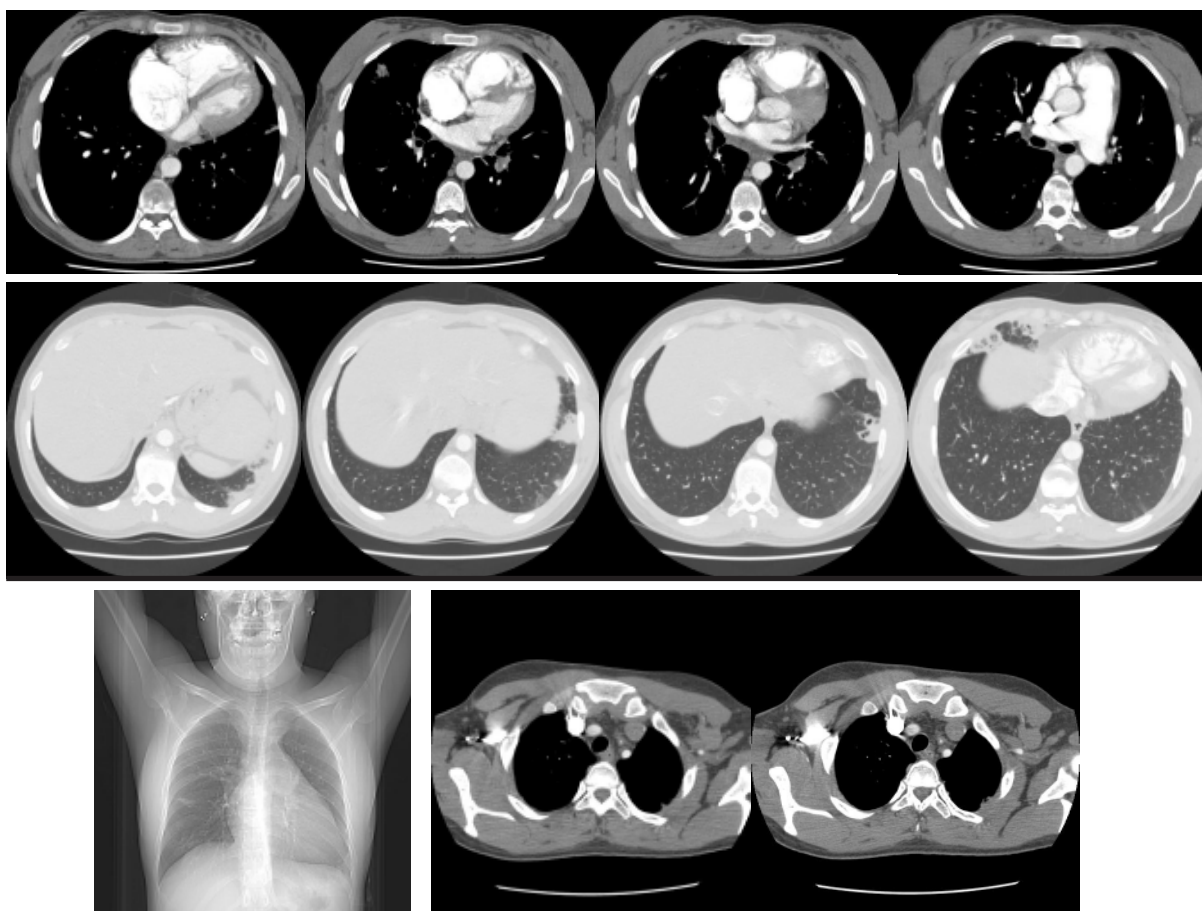


Diagnóstico Radiológico

We ask: What is the diagnosis?

DANY JASINOWODOLINSKI¹, GUSTAVO DE SOUZA PORTES MEIRELLES²,
JAQUELINE OTA³, NESTOR L MÜLLER⁴

42-year-old female patient, complaining of fatigue for a considerable length of time, accompanied by sporadic muscle and joint pain. Reports recent episodes of hemoptysis and chest pain accompanied by progressive dyspnea. Taking only hypertension medication and denies smoking or having a history of any relevant events hipertensão e nega tabagismo ou outros antecedentes relevantes.



The objective of this section is stimulate an approach for the diagnosis based on clinical information and radiology. We invited all of the readers to participate. To answer it follows the instructions, click on the title of the question, and in the next screen it fills out the form with your diagnosis. Don't forget to identify the full name and institution the one that is linked. We published the names of who gets right the diagnosis. The shown images are the most important for the diagnosis. The diagnosis of that case will be published in the next number of the Journal.

1. Attending Radiologist at the Fleury Center for Diagnostic Medicine, São Paulo, São Paulo, Brazil
2. PhD in Radiology at the Universidade Federal de São Paulo (UNIFESP, Federal University of São Paulo), São Paulo, São Paulo, Brazil
3. Attending Physician in the Pulmonology Department of the Universidade Federal de São Paulo (UNIFESP, Federal University of São Paulo), São Paulo, São Paulo, Brazil
4. Full Professor of Radiology at the University of British Columbia, Vancouver, British Columbia, Canada