



LUND UNIVERSITY

Peripheral arterial disease.

Cronberg, Carin; Sjöberg, S; Albrechtsson, Ulf; Leander, Peter; Lindh, Mats; Norgren, Lars; Danielsson, Peter; Sonesson, Björn; Larsson, Elna-Marie

Published in:
Acta Radiologica

DOI:
[10.1034/j.1600-0455.2003.00007.x](https://doi.org/10.1034/j.1600-0455.2003.00007.x)

2003

[Link to publication](#)

Citation for published version (APA):

Cronberg, C., Sjöberg, S., Albrechtsson, U., Leander, P., Lindh, M., Norgren, L., Danielsson, P., Sonesson, B., & Larsson, E-M. (2003). Peripheral arterial disease. *Acta Radiologica*, 44(1), 59-66. <https://doi.org/10.1034/j.1600-0455.2003.00007.x>

Total number of authors:
9

General rights

Unless other specific re-use rights are stated the following general rights apply:
Copyright and moral rights for the publications made accessible in the public portal are retained by the authors and/or other copyright owners and it is a condition of accessing publications that users recognise and abide by the legal requirements associated with these rights.

- Users may download and print one copy of any publication from the public portal for the purpose of private study or research.
- You may not further distribute the material or use it for any profit-making activity or commercial gain
- You may freely distribute the URL identifying the publication in the public portal

Read more about Creative commons licenses: <https://creativecommons.org/licenses/>

Take down policy

If you believe that this document breaches copyright please contact us providing details, and we will remove access to the work immediately and investigate your claim.

LUND UNIVERSITY

PO Box 117
221 00 Lund
+46 46-222 00 00

PERIPHERAL ARTERIAL DISEASE

Contrast-enhanced 3D MR angiography of the lower leg and foot compared with conventional angiography

C. N. CRONBERG¹, S. SJÖBERG², U. ALBRECHTSSON¹, P. LEANDER², M. LINDH², L. NORGRÉN³, P. DANIELSSON³, B. SONESSON³ and E.-M. LARSSON¹

¹Center for Medical Imaging and Physiology, University Hospital, Lund, Departments of ²Diagnostic Radiology and ³Vascular Surgery Malmö/Lund, University Hospital, Malmö, Sweden.

Abstract

Purpose: To determine whether contrast-enhanced 3D MR angiography (CE MRA) could replace digital subtraction angiography (DSA) for the evaluation of atherosclerotic peripheral vascular disease of the lower leg and foot.

Material and Methods: Thirty-five patients with symptoms of atherosclerotic disease of the leg were examined prospectively with CE MRA of the foot and the lower legs as well as with DSA from the aorta to the pedal arches. The MRA technique was focused on optimal imaging of the arteries of the foot.

Results: The agreement between CE MRA and DSA for grading of stenosis was moderate to good (weighted κ -values 0.48–0.80). The sensitivity of CE MRA for detection of significant stenosis ($\geq 50\%$) was 92% and the specificity was 64% with DSA as gold standard.

Conclusion: CE MRA is a fairly accurate method for the demonstration of atherosclerotic disease below the knee including the pedal arches. It can replace DSA for the assessment of distal arteries in patients with impaired renal function. However, image quality and resolution still needs to be improved before CE MRA can become the method of choice in all patients.

Key words: Lower leg, foot; arteries; MR angiography; digital subtraction angiography.

Correspondence: Elna-Marie Larsson, Center for Medical Imaging and Physiology, University Hospital, SE-221 85 Lund, Sweden.
FAX +46 46 211 69 56.
E-mail: elna-marie.larsson@drad.lu.se

Accepted for publication 4 October 2002.

Atherosclerotic occlusive disease of the lower extremity is common, not least in diabetic patients, in whom arterial lesions are frequently distributed in the distal arterial tree.

Digital subtraction angiography (DSA) has been the method of choice to assess the arterial tree for planning of revascularization. DSA is invasive and has intrinsic risks and complications (7, 11). It also uses iodinated contrast agent, potentially harmful to the kidneys (23). Contrast-enhanced MR angiography (CE MRA) is non-invasive and uses gadolinium-based contrast agents which have been

shown to lack clinically important nephrotoxicity even at higher intravenous doses (6, 16, 20). This makes it attractive for patients with underlying renal insufficiency, a common entity among diabetics. MRA can be performed as an out-patient procedure which reduces costs.

For preoperative planning, accurate information on vascular lesions as well as on the inflow and outflow situation is required (3).

Imaging of the arteries from the infrarenal aorta to the ankle with MRA is feasible. Unenhanced 2D time-of-flight (TOF) MRA, CE 3D MRA and bolus

chase techniques have been employed (2, 13, 14, 22). 2D TOF studies tend to exaggerate the length of stenoses (9) and thereby fail to properly image the outflow vessels. In addition, the saturation pulse used to suppress venous flow also suppresses arterial retrograde flow. Signal losses occur from in-plane saturation, turbulent triphasic and pulsatile flow and there are susceptibility effects in the region of surgical clips and vascular stents. Several studies show greater accuracy with CE MRA (1, 5, 12, 15, 19, 21, 24, 25). CE MRA depends on accurate timing of the acquisition sequences and the arrival of the contrast bolus and therefore needs no saturation pulses. It can better image retrograde flow and seems to display the extent of disease more adequately. CE MRA sequences are much faster than TOF sequences and thereby drastically shorten imaging times. This is very convenient as patients with atherosclerotic occlusive disease of the leg often have rest pain that prevents them from lying still during a long acquisition time. Short examination time is also necessary to make MRA a feasible alternative to X-ray angiography.

The purpose of this study was to determine whether CE MRA could replace DSA for the evaluation of atherosclerotic peripheral vascular disease of the lower leg and foot.

Material and Methods

In a prospective study, 35 patients were included. Twenty of them were investigated at the University Hospital, Lund, and 15 at the University Hospital MAS, Malmö. Among the 35 patients, 16 were men and 19 women. The median age was 77 years (range 50–98 years) and the mean age was 78 years. All patients were planned for DSA to reveal surgical reconstructive options. Thirty-two patients (91%) had critical limb ischemia (Table 1). The study was approved by the Ethical Committee of Lund University.

The patients were invited to undergo CE MRA before DSA, were told about the study and left their informed consent. DSA was never delayed because of MRA. The mean interval between MRA and

DSA was 12 days (range 4–57 days). Patients with previous ipsilateral arterial reconstruction and those with impaired renal function (creatinine/s > 150 µmol/l) were not included. Most of the patients were outpatients.

MRA: On arrival at the department of MRI, intravenous access was established. No premedication was given. The patients were placed in a supine position feet-first on the table. The knees and ankles were placed on cushions to keep the vessels of the lower leg approximately horizontal to enable inclusion into the coronal 3D imaging volume for the lower legs. The legs were not restrained but the patients were asked to remain still during image acquisition.

The examinations were performed on 1.5 T Siemens Magnetom Vision MR scanner.

A bolus test sequence with 1 image/s during 40 s was used to determine contrast travel time. The body coil was used and the test scan was centered at the knee. A contrast bolus of 2 ml gadodiamide (Omniscan, Amersham Health Inc.) followed by 40 ml saline was injected at a speed of 2 ml/s. At every step in the following, contrast was injected at 2 ml/s and always followed by injection of 40 ml saline, injected at the same speed. The circulation time was deduced from a graph displaying the arrival and concentration of contrast in the popliteal artery.

If no flow could be detected at the level of the knee, the bolus test scan was obtained at the most distal portion of the femoral artery that could be seen and the time delay for the imaging sequences was adjusted (adding 1 s time delay/every 8 cm above the knee).

The patient was then repositioned and the foot from which the patient had the most severe symptoms was placed in the head coil. Imaging was centered at the heel. Four scout sequences (transverse, sagittal, coronal, transverse) were followed by a 3D turbo MRA sequence in the sagittal plane without contrast injection. The first 10 patients were examined according to protocol A (Table 2). Turbo-MRA sequences then became available and were used in the remaining 25 patients (Table 2).

The sequence was repeated after contrast injection (0.2 mmol/kg). The time delay was calculated as

$$T_{\text{delay}} = T_{\text{circ}} - \text{scan time}/4 + 5$$

as suggested by the manufacturer, with our addition of 5 s for the delay between the popliteal artery and the foot.

For the crural vessels above the ankle the patient was repositioned, placed feet-first in the body coil. Imaging was centered 25 cm above the ankle. Four

Table 1

Fontaine classification

Grade		No. of patients
I	asymptomatic	0
II	claudication	3
III	rest pain	1
IV	tissue loss	31

Table 2
MRA sequences

	TR, ms	TE, ms	Flip angle, degrees	Matrix	Slab thickness, mm	Effective slice thickness, mm	FOV foot, sag, mm	Scan time foot, s	FOV lower leg, cor, mm	Scan time lower leg, s
Protocol A (10 patients)	7.8	2.1	30	512	70	2.5	300	37	500	42
Protocol B (turbo MRA) (25 patients)	6.8	2.1	25	512	70	1.94	300	32	500	32

TR = repetition time, TE = echo time, FOV = field of view, sag = sagittal, cor = coronal.

scout sequences (transverse, sagittal, coronal, coronal) were run and the time delay was calculated according to the formula

$$T_{\text{delay}} = T_{\text{circ}} - \text{scan time}/4$$

The same imaging sequence was used as for the foot, but now in the coronal plane and with a larger FOV (Table 2) including both legs. Contrast agent was administered at a dose of 0.1 mmol/kg and the sequence was repeated.

Three repeated acquisitions were performed after contrast injection at each station, foot and lower legs, respectively. The best arterial phase sequences were chosen for subtraction.

The total table-time was approximately 40 min.

In the beginning of the study, contrast medium was injected manually. From patient no. 12 on an automatic power injector (Spectris, Medrad) was used in Lund.

Subtracted maximum intensity projection (MIP) images were created in six standard projections each for the foot and lower leg. The projections were chosen to resemble those used with DSA. To make anatomical orientation easier, one unsubtracted image (providing osseous landmarks) was created in the sagittal plane for the foot and one in the coronal plane for the lower leg.

DSA: Angiography was performed on a Polydiagnost A (Philips) equipment in Lund and on a Polythron (Siemens AG) equipment in Malmö. Digital reconstruction and subtraction were performed. Contrast medium (Omnipaque, Amersham Health Inc.; and in some Malmö cases Hexabrix, Gothia) was injected with an automatic power injector (Mark IV, Medrad) or by hand. A contrast concentration of 300 mg I/ml was used.

In 25 cases the examination was performed after catheterization of the superficial femoral artery, either after antegrade puncture of the ipsilateral common femoral artery or from the contralateral side. In 10 patients, evaluation was made after contrast injection in the common iliac artery or in the aorta because of occlusion of proximal arteries. For DSA, catheters with an outer diameter of 1.7 mm (5 F), either straight or pigtail, were used.

Exposures were made over the thigh, knee, proximal and distal lower leg and foot in at least two projections at each site. Evaluation was made from printed non-subtracted and subtracted images.

Evaluation: The images obtained in Lund were evaluated at different sessions for CE MRA and DSA in consensus by one vascular surgeon, one radiologist especially dedicated to DSA and two radiologists with special interest in MRA. The images obtained in Malmö were evaluated in the same way by the same two MR radiologists together with the local surgeon and DSA radiologist. Thus, the two groups were not completely identical. When evaluating the DSA images, the groups were unaware of the CE MRA results and vice versa. For each patient and each modality the vessels were subdivided into 13 segments, and each segment was evaluated according to a four-graded scale modified after BAUM et al. (1) (Tables 3 and 4, Fig. 1).

Statistical analysis: The Mann-Whitney test was used to determine if there was any difference between the evaluations made by the reviewer groups in Lund and Malmö. κ -statistics were used as measure of agreement between CE MRA and DSA in the grading of the vessels.

Table 3

Vessel segments used for evaluation of MRA and DSA, modified after BAUM et al. (4) (Fig. 1)

Below-knee popliteal (1)	
Tibioperoneal trunk (2)	
Anterior tibial	proximal third (3) middle third (4) distal third (5)
Posterior tibial	proximal third (6) middle third (7) distal third (8)
Peroneal	proximal third (9) middle third (10) distal third (11)
Dorsal pedal arch (12)	
Plantar pedal arch (13)	

Table 4*Grading of the vessel segments modified after BAUM et al. (1)*

1. fairly normal	including all stenoses < 50%
2. stenosis of significance	one single lesion of $\geq 50\%$ and < 100% stenosis
3. diffusely diseased	multiple lesions with stenoses $\geq 50\%$
4. occluded	

Results

A total of 418 out of 455 arterial segments were successfully studied with both CE MRA and DSA and were included in this study. The missing segments belonged to 7 different patients and the reasons for their exclusion are described in Table 5.

The turbo MRA sequences used in protocol B (Table 2) had shorter scan times and used interpolation in the slice select direction decreasing the partition thickness. This resulted in smoother vessel contours on the MIP images, although the spatial resolution was not improved.

Our addition of 5 s for the delay between the popliteal artery and the foot proved quite accurate.

There was no significant difference between the evaluations made by the groups in Malmö and Lund ($p = 0.48$).

Out of the 418 evaluated segments, 302 (72%) were graded similarly (Fig. 2). In 54 segments (13%) the difference was only one grade; in 29 segments (7%) the difference was two grades; and in 23 segments (6%) the grading of the segments differed three grades.

The weighted and unweighted κ -values for the 13 segments used in our study were 0.48–0.80 and 0.30–0.80, respectively, i.e., agreement was moderate to good or fair to good (Table 6).

The results of the grading of all vessel segments on CE MRA and DSA are summarized in Table 7. DSA identified 247 segments with significant stenoses (50–100%), including 190 occluded segments. MRA reported 289 segments with significant stenoses, including 214 occluded segments. If DSA is regarded as the gold standard, MRA had 92% sensitivity for detection of significant stenosis or occlusion. The specificity of MRA was 64%. In 20 of the 129 segments classified as fairly normal by CE MRA, DSA reported significant stenosis and/or occlusion, i.e., CE MRA interpreted vessels as patent where DSA showed a lesion (Figs 3 and 4). In 11 of these segments, the previous segment had been assessed as occluded by both DSA and CE MRA. Of the remaining 9 segments, 5 were very distal (foot vessels) and 4 vessels of the lower leg

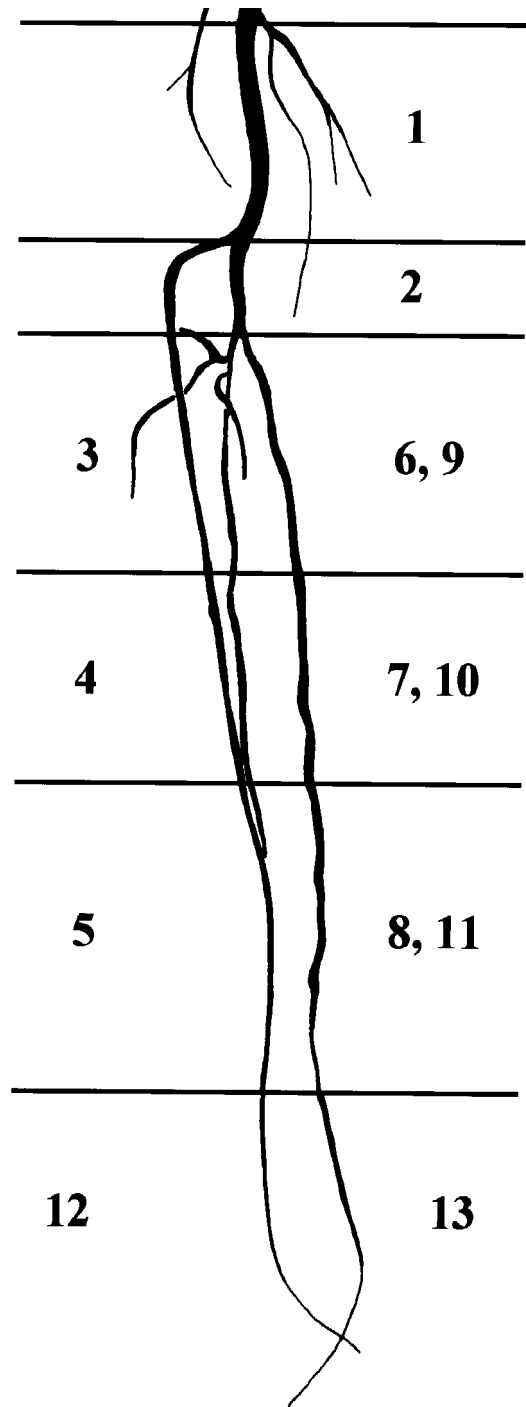


Fig. 1. Vessel segments used for evaluation of MRA and DSA (Table 3).

preceded by severely diseased vessel segments. Thirty-eight segments had significant stenosis (50–99%) on MRA but not on DSA (Fig. 4). Twenty-four segments were falsely thought to be occluded when imaged by CE MRA. Out of these, 13 segments referred to vessels of the foot or the distal third of the lower leg (segments 5, 8, 11, 12 or 13) (Table 3, Fig. 1).

Table 5*Reason for exclusion of vessel segments*

Patient	Reason for exclusion of vessel segment/s	Segments excluded	Segments used
L 1	First patient. Only foot/distal calf studied. by MRA.	8	5
L 12	Foot not studied by DSA.	2	11
L 18	Dorsal arch of the foot not examined by DSA.	1	12
L 19	Timing of the Gd failed for the lower leg.	11	2
M 11	Bad timing of Gd. Too much veins. Pedal arch not assessable.	1	12
M 12	Arterial flow occluded just below the knee. With the tip of the catheter just above the occlusion and hand injection of contrast medium DSA managed to depict vessels where MRA failed. Lower leg amputated shortly after.	13	0
M 15	For technical reasons DSA failed to image the middle part of the peroneal artery.	1	12

L = Lund, M = Malmö, e.g., L1 = Patient number 1, examined in Lund. Gd = The Gd-based contrast medium used for MRA.

Discussion

In order to find a minimally invasive method without use of iodinated contrast medium for the evaluation of the arteries of the lower limbs many MRA techniques have been tried. They can generally be divided into two groups – 2D time-of-flight (TOF) techniques and 3D CE MRA techniques. CE MRA techniques have advantages since the contrast enhancement reduces artifacts and imaging times. Signal-to-noise ratios are higher and spatial resolution better (18). Several previous studies have

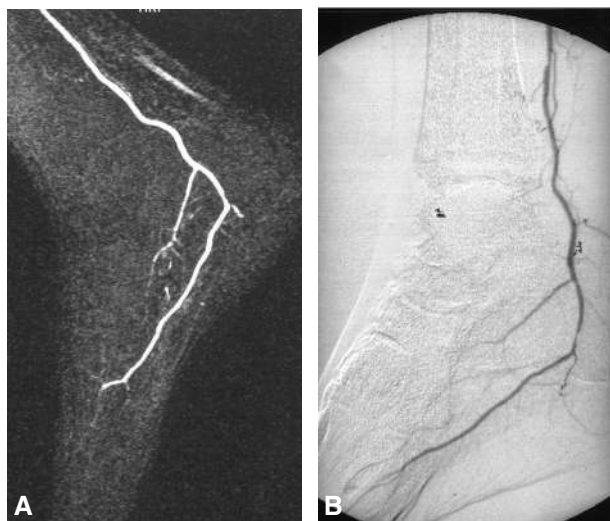


Fig. 2. A 73-year-old man with severe claudication of the right leg. A) CE MRA (sagittal MIP) of the foot. B) DSA (lateral view) of the foot. In this patient with very slow poor distal arterial flow, similar results are obtained with MRA and DSA.

Table 6*Agreement between MRA and DSA in grading of the different vessel segments*

Segment	Weighted k-value	Unweighted k-value
1	0.79	0.45
2	0.69	0.52
3	0.74	0.67
4	0.81	0.69
5	0.62	0.43
6	0.68	0.56
7	0.76	0.64
8	0.80	0.80
9	0.54	0.38
10	0.51	0.41
11	0.48	0.30
13	0.62	0.47

Table 7*Summary of grading of all vessel segments with CE MRA and DSA*

No. of vessel segments	DSA +	DSA –	Total no.
CE MRA +	227	62	289
CE MRA –	20	109	129
Total no.	247	171	418

DSA +: Stenosis/es \geq 50% and/or occlusion on DSA.

DSA –: Normal or stenosis/es < 50% on DSA.

CE MRA +: Stenosis/es \geq 50% and/or occlusion on CE MRA

CE MRA –: Normal or stenosis/es < 50% on CE MRA.

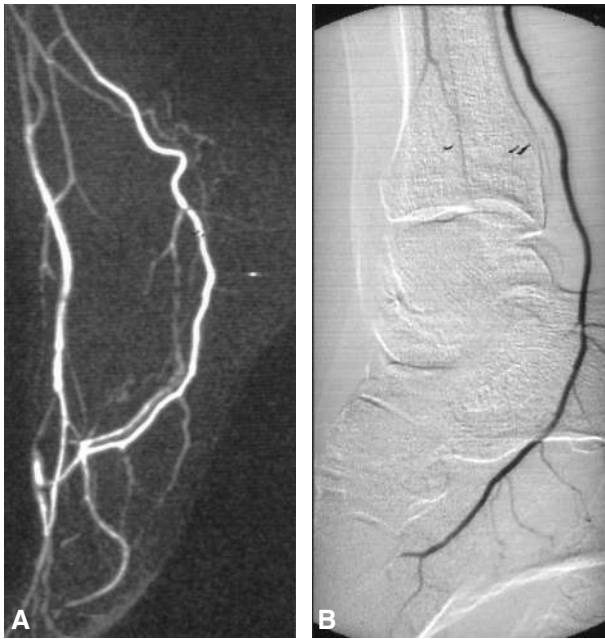


Fig. 3. A 54-year-old man with claudication of the right leg. A) CE MRA (sagittal MIP) of the foot. B) DSA (lateral view) of the foot. MRA shows patency of the dorsal arch whereas the dorsal vessels are not filled on DSA.

shown accurate imaging of the vessels of the leg from the aorta to the ankle with CE MRA (8, 12, 18) but few studies have successfully imaged the very small and distal, but very important, runoff vessels of the foot (4, 21). We focused our interest in this area in the present study.

The most distal vessels of the leg and foot were well depicted even though our patients had rather severe occlusive peripheral vascular disease (Table 1). In some previous studies the patients had less severe disease (25), and thereby less pronounced vascular lesions.

The best agreement was noted for the proximal and middle portions of the anterior tibial artery and the middle and distal portions of the posterior tibial artery (Table 6).

The sensitivity of CE MRA to detect significant stenosis or occlusion was 92% with DSA as gold standard. The specificity for CE MRA was 64%. The 20 vessel segments classified as less severely diseased by CE MRA were preceded by occlusions or severely diseased vessel segments, or were distal foot vessels. Thus, MRA was correct in these segments with slow or delayed flow, whereas DSA did not show any flow (Fig. 3). It could therefore be discussed if the use of DSA as gold standard is correct (10). Out of the 38 segments where MRA

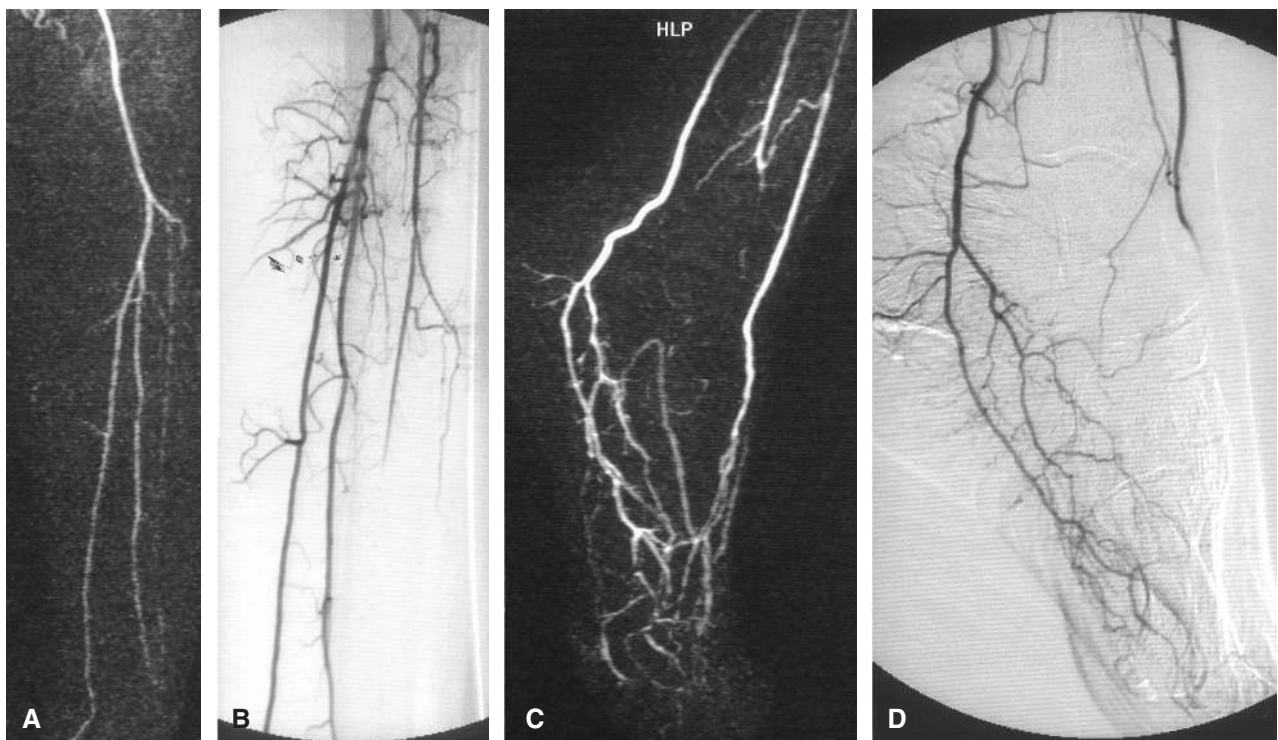


Fig. 4. A 75-year-old woman with critical ischemia of the left foot. A) and C) CE MRA of the lower leg (coronal MIP) and foot (sagittal MIP). B) and D) DSA of the lower leg (frontal view) and foot (lateral view). The flow in the anterior tibial artery is not as well shown in the CE MRA (coronal MIP) (A) as with DSA (B) MRA (C) shows flow in the dorsal arch of the foot, which is not seen on DSA (D).

found significant stenosis while DSA did not, 17 followed low flow. In the remaining 21 segments, there was no apparent reason for the mismatch. However, these segments were situated at the edge of the MRA FOV, which may have decreased the possibility to evaluate the region proximal or distal to the stenosis. Overestimation of stenosis by MRA could in the calf be due to the limited spatial resolution and signal-to-noise ratio of body coil imaging in agreement with other reports (26) (Fig. 4).

The addition of 5 s for the delay time between the popliteal artery and the foot was estimated, but proved to be accurate and is in agreement with the observations made by PRINCE et al. (17).

The major limitations of our study are that we have used a triple-dose Gd-based contrast agent and still have imaged only the peripheral vasculature below the knee. We chose to do so to obtain optimal images of the pedal vessels. This technique could be used in combination with duplex ultrasonography of the proximal vessels of the leg when the disease is suspected to be distal. However, duplex has its limits as it is operator-dependent, cannot produce 3D images and does not provide an anatomic chart with landmarks familiar to the vascular surgeon. Our method for MRA of the foot could potentially be combined with faster sequences with higher spatial resolution and bolus chase with moving table technique (12).

The combination of our head coil-method with double-dose contrast agent to image the foot followed by single-dose moving table methods to acquire images of the more proximal parts of the arterial tree may prove to be useful for patients with distal vascular disease.

In order to achieve optimal spatial resolution, we only examined one foot in each patient. Most patients have more pronounced symptoms from one limb. Both feet can be placed in the head coil, but this is very uncomfortable for the patient. Dedicated coils may solve this problem. MRA allows retrospective image manipulation with construction of MIP projections from any angle, whereas DSA requires a new examination with contrast injection for every new projection.

In conclusion, CE MRA is a fairly accurate method for selective demonstration of arterial lesions below the knee, including the pedal arches. However, the image quality and spatial resolution still need to be improved to replace DSA in the routine evaluation of the arteries of the lower leg and foot. CE MRA has already a role for the pre-operative assessment of patients with diabetes and impaired renal function suffering from peripheral arterial disease.

ACKNOWLEDGMENT

Amersham Health Inc. provided the contrast agent Omniscan for this study.

REFERENCES

1. Baum RA, Rutter CM, Sunshine JH et al. Multicenter trial to evaluate vascular magnetic resonance angiography of the lower extremity. *JAMA* 1995; 274: 875.
2. Carpenter JP, Owen RS, Baum RA. Magnetic resonance angiography of peripheral runoff vessels. *J. Vasc. Surg.* 1992; 16: 807.
3. Dardik H, Ibrahim IM, Sussman B. Morphologic structure of the pedal arch and its relationship to patency of crural vascular reconstruction. *Surg. Gynecol. Obstet.* 1981; 152: 645.
4. Goyen M, Quick HH, Debatin JF et al. High resolution whole body 3D MR angiography (AngioSURF): Initial clinical experience. *Proc. Int. Soc. Magn. Reson. Med.* 2001; 9: 45.
5. Grist TM. MRA of the abdominal aorta and lower extremities. *J. Magn. Reson. Imaging* 2000; 11: 32.
6. Haustein J, Niendorf HP, Krestin G. Renal tolerance of gadolinium-DTPA/dimeglumine in patients with chronic renal failure. *Invest. Radiol.* 1992; 27: 153.
7. Hessels SJ, Adams DF, Abrams HL. Complications of angiography. *Radiology* 1981; 138: 2273.
8. Ho K, Leiner T, De Haan M, Kessels AG, Kitslaar PJ, van Engelshoven JM. Peripheral vascular tree stenoses: evaluation with moving-bed infusion tracking MR angiography. *Radiology* 1998; 206: 683.
9. Kaufman JA, McCarter D, Geller SC, Waltman AC. Two-dimensional time-of-flight MR angiography of the lower extremities: artifacts and pitfalls. *AJR* 1998; 171: 129.
10. Kreitner KF, Kalden P, Neufang A et al. Diabetes and peripheral arterial occlusive disease: prospective comparison of contrast-enhanced three-dimensional MR angiography with conventional digital subtraction angiography. *AJR* 2000; 174: 171.
11. Lang EK. A survey of the complications of percutaneous retrograde arteriography. *Radiology* 1963; 81: 257.
12. Meaney JFM, Ridgway JP, Chakraverty S et al. Steppable gadolinium-enhanced digital subtraction MR angiography of the aorta and lower extremity arteries: preliminary experience. *Radiology* 1999; 211: 59.
13. Owen RS, Carpenter JP, Baum RA, Perloff LJ, Cope C. Magnetic resonance imaging of angiographically occult runoff vessels in peripheral arterial occlusive disease. *N. Engl. J. Med.* 1992; 326: 1577.
14. Owen RS, Baum RA, Carpenter JP, Holland GA, Cope C. Symptomatic peripheral vascular disease. selection of imaging parameters and clinical evaluation with MR angiography. *Radiology* 1993; 187: 627.
15. Poon E, Yucel EK, Pagan-Marin H, Kayne H. Iliac artery stenosis measurements. comparison of two-dimensional time-of-flight and three-dimensional dynamic gadolinium-enhanced MR angiography. *AJR* 1997; 169: 1139.
16. Prince MR, Arnoldus C, Frisoli JK. Nephrotoxicity of high dose gadolinium compared with iodinated contrast. *J. Magn. Reson. Imaging* 1996; 6: 162.
17. Prince MR, Wang Y, Watts R, Chen C. Contrast travel times measured on 2D projection MRA in patients with peripheral vascular disease. *Proc. Int. Soc. Magn. Reson. Med.* 2001; 9: 47.
18. Quinn SF, Sheley RC, Semonsen KG, Leonardo VJ, Kojima K, Szumowski J. Aortic and lower-extremity arterial disease: evaluation with MR angiography vs. conventional angiography. *Radiology* 1998; 206: 693.
19. Quinn SF, Sheley RC, Szumowski J, Shimakawa A. Evaluation of the iliac arteries: comparison of two-

- dimensional time of flight magnetic resonance angiography with cardiac compensated fast gradient recalled echo and contrast-enhanced three-dimensional time of flight magnetic resonance angiography. *J. Magn. Reson. Imaging* 1997; 7: 197.
20. Rofsky NM, Weinreb JC, Bosniak MA, Libes RB, Birnbaum BA. Renal lesion characterization with gadolinium-enhanced MR-imaging. efficacy and safety in patients with renal insufficiency. *Radiology* 1991; 180: 85.
 21. Rofsky NM, Adelman MA. MR angiography in the evaluation of atherosclerotic peripheral vascular disease. *Radiology* 2000; 214: 325.
 22. Scheibler ML, Listerud J, Baum RA. Magnetic resonance angiography of the pelvis and the lower extremities. *Magn. Reson. Q.* 1993; 9: 152.
 23. Shehadi WH. Contrast media adverse reactions: occurrence, recurrence, and distribution pattern. *Radiology* 1982; 143: 11.
 24. Snidow JJ, Aisen AM, Harris VJ. Iliac artery MR angiography. Comparison of three-dimensional gadolinium-enhanced and two-dimensional time-of-flight techniques. *Radiology* 1995; 196: 371.
 25. Sueyoshi E, Sakamoto I, Matsuoka Y et al. Aortoiliac and lower extremity arteries: comparison of three dimensional dynamic contrast-enhanced subtraction MR angiography and conventional angiography. *Radiology* 1999; 210: 683.
 26. Winterer JT, Schaefer O, Uhrmeister P et al. Contrast enhanced MR angiography in the assessment of relevant stenoses in occlusive disease of the pelvic and lower limb arteries: diagnostic value of a two-step examination protocol in comparison to conventional DSA. *Eur. J. Radiol.* 2002; 41: 153.