

Received: 2014.03.08
Accepted: 2014.03.24
Published: 2014.07.10

Peripheral primitive neuroectodermal tumor of the dura in a 51-year-old woman following intensive treatment for breast cancer

Authors' Contribution:

Study Design A
Data Collection B
Statistical Analysis C
Data Interpretation D
Manuscript Preparation E
Literature Search F
Funds Collection G

EFG 1 **Marion Cole***
EF 2 **Shobha Parajuli***
E 3 **Douglas Laske**
E 1 **Lori Goldstein**
E 1 **Tara Morrison**
E 2 **Abir Mukherjee**
E 1 **Kathryn Tumelty**
E 1 **Eric Tetzlaff**
E 1 **Margaret von Mehren**
E 2 **Susan Inniss**

1 Department of Medical Oncology, Fox Chase Cancer Center, Philadelphia, PA, U.S.A.

2 Department of Pathology and Laboratory Medicine, Temple University Hospital, Philadelphia, PA, U.S.A.

3 Department of Neurosurgery, Temple University School of Medicine, Philadelphia, PA, U.S.A.

* Both authors have contributed equally to this article

Corresponding Author: Marion Cole, e-mail: marioncole@nvoncology.com

Conflict of interest: None declared

Patient: Female, 51
Final Diagnosis: Ewing sarcoma
Symptoms: Visual disturbances
Medication: —
Clinical Procedure: —
Specialty: Oncology

Objective: Rare disease


Background: Primitive neuroectodermal tumor/Ewing sarcoma (PNET/EWS) is a round blue cell sarcoma that shows varying degrees of neuroectodermal differentiation. PNET/EWS as a primary intracranial tumor is extremely uncommon.

Case Report: We report a unique case of peripheral PNET presenting as an intracranial mass in an adult following chemotherapy and radiotherapy for a solid tumor. A 51-year-old woman with previously treated left breast cancer was evaluated for a newly developed brain mass. She underwent craniotomy with resection. Surgical pathology was consistent with a peripheral PNET/EWS with Ewing sarcoma gene translocation. She was treated appropriately with vincristine, cyclophosphamide, and doxorubicin (later dactinomycin) alternating with ifosfamide and etoposide.

Conclusions: Although development of PNET/EWS presenting along the CNS is exceedingly rare in adults, establishing the proper diagnosis of this "small blue cell tumor" is critical. The further distinction between central PNET and peripheral PNET can greatly impact both prognosis and treatment. Our case also highlights the importance of considering the impact of prior intensive therapies, including radiation and chemotherapy, on predisposing to future PNET/EWS.

MeSH Keywords: Central Nervous System • Neuroectodermal Tumors, Primitive, Peripheral • Sarcoma, Ewing

Full-text PDF: <http://www.amjcaserep.com/abstract/index/idArt/890656>



1965



1



2



15



Background

Primitive neuroectodermal tumor/Ewing sarcoma (PNET/EWS) is a rare family of malignancies that comprises Ewing sarcoma of bone, extraskeletal Ewing sarcoma, peripheral primitive neuroectodermal tumor (pPNET), and Askin tumor [1]. Histologically, these tumors are small round cells showing varying degrees of neuroectodermal differentiation. Ewing sarcoma describes tumors that lack evidence of neuroectodermal differentiation, whereas PNET describes tumors that demonstrate neuroectodermal features. PNET/EWS characteristically expresses fusion of the EWSR1 gene (22q12) with a member of the ETS gene family, including FLI1 (11q24), ERG (21q22), ETV1 (7p22), ETV4 (17q12), and FEV (2q36). They often present in the diaphysis or the metaphyseal-diaphyseal portion of long bones and deep in soft tissues early in life and are extremely uncommon in adults over 30 years of age, with peak incidence at age 15 [2]. The central nervous system (CNS), however, is an uncommon site of primary disease or metastasis [3]. PNET originating in the CNS (cPNET) usually occurs in children but only sporadically in adults. It accounts for approximately 2.5% of brain tumors in children and 0.46% in adults [4]. We report a rare case of an extra-axial pPNET involving the dura in a female with a prior history of stage III breast cancer. She presented 10 years after breast cancer treatment with a parieto-temporal mass initially suspicious for metastatic breast cancer.

Case Report

In March 2012, a 51-year-old woman presented with new-onset symptoms of visual disturbances not attributable to structural changes of the eye. She denied headache, nausea, vomiting, seizures, or loss of consciousness. A magnetic resonance imaging (MRI) scan of the brain demonstrated an extra-axial-appearing, 3.5×3 cm, heterogeneously enhancing, left parieto-temporal mass. There was visible mass effect on the adjacent brain parenchyma, as well as associated vasogenic edema and effacement of the left lateral ventricle without midline shift (Figure 1). Nuclear bone scan and computerized tomography (CT) scan of the chest, abdomen, and pelvis were negative for metastatic disease.

The patient's past medical history dates back to June 2002 when she was diagnosed with stage IIIA (T1N2M0, AJCC 6th TNM staging system) invasive ductal carcinoma of the left breast, ER/PR (estrogen, progesterone receptors) positive and Her2 (human epidermal growth factor receptor 2) negative. She was treated with a modified radical mastectomy followed by adjuvant dose-dense doxorubicin, cyclophosphamide, and paclitaxel, and completed postoperative radiation therapy to the left chest wall and axilla in March 2003. She received adjuvant endocrine therapy with tamoxifen until April 2008 followed by letrozole and monthly goserelin injections.

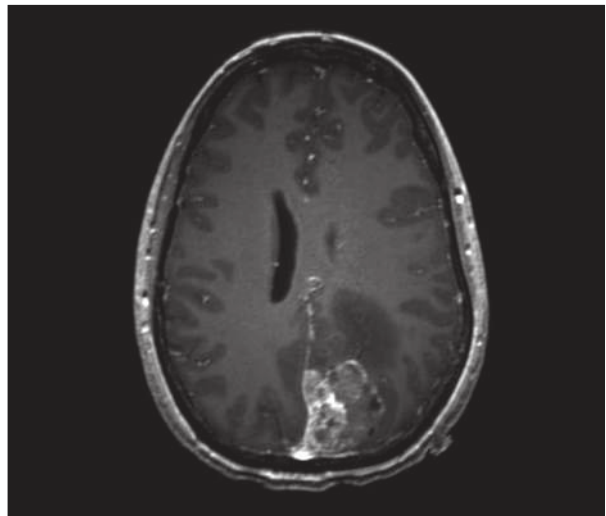


Figure 1. Axial T1 post gadolinium enhanced image of the brain revealing a dural based heterogeneously enhancing mass with surrounding vasogenic edema.

The patient's family history was significant for a paternal grandmother with breast cancer who died at age 72, a paternal aunt with breast cancer diagnosed at age 56, and a mother diagnosed with lung cancer at age 50 believed to be secondary to radon exposure. The patient had previously worked as a hospital technician in a blood bank and had no exposures to chemicals in the past.

Upon discovery of the brain mass, the patient underwent a left parieto-occipital craniotomy with resection. Intraoperative histopathologic evaluation of the resected tissue revealed diffuse sheets of tumor cells with monomorphic appearance. However, permanent sections showed a malignant small round blue cell neoplasm with primitive-appearing and undifferentiated cells in a diffuse pattern displaying a brisk mitotic rate as well as necrosis. Many cells had clear cytoplasm and PASD (periodic acid-Schiff with diastase) stain confirmed the presence of glycogen. The findings were consistent with a Ewing sarcoma family tumor (Figure 2).

Immunohistochemistry (IHC) staining showed a strong and diffuse positivity for membranous CD99, vimentin, and S100, as well as moderate positivity for synaptophysin and neuron specific enolase (NSE) (Figure 2). The tumor cells were negative for keratins (AE1/AE3, CAM 5.2, CK903, CK7, CK20), EMA, CD45, BRST-2, ER, TTF-1, Melan-A, HMB-45, chromogranin, CD56, CD57, SMA, desmin, and GFAP. Although Homer-Wright rosettes were not prominent, the uniform membranous positivity for CD99 and for synaptophysin and S100 pointed toward a diagnosis of pPNET. The molecular analysis with fluorescence *in situ* hybridization (FISH) testing using a EWS break-apart probe was positive, thus confirming the diagnosis of Ewing sarcoma.

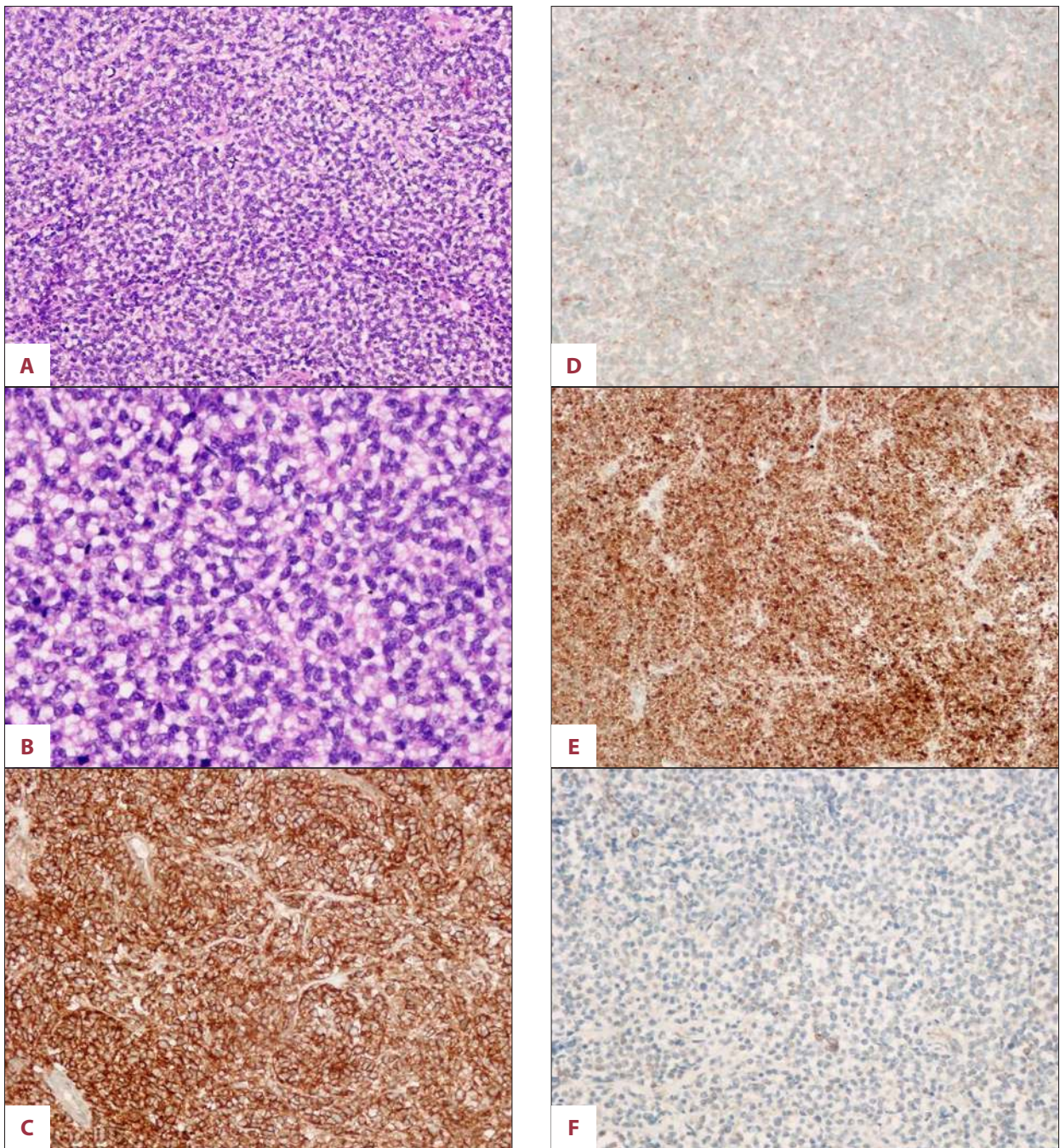


Figure 2. Histopathological and immunohistochemical findings of the tumor. (A, B) Small round blue cell neoplasm with primitive-appearing and undifferentiated cells displaying mitotic figures (hematoxylin and eosin; 20× and 40× respectively). (C) Strong membranous positivity with CD99 (20×). (D) Moderate positivity with synaptophysin (20×). (E) Strong positivity with S-100 (20×). (F) Moderate positivity with NSE (20×).

Postoperative MRI of the cervical, thoracic, and lumbar spine, as well as bone marrow aspirate and biopsies, showed no evidence of disease. Chemotherapy was initiated with vincristine, cyclophosphamide, and doxorubicin alternating with ifosfamide and etoposide. After completion of 3 cycles of chemotherapy, a repeat multigated acquisition (MUGA) scan revealed an

asymptomatic decreased ejection fraction from 50.4% to 41.9%, despite use of dexrazoxane. Upon initiation of cycle number 4, doxorubicin was discontinued in favor of dactinomycin. In addition, the patient required a 20% dose reduction of all agents due to hematologic toxicities. The patient completed 14 cycles of chemotherapy from April 2012 through January 2013.

Table 1. Differences between pPNET of the Dura and cPNET.

	pPNET	cPNET
Cell of origin	Neural crest cells located outside the CNS	Precursor cell of the subependymal matrix of the CNS
Presentation	Spreading along meninges without a primary meningeal or parenchymal tumor	Largely localized to the CNS with rare metastases elsewhere
Immunohistochemistry	Well circumscribed dural mass (+) CD99, synaptophysin, NSE, vimentin, S100, neurofilament	Involvement of the CSF in 10–30% of cases (+) synaptophysin, neurofilament, Neu-N, GFAP, INI-1
Staging	CT or PET/CT MRI Bone Marrow Biopsy	CT or PET/CT MRI Lumber puncture
Genetics	Chromosomal translocation: t(11,22)(q24;q12)	Increased expression of MYCN or MYCC genes Polysomies of chromosomes 2 and 8 Isochromosome 17q; losses of chromosomes 6q, 9p, 10q, 11 and 16q; trisomy-1q; and mutations of TP53
Treatment (excluding surgical resection)	Systemic chemotherapy with doxorubicin, vincristine, and cyclophosphamide, alternating with ifosfamide and etoposide as well as radiation	Intrathecal methotrexate followed by systemic chemotherapy with platinum agents, etoposide, lomustine, and vincristine as well as radiation
Longterm prognosis (5–7.5 years)	Localized disease: 50–70% Overall survival: 45–60%	Localized disease: 50–70% Overall survival: 33%

Radiation therapy was not considered because the resection was complete, and there was no evidence of residual disease in the postoperative imaging studies. She is now being monitored every 3 months, with no evidence of recurrence to date.

Discussion

In 1973, Hart and Earle coined the term “primitive neuroectodermal tumor” [5]. PNET is a broad term that includes poorly differentiated or undifferentiated small round cell tumors of neuroectodermal origin [5,6]. While PNET/EWS can affect both the central and peripheral nervous systems, pPNET needs to be distinguished from cPNET. PNETs have morphological attributes of germinal neuroepithelium [6]. Table 1 outlines the differences between these 2 entities. cPNETs arise from a precursor cell of the subependymal matrix of the CNS/precursor cells present in the external granular layer of the cerebellum, pinealocytes, and the subependymal cells of the ventricular system, whereas pPNETs derive from the neural crest located outside the CNS [7,8]. pPNETs occur in meninges of the cranial

vault, of which the dura is the outermost layer, and in the epidural space of the spinal canal [6,7].

These separate entities differ not only in their cell of origin but also their presentation, treatment, and prognosis. Both cPNETs and pPNETs are aggressive tumors. However, cPNETs remain largely localized to the CNS with rare metastases elsewhere. cPNETs also involve the cerebrospinal fluid (CSF) in 10–30% of cases at the time of diagnosis [7].

In a patient with a history of breast cancer, the most common lesion in the brain is a metastasis rather than primary CNS malignancy; indeed, 20–30% of all brain metastases arise from breast cancer. Our case is a rare example of primary pPNET arising in the dura. Upon review of the databases from PubMed, Ovid, and EBSCO, 141 cases of primary intraspinal extraskeletal Ewing sarcoma/pPNET were found from 1969 to 2011 [9].

Unlike cPNETs, pPNETs express large amounts of MIC2 antigen (CD99) and the chromosomal translocation of the EWS gene with transcription factors, leading to abnormal activation of

the EWS gene. Chromosomal translocation (EWS-FLI1 gene) of chromosome t(11,22) (q24;q12) is a characteristic and unique feature of PNET/EWS, leading to oncogenesis. The chromosomal translocation t(11,22) (q24;q12) is apparent in 80–95% of pPNETs [6,7]. In addition, cPNETs have increased expression of MYCN or MYCC genes and polysomies of chromosomes 2 and 8, which may in part account for their more aggressive behavior [4].

In this case, both CT and MRI were used to better characterize the tumor. PNET/EWS on CT appears hyperdense compared to the surrounding gray matter. On MRI, it appears iso-to-hypointense on noncontrast T1-weighted sequences and hypo-to-hyperintense on T2-weighted sequences. It demonstrates enhancement after administration of gadolinium contrast. Areas of hemorrhage and cystic changes can also be seen in MRI [8]. Fludeoxyglucose positron emission tomography (FDG-PET) scan or bone scan can be used for systemic staging. Our patient had a negative bone scan result. Bilateral bone marrow biopsies should be performed as part of staging for pPNET, as metastasis to the bone marrow portends a worse prognosis. These were performed for our patient and were without evidence of metastasis. A lumbar puncture is useful in cPNET because the cerebral spinal fluid (CSF) can be affected, but it is not required for pPNET staging.

Making the distinction between cPNETs and pPNETs is essential because of the implications for treatment and overall prognosis. A long-term survival (7.5 years) of 45–60% was noted for pPNET patients [3]. cPNET patient survival was much shorter, with a 3-year survival in 1 review of 33 cases of only 33% [4,8]. Other studies [8] have shown an estimated 5-year survival of 77% in pPNET, compared with 44% in cPNET. In localized disease, however, a similar 5-year survival in pPNETs and cPNETs of 50–70% has been seen in multi-center randomized clinical trials [7]. Our case involved a tumor presenting as a dural mass. This may have implications for survival, as a well-circumscribed dural mass is more amenable to surgical resection than a tumor with extensive spread. Curative treatment for both the localized cPNETs and pPNETs involves adequate surgical resection followed by aggressive chemotherapy. In the case of pPNETs, the systemic chemotherapy includes the agents used for our patient. cPNETs are treated with intrathecal methotrexate as well as systemic chemotherapy, including platinum agents, etoposide, lomustine, and vincristine [3]. In contrast to pPNET, entire neuraxis radiation is used in children with cPNET [7].

Typically, PNETs present in childhood. In addition to pPNET being an exceedingly rare tumor, its presentation in this case is unique as well. Our patient is much older than the average patient with this tumor type, presenting at age 51. Interestingly, she was also treated 10 years prior for an aggressive but

curable breast cancer. This treatment could potentially have led to unrecognized mutations predisposing her to a second malignancy [10].

Reports of PNET in children and adults following chemotherapy, including alkylating agents and radiotherapy [11–13] as treatment for leukemias or lymphomas, have been published. The Childhood Cancer Survivor Study reported the standardized incidence ratio and excess absolute risk for secondary Ewing's sarcoma of 6.7 (95% confidence interval (CI) 2.5–17.8) and 9.3 (95% CI 5.3–24.0), respectively. The report also indicates that of the 49 secondary cases of Ewing's sarcoma, 12 arose in patients with a primary breast cancer. As this was a study of children with cancer, it is likely that primary breast cancer would have been related to an inherited disorder, such as Li Fraumeni, rather than being *de novo*.

Other risk factors for PNET/EWS include a possible genetic predisposition. Those individuals with Li-Fraumeni syndrome with germline p53 mutations have an increased risk for breast cancer and sarcoma [14]. One study of 525 patients, of which 91 were identified as having germline p53 mutations, showed a 35% incidence of breast cancer and a 26% incidence of sarcoma. Although our patient had family members diagnosed with malignancies, there was no obvious hereditary syndrome. Alternatively, our patient may have a *de novo* mutation, given the young age at diagnosis of breast cancer.

Although our patient did not have a history of smoking, her mother died at age 50 of lung cancer and both the patient and her mother had had exposure to radon. Radon has been associated with an increased risk of lung malignancy, although there is no known association with sarcoma [15].

Conclusions

Though brain metastasis is common in patients with prior history of malignancy, one must also consider the diagnosis of a new primary cancer, especially in those with aggressive prior treatment. pPNET arising in the dura is extremely rare and thus can be difficult to distinguish from cPNET. The distinction between these diagnoses is critical in terms of both prognosis and therapy. The Ewing's sarcoma family of tumors has been increasingly reported as a secondary cancer, particularly after treatment for childhood leukemias and lymphomas. Our case illustrates a rare example of a dural pPNET as a new primary malignancy in a patient previously treated with radiation and chemotherapy for breast cancer. Clinicians should be aware that PNET/EWS can occur in adults following chemotherapy and/or radiotherapy and it should be added to the differential diagnoses when faced with a "small blue cell tumor."

References:

1. Javery O, Krajewski K, O'Regan K et al: A to Z of Extraskelatal Ewing sarcoma family of tumors in adults: imaging features of primary disease, metastatic patterns, and treatment responses. *Am J Roentgenol*, 2011; 197: W1015-22
2. Ushigome S, Machinami R, Sorensen PH: Ewing sarcoma/Primitive neuroectodermal tumour (PNET). In: Fletcher CDM, Unni KK and Mertens F, eds. *World Health Organization classification of tumours pathology and genetics of tumours of soft tissue and bone*. Lyon, France: IARC Press, 2002: 298-300
3. Dedeurwaerdere F, Giannini C, Sciot R et al: Primary peripheral PNET/Ewing's sarcoma of the dura: a clinicopathologic entity distinct from central PNET. *Mod Pathol*, 2002; 15: 673-78
4. Ašmonienė V, Skiriutė D, Gudinaičienė I et al: A primary primitive neuroectodermal tumor of the central nervous system in a 51-year-old woman: a case report and literature review. *Medicina (Kaunas)*, 2011; 4(8): 440-45
5. Hart MN, Earle KM: Primitive neuroectodermal tumors of the brain in children. *Cancer*. 1978; 32: 890-97
6. Mobley BC, Roulston D, Shah GV et al: Peripheral primitive neuroectodermal tumor/Ewing's sarcoma of the craniospinal vault: case reports and review. *Human Pathology*, 2006; 37: 845-53
7. Kampman WA, Kros JM, De Jong TH, Lequin MH: Primitive neuroectodermal tumors (PNETs) located in the spinal canal; the relevance of classification as central or peripheral PNET: case report of a primary spinal PNET occurrence with a critical literature review. *J Neurooncol*, 2006; 77: 65-72
8. Karikari IO, Mehta AI, Nimjee S et al: Primary intradural extraosseous Ewing sarcoma of the spine: case report and literature review. *Neurosurgery*, 2011; 69(4): 995-99
9. Saeedinia S, Nouri M, Alimohammadi M et al: Primary spinal extradural Ewing's sarcoma (primitive neuroectodermal tumor): report of a case and meta-analysis of the reported cases in the literature. *Surg Neurol Int*, 2012; 3: 55
10. Cole M, Strair R: Acute myelogenous leukemia and myelodysplasia secondary to breast cancer treatment: case study and literature review. *Am J Med Sci*, 2010: 36-40
11. Applebaum M, Goldsby R, Neuhaus J, DuBois SG: Clinical features and outcomes in patients with secondary Ewing sarcoma. *Pediatr Blood Cancer*, 2013; 60: 611-15
12. Lim S, Lee JY, Lee JY et al: Unusual presentation of Ewing sarcoma in the adrenal gland: a secondary malignancy from a survivor of Burkitt lymphoma. *Jpn J Clin Oncol*, 2013: 1-5
13. Friedman D, Whitton J, Leisenring W et al: Subsequent neoplasms in 5-year survivors of childhood cancer: the childhood cancer survivor study. *J Natl Cancer Inst*, 2010; 102: 1083-95
14. Gonzalez K, Noltner K, Buzin C et al: Beyond Li Fraumeni syndrome: clinical characteristics of families with p53 germline mutations. *J Clin Oncol*, 2009; 27: 1250-56
15. Sethi TK, El-Ghamry MN, Kloecker GH: Radon and lung cancer. *Clin Adv Hematol Oncol*, 2012; 10: 157-64